

FACTS, VIEWS & VISION

Journal of the European Society for Gynaecological Endoscopy (ESGE)

in ObGyn

Volume 11, Supplement 1, 2019

SUPPLEMENT I

Abstracts of the ESGE 28th Annual Congress | 6-9 October 2019 | Thessaloniki | Greece

ESGE 28th Annual Congress


6th – 9th October 2019 · Thessaloniki · Greece



www.esge.org

Official Abstracts Publication

Primum non nocere: Maintain safety
while pushing the boundaries



Ωφελείειν ή μη βλάπτειν

Hippocrates, 4th century B.C.



www.esgecongress.eu

BEST SELECTED ABSTRACTS (26)

ES28-0452 - Best Selected Abstracts 1

The endometrial expression of LIF and LIFR in infertile patients with uterine pathology during the window of implantation

Irena Kozachenko¹, Nafisa Fayzulina², Aleksander Shegolev², Leila Adamyan¹

¹National Medical Research Center for Obstetrics- Gynecology and Perinatology of the Ministry of Health of Russia, Operative Gynecology, Moscow, Russia

²National Medical Research Center for Obstetrics- Gynecology and Perinatology of the Ministry of Health of Russia, Pathomorphology, Moscow, Russia

Background

Adenomyosis, myoma, uterine malformations, synechia, and polyps were found to have negative impact on embryo implantation. Leukaemia inhibitory factor (LIF), is a molecular marker for endometrial receptivity, and has an effect through the LIF receptor (LIFR) on both the embryo and the endometrium site. The aim of our study was to evaluate the endometrial expression of LIF and LIFR in patients with adenomyosis, myoma, uterine malformations, synechia and polyps during the window of implantation (WOI).

Methods

Endometrium was obtained during the WOI from infertile patients of reproductive age planning IVF with adenomyosis (10 patients), myoma (10 patients), uterine malformations (10 patients), synechia (10 patients) and polyps (10 patients) before and after surgery. In the comparative group were 10 patients with tubal factor of infertility and without any uterine pathology. The LIF and LIFR expressions were measured by immunohistochemistry for protein intensity and localisation.

Results

The mean age of the patients was as follows: adenomyosis (35,9±0,5 years), myoma (36,2±5,2), uterine malformations (29,0±5,1), synechia (34,2±0,7) and polyps (32, 8±1,7). Patients with adenomyosis, myoma, uterine malformations, synechia and polyps showed significantly and parallel reduced LIF and LIFR expressions in the eutopic endometrium during WOI as compared with the control group. An increase in the level of expression of LIF and LIFR was observed after surgery, which correlated with positive results of IVF.

Conclusions

Significant reduction of LIF and LIFR expression as markers of endometrial receptivity explains the negative impact of adenomyosis, myoma, uterine malformations, synechia and polyps on implantation processes and hence the results of IVF.

ES28-0120 - Best Selected Abstracts 1

The long-term follow-up including reproductive outcomes after laparoscopic resection of large symptomatic niches in the uterine caesarean scar

Jolijn Vissers¹, Anke Vervoort², Wouter Hehenkamp³, Hans Brölmann², Judith Huirne²

¹Amsterdam UMC- location VUmc, Amsterdam UMC- VU University Medical Center, Amsterdam, The Netherlands

²Amsterdam UMC- VU University Medical Center, Department of Obstetrics and Gynaecology, Amsterdam, The Netherlands

³Amsterdam UMC- VU University Medical Center, Department of Obstetrics and Gynaecology, Amsterdam, The Netherlands

Background

To study the long-term effectiveness of a laparoscopic niche resection on niche related symptoms, ultrasound findings, quality of life and reproductive outcomes.

Methods

We conducted a prospective cohort study in 166 women. Women with a large niche (residual myometrium thickness (RM) <2mm) and symptoms of postmenstrual spotting, dysmenorrhea, subfertility in combination with intrauterine fluid accumulation or difficulties with embryo transfer due to distorted anatomy underwent a laparoscopic niche resection in a university hospital in The Netherlands between 2010-2019.

Results

166 women underwent a laparoscopic niche resection with a follow-up of at least 12 months. Median postmenstrual spotting, dysmenorrhea and discomfort related to spotting decreased (all with p-value <0.01). The RM thickness increased substantially. Intrauterine fluid accumulation resolved in all women. QOL of life improved significantly in 6 out of 8 subdomains of the SF36 at 12 months follow-up. At the moment of submission of this abstract 64% of 101 women desiring a pregnancy conceived with a median interval of 3 (IQR 1-6) months after stopping contraceptives. In total 66.0% with previous failed ART conceived, of whom 45.2% conceived spontaneously. Currently, we are analysing the remaining dataset with a follow-up of at least 24 months.

Conclusions

Laparoscopic niche resection reduced postmenstrual spotting, discomfort due to spotting, dysmenorrhea, QOL, the presence of intrauterine fluid and enlarged the RM. The majority of women conceived within six months after discontinuation of contraceptives.

ES28-0161 -

Best Selected Abstracts 1

The effect of single- versus double-layer closure of the uterine caesarean scar on postmenstrual spotting: a multicentre, double-blind, randomised controlled trial

Stegwee, Sanne¹, van der Voet, Lucet², Bongers, Marlies^{3, 19}, de Groot, Christianne¹, de Leeuw, Robert¹, Hehenkamp, Wouter¹, Lambalk, Nils¹, Pajkrt, Eva⁴, van Kesteren, Paul⁵, Radder, Celine⁶, Hemelaar, Majoie⁷, van Baal, Marchien⁸, Visser, Harry⁹, van Laar, Judith³, van Vliet, Huib¹⁰, Rijnders, Robbert¹¹, Sueters, Marieke¹², Janssen, Ineke¹³, Hermes, Wietske¹⁴, Feitsma, Hanneke¹⁵, Kapiteijn, Kitty¹⁶, Scheepers, Liesbeth¹⁷, Langenveld, Josje¹⁸, de Boer, Karin¹⁹, Hink, Esther²⁰, Schippers, Daniela²¹, Oei, Angèle²², Kaplan, Mesrur²³, Papatsonis, Dimitri²⁴, de Vleeschouwer, Marloes²⁵, van Beek, Erik²⁶, Bekker, Mireille²⁷, Huisjes, Anjoke²⁸, Meijer, Wouter²⁹, Deurloo, Koen³⁰, Boormans, Elisabeth³¹, van Eindhoven, Hugo³², Huirne, Judith^{1*} (2Close study group)

Affiliations:

¹ Amsterdam UMC, Vrije Universiteit, Department of Obstetrics and Gynaecology, Amsterdam Reproduction and Development research institute, De Boelelaan 1117, 1081 HV, Amsterdam, the Netherlands

² Deventer Hospital, Department of Obstetrics and Gynaecology, Nico Bolkesteinlaan 75, 7416 SE Deventer, the Netherlands

³ Máxima Medical Centre, Department of Obstetrics and Gynaecology, De Run 4600, 5504 DB Veldhoven, the Netherlands

⁴ Amsterdam UMC, Univ of Amsterdam, Department of Obstetrics and Gynaecology, Meibergdreef 9, 1105 AZ Amsterdam, the Netherlands

⁵ OLVG-oost, Department of Obstetrics and Gynaecology, Oosterpark 9, 1091 AC Amsterdam, the Netherlands

⁶ OLVG-west, Department of Obstetrics and Gynaecology, Jan Tooropstraat 164, 1061 AE Amsterdam, the Netherlands

⁷ Dijklander hospital – location Hoorn, Department of Obstetrics and Gynaecology, Maelsonstraat 3, 1624 NP Hoorn, the Netherlands

⁸ Flevo hospital, Department of Obstetrics and Gynaecology, Hospitaalweg 1, 1315 RA Almere, the Netherlands

⁹ Tergooi hospital, Department of Obstetrics and Gynaecology, Rijksstraatweg 1, 1261 AN Blaricum, the Netherlands

¹⁰ Catharina hospital, Department of Obstetrics and Gynaecology, Michelangelolaan 2, 5623 EJ Eindhoven, the Netherlands

- ¹¹ Jeroen Bosch hospital, Department of Obstetrics and Gynaecology, Henri Dunantstraat 1, 5223 GZ 's-Hertogenbosch, the Netherlands
- ¹² Leiden University Medical Centre, Department of Obstetrics and Gynaecology, Albinusdreef 2, 2333 ZA Leiden, the Netherlands
- ¹³ Groene Hart hospital, Department of Obstetrics and Gynaecology, Bleulandweg 10, 2803 HH Gouda, the Netherlands
- ¹⁴ Haaglanden Medical Centre – Westeinde hospital, Department of Obstetrics and Gynaecology, Lijnbaan 32, 2512 VA Den Haag, the Netherlands
- ¹⁵ Haga hospital, Department of Obstetrics and Gynaecology, Els-Borst-Eilersplein 275, 2545 AA Den Haag, the Netherlands
- ¹⁶ Reinier de Graaf hospital, Department of Obstetrics and Gynaecology, Reinier de Graafweg 5, 2625 AD Delft, the Netherlands
- ¹⁷ Maastricht University Medical Centre, Department of Obstetrics and Gynaecology, Research school 'GROW', P. Debyelaan 25, 6229 HX Maastricht, the Netherlands
- ¹⁸ Zuyderland Medical Centre, Department of Obstetrics and Gynaecology, Henri Dunantstraat 5, 6419 PC Heerlen, the Netherlands
- ¹⁹ Rijnstate hospital, Department of Obstetrics and Gynaecology, Wagnerlaan 55, 6815 AD Arnhem, the Netherlands
- ²⁰ Radboud University Nijmegen Medical Centre, Department of Obstetrics and Gynaecology, Geert Grooteplein Zuid 10, 6525 GA Nijmegen, the Netherlands
- ²¹ Canisius-Wilhelmina hospital, Department of Obstetrics and Gynaecology, Weg door Jonkerbos 100, 6532 SZ Nijmegen, the Netherlands
- ²² Bernhoven hospital, Department of Obstetrics and Gynaecology, Nistelrodeseweg 10, 5406 PT Uden, the Netherlands
- ²³ Röpcke-Zweers hospital, Department of Obstetrics and Gynaecology, Jan Weitkamplaan 4 a, 7772 Hardenberg, the Netherlands
- ²⁴ Amphibia hospital, Department of Obstetrics and Gynaecology, Langendijk 75, 4819 EV Breda, the Netherlands
- ²⁵ Sint Franciscus Hospital, Department of Obstetrics and Gynaecology, Kleiweg 500, 3045 PM Rotterdam, the Netherlands
- ²⁶ Sint Antonius Hospital, Department of Obstetrics and Gynaecology, Koekoekslaan 1, 3435 CM Nieuwegein, the Netherlands
- ²⁷ Birth Centre Wilhelmina Children Hospital/University Medical Centre Utrecht, Department of Obstetrics and Gynaecology, Lundlaan 6, 3584 EA Utrecht, the Netherlands
- ²⁸ Gelre hospital – location Apeldoorn, Department of Obstetrics and Gynaecology, Albert Schweitzerlaan 31, 7334 DZ Apeldoorn, the Netherlands
- ²⁹ Gelre hospital – location Zutphen, Department of Obstetrics and Gynaecology, Den Elterweg 77, 7207 AE Zutphen, the Netherlands
- ³⁰ Diakonessenhuis, Department of Obstetrics and Gynaecology, Bosboomstraat 1, 3582 KE Utrecht, the Netherlands
- ³¹ Meander Medical Centre, Department of Obstetrics and Gynaecology, Maatweg 3, 3813 TZ Amersfoort, the Netherlands
- ³² Isala clinics, Department of Obstetrics and Gynaecology, Dokter van Heesweg 2, 8025 AB Zwolle, the Netherlands

Background

Caesarean section (CS) is the most frequently performed gynaecological operation, but no consensus exists about the optimal way to perform uterine caesarean closure regarding gynaecological symptoms. The objective of this study is to determine the effectiveness of double-layer compared to single-layer uterine closure in the prevention of niche related postmenstrual spotting nine months after a first CS.

Methods

A multicenter, double-blind, randomised controlled trial was performed at 32 university and teaching hospitals in the Netherlands. Women aged over 18 years undergoing their first CS were randomised to receive single-layer or double-layer closure of the uterine incision. Single-layer closure was performed with a continuous running, unlocked suture, with or without endometrial saving technique. Double-layer closure was performed with the first layer in a continuous unlocked suture including the endometrial layer and the second layer also continuous unlocked, imbricating the first. The primary outcome was the number of days with postmenstrual spotting during one menstrual cycle nine months after CS. Secondary outcomes included presence and characteristics of a niche on transvaginal ultrasound three months after CS, other menstrual characteristics, quality of life and sexual functioning. Primary analysis was by intention-to-treat and additional per-protocol analyses were also performed. This completed study is registered in The Netherlands Trial Register, number NTR5480.

Results

(Preliminary): From May 2016 to June 2018, we randomly assigned 2294 women to single-layer (N=1146) or double-layer (N=1148) closure of the uterine incision. 1882 (82.0%) participants responded to our nine months follow-up questionnaire. Of them, 341 participants (20.4%) reported postmenstrual spotting; 190 participants (20.0%) in the single-layer and 194 (20.8%) in the double-layer group ($p=0.731$). A transvaginal ultrasound was performed in 1963 participants (85.6%). A niche was present in 792 participants (79.4%) in the single-layer and 806 (83.4%) in the double-layer group ($p=0.024$). We are currently analysing the data and we would like to present the final and detailed results at the ESGE Congress 2019.

Conclusions

Reported prevalence of postmenstrual spotting was similar after single- versus double-layer closure of the uterine incision after a first CS.

ES28-0253 -

Best Selected Abstracts 1

Hysteroscopic examination and reporting system for niches in the uterine caesarean scar: a European modified Delphi procedure

Lucet van der Voet¹, Attilio di Spiezio Sardo², Pere Barri³, Margit Dueholm⁴, Olivier Donnez⁵, Robert de Leeuw⁶, Ertan Saridogan⁷, Justin Clark⁸, Hans Brolmann⁶ Andreas Thurok⁶, Davor Jurkovic⁹, Thierry Van Den Bosch¹⁰, Wouter Hehenkamp⁶ Judith Huirne⁶.

¹Deventer Ziekenhuis, Obstetrics and Gynaecology, Deventer, The Netherlands.

²Università degli Studi di Napoli "Federico II", Ginecologia ed Ostetricia, Napoli, Italy.

³Institut Universitari Dexeus- Càtedra d'Investigació en Ginecologia-, Departament d'Obstetricia i Ginecologia-, Barcelona, Spain.

⁴Aarhus University, Department of Clinical Medicine - Department of Obstetrics and Gynaecology, Aarhus, Denmark.

⁵Institut du sein et de Chirurgie gynécologique d'Avignon ICA, Polyclinique Urbain V Groupe ELSAN, Avignon, France.

⁶Amsterdam University Medical Center, Gynaecology, Amsterdam, The Netherlands

⁷University College London Hospitals, Reproductive Medicine and Minimal Access Surgery London, United Kingdom

⁸Birmingham Women's & Children's Hospital, University of Birmingham, Birmingham, United Kingdom

⁹ University College Hospital, Gynaecology Diagnostic and Outpatient Treatment Unit, London, United Kingdom

¹⁰ Universitair Ziekenhuis Leuven, Department Gynaecology and Obstetrics, Leuven, Belgium

Background

Only recently, we are more aware of niches in the uterine caesarean scar. Currently, a standardized guidance in hysteroscopic evaluation and uniform reporting system is lacking. We aimed to develop a guidance for hysteroscopic evaluation of the uterine caesarean scar, including a uniform reporting form.

Methods

A modified Delphi procedure was conducted among experts. All experts were recruited by their membership of the ESGE niche taskforce and needed to have extensive experience in hysteroscopic niche evaluation. Consensus was predefined as a consensus rate of at least 75% agreement.

Results

Potential relevant items were selected after a literature search and focus group meeting among experts. Thirteen experts participated in the Delphi procedure. Consensus was achieved after two online questionnaires and two face-to-face meetings on all preselected items and additional added items.

All experts underlined the need for a uniform definition and structured registration form in the evaluation of a niche. Additionally it was fully consented that in addition to hysteroscopy a niche should be evaluated by sonography to assess the thickness of the residual myometrium. Using hysteroscopy, a niche was defined as any indentation in the myometrium at the site of a previous CS. In total six items were selected to be relevant in the method of hysteroscopic niche evaluation and 15 items were selected to be included in the registration form; classification, localisation and size of the niche, amounts of niches, presence of branches, crypts, cystic formations, vessels, polyp like structures, mucus, blood, fibrotic tissue, dynamic valve, placental remnants and endometrium in the niches.

Conclusions

With a modified European Delphi procedure, consensus was achieved on the hysteroscopic evaluation of niches in the uterine caesarean scar and a structured registration form was developed.

ES28-0366 - Best Selected Abstracts 1

Mira-trial: Mirena versus NovaSure ablation in women with heavy menstrual bleeding: a cohort-study

Marleen van der Velde¹, Pleun Beelen¹, Peggy Geomini¹, Marlies Bongers¹

¹Maxima Medical Centre, Gynaecology, Veldhoven, The Netherlands

Background

Heavy menstrual bleeding (HMB) is a common health problem causing a major impact on the quality of life of many women. Two frequently applied treatments are the levonorgestrel releasing intra-uterine system (LNG-IUS) and endometrial ablation (EA). In a recently conducted multicentre randomised controlled trial (RCT), which compared these treatment strategies, non-inferiority of the LNG-IUS compared to EA could not be demonstrated. Alongside this RCT, we conducted a parallel cohort-study for women who declined randomisation. The primary objective of this cohort-study is to assess the effectiveness of both treatment strategies and to evaluate the effect of treatment preference on patient satisfaction and re-interventions.

Methods

Eligible women were identified by gynaecologists or general practitioners. Women who declined randomisation were asked to participate in the observational study. Women chose between a strategy starting with LNG-IUS or a strategy starting with EA and were followed up to 24 months after treatment. The primary outcome was re-intervention, secondary outcomes were patient satisfaction and pictorial blood assessment chart (PBAC)-score. The ethics committee of the Academic Medical Centre Amsterdam, The Netherlands and the board of directors of each participating hospital approved this study.

Results

Between April 27, 2012 and January 12, 2016, we included 270 women, 87 women in the LNG-IUS group and 183 women in the EA-group. At 24 months of follow-up women in the LNG-IUS-group were more likely to receive a re-intervention compared to women in the EA-group, respectively 35% (28/81) vs 14% (25/178), RR 3.34, 95% CI 2.17-5.14. Hysterectomy rates were comparable (4.9% in the LNG-IUS group vs 5.6% in the EA-group). At 3 months follow-up we found a significant difference in satisfaction-rates between the two groups (56% in the LNG-IUS-group was satisfied vs 95% in the EA-group, RR 0.69, 95% CI 0.56-0.86). This difference was no longer present from 6 months of follow-up until 24 months of follow-up. In both treatment groups women showed a strong decline in PBAC-scores, with no significant difference in controlled bleeding (PBAC-score \leq 75) at 24 months of follow-up (86% in the LNG-IUS group vs 95% in the EA-group, RR 0.90, 95% CI 0.79-1.02). Comparing these results to the results of the previous conducted RCT, we found free treatment choice results in higher satisfaction-rates and a lower percentage of hysterectomy in both groups.

Conclusions

Both treatment strategies were found to be effective for the treatment of women with HMB. Women in the LNG-IUS group were more likely to receive a re-intervention, however no difference in hysterectomy rate was found. Furthermore, this study shows the importance of discussing a patient preference and expectations during counseling.

ES28-0384 - Best Selected Abstracts 1

Randomised controlled trial comparing the levonorgestrel releasing intrauterine system (Mirena) with endometrial ablation in women with heavy menstrual bleeding: MIRA trial

Pleun Beelen¹, Marian van den Brink², Peggy Geomini¹, Malou Herman¹, Marlies Bongers¹

¹Maxima Medical Centre, Gynaecology, Veldhoven, The Netherlands

²University Medical Centre Groningen, Department of general practice, Groningen, The Netherlands

Background

The levonorgestrel intrauterine system (LNG-IUS) and endometrial ablation (EA) are two frequently applied treatments in women with heavy menstrual bleeding (HMB). The objective of this study is to compare a treatment strategy starting with LNG-IUS to a strategy starting with EA.

Methods

In this multicentre, open-label, randomised controlled trial (Netherlands Trial Register; NTR 2984), we recruited women with HMB, aged 34 and older, without intracavitary pathology and not planning future pregnancies, from 26 hospitals and nearby general practices in The Netherlands. Women were randomly assigned (1:1) to a strategy starting with either LNG-IUS (n=132) or bipolar radiofrequency EA (n=138). The primary outcome was mean blood loss at 24 months, assessed with a Pictorial Blood Assessment Chart (PBAC)-score. The non-inferiority margin was set at 25 points. Secondary outcomes included re-intervention rates, patient satisfaction, quality of life and sexual function. Women completed questionnaires at baseline, and at 3, 6, 12, and 24 months after randomisation. The study was approved by the ethics committee of the Academic Medical Centre Amsterdam, The Netherlands (registration number 2011_372), and by the board of directors of each of the participating hospitals.

Results

Between April 2012 and January 2016, we randomised 270 women to an initial treatment with LNG-IUS (N=132, baseline PBAC-score 616) or EA (N=138, baseline PBAC-score 630). 247 women were included in the intention to treat analysis. Mean PBAC-scores were 64.8 in the LNG-IUS-group and 14.2 in the EA-group (difference 50.5 points, 95% CI 4.3 to 96.7, non-inferiority p-value=0.87). At 24 months 100 women (87%) in the LNG-IUS group had a PBAC-score not exceeding 75 points compared to 124 women (94%) in the EA-group (RR 0.93, 95% CI 0.85 to 1.01). Of the women in the LNG-IUS-group 44 (35%) underwent a re-intervention compared to 27 (20%) in the EA-group (RR 1.77, 95% CI 1.17 to 2.68). In the LNG-IUS-group 31 women (24%) eventually underwent EA. At 24 months of follow-up 74% of women in the LNG-IUS-group was satisfied compared to 84% of women in the EA-group (RR 0.88, 95% CI 0.76-1.01). We found no significant differences over time in quality of life and sexual function between the two treatment groups.

Conclusions

Non-inferiority of the LNG-IUS compared to EA could not be demonstrated. A lower mean PBAC-score was observed in the EA-group, though the LNG-IUS was found to be effective in a large proportion of women, and almost three quarters of women did not need a surgical intervention. The results of this study will contribute to informed and shared decision making in women suffering from HMB.

**ES28-0119 -
Best Selected Abstracts 1**

Benign endometrial polyp recurrence after office hysteroscopic polypectomy according to surgical procedure.

Mario Franchini¹, Oronzo Cec², Rossella Cannone², Stefano Bettocch², Giovanna Giarrè¹, Ettore Cicinell²

¹*Freestanding Palagi Florence, Minimally Invasive Gynecology, Firenze, Italy*

²*2nd Unit of Obstetrics and Gynecology- University of Bari-, Department of Biomedical Science and Human Oncology, Bari, Italy*

Background

To compare the recurrence of benign endometrial polyps after hysteroscopic polypectomy performed with bipolar electrode (BE) or a small diameter mechanical hysteroscopic tissue removal system (mHTRs).

Methods

From January to December 2017, ninety-three of 120 fertile women, with a single endometrial polyp (between 10 and 20 mm) accepted to participate in the prospective study and were randomised into two groups according to the type of surgical procedure assigned by "QuickCalcs" of "Graphpad Software". All women gave their consent to participate to this study approved by the Institutional Review Board. A 4 mm hysteroscope (Karl Storz®, Germany) with a twizzle bipolar electrode (Versapoint, Gynecare®, USA) was used in 51 women (BE Group). A 5 mm HTRs (TruClear 5C System, Medtronic, Ireland) was used in 42 women (TruClear Group). All hysteroscopic polypectomies were performed in an office setting with the vaginoscopic approach during the early proliferative phase by skilled surgeons. Women with removed polyps, classified as "benign" after pathological assessment, were considered and scheduled for a 12-month postoperative transvaginal ultrasound evaluation.

Results

Polyps were completely removed in 48 out of 51 (94.17%) BE group and in 40 out of 42 HTR group (95.23%). The median time for polypectomy was significantly lower for *HTR group* (3.6 ± 1.7 minutes) compare to 8.7 ± 2.8 minutes for the *BE Group*, $p < 0.05$. Sixty-six women completed the evaluation at one-year ultrasound follow-up, four single polyps (size from 10 to 15 mm) were identified in BE Group and two (12 and 16 mm) in HTR Group. All polyps were hysteroscopically confirmed and simultaneously removed (4/34 vs. 2/28, $p = 0,999$). Polyps were confirmed as "benign" by the pathologist.

Conclusions

In this prospective randomised study, hysteroscopic endometrial polypectomy was significantly quicker with HTR compared to BE without differences in complete removal and recurrence rates.

**ES28-0333 -
Best Selected Abstracts 1**

Hysteroscopic metroplasty using a dual-wavelength diode laser system: our experience

Nappi Luigi¹, Felice Sorrentino¹, Antonio Accard², Francesca Greco¹, Francesco D'Antonio¹, Stefano Angioni³

¹*Institute of Obstetrics and Gynecology- University of Foggia, Department of Medical and Surgical Sciences, Foggia, Italy*

²*Asp 6, Department of Gynecology and Obstetrics, Palermo, Italy*

³*University Hospital of Cagliari, Department of Surgical Sciences- Clinic of Obstetrics and Gynecology, Cagliari, Italy*

Background

The aim of this study was to assess the feasibility, safety and efficacy of office hysteroscopic metroplasty using a dual-wavelength (980nm and 1470nm) diode laser system and to evaluate reproductive outcomes.

Methods

30 patients were treated for septate uterus between January 2016 and December 2018 in three Italian centres. The indications for hysteroscopic metroplasty were recurrent abortion and primary infertility. We used a 4 mm-office hysteroscope with a diode laser fibre. After exploration of the cavity, the septum was divided with use of the laser fibre.

Results

Operating time of the procedure was $15 \pm 1,08$ min. Intraoperative pain was $3,01 \pm 0,52$. There were no intraoperative complications and blood loss was minimal. The hysteroscopic second-look after two months showed in all patients the complete removal of the septum and no intrauterine synechiae. We analysed the pregnancy outcomes (follow-up post-surgery for 6-24 months). We had 19 pregnancy reported in 24 months: 11 reached term, 5 were ongoing at the time of analysis and 3 resulted in first-trimester miscarriage.

Conclusions

Hysteroscopic metroplasty using a dual-wavelength (980nm and 1470nm) diode laser system is a feasible and safe alternative to the scissor, bipolar twizzle and bipolar or monopolar resectoscope techniques. We believe that vaporisation of the septum with a diode laser could reduce the formation of adhesions and consequently reduce the occurrence of septum persistence.

ES28-0422 - Best Selected Abstracts 1

Septate uterus: overcoming the discrepancies between current classifications

Caterina Exacoustos¹, Francesca Conway¹, Terry Siciliano¹, Sara Camilli¹, Francesco Martire Giuseppe¹, Emilio Piccione¹

¹University of Rome- Tor Vergata, Department of Biomedicine and Prevention- Obstetrics and Gynecology Clinic, Roma, Italy

Background

The ESHRE/ESGE classification has been criticised for eliminating the arcuate category and the definition of septate uterus (U2a) which classified as anomalies small indentations. Other classifications have been proposed to define a septate uterus, however underestimating this anomaly. The question is still open on the real reproductive impact of small defects and the need for surgery. The aim of the study was to compare the different classifications in use for septate uterus, correlate the classifications to reproductive outcomes and propose other 3D ultrasound parameters to better classify U2A uteri.

Methods

We evaluated 664 patients with 3D ultrasound diagnosis of a uterine fundal indentation of ≥ 3 mm < 30mm. We excluded complete septate uterus. For each patient the sonographic uterine morphology was evaluated offline on the coronal plane and the following measurements were recorded: uterine cavity width, septal or indentation length, uterine wall thickness and fundal indentation angle. Each uterus was subclassified according to the following classifications: Salim (2003), ESHRE/ESGE (2013), ASRM (2016), CUME (2018). The reproductive history of each patient was correlated to the type of uterine anomaly according to the four different classifications.

Results

Of 664 uteri with fundal indentations, a septate uterus according to Salim was found in 79(12%) patients, according to ESHRE/ESGE in 402 (61%), according to ASRM(2016) in 46 (7%), according to CUME with a cut-off of septal length ≥ 1 cm in 143 (22%), using the indentation angle of $\leq 140^\circ$ in 475 (72%), and finally with the cut off for the septal length/myometrial ratio $< 110\%$ in 154 (23%) patients. 458 patients tried to conceive before our scan, 176 (38%) were infertile, 282 (62%) had at least one pregnancy with at least one miscarriage in 213 patients and at least one delivery in 91 patients of which 85% at term (77) and 15% preterm (14). Among patients who tried to conceive we observed 119 patients with recurrent abortion (≥ 2 miscarriage); of these a septate uterus was found in 11% according to Salim, in 53% according to ESHRE/ESGE, in 3% when using ASRM (2016) and finally in 22% using CUME with cut-off ≥ 1 cm in 22%, 68% with the angle $\leq 140^\circ$ and in 21% with the cut-off ratio $> 110\%$ in 21%. The correlation to pregnancy outcome becomes stronger by imposing an indentation cut-off > 5 mm and/or an angle $> 100/120^\circ$ to the ESHRE/ESGE classification.

Conclusions

Current classifications don't correlate to each other and with reproductive outcomes. These wide discrepancies between different classifications cause clinical difficulties with regards to patient counselling and choice of treatment in women with miscarriages and infertility. ESHRE/ESGE classification could be integrated with further 3D ultrasound measurements to better define U2a anomaly and better correlate to reproductive outcome.

Expanding the limits of operative office hysteroscopy: the role of the intrauterine tissue removal system of 5,7 mm and the bipolar resector of 5,3 mm

Paloma Lobo Abascal¹, Silvia Duch Grau¹, Yasmina Cabrera Guerra¹, José Rubio Valtueña¹, Susana Gamir Henderson¹, Julio Álvarez Bernardi¹

¹Hospital Universitario Infanta Sofía, Servicio de Ginecología y Obstetricia, Madrid, Spain

Background

Analyse the percentage of procedures resolved in the office setting (OS) (polypectomies, myomectomies and removal of retained products of conception (RPoC)) comparing two time periods differentiated by the use of new instruments

Methods

Longitudinal retrospective study analysing the percentage of above-mentioned procedures resolved in OS or in Operating Room (OR) in two different periods. From 2008 to March 2011 we used mechanical instruments (grasping forceps and scissors) and the bipolar electrode (Versapoint). In March 2011 we started to use also the intrauterine tissue removal system of 5,7 mm (ITRS- 5,7) with the Truclear incisor device for soft tissues. In January 2014 we started to use the bipolar resector of 5,3 mm (BR-5,3) and from July 2018 we use the IURS- 5,7 with the Truclear ultra mini device for myomas.

Results

From 2008 to 2011 we performed 698 hysteroscopies in OS with the above-mentioned diagnosis. In 79 cases (11,3%) an operative hysteroscopy in OR was required: 54,4% for removing myomas; 39,2% for polyps and 6,3% for RPoC.

Regarding the results in OS:

- Polyps: From a total of 593 cases 86,5% were completely removed, 6,9% partially and 6,57% not removed
- Myomas: From a total of 93 cases 27,9% were completely removed; 12,9% partially and 59,1% not removed.
- RPoC: From a total of 12 cases 58,3% were completely removed and 41,66% not removed.

The tolerance was good in 90,5% of the procedures.

From March 2011 to May 2019 we performed 2799 hysteroscopies in OS with the above-mentioned diagnosis. In 68 cases (2,42%) an operative hysteroscopy in OR was required: 79,41% for removing myomas; 14,7% for polyps and 7,35 % for RPoC.

- Polyps: From 2196 procedures 98,26% were completely removed, 0,72% partially and 1% were not removed. 686 procedures were performed with ITRS-5,7 and 18 with BR-5,3.
- Myomas: From a total of 479 procedures 60,33% were completely removed; 17,53% partially and 18,58 % were not removed. 150 procedures were performed with BR-5,3 and 56 with ITRS-5,7 ; 40 of those with the ultra mini device.
- RPoC: From a total of 124 procedures 95,9% were completely removed and 4,1% were not removed. 94 procedures were performed with ITRS-5,7.

The tolerance was good in the 95% of the procedures

With the use of new devices we have increased the number of procedures resolved in OS

- 11,76% more total polypectomies
- 32,43% more total myomectomies
- 37,6% more complete removal of RPoC.

From the 2799 procedures performed in the second period 836 (29,86%) were performed with ITRS-5,7 and 168 (6%) with BR-5,3.

Conclusions

The use in OS of new devices like the ITRS-5,7 mm and the BR-5,3 contribute to improve our results and to expand the limits of Operative Office hysteroscopy with better tolerance and in the case of the tissue removal system with a shorter learning curve.

ES28-0420 - Best Selected Abstracts 2

Endometrial sampling before or after saline infusion sonography (ESPRESSO Trial): preliminary data of a multicentre RCT

Albertine Vroom^{1,2}, *Luca Aerts*², *Marlies Bongers*^{1,2}, *Peggy Geomini*¹, *Nehalennia van Hanegem*², *Arianne Lim*²

¹*Maxima Medisch Centrum- Veldhoven, Department of Gynecology and Obstetrics, Maastricht, The Netherlands*

²*Maastricht UMC+- Maastricht- GROW- School for Oncology and Developmental Biology., Department of Obstetrics and Gynecology, Maastricht, The Netherlands*

Background

Postmenopausal bleeding (PMB) can be the first sign of endometrial cancer. In case of a thickened endometrium, a diagnostic work-up including endometrial sampling and saline infusion sonography (SIS) is advocated. These procedures can be performed subsequently in one visit, but consensus about the order of this diagnostic work-up women with postmenopausal bleeding women hasn't been reached.

The objective of this study is to evaluate the effect of the order of procedures (SIS-aspiration or aspiration-SIS) on the conclusiveness of the endometrial tissue samples, the failure rate of the SIS procedure and the intensity of pain in women with postmenopausal bleeding with an indication for further diagnostic work up.

Methods

We performed a randomised controlled trial comparing two diagnostics work-ups (SIS- aspiration vs. aspiration-SIS) in 196 postmenopausal women in two outpatient clinics in The Netherlands. Inclusion criteria were women with postmenopausal bleeding and an increased endometrial thickness of >4 mm and exclusion criteria were cervical carcinoma and the use of Tamoxifen or hormone replacement therapy. The quality of the tissue sample was evaluated by a pathologist to be conclusive or not. Additionally, we investigated the intensity of pain on the NRS (numeric rating score) and the incidence of failed SIS procedures.

Results

The diagnostic conclusiveness of the endometrial tissue samples did not differ significantly when endometrial sampling was performed first, compared with the patients allocated to the reverse order of procedures. We found an inadequate sample rate of 38.3% in the SIS-aspiration group and 31.9% in the aspiration-SIS group ($p = .45$).

The aspiration-SIS group rated their procedure related pain overall higher in comparison to the SIS-aspiration group. The only significant difference was found for the pain measured between the two investigations on the NRS, 1.8 ± 2.0 for the aspiration-SIS group and 1.0 ± 2.0 for the SIS-aspiration group ($p = .02$).

Regarding the failed SIS procedures, a failure rate of 15.3% for the SIS-aspiration group and 20.4% for the aspiration-SIS group was found ($p = .46$). Respectively 26.7% and 35% of the failed SIS procedures was due to inadequate distension.

Conclusions

These preliminary results suggest that there is no difference in inadequate endometrial tissue samples and failed SIS procedures when the aspiration is performed before or after the SIS for women with postmenopausal bleeding. Based on the higher pain scores when aspiration is performed before the SIS, we recommend conducting the SIS before the endometrial aspiration in terms of patient's comfort.

ES28-0463 - Best Selected Abstracts 2

Laparoscopic abdominal cerclage, from two different perspectives

*Nicole Burger*¹, *Hans Brölmann*¹, *Wouter Hehenkamp*¹, *Judith Huirne*¹

¹*Amsterdam University Medical Center- location VUmc, Obstetrics and Gynecology, Amsterdam, The Netherlands*

Background

Despite advances in preventing preterm birth, such as cervical length screening, use of progesterone and vaginal cerclage placement, preterm birth remains the leading cause of neonatal morbidity and mortality. In patients with a previously failed vaginal cerclage and/or a short or absent cervix a laparoscopic abdominal cerclage can be placed.

This minimal invasive technique can be applied either pre- or postconceptionally. The aim of this study is to evaluate the surgical and obstetrical outcomes of pre- and postconceptional laparoscopic abdominal cerclage placement.

Methods

A retrospective cohort study with consecutive inclusion of all eligible patients from 1997 onwards was conducted. Eligible patients experienced at least one second or third trimester foetal loss because of cervical insufficiency and/or a short or absent cervix after cervical surgery. This includes large loop excision of the transformation zone (LLETZ), conisation and/or trachelectomy. All laparoscopic abdominal cerclages were placed in an elective setting and were inserted by three experienced gynaecologic surgeons of the Amsterdam University Medical Center, location VUmc.

Results

A total of 72 consecutive patients were included. A laparoscopic abdominal cerclage was placed preconceptionally in 65 patients and postconceptionally in 7 patients. Forty-four patients of the total group (61,1%) had a history of at least one second or third trimester foetal loss and 31 patients (43,1%) had a previously failed vaginal cerclage. Fifty patients (70.4%) had undergone cervical surgery. Preconceptional placement of the laparoscopic abdominal cerclage showed positive surgical outcomes, with four minor complications such as uterine perforation. One conversion to laparotomy occurred during postconceptional placement because of blood loss and subsequent poor visualization. Blood transfusions were not required. All patients went home the day after laparoscopic surgery. Forty-four patients were pregnant (75,9%) after preconceptional surgery. Seven patients were lost to follow-up. A total of 44 completed pregnancies could be evaluated. This includes 38 patients with a preconceptional laparoscopic abdominal cerclage and 6 patients with a postconceptional laparoscopic abdominal cerclage. One patient is currently in her third trimester of pregnancy following a postconceptionally placed laparoscopic abdominal cerclage. In patients with a preconceptional laparoscopic abdominal cerclage 30 patients (78,9%) had a Caesarean Section \geq 34 weeks of pregnancy and two (5,3%) second-trimester foetal losses occurred. In patients with a postconceptional laparoscopic abdominal cerclage 5 patients (83,3%) had a Caesarean Section \geq 34 weeks of pregnancy. One patient (16.7%) had a Caesarean Section at 32 weeks of gestation because of severe preeclampsia and HELLP syndrome. Foetal survival rate (excluding first-trimester miscarriages) was 94,9% in the total group.

Conclusions

Pre- and postconceptional laparoscopic abdominal cerclage placement is a feasible and safe procedure with favourable pregnancy outcomes in patients with a poor obstetric history.

ES28-0247 -

Best Selected Abstracts 2

Advanced bipolar tissue sealers versus classic bipolar instruments in gynaecological laparoscopy: which help residents the most? Preliminary data analysis

Gaetano Riemma¹, Antonio Schiattarella¹, Marco La Verde¹, Anna Conte¹, Nicola Colacurci¹, Pasquale De Franciscis¹
¹University of Campania 'Luigi Vanvitelli', Department of Woman- Child and General and Specialized Surgery, Naples, Italy

Background

To evaluate differences in surgical outcomes and operators' satisfaction between advanced bipolar tissue sealers and classic bipolar instruments for laparoscopic gynaecological procedures conducted by residents and helped by one expert surgeon.

Methods

A prospective observational study conducted at a Tertiary University Hospital between November 2018 and March 2019 on 70 consecutive minor laparoscopic procedures: 40 adnexectomies (group **A**) and 30 salpingectomies (group **B**). Procedures were subdivided depending on which of the following haemostatic control and vessel sealing device was used: a 5 mm diameter, 35 cm length curved branch radiofrequency tissue sealer connected at dedicated electric generator (groups **A1** and **B1**) or classic rotating bipolar forceps (groups **A2** and **B2**)

From every intervention, the following data were obtained: duration of surgical procedure, post-surgical complications, intra-operative and day-1 blood loss, numbers of re-interventions, post-surgical stay, 24 hours post-operative pain. Operator's subjective judgment regarding visibility of the surgical field, the difficulty of intervention and overall satisfaction were analysed by means of a Numeric Rating Scale (NRS).

Results

Concerning 40 adnexectomies, 20 were conducted using a tissue sealer (group A1) and 20 with bipolar forceps (A2). A significant reduction of intra-operative blood loss was achieved in group A1 ($12,2 \text{ ml} \pm 4,7 \text{ ml}$ vs $33,2 \text{ ml} \pm 29,7 \text{ ml}$; $p=0,03$). Post-operative pain was lower with a tissue sealer usage ($4,5 \pm 1,1$ vs $5,7 \pm 1,8$; $p=0,02$). No other differences were observed between operative data. Residents' judgment underlined a better visibility in A1 ($8,5 \pm 0,6$ vs $7,2 \pm 0,9$; $p=0,01$) together with a reduced difficulty ($5,4 \pm 1,2$ vs $6,9 \pm 1,9$; $p=0,01$) and an improved overall satisfaction ($9,1 \pm 0,4$ vs $7,5 \pm 0,7$; $p=0,01$)

Of 30 salpingectomies, 15 were done by means of a tissue sealer (group B1), meanwhile 15 using bipolar forceps (B2). A statistically significant reduction of procedure duration was notable in group B1 ($7,2 \pm 3,4 \text{ min}$ vs $12,2 \pm 8,3 \text{ min}$; $p=0,04$). When a tissue sealer was used, enhanced visibility of the field ($8 \pm 1,1$ vs $6,5 \pm 1,3$; $p=0,01$), reduction of difficulty ($6,1 \pm 1,7$ vs $7,6 \pm 0,7$; $p=0,01$) and a better operator satisfaction ($9,2 \pm 0,7$ vs $7,6 \pm 0,8$; $p=0,01$) were observed. For each group, there were no surgical complications or need for re-intervention.

Conclusions

Although classic bipolar instruments still play a major role in gynaecological surgery, the usage of radiofrequency haemostatic control and vessel sealing devices should be encouraged in residents' educational path thanks to their improved surgical outcomes, reduced difficulty usage and simplified user satisfaction.

ES28-0354 -

Best Selected Abstracts 2

Ultrasound evaluation of uterine contractility in women affected by adenomyosis: a prospective study

Alessandro Arena¹, Eugenia Degli Esposti¹, Elisa Moro¹, Margherita Zanello¹, Chiara Ricchiuti¹, Renato Seracchioli¹
¹Sant'Orsola Hospital - University of Bologna, Gynaecology and Human Reproduction Physiopathology, Bologna, Italy

Background

Uterine adenomyosis is defined by the presence of endometrium within the myometrium. The myocytes of uteri affected by adenomyosis seem to be structurally different from those of normal uteri, suggesting a possible defect in myometrial contractility. Transvaginal ultrasound represents the main non-invasive method for the evaluation of endometrial wave patterns. Our study aims to assess uterine contractility in women affected by adenomyosis with transvaginal ultrasound.

Methods

This preliminary study was conducted in our academic centre from March 2018 to April 2019. Nulliparous women aged between 18 and 50 years old evaluated at our institution because of a suspected gynaecological issue were enrolled in this study. Exclusion criteria were: personal history of malignancies, previous diagnosis of urogenital prolapse, previous abdominal surgery, congenital anomalies of the pelvis or the pelvic floor and current hormonal therapy. Women were subsequently divided into two groups: patients in group A had a clinical and ultrasonographic diagnosis of adenomyosis according to the MUSA criteria, patients in group B had no pathological findings. Presence and direction of endometrial waves (EW) was evaluated in each patient at periovulatory (cycle days 11-14) and midluteal (cycle days 19-22) phase, through a 3-minute transvaginal ultrasound scanning on sagittal uterine plane. The study protocol was approved by the local ethical committee.

Results

Thirty-eight women were enrolled in this study, 18 in group A and 20 in group B. Three women in group A and 4 in group B were subsequently ruled out based on exclusion criteria. Two women in each group did not show up at midluteal phase evaluation and were therefore excluded. EW evaluation at periovulatory phase showed a significantly lower prevalence of the retrograde pattern in adenomyotic patients compared to healthy controls (30.8% vs 71.4%, $p = .03$). Moreover, women in group A more frequently exhibited the opposed pattern compared to those in group B, but this was not statistically significant (46.2% vs 14.3%, $p = .06$). The two groups did not show significant differences in terms of endometrial wave patterns at midluteal evaluation.

Conclusions

Adenomyosis seems to affect uterine contractility in periovulatory phase, evaluated by transvaginal ultrasound. Altered uterine contractility may partially explain adenomyosis-related symptoms, such as pain, abnormal uterine bleeding and infertility. Further studies are needed to evaluate the possible impact of this findings on symptoms and clinical implications of these data on a larger scale.

**ES28-0327 -
Best Selected Abstracts 2**

Impact of the Olympus/ BSGE ST5+ Immersion training Programme on laparoscopic suturing skills - a prospective cohort study

Krupa Madhvani¹, Zaid Hasafa²

¹*Blizard Institute, Barts and the London School of Medicine and Dentistry, London, United Kingdom*

²*Royal Cornwall Hospital, Gynaecological Surgery, Cornwall, United Kingdom*

Background

A prospective cohort study to assess the change in laparoscopic suturing skills 24 candidates in the Olympus & BSGE ST5+ Immersion Training Programme 2018, which is an intensive laparoscopic training programme aimed towards developing skills in laparoscopic hysterectomy.

Methods

The European Academy of Gynaecological Endoscopy validated suturing and knot tying training and testing method (SUTT1) was used to evaluate candidates' laparoscopic suturing skills. Candidates were asked to perform five stitches and an intra-corporeal knot and the beginning and the end of the training programme. Examiners were independent of the programme faculty.

The online scoring platform for the European Academy of Gynaecological Surgery was used to calculate the overall score for each participant considering their previous psychomotor training. Individual components assessed within the overall score were: time to complete the task, number of correct sutures placed, knot security, precision and no trauma which was scored in three categories; "no trauma", "some trauma" and "excessive trauma".

Comparisons of the overall score and each of the five components (time, number of correct sutures, knot security, precision and "no trauma") were performed using the non-parametric tests for paired samples.

Results

Three candidates completed the assessment successfully before the programme and all candidates completed it after the programme ($p < 0.000$). The median number of sutures improved from 1/5 to 4/5 after the programme ($p < 0.000$). The number candidates who were able to place a secure knot laparoscopically improved from 11 to 20 ($p < 0.000$). Precision improved from a median score of 4/10 to 8/10 after the programme ($p < 0.01$). Eight candidates "no trauma" score improved, six worsened and nine of the candidates' no trauma score did not change.

Conclusions

Laparoscopic suturing skills in all candidates significantly improved after participation in the Olympus & BSGE ST5+ Immersion Training Programme and this is a useful programme to allow participants to develop the laparoscopic skills required to deliver laparoscopic hysterectomy.

**ES28-0489 -
Best Selected Abstracts 2**

A booster to national laparoscopic training opportunities - LapMapUK

Jessica Preshaw¹, Toshi Sherpa¹, Wojciech Szubert²

¹*Southmead Hospital, Gynaecology, Bristol, United Kingdom*

²*Ninewells Hospital, Gynaecology, Dundee, United Kingdom*

Background

Laparoscopic education is often highlighted inaccessible and inadequate with vast geographical variation in opportunities available. This motivator prompted a project addressing the following objectives:

1. To develop an interactive online resource mapping laparoscopic simulation equipment available and accessibility to training courses at local and regional level across the UK.
2. To create a network of laparoscopic champions to strengthen training opportunities.
3. To assess trainees engagement and use of LapMapUK.

Methods

May 2018 a survey was emailed to all fifteen BSGE Registrars in Gynaecological Surgery (RIGS) representatives collecting information on:

1. Deanery/region wide courses/study days, regional contacts
2. Hospital/local courses/study days, local contacts, locally available laparoscopic training equipment

Results

Response rate equalled 100%. This enabled the creation of LapMapUK - a free, simple, interactive, instant resource to track laparoscopic training opportunities.

LapMapUK is accessed on:

https://www.google.com/maps/d/edit?mid=1b1JR6v7ehEkQ7B8JykbzxGvwECmK_rLM&ll=53.03976685302315%2C-2.260126150000019&z=6

Red markers represent the region. Blue markers represent the hospital. (Only hospitals for which information has been obtained are included so far.) RIGS representatives have editing privileges. Their responsibility is to keep regional information up to date. Information is reviewed biennially at a minimum. Map users noticing incomplete information can contact their RIGS representative directly.

Conclusions

The high response rate from RIGS representatives meant successful creation of LapMapUK. This demonstrates the interest and ongoing potential of a functional network of laparoscopic champions in improving laparoscopic training. Since launch, LapMapUK has already been visited over 330 times. With further publicity and engagement, we anticipate substantial increase in usage.

Once LapMapUK is established, we believe international expansion with 'LapMapGlobal' to generate a global laparoscopic network is possible.

ES28-0686 - Best Selected Abstracts 2

Burnout and resilience in obstetrics and gynaecology: a national survey of Wales

Angharad Jones¹, Caryl Thomas¹, Anthony Griffiths¹

¹University Hospital of Wales, Obstetrics and Gynaecology, Cardiff, United Kingdom

Background

With the ever-changing work environment in Obstetrics and Gynaecology, there are increasing concerns regarding burnout in doctors across all levels due to work-related stress. This impacts on staffing levels, team morale, quality of patient care and safety. Research suggests at least 40% of doctors show symptoms of burnout, with Obstetrics in particular a high-risk speciality. We sought to assess the impact of burnout on the Obstetric and Gynaecology (O&G) workforce in Wales with evaluation of resilience.

Methods

Doctors of all grades working in O&G in Wales were contacted via a central email database to complete an anonymous survey on "Survey Monkey" within a week timeframe and data exported into SPSS for analysis. The Oldenburg Burnout Inventory was used to score for exhaustion (physical, cognitive, and affective features) and disengagement. The inventory allowed for each burnout dimension to be analysed as a continuous variable, with greater indication of burnout with increasing scores. Items assessing resilience were developed using resources from Stamford University and American Psychological Association. Data was analysed to assess relationships between burnout, resilience and associated variables of age, experience, subspeciality, commute and on-call frequency. Participants were assessed on risk-taking behaviours, impact on relationships and work stress related health problems.

Results

The response rate was 29% (62.5% trainees and 33.9% consultant). 73% of participants were female and 84% work full-time.

62.5% stated that work impacted negatively on relationships, 30% described using drugs/alcohol and 23% had sought medical help due to work stress.

The mean age was 39 years and resilient behaviours were demonstrated with increasing age. 27% reported receiving formal resilience training.

Less burnout was demonstrated in those with increased resilience. When observing the relationship between burnout and resilience, the coefficient of determination (R^2) shows 48.6% of variability in burnout scores can be accounted by level of resilience, with the remaining 51.4% due to other variables.

Conclusions

This study demonstrates work-related stress has huge impact on our workforce. Results suggest that improving resilience in doctors could potentially reduce burnout and the related impact on attrition rates and patient care. This could be achieved by promotion of positive, supportive workplace behaviours or incorporation of formal resilience training into the curriculum. A logistic regression model could be developed to identify predictors of burnout in doctors to enable resources of support to be directed appropriately or inform junior doctors' choices of sub-specialisation. The next step is to conduct a national survey of BSGE members to assess the effect of burnout on minimal access surgeons, comparing to other sub-specialities within Obstetrics and Gynaecology to evaluate if there is an association with personality type and choice of sub-speciality.

ES28-0473 -

Best Selected Abstracts 2

Pregnancy outcomes after ultrasound-guided focused ultrasound surgery (USgFUS) for conservative treatment of uterine fibroids: experience of a single institution

Jordi Rodriguez¹, Antoni Pessarrodona¹, Anna Carmona¹, Jordi Cassado, Nuria Pons¹, Jordi Isern¹, Jose Angel De Marcos²

¹University Hospital Mutua Terrassa, Obstetrics and Gynecology, Barcelona, Spain

²University Hospital Mutua Terrassa, Radiology, Barcelona, Spain

Background

To assess the impact of ultrasound guided focused ultrasound surgery (USgFUS) for uterine fibroids on fertility.

Methods

Five hundred and sixty patients with symptomatic uterine fibroids were treated using USgHIFU at University Hospital Mutua Terrassa, from February 2008 to February 2018. Pregnancy outcomes and complications were analysed.

Results

After HIFU treatment, 71 pregnancies of 55 patients were obtained. Among them, 58 (82%) cases were natural pregnancies and 13 (18%) were test-tube pregnancies. Of the 55 patients who became pregnant, 44 (80%) were nulliparous, 10 (18%) had at least one miscarriage, 1 had a preterm birth and 18 patients (33%) had primary or secondary infertility before HIFU treatment. After USgFUS treatment, the mean time to conception was 19 ± 18 months (range: 1-72 months) (median 12). Of the 71 pregnancies, there were 22 (31%) spontaneous abortion, 6 (9%) elective terminations, 42 (59%) successful deliveries, including a twin gestation, and 1 (1%) ongoing pregnancy at the time of report. During pregnancy, ultrasound examination detected 3 (6.9%) cases of intrauterine growth restriction (IUGR), 2 (4.6%) smalls for gestational age (SGA), 1 (2.3%) case of Tetralogy of Fallot and one (2.3%) of aberrant right subclavian artery (ARSA). The rate of full-term deliveries was 90% (38/42). The remaining 10% (4/42) were preterm deliveries at 32.5, 34, 34 and 35 weeks due to preterm premature rupture of membranes (PPROM) in the first two cases, and due to placenta previa and preterm labour in the other two. Of the 43 live births, 24 (56%) were born vaginally and 19 (44%) by caesarean section. The complications reported included 3 women with retained placenta (7%), 2 with placenta previa (5%) and 1 with severe preeclampsia (2%). The mean birth weight was 3.1 kg (range: 1.4-4.3), and all babies developed well without complications during postpartum and breastfeeding.

Conclusions

Patients undergoing USgFUS for treatment of uterine fibroids can achieve full-term pregnancies with few intrapartum or postpartum complications. In some cases, USgFUS can even improve the fertility of patients with a history of primary or secondary infertility.

**ES28-0048 -
Best Selected Abstracts 3**

The Bermuda Triangle in endometriosis surgery: a web-based solution for ASRM, ENZIAN and EFI scoring system

Jeroen Metzemaekers¹, Maddy Smeets², Johann Rhemrev², Andries Twijnstra³, James English², Frank Willem Jansen¹

¹LUMC, Gynaecology, Leiden, The Netherlands

²Endometriose in Balans, Gynaecology, Den Haag, The Netherlands

³LUMC, Gynaecology, Leiden, The Netherlands

Background

The World Endometriosis society stated that “Until better classification systems are validated, all women with endometriosis undergoing surgery should have a r-ASRM score and stage completed, women with deep endometriosis should have an Enzian classification completed and women for whom fertility is a future concern should have an EFI score completed and documented in the medical/surgical notes (strong GPP)”

We developed an objective web-based reporting system to improve uniform evidence based (big) data collection. The system is named EQUJUM (**Q**uality and grading instrument for **S**urgical performance in **E**ndometriosis) and can be used worldwide.

The E-QUSUM provides electronic synoptic operative reporting (E-SOR) and easy staging/classification with r-ASRM and ENZIAN of (deep) endometriosis by anatomical pictures. Furthermore, the endometriosis fertility index (EFI) is incorporated for fertility advice after surgery.

Methods

Test enrolled under endometriosis specialists. 20 cases were collected on paper and 20 cases web-based (EQUJUM). The primary outcome was correct staging of r-ASRM, ENZIAN and EFI score between the paper version and the digital EQUJUM system. Secondary outcomes were application of the exception rules for classification systems and to see if this has clinical implications regarding fertility advice after surgery.

Results

r-ASRM was scored right in 0% in the non-digital version versus 60% on the digital method. For the ENZIAN it was respectively 50% correct versus 90%. With the EFI 20% was correct in the paper version versus 70% in the digital version. In the paper version on average 47% of the exception rules were used versus 85% on the digital system. Inherently the incorrect use of the current non-digital classification has clinical impact on fertility score after surgery.

Conclusions

Our study shows that not all exception rules are known under endometriosis specialist and that a digital system could simplify and improve the accuracy of classification of endometriosis. It also shows that incorrect measurement has its impact on clinical relevant outcomes like wrong staging and different EFI score outcomes.

**ES28-0326 -
Best Selected Abstracts 3**

Complications, bowel function and quality of (sexual) life following surgery for deep invasive endometriosis

Wessel Scheepers¹, Jacques Maas¹, Arijan Luijten²

¹Máxima Medical Centre, Obstetrics & Gynaecology, Veldhoven, The Netherlands

²Máxima Medical Centre, Surgery, Veldhoven, The Netherlands

Background

Quantifying the different intraoperative and postoperative complications of bowel surgery for deep invasive endometriosis (DIE) in our centre, to compare these results with international literature and to assess postoperative quality of life and bowel functions with special focus for the low anterior resection syndrome (LARS).

Methods

All patients who underwent rectal shaving, discoid-excision or segmental-resection for DIE between 2013 and 2018 were included in our retrospective analysis of operative reports and post-operative follow-up, allowing to specify and

quantify complications. Postoperative quality of life, constipation, fecal incontinence and LARS-scores were assessed using the endometriosis health profile-30 (EHP-30) and the Groningen Defecation and Fecal Continence (DeFeC) questionnaires. Our data were compared with the most recent meta-analysis on complications following surgery for DIE available.

Results

115 surgeries had been performed in our centre during that time of which 92 shavings, 22 segmental resection and one discoid excision. In total 56 complications were reported including 13 major complications in 11 patients of which: four haemorrhages (one was intraluminal), two rectovaginal fistulas, one anastomotic leakage, two bladder lesions, two cases of vaginal wound dehiscence and two abscesses. These numbers are not significantly different from the complication rates as found in literature. 62% of women who underwent a rectal shaving and 73.9% of women who underwent a segmental resection filled in our questionnaires. We found no significant difference in bowel function between the rectal shaving and segmental-resection group. Interestingly 30.3% of women without a segmental resection still had a postoperative LARS-score indicating minor or major LARS. The shaving group has a significantly better EHP-30 sexual relation score compared to the segmental-resection group. We also found a significant association of the postoperative constipation-score with worse outcomes of the EHP-30 quality of life, pain and sexual relationship scores and an association between a higher LARS score and a worse EHP-30 sexual relationship score.

Conclusions

The incidence of complications in our centre does not differ from the complication rates reported in literature. Postoperative bowel function does not significantly differ between chosen operative techniques. Minor and major LARS can also be found postoperatively in women who underwent only rectal shaving. Postoperative constipation scores are associated with worse quality of life outcomes and a higher LARS score is associated with a lower sexual relationship score.

ES28-0433 - Best Selected Abstracts 3

Is there still a role for laparoscopic radical hysterectomy? Personalizing surgical approach in early stage cervical cancer

Luigi Pedone Anchorà¹, Nicolò Bizzarri¹, Gabriella Ferrandina¹, Giovanni Scambia¹, Valerio Gallotta¹, Vito Chiantera²

¹Fondazione Policlinico Universitario A. Gemelli IRCCS,

Department of Woman and Child Health and Public Health- Woman Health Area, Rome, Italy

²University of Palermo, Department of Gynecologic Oncology, Palermo, Italy

Background

To compare survival outcomes of laparoscopic and open surgery for radical hysterectomy (RH) among patients with early-stage cervical cancer (CC) and to identify which subgroups may benefit from one approach rather than the other.

Methods

237 and 303 consecutive patients, with clinical FIGO stage from IA1 with lymph vascular space involvement to IB1/IIA1 CC underwent open and laparoscopic RH respectively in 3 Italian Institutions. Differences in terms of progression-free survival (PFS) between the two surgical approaches were tested in the entire population and in different patient's subgroups

Results

Median follow up was 34 months. Open and laparoscopy procedures had similar 3-yr PFS rate in the entire series (86.4% vs 85.6%, $p=0.987$). PFS of the two approaches were compared among subgroups stratified by tumour histology, tumour grading, tumour diameter, lymph vascular space status, parametrial invasion, lymph node status and adjuvant treatment. Open and laparoscopic approaches revealed a significantly different 3-yr PFS rate only among patients with >20mm tumour (85.2% vs 69.2% respectively, $p=0.026$). [NB1] On the contrary 3-yr PFS in <2cm tumour did not differ between open and laparoscopic surgery (87.5% vs 93.4% respectively, $p=0.151$).

Conclusions

Tumour diameter could be considered the most important determinant to choosing to guide the choice of surgical approach in early stage CC. Women with > 20mm disease should undergo open RH. In case of tumour <20mm, both of the approaches appear to be safe. Therefore, laparoscopic surgery could still be considered an option in this subgroup of patients.

**ES28-0590 -
Best Selected Abstracts 3**

Comparison of two sonographic classification for adenomyosis evaluation

Chiara Barbanti¹, Lucia Lazzeri¹, Giorgia Monti¹, Gabriele Centini¹, Caterina Exacoustos², Errico Zupi¹

¹*Obstetrics and Gynecology- University of Siena, Department of Molecular and Developmental Medicine, Siena, Italy*

²*Obstetrics and Gynecological Clinic - University of Rome "Tor Vergata", Department of Biomedicine and Prevention, Rome, Italy*

Background

Adenomyosis is a benign uterine disorder characterised by the presence of endometrial glands and stroma within the myometrium surrounded by hyperplastic smooth muscle cells. Considering the importance of transvaginal sonography for management of adenomyosis, in 2018 Lazzeri et al. and in 2019 Van Den Bosch et al. tried to develop a sonographic classification for diagnosing adenomyosis. Lazzeri et al. distinguished adenomyoma, diffuse and focal adenomyosis, they divided it for the outer myometrium and for the junctional zone (JZ) and separated into four grades; finally, they sum the score to divide the disease in mild, moderate and severe. Van Den Bosch et al. classified adenomyosis checking for adenomyoma, focal and diffuse lesion, the involvement of uterine layers and the subjective evaluation of the extent of disease. Evaluating the ultrasound features and the clinical characteristic of women with adenomyosis we tried to compare these two types of classifications, and their association with symptoms.

Methods

We retrospectively evaluated thirty women in fertile age who underwent ultrasound examination and who received a ultrasonographic diagnosis of adenomyosis. For each woman, we considered the sonographic characteristics of the two classifications and the clinical features; dysmenorrhea was investigated using the 10-point Visual Analogue Scale (VAS), while heavy menstrual bleeding was considered in the presence of a Pictorial Blood Assessment Chart (PBAC) >100.

Results

Using the Van Den Bosch et al. classification we found 44% of cases with mild adenomyosis, 31% with moderate and 25% with severe disease. In the Lazzeri et al. mapping system 38% of women presented mild extension, 44% moderate and 19% severe adenomyosis. Considering the Cohen k index, we found very good agreement for mild and severe extension (0,871-0,818) and good agreement for moderate adenomyosis (0,733). In patients in whom all myometrial layers were involved by adenomyosis, considering the classification system, we assigned the highest score in the evaluation of different type of adenomyosis using the mapping system.

Assessing the dysmenorrhea, we found a better agreement between the VAS score and the mild extent evaluated with the Van Den Bosch et al. classification (43% vs 33% of mild type is associated with moderate pain), while using the Lazzeri et al. mapping system we assessed a superior association between the VAS score and the severe extent (50% vs 67% of severe type is associated with severe pain). While, considering the heavy menstrual bleeding, we found no difference between two classifications.

Conclusions

Although these two classifications differently evaluate the extent of adenomyosis (measurement of lesion vs subject evaluation) we found very good-good agreement between two systems. However, we need an international validation of these classifications to improve their agreement with severity of symptoms and to manage the response of the disease to different therapeutic approach.

**ES28-0218 -
Best Selected Abstracts 3**

Incidence of different surgical technics for colorectal deep infiltrating endometriosis on the post-operative fertility

Mathilde Lapointe¹, Mary Pontvianne¹, Justine Riss¹, Lise Lecointre¹, Emilie Faller¹, Cherif Akladios¹

¹*Hôpitaux Universitaires Strasbourg, Gynecology and Obstetrics, Strasbourg, France*

Background

Endometriosis is a chronic inflammatory disease affecting 10 to 15 % of women in childbearing age among which 20% present a deep infiltrating form.

The latter can lead to infertility; indeed the spontaneous pregnancy rate is estimated between 8,7 and 13%.

Surgical treatment seems to improve fertility. The goal of this study is to evaluate the incidence of different surgical

techniques (shaving vs. bowel resection), used in the treatment of colorectal deep infiltrating endometriosis, on post-operative fertility.

Methods

A retrospective study was carried-out among the gynaecologic and obstetric department of Strasbourg, France, university hospital (HUS) from 2009 to 2016.

All the patients with a desire for pregnancy and treated for deep infiltrating colorectal endometriosis were included. Two distinct groups were analysed and compared: treatment by conservative surgery (shaving) and by radical surgery (discoid resection or segmental resection) respectively. The main outcome of the study was the pregnancy rate after surgery. Secondary outcomes were the mode of occurrence of pregnancy: spontaneous versus medically assisted reproduction, the delay of occurrence, the term at birth, the occurrence or not of complications during pregnancy.

Results

We included 94 patients among which 39 benefited from a radical surgery and 55 from a conservative surgery. The two groups had similar pre-operative characteristics.

The pregnancy rate was 52,1% for the whole population without significant differences between the two groups ($p=0.68$). Yet, we found a significantly greater amount of spontaneous pregnancies among the radical surgery group with 73,7% ($p=0,0086$).

Conclusions

This study suggests that, for patients with deep infiltrating colorectal endometriosis, the surgical treatment improves fertility in a general way. Moreover, the radical surgery seems to significantly improve the occurrence of spontaneous pregnancies. However, this surgery is not without risks and multidisciplinary discussions and thorough information to the patient are a prerequisite.

ES28-0260 - Best Selected Abstracts 3

Does extra-ovarian deep endometriosis surgery affect AMH level one year after surgery? A prospective study

Charline Calabre¹, Emilie Faller¹, François Lefebvre², Akladios Cherif¹, Rongières Catherine³

¹University Hospital of Strasbourg, Department of Surgical Gynaecology, Strasbourg, France

²University Hospital of Strasbourg, Department of Medical Information, Strasbourg, France

³University Hospital of Strasbourg, Department of Reproductive Medicine, Strasbourg, France

Background

Deep endometriosis is a usual gynaecologic disease, affecting women of reproductive age. The first-line surgical treatment of endometrioma is cystectomy but several studies show a decreasing Anti-Mullerian-hormone (AMH) levels after surgery. However, up to date, no study concerning serum AMH after extra-ovarian deep endometriosis surgery is published.

Methods

We performed a prospective single centre study comparing the variation in the AMH serum 6 and 12 months after surgery of deep endometriosis isolated (group A) with deep endometriosis surgery associated with endometrioma's cystectomy (group B). Patients who were admitted for a surgery of deep endometriosis in one of the two gynaecological surgery departments of the University Hospital of Strasbourg (HUS), France, could be included in this prospective study, if their age were between 18 and 37 years included. An AMH sample was collected at the HUS the day before or the day of the surgery, 6 months and 12 months after surgery. Primary outcome was the variation in the AMH serum 12 months after surgery, secondary outcomes were pregnancy rate after surgery and variation in the AMH serum 6 months after surgery.

Results

118 patients were included between June 2015 and March 2018, 101 after exclusion of hysterectomy, annexectomy or no deep endometriosis surgery, 53 in the group A and 48 in the group B. Up to this day, 29 AMH serum 12 months after surgery are available in the group A and 20 in the group B.

Patients in group A had a significantly decreasing AMH serum of 1.07 ng/mL 12 months after surgery $p : 0.00481$ and patients in group B had a significantly decreasing AMH serum of 1.37 ng/mL 12 months after surgery $p : 0.00289$, but no difference were founded between group A and B $p : 0.60$.

Patients in group A had a significantly decreasing AMH serum of 0.85 ng/mL 6 months after surgery p : 0.00245 and patients in group B had a significantly decreasing AMH serum of 1.14 ng/mL 6 months after surgery p : 0.00022, but no difference were founded between group A and B p :0.47.

Type of surgery and AFS scale doesn't seem to have an impact on the AMH's change.

However, in patients reporting preoperative infertility, we found pregnancy rates of 44 % in group A and 61 % in group B 1 year after surgery.

Conclusions

The surgery for deep endometriosis seems to reduce AMH serum 12 months after surgery even if cystectomy is not performed but pregnancy rate one year after surgery is encouraging.

ES28-0010 - Best Selected Abstracts 3

lncRNA-H19 regulated cell proliferation and invasion of ectopic endometrium by targeting ITGB3 via modulating miR-124-3p

Songping Liu¹, Hongyan Cui¹, Keqin Hua²

¹Zhenjiang Maternal and Child Health Hospital, Department of Obstetrics and Gynecology, Zhenjiang, China

²Obstetrics and Gynecology Hospital of Fudan University, Department of Gynecology, Shanghai, China

Background

The pathogenesis of endometriosis is not known well and none of the previous theories can explain the etiology of endometriosis completely. Long non-coding RNA (lncRNA) has got much attention in recent years and the related research results have showed a new way to understand the complexity of disease from the dimension of gene expression regulation network. However, there are few reports about lncRNA in endometriosis. In view of this, we used RNA sequencing technology to analyse the transcriptome of endometriosis in the prior study, which indicated that the upregulation of lncRNA H19 was the most obvious in both ectopic and eutopic endometrium. As one of lncRNAs discovered the earliest, lncRNA H19 has achieved remarkable results in other research fields, but rare studies were reported about its function and mechanism in endometriosis.

Methods

A series of experiments, including qRT-PCR, CKK-8, Transwell, gene knockdown, overexpression, dual luciferase reporter assay, were performed to explore how lncRNA H19 interacted with miRNA to regulate the target gene in the pathogenesis of endometriosis.

Results

Elevated lncRNA-H19 was observed in ectopic endometrial cells of women with endometriosis, which may correlate with the progression of endometriosis. Knockdown of H19 in ectopic endometrial cells significantly inhibited cell proliferation and invasion, concurrent with increased miR-124-3p and decreased integrin beta-3 (ITGB3), which was potently counteracted by miR-124-3p inhibitor. Up-regulation of miR-124-3p markedly suppressed ITGB3 expression by binding to the 3' UTR of ITGB3, whereas miR-124-3p inhibition had an opposite effect. In addition, the effects of miR-124-3p mimics on ectopic endometrial cells were potently counteracted by ITGB3 overexpression.

Conclusions

It could be inferred that miR-124-3p and ITGB3 may be the downstream of lncRNA-H19 in endometriosis and down-regulation of lncRNA-H19 could inhibit ectopic endometrial cell proliferation and invasion by targeting ITGB3 via modulating miR-124-3p.

Exosomal long noncoding RNA-NONHAT076754 facilitates endometriosis invasion and is associated with endometriosis recurrence

Junjun Qiu¹, Keqin Hua¹

¹*The Obstetrics and Gynecology Hospital of Fudan University, Obstetrics and Gynecology, Shanghai, China*

Background

Exosome-mediated transfer of long noncoding RNAs (lncRNAs) to influence recipient cells is emerging as a novel mechanism for disease progression. NONHAT076754 is a newly identified metastasis-related lncRNA involved in cancer. Since endometriosis exhibits malignancy-like prometastasis behaviour similar to those observed in cancer, we aimed to investigate whether NONHAT076754 is involved in endometriosis and, if so, whether the exosome-mediated transfer of NONHAT076754 contributes to endometriosis migration/invasion. Additionally, we aimed to investigate the clinical significance of serum exosomal NONHAT076754 in endometriosis.

Methods

The distribution and expression of NONHAT076754 in ectopic, eutopic and normal endometria was evaluated using fluorescence in situ hybridization (FISH) and quantitative real-time polymerase chain reaction (qRT-PCR). Primary ectopic endometrial stromal cells (Ec-ESCs) and eutopic endometrial stromal cells (Eu-ESCs) were isolated and confirmed by immunocytochemical staining. A lentivirus system was used to silence NONHAT076754 in Ec-ESCs. Exosomes derived from Ec-ESCs were identified using transmission electron microscopy (TEM), nanoparticle tracking analysis (NTA) and western blotting and labelled using the green dye PKH67. In vitro functional migration/invasion assays were performed to investigate the roles and mechanisms of exosomal NONHAT076754 in endometriosis migration/invasion. Additionally, the expression pattern and clinical relevance of serum exosomal NONHAT076754 in endometriosis were investigated.

Results

We found that NONHAT076754 was mainly located and highly expressed in ectopic endometrial stromal tissues than in the paired eutopic and normal endometria. In vitro, using NONHAT076754-high-expression Ec-ESCs and NONHAT076754-low-expression Eu-ESCs as cell models, we initially extracted and characterized the exosomes derived from Ec-ESCs. TEM and NTA results showed that the isolated exosomes had a spherical-shaped appearance and a predominant size of 30-150 nm in diameter. Western blot analysis confirmed that the exosomal markers CD9 and Hsp70 were enriched in the isolated exosomes, suggesting that the exosomes were successfully isolated. Subsequently, we observed that the PKH67-labeled Ec-ESCs derived exosomes were effectively internalized by recipient Eu-ESCs. Further in vitro loss-of-function experiments showed that exosome-shuttled NONHAT076754 could be transferred from Ec-ESCs to recipient Eu-ESCs which in turn elicited the migratory/invasive ability of recipient Eu-ESCs partially through the regulation of ZO-1, E-cadherin and N-cadherin, eventually facilitating endometriosis migration/invasion. Notably, NONHAT076754 could be detected in serum exosomes of endometriosis patients. The serum exosomal NONHAT076754 expression in endometriosis patients was significantly higher than that in controls. Elevated serum exosomal NONHAT076754 was closely associated with the advanced clinical stages and recurrence of endometriosis.

Conclusions

Our study elucidates a potential crosstalk between ESCs via exosomes in endometriotic milieu, suggests a novel mechanism for the malignancy-like prometastasis behaviour of endometriosis from the perspective of the "exosomal transfer of lncRNA" and highlights the potential of serum exosomal lncRNA -NONHAT076754 as a biomarker for endometriosis.

PHD ABSTRACTS (9)

ES28-0316 -
PHD Session

Reproductive performance after at least 35 months following the application of hyaluronic acid gel after dilatation and curettage for miscarriage

Angelo Hooker¹, Judith Huirne², Jos Twisk³

¹Zaans Medical Center ZMC, Department of obstetrics and Gynaecology, Zaandam, The Netherlands

²Amsterdam UMC - location VU University Medical Center, Department of Obstetrics and Gynecology, Amsterdam, The Netherlands

³Amsterdam UMC - location VU University Medical Center, Department of Epidemiology and Biostatistics, Amsterdam, The Netherlands

Aim

To examine whether intrauterine application of auto-crosslinked hyaluronic acid (ACP) gel, following dilatation and curettage (D&C) improves reproductive performance after at least 35 months follow-up.

Background

Intrauterine adhesions (IUAs) are encountered in approximately one in five women following a miscarriage, with 42% of moderate to severe extent. Women with recurrent miscarriage have an increased risk for adhesion formation; the number of dilatation and curettage (D&C) procedures seems to be the main driver behind the association. The presence of moderate to severe IUAs can have debilitating effect on women's health, predisposing to fertility, pregnancy and obstetric complications. Even after appropriate treatment, reproductive outcomes often remain unsatisfactory, constituting a great threat to the women's health. Therefore, prevention of adhesions is crucial. While detection remains essential as treatment can improve outcome.

The Prevention of Adhesion Post Abortion (PAPA) study, a multicentre, prospective randomized controlled trial (RCT) showed that application of auto-crosslinked hyaluronic acid gel (ACP), in women who experienced at least one previous D&C, results in a significant lower rate of IUAs, 13.0% versus 30.6% (relative risk (RR) 0.43, 95% confidence interval (CI) 0.22-0.83), lower mean adhesion score and significant less moderate to severe IUAs. Although subsequent fertility is a key consideration, data on reproductive performance following application of ACP after D&C for miscarriage remain limited.

Materials / Patients

The PAPA study, a multicentre, women- and assessors-blinded RCT was conducted in eight centers in The Netherlands. The study was registered at the Dutch Clinical Trial Registry (NTR 3120), by the ethics committee of the Free University Medical Center (2011/2562011/256), and by the boards of directors of all the participating hospitals. In summary, 152 women aged eighteen years or older who experienced a first trimester miscarriage (less than fourteen weeks) with at least one dilatation and suction or abrasive (blunt or sharp) curettage (D&C) in history were randomized. In women assigned to the intervention group, one sterile syringe containing 10 ml ACP gel was applied in the uterine cavity and cervical canal, after the D&C procedure. Women in the control group received D&C without the application of ACP gel. A follow-up hysteroscopy was scheduled eight to twelve weeks after the initial D&C procedure in all patients and if IUAs were seen they were lysed in the same setting as we found it unethical not removing them if visualized.

Methods / Results

To evaluate reproductive outcomes, participants received a questionnaire by post or email after at least 35 months. The questionnaires consisted of questions related to received interventions, complications, menstrual cycle characteristics and symptoms, contraceptive use, the desire to become pregnant, conception and outcome of subsequent pregnancies. The primary outcome were an ongoing pregnancy and live birth after following the D&C procedure.

The response rate after at least 35 months was 91.7% in the intervention group versus 94.1% in the control group. The number of respondents with IUAs was respectively 12.1% in the intervention group versus 28.1% in the control group, $p=0.029$. In all cases, adhesiolysis had been executed at that time according to study protocol.

Of the women pursuing a pregnancy, the conception rate was similar in both groups, respectively 98.1% in the intervention group versus 96.7% in the control group. The ongoing pregnancy rate was 94.2% versus 71.7% ($p<0.01$) the live birth rate 88.5% versus 70.0% ($p=0.02$). The miscarriage rate was respectively 26.9% versus 38.3% ($p=0.23$). The ectopic pregnancy and termination of pregnancy rates were similar.

Discussion

IUAs is an acquired condition that can have a debilitating impact on women's health and quality of life and has become a common cause of female infertility, due to increasing intrauterine surgery. IUAs formation is multi factorial, with multiple predisposing and causal factors (ref). The pathogenesis of IUAs is still poorly understood while it is imperative to understand the underlying pathophysiology to be able to identify prevention measures. The most important predisposing factor is the pregnant uterus, which seems susceptible to trauma to the endometrium but constitutional characteristics, inflammation and infection are also considered relevant factors

In the current study participants of the PAPA-study, women with at least one D&C in history who received questionnaires at least 35 months after the D&C procedure to establish reproductive performance. The conception rate of women pursuing a pregnancy was similar in both groups, but significant more ongoing pregnancies and live births were encountered in the intervention group, after application of ACP gel. Furthermore, there was a non-significant decrease in miscarriages. As all detected IUAs were routinely removed, as it was considered unethical not to perform adhesiolysis, the reported differences are probably an underestimation of the real difference between the groups.

Conclusion

In the current report reproductive performance after at least 35 months following intrauterine application of ACP gel following D&C for miscarriage in women who have experienced at least one previous D&C are reported. It seems reasonable on basis of the presented results to assume that application of ACP improves subsequent fertility and reproductive performance.

The results of our study encourage the design of a larger RCT comparing the application of ACP gel versus controls, with reproductive outcomes as primary objective.

Impact to Patients' Health

IUAs is an acquired condition that can have a debilitating impact on women's health, fertility and quality of life. Prevention of IUAs and particular improving reproductive performance may have a huge impact of the quality of life of women who have experience recurrent miscarriages.

ES28-0195 - PHD Session

Bioengineering strategies of the uterus towards improving current investigative models and female reproductive health

*Hannes Campo*¹, *Ximo García-Domínguez*², *Sara López-Martínez*¹, *Francisco Marco-Jiménez*², *Irene Cervelló*¹, *Antonio Pellicer*¹

¹Fundación IVI- Instituto de Investigación Sanitaria La Fe, innovation and research, Valencia, Spain

²Instituto de Ciencia y Tecnología Animal- Universitat Politècnica de València, Ciencia Animal, Valencia, Spain

Aim

The main objective of this thesis was to use tissue-engineering approaches to make decellularised whole uteri and using this to create different types of biomaterials that could innovate aspects within reproductive medicine. We investigated if these bioscaffolds could improve current investigative *in vitro* models while also showing potential to be used as a novel treatment for female pathologies that lead to reproductive dysfunction.

Background

Tissue engineering (TE), represents a promising interdisciplinary field of investigation, combining aspects of cell transplantation, materials science and bioengineering. The original aim of TE, defined by Langer and Vacanti, is to restore, maintain or improve function of tissues or whole organs (regenerative medicine, *in vivo* application). However, these engineered tissues have also evolved into a viable option for drug testing, disease modelling and precision medicine (*In vitro* applications). What sets TE apart is the use of biomaterials or scaffolds; these are devices or constructions with specific and complex physical and biological functions that interact through biochemical and physical signals with cells and, when implanted, with the body environment.

Decellularisation (DC) is an innovative method to create complex natural scaffolds. Here, all cellular material is removed from a tissue or organ, while maintaining the hierarchical complexity, composition and the three-dimensional (3D) ultrastructure of the extracellular matrix (ECM). The composition of the ECM is unique and dynamic for each tissue, making it a potentially ideal tissue-specific scaffolding material. By removing the cellular antigens, detrimental immunological or inflammatory reactions are attenuated. This means that biomaterials from both allogeneic and

xenogeneic origins can be used. The last and unique advantage of decellularised biological scaffolds is the ability to decellularise entire organs by perfusion. By using the vascular system, decellularisation agents are delivered to all layers of the organ, where the cells are lysed. Cellular debris is then removed, leaving an acellular vascularized three-dimensional bioscaffold.

This complex DC tissue can be processed in various ways to serve different purposes. For instance, sections or blocks of decellularised tissues can be made and seeded with different types of (stem) cells to create three-dimensional cell culture systems. These acellular scaffolds can be also converted into ECM hydrogels or coatings. These injectable ECM hydrogels undergo a non-toxic, collagen-based self-assembly process into a nanofibrous hydrogel when incubated at 37°C or introduced *in vivo*, which makes them an interesting option for regenerative medicine purposes and especially for minimally invasive procedures. A good example of this type of hydrogels is a porcine-derived myocardial ECM hydrogel, showing therapeutic potential in animal models as treatment after myocardial infarction and is currently in clinical trials (ClinicalTrials.gov Identifier: NCT02305602).

Materials / Patients

For the purposes of this thesis, two animal models were used: the pig and rabbit model. This will be reflected in the structure of the methods, results and discussion.

Methods / Results

The goal of the pig model was to develop a perfusion-based DC protocol usable for large reproductive organs, resulting in a biocompatible bioscaffold. The effect of a prior freeze/thaw (F/T) step was also assessed. For this, three frozen-thawed and three fresh uteri were subjected to a protocol we optimised for the pig uterus. After two identical 24-hr DC cycles a macroscopically acellular matrix was produced, having a semi-transparent and white appearance.

The DC efficiency was tested by histology (H&E) and by DNA and protein quantification. Additionally, the physical and possible mechanical properties were demonstrated by the presence of native collagen fibres visualised with Masson's trichrome and Alcian blue staining. The absence of vital cellular constituents shows that a sufficient amount of native cell material was removed to consider the organ as a 'decellularised scaffold'. Vascular corrosion casts, immunofluorescence (Collagen I & IV, elastin, laminin and fibronectin), scanning and transmission electron microscopy (SEM, TEM) were also performed. These tests demonstrated that the major components of the ECM were preserved. Vascular integrity was slightly compromised but capillary structures were present in all corrosion casts, also the ultrastructure retained its fibrous aspect. Furthermore, the F/T step did not noticeably affect the ECM architecture in our experience.

The final step was to verify the biocompatibility of the generated xenogeneic scaffolds *in vitro*. Human endometrial Side Population stem cell lines (ICE 6 & 7) were cultivated on top of endometrial disk in hypoxic conditions; after 3-4 days they rolled up and after 9-12 days organoid-like structures were observed. This structure was further investigated by histology, showing a tight interaction between the cells and the scaffold. Furthermore, endometrial cells of both epithelial (cytokeratin positive) and stromal (vimentin positive) fractions were identified in the structure.

The goal of the rabbit study was to create coatings and hydrogels from decellularised endometrial tissues and compare the *in vitro* embryo development on these substrata, commercial options and standard culture conditions. Four whole uteri were first decellularised, two from non-synchronous rabbits (NS) having a non-proliferating endometrium and two from rabbits 72h after ovarian stimulation (S, synchronous with day 3 embryos). After testing DC efficiency, the acellular endometrium was separated via microdissection, lyophilised and milled. This ECM enriched powder was put into suspension by partial digestion. The resulting hydrogel was characterised by analysis of proteomics, electron microscopy and gelling kinetics. Gelation of the S hydrogel started almost immediately and tended to have a lower lag time than the NS hydrogel ($t_{lag} = 2.98 \pm 0.86$ min vs 4.9 ± 0.33 min). Scanning electron microscopy of the gel surface showed that both NS and S gels have a homogenous, randomly interlocking fibrillar structure of similar density.

Hatching rates, morphometry and mRNA expression of 3 core pluripotency markers (OCT4, Nanog and SOX2) were analysed and compared in day 3 embryos cultured for 48h in 8 different culture conditions:

- Three different surface coatings or hydrogels made from non-synchronous acellular endometrium (NSC & NSH), synchronous acellular endometrium (SC & SH) and Matrigel (MC & MH).
- Two standard culture conditions using uncoated wells with culture medium supplemented with and without 10% Fetal Bovine Serum (C+FBS and C-FBS, respectively).

Our results showed that development was significantly affected by the hydrogel culture conditions, averaging around $27.64 \pm 26.38\%$. However, this was not the case for the coating conditions, the mean value of hatching rate here was $89.4 \pm 3.13\%$. The mean diameter of the embryos of SC and C+FBS groups was significantly higher than the diameter of the NSC, C-FBS and MC groups after 48 hours of *in vitro* culture. In addition, the pattern of mRNA expression of NANOG was not significantly affected by culture conditions. Nevertheless, blastocysts developed in NSC group

showed higher levels of OCT4 transcript abundance than C-FBS group, while SOX2 transcript abundance was higher in the blastocysts developed in SC, NSC and C+FBS groups, in comparison with the MC and C-FBS groups.

Discussion

With more than 70 million couples affected, infertility is considered a worldwide public health issue, affecting both males and females, many of which come from developed countries. In the United States alone, 12% of 15-44 years old women (7.3 million) have impaired fecundity. These issues resulted in the birth of medically assisted reproduction and great advances in treating have been made ever since. However, some of the pathologies leading to reproductive dysfunction are still poorly treatable and can profit greatly from advances made by reproductive bioengineering.

One of the main afflictions in reproductive medicine that was untreatable until recently is Absolute Uterine Factor Infertility (AUI). Until recently, gestational surrogacy was the only alternative, the only definitive treatment for AUI is allogeneic transplantation. Apart from the inherent risk of surgery, there are long waiting periods caused by the lack of compatible donor organs and the need for long-term immunosuppression after the transplantation. The latter is associated with severe side effects lowering the quality of life of the patients. Examples of this are nephrotoxicity, increased susceptibility to infections, diabetes and accelerated arteriosclerosis. Many techniques and technologies are being developed to resolve the problems affecting organ transplantations. One line of investigation, the de- and recellularisation of whole organs, has shown promising results to possibly someday engineer transplantable organs.

For this, a DC protocol was first established for large porcine uteri, and the effects on the ECM, ultrastructure and vasculature was evaluated extensively to evaluate the protocol for possible whole organ bioengineering. Altogether, it is apparent that the destructive structural changes to the ECM are reduced to a minimum, offering a usable complex bioscaffold for future recellularization experiments. The biocompatibility was tested by recellularising thin sheets of the endometrium with human endometrial SP stem cells, more optimisation and investigation have to be done to be able to confirm if the formed structures are functional organoids.

Additionally, this perfusion protocol was only slightly changed for the rabbit uterus that is synchronous or nonsynchronous with an embryo at day 3 of development. In this study we present that endometrial tissue-specific ECM derived coatings obtained from whole decellularised organs create a biomimetic environment allowing for the growth of pre-implantation embryos. Furthermore, this sensitive *in vitro* technique demonstrates that the specific mixture of biochemical signals derived from the native microenvironment is retained after biochemical and mechanical treatments. We demonstrated the appropriate preservation of the ECM, providing for the first time the initial step to mimic the endometrial environment *in vitro*. We demonstrated that coatings from synchronous decellularized endometrium act as a biomimetic support for rabbit embryo development and is comparable to optimal protocols, possibly because of the slow release of synchronous-specific endometrial proteins.

This investigation shows that endometrial ECM hydrogels and coatings have the potential to become a platform used in the culture of stem/progenitor cells and primary culture cells to better maintain their tissue-specific phenotype, improving *in vitro* models.

Conclusion

In this thesis, we intended to develop tissue-engineering approaches based on decellularised (DC) uterine tissues obtained from whole organs to improve several aspects within reproductive medicine. We hypothesised that the decellularisation of whole uteri from different species has not only the potential to, one day, create tissue-engineered, transplantable organs as but that the DC endometrial fraction can also be processed further into thin sections, ECM hydrogels and coatings that can be used as a biocompatible tissue-specific substrate for cell and embryo culture. These hydrogels could also have *in vivo* applications for treating endometrial pathologies.

In conclusion, tissue engineering is a promising and burgeoning multidisciplinary field of investigation, poised to transform translational medicine and investigation. Even though it is only in its infancy for reproductive medicine, techniques such as the de- and recellularisation of tissues and 3D *in vitro* approaches based on tissue-specific hydrogels have shown promise to treat even the most intrusive female pathologies that lead to infertility.

Impact to Patient's Health

There are several uterine pathologies that could benefit from the tissue engineering and from the investigation done in this thesis. Absolute uterine factor infertility (AUI) affects 1 in every 500 women of fertile age, which translates to possibly up to 1.5 million women worldwide. AUI can come from congenital origins or be acquire. The only true way to restore fertility is by uterine transplantation, the proof-of-concept was recently provided by the Brännström group, where the first successful live birth after uterus transplantation was achieved. Great strides have been made in vital organs in the recellularisation of whole organs, giving hope to one day create a transplantable uterine construct for these patients. Endometrial atrophy (EA) is a rare pathology where the endometrium never grows thicker than around 7 mm, which is correlated with a decreased probability of pregnancy and is considered as suboptimal for embryo transfer. In Asherman's syndrome (AS), the functional endometrium is destroyed due to intrauterine adhesions. As treatment drugs, hormones, cell treatment and chirurgical options are established or under investigation for these

endometrial pathologies. However, it is apparent that bioengineered tissue-specific approaches such as ECM hydrogels are a promising avenue to be used as a minimally invasive treatment for these patients.

ES28-0256 - PHD Session

Prospective controlled assessment of stress hormones and pain in patients undergoing myomectomy performed by laparoscopy versus laparotomy

Konstantinos Katrantsiotis¹, George Pados¹, Dimitrios Tsolakidis¹, Spiridon Gerou², Konstantinos Almaloglou³

¹*Papageorgiou Hospital Thessaloniki, Endoscopic Surgery, Thessaloniki, Greece*

²*Analysis Laboratory, Diagnostic and Research Centre, Thessaloniki, Greece*

³*Diavalkaniko Hospital, Endoscopic Surgery, Thessaloniki, Greece*

Aim

The rapid technological advance in all fields of medicine has brought forth new horizons of treatment. Surgery could not remain unaffected. Laparoscopic surgery undoubtedly has certain advantages compared to laparotomy in terms of *de novo* adhesion formation, recovery, shorter hospital stay and consequently secondary financial benefits for the patient and health system, as well as postoperative pain, but which has not been evaluated objectively.

The aim of this study was the prospective assessment of surgical stress and post-operative pain through the determination of stress hormones and patient discomfort, as well as the determination of the stress hormones' response after myomectomy performed by laparoscopy versus laparotomy.

Background

The initial idea of the study was cleverly conceived by the laparoscopic surgeon Prof. G. Pados, who considered necessary to actively demonstrate the benefits of endoscopic surgery through a clinical trial and stress hormone measurement. The protocol was approved by the Surgical Department Board of Aristotle University of Thessaloniki on 20/03/2012 with protocol No:10. Soon afterwards, on 14/1/2013, it received the approval of the Bioethical Committee of the Aristotle University Medical School with protocol No:19. Active measurements started and study progress and reports were presented in the following years from 2014 to 2017. Soon afterwards, after the finalisation of measurements, the results were processed by a statistical analyst subsequently leading to the completion of the PhD and submission of it to the university. All operations were performed by the same two surgical teams in the 1st department of OB-GYN of General Hospital of Thessaloniki Papageorgiou (laparotomy) and endoscopic surgery department of "Diavalkaniko" Medical Centre (laparoscopy) respectively. The samples were handled in the Biochemistry Department Laboratory of Papageorgiou General Hospital and in "Analysis" Biochemistry Laboratory.

Materials / Patients

This is a prospective matched case control study of women who underwent myomectomy. For that reason, a total of 65 patients were included in the cohort, of which 30 were treated by laparoscopy, 30 by laparotomy and 5 were excluded due to exclusion criteria, such as different surgery outcome, blood transfusion etc. Indications for intervention were: (i) symptomatic growth of a uterine leiomyoma resulting in changes in menstrual profile (menometrorrhagia). (ii) Infertility if distortion of the uterine cavity was revealed by hysterosalpingography. (iii) History of abortion or preterm delivery if the presence of the leiomyoma compromised the shape of the uterine cavity. The maximum diameter of the operated leiomyomas was 8cm, the maximum collective diameter of them 15 cm and the total amount was up to 4. The BMI of the patients was 23.6 ± 4.25 and 26.20 ± 5.88 in the laparoscopy and laparotomy groups respectively.

Exclusion criteria involved allergies, endometriosis, endocrine disorders, previous laparotomy, pre-operative GnRH-a, number of fibroids greater than 4, sum of the largest diameter of all 4 fibroids greater than or equal to 15 cm and size of each one more than 8 cm. All surgical procedures were performed by the same two surgical teams as mentioned above and the surgical technique in both open and laparoscopic surgery was identical.

Methods / Results

Three venous blood samples were received from each patient. The first one was collected before surgery, the second at the end of the surgical procedure after extubation with the patient awake and the third on the morning of the first post-operative day. The blood samples were centrifuged, tagged and stored in deep freeze conditions (-90°C) until analysed. They were finally measured together to avoid inter-assay & intra-assay variation. We evaluated intraoperative and postoperative variations of the following stress related markers: adrenocorticotrophic hormone (ACTH), corticotropin-releasing factor (CRF), cortisol, noradrenalin and b-endorphin. Cortisol was measured by direct chemiluminescent technology (ADVIA Centaur Siemens), ACTH was measured by sequential chemiluminescent

immunometric assay, (Immulite 2001- Siemens Healthcare Diagnostics Ltd). CRF and b-endorphin were measured by ELISA (Phoenix Pharmaceuticals Inc.), while noradrenaline was measured by the same method using the IBL International GmbH kit. Statistical analysis was performed with SPSS v23 (SPSS, Inc. Chigago IL, USA) using the Wilcoxon signed-rank non-parametric statistical test with a significance threshold of $p < 0.01$. Furthermore, a questionnaire was administered the first post-operative day, in which patients were asked to indicate the level of pain they were experiencing through a Visual Analog Scale of Pain (VASP). An informed consent form was signed by each patient prior to the surgery after detailed explanation of the aim of the study, the minimal impact to the patient and the anonymity of the study. There was no change in patient's management since all venous blood samples were collected at the same time of the programmed pre and post-operative patient evaluation protocol of the clinic.

Results

The mean age of the patients was 37.9 ± 5.66 and 39.53 ± 4.82 in the laparoscopy and laparotomy groups respectively. Operation time was 86.67 ± 25.87 mins in the laparoscopy group and 70.67 ± 23.81 mins in the laparotomy one ($p = 0.028$). The hospitalisation time presented substantial difference for the two procedures as it was one day for all laparoscopic and 3 days for the laparotomy procedures according to the relevant treatment protocols ($p < 0.01$). The mean number of fibroids was 1.57 ± 0.73 and 1.63 ± 0.89 in the laparoscopy and laparotomy groups respectively. The mean volume was $171.37 \pm 100.63 \text{ cm}^3$ and $202.77 \pm 127.49 \text{ cm}^3$ in the laparoscopy and laparotomy groups respectively ($p = 0.434$).

There were significant differences between the two groups for ACTH with $15.90 \pm 9.02 \text{ pg/ml}$ and $12.68 \pm 9.97 \text{ pg/ml}$ in the laparotomy and laparoscopy groups respectively ($p < 0.025$) on the 1st post-operative day. Also, noradrenalin was different in the 1st post-operative day with $20.7 \pm 7.28 \text{ ng/ml}$ and $22.33 \pm 5.82 \text{ ng/ml}$ and in the laparoscopy and laparotomy groups respectively ($p < 0.027$).

CRF values were statistically significant amongst the groups in all the phases with higher ones for laparoscopy (1.10 ± 0.98 , 1.17 ± 1.08 and $1.12 \pm 1.01 \text{ ng/ml}$ for pre, post and 1st post op day respectively) and lower for laparotomy (0.52 ± 0.78 , 0.61 ± 0.89 and $0.63 \pm 0.97 \text{ ng/ml}$ for pre, post and 1st post op day respectively) with $p < 0.003$, $p < 0.009$ and $p < 0.05$ for each respective comparison.

Of note is the fact, that CRF measurement in the laparotomy group on the 1st postoperative day was statistically significant from the pre-surgery measurement of the same group ($0.52 \pm 0.78 \text{ ng/ml}$ pre to $0.63 \pm 0.97 \text{ ng/ml}$ on the 1st post op day with $p = 0.028$). No such difference was evident for the laparoscopic group.

Postoperative pain was significantly higher in the laparotomy group with an average score of 5.67 ± 1.15 and 3.3 ± 1.05 for the laparotomy and the laparoscopic group respectively on the V.A.S.P scale ($p < 0.001$).

On the contrary, no statistical difference was observed in cortisol levels on the 1st post-op day, ($11.71 \pm 5.82 \text{ } \mu\text{g/dl}$ and $11.81 \pm 7.61 \text{ } \mu\text{g/dl}$ for laparoscopy and laparotomy groups respectively) ($p > 0.94$) and, also, for b-endorphin levels ($4.88 \pm 1.57 \text{ ng/ml}$ and $4.91 \pm \text{ ng/ml}$, ($p > 0.61$).

Discussion

The human body has the ability to carry out numerous processes at the same time and also has adaptive mechanisms that are not depleted in the fulfilment of their physical needs but extend to the assurance of their mental wellbeing. This corrective action varies according to each person's ability to adapt, intensity and duration of the stimulus and is different in each human being, depending on previous experience and response.

Today, we know that after an intense physical stimulus such as surgery, the body reacts with the mobilisation of the autonomic nervous system that leads to a series of hormonal changes. These in turn modify the function of many organs and systems, including circulatory and immune systems and bring changes in homeostasis in general. This reaction, known as response to surgical stress, is believed to implicate a whole cycle, in which the endocrine, nervous and immune systems interact in both directions. All these changes aim at maintaining an adequate blood flow to the vital organs as well as in the mobilisation of energy sources such as glucose and free fatty acids at a time when the requirements of the body are high. Through the homeostasis of these mechanisms, the human body ensures mental and physical health.

The majority of open surgery methods nowadays have a corresponding laparoscopic method. Laparoscopic surgery has undeniable advantages over laparotomy in terms of postoperative pain, recovery and reintegration of the patient in previous activities, lower rate of *de novo* adhesion formation and shorter duration of hospitalisation and therefore the development of operative laparoscopy represents one of the most important milestones in the field of surgery in the past 20 years. With regard to the stress of patients, although reported to be less, the efficacy of the laparoscopic approach to the postoperative neuroendocrine and immune response, which largely determines the postoperative course of the patients, has not been adequately documented. Comparative laparoscopic and laparotomy studies focus on pain monitoring for both methods and not on prospective comparative assessment of stress hormones. There are few studies of stress in these two methods.

Conclusion

In conclusion, this study is the first to our knowledge regarding the assessment of stress hormones by monitoring the biochemical markers ACTH, cortisol, β -endorphin, norepinephrine, CRF and postoperative pain in women undergoing myomectomy by laparoscopy vs laparotomy. It is clear, therefore, that laparoscopy is superior to laparotomy for the surgical removal of fibroids in terms of postoperative pain and surgical stress.

The main limitation of the study is the relatively small number of patients under investigation, although there are no other studies in the literature addressing this issue, while the prospective design of the study, as well as the extensive number of factors examined ensure a very thorough scientific approach.

Impact to patient's health

The study has a strong positive impact to patient's health as it clearly demonstrated that laparoscopic surgery has important modifying effects on classic endocrine metabolic responses, stress hormones and pain. Although more data is needed, the clinical consequences of these findings in relation to stress and pain reduction combined with the favourable surgical outcome and provision of an active rehabilitation with early mobilisation, place laparoscopy as the surgical method of choice.

ES28-0382 - PHD Session

Adenomyosis: diagnosis and steps towards a molecular analysis

Tina Tellum^{1,2}, Marit Lieng^{1,2}, Erik Qvigstad^{1,2}

¹*Oslo University Hospital, Department of Gynaecology, Oslo, Norway*

²*University of Oslo, Institute of Clinical Medicine, Oslo, Norway*

Aim

This thesis is thematically structured into two parts. In the first part, we aimed to validate existing diagnostic criteria for adenomyosis in transvaginal ultrasound (TVUS) and magnetic resonance imaging (MRI) and further develop imaging algorithms that could help diagnose adenomyosis in a premenopausal population. In the second part, we wanted to evaluate if it is safe and possible to obtain tissue of adenomyosis without a hysterectomy and by that offer the possibility of molecular investigations of adenomyosis in a younger, non-hysterectomy population.

Background

Adenomyosis is defined by the presence of ectopic endometrial tissue located in the muscular wall of the uterus. The predominant symptoms of adenomyosis are severe dysmenorrhea and heavy menstrual bleeding, which cause concomitant disease such as anaemia and reduce the quality of life. Adenomyosis also has broader implications, such as a negative impact on fertility and pregnancy outcome. The presence of adenomyosis or not will fundamentally influence both surgical and medical decision making, and it is especially relevant to identify adenomyosis in younger, fertile women where hysterectomy is not an option. MRI and TVUS play the most important roles in diagnosing adenomyosis, but both have their limitations. In TVUS, many signs are described but there is no consensus on which and how many should be used. Also, the most specific signs are rare, and the most common very unspecific. This is challenging, especially for less experienced gynaecologists. When we developed this study, only the research by Exacoustos et al. described 3D TVUS in diagnosing adenomyosis. The study showed a high diagnostic accuracy and we found it relevant to validate those findings. We also wanted to investigate if 3D TVUS could reach the same diagnostic accuracy as MRI.

In MRI, mainly one diagnostic sign is used: the maximal width of the junctional zone (JZ_{max}). However, there are only three studies that prospectively investigated the diagnostic accuracy of MRI in diagnosing adenomyosis compared to the gold standard, which is histopathology; those studies were performed 18-23 years ago and included a large number of postmenopausal women. We wanted to investigate how JZ_{max} would perform with the use of modern MRI and in a younger, premenopausal population.

While imaging modalities are indispensable in clinical practice, they contribute little to clarify the pathological mechanisms underlying adenomyosis. Experimental studies are better suited to reveal those pathways and provide possible therapeutic tools. Previous reports on the molecular implications of adenomyosis have come from studies that used tissue obtained from hysterectomy specimens, which are more likely to represent more-advanced stages of adenomyosis. Therefore, we found it relevant to investigate if adenomyosis tissue can be safely obtained in vivo, with ultrasound-guided, transvaginal biopsies. Furthermore, if adenomyosis glands can be isolated from the myometrial fractions by laser-capture microdissection (LCM) in those samples.

Materials / Patients

One hundred consecutively enrolled premenopausal women aged 30–50 years, undergoing hysterectomy due to a benign condition, not using hormonal treatment.

Methods / Results

This is a prospective, single-centre cohort study (university hospital). All women underwent 2D and 3D TVUS investigations, MRI and hysterectomy without morcellation. Before hysterectomy, when the woman was in full anaesthesia, ultrasound-guided, transvaginal uterine core biopsy samples were obtained. All tests were performed and documented in a standardised form. The 2D TVUS, 3D TVUS, and the transvaginal biopsies were performed and analysed by the PhD. candidate, the MR images by two independent radiologists with >12 years of body imaging experience, and the histopathological analysis by two independent pathologists. All were blinded to the findings from the other modalities and each other. Clinical information was collected using a questionnaire. The hysterectomy specimen was analysed in a standardised manner, obtaining a large number of sections from each region. The presence of ectopic endometrial glands and stroma at 2.5mm below the endometrial-myometrial junction was defined as adenomyosis. For ultrasound, two or more of the following parameters were considered diagnostic of adenomyosis: a globular uterine shape, asymmetry of anterior and posterior walls, presence of myometrial alterations (hyperechoic islets, fan-shaped echo, subendometrial buds and lines, anechoic areas, and myometrial cysts); those were assessed using 2D TVUS. Further a $JZ_{max} \geq 8$ mm and the irregular appearance of the JZ in the sagittal and coronal planes, as determined using 3D TVUS. The independent diagnostic performance (sensitivity, specificity, negative predictive value (NPV), positive predictive value (PPV) and area under the curve (AUC)) for each diagnostic sign (predictor) was calculated. In addition, these variables were combined into a prediction model, where the β values calculated by logistic regression quantify the effects of the variables on the probability of adenomyosis. For MRI, the presence of a $JZ_{max} \geq 12$ mm, the presence of ill-defined, low-intensity areas and/or high-intensity signal spots in T2 weighted images were considered diagnostic. Also, the appearance of the JZ was classified into regular or irregular, based on pattern recognition.

For the in-vivo biopsies, any trauma to the pelvic organs, blood loss, and other complications were documented during the subsequent hysterectomy. Two biopsy samples were analysed histopathologically to confirm the presence of adenomyosis, and another two were snap frozen using liquid nitrogen. Laser microscopy dissection (LCM) and RNA extraction were performed on the collected samples, to proof the concept that those samples are useful for molecular analysis.

97 women underwent a hysterectomy, of which two had inconclusive histopathology, and two did not have an MRI. Eighty-one underwent biopsy taking. Fifty-nine women had adenomyosis; the mean age of the population was 42 years (range 30–50). For 2D and 3D TVUS, the combination of nine predictors into a diagnostic prediction model showed a good test quality [AUC=0.86 (95% CI=0.79–0.94), optimal cutoff 0.56, sensitivity of 85%, specificity 78%]. These signs were included into the prediction model [(sensitivity, specificity, β) or (AUC, β): presence of myometrial cysts (51%, 86%, $\beta=0.86$), fan-shaped echo (36%, 92%, $\beta=0.54$), hyperechoic islets (51%, 78%, $\beta=0.62$), globular uterus (61%, 83%, $\beta=0.2$), normal uterine shape (83%, 61%, $\beta=-0.75$), thickest/thinnest ratio for uterine wall (0.61, $\beta=0.26$), JZ_{max} (sagittal plane) (0.71, $\beta=0.1$), regular appearance of JZ (31%, 92%, $\beta=-1.0$), and grade of dysmenorrhea measured on a verbal numerical rating scale (0.61, $\beta=0.08$). The model was robust, not influenced by missing values or the presence of fibroids, and it was better than that of a simple “two-sign rule” (sensitivity 71%, specificity 74%). JZ measurements obtained from the coronal plane had no association with the diagnosis of adenomyosis, nor did a cut off of $JZ_{max} \geq 8$ mm ($P=0.81$).

In MRI, JZ_{max} was not positively correlated with adenomyosis diagnosis (AUC=0.57, $P=0.26$) and did not differ significantly between those with and without adenomyosis (10.3 vs. 10.1 mm, $P=0.88$), nor was a cutoff of $JZ_{max} \geq 12$ mm [$n=30/57$ (53%) vs. $n=16/36$ (44%), $P=.29$]. The presence of an irregular JZ showed the best association with adenomyosis among the evaluated signs [sensitivity 74% (95% CI: 60–85); specificity 83% (95% CI: 67–94%) ($P<0.001$)]. Combining the primary diagnostic markers $JZ_{max} \geq 12$ mm, myometrial cysts and adenomyoma, the test quality when accounting for the undetermined cases as being respectively positive or negative could be quantified as follows (95% CI): sensitivity 77% (64–87%) and 72% (59–83%), specificity 53% (36–70%) and 67% (49–81%), accuracy 68% (57–77%) and 70% (60–79%) (all $P<0.001$). A cut off of $JZ_{max} \geq 12$ mm contributed to a high number of false positive and false negative cases.

We obtained biopsy specimens in 80 (99%) of the 81 cases. There was no visible trace of the biopsy retrieval in 20 women (25%), perforation of uterine serosa or peritoneum was present in 56 (70%), and ongoing minor bleeding occurred in 4 (5%). The median amount of bleeding was 2 ml (range 0–200 ml). No serious complications were observed. The procedure took 6.1 ± 1.9 min (mean \pm SD). Adenomyosis tissue was obtained in 10 (22%) of the 45 cases with adenomyosis. The inner myometrium with the JZ was accessible in all cases. It was possible to produce frozen sections, extract RNA and dissect single adenomyosis glands with LCM.

Discussion

JZ measurements showed to be of limited diagnostic value, both in TVUS and MRI. This is in contrast to prior studies. In 3D TVUS, our mean JZ measurements were significantly lower than in a study of Exacoustos et al., which might be

due to different patient populations or different ways of measuring. The diagnostic value of the individual markers in TVUS was in line with prior studies. However, we found that a multivariate model that weights each of the different predictors according to their diagnostic accuracy performs better than a simple “two-sign-rule”. For MRI, we could not identify any prior study that had prospectively validated a JZ_{max} cut-off of 12mm and used the gold standard for confirmation of adenomyosis. Reinhold et al. were the first to describe this value, but it was determined post-hoc and might be overfitted to their population. Their study comprised a large proportion of postmenopausal women (mean age 51 years) and 22% had endometrial carcinoma, which might have influenced the JZ appearance. Bazot et al. described “ $JZ_{max}>12mm$ and/or irregular JZ” as a combined marker, while Dueholm et al. used a cut-off of 15mm in their study. Our study is the first to validate a cut-off of 12mm prospectively. In our much younger and premenopausal population, we could not find a significant association of JZ_{max} and adenomyosis. In contrary, this marker contributed to many false positive and negative diagnoses. We found that the regular or irregular appearance of the JZ was highly associated with having adenomyosis or not, and that is actually in line with the observation of several authors (Reinhold 1996, Bazot 2001, Dueholm 2001, Brosens 1995, Stamatopoulos 2012). Overall, combined 2D and 3D TVUS performed better than MRI in our study. While our diagnostic studies have clear strengths (consecutive, prospective sample; blinded investigators; confirmation of diagnosis by gold standard), the main limitation is the need for hysterectomy, that introduces a bias in the patient selection. Also, the diagnostic prediction model needs prospective validation before it should be taken in clinical use.

For our transvaginal in-vivo biopsies, we showed that they could be taken with low risk for serious complications. This is the first study that reports the safety of transvaginal myometrial biopsies. The sensitivity of the present method for obtaining adenomyosis tissue was low but could be improved by a strict patient selection or different imaging modalities, such as fusion-imaging (MRI combined with TVUS). LCM made it possible to isolate adenomyosis cells from the surrounding myometrial tissue, which provides the possibility of highly specific analyses of only the diseased cells. Furthermore, we found that RNA could be isolated from the biopsy specimens, which demonstrates the possible exploitation potential of such biopsies in basic research.

Conclusion

- We have developed a multivariate model for diagnosing adenomyosis that weights predictors based on their diagnostic significance. It could aid clinicians who are interpreting the heterogeneous appearance of adenomyosis in ultrasonography.
- The model shows a good test quality (AUC=0.86) and a high sensitivity (85%) and good specificity (78%) but still requires validation.
- In MRI, JZ measurements are not validated for a young patient population with moderate disease and should, therefore, be used with caution.
- In MRI, the irregular appearance of the JZ and the presence of myometrial cysts are independent predictors of adenomyosis.
- Ultrasound-guided, transvaginal uterine biopsies of adenomyosis can be obtained with low risk for complications. They should not be used for diagnostic purposes.
- This technique opens up the possibility of investigating early stages of adenomyosis and the inner myometrium, containing the JZ, independent of hysterectomy specimens.

Impact to Patient's Health

Our ultrasound-based diagnostic prediction model can be used as an easy, widely available, and cheap screening tool for adenomyosis, also by less experienced examiners. The presence of adenomyosis is highly relevant for therapeutic decision making in women suffering from dysmenorrhea or infertility. This tool might improve the treatment of those patients. Our proposed parameters might improve diagnostic accuracy when using MRI to diagnose younger women with adenomyosis. In vivo biopsies of adenomyosis can contribute to understanding the pathophysiological pathways of adenomyosis in earlier stages, which can lead to new targets for treatment.

Neoadjuvant chemotherapy versus primary debulking surgery in FIGO stage III and IV epithelial ovarian cancer

Pantelis Trompoukis², Alexander Tzanis¹, Stavros Antoniou³

¹European University of Cyprus, School of Medicine, Volos, Greece

²European University of Cyprus, School of Medicine, Marousi Athens, Greece

³European University of Cyprus, School of Medicine, Thessaloniki, Greece

Aim

To assess whether neoadjuvant chemotherapy (NACT) followed by interval debulking surgery (IDS) could be a non-inferior therapeutic alternative to primary debulking surgery (PDS) in terms of overall survival, progression-free survival and perioperative complications in women with FIGO stage III and IV epithelial ovarian cancer (EOC).

Background

Ovarian cancer is the 2nd most common gynaecologic cancer, yet the leading cause of death of all gynaecologic neoplasms and the 7th most common malignancy affecting women worldwide. The majority of ovarian neoplasms arise from the surface epithelial cells of the ovary, resulting in epithelial ovarian cancer. Due to the lack of effective screening, nearly 60% of all cases are diagnosed at metastatic, FIGO stage IIIc and IV. As a result, the 5-year survival rate for women with metastatic EOC is approximately 29%. The standard of treatment for those women has been PDS followed by platinum-based adjuvant chemotherapy. However, NACT followed by IDS is widely used as an alternative and seems to offer certain clinical advantages.

Materials / Patients

We searched for eligible randomized control trials (RCTs) in the electronic databases PubMed, Cochrane central register of controlled trials and Scopus published from inception to April 2019.

Methods / Results

A total of 4 trials involving 1,803 women with FIGO stage III and IV were included in our systematic review. Compared with PDS, NACT demonstrated similar survival rates and higher rates of optimal cytoreduction (74.5% achieved optimal cytoreduction in the NACT group compared to 43.3% in the PDS group). NACT was also associated with lower perioperative morbidity in terms of infection, venous thromboembolism, any grade 3 or 4 adverse event and less postoperative mortality within 30 days.

Discussion

Although our results showed decreased perioperative complications of grade 3 and 4, decreased postoperative mortality and increased cytoreduction rates in the NACT group, this was not translated into a survival benefit. This could be attributed to the selection of patients in the included trials, as 3 of them had recruited patients with bulky primary and even metastatic disease. A second important factor that possibly contributed to non-superiority of NACT in terms of survival is the increased rates of chemoresistance compared to PDS. Finally, patients undergone IDS after NACT could have a higher incidence of non-surgically detectable minimal residual lesions, eventually hidden by scar tissues, especially in upper abdomen and diaphragmatic surfaces.

Conclusion

NACT followed by IDS is associated with superior optimal cytoreduction rates, lower perioperative morbidity and postoperative mortality and non-inferior survival compared to PDS. Further research should focus on the optimal selection of patients with advanced-stage EOC that could benefit from this alternative therapeutic approach.

Impact to Patient's Health

NACT shows promising results as an alternative therapeutic approach for patients with advanced-stage EOC. The low perioperative morbidity and mortality rates suggest that it can be applicable to patients with a high tumour load, unresectable disease or poor performance status. The increased cytoreduction rates of NACT could also establish ground for further research regarding new protocols that could translate these important findings into increased survival and better quality of life for patients with advanced EOC.

A 20-year-retrospective study of diagnostic hysteroscopy in the outpatient office of The University Hospital of Ioannina: the largest study in Greece to date

Orestis Tsonis¹, Fani Gkrozou², Ektoras Gazos³, Minas Paschopoulos¹

¹*University Hospital of Ioannina, Obstetrics and Gynaecology, Ioannina, Greece*

²*University Hospitals of Birmingham, Obstetrics and Gynaecology, Birmingham, United Kingdom*

³*General Hospital of Karditsa, Obstetrics and Gynaecology, Karditsa, Greece*

Aim

The aim of the study is to demonstrate the role of hysteroscopy as it is described by the results of a 20-year-old study, of outpatient hysteroscopy

Background

Hysteroscopy is the leading diagnostic tool in cases of abnormal uterine bleeding, submucous myomas and endometrial polyps, as well as, in detecting subfertility associated underlined endometrial pathologies, to name a few. Inpatient hysteroscopy is considered to be the gold standard when it comes to assess the endometrial pathologies with a high sensitivity of 98%, when in conventional procedures such as dilatation and curettage (D&C) the percentage is about 65%. Nowadays the conventional method with the use of general anaesthesia is abandoned since the technological developments led to the construction of fine hysteroscopes with high resolution and a feature of utilising the light properties for a better and more accurate view of the endometrial cavity.¹ The distension medium, which is used, is normal saline, since, compared to CO₂, gives better results during this procedure. Furthermore, the vaginoscopic approach, which is used broadly, results to a more comfortable experience by the patients undergoing this procedure in an outpatient set up. These features increase the feasibility and acceptability of outpatient diagnostic and therapeutic hysteroscopy. Nevertheless, hysteroscopy continues to be depended by the cooperation of the hysteroscopist and the patient.

Moreover, the past concept of 'diagnostic hysteroscopy' has changed to 'office hysteroscopy', in which we 'see and treat' any pathological findings. The use of hysteroscopy seems to be more efficient than sonographic findings regarding the detection of endometrial pathology. Recent advances in reducing the calibre of hysteroscopes and the onset of bipolar energy has allowed treating most of the intracavitary lesions in the office, without using the operating room.

Materials / Patients

For this study, data from 2674 patients, from 18 till 80 years of age, who underwent outpatient diagnostic hysteroscopy in the outpatient office of endoscopic department of the University of Ioannina, Epirus. All women came from the region of Epirus and the operation was performed by the same hysteroscopist. During this procedure no analgesia was given and all the data was stored, filed and then processed by the endoscopic team.

The procedure was explained in detail to any patient and they signed an informed consent before the procedure. No drugs were administered prior the procedure and all patients were advised to be accompanied after the procedure. The equipment used was the Bettocchi's set (Karl Storz Endoscopia Iberica SA, Madrid, Spain), a continuous flow rigid hysteroscope. This hysteroscope is a Hopkins 2.8 mm optical type with fore-oblique vision of 30°. It has an oval sheath with a diameter of 5.3 mm and an operative channel 5 Fr. The distension medium was saline. The approach technique was 'no touch' Bettocchi's technique or vaginoscopic. After vaginoscopy, the endometrial cavity was approached through the cervical canal while it was examined, in some cases trying to make a definitive diagnosis at the same time.

Methods / Results

Hysteroscopy was able to detect common endometrial pathologies in the majority of cases. The procedure was well tolerated by the patient. Most common endometrial pathology found to be endometrial polyps. Fibroids and congenital malformations were also observed as primary results. Zero complications were noted. The most common indications was AUB ABnormal uterine bleeding and infertility.

Discussion

Nowadays hysteroscopy is taking the lead when it comes as a tool for inspecting the uterine cavity. It seems that outpatient hysteroscopy was evolved as easy to perform as transvaginal ultrasound is. Our experience showed common indications and diagnostic results in the patients as a total.

Conclusion

Outpatient hysteroscopy should be a first line diagnostic tool when it comes to gynaecologic patients.

Impact to patient's health

This study demonstrates the value of hysteroscopy in detecting endometrial pathologies in an outpatient facility.

ES28-0534 - PHD Session

Impact of endometrioma surgery on fertility

Amal Mouzali¹, Mohamed Ziad Cheikh Al Ghanama¹, Fadila Madaci¹

¹Medecine, Gynaecology CHU BEO, Algiers, Algeria

Aim

Our principal aim is to evaluate the impact of endometrioma cystectomy, on the ovarian reserve three and twelve months after surgery in infertile women by measuring: AFC, FSH and AMH

The second aims are:

- to calculate the pregnancy rate after surgery;
- to evaluate the pain by EVA before surgery and three and twelve months after;
- to calculate the follicles' numbers retrieved on endometrioma cyst.

Background

Endometriosis is a common disease which can cause infertility, particularly in the case of endometrioma where two controversial options are proposed: surgery or AMP (medical assistance of procreation) beside the absence of well-established recommendations.

Materials / Patients

In this study, 40 infertile patients with ovarian endometriomas greater than 4 cm aged between 21 and 40 years with normal spermogram and tubal patency, underwent laparoscopic surgery for cystectomy and treatment of endometriotic deep lesions. Women with other causes of other pathologies such as myomas, and uterine septa were excluded. Surgeries were performed at laparoscopy and one gynaecologist performed all operations with patient consent.

Inclusion criteria were:

Age under 35 years old and AMH ≥ 1 ng/ml

Age 35 or over years even if AMH < 1 ng/ml who refused AMP alternative

Endometrioma ≥ 4 cm

Normal spermogram and

Tubal patency at least unilateral

Exclusion criterion was previous cystectomy for:

Endometrioma

Methods / Results

This is a prospective and descriptive longitudinal study in a single centre at BAB El Oued state Hospital in Alegria between February 2014 and December 2018 that concern infertile women.

The average age was: 31 ± 0.7 years

The endometrioma was isolated in 30% of cases, while 70% of endometriomas were associated with other pathologies of which 50% are deep endometriosis.

On cycle day 3 the following hormone levels were measured: serum levels of anti-Müllerian hormone (AMH), follicle-stimulating hormone (FSH), the number of antral follicles (AFC) was counted as well. The scanning was performed through 2D technology transvaginal ultrasound.

After cystectomy by laparoscopy, there was a significant increase of AFC 12 months after surgery (7.75 ± 0.58 follicles before surgery versus 8.48 ± 0.55 follicles after surgery, IC 95% [-3.16, -1.13], $p < 10^{-3}$).

The average of FSH doesn't increase whereas; the AMH decreases significantly in the postoperative period after three and twelve months (2.29 ± 0.26 ng/ml before versus 1.47 ± 0.23 ng/ml after three months ; 95% IC [0.50, 1.14], $p < 10^{-3}$ and 1.46 ± 0.20 ng/ml twelve months after surgery ; 95% [0.51, 1.14] , $p < 10^{-3}$).

But after stratification into three groups:

A first group where AMH is decreased after surgery in 50% of patients (2.55 ± 0.4 ng/ml preoperatively and 1.15 ± 0.21 ng/ml at 12 months postoperatively with $P < 10^{-3}$)

A second group where AMH is increased in 35% of patients at 12 months after surgery (2.69 ± 0.37 ng/ml preoperatively and increased at 12 months postoperatively 2.37 ± 0.37 ng/ml, $p = 0.13$)

A third group in 15% of patients where AMH is already decreased before surgery (0.50 ± 0.1 ng/ml preoperatively and 0.36 ± 0.2 ng/ml at 12 months postoperatively with $P = 0.31$)

Significant linkage is found between the decrease of AMH after surgery and the associated endometrioma with other surgical gestures. $P < 0.02$ caused by a probably ovarian devascularisation.

The number of follicles removed from cysts are correlated to the AMH preoperatively but its absence postoperatively means that more the AMH is higher more are the follicles retrieved especially the primordial ones, in the other hand, the decrease of AMH postoperatively isn't correlated with follicles retrieved.

The surgery is efficient since 47.5% of our patients have obtained spontaneous pregnancy after 32 months of follow up and 35% after one year despite low levels of AMH and there is one factor that may be incriminated in the non-occurrence of spontaneous pregnancy which is adenomyosis.

The decrease of pains (dysmenorrhoeas, dyspareunias) is significative after three and twelve months after surgery.

Discussion

Our study shows that the surgery of endometrioma is efficient since AFC increases in postoperatively, FSH doesn't increase nevertheless the AMH decreases in general. However, after stratification into three groups, we find a significant relation at the Khi 2 test between the decrease of AMH after surgery and the group where patients underwent endometrioma cystectomy and surgical treatment of other lesions notably deep endometriosis which represented 50% of cases like nodule ablation, shaving, uterolysis...

The AMH level after surgery isn't correlated with the number of follicles retrieved on cysts.

Based on our findings, the endometrioma cystectomy, which has been accused to be deleterious for many years, doesn't really damage the ovarian reserve by itself nevertheless the treatment of lesions particularly the deep endometriotic ones could devascularise ovaries. In some cases, there was an increase in AMH average after 12 months from surgery, probably after ovarian recovery and revascularization. In 50% there was a decrease in AMH average in cases where cystectomy is associated with other treatment especially deep endometriosis and 12 months weren't sufficient for ovarian revascularisation and recovery.

We can also find a decrease of AMH before any surgery, that suggests the diminution of ovarian reserve is possible and can be created by the endometriosis environment. Absence of correlation between the average of AMH after surgery and bilateral localisation of endometrioma is almost certain because of non-bilateral cystectomy. In our protocol, in case of bilateral endometriomas, we decided to perform one unilateral total cystectomy and a partial one or just aspiration of the cyst in the opposite ovary. The rate of spontaneous pregnancy is 47.5% until 32 months follow up and 35% after one year whereas 52.6 % were pregnant in the first 06 months after surgery and 73.7 % after 12 months, obviously the surgery has a good effect. The majority of our patients have got pain associated with infertility also the surgery reduce pain in a significant way.

Conclusion

Endometrioma's surgery has been proved to be efficient without increase of FSH and an increase of AFC, nevertheless the decreased rate of AMH which can be increased in some cases in isolated endometrioma. The decrease in AMH level is not correlated with the number of follicles removed and despite this decrease, we get a pregnancy rate up to 47.5% and a reducing pain.

Impact to patient's health

Endometrioma cystectomy should be an alternative treatment of infertility on young patient instead of AMP if ever sperm is normal and tuba is patent, particularly if pain is associated. However, we should avert patients that AMH can be decreased in case endometrioma isn't isolated but without reducing the spontaneous pregnancy rate

ES28-0642 - PHD Session

The quality of life in patients with deep infiltrative endometriosis and colorectal laparoscopic resection

Catalin Bogdan Coroleuca¹, Munteanu Rubin², Coroleucă Ciprian Andrei³, Brîndușe Lăcrămioara⁴, Vlădăreanu Radu⁵, Brătilă Elvira⁶

¹Clinical Hospital of Obstetrics & Gynaecology "Prof. Dr. Panait Sarbu"- University of Medicine and Pharmacy "Carol Davila" Bucharest- Romania, Obstetrics & Gynaecology, Bucharest, Romania

²Monza Hospital, General Surgery, Bucharest, Romania

³Clinical Hospital of Obstetrics and Gynaecology "Prof. Dr. Panait Sârbu"- University of Medicine and Pharmacy "Carol Davila"- Bucharest- Romania, Obstetrics and Gynaecology, Bucharest, Romania

⁴Department of Health, University of Medicine and Pharmacy "Carol Davila"- Bucharest- Romania, Bucharest, Romania

⁵Elias University Emergency Hospital, Obstetrics and Gynaecology, Bucharest, Romania

⁶Clinical Hospital of Obstetrics and Gynaecology "Prof. Dr. Panait Sarbu", Obstetrics and Gynaecology, Bucharest, Romania

Aim

The aim of this paper is to present the authors experience and to evaluate the effectiveness of laparoscopic colorectal resection in cases with deep infiltrating endometriosis as well as the impact on quality of life, symptomatology and digestive symptoms.

Background

The decision to perform a laparoscopic colorectal resection in a patient with deep infiltrating endometriosis must be made with an extensive preoperative work-up and an informed patient consent due to the risk of complications involving this procedure.

Materials / Patients

During June 2017 until May 2019 a number of 131 patients underwent laparoscopy for deep infiltrative endometriosis. 42 patients with deep endometriosis were included in the study - all the patients included in the study completed a questionnaire on the symptoms of preoperative endometriosis and quality of life (Questionnaire SF-36), complete preoperative evaluation (MRI, transvaginal ultrasound, endo-rectal ultrasound, HydroColo-CT). Status and quality of life were assessed postoperative. Gynaecological and digestive symptoms as well as the rate of perioperative complications were also evaluated. Laparoscopic surgery was performed by the same surgical team in all cases.

Methods / Results

Twenty patients (47.62%) benefited from laparoscopic segmental recto-sigmoid resection with end-to-end mechanical anastomosis. 21 patients (50%) with deep endometriosis benefited from laparoscopic excision of deep endometriosis nodules. The average age of patients is 34 years. The laparotomy conversion rate was null. Following surgery, a significant improvement in dysmenorrhea, dyspareunia, chronic pelvic pain, defecation pain, and lower abdominal pain was noted. In cases of deep endometriosis and colorectal resection, an improvement in the quality of life score assessed by the SF-36 questionnaire was observed. One patient (2.38%) refused colorectal resection for objective reasons. The rate of perioperative complications was 2.38% - a reintervention at 5 days postoperatively - ileostomial protection. The rate of hemoperitoneum, rectovaginal fistula, uroperitoneum and pelvic abscess was null.

Discussion

Laparoscopic colorectal resection should be performed only in patients with symptomatic endometriosis that affects the quality of life.

Conclusion

Laparoscopic segmental colorectal resection for endometriosis significantly improves the quality of life and gynaecological and digestive symptoms. Preoperative investigations allow for surgical planning and the formation of a multidisciplinary team for the correct management and complete excision of endometriotic lesions.

Impact to Patient's Health

However, women should be informed about the risk of complications, including rectovaginal fistula. The need for adherence to a national guide on therapeutic conduct in deep endometriosis cases and standardisation of treatment allows us to achieve satisfactory results in terms of improving the quality of life in patients with colorectal resection.

ES28-0281 - Free Communication 5 (PHD)

The SNP rs1810636 associated with uterine prolapse could improve the selection of the best surgical approach in these patients

Tina Bizjak¹, Mario Gorenjak², Uroš Potočnik², Igor But¹

¹University Medical Centre Maribor, Department of general Gynaecology and Gynaecologic Urology, Maribor, Slovenia

²Faculty of Medicine- University of Maribor, Centre for Human Molecular Genetics and Pharmacogenomics, Maribor, Slovenia

Aim

Causes of pelvic organ prolapse (POP) are most likely multifactorial and are similar for all types of POP, also uterine prolapse (UP). Evidence for a hereditary association to POP was found in previous studies, but the disadvantage of these investigations is that the analysis included women with all forms of POP, including cystocele and rectocele, as well as uterine prolapse. So far no research on genetic risk factors for UP have been published. Level I support, hence the cardinal and sacrouterine ligament, is accountable for support of the uterus. We believe that genetic polymorphisms causing microscopic changes of uterine ligaments are responsible for uterine prolapse since these ligaments have different structure and function than connective tissue of the vagina. We conducted a candidate gene association study to verify findings on 6 polymorphisms that were previously associated with POP in GWAS (Allen-Brady et al., *obstet gynecol*, 2011), considering adjustments for contributing risk factors such as age, smoking status, number of births given and body mass index. In addition, our study also investigated the expression of the nearby genes of the significant SNP measured on sacrouterine ligaments gained mainly during laparoscopic hysterectomy and some during vaginal hysterectomy in UP patients and during laparoscopic or open hysterectomies for other benign diseases in controls.

Background

Uterine prolapse (UP) is defined when the uterus descends towards or through the opening of the vagina due to weakness in supportive structures. It is usually the result of poor cardinal and/or uterosacral ligament. UP rarely results in severe morbidity and mortality, but it often causes significant deterioration of woman's standard of living; in rare occasions it can lead to severe complications such as intestinal obstruction or acute renal failure due to ureteral obstruction (Jelovsek JE et al, *Am J Obstet Gynecol*, 2006).

In the Women's Health Initiative (WHI) study UP was observed in 14 % of women between 50 and 79 years of age (Hendrix SL et al, *Am J Obstet Gynecol*, 2002). POP is one of the most frequent reasons for gynaecological surgery. 12-20% of woman with POP have surgery during their course of life and one third will get multiple surgeries (Nguyen L et al., *Int Urol Nephrol*, 2018). Treatment depends on the severity of UP, age, comorbidities and patient's preferences. Vaginal pessaries and self-care measures such as kegel exercises are mostly used for limited periods of time or if patient's condition is not suitable for surgery. Surgery is the only permanent solution and includes repair of weakened pelvic floor tissues or removal of the uterus. Nowadays laparoscopic approach is gaining in popularity since it is minimally invasive, with lower complication rate compared to open surgery and fast recovery rate. Additionally, women have the possibility to preserve the uterus.

Causes of POP are most likely multifactorial. Various risk factors are associated with POP with vaginal delivery being the most associated risk factor. Recently, there is growing evidence that heredity also plays a role in the occurrence of these disorders. It was observed that some women with no risk factors develop POP already early in their life, where there are women who never develop POP in spite of several risk factors. Studies show a five-fold increased risk of prolapse among siblings of women with severe prolapse as compared to the general population (Jack GS et al., *Int Urogynaecol J Pelvic Floor Dysfunct*, 2006). High concordance of prolapse was also confirmed in twin sister (Altman et al., *Am J Hum Gen*, 2009).

Abnormalities in the connective tissue of pelvic floor has been the main investigated mechanism for development of POP. Candidate gene studies have been mainly focused on collagen and elastin synthesis and remodelling (Kasyan GR et al., *Urologiia*, 2017; Kluivers KB et al, *Int Urogynecol J Pelvic Floor Dysfunct*, 2009), endothelial cell receptors (Ferrell G et al, *Reprod Sci*, 2009), and hormone receptors (Chen HY et al, *Int Urogynecol J Pelvic Floor Dysfunct*, 2008; Chen HY et a, *Acta Obstet Gynecol Scand*, 2009; Chen HY, *Eur J Obstet Gynecol Reprod Biol*, 2008). Two genome wide association studies (GWAS) determined six loci suggestive for genome-wide significance in a cohort of women of European descent (Allen-Brady et al., *Obstet Gynecol*, 2011), and further several loci showed suggestive signals in a GWAS of African American and Hispanic postmenopausal women dataset of the Woman's Health Initiative SNP Health Associated Resources (SHARe) (Giri A et al, *PLoS One*, 2015). Genome-wide linkage studies showed suggestive evidence on chromosome 9q21 (Allen-Brady K et al., *Am J Hum Genet*, 2009), 10q24-26 and 17q25 in caucasian women (Allen-Brady K et al, *Am J Obstet Gynecol*, 2015) and in a region near LAMC1 gene in a single Filipino family with a high penetrance of POP (Nikolova A et al, *Hum Genet*, 2007).

Materials / Patients

The recruitment of 107 patients who underwent surgical repair due to stage III-IV UP and 112 controls from the pool of patients with intact support of the cervix and upper vagina between 30 and 55 years of age was performed. Samples of peripheral blood for the DNA genotyping were obtained from all the subjects. In addition to blood samples, 0.5 cm² of the sacrouterine ligament for gene expression was retrieved about 2 cm posterior to the uterus intraoperatively from 16 UP patients during planned surgery due to UP (laparoscopic hysteropexy or vaginal surgery) and from 9 controls during planned hysterectomy due to other benign diseases (laparoscopic or abdominal hysterectomy). Information was obtained from all study participants about risk factors and a Pelvic Organ Prolapse Quantification (POP-Q) status was performed.

Methods / Results

Genotyping:

DNA for genotyping was extracted from peripheral blood mononuclear cells using TRI-reagent. Single nucleotide polymorphisms were selected based on literature and missing SNPs were substituted with LD proxy SNPs. Targeted SNP genotypes were extracted from available Infinium Global Screening Array (GSA_24v1) genotype data after quality control.

Gene expression:

Tissue samples of the sacrouterine ligaments were first homogenised using bullet blender homogeniser and total RNA was immediately extracted using TRI reagent®. mRNA sequences of target and reference genes were retrieved from NCBI nucleotide database (www.ncbi.nlm.nih.gov/nucleotide/). Primers were designed using IDT OligoAnalyser 3.1 (eu.idtdna.com/calc/analyser). All primers were synthesised by Sigma. Gene expression assay was carried out using Lightcycler 480® SYBR Green I Master Mix and Lightcycler 480® real-time thermocycler. 2 µL of 10-fold diluted cDNA (5 ng/µL) was used for qPCR. Normalisation of raw data was performed using geometric averaging of reference genes (*ACTB* and *B2M*) and relative expression was calculated using 2^{-ΔΔCt} method.

Statistical Analysis:

Student T-test and Mann-Whitney U-test were used to compare continuous data between the patient and control groups. Fisher's exact test was used when assumptions for chi-square distribution were violated.

Data were analysed using PLINK 1.9 (<https://www.cog-genomics.org/plink2/>) software. Association analysis was performed for allelic, minor allele dominant and minor allele recessive models regarding case/control and quantitative POP-Q measure. Additionally, regression analyses were performed in order to adjust the SNP association to risk factors. Principal components were additionally used as covariates in regression models to correct for possible ethnic groups of the patients.

Results

Altogether, 100 patients with total UP and 105 matched controls were included in the study. Mean BMI (26.3 ± 5.7 vs 27.2 ± 5.5, *p* = 0.3) and percent of smokers (37% vs 32.6%, *p* = 0.8) were similar compared between the two groups. Mean age ± SD (47,2 ± 6,1 vs. 45 ± 5.8) had a significant difference (*p* = 0.01), nevertheless, we think the development of UP in controls is improbable due to excellent POP-Q status. There was a significant difference in vaginal parities due to a different range (median 2 (6) vs. 2 (4), *p* = 0.01). Family history was positive in only 1 % of controls and 25 % of cases (*p* = <0.00001). Six SNPs were considered in our study as described in table 1. All six loci have been previously identified in a genome-wide association study for advanced POP in European pedigrees (Allen-Brady et al., *Obstet Gynecol*, 2011).

SNP	LD SNP	Chromosome region	Gene	Function
rs1455311	rs6852257	4q21	LINC01088	intron
rs1036819	N/A	8q24	ZFAT, ZFAT-A1	intron
rs430794	rs4436246	9q22	LOC100507103	intron
rs8027714	rs77662161	15q11	N/A	N/A
rs1810636	rs6051098	20p13	LOC105372507	intron
rs2236479	rs7279445	21q22	COL18A1	intron

Table 1. Investigated SNPs

All 6 SNPs were in Hardy-Weinberg equilibrium in the cases and in the controls. Only one SNP was associated with total UP.

In our analysis, the dominant model for rs1810636 was found to be higher in the cases than in controls ($p = 0.049$). This effect remained significantly associated with UP after applied adjustments for age, BMI, smoking and vaginal parity ($p = 0.046$).

Additional to genotyping, we performed gene expression of the *LOC105372507* gene and three genes which are located in its near proximity (*EPF4*, *NOP56*, and *IDH3B*). Relative to the controls we observed 3-fold (0.3; 0.2-0.4) and 2-fold (0.5; 0.4-0.8) down-regulation of *LOC105372507* and *EPF4*, respectively. *NOP56* was 1.4-fold (1.4; 1.2-1.6) up-regulated relative to the controls. The expression of the gene *IDH3B* was unspecific.

Discussion

In our study, we investigated if candidate genes from a previous study on POP are associated with total UP. Of six SNPs, only one was associated with UP. The statistical association of the SNP rs1810636 was accentuated with applied adjustments for risk factors.

We then investigated rs1810636, which is located in the non-coding RNA gene *LOC105372507*. In its near proximity, there are three protein-coding genes, two of which got differently regulated in cases compared to controls. The first *NOP56* gene is entangled in pre-RNA processing and one variant was found to be connected to anal incontinence, a form of pelvic floor dysfunction. The *EBF4* gene belongs to a family of transcription factors and plays an important role in B-cell maturation. *IDH3B* gene codes for the beta subunit of the isocitrate dehydrogenase; studies suggest that wild-type *IDH* species play significant roles in managing the extent of oxidative stress in response to various cellular insults.

All three protein-coding genes may facilitate the pathological process of UP.

Conclusion

The findings of the present study verified rs1810636 as a possible genetic cause for UP. The genes in the near proximity of rs1810636 show different expression in cases vs. controls and could be linked to UP.

Impact to patient's health

knowledge of the genetic predisposition for UP could facilitate counselling regarding pregnancy and mode of delivery. It would be possible to give better instruction on preventive measures to reduce the risk of POP.

Treatment of uterine prolapse is strictly surgical (open, vaginal or laparoscopic). Women are increasingly choosing to preserve their uterus with minimally invasive procedures, such as laparoscopic hysteropexy. Laparoscopic hysteropexy is the treatment of choice for patients wishing to retain fertility. The procedure is used to suspend the uterus using mesh and involves attaching the uterus either to the sacrum or the iliopectineal ligaments.

It is currently unclear whether the genetic predisposition may be the reason for the recurrence of POP after surgery. If we would have the hereditary predisposition confirmed preoperatively the best surgical approach for an individual patient could be discussed. This could reduce the incidence of recurrence after surgery and thereby increase the satisfaction of patients.

BEST SELECTED VIDEOS (23)

ES28-0177 -

Best Selected Videos 1

En-block resection of the “butterfly area” for deep infiltrative endometriosis

Konstantinos Kyriakopoulos¹, Shaheen Khazali¹, Vasileios Minas¹, Matthew Errity¹

¹NHS, Centre for Endometriosis and Minimal Invasive Gynaecology, Chertsey, United Kingdom

Background

In this video, we demonstrate our structured approach for excision of the “butterfly area” when endometriosis involves both pelvic sidewalls, uterosacral ligaments and torus uterinus.

Methods

This is an edited video of a procedure performed at our unit in Chertsey, UK, CEMIG (Centre for Endometriosis and Minimal Invasive Gynaecology).

Results

We follow a structured approach which we call by the mnemonic “**SO SURE Resection**”. Depending on the case there may be an adjustment on the above order but in general the acronym itself is a well structured approach that facilitates the procedure.

The stages of the excision are as following:

1. **S**urvey of lower and upper abdomen and **S**igmoid mobilisation
2. **O**varian mobilisation (combination of sharp/blunt dissection)
3. a. **S**uspension of uterus using sutures
b. **S**uspension of ovaries
4. **U**reterolysis
5. **R**ectovaginal septum entry (disease is left on the uterus and normal tissue is entered in the rectovaginal space)
6. **E**nter into pararectal space
7. **R**esection of the “Butterfly area”(care is taken to lateralize the hypogastric nerve)

At the end of the procedure we perform the Michellin test to ensure the integrity of rectal wall.

Conclusions

Following a structured approach ensures a safer and quicker procedure. En-bloc excision not only provides a cleaner, more satisfying surgical field, it also ensures that the microscopic skip lesions between the endometriotic lesions are included in the specimen, providing a clean surgical field where all anatomical structures, (including the hypogastric nerves) can be easily seen and preserved.

<https://player.vimeo.com/video/335251827?autoplay=1>

**ES28-0211 -
Best Selected Videos 1**

Inadvertent ureteral injury management during DIE resection with the laparoscopic Boari Flap method

Masaaki Andou¹, Shiori Yanai¹, Kiyosh Kanno¹, Midori Okumura²

¹Kurashiki Medical Center, Gynecology, Kurashiki-shi, Japan

²Shirakawa Clinic, Gynecology, Fukuyama-shi, Japan

Background

To show minimally invasive strategies for management of inadvertent intraoperative ureteral injury during difficult to dissect DIE with the Boari flap technique.

Methods

The case presented suffered an inadvertent ureteral injury during the dissection of severe and extensive fibrosis. The surgeon misrecognized the ureter for the deformed sacrouterine ligament and this structure was coagulated and resected. At this time in the surgery the author of this report was called to manage the intraoperative minimally invasive repair and reconstruction. We opted to compensate for the length of the ureter with the laparoscopic Boari flap with psoas hitch technique. In this technique the ureter is mobilised cranially and the bladder is also dissected and mobilised. Then a flap is cut from the wall of the bladder and this flap is suture fixed to the psoas fascia and enveloped to make a tunnel for the cut end of the ureter. This adds length to the ureter and allows for a tension free adaptation.

Results

The patient was able to ambulate and take a normal diet the next day. No stenosis or leaks occurred and no blood transfusions were required. The patient featured in this video presentation gave her consent for her operative footage and patient data to be used for research and educational purposes.

Conclusions

This technique allows for the repair and reconstruction of an inadvertent injury to follow the minimally invasive intent of the original surgery. This strategy is an important skill for when repair scenarios are required.

<https://player.vimeo.com/video/335891595?autoplay=1>

**ES28-0179 -
Best Selected Videos 1**

Posterior compartment deep endometriosis resulting in hydroureter, silent kidney failure and need for nephrectomy and bowel resection: case report

Denis Tsepov¹, Nadine DiDonato¹, Lemke Solomon², Janet Berry³

¹Consultant Gynaecologist, Portsmouth Endometriosis Centre, Woking, United Kingdom

²Consultant Urologist, Portsmouth Endometriosis Centre, Woking, United Kingdom

³Gynaecology trainee, Portsmouth Endometriosis Centre, Portsmouth, United Kingdom

Background

Ureteral involvement is rare, with an estimated frequency of 10–14% in cases of deep infiltrating endometriosis. An important complication of ureteral involvement is asymptomatic loss of renal function. We reported a 34-year-old woman affected by severe endometriosis infiltrating the rectal wall and left ureter. MRI and CT urography showed left ureteral obstruction with chronic renal atrophy in presence of deep infiltrating endometriosis on sigmoid-colon and left parametrium. The renogram (99mTc-MAG3) showed a residual renal function of 12% in the left kidney and 88% in the right kidney. The patient was evaluated and discussed by a multidisciplinary team including urology. In view of persistent flank pain and recurrent urinary infection, left nephroureterectomy was planned with excision of severe endometriosis and high risk of bowel resection.

Methods

During laparoscopy, we found a frozen pelvis with significant adherence syndrome. The left ureter was entrapped by an endometriotic nodule that also affected the left uterosacral ligament and the sigmoid colon. The retroperitoneal space was opened above the ureter and ureterolysis was performed by blunt dissection until the severe ureteric obstruction. Both para-rectal spaces and hypogastric nerves were identified. A radical excision of deep infiltrating endometriosis on left parametrium and on the sigmoid colon requiring a segmental bowel resection was performed. At the end, left nephroureterectomy was also planned in conjunction with the urology team. The nephrectomy has been done via flank incision and we proceeded with blunt dissection until the renal vessels were identified and dissected.

Results

Unilateral laparoscopic nephrectomy, ureterectomy and bowel resection for severe endometriosis were necessary measures to treat severe endometriosis in this case as there was evidence of severe ureteric stenosis with reduction of kidney function to 12% on the affected side and MRI evidence of recto-sigmoid colon muscularis infiltration with marked pain and bowel symptoms.

Conclusions

Conclusions: Surgery for severe endometriosis requires advanced laparoscopic skills and a multidisciplinary support able to provide the best care for the patients

<https://player.vimeo.com/video/335963930?autoplay=1>

ES28-0185 - Best Selected Videos 1

Laparoscopic management of surgical emergency in adolescence: huge adnexal torsion

Shrikant Ohri¹, Namrata Ray²

¹Newlife Hospital, Varanasi, India

Background

Today Laparoscopy is the gold standard approach for management of benign ovarian cysts, adnexal masses or torsion.

A major deciding factor for a surgeon to perform laparotomy is the size of the ovarian mass and emergency condition as in case of huge torsion

The definition of huge ovarian cysts is not well described. Some authors define large ovarian cysts as those that are more than 10 cm in diameter as measured by preoperative scans and according to others those that are reaching up to umbilicus. Still, most patients with huge adnexal mass are managed by laparotomy.

This video evaluates the safety, effectiveness and feasibility of operative laparoscopy in the management of huge adnexal mass reaching upto the umbilicus.

Methods

Our video presents a case of acute torsion of huge adnexal mass in a 16 year old girl managed by laparoscopy. Patient complained of abdominal distention and pain, physical examination and imaging studies were in favour of a benign nature of the cysts, the examination revealed huge ovarian masse up to the umbilicus.

USG and MRI showed evidence of well defined cystic lesion form right ovary of size 10.0x8.5x6.8cm, no obvious thick septa/solid elements.

Evidence of elongated, lobulated lesion in the cul de sac extending at right upper region abutting right ovary, with heterogenous iso to hypointense signal at T1. Tumour markers were not done due to acuteness of case. Informed consent was obtained for possible conversion to laparotomy in case of technical difficulties or if there is an incidental finding of malignancy.

Results

Patient kept in lithotomy position with no vaginal manipulator. Surgery was performed under GA. Direct entry 2cm above umbilicus for optical port was done. Omental adhesions were cleared from cyst, then inspected for signs of malignancy, it was a huge right ovarian cyst with necrotic right fallopian tube. Twisted pedicles of tube and ovarian ligament were identified. Pedicles were cut near the cornual end, away from the torsion, as de torsion was not possible. The other side was not visible so cyst was drained using a suction device. It was a thick cyst wall. After that we proceeded with laparoscopic oophrectomy by identifying the torsion at right infundibulopelvic ligament. Right adnexal mass was separated and removed in an endobag and sent for HPE. Haemostasis was confirmed. HPE later showed serous cystadenoma of ovary and fallopian tube as unremarkable.

Conclusions

The above surgery concludes that any size of the ovarian cyst in acute condition i.e. torsion of the cyst can be managed with laparoscopy efficiently. In this case right adnexa were not salvageable due to torsion at two places i.e. ovarian ligament along with fallopian tube and second at infundibulopelvic ligament thus completely obliterating the blood supply to the ovary and tube.

<https://player.vimeo.com/video/336023209?autoplay=1>

ES28-0251 -

Best Selected Videos 1

Laparoscopic Davydov or laparoscopic transposition of the peritoneal colpopoiesis described by Davydov for the treatment of congenital vaginal agenesis in 8 steps

Muriel Vermeil¹, Thomas Schwaab¹, Olivier Garbin¹

¹CMCO - Strasbourg University Hospital, Department of Gynecology, Strasbourg, France

Background

Utero-vaginal agenesis is a rare congenital defect. Vaginal agenesis treatment can be performed by different surgical and non-surgical techniques. Laparoscopic Davydov intervention is one of them. The aim of this video is to describe the different steps of Davydov surgical technique for creating a neovagina, emphasizing visualization of recto-vesical cleavage and peritoneal-vaginal anastomosis by laparoscopic and vaginal approach.

Methods

This surgical video underlines the case of an 18-year-old patient with MRKH (Mayer-Rokitanski-Kuster-Hauser) syndrome, who underwent Davydov procedure after dissatisfaction with Franck method of self-expansion. All the video sequences were done with a laparoscopic camera.

Results

Production of a step-by-step surgical video tutorial presenting Davydov technique by laparoscopic and vaginal approach with the creation of a neovagina using peritoneal flaps, obtained after recto-vesical cleavage by laparoscopic approach then fastened to the introitus by vaginal approach. An intravaginal dilator is left in place and a final view of the peritoneal cavity is performed by laparoscopy. The result at one year shows the transition from a narrow vaginal dimple of 2 cm length to a neovagina of 10 cm length, permeable, well epithelialised and correctly healed without stenosis associated.

Conclusions

Davydov technique requires a trained team but allows good outcomes without the invasive use of sigmoidal graft, cutaneous flap or prosthesis. Davydov technique must be proposed to every patient experiencing failure with Franck non-surgical method.

<https://player.vimeo.com/video/336212960?autoplay=1>

ES28-0338 - Best Selected Videos 1

A standardised and reproducible technique for nerve sparing resection of colorectal endometriosis: a single-centre experience

Jeffrey Ahmed¹, Kiran Devgun², John Bidmead¹

¹King's College Hospital, King's College Endometriosis Centre, London, United Kingdom

²King's College Hospital, Department of Obstetrics & Gynaecology, London, United Kingdom

Background

Deep infiltrating endometriosis invading the sigmoid colon or rectum can be resected laparoscopically using disc-excision techniques, trans-anal stapler assistance or by laparoscopic anterior resection of the rectum. All commonly used techniques mandate proper preparation of the rectovaginal septum, pararectal spaces and (in the case of anterior resection) the mesocolon. The inferior hypogastric plexus of nerves runs close to these spaces and little attention has historically been placed on preserving them in their entirety. Their function remains poorly understood but are agreed to be involved in sexual and bladder function.

Methods

In this video presentation of our standard technique we outline the surgical steps involved in exposing and protecting the inferior hypogastric nerves after the retroperitoneum is opened and the ureters exposed from the sacral promontory to the ureteric tunnels. Our technique is straightforward and efficient to perform requiring little additional operative time compared with standard ureterolysis. Exposure of the inferior plexus permits segmental resection of the rectum or excision of rectovaginal endometriosis without iatrogenic nerve injury.

Results

A HD video presentation

Conclusions

We consider that any skilled endometriosis surgeon should be capable of incorporating a nerve-sparing approach to their practice: this video presentation goes some way to explore our easily reproducible technique.

<https://player.vimeo.com/video/338979658?autoplay=1>

ES28-0370 - Best Selected Videos 1

Laparoscopic isthmocele repair during pregnancy

Laurentiu Pirtea¹, Dorin Grigoras¹, Secosan Cristina¹, Balint Oana¹, Balulescu Ligia¹

¹University of Medicine Timisoara, Obstetrics and Gynaecology, Timisoara, Romania

Background

Isthmocele is a defect of the caesarean scar characterised by myometrial discontinuity on the anterior isthmus of the uterus. This defect contains debris, mucus and blood which is responsible for symptoms like abnormal uterine bleeding, chronic pelvic pain. Isthmocele is a frequency complication of c-section.

Methods

We present the case of a 29 year old patient who previously had one delivery by c-section who presented in our clinic with a positive pregnancy test for pregnancy confirmation. We present step by step the description of laparoscopic surgical treatment.

We incise the peritoneum in order to dissect the paravesical space bilaterally. Incision was difficult and dissection at the level of the vesicovaginal space. The plane was difficult to identify due to scar tissue at this level. We used a vaginal retractor in order to correctly identify the vesico-vaginal plane. Using ultrasound guidance, we identified a zone of minimal resistance at the level of uterine isthmus. Incision was performed at this level using a monopolar cautery. The margins of the defect were resected. We performed a continuous suture in 2 layers. The first using slow absorbable suture and the baseball stitch technique. Here you can see the first layer of the suture, using a 2.0 vicryl and the second layer, again a baseball stitch using a continuous suture.

Results

Successful laparoscopic repair of isthmocele. Pregnancy viability was also evaluated at the end of procedure.

Conclusions

Isthmocele is a frequency complication of c-section. To our knowledge is the first case of laparoscopic repair of pregnant uterus.

<https://player.vimeo.com/video/336433547?autoplay=1>

ES28-0509 - Best Selected Videos 1

Intraoperative laparoscopic ultrasound guidance to diagnose and treat a rare case of unilateral cervical dysplasia in a patient with a bicorporal uterus

Ilaria Romito¹, Ursula Catena¹, Benito Marinucci¹, Ilaria De Blasis¹, Antonia Carla Testa¹, Giovanni Scambia¹
¹Fondazione Policlinico Universitario Agostino Gemelli- IRCCS. Catholic University of Sacred Heart, Division of Gynaecological Oncology. Department Woman and Child Health and Public Health, Rome, Italy

Background

Cervical aplasia/dysplasia is among the rarest congenital anomalies of the female genital tract. According to ESHRE/ESGE classification: "Class C3 cervix" (unilateral cervical aplasia) includes patients with double cervix, one of which is aplasic. "Class C4 cervix" (cervical aplasia) is defined as a uterus with a single cervix aplasia. Preoperative diagnosis is difficult and there is no gold standard for treatment. The main objective is to demonstrate the utility of the laparoscopic ultrasound guidance for intraoperative diagnosis of the malformation, for surgical treatment and to avoid intraoperative complications.

Methods

A 30-year-old nulligravida woman, with irregular menstrual cycles, was referred to our gynaecological department for chronic pelvic pain and dysmenorrhea. The transvaginal ultrasonographic evaluation and the hysteroscopy revealed a bicorporal uterus, with double cervical canal, hematotrachelos content in the right cervical canal, consisting of an imperforated right cervix (Class U3b,C3,V0 ESHRE/ESGE classification). The hysteroscopic correction of the anomaly was performed under laparoscopic ultrasound guidance. In order to resolve the hematotrachelos, the surgeon performed the drilling and coring technique, consisting in external uterine ostium puncturing by hysteroscopic approach. The right cervical canal was filled with haemorrhagic material, which was drained during the procedure. A right uterine hemicavity was entered from this right cervical canal and a single tubal ostium was visualized. A 10 Fr catheter was placed in the right hemicavity to keep the walls outstretched avoiding postoperative adhesions and possible right cervical canal reclosure.

Results

No intra or postoperative complications occurred. At day 21, in post-operative follow-up, the transvaginal sonographic evaluation revealed a bicorporal uterus with double normal endometrial cavity and two normal cervical canals.

Conclusions

The laparoscopic ultrasound guidance facilitates precise anomaly diagnosis. Additionally, complication risk can be reduced.

<https://player.vimeo.com/video/338852021?autoplay=1>

**ES28-0530 -
Best Selected Videos 1**

Lich-Gregoir extravesical procedure for ureter reimplantation in ureter endometriosis

*Ma Li*¹

¹*National University Hospital Singapore, Obstetrics and Gynaecology, Singapore, Singapore*

Background

To describe Lich-Gregoir extravesical procedure for ureter reimplantation using video demonstration in a rare case of endometriosis requiring bilateral ureteric re-implantation.

Methods

Lich et al and Gregoir developed the extravesical approach for ureter reanastomosis for treatment of vesicoureteral reflux. We report our experience with extravesical ureteral reimplantation for the treatment of ureteral endometriosis requiring reimplantation.

We report a case of bilateral ureteral endometriosis presented with dysmenorrhea and flank pain. Her creatinine level was elevated at 458umol/L (normal range 50-90umol /L). The Computed Tomography scan of the Kidney, Ureters, Bladder (CT-KUB) confirmed severe bilateral hydro-ureteronephrosis with marked cortical thinning. The dilatation extended distally to the level of the distal ureters within the pelvis where there was a large right adnexal hypodense mass measuring 9.7 x 10.7 x 10.3cm.

INTERVENTION:

Laparoscopic radical resection of endometriosis and bilateral ureter preimplantation were performed. Ureterolysis was done bilaterally from pelvic rim. Bilateral ureters were transected distal to the stricture area, and spatulated at 6 o'clock. Left ureter was passed under left colon mesentery. Bladder mobilisation was achieved by ligation and cutting of the ipsilateral obliterated umbilical artery. Finally the bladder was hitched to the right psoas tendon with Polydioxanone (PDS) figure of 8 suture.

Vesicoureteral reflux (VUR) is characterised by the retrograde flow of urine from the bladder to the kidneys.

In order to prevent vesicoureteral reflux, Lich-Gregoir extravesical procedure was performed. For better anastomosis, a 5cm laparotomy incision was made, and uretero-neocystostomy performed in two layers. The first layer only included bladder mucosa with continuous PDS 5/0 suture. DJ stent was inserted. And tension free water tight suture was done over DJ stand as per Lich-Gregoir method, avoiding any strangulation of the neohiatus. Second layer was closed with 3/0 vicryl with interrupted sutures.

Results

Patient was given progesterone suppression after operation was followed up postoperatively regularly. There was no sign of recurrence for endometriosis.

Conclusions

We have demonstrated in detail the Lich-Gregoir extravesical procedure for ureter reimplantation.

<https://player.vimeo.com/video/338911750?autoplay=1>

**ES28-0628 -
Best Selected Videos 1**

Unusual and multifocal locations of endometriosis: pubic bone

*Maciej Pliszkiwicz*¹, *B. Paweł Siekierski*¹, *Joanna Jacko*¹

¹*Medicover Hospital, Gynaecology, Warszawa, Poland*

Background

Endometriosis affects 10% to 15% of the female population of childbearing potential. Multifocal endometriosis is common, sometimes involving unexpected anatomical sites, that are difficult in both diagnostics and treatment.

Methods

This video presents the case of a 40-year-old multipara with no previous abdominal surgeries, who presented with increasing dysmenorrhoea, dysuria, dyspareunia, and debilitating pain in the area of the pubic bone. Sonography investigation revealed a bilateral hypoechogenic, subperitoneal and submuscular lesion, consistent with endometriosis, as well as a 2 cm bladder nodule. Moreover, the patient had severe adenomyosis, and evidence of involvement of sacrouterine ligaments. She also presented evidence of an umbilical endometriosis nodule.

Results

The patient was qualified for surgery, and TLH with fallopian tubes was planned, along with removal of all endometriotic lesions. Laparoscopy revealed a multifocal disease, confirmed the presence of bladder and sacrouterine ligaments involvement. At first glance, there were no other lesions that would suggest public bone involvement, but deep preparation revealed bilateral lesions of the public bone, with periosteum involvement. TLH with fallopian tubes was performed, all endometriotic lesions have been removed, including public bone lesions and umbilicus, and to date the patient remains asymptomatic. Pathology confirmed endometriosis in all specimen.

Conclusions

Endometriosis remains a mysterious disease, and occurs in most unexpected locations, such as the public bone area, without prior abdominal surgery or caesarean section. This case shows how surprising the disease can be, and confirms how laparoscopy may lead the way to new surgical sites, and help relieve complaints in patients often left alone without help, without the necessity to proceed with open surgery.

<https://player.vimeo.com/video/339195269?autoplay=1>

ES28-0667 - Best Selected Videos 1

Interest of 4D ultrasound scan during hysteroscopic septoplasty

Olivier Garbin¹, Kohler Monique¹, Gabriele Victor¹, Barranger Xavier², Pelissie Mathilde¹, Lecointre Lise³

¹CMCO - Hôpitaux Universitaires de Strasbourg, Gynecology, Strasbourg, France

²HHC - Hôpitaux Universitaires de Strasbourg, Radiology, Strasbourg, France

³Hôpital de Hautepierre - Hôpitaux Universitaires de Strasbourg, Gynecology, Strasbourg, France

Background

The mean difficulty during an hysteroscopic septoplasty is to appreciate the thickness of the residual fundic myometrium

Methods

This video illustrates an hysteroscopic septoplasty performed under the control of 4D ultrasound scan

Results

The 4D ultrasound gives a frontal view of the uterine cavity and allows to appreciate the thickness of the fundic myometrium in real time.

Conclusions

4D ultrasound scan seems interesting during hysteroscopic septoplasty to increase the safety of the procedure

<https://player.vimeo.com/video/339219677?autoplay=1>

**ES28-0043 -
Best Selected Videos 2**

Pelvic sidewall anatomy

Resad Pasic¹, Megan Cesta², Rebecca Thompson³, Nkiruka Chuba⁴

¹Univeristy Of Louisville, Obs&Gyn MInimally Invasive Gynaecological Surgery, Louisville, USA

²Univeristy of Lousiville Hosital, Minimally Invasive Gynecology, Louisville, USA

³University of Louisville Hospital, Minimally Invasive Gynecology, Lousiville, USA

⁴Univeristy of Louisville Hospital, Minimally Invasive Gynecology, Lousiville, USA

Background

A review of retroperitoneal pelvic sidewall anatomy and laparoscopic dissection.

Methods

Cadaveric dissection of pelvic sidewall was performed and recorded for teaching purposes.

Results

Video for teaching purposes.

Conclusions

Laparoscopic cadaveric dissection is a useful tool to aid in learning pelvic sidewall anatomy.

<https://player.vimeo.com/video/330017500?autoplay=1>

**ES28-0191 -
Best Selected Videos 2**

Be conscious of “the dissectible layer” in gynaecologic surgery

Shiori Yanai¹, Masaaki Andou¹, Yoshiaki Ota¹, Kiyoshi Kanno¹

¹Gynecology, Kurashiki Medical Center, Kurashiki, Japan

Background

With recent development of the surgical visual system, laparoscopic surgeons have become more conscious of the fascial structures. However, surgeons still help different views on regarding the fascia had been different among surgeons. The Fascia Nomenclature Committee gave the description that the fascial system interpenetrates and surrounds all organs. A Japanese surgeon Prof. Shinohara advocated surgical meaning of these fascia and named it “the dissectible layer”. According to his concept, we can isolate the target organs without bleeding by consciously dissecting loose connective tissue, the dissectible layer, between the organs.

Methods

Certainly, we can create the layer around any blood vessels or muscles or organs by pulling surrounding structure also in gynaecologic surgery. Further, the dissected fascia looks like to stick around, it means that loose connective tissue has adhesion ability. It is meaningful in that we can retain the oncological margin by the dense connective tissue attachment to the organ. By pulling and extending the layer, we can select the cutting line close or distant from the target organs as per tumour progression. The concept is actually applied to the rectal or prostate cancer surgery especially in nerve sparing surgery.

Results

The video presents the dissectible layers in actual gynaecologic surgery and application to oncologic surgery.

Conclusions

By being aware of the “dissectable layers,” bleeding can be minimised and surgical accuracy can be improved. For malignancy, en-bloc removal is possible and the margin can be adjusted as per tumour progression. The use of this concept may have the potential to improve oncologic outcomes.

<https://player.vimeo.com/video/335140760?autoplay=1>

ES28-0133 -

Best Selected Videos 2

Laparoscopic management of early endometrial cancer in 10 steps

Eleni Karatrasoglou¹, Marta Kemp², Krzysztof Galczyński³, Michel Canis⁴, Benoit Ranischong⁴, Nicolas Bourdel⁴

¹*Euroclinic Hospital, Department of Gynecologic surgery, Athens, Greece*

²*Federal University of São Paulo, Department of Gynecology, São Paulo, Brazil*

³*Medical University of Lublin, Department of Gynecology, Lublin, Poland*

⁴*CHU Clermont Ferrand, Department of Gynecologic Surgery, Clermont Ferrand, France*

Background

Endometrial cancer is the most prevalent of all gynaecological malignancies. Currently, the endometrial adenocarcinoma is the fourth most common cancer in females. In the majority of cases the tumour is confined to the uterine corpus, at the time of the diagnosis and as a consequence it can be approached surgically and efficiently by laparoscopic gynaecologists. The high survival rate of an effective surgical management imposes the standardisation of the procedure, which will lead to reduction of human errors and complications. We here present the laparoscopic management of early endometrial cancer in 10 steps.

Methods

This video presents in 10 steps the surgical strategy that should be followed not only by the surgeon but also by the first and second assistants in order to achieve the best surgical outcome in the minimum time. The steps contemplate the pre-operative work-up, the practical manoeuvres, in order to expose the necessary anatomical spaces and landmarks of the pelvis and the tips that will maximise the results of cooperation among the surgeon and his assistants.

Results

Ten important steps that will facilitate the laparoscopic surgery in patients with early endometrial cancer are presented and standardised:

1. Vaginal ergonomomy
2. Laparoscopic ergonomomy
3. Exploration of abdominal cavity
4. Bilateral tubal coagulation
5. Introduction of uterine manipulator
6. Dissection of the necessary anatomical spaces
7. Colpotomy
8. Extraction of the uterus
9. Vaginal closure
10. Final actions

Conclusions

Due to the high prevalence rate of patients with early endometrial cancer and the minimal invasive approach that is growing up, the standardisation of the surgical procedure is of high value for the patient and the surgeon. This 10-step presentation helps to perform each part of the surgery in a logical sequence, making the procedure ergonomic and easier to adopt and comprehend.

<https://player.vimeo.com/video/335609142?autoplay=1>

ES28-0153 - Best Selected Videos 2

Laparoscopic nerve-sparing meso-anatomical theory and technique for deep infiltrating endometriosis
Kiyoshi Kanno¹, Masaaki Andou¹, Shiori Yanai¹, Yoshiaki Ota¹
¹Kurashiki Medical Center, Gynecology, Kurashiki, Japan

Background

The concept of nerve-sparing radical hysterectomy has become standard in many gynaecological oncology centres and it has led to a much improved quality of life. Surgery for complete excision of deep infiltrating endometriosis (DIE) may include, in a similar way to cervical cancer, resection around the uterosacral ligament, posterior broad ligament, parametrium, ureter and rectum. For this reason, such techniques have recently been imported and adapted for DIE surgery with the aim of preserving pelvic nerves. Therefore, DIE is a benign disease and simultaneous curability of DIE and functional preservation are essential. A meta-analysis suggested significant advantages of the nerve-sparing technique for DIE in reducing the risk of urinary retention due to iatrogenic injury to nerves. However, this procedure is technically not very easy and we think that establishment of a safe and precise approach based on detailed meso-anatomical theory is needed.

Methods

In DIE, the central area of the pelvis, such as the pouch of Douglas, is often obliterated by adhesions and fibrosis. However, the posterolateral space to the rectum remains intact in most cases at the level of the promontory. So, we enter from this virgin area to develop the retroperitoneal space. The hypogastric nerve consists of the upper edge of the pelvic plexus, so autonomic nerves are separated as a “nerve plane“ by interfascial dissection of the layer both above (between mesorectal fascia and pre-hypogastric nerve fascia) and below (between pre-hypogastric nerve fascia and presacral fascia) the hypogastric nerve. We then resect the DIE lesion completely not to injure the nerve plane. This nerve-sparing technique is referred from the Negrar method by Dr. Marcello Ceccaroni and total mesometrial resection (TMMR) by Dr. Michael Höckel.

Results

Although this nerve-sparing techniques are feasible in severe endometriosis cases such as complete cul-de-sac obliteration, nerve-sparing technique allows nerve preservation in cases where the nerve plane is disease-free. In cases where the DIE involves the nerve plane, nerve-sparing techniques are no longer feasible, except in those with unilateral involvement. In a small number of our cases (n=18), pelvic autonomic nerves could be preserved completely in all cases of DIE surgery using this technique and no dysfunction of the bladder and rectum developed; thus, there were no complications. We consider that this technique also can be applied for segmental rectal resection for rectal endometriosis or radical hysterectomy for cervical cancer.

Conclusions

Our laparoscopic nerve-sparing theory and technique based on detailed pelvic meso-anatomy can be used for DIE surgery with safety and reproducibility. This technique can provide both curability of DIE and functional preservation for the patient.

<https://player.vimeo.com/video/335699144?autoplay=1>

ES28-0158 - Best Selected Videos 2

Laparoscopic findings of the liver – a tutorial for the attentive caregiver

Stefan Mohr¹, Sara Imboden¹, Susanne Lanz¹, Annette Kuhn¹, Jean-Francois Dufour², Michael Mueller¹
¹Inselspital- University Women's Hospital, Department of Obstetrics and Gynecology, Bern, Switzerland
²Inselspital- University Hospital, Department of Hepatology, Bern, Switzerland

Background

During laparoscopic surgery it is desirable to achieve a holistic view of the abdominal cavity instead of focusing on the (sub-)specialty's organs. All viscera should be viewed and photos taken in case any special finding appears. In

gynaecologic surgery this is particularly true for the upper abdomen to put emphasis on the diaphragm since ovarian cancer lesions or endometriosis might be missed if no systematic diagnostic laparoscopy is performed. Frequently, variants and abnormal findings of the liver, stomach and intestine occur.

Methods

During laparoscopic surgeries we collected video sequences of liver findings. The video material was discussed and interpreted with a hepatologist and linked with the patient's histories.

Results

Our work resulted in a tutorial video of liver findings and their interpretation.

Conclusions

During laparoscopic surgery we should not neglect the opportunity to inspect the whole abdominal cavity. If we only focus on obvious pathologies in the pelvis there is a risk of missing peculiarities in other abdominal areas. Our tutorial video aims at describing liver findings any surgeon could possibly be confronted with during surgery. Surgeons carrying out laparoscopic operations should be familiar with such findings to allow for intraoperative decision-making.

ES28-0199 - Best Selected Videos 2

Bowel injuries and laparoscopic repair

Midori Okumura¹, Andou Masaaki²

¹Shirakawa Clinic, Obstetrics and Gynecology, Hiroshima, Japan

²Kurashiki Medical Center, Obstetrics and Gynecology, Okayama, Japan

Background

To describe prevention and laparoscopic management of a rectal injury during an operation for severe endometriosis

Methods

This is the case report of a 30 y.o. 1G1P woman presenting with a 6cm chocolate cyst in the left ovary and Douglas pouch obliteration, suffering from severe dysmenorrhea. Usually our strategy for rectal dissection in cases when Douglas pouch obliteration is also present is grasping and pulling and pushing the rectum to confirm its contour; and short, sharp and repeated cutting of the rectum followed by blunt dissection with an aspiration tube.

In this case, during the cystectomy, at dissection of the rectum, a rectal perforation occurred. In this presentation, I will show the causes of the injury and how we can prevent this from occurring by finding an appropriate, dissectable plane as well as how to repair the injury safely.

The hole in the rectum was repaired in two layers. Firstly, we closed the hole with a single suture at full layer to avoid spillage of bowel content (inverted suture). Then, we dissected the correct layer of the bowel carefully. Finally, we sutured outside of the first suture in an Albert-Lembert suture fashion. The suture must be placed longitudinally to prevent stenosis. An air leak test showed no leak from the bowel after the repair.

Results

After the operation, as part of the recovery strategy the patient was nil by mouth for 2 days post-operative. The patient showed no sign of peritoneal irritation and the CRP did not increase. The patient was discharged 4 days after the procedure and the recovery course was uneventful. The patient's dysmenorrhea reportedly decreased dramatically. In our clinic, we have performed 2090 laparoscopic operations from 2011 to 2018. In that period, 2 bowel injuries have occurred and both of them could be repaired laparoscopically intraoperatively without sequel. The patient featured in this video presentation gave her consent for their operative footage and patient data to be used for research and educational purposes.

Conclusions

For a complete resection of deeply infiltrated endometriosis, anatomical knowledge and safe dissection techniques are important. Moreover, with knowledge of how to repair the bowel injuries, it is possible to repair it injuries, should they occur, intraoperatively safely.

<https://player.vimeo.com/video/336064525?autoplay=1>

ES28-0235 - Best Selected Videos 2

Laparoscopic management of obturator nerve injury

Enrique Moratalla Bartolomé¹, Carmen Martín Blanco², Elena Cabezas López¹, Irene López Carrasco³, Nerea Montero Pastor³, Jesús Lázaro de la Fuente²

¹University Hospital Ramón y Cajal, University Hospital HM Montepíncipe, Obstetrics and Gynecology, Madrid, Spain

²University Hospital Ramón y Cajal, Obstetrics and Gynecology, Madrid, Spain

³University Hospital HM Montepíncipe, Obstetrics and Gynecology, Madrid, Spain

Background

Pelvic lymphadenectomy in the obturator fossa in the patients with gynaecologic cancer are increased risk of obturator nerve injury.

Damage of this nerve causes medial thigh or groin pain, weakness with leg adduction and sensory loss in the medial thigh of the affected side.

Intraoperative repair may be done by end-to-end anastomosis.

Methods

To present a case of obturator nerve transection during laparoscopic pelvic lymph nodes dissection in a patient with endometrial cancer and its immediate laparoscopic repair.

Results

During lymphadenectomy, the obturator nerve should attempt to identify itself lateral to the external iliac artery and medial to the psoas muscle, at the depth of the dissection. The nerve must be identified lateral by to the umbilical artery.

In this case, we started by identifying the nerve and then the lymph nodes dissection is started. Unlike most cases, in this patient the lymph nodes were very attached, in fact the anatomopathological result was positive for tumour infiltration. It was decided to pull cranially to liberated adenopathy found at this level and the nerve is unintentionally sectioned.

Once the both caudal and cranial ends of the section nerve are identified, a suture of the same terminal term with 5-0 prolene is performed. In order to minimise sequelae, the ends must be approximated as much as possible. When the suture is completed and observing that the ends of the nerve are properly confronted, we add tissucol to reinforce the union.

The patient has not developed any functional deficiency and the neurophysiological study performed showed a complete recovery of the nerve.

Conclusions

Immediate laparoscopic repair of the obturator nerve is an effective technique that solves the obturator nerve injury that it may arise during pelvic lymphadenectomy.

<https://player.vimeo.com/video/336200108?autoplay=1>

ES28-0238 - Best Selected Videos 2

Surgical traps in laparoscopic sacrocolpopexy for vaginal vault prolapse
Floriane Jochum¹, Aline Host¹, Lise Lecointre¹, Michel Hummel¹, Cherif Akladios¹, Olivier Garbin¹
¹Universary Teaching Hospital of Strasbourg, Obstetrics and Gynecology, Strasbourg, France

Background

The management of vaginal vault prolapse remains challenging. Bladder injuries are not rare and occur in about 2 to 6% of laparoscopic vaginal vault prolapse surgery. Vaginal openings are less common, but remain at risk. The objective of this video is to describe the possible difficulties encountered in the event of laparoscopic sacrocolpopexy for vaginal vault prolapse, with a special focus on surgical traps.

Methods

Video recordings of different laparoscopic sacrocolpopexies for vaginal vault prolapse showing various situations and difficulties. Universary Teaching Hospital of Strasbourg.

Results

In case of previous hysterectomy, adhesions can be observed at different pelvic levels and need adhesiolysis. The posterior dissection is generally easy, while it is not the case of the anterior dissection. The bladder bulges into the Douglas and is then difficult to identify. It can lead to dissect in the wrong plan and to injure the bladder or the vagina. This video illustrates how to avoid these surgical traps. The surgeon should remember to use a vaginal valve to mobilise the vaginal vault and to pull up the bladder. They have to begin the dissection very low and first laterally. In case of difficulty, it is necessary to think of moving at a lower level in order to expose the right plan. To help them, they can use the filling of the bladder with methylene blue. The surgeon must remember that a correct dissection plan is an avascular plan and the latter must be suspicious of any abnormal bleeding.

Conclusions

Laparoscopic vaginal vault prolapse surgery requires specific and careful attention.

<https://player.vimeo.com/video/336201173?autoplay=1>

ES28-0394 - Best Selected Videos 2

Genitofemoral nerve sparing adhesiolysis

Tina Ngan¹, John Thiel^{1,2}, Darrien Rattray^{1,2}
¹Regina General Hospital, Obstetrics and Gynaecology, Regina, Canada
²University of Saskatchewan, Obstetrics and Gynaecology, Regina, Canada

Background

The objective of this video is to review the anatomical landmarks, innervations and mechanisms of injury of the genitofemoral nerve in order to avoid its injury in cases with significant pelvic adhesions.

Methods

During the laparoscopic bilateral salpingo-oophorectomy, genitofemoral nerve sparing adhesiolysis was performed.

Results

The patient had an uneventful recovery.

Conclusions

In the case of severe pelvic side wall adhesions and absence of a uterus, recognition of pelvic landmarks is of paramount importance. This facilitates identification of other pelvic structures and in this case, prevented injury to the external iliac artery and the genitofemoral nerve. Furthermore, careful tissue handling and dissection techniques are crucial. These help to maintain minimal blood loss, develop surgical planes and avoid injuries to pelvic structures.

<https://player.vimeo.com/video/336567227?autoplay=1>

ES28-0429 -

Best Selected Videos 2

Mini-invasive laparoscopic enucleation of la lombo-aortic sovramesenteric metastasis of ovarian cancer

Alberta Ricci¹, Sara Fantinato¹, Valentina Bresciani¹, Andrea Serena¹, Mauro Fiorese¹, Marcello Scollo¹

¹Alto Vicentino Hospital- AULSS 7 Pedemontana, Gynecology and Obstetrics, Santorso, Italy

Background

The objective of this video is to report the feasibility of a laparoscopic mini-invasive enucleation of para-aortic relapse in ovarian cancer after chemotherapy.

A 57 years old adult patient underwent extra-fascial laparoscopic radical hysterectomy with pelvic and lombo-aortic lymphadenectomy in March 2018 for ovarian clear-cell carcinoma FIGO 1st A, N0. She underwent 6 cycles of adjuvant chemotherapy. By a chest and abdomen CT performed at the end of the therapy, a para-aortic recurrence above mesenteric artery, of about 3 cm, was discovered and then confirmed by the TAC PET with a SUV> 16. CA 125 was negative.

Methods

We used a minimally invasive laparoscopic approach, positioning 5 mm trocars in the umbilical, suprapubic and lateral pelvic regions. The pneumoperitoneum pressure was 6 mmHg. The patient was placed in Trendelenburg position. The optic was inserted in the suprapubic trocar. After an exploration of the entire abdomen, a suspected area of peritoneal localization was seen in the region of an epiploic appendix that was therefore removed. By the identification of the presacral region the peritoneum was incised and the aortic bifurcation and the vena cava were identified. The large vessels had been progressively isolated until the inferior mesenteric artery and the left renal vein were identified. The metastasis of about 2 cm was identified below the left renal vein and above the inferior mesenteric artery. One proceeded with careful enucleation of the same using ultrasounds and bipolar energy, paying attention to haemostasis. The lesion was placed in a laparoscopic bag and then removed by the right access.

Results

There were no immediate or late postoperative complications. The patient was discharged on the first day. An histological examination confirmed the single relapse (the peritoneal biopsy and washing were negative). A chest and abdomen CT performed 30 days after the surgery has confirmed the complete removal of the disease.

Conclusions

Laparoscopic mini-invasive approach for enucleation of lombo-aortic relapse in ovarian cancer is feasible in experienced hands without complications with fast postoperative recovery.

<https://player.vimeo.com/video/336458750?autoplay=1>

**ES28-0448 -
Best Selected Videos 2**

Resection of retroperitoneal mature teratoma causing severe urinary symptoms

Khashayar Shakiba¹, Sofia Gabrilovich¹, Kerly Guerrero

¹Hackensack University Medical Center, Obs&Gyn, Hackensack, USA

Background

The patient is a 28 yo G1P1 who presented to care in November 2018 for worsening left lower quadrant pain and pressure, urinary frequency, urgency and hourly nocturia. History is significant for dysmenorrhea, abdominoplasty and acne taking spironolactone. Imaging revealed amidly complex mass in the cul-de-sac measuring 10.6 x 8.3 x 7.3 cm, without thickening or nodularity, probably cystic and arising from the left ovary. She underwent laparoscopy for planned excision which was aborted as a retroperitoneal mass was identified involving the cul-de-sac and left pelvic sidewall without involvement of the ovaries, fallopian tubes and uterus. She was then referred to gynaecologic oncology, neurosurgery and then by urogynaecology.

Methods

She underwent a robotic assisted laparoscopic removal of the left retroperitoneal mass with care to avoid use of excessive cautery, excision of endometriosis, left ureterolysis, enterolysis, peritoneal biopsy and cystoscopy with an intraoperative left ureteral stent placed by urology, removed at the end of the case. After removal of the mass her urinary symptoms and pelvic pain completely resolved. Her postoperative course was uncomplicated. Pathologic findings of the retroperitoneal mass were consistent with a mature teratoma.

Results

The retroperitoneal teratoma compressed the inferior hypogastric plexus which led to the patient's symptoms. Careful dissection of the pararectal and paravesical space was performed to cause minimal damage to the inferior hypogastric plexus and surrounding nerves with complete resolution of symptoms. Limited use of electrocautery was employed to avoid thermal damage. Extragonadal teratoma is a rare finding.

Conclusions

The objective of this video is to depict a robotic assisted laparoscopic resection of a retroperitoneal mass, showing a unique case where compression on the pelvic splanchnic nerves produced severe urinary symptoms in a patient which resolved immediately after the procedure. It also shows a rare case of extraogonadal retroperitoneal mature teratoma.

<https://player.vimeo.com/video/336488424?autoplay=1>

**ES28-0503 -
Best Selected Videos 2**

Single port laparoscopic pectopexy

Xuyin Zhang¹, Ding Yan¹, Hua Keqin¹

¹GybObs Hospital- Fudan University, Gynecology, Shanghai, China

Background

In this video, we will introduce single port laparoscopic pectopexy in a postmenopausal woman with uterine prolapse.

Methods

A fascia platform was established for single port laparoscopy without special instruments. The vesical peritoneal reflection was incised. Along with the round ligament, the peritoneum was dissociated to the iliopectineal ligament. The bladder was pushed down and the cervix was exposed. The mesh was sutured to the cervix with non-absorbable stitches. Then, the iliopectineal ligament was sutured with the mesh. After that, the peritoneum was closed.

Results

The operation was performed successfully. No complications occurred. The operation time was 1 hour. The blood loss was 10ml. The length of stay was 2 days. Prolapse did not occur and mesh erosion / exposure was not observed during a 1-year follow-up period.

Conclusions

The technique is easy to learn and perform. And it provided a feasible, safe, and comfortable alternative for apical prolapse surgery with functional and anatomic satisfaction. No special surgical apparatus is needed with this technique.

<https://player.vimeo.com/video/338808143?autoplay=1>

ORAL IN PLENARY (23)

ES28-0630 - Adenomyosis

Ultrasound findings of adenomyosis in adolescents: type and grade of the disease

Lucia Lazzeri¹, Francesco Martire², Caterina Exacoustos², Terry Siciliano², Emilio Piccione², Errico Zup²

¹University of Siena, Department of Molecular and Developmental Medicine, Siena, Italy

²University of Rome Tor Vergata, Department of Biomedicine and Prevention, Rome, Italy

Background

To assess in adolescents the ultrasound features of adenomyosis and clinical symptoms, since it is of great interest and relevance to investigate the presence of this disease even in young girls, especially if symptomatic.

Methods

This retrospective observational study included 20 adolescents who underwent 2D, 3D and power Doppler ultrasound examination (trans-abdominal and trans-vaginal or trans-rectal in adolescents with an intact hymen) for several indications, and where ultrasound findings of adenomyosis were observed. Adenomyosis was classified according to our previous classification published in 2018.

Pain symptoms were assessed in all adolescents by visual analogue scale (VAS).

Results

Concerning demographic characteristics patients mean age was mean age 18.6 ± 1.6 years, the mean body mass index (BMI) was 21.2 ± 3 and all patients were nulliparous.

Almost all patients (90%, 18/20) referred dysmenorrhoea, with a mean VAS score of 8.1 ± 2.4 . 70% (14/20) of adolescents complained about heavy menstrual bleeding. Concerning the other pain symptoms investigated 7 patients (35%) reported dyspareunia, 6 (30%) dyschezia and 3 (15%) dysuria.

Associated endometriosis was found in 7 patients (35%), of these 2 patients had endometrioma, 1 patient had deep infiltrating endometriosis (DIE) and the remaining 4 present both ovarian endometriosis and DIE.

Adenomyosis was observed mostly as diffuse pattern of the external myometrial wall (17/20, 80%), of these 7 had in association diffuse involvement of the junctional zone, 1 patient with diffuse external adenomyosis had also an adenomyoma, 2 patients showed focal adenomyosis (10%), both of the external myometrium. Most patients had mild adenomyosis (80%, 16/20), 4 presented moderate adenomyosis (20%) and severe adenomyosis was not detected.

At the time of the ultrasound assessment 8 patients (40%) assumed combined oral contraceptives.

Conclusions

The rates of dysmenorrhea and heavy menstrual bleeding are high. Although there were few cases, it was possible to observe a strong association between adenomyosis and clinical symptoms in adolescent women.

The use of the mesorectal flap as prevention of rectovaginal fistula in patients with endometriosis with resection of the rectosigmoid and vagina at one time

Jiri Hanacek¹, Lukas Havlu², Jan Drahonovsky³, Iva Urbankova³, Noble Ayayee³, Jaroslav Feyereis³

¹- Institute of Care about Mother and Child- Prague, Gynaecology and Obstetrics, Prague, Czech Republic

²Third Faculty of Medicine and University Hospital Královské Vinohrady- Charles University- Prague- Czech Republic, Department of General Surgery, Prague, Czech Republic

³Institute of Care about Mother and Child- Prague, Gynaecology and Obstetrics, Prague, Czech Republic

Background

Surgical approach to endometriosis of the rectosigmoid includes three main options; shaving technique, discoid resection or segmental resection. Procedures could be associated with some complications. One of the most debilitating complication is the rectovaginal fistula (RF). The RF usually develops after concomitant resection of vaginal and rectosigmoid nodules. Prevention of the RF formation is either a two-step surgery, with a preventive colostomy. Another possibility is insertion of the omental flap between the sutures on the vaginal and intestinal wall. Hereby, we would like to present another option that includes the interposition of the mesorectal flap. This flap is a preserved mesentery after the "limited" recto/sigmoideal resection. Its anatomical location allows easy interposition between the two sutures.

Methods

This procedure was carried out in six women with similar conditions. They reported dysmenorrhoea, dyschezia and dyspareunia with visual analogue score (VAS) >6 for all symptoms. All of them were also planning pregnancy. The rectal nodules were 32-45mm large with a distance from the anal verge 6- 9cm, respectively. Surgery was carried out with two experienced laparoscopic surgeons (gynaecologist and colorectal surgeon). Firstly, the affected vaginal wall was sharply resected with a monopolar cut and closed with an interrupted polyglactin 910 suture. In all women, the vaginal suture was more than 3cm long. Secondly, the general surgeon dissected the mesorectum and adipose tissue, and released the rectosigmoid. A linear stapler was used to perform the intestinal resection. Extra-abdominally, the necessary part of the intestinal wall was resected with a monopolar cut, the anvil of circular stapling device (29/33mm) was inserted into the descending colon. The intestinal anastomosis was carried out laparoscopically with the circular stapling technique. Suture integrity was tested for water tightness. The mesorectal flap is constructed from the left mesorectum. The mesorectum was mobilized and cut at the level of the distal resection line of the rectum. This vascularized flap was rotated and inserted between the sutures on the rectum and vagina. The flap was fixed with an interrupted 2/0 polyglactin 910 suture approximately 2cm caudally to the vaginal closure.

Results

Women had follow-up consultation with the attending gynaecologist and surgeon 3 months postoperatively. All women recovered uneventfully, had shorter hospital stay and reported VAS between 0-2 for all preoperative complaints. There were no gastrointestinal complication or RV fistula development.

Conclusions

This is an adaptation of classical onco-surgical procedure, that includes resection of the left colon but preserves the mesorectum. Preserved "mesorectal" flap could be used in women who require a concomitant rectal and vaginal resection of DIE. Undamaged vessels and less affected nerves create a good quality tissue that could prevent the formation of the rectovaginal fistula between the two sutures.

<https://player.vimeo.com/video/332839654?autoplay=1>

Quality of life and gastro-intestinal well-being evaluation after segmental colo-rectal resection for deep infiltrating endometriosis (ENDO-RESECT QoL)

Luigi Carlo Turco¹, Virginia Vargiu², Anna Fagotti², Vito Chiantera³, Giovanni Scambia², Francesco Cosentino¹

¹Fondazione di Ricerca e Cura Giovanni Paolo II- Università Cattolica del Sacro Cuore,

Division of Gynaecologic Oncology, Campobasso, Italy

²Fondazione Policlinico Universitario A. Gemelli IRCCS., Department of Women's and Children's Health- Università Cattolica del Sacro Cuore-, Roma, Italy

³University of Palermo, Division of Gynaecologic Oncology, Palermo, Italy

Background

Deep Infiltrating Endometriosis (DIE) affects negatively quality of life and psychological well-being of women. Intestinal involvement of endometriosis occurs in 3% to 37% of all cases, most commonly involving the rectum and sigmoid colon, causing pelvic pain, dysmenorrhea, dyschesia, constipation, rectal bleeding, bloating, flatulence, defecation urgency and/or incomplete evacuation sensation. Conservative surgery *versus* radical surgery is patient-personalised and evaluated individually, because the two different approaches have different indications, outcomes and complications. Segmental resection is often associated with higher post-operative major complication rate and with short and long-term gastrointestinal quality of life setbacks compared to conservative approaches. Small sample sizes, short follow-up periods, absence of specific quality of life endometriosis patient questionnaires and of a specialised gastroenterologic evaluation affected the significance of these studies. The aim of this study is to follow-up DIE-patients after intestinal segmental resection, evaluating long-term quality of life and gastrointestinal well-being with specific questionnaires.

Methods

A single centre observational cohort study: ENDO-RESECT (ClinicalTrials.gov ID: NCT03824054) conducted in a third referral university hospital. All clinical data about women who underwent segmental colorectal resection for intestinal-DIE between October 2005 and November 2017 were collected. Patients responded the Endometriosis quality of life Questionnaire (EHP30), Psychological General Well-Being Index (PGWBI), Hospital Anxiety and Depression Scale (HADS), Gastrointestinal Well-being Questionnaire (GSRS) and the Bristol Stool Chart (BSC) referring their clinical situation before surgery and at the last follow up visit.

Results

A total of 50 women, 18% stage III and 82% stage IV, classified according to the revised American Fertility Society have been enrolled in the study. Laparoscopy was performed in 84% of patients. Only 3 (6%) cases of late major grade III complications have been registered at the end of the study. Median follow-up time after colorectal resection was 42.5 months (range 12–157 months). EHP-30 interpretation demonstrates an overall significant improvement ($p < 0.001$) and in all continuous variables measured except for fertility concerns. Overall gastrointestinal quality of life and most specific symptoms improved after surgery (reflux $p < 0.001$, indigestion syndrome $p = 0.05$, abdominal pain $p < 0.001$). An increase of daily defecations number in 14% of population was noticed ($p < 0.001$) without negative impact on general and gastrointestinal quality of life. Women with increased post-operative diarrhoea syndrome were mostly those suffering from anxiety. Constipation symptom remained unchanged. Patients with increased likelihood for condition improvement after surgery resulted to be those ones with multiple intestinal nodules, with depression (more than anxiety), which underwent laparoscopic surgery.

Conclusions

A general and gastrointestinal quality of life improvement was noticed after segmental colo-rectal resection. Radical surgery was not associated with higher risk of major complication compared to literature. Patients with multinodular bowel infiltration, depression symptoms and managed with laparoscopy benefited most from this surgery type.

ES28-0472 - HMB I Fibroids

Efficacy, safety and eligibility of ultrasound-guided high-intensity focused ultrasound ablation for uterine fibroids: an eleven years' experience

Jordi Rodriguez¹, Nuria Pons¹, Anna Carmona¹, Jose Angel De Marcos², Marta Paraira², Antoni Pessarrodona¹

¹University Hospital Mutua Terrassa, Obstetrics and Gynaecology, Barcelona, Spain

²University Hospital Mutua Terrassa, Radiology, Barcelona, Spain

Background

To analyse safety and effectiveness of ultrasound-guided high-intensity focused ultrasound (USgHIFU) on symptomatic uterine fibroids. We also evaluate the effect of magnetic resonance imaging (MRI) characteristics on the response of uterine fibroids to HIFU treatment.

Methods

A total of 630 women with symptomatic uterine fibroids underwent USgHIFU from February 2008 to February 2018. Before treatment fibroids were classified into 3 types based on the signal intensity of T2-weighted MRI as follows: type 1, low intensity; type 2, intermediate intensity; type 3, high intensity. They were also classified according to the degree of vascularisation on T1-contrast-enhanced MRI: high, medium and low vascularisation. After treatment, we used T1-contrast-enhanced MRI to measure the mean nonperfused volume ratio of the fibroids. The volume change ratio was calculated at 3, 6, 12 months and annually based on transvaginal sonography images. The symptom severity score was examined before and after treatment according to the Uterine Fibroid Symptom and Quality of Life questionnaire. The complication and reintervention rates after HIFU treatment were also recorded. These results were also stratified according to the signal intensity and degree of vascularisation of fibroids on MRI.

Results

Seven hundred and forty-eight treatments in 630 patients were done. The treatment was achieved in 598 patients (95%) and it didn't achieve in 32 patients (5%) because of vesical air, bowels within the sonication pathway, pain or poor visualisation. 68% (404/598) had a successful treatment and 32% (194/598) required a surgical procedure. The mean baseline volume of treated myoma was 190 cm³. The average nonperfused volume (NPV) ratio was 60% immediately after treatment. Treated fibroids decreased in volume by 46%, 53%, 58%, 60%, 77% and 78% at 6, 12 months, 2, 4, 6 and 8 years respectively. There was a 25% reduction in median symptom severity score at 6 months and 27%, 29%, 36%, 76% and 77% at 1, 2, 4, 6 and 8 years respectively. The stratified analysis revealed an average NPV rate of 40% and 74% and a reintervention rate of 50% and 10% for fibroids with high and low vascularisation respectively. In type 1 and type 3 myomas the average NPV rate was 70% and 42% with a reintervention rate of 20% and 55% respectively. Treatment-related complications were observed in 58 patients (9%). All of them were mild complications except a patient who had a third-grade skin burn.

Conclusions

We demonstrate the clinical efficacy and safety of USgFUS on symptomatic uterine fibroids. The best results were obtained for type 1 fibroids and low vascularisation fibroids. Type 3 fibroids and high vascularisation fibroids were associated with the lowest treatment efficacy and are not suitable candidates for USgHIFU.

ES28-0291 - Hysteroscopy

Efficiency of antiadhesion barrier application during hysteroscopic adhesiolysis

Alexander Popov¹, Anton Fedorov¹, Alexey Koval¹, Anastasiia Bespalova¹

¹Moscow Regional State Research Institute O/G, Endoscopy, Moscow, Russia

Aim

To compare adhesiolysis and improve the results of IUA treatment using two different antiadhesion barriers "Protescal" (LG Life Science, LTD Korea) and «Mesogel» (Lintex, Russian Federation)

Background

Intrauterine adhesions (IUA) is one of the intrauterine infertility factors. In this group of patients intrauterine hysteroscopic adhesion resection is mandatory. Grade of IUA influence on the incidence of adhesion recurrence.

According to M. Hanstede data (FertilSteril., 2015) at patients with Asherman syndrome the recurrence rate of IUA after uterine cavity restoration is 28,7%.

Materials / Patients

80 patients with grade 2-3 IUA classified by AFS classification were included in our study. We divide patients in 3 groups. First group (25 patients) with "Protescal" application, second group (also 25 patients) with barrier "Mesogel". In the third group – control group (30 patients) - hysteroscopic adhesiolysis was performed without the use of any barrier. All the patients had history of previous intrauterine manipulations. According to our data approximately 60% of all cases of severe IUAs are associated with postpartum complications.

Methods / Results

Hysteroscopic adhesiolysis was classified as successful if menstrual function became normal along with a restored cavity anatomy with hysteroscopic visualisation of ≥ 1 tubal ostium. Hysteroscopic adhesiolysis was mainly performed by scissors. After successful adhesiolysis adhesion barriers was introduced into the uterine cavity of 1,5 - 3,0 - 5,0 ml.

Results: the procedures were successful in all women (100%), a healthy uterine cavity was restored with hysteroscopic adhesiolysis in 1-3 attempts and restoration of menstrual blood flow occurred in 100%. During office hysteroscopy 4-8 weeks after last adhesiolysis recurrence IUA were diagnosed in 4 (16%) patients in «Protescal» group, and in 6 cases (24%) in «Mesogel» group, who had IUA with third stage. Recurrence rate of IUA in the control group was in 10 cases (33,33%).

Conclusion

Postoperative prognosis depends on the severity of IUA. High grade of adhesions warn of a higher chance of spontaneous recurrent of adhesions. The use of antiadhesions barrier reduce the risk of adhesions recurrence.

ES28-0329 - Hysteroscopy

A new highly compact diode laser for office hysteroscopic polypectomy: preliminary results

Felice Sorrentino¹, Francesco D'Antonio¹, Anna Morrone¹, Tea Palieri¹, Maria Grazia Morena¹, Luigi Nappi¹
¹Institute of Obstetrics and Gynaecology- University of Foggia- Foggia- Italy,
Department of Medical and Surgical Sciences, Foggia, Italy

Background

Currently, endometrial polyps may be successfully treated with 5 Fr mechanical and bipolar instruments. Our aim is to evaluate the benefits of minimally invasive techniques in hysteroscopy, focusing on the use of a highly compact diode laser in the treatment of endometrial polyps.

Methods

20 patients with ultrasound diagnosis of endometrial polyp with maximum diameter 2.5 cm were recruited from January to May 2019. Hysteroscopic procedures were performed by a 4 mm continuous flow office hysteroscope (Bettocchi Office Hysteroscope size 4, Karl Storz, Tuttlingen, Germany). We collected data of the operative time and pain assessment was analysed according to patient responses to a VAS score from 0 to 10. Polyps resection was performed with a highly compact diode laser featuring the combination of two wavelengths, 980nm and 1470nm, respectively giving a power of 10 and 4 watts. The procedure was carried out without anaesthesia and antibiotic prophylaxis was not administered.

Results

Operating time was $6 \pm 1,05$ min. Blood loss during the procedure was minimal. There were no intraoperative complication. Intraoperative pain was $3,06 \pm 0,52$. No postoperative complications were observed in any patients. All patients were discharged in the same day.

Conclusions

Office hysteroscopic polypectomy can be successfully performed using a highly compact diode laser. It could be a feasible and safe alternative to the scissor, bipolar twizzle and bipolar or monopolar resectoscope techniques. Further well-designed studies are necessary, however, to explore the feasibility and reproducibility of the technique by other authors.

ES28-0228 - Endometriosis 1

Feasibility and safety of two different surgical routes for the eradication of recto-vaginal endometriosis with vaginal mucosa infiltration

Diego Raimondo¹, Manuela Mastronardi¹, Luigi Carlo Turco², Francesco Cosentino², Giovanni Scambia³, Renato Seracchioli¹

¹Sant'Orsola Hospital - University of Bologna,

Department of Obstetrics and Gynaecology - Dipartimento di Scienze Mediche e Chirurgiche DIMEC, Bologna, Italy

²Fondazione di Ricerca e Cura Giovanni Paolo II - Università Cattolica del Sacro Cuore,

Division of Gynaecologic Oncology, Campobasso, Italy

³Fondazione Policlinico Universitario Agostino Gemelli IRCCS - Università Cattolica del Sacro Cuore,

Department of Women's and Children's Health, Roma, Italy

Background

Vaginal endometriosis is defined as the posterior vaginal fornix wall infiltration by the disease. It is usually associated with a nodule in the recto-vaginal space and the anterior surface of the recto-sigmoid tract (recto-vaginal endometriosis, RVE). RVE surgical management needing partial colectomy is a surgically challenging condition and has been associated with a notable risk of major postoperative complications. Although laparoscopy represents the gold standard for endometriosis treatment, no strong evidence supports the best approach in case of RVE. In the present study, we sought to compare feasibility and safety of total laparoscopic (TL) and vaginal-assisted (VA) routes in patients affected by symptomatic RVE with vaginal mucosa infiltration scheduled for minimally invasive surgery.

Methods

This is a multi-centric, retrospective cohort study on medical records of consecutive fertile patients submitted to complete macroscopic eradication of symptomatic RVE with vaginal mucosa infiltration between March 2013 and November 2017. Exclusion criteria were: patients < 18 years and > 50 years; history of RVE surgical treatment or hysterectomy; previous or ongoing gynaecological neoplastic pathology. The two groups were compared in terms of preoperative data (age, body mass index, parity, previous surgery for endometriosis, stage of disease, preoperative pain symptoms, preoperative medical therapy) and surgical outcomes (operative time, estimated blood loss, laparotomic conversion rate, associated surgical procedures, length of hospitalisation, intra and postoperative complications rate). Women were followed up 30 days after surgery in order to evaluate their general health condition and possible post-operative complications. The study was approved by the local Ethical Committee and registered on ClinicalTrial.gov with the following ID number: NCT03744143.

Results

84 patients were included in the study (TL=57 and VA=27). The two groups were comparable in terms of preoperative, surgical and postoperative data. In the TL group, the mean operative time was 197.0 ± 83.4 minutes and the mean hospitalisation length 7.2 ± 3.6 days. In the VA group, the mean operative time was 191.3 ± 92.0 minutes the mean hospitalisation length 6.9 ± 3.1 days. Intra- and postoperative complications rate was 15.8% (9/57 women) in the TL group and 18.5% (5/27 women) in the VA group.

Conclusions

In the present study, we did not observe any significant differences in terms of safety and feasibility between TL and VA routes for the surgical treatment of symptomatic RVE involving the posterior vaginal mucosa.

ES28-0208 - Endoscopy and Pregnancy

Open port placement laparoscopic technique for persistent ovarian masses in pregnancy

Marilou Mangubat¹, Syrra Kyzle Guimba¹, Evelyn Tam¹

¹Perpetual Succour Hospital of Cebu, Department of Obstetrics and Gynaecology, Cebu City, Philippines

Background

Complex and large ovarian masses during pregnancy are at increased risk for torsion, rupture and dystocia. Six cases of ovarian masses with pregnancy between June 2015 and 2019 are included in a case series to demonstrate the safety and advantages of open port placement laparoscopic technique for persistent large symptomatic ovarian masses in pregnancy.

Methods

Intervention: CA 125 tumour marker on 2 cases and pelvic ultrasound were taken before laparoscopy. Progesterone 200 mg was given vaginally pre- and post-operatively. All patients were counselled on the probable risk of anaesthesia and the benefits and risks of the open laparotomy versus laparoscopic approach. Under general anaesthesia all cases were successfully operated maintaining 10-12 mm Hg intra-abdominal pressure. Compression stockings were applied up to the knees. The patients were placed on dorsal supine with a leftward tilt but without any Trendelenburg position. The initial site for abdominal access was adjusted according to the fundal height. Using the Hasson open port placement technique, the 1st major 10 mm blunt trocar was placed mid-umbilical in 2 cases (14 weeks gestation) or supra-umbilical (Lee Huang point) in 4 cases (16-19 weeks gestation). There were 5 mm lateral ports on both sides above the anterior superior iliac spines and 2 high lateral ports ipsilateral to the minor ports placed lateral to the midline. Cyst walls were incised using bipolar scissors. Cystectomy was performed successfully with combined hydro dissection and blunt peeling. The cysts were removed through contained tissue extraction. A multidisciplinary team was included in the patient care.

Results

The indications for intervention were pelvic pain and persistent large adnexal masses. 3 were located posterior to the gravid uterus, 1 prolapsing into the rectovaginal space and 2 were lateral to the uterus. The sonographic findings in all cases (except 1 case of endometrioma) showed benign features of dermoid cyst with hyperechoic lines and dots and diffuse echogenicities. Age range was 27-37 years. 3 were nulliparas and 3 were primiparas. The range gestational age was 14-19 weeks. The size of the cysts varied from 8-12 cm. Laparoscopic bilateral cystectomy was performed on 2 cases. No complications were encountered intra- and post-operatively. Operative time was 90-150 minutes. The average hospital stay was 2-3 days. Estimated blood loss was 50-150 cc. Prenatal course was uneventful. The pregnancy outcome was normal. All except one (elective repeat caesarean section) had normal spontaneous vaginal delivery. On follow-up, both mothers and babies are well. Histopathology reported endometriotic cyst in one case and mature dermoid cysts in other cases.

Conclusions

Laparoscopic surgery for ovarian new growths in pregnancy using the open port placement technique is safe and effective ideally carried out in 2nd trimester of pregnancy with good foetal-maternal outcome.

ES28-0282 - Reproductive Medicine

Adolescence and endometriosis: ultrasound assessment

Caterina Exacoustos¹, Francesco Giuseppe Martire¹, Terry Siciliano¹, Martina Cosentino¹, Emilio Piccione¹, Errico Zup²

¹University of Rome- "Tor Vergata"-, Department of Biomedicine and Prevention - Obstetrics and Gynaecology Clinic-, Roma, Italy

²University of Siena, Molecular and Developmental Medicine, Siena, Italy

Background

Endometriosis in adolescence has been considered a rare, often transient, condition. Diagnosis is often delayed for years, even in adult women. The incidence of surgically confirmed endometriosis range from 19 to 73%. The objectives of this study were to assess the prevalence and ultrasound features of pelvic endometriosis in adolescents.

Methods

This retrospective observational study included 238 adolescents (mean age 17.7 ±1.9 yrs.) referred to our gynaecological clinic from January 2010 to December 2018. A 2D, 3D and power Doppler ultrasound examination (trans-vaginal or trans-rectal in adolescents with an intact hymen) was conducted in all patients. All possible locations of endometriosis were evaluated and recorded using a dedicated mapping sheet. Levels of pelvic pain were assessed in all adolescents by visual analogue scale (VAS).

Results

The most frequent symptoms were dysmenorrhea 57.1 % (136/238) and heavy menstrual bleeding 27% (64/238). Endometriosis was identified in 54 adolescents (22.7%). In particular, endometriomas were found in 17 adolescents (7.1%), deep infiltrating endometriosis (DIE) in 9 (3.8%), adhesions in 18 (7.6%) and ultrasound signs of adenomyosis in 16 (6.7%). In the group that complained dysmenorrhea (136 adolescents) the percentage of endometriosis was 18.5 %; in particular, endometriomas were present in 7.3 %, DIE in 2.9%, adenomyosis in 5.9% and adhesions in 10.3%.

Conclusions

The rates of dysmenorrhea and heavy menstrual bleeding in adolescents are high. In teenagers with painful menses ultrasound features of endometriosis are significantly higher compared to those without. Considering the lacking knowledge of the disease among adolescents, those involved with teens, within the health profession or in schools, should be educated about endometriosis and its symptoms, to reduce the significant delay between the onset of symptoms and the diagnosis by referring to appropriate tertiary care centres.

ES28-0174 - Hysteroscopy

A randomised trial comparing morcellator versus resectoscope in the treatment of uterine polyps by hysteroscopy: the RESMO study

Olivier Garbin¹, Stoll François¹, Meyer Nicolas¹, Faller Emilie², Hummel Michel¹, Host Aline³

¹Hôpitaux Universitaires de Strasbourg, Santé Publique, Strasbourg, France

²Hôpitaux Universitaires de Strasbourg, Gynaecology, Strasbourg, France

³CMCO- Hôpitaux Universitaires de Strasbourg, Gynaecology, Strasbourg, France

Background

Background: To compare a multi-use hysteroscopic morcellator and standard resectoscopes in the hysteroscopic management of uterine polyps.

Methods

Methods : single-centre randomised prospective single-blind trial (RESMO Study). Inclusion criteria: single uterine polyp ≥ 10 mm. After obtaining consent, patients were randomised into two groups: group A: morcellation (MH); group B: hysteroscopy resectoscopy (RS). Primary end point: time of morcellation or resection. Secondary criteria: the total operating time (min), the amount of fluid used (ml), the fluid deficit (ml), the number of introduction of morcellator or resectoscope, operator comfort on an EVA of 0 at 10 and the quality of the vision on a scale of 0 to 5, complication rate, synéchiaie rate at the control hysteroscopy 6 weeks after. The statistical analyses were carried out according to the Bayesian methods.

Results

Ninety patients were randomised, 45 in group A and 45 in group B. The mean age of the patients was 54.5 ± 11.22 years (range 26-78). The polyp was found following metrorrhagia in 48% of cases, in the context of infertility in 9% of cases, during a routine ultrasound in 47% of cases. The average size of polyps at hysteroscopy was 16.08 mm. Morcellation time was less than resection time [6, 09 vs 8.98 min; P (MH> RS) = 0.0004, very highly probable]. It is the same for the total operating time [12.21 vs 15.64 min; P (MH> RS) = 0.015, highly probable], the number of morcellator or resectoscope insertions [1.50 vs 5.99; P (MH> RS) = 0, very highly probable], the volume of fluid used [767 vs 1119 ml; P (MH> RS) = 0.006, very highly probable], fluid deficit [60 vs 170 ml; P (MH> RS) = 0.011, highly probable]. Operator comfort was better in the morcellator group [8.43 vs 7.38 min; P (MH> RS) = 0.999, very highly probable] as well as vision quality [4 vs 3.7; P (MH> RS) = 0.911, highly probable]. Five peri-operative complications occurred (5.6%), the five in the group resection (group B): 2 cervical lacerations, perforation during dilatation, fundic pre-perforation with the loop, anaphylactic shock during induction. The difference between the two groups is highly probable P (MH> RS) = 0.011. A control hysteroscopy check was performed in 76 cases (84%); It was informative in 72 cases (95%). It was found a remainder of polyp in 13% of the cases, without difference between the two groups. Minimal synechiaie (grade I) were found in 3 patients (4%), again without any difference between the two groups.

Conclusions

The multi-use morcellator is faster, uses less fluid with less deficit and less introductory manoeuvres with better comfort, better vision, less complications and the same results than resectoscopes for hysteroscopic treatment of uterine polyps.

ES28-0540 - Hysteroscopy

Altered endometrial gene expression profile in women with chronic endometritis: a possible molecular link with infertility and endometrial hyperplastic lesions

Ettore Cicinelli¹, Amerigo Vitagliano², Rossella Cicinelli¹, Pasquale Capuano¹, Paola Traversi¹, Luigi Viggiano¹
¹2nd Unit of Obstetrics and Gynaecology, Department of Biomedical and Human Oncologic Science, Bari, Italy
²University of Padua, Women and Childrens' Health, Padua, Italy

Background

Chronic endometritis (CE) is the chronic inflammation of endometrial lining. During the implantation window, CE alters endometrial expression of paracrine factors involved in the embryo-endometrial crosstalk, impairing the accomplishment of embryo implantation. Few data exist on the effects of CE on endometrial expression of paracrine factors involved in the proliferation of endometrial cells. In a previous study, we found and increased incidence of CE in women with endometrial polyps. In the present prospective, comparative study we compared the endometrial expression of paracrine factors involved in the proliferation and the apoptosis of endometrial cells in women with and without CE.

Methods

15 women in reproductive age diagnosed with CE at hysteroscopy and 15 women with no signs of CE (control group) were included in the study. All women underwent hysteroscopy with endometrial biopsy for the investigation of stromal plasma cells. Plasma cells were identified through conventional histological evaluation with hematoxyline & eosine (H&E) and with CD138 immuno-histochemistry. Bio-molecular evaluation of the endometrium was performed in all women by using high-throughput real-time (RT)-PCR. We investigated the expression of many genes involved in the inflammatory and replicative processes.

Results

Endometrial gene expression profile showed some significant differences in women with CE compared to controls. Specifically, Mann-Whitney U test found that the values of VEGFA, VEGFB, VEGFC, EGF, TNF, TGFB1, IFNG, TP73, BAX, CDC2, CCND3, CCNB1 were considerably different between women with CE and women without CE (all $p < 0.01$ or $p < 0.05$).

Conclusions

In women with CE, the proliferative endometrium displays an altered endometrial expression of some genes involved in tissue inflammation, cell proliferation and apoptosis processes. Such altered endometrial gene expression may explain the pathophysiology of impaired endometrial receptivity in women with CE. Moreover, it may suggest a possible etiopathogenic link between CE and endometrial hyperplastic lesions.

ES28-0296 - ESGE | SERGS Session

Surgical outcomes of single-site robotic surgery in gynaecologic oncology: preliminary single centre study

Jung Hwan Ahn¹, Keun Ho Lee¹, Athithan Rattanaburi¹, Ji Geun Yoo¹
¹Seoul St. Mary's Hospital, ObGyn, Seoul, Korea- Republic Of

Background

We tried to report the surgical outcomes of single-site robotic surgery in gynaecologic oncology.

Methods

Retrospectively reviewed the medical chart of patients who was performed single site robotic surgery in tertiary referral single hospital. Thirteen endometrial, 7 ovarian and 6 cervical cancer patients had a single-site robotic staging surgery via daVinci Xi system between Dec 2016 and Mar 2018.

Results

In 16 endometrial cancer patients, 15 hysterectomy and 13 pelvic and paraaortic lymphadenectomy including 2 sentinel biopsies were performed. All the patients were stage I disease but 2 upgraded to stage IIIC. Seven ovarian cancer patients had staging surgery with 5 lymphadenectomy. In cervical cancer, 3 hysterectomy and 2 lymphadenectomy were performed. Total operating times were 122, 143 and 73 minutes respectively in endometrial,

ovarian and cervical cancer. Mean docking time was 17 minutes. Mean estimated blood loss were 58 cc and mean number of harvested lymph nodes were 19. Hospital stay was 1 day.

Conclusions

Single-site robotic surgery in endometrial, ovarian and cervical cancer patients were relatively safe and comparable to standard robotic surgery. This data showed the preliminary results of single-site robotic surgery and larger comparative study were needed.

ES28-0496 - Oncology 1

The accuracy of target-eye office biopsy in the presurgical staging of endometrial cancer

Giuseppe Bifulco¹, Maria Chiara De Angelis², Luigi Della Corte², Pierluigi Giampaolino³, Fulvio Zullo²

¹University of Naples Federico II,

Department of Neuroscience- Reproductive Sciences and Dentistry- School of Medicine, Naples, Italy

²University of Naples " Federico II",

Department of Neuroscience- Reproductive Sciences and Dentistry- School of Medicine, Naples, Italy

³University of Naples " Federico II", Department of Public Health- School of Medicine, Naples, Italy

Background

Endometrial carcinoma (EC) is considered the most common gynaecologic neoplasia in developed western countries and its incidence has increased in recent years. Dilation and curettage (D&C) was once the gold standard for endometrial sampling, but recent studies have demonstrated that this diagnostic technique blindly scrapes less than 50% of the uterine wall, missing nearly 10% of EC. Nowadays, hysteroscopic endometrial sampling seems to be a better alternative to D&C, since it can be performed in an office setting and allows direct visualisation of the lesion, making target-eye biopsies. The objective is to investigate the diagnostic accuracy of in-office hysteroscopic biopsy performed with miniaturised instruments for presurgical evaluation of 1) hystotype and 2) grading of EC.

Methods

This was a retrospective study conducted on 129 women with a diagnosis of EC, enrolled between January 2015 and December 2018 at the Department of Neuroscience, Reproductive Sciences, and Dentistry of the University of Naples "Federico II". Clinical records of these patients were collected in a dedicate database. All the patient underwent office hysteroscopy performed by vaginoscopic approach, followed by a targeted grasp biopsy as the diagnostic procedure, and received total hysterectomy as the treatment. All patients whose diagnosis or treatment had been performed outside our department were excluded from the study. In order to minimise inter-individual variability among pathologists, we claimed a second look evaluation of discordant biopsy and surgical specimen by a senior expert pathologist. The concordance between grading obtained at hysteroscopy and surgical specimen findings was calculated using *k Cohen*.

Results

In all cases the endometrial specimens obtained in office setting with miniaturised instruments were adequate for an histological evaluation. The agreement rate for the hystotype was 91.2% (104/114) for endometrioid EC and 75% (6/8) for serous-papillary EC. All discordant cases were confirmed at second look evaluation. At first histological evaluation, the concordance was lower for the G1 EC (17/34 cases, 50%), and higher for G2 (35/42 cases: 83%) and G3 (23/28 cases:82%) biopsies. After a second look evaluation, the 29 discordant cases were reviewed, obtaining an increased overall agreement of 96.1% (100/104). *K Cohen* was excellent for all grades of EC ($k = 0.80 - 1$).

Conclusions

According to our findings, pre-operative office target-eye biopsy provides an adequate amount of tissue available for an accurate diagnosis and staging of patients with EC. A skilled pathologist is also needed, mostly for an accurate evaluation of EC grading. Further larger series are required to confirm these preliminary data.

ES28-0015 - Urogynaecology

A national population-based survey of the prevalence, potential risk factors, and symptom-specific bother in symptomatic pelvic organ prolapse in adult Chinese women

Lan Zhu¹, Lei Zhang¹

¹Peking Union Medical College Hospital- Beijing, Department of Obstetrics and Gynaecology, Beijing, China

Background

Few studies have investigated pelvic organ prolapse (POP) at a national level, especially diagnosed in a physical objective examination.

Methods

We conducted a national cross-sectional study from February 2014 through March 2016. A nationally representative sample of 54,000 adults who were 20 years old or older were sampled using multi-stage, stratified, cluster sampling at six populous provinces in mainland China among participants of National Mass Screening on breast and cervical cancers. POP was assessed using Pelvic Organ Prolapse Quantification (POP-Q) stage and validation questionnaires. Multivariable logistic regression was used to assess factors associated with each degree or bother POP.

Results

The prevalence of symptomatic POP (POP-Q stage II or higher) was 9.56%. Stage II POP was the most common (7.52%) and mainly involved anterior compartment. Incidence increased with age for all stages ($P \leq 0.05$). Minor or moderate bother were the most common responses that were reported for every stage of POP (9.72%). Only 0.08% of the participants reported that the condition had a severe impact on their quality of life. Older age, postmenopausal status, and multiple vaginal deliveries increased the odds of every kind of POP ($p \leq 0.05$).

Conclusions

Based on physical objective examination, our study yielded a Lower prevalence than that in other surveys and mainly involved anterior compartment, which suggests that it should be considered for medical intervention. Older age, postmenopausal status, and multiple vaginal deliveries increased the odds of every kind of POP.

ES28-0196 - Neuropelvelogy

Obturator nerve injury in pelvic lymphadenectomy – to stitch or not to stitch?

Peter Kascač¹, Martin Hlavacik¹

¹Faculty Hospital Trencin, Department of Obstetrics and Gynaecology, Trencin, Slovakia

Background

In the presented case report we discuss the necessity of immediate treatment of obturator nerve damage in pelvic lymphadenectomy in the light of new surgical procedures in oncogynaecology, while considering the abilities and possibilities of the self-repair of damaged peripheral nerves.

Methods

Between 2011 and 2018 we performed 482 pelvic lymphadenectomy procedures. 470 cases (97.5%) were laparotomies. In 4 cases obturator nerve was injured (0.8%). In 3 patients, the injury occurred during the laparotomy and the nerve was immediately sutured without any subsequent functional deficiency. We present a case of nerve injury during laparoscopic lymphadenectomy where we did not proceed with the immediate treatment. Despite this, the patient suffered no sensitive or functional impairment, either after surgery or 6 months later. Laparoscopic staging was done due to an early stage ovarian carcinoma in a 67-year-old woman. During the right-sided pelvic lymphadenectomy, the obturator nerve was completely transected. Procedure was completed without further complications however immediate endoscopic treatment of the nerve injury was not possible. After some discussion we forgot the idea of immediate laparotomy. Since the patient did not experience any clinical signs of nerve damage, even after postoperative recovery, we definitely abandoned the idea of treating damaged nerve surgically. We have documented this complication on video.

Results

Obturator nerve is a mixed nerve that has both sensitive and motor component. Nerve can be damaged, or transected during radical hysterectomy, lymphadenectomy, forceps delivery, radical prostatectomy, acetabular and pelvic bones fractures. Damage can also occur due to patient positioning. Rehabilitation therapy is used to treat such nerve damage. It is also recommended that a neurosurgeon be consulted for possibility of nerve suture in unambiguous nerve disruption.

Procedures in oncogynaecology yield to lesions of peripheral nerves in only 1.8-1.9% of cases. Complete repair without further surgery is reported in 73-91% of cases. Case reports of immediate nerve treatment with excellent functional outcome have also been described. However, it is thought that if a functional recovery is seen within six months, dual innervation or accessory nerve branches must be present. Recently, in some super-radical procedures in oncogynaecology (e.g. laterally extended endopelvic resection), intended nerve resection (without treatment) occurs in up to one third of cases. The uncertainties in necessity and technique of nerve damage treatment stems from the anatomical structure of peripheral nerves and their ability to heal and regenerate.

Conclusions

Immediate treatment and its technique, delayed suture or conservative procedure for obturator nerve injury can all yield to the favourite functional outcome. In our case, we have abandoned the idea of nerve suture after laparoscopic lymphadenectomy and the patient showed no clinical signs of nerve damage.

ES28-0364 - Complications in surgery

Laparoscopic intervention after ventriculoperitoneal shunt: a case report, systematic review and recommendations

Morva Tahmasbi Rad¹, Sandra Bogdanyova¹, Juergen Konczalla², Sven Becker¹

¹University of Frankfurt, Department of Gynaecology and Obstetrics, Frankfurt, Germany

²University of Frankfurt, Department of Neurosurgery, Frankfurt, Germany

Background

In patients presenting pelvic pathology and a placed ventriculoperitoneal (VP) shunt, there is uncertainty regarding the decision whether to use laparoscopy. The aim of the paper is to examine the available literature as well as sharing our own experiences operating on a patient with a VP shunt using laparoscopy.

Methods

We searched online libraries (PubMed, EMBASE, and Google Scholar) for all publications published between January 1975 and December 2018 on our topic. We performed a systematic review and also shared our experience with laparoscopy in a patient with shunt and ovarian cancer.

Results

The age of the patients ranged from 1 to 79 years old. The operations were performed by the departments of general surgery, gynaecology and urology. The time from the shunt operation to laparoscopy ranged from 5 days to 28 years. In different articles four important points were considered and discussed: the risk of a shunt infection or complication, technical difficulties carrying out laparoscopy in patients with a VP shunt, the necessity of routine monitoring of the ICP intraoperatively and perioperative strategies to avoid complications.

Conclusions

It seems that a laparoscopic surgery in adults with a VP shunt appears to be a safe option. Based on the results of our case and the review of literature we consider it necessary to have a neurosurgical consult performed prior to surgery, the procedure be carried out by an experienced surgeon and to avoid complications by implementing recommended precautions.

**ES28-0149 -
Miscellaneous**

Surgical removal of Essure® micro inserts by vaginal hysterectomy or laparoscopic salpingectomy with cornuectomy: case series and follow up survey about device-attributed symptoms resolution

Perrine Capmas¹, Margaux Jegaden¹, Anne Gaele Pourcelot¹, Herve Fernandez¹

¹Hopital Bicetre, Gynaecology, Le Kremlin Bicetre, France

Background

Available since 2001, the micro inserts Essure (Bayer, Whippany, NJ, USA) were approved November 4, 2002 by the Food and Drug Administration (FDA) as a minimally invasive birth control method. This hysteroscopic sterilisation had a significant success with over than 750 000 procedures performed due to its easy procedure and its low reported failure rate. Due to reported adverse events, Essure® micro inserts were withdrawn from the market on September 18th, 2017 in Europe. Many women asked for a removal of Essure micro inserts.

Aim of this study is to evaluate the quality of life and device-attributed symptoms resolution after surgical removal of Essure® micro inserts on short and long term. To compare effectiveness and evolution of symptoms between two surgical approaches: vaginal hysterectomy and laparoscopic salpingectomy with cornuectomy.

Methods

This retrospective case series and follow-up survey took place in the gynaecologic department of a teaching hospital. Women who underwent surgical removal of Essure® micro inserts between January 2017 and April 2019 were included. They had or a laparoscopic salpingectomy with cornuectomy or a vaginal hysterectomy and they answered questions about their symptoms before surgery, at 1 month and between 3 and 12 months after surgery. Data regarding women characteristics, preoperative symptoms, insertion procedure, Essure® localisation before surgery for removal of the implants, surgical removal procedure, complications, post removal radiography control, and postoperative symptoms at 1 and between 3 and 12 months after surgery.

Results

Ninety-two women aged 36 to 56 years old had a removal surgery of Essure micro inserts during the study period. Fifty-one vaginal hysterectomies and thirty-six laparoscopic salpingectomies with cornuectomy were performed. Main symptoms reported were: pelvic pain (63.2%), asthenia (57.9%) and abnormal bleeding (44.7%). One month after surgery 52.8% of patient have a complete resolution of symptoms, 44.4% a partial resolution and 2.8% didn't notice any change. Long-term results after surgery are comparable. After vaginal hysterectomy, 51% of women had a complete resolution of symptoms compare to 53.5% in laparoscopic salpingectomy with cornuectomy without any significant difference.

Conclusions

Surgical removal may be effective for treating most women with attributed-device symptoms however, a few numbers of women didn't notice any improvement. For removal techniques, the two surgical approaches by vaginal hysterectomy or laparoscopic salpingectomy seem to be equivalent for the rate of resolution of symptoms.

**ES28-0413 -
Ovarian Cancer**

Comparison of laparoscopy and laparotomy in the surgical management of early-stage ovarian cancer

Nuria Garcia Ginjaume¹, Cristina Soler Moreno², Natalia Teixeira¹, Sara Marín Garrayo¹, Rocío Luna Guibourg², Ramon Rovira Negre²

¹Hospital de la Santa Creu i de Sant Pau, Gynaecology and Obstetrics, Barcelona, Spain

²Hospital de la Santa Creu i de Sant Pau, Gynaecological Oncology, Barcelona, Spain

Background

Objective: To assess the feasibility and survival outcomes of laparoscopic surgical staging for patients with early-stage ovarian cancer compared with laparotomic approach.

Methods

Retrospective observational study including 46 patients who underwent laparoscopy (20 patients) or laparotomy (26 patients) for surgical staging of early-ovarian cancer between 2010 and 2018 in Hospital de la Santa Creu i Sant Pau (Barcelona). We have analysed clinical data and compared surgical and survival results of both approaches.

Results

Forty-six patients with mean age 60 ± 20 years and mean body mass index 22 ± 3 kg/m² were included. Nineteen (41%) were classified as stage IA, 22 (47%) as stage IC, 2 (4%) as stage IIA and 3 (7%) as stage IIB. The histological types included: serous in 16 (35%), mucinous in 5 (11%), clear cell in 10 (22%), endometrioid in 6 (13%) patients and 9 (20%) cases were classified as others, including carcinoid, yolk-sac, disgerminoma, granulosa-cell and seromucinous. Two of the patients who underwent laparoscopy required conversion to laparotomy. The laparoscopy group compared to the laparotomy group had significantly shorter hospital stay (4,8 days vs 9,2 days) and lower complication rate (2% vs 22%). In the laparotomy group 1 patient presented intraoperative vascular injury and another urologic injury. Postoperatively 2 patients presented respiratory infection, 3 urinary infection, 1 haemorrhage, 1 paralytic ileus and 1 asymptomatic lymphocele. In the laparoscopy group no patients presented intraoperative complications and postoperatively only 1 patient presented a symptomatic lymphocele. Intraoperative blood loss tended to be lower in the laparoscopy group (197,1 vs 459,1ml), although the difference did not reach statistical significance ($p=0,07$). The 2 groups did not show significant differences in operative time, number of removed lymph nodes, intraoperative tumour rupture rate, postoperative chemotherapy, recurrence or survival rates. Thirteen patients (28%) presented disease recurrence; 10 of which had undergone laparotomy and 3 laparoscopy. The overall survival rate in the current series was 93% in a median follow-up of 37 months; 2 of the 3 exitus patients had undergone laparotomic surgery and one of them laparoscopic approach.

Conclusions

Laparoscopic staging surgery performed by a trained gynaecologic oncologist is a safe and effective alternative for early ovarian cancer. It has the advantage of minimum invasiveness, providing a shorter hospital stay and faster recovery, whilst preserving the requirements of an optimal surgery and the survival outcomes compared to laparotomic approach.

ES28-0417 - Endometriosis 3

Impact of surgical versus hormonal treatment on recurrence rates in patients with thoracic endometriosis: a systematic review and meta-analysis

Islam Gamaleldin¹, Eveline Internullo², Sanjay Vyas³

¹Southmead Hospital and University of Bristol- UK, Women and Children, Bristol, United Kingdom

²University Hospital Bristol, Thoracic Surgery, Bristol, United Kingdom

³Southmead Hospital Bristol, Women and Children, Bristol, United Kingdom

Background

Management of patients with thoracic endometriosis is challenging because of the lack of national and international guidelines. Combined surgical and hormonal treatment have been proposed, however, there is no consensus. The aim of this systematic review and meta-analysis is to assess the effect of surgical versus hormonal treatment on recurrence rates in patients with thoracic endometriosis.

Methods

Searches were conducted on medline, embase, Cochrane Library and Web of Science (inception, December 2018). Observational studies and case series of more than 10 patients where endometriosis was confirmed histologically were included. Primary outcome was recurrence rates following surgical/hormonal/surgical and hormonal treatment. The Newcastle-Ottawa Quality Assessment Scale was used for quality assessment. Study selection and data extraction was conducted independently by two reviewers. Relative risk from individual studies were meta-analysed.

Results

The search strategy yielded 832 publications, of which 811 were excluded. Twenty-one studies were eligible for meta-analysis including collectively 377 women. The mean age of patients was $35(+/-0.6)$. Chest pain was the presenting symptom in 90% of the patients. Thoracic endometriosis affected the right side in 95% of the cases; bilateral in 4% of cases; and in 1% of the cases it affected the left side. Meta-analysis of these studies showed lower recurrence rates with surgical treatment followed by gonadotrophin-releasing hormone (GnRH) analogues, when compared with either surgical treatment or hormonal treatment alone (relative risk [RR] = 0.93, 95% confidence interval [95%CI] 0.87-0.99, $P = 0.03$).

Conclusions

Surgical treatment of thoracic endometriosis followed by GnRH analogues is associated with significantly lower recurrence rates, when compared to either surgical treatment or hormonal treatment alone.

**ES28-0680 -
Miscellaneous**

Adnexal surgery through transvaginal NOTES

Pedro Brandão¹, Amélia de Almeida¹, Paula Ramôa¹

¹Hospital Lusíadas Porto, Obstetrics and Gynaecology, Porto, Portugal

Background

Natural Orifice Transluminal Endoscopic Surgery (NOTES) is a minimally invasive surgery approach using body natural orifices to access the peritoneal cavity, leaving no visible scars. In spite of being technically challenging, in experienced hands NOTES appears to be a feasible technique to several surgical procedures, with less post operative complications and pain, and better overall patients' satisfaction. There is few published information about pure transvaginal NOTES (vNOTES) for gynaecological procedures. The aim of this study is to review all cases of vNOTES for adnexal procedures the authors have performed, in order to evaluate the security, feasibility, reliability, advantages and disadvantages of this technique.

Methods

The authors reviewed all cases of vNOTES for adnexal procedures performed in Hospital Lusíadas Porto from 2012 till may 2019. Clinical data was evaluated, concerning patients' profile, surgery's indication, surgery details, expected and unexpected complications during or after the procedures, outcomes and patient's satisfaction.

Results

17 patients underwent vNOTES, including adnexectomies, salpingectomies and cystectomies. Only in one case it wasn't possible to go on with the procedures due to patient's intolerance to the pneumoperitoneum, needing open abdominal surgery. All of the other procedures were successfully completed. There were no expected or unexpected complications during procedures. All of the patients needed minimal postoperative analgesia and were discharged the day after surgery. There were no complications after surgeries, including infection, hernia or vaginal wound dehiscence. No patients complained of dyspareunia. One of the patients had spontaneous pregnancy after the procedure with no complications and an uncomplicated vaginal delivery of a healthy child.

Conclusions

Our case series shows that pure vNOTES seems to be a safe and desirable approach to the adnexa, with evident advantages comparing to conventional laparoscopy.

**ES28-0147 -
Innovations**

Transvaginal in-bag specimen extraction of surgical specimens after laparoscopic myomectomy: a feasible and safe alternative to in-bag intra-abdominal morcellation?

Antonio Simone Laganà M.D.¹, Jvan Casarin¹, Stefano Uccella², Paolo Puggina³, Simone Garzon¹, Fabio Ghezzi¹

¹University of Insubria, Department of Obstetrics and Gynecology - "Filippo Del Ponte" Hospital, Varese, Italy

²Ospedale Degli Infermi, Obstetrics and Gynecology Department, Biella, Italy

³Evangelical Hospital - "Villa Betania", Department of Obstetrics and Gynecology, Naples, Italy

Background

We aimed to evaluate the rate of intraoperative and postoperative complications in women undergoing transvaginal in-bag specimen extraction of surgical specimens after laparoscopic myomectomy.

Methods

Retrospective analysis of prospectively collected data, between January 2004 and December 2018. The laparoscopic myomectomy was performed in a standard fashion. After the myoma(s) enucleation, a posterior 1–2 cm transverse colpotomy was performed laparoscopically, precisely in the midline of the posterior fornix. We introduced a 10- or 15-mm polyurethane specimen pouch through the colpotomy incision, opening it into the abdominal cavity. Once the fibroid was placed into the bag using a laparoscopic grasper, the specimen bag was tightened and pulled out for transvaginal removal. In case the fibroid was too large to fit through the colpotomy, we performed in-bag manual morcellation to take the specimen out, until the fibroid pieces were small enough to remove them along with the bag. A careful gross inspection of bag integrity was always performed, filling the bag with saline solution. Subsequently, the colpotomy was closed transvaginally using a running 1-0 polyglactin suture. For each patient, we recorded age, Body Mass Index (BMI), parity, indication for myomectomy, largest myoma size, number of fibroids removed, myoma(s)

total weight, operative time, intraoperative blood loss, hospital stay, intraoperative and perioperative complications, as well as complications found at the 30-days follow-up.

Results

During the study period, we collected 440 consecutive women who underwent transvaginal in-bag specimen extraction of surgical specimens after laparoscopic myomectomy. The study design was approved by an independent institutional review board and each patient signed informed consent to allow data collection for research purpose. The median age was 36 (19–65) years, median BMI was 22 (17–32) and 193 women (61.5%) were nulliparous. Indication for myomectomy was abnormal uterine bleeding in 243 (55.2%) cases, pain in 43 (9.8%) cases and subfertility/infertility in 154 (35%) cases. The median largest myoma size was 7 (3–15) cm, median number of fibroids removed was one (1–5), median myoma(s) weight was 150 (30–800) grams, median operative time was 80 (20–320) minutes, median blood loss was 125 (20–1000) ml. Median hospital stay was 2 (1–7) days. We did not observe any intraoperative complication. In the early post-operative period, we had 21 (4.8%) cases of fever, treated with antibiotics and antipyretics, and 3 (0.7%) cases of minimal haemoperitoneum, which resolved spontaneously after expectant management. We did not observe any complication at the 30-days follow-up, including dyspareunia, vaginal dehiscence/bleeding, need for readmission/reoperation. We did find any case of misdiagnosed malignancy (leiomyosarcoma) or uncertain malignant potential.

Conclusions

Transvaginal in-bag specimen extraction of surgical specimens after laparoscopic myomectomy could be considered a feasible, not expensive and safe alternative to in-bag intra-abdominal morcellation.

ES28-0307 - Miscellaneous

Temporary uterine arteries occlusion in laparoscopic myomectomy

Nerea Montero Pastor¹, Mónica Novelle García¹, Irene López Carrasco¹, Elena Cabezas López², María Miró Matos¹, Enrique Moratalla Bartolomé²

¹University Hospital HM Montepíncipe, Obstetrics and Gynaecology, Madrid, Spain

²University Hospital Ramón y Cajal, Obstetrics and Gynaecology, Madrid, Spain

Background

The aim of this observational retrospective study is to compare results between laparoscopic myomectomies with and without bilateral temporary occlusion of uterine arteries.

Methods

210 women were analysed from April 2009 to April 2019, with growing or symptomatic myomas or with reproductive desire, who underwent laparoscopic myomectomy with or without clipping the uterine and infundibulopelvic arteries. All the laparoscopic myomectomies were performed by the same surgeon.

2 groups were made, one with temporal occlusion of uterine and infundibulopelvic arteries with a titanium laparoscopic clip at the beginning of the surgery (Clip group 73 patients) and a second group where the laparoscopic myomectomy was performed directly, without clipping temporary those arteries (Non-clip group, 137 patients)

Surgical outcomes include operative time, blood loss and complications.

Results

437 myomas were removed during that period, 260 myomas in the non clip group and 177 in the clip group.

The growth of the myoma is the main surgical indication of both groups, but polymyomatous uterus and hypermenorrhoea are more frequent in the clip group. Pelvic pain and reproductive desire indication had the same frequency in both groups. Both groups are homogeneous in age (37,4 years old in clip group vs 38,2 years old in non clip group), BMI (22,3 vs 22,6), blood loss (1,65 grs/dl vs 1,68 grs/dl), myomas size (43,3mm vs 43,4mm) and haemoglobin before surgery (13,4 grs/dl). There are no significant differences in the type of myomas operated. Major type in the clip group are intramural myomas and in the non-clip group are subserous myomas.

Significant differences were found in surgery time (111,2 minutes in clip group vs 96,75 in non clip group). Time is longer in the clip group but the number of fibroids that were removed is also higher (3,45 vs 2,20)

There are no significant differences in blood loss between both groups.

Conclusions

Temporary occlusion of uterine and infundibulopelvic arteries during laparoscopic myomectomy increases slightly the surgery time, but allows to remove a higher number of myomas per patient without increasing the blood loss.

Although further randomised controlled trials are needed to analyse the effect of temporal uterine arteries occlusion in laparoscopic myomectomy

ES28-0385 - Training

Laparoscopic hysterectomy versus vNOTES hysterectomy. Two peas in a pod? An initial comparative study in the UK

Jody Taylor¹, Tara Giacchino¹, Rebecca Karkia¹, Elias Kovoov¹, Abhishek Gupta¹, Ammara Ghaffar¹

¹Darent Valley Hospital, Gynaecology, Kent, United Kingdom

Background

Transvaginal natural orifice transluminal endoscopic hysterectomy (vNOTES) has introduced a fresh approach to hysterectomy, and involves using laparoscopic instruments through the vagina via a single gel port device to perform hysterectomies and/or adnexectomies after pneumoperitoneum is achieved. This provides scar less surgery in patients who would have otherwise been deemed difficult for laparoscopic or open surgery. We believe it has the potential to improve patient outcomes in comparison to laparoscopic hysterectomy (TLH) and aim to evaluate the differences in outcomes one year following the introduction of vNOTES.

Methods

Data from patients undergoing vNOTES hysterectomy and TLH was collected prospectively from Darent Valley and Benenden Hospital over a 12-month period. Data was collated on a private shared drive noting patient demographics, indications for surgery, operation outcomes and patient follow-up for both procedures.

Results

Between January and December 2018, 33 patients underwent vNotes hysterectomy. For comparison, the first 33 patients who had their TLH done by the same 2 consultants performing vNOTES over the same time period were reviewed. The main indication for surgery in the vNotes group was dysfunctional uterine bleeding and in TLH group, pelvic pain and dysmenorrhoea. The highest patient BMI for vNotes was 53. The highest BMI in the TLH group was 43 and this was the only conversion to an open procedure due to restricted views.

The mean operation time was 98 minutes for TLH compared to a significantly lower time of 69 minutes for vNotes but with similar mean intraoperative blood loss of around 250mls. 3 patients in the TLH group and 5 in the vNOTES group had a blood loss equal to or more than 500mls. Both groups had a low post-operative complications rates with minor complications such as urinary tract infections and urinary retention. Only 2 patients were readmitted over a 30-day period in each group and both required conservative treatment. VNotes patients had a VAS pain score of 0 at discharge compared to 1 for TLH. The mean length of stay for the TLH group was 1.5 and 1.4 nights in the vNotes group.

Conclusions

We present a preliminary study on our initial experience of vNOTES vs standard TLH. Our data set is small however points to consider include the following; conversion occurred in a TLH patient; vNOTES allows better surgical access in obese patients and reduces the risks of increased morbidity and longer recovery of open procedures. The operation time was significantly less in vNOTES hysterectomy which is beneficial for the patient and health economy. Results for mean blood loss, post-operative complication rate, readmission rate, VAS pain score and length of stay are similar. We are collecting more data to further improve our results and hope to publish a comparative study in the near future.

VIDEO IN PLENARY (3)

ES28-0156 - Hysterectomy

Three steps to reconstruction of any ureteral defect

Masaaki Andou¹, Shiori Yanai¹, Kiyoshi Kanno¹, Midori Okumura²

¹Kurashiki Medical Center, Gynaecology, Kurashiki-Shi, Japan

²Shirakawa Clinic, Gynaecology, Fukuyama-Shi, Japan

Background

To present 3 ureteral reconstruction methods, the psoas hitch, the Boari flap and ileal interposition to compensate for various degrees of loss of ureteral length due to ureteral endometriosis, accidental intraoperative injury or advanced or recurrent cancer.

Methods

Laparoscopic extensive resection of DIE and the resection of the involved ureter was performed in patients suffering from ureteral stenosis, hydronephrosis and hydroureter. The resection resulted in extensive loss of ureteral length requiring varying degrees of reconstruction of the urinary tract. The type of reconstruction depends on the size of the defect. For smaller defects, we simply reimplanted the ureter into the bladder. For larger defects, the psoas hitch and sometimes a Boari flap methods were applied depending on how much of the ureter needed to be compensated for. In rare cases where there is a great deal of loss of ureteral length, we harvested a graft of the ileum and used this graft in reconstruction with functional end-to-end anastomosis.

Results

The patients were relieved of dysmenorrhea and back pain as a result of the surgery. No stenosis, leakage or regurgitation occurred in any patient. All patients featured in this video presentation gave their consent for their operative footage and patient data to be used for research and educational purposes.

Conclusions

These three techniques allow for the compensation of any size of defect. This technique is primarily used in cases of accidental injury to the ureter, ureteral endometriosis cases and in advance or recurrent cancer cases. These techniques allow for the bladder to be converted into a duct for tension free and sound adaptation.

<https://player.vimeo.com/video/335744427?autoplay=1>

ES28-0398 - Hysterectomy

Challenges when performing laparoscopic hysterectomy in women with BMI ≥ 40

Tina Ngan¹, Julie Vermeer^{1,2}, Darrien Rattray^{1,2}, John Thiel^{1,2}

¹Regina General Hospital, Obstetrics and Gynaecology, Regina, Canada

²University of Saskatchewan, Obstetrics and Gynaecology, Regina, Canada

Background

Obesity has become a worldwide epidemic. In 2016, 15% of women aged 18 and over were obese. In this video, we will review a total of seven potential challenges encountered when performing laparoscopic hysterectomy in women with BMI above 40. These include comorbidities, patient positioning, insufflation of the abdomen, accessory ports placement suboptimal exposure of surgical field, bladder dissection and vaginal cuff closure.

Methods

Management options and technical tips for these challenges are discussed in this video.

Results

n/a (footages from this video are obtained from different patients; they all successfully underwent laparoscopic hysterectomy and had an uneventful recovery)

Conclusions

In conclusion, laparoscopic surgery has numerous benefits over laparotomy, especially in obese patients. Laparoscopic hysterectomy can be safely performed in obese women when the discussed challenges are overcome.

<https://player.vimeo.com/video/336585914?autoplay=1>

ES28-0186 - Miscellaneous

Hysteroscopic approach to septate uterus

Enrique Moratalla Bartolomé¹, Ana Vegas Carrillo de Albornoz², Irene López Carrasco², Elena Cabezas López¹, Nerea Montero Pastor², Monica Novelle García²

¹University Hospital Ramón y Cajal. University Hospital HM Montepíncipe, Obstetrics and Gynaecology, Madrid, Spain

²University Hospital HM Montepíncipe, Obstetrics and Gynaecology, Madrid, Spain

Background

The uterine septum is a müllerian malformation that appears due to a failure in the resorption of the connecting tissue between the two paramesonephric ducts during the uterine development.

The prevalence of this malformation is not clear, but it is described that it ranges between 1-2/1000 and 15/1000 patients.

Septate uterus are usually asymptomatic, but in some patients this kind of anomalies have been related to infertility or adverse obstetrics outcomes as preterm labour, preterm premature rupture of membranes, placental accretism or late miscarriages.

The gold standard for the diagnosis requires the direct visualisation of the cavity by hysteroscopy and the uterine contour by laparoscopy. However, nowadays the precision of the 3D ultrasound images or MRI allow us to identify with accuracy the internal and external shape of the uterus avoiding invasive tests.

The European Society of Human Reproduction and Embryology and the European Society for Gynaecological Endoscopy (ESHRE-ESGE) define the septum as an internal indentation extending >50% of myometrial wall thickness. Depending on the size of the indentation, it could divide partly or completely the uterine cavity and even in some cases we can find a septate cervix or vagina. The treatment of this malformation consists on the resection of the septum. It is only recommended for symptomatic patients with history of bad obstetrics outcomes or infertility. The most suitable approach is the hysteroscopic resection.

Methods

To present the hysteroscopic resection of a uterine septum in two different patients. In both cases hysteroscopies were performed under general anaesthesia using saline solution as distention media. The surgical procedures were performed with the 5mm hysteroscope and a 5Fr bipolar electrode.

Results

In this video we present two cases, the first patient presented a septate uterus with septate cervix and the second one had been diagnosed of a uterine septum associated to a double normal cervix and a vaginal septum. The steps to perform this technique safely and effectively are described in detail.

Conclusions

Hysteroscopic resection of a uterine septum is a safe and effective technique for restoring the normal shape of the uterine cavity in patients with symptomatic septate uterus.

<https://player.vimeo.com/video/336025909?autoplay=1>

ORAL PRESENTATIONS (101)

ES28-0011 -

Free Communication 1

Expression and clinical significance of lncRNA H19 in endometriosis

Songping Liu¹, Hongyan Cui¹, Keqin Hua²

¹Zhenjiang Maternal and Child Health Hospital, Department of Obstetrics and Gynecology, Zhenjiang, China

²Obstetrics and Gynecology Hospital of Fudan University, Department of Gynecology, Shanghai, China

Background

The pathogenesis of endometriosis is not known well and none of the previous theories can explain the etiology of endometriosis completely. Long non-coding RNA (lncRNA) has got much attention in recent years and the related research results have showed a new way to understand the complexity of disease from the dimension of gene expression regulation network. However, there are few reports about lncRNA in endometriosis. In view of this, we used RNA sequencing technology to analyse the transcriptome of endometriosis in the prior study, which indicated that the upregulation of lncRNA H19 was the most obvious in both ectopic and eutopic endometrium. As one of lncRNAs discovered the earliest, lncRNA H19 has achieved remarkable results in other research fields, but rare studies were reported about its expression and clinical significance in endometriosis.

Methods

(1) The expression of lncRNA H19 was evaluated by quantitative real-time reverse transcription polymerase chain reaction (qRT-PCR) in 104 ectopic and eutopic endometrium samples with endometriosis and 50 normal endometrium samples without endometriosis. (2) The correlation between lncRNA H19 expression and clinical factors of endometriosis as well as its value as a potential biomarker of endometriosis were analysed.

Results

(1) The expression of lncRNA H19 in ectopic and eutopic endometrium was significantly higher than that in normal endometrium. (2) High lncRNA H19 expression level in ectopic endometrium was correlated with infertility, recurrence, bilateral ovarian lesions, CA125 level and ARSM stage but not with chronic pelvic pain, cyst size, peritoneal lesions and deep infiltrative endometriosis (DIE). High lncRNA H19 expression level in eutopic endometrium was only correlated with infertility but not with other clinical variables. (3) Receiver operating characteristic(ROC) curves were drawn based on lncRNA H19 expression in ectopic endometrium and these results illustrated a stronger separation between stage III-IV endometriosis patients and the control group than between stage I-II endometriosis patients and the control group, also between endometriosis patients with recurrence and the control group than between endometriosis patients without recurrence and the control group, suggesting that lncRNA H19 has potential value in diagnosis, evaluation and recurrence prediction of endometriosis.

Conclusions

High lncRNA H19 expression level in ectopic endometrium was correlated with infertility, recurrence, bilateral ovarian lesions, CA125 level and ARSM stage, which may play an important role in the development of endometriosis. lncRNA H19 is a potential diagnostic and follow-up biomarker for endometriosis.

ES28-0075 -

Free Communication 1

Circulating exosomal long noncoding RNA-TC0101441 as a non-invasive biomarker for the prediction of endometriosis severity and recurrence

Junjun Qiu¹, Xuyin Zhang¹, Yan Ding¹, Keqin Hua¹

¹The Obstetrics and Gynecology Hospital of Fudan University, Obstetrics and Gynecology, Shanghai, China

Background

Exosomal long noncoding RNAs (lncRNAs) are emerging as novel non-invasive biomarkers for various diseases. However, in endometriosis field, the exosomal lncRNAs have been rarely investigated. This study focused on TC0101441, a novel metastasis-related lncRNA identified by our laboratory and aimed to investigate (1) the involvement of TC0101441 in endometriosis; (2) the presence of TC0101441 in exosomes derived from serum and

peritoneal fluid of endometriosis patients; (3) the potential of circulating serum exosomal TC0101441 as a biomarker for endometriosis.

Methods

Sixty three patients with ovarian endometriotic cysts and thirty control non-endometriotic patients who underwent laparoscopic myomectomy were recruited from 2015 to 2017. The distribution and expression of TC0101441 in ectopic, eutopic and normal endometria was evaluated using fluorescence in situ hybridization (FISH) and quantitative real-time polymerase chain reaction (qRT-PCR). Exosomes were extracted from serum and peritoneal fluid of endometriosis patients and confirmed using transmission electron microscopy (TEM), nanoparticle tracking analysis (NTA) and western blotting. Clinical correlation analysis was performed using chi-square or Fisher's exact tests. Endometriosis recurrence was analysed using Kaplan-Meier method and Multivariate Cox regression model. A predictive model for endometriosis recurrence was established based on significant variables in the multivariate analysis by R version 3.4.3 (<https://www.r-project.org/>), and Harrell's concordance index (c-index) was used to evaluate its predictive efficiency.

Results

We observed that TC0101441 was mainly located in ectopic endometrial stromal tissues using FISH. The qRT-PCR results showed that TC0101441 expression in the ectopic endometria was significantly higher than that in the paired eutopic and normal endometria ($P<0.01$). Additionally, we successfully isolated the exosomes derived from serum and peritoneal fluid of endometriosis patients, which exhibited the round-shaped cystic vesicles (30-150 nm in diameter) and expressed the specific exosomal marker proteins including CD9 and Hsp70. TC0101441 levels in the exosomes derived from serum and peritoneal fluid were elevated in endometriosis than those in controls and significantly correlated to TC0101441 expression in the matched ectopic endometria ($P<0.01$). Moreover, high serum exosomal TC0101441 levels were associated with the clinical characteristics including infertility, chronic pelvic pain, endometriosis severity (stage III/IV) and recurrence ($P<0.01$). Further univariate and multivariate analysis showed that serum exosomal TC0101441 was an independent predictive factor for endometriosis recurrence ($P<0.05$). Of note, a nomogram model we established indicated that serum exosomal TC0101441 exhibited a good predictive value for endometriosis recurrence according to the c-index and the calibration curve which showed that the predicted observations matched the actual observations.

Conclusions

Circulating exosomal TC0101441 can serve as a promising biomarker for the prediction of endometriosis severity and recurrence.

ES28-0321 -

Free Communication 1

Pelvic floor muscle physiotherapy in women with deep infiltrating endometriosis and superficial dyspareunia: preliminary data from a randomised controlled trial

Alessandro Arena¹, Simona Del Forno¹, Valentina Pellizzone¹, Martina Alessandrini¹, Mohamed Mabrouk², Renato Seracchioli¹

¹Sant'Orsola Hospital - University of Bologna, Gynaecology and Human Reproduction Physiopathology, Bologna, Italy

²Cambridge University Hospitals, Endometriosis and Endoscopic Surgery Unit, Cambridge, United Kingdom

Background

Deep infiltrating endometriosis (DIE) is associated with dyspareunia, both superficial and deep. This study aims to assess the effects of pelvic floor muscle physiotherapy (PFMP) in women with DIE on superficial dyspareunia and pelvic floor morphometry, evaluated by 3D/4D transperineal ultrasound.

Methods

A randomised controlled trial was conducted between June 2018 and February 2019 in our academic centre. We recruited nulliparous women never subjected to previous abdominal surgery, with clinical and sonographic diagnosis of DIE experiencing superficial dyspareunia. Women were randomly divided into two groups: one group received 5 individual sessions of PFMP by an experienced physiotherapist (30 min for each session at 1,3,5,8,11 weeks from the first examination) while the other group did not receive any treatment except for standard care. Endometriosis-related symptoms were evaluated by numeric rating scale (0-10) before and after the PFMP, mainly focusing on deep and superficial dyspareunia. Transperineal 3D/4D ultrasound was performed to compare pelvic floor muscles morphometry between the two groups before and after PFMP (or after 3 months for the control group) through the assessment of the levator hiatus area (LHA). The study protocol was approved by the local Ethics Committee.

Results

Thirty women were enrolled in the study: 15 in the study group and 15 in the control group. Baseline characteristics were similar between the two groups for demographic data, endometriosis related-symptoms and localisations of the disease. Women who received PFMP experienced significant improvement of superficial dyspareunia: median pre-treatment 8 (min 4 max 10) vs median post-treatment 3 (min 0 max 8), $p=.003$, while no differences were reported in the control group. Moreover, deep dyspareunia also decreased after PFMP: median pre-treatment 8 (min 0 max 10) vs median post-treatment 4 (min 0 max 10), $p=.026$. LHA at rest evaluated by transperineal ultrasound increased significantly in women who received PFMP (mean pre-treatment $10.5 \pm 2.18 \text{ cm}^2$ vs post-treatment $11.8 \pm 2.34 \text{ cm}^2$, $p=.043$), while no differences were reported in the control group.

Conclusions

Pelvic floor muscle physiotherapy seems to be a valid treatment for superficial dyspareunia in women affected by DIE. Levator hiatus area significantly increased in the study group after treatment, suggesting a possible role for transperineal ultrasound in evaluating pelvic floor muscle in women affected by DIE during pelvic floor muscle physiotherapy.

ES28-0403 - Free Communication 1

Expression of inhibitory receptors among women with endometriosis and concomitant peritoneal adhesions

Monika Abramiuk¹, Ewelina Grywalska², Małgorzata Sobstyl³, Jan Kotarski¹, Jacek Roliński²

¹Medical University of Lublin, 1st Chair and Department of Gynecological Oncology and Gynecology, Lublin, Poland

²Medical University of Lublin, Chair and Department of Clinical Immunology, Lublin, Poland

³Medical University of Lublin, Chair and Department of Gynaecology and Gynaecological Endocrinology, Lublin, Poland

Background

The reasons for the development of endometriosis remain unknown. Inconsistent presentation of the disease may indicate the existence of many pathomechanisms affecting its development. Based on the conducted studies on the interdependence of endometriosis and disorders of the immune system, a number of abnormalities in the immune system have been detected in patients with endometriosis. The aim of the study was to evaluate frequencies of PD-1 or CTLA-4 or CD200 or its ligands positive T CD3⁺ cells (CD4⁺ and CD8⁺) and B cells (CD 19⁺) in peripheral blood of patients with endometriosis and concomitant peritoneal adhesions. The results were compared to patients with endometriosis, but without adhesions and to the control group.

Methods

The study group included 31 patients with confirmed endometriosis and peritoneal adhesions and 23 patients with endometriosis but without peritoneal adhesions. The control group comprised of 20 healthy age- and sex-matched subjects. Material for the study were peripheral blood (PB) samples. Using the flow cytometric analysis we assessed the differences in the frequencies of PD-1-positive T and B lymphocytes between the study groups and healthy individuals.

Results

Patients suffering from endometriosis and concomitant peritoneal adhesions were characterised by a statistically significantly higher percentage of PD-L1 form. In addition, a higher percentage of T lymphocytes expressing the CD200 molecule and a higher percentage of CD4⁺ / CD200R⁺ T lymphocytes were found in this group of patients compared to the remaining patients with endometriosis. The percentage of T lymphocytes expressing the CTLA-4 antigen in patients with peritoneal adhesions and endometriosis was also higher compared to the remaining patients.

Conclusions

The observed higher percentage of T lymphocytes expressing CD200, CD200R and CTLA-4 antigens, as well as higher concentration of percentages of PD-L1 in PB in patients with endometriosis accompanied by peritoneal adhesions, indicates the important role of the molecules involved in negative costimulation in induction of persistence of chronic inflammation within the peritoneum, leading to connective tissue proliferation.

**ES28-0464 -
Free Communication 1**

The incidence of fallopian tube endometriosis in women undergoing operative laparoscopy for pelvic pain

Ceana Nezhat¹, Lauren Ursillo², Vanessa Martinell², Farr Nezhat²

¹*Nezhat Medical Center, MIS, Atlanta, USA*

²*NYU Winthrop Hospital, Minimally Invasive Gynecologic Surgery, Mineola, USA*

Background

Endometriosis is a major and debilitating gynaecological disease affecting 10% of all women of reproductive age. The most common sites of endometriotic lesions are the ovaries, uterosacral ligament and pelvic sidewall. The incidence of fallopian tube endometriosis has been reported to be rare, roughly 3-4%. Given the negative impact on fertility, understanding the occurrence of fallopian tube endometriosis is important for counselling patients. Our objective is to determine the incidence of pathologically proven endometriosis in the fallopian tubes among women with pelvic pain.

Methods

This is a retrospective chart review from July 2015 to June 2018 of all patients who underwent laparoscopic surgery with an endometriosis specialist. Pathology was reviewed for patients with preoperative diagnosis of endometriosis, infertility, chronic pelvic pain and adnexal mass. Patients with diagnosis of cancer or without the diagnoses previously listed were excluded.

Results

Over the 3 years, 444 surgeries were performed and 208 were included in the study. Of the 208 patients, 79.8% (n=166) had endometriosis, of which 22% (n=37) had fallopian tube involvement. Patients with tubal endometriosis were more likely to have severe disease compared to those without. Age, parity, gravity and medical management had no impact on presence or absence of fallopian tube endometriosis.

Conclusions

Contrary to common belief, fallopian tube endometriosis is not uncommon. For patients with endometriosis and pelvic pain, who no longer desire fertility preservation or plan to undergo in vitro fertilization (IVF), performing bilateral salpingectomy should be considered to not only complete endometriosis treatment and improve fertility rates but decrease possible future ovarian cancer.

**ES28-0580 -
Free Communication 1**

Nurse led preoperative surgical consent clinic for advanced laparoscopic and deep infiltrating endometriosis procedures: an evaluation of a new service set-up.

Liz Bruen¹, Caryl Thomas¹, Angharad Jones¹, Richard Penketh¹, Anthony Griffiths¹, Lutfi Shamsuddin¹

¹*Cardiff University Health Trust, Obstetrics and Gynaecology, Cardiff, United Kingdom*

Background

To evaluate the impact of change in clinical practice from bedside consent on day of surgery (DOS) to the introduction of the nurse led preoperative consent clinic within a tertiary endometriosis referral centre. Other tasks also previously performed on DOS such as cross match; bowel preparation; quality of life database questionnaires were also completed as part of this clinic's remit. It has enabled highlighting of potential problems in a timely manner, which could negatively impact the list. The primary outcomes assessed include evaluation of enhanced theatre efficiency; patient satisfaction; safe practice and compliance with General Medical Council (GMC) Consent guidelines.

Methods

A modified Combined Outcome Measure for Risk Communication and treatment Decision making Effectiveness (COMRADE) questionnaire was devised to evaluate patient satisfaction and 100 patients were invited to complete this by telephone consultation which was anonymised.

An interdisciplinary focus group (n=10) consisting of clinical and administrative staff from all areas were interviewed to evaluate the impact of this change on safe practice; compliance with GMC guidance; improved efficiency for list management and trouble shooting.

Results

Preliminary results indicate increased patient satisfaction particularly as many have not been reviewed since initial listing it gave ample time to discuss complex surgical procedure. Compliance with GMC guidelines is now in practice. Addressing consent and other preoperative workup investigations prior to DOS has been identified by both patients and the focus group as less stressful and has been identified as a positive impact on list logistics.

Conclusions

The consent clinic is having a positive impact on patient experience and has decreased the pressure on DOS services both for clinicians and patients. There has been a reported positive impact but this now needs to be expanded to include all patients prior to surgery.

ES28-0587 -

Free Communication 1

Dienogest and endometriomas transvaginal aspiration as an 'interval strategy' before ovarian preservation: a new approach

Elisabetta Micelli¹, Chiara Vacca¹, Maria Elena Rosa Obino¹, Francesca Papini¹, Francesca Vergine¹, Vito Cela¹

¹University of Pisa, Department of Clinical and Experimental Medicine- Division of Gynecology and Obstetrics, Pisa, Italy

Background

Laparoscopic cystectomy is the gold standard for surgical management of ovarian endometriomas. Nevertheless, literature has shown this technique impacts the ovarian function because of the surgical stress. Furthermore, the presence of endometriotic cysts leads to a more difficult follicular aspiration and can impact on oocytes retrieval because of a more difficult follicles detection or a chocolate liquid spilling. Ultrasonography-guided transvaginal cyst aspiration is not recommended as first line of treatment, this technique has in fact shown the 100% recurrence rate. However endometriomas aspiration can represent a safety minimally invasive surgical strategy before ovarian preservation and subsequently radical excision of ovarian and extraovarian endometriosis.

Methods

We treated eight symptomatic women with ovarian mono-lateral single cyst and deep endometriosis undergoing laparoscopic radical surgery, with the desire of ovarian preservation. The median size of ovarian endometriosis cysts was 44.8 mm. All the women were treated with dienogest for three months and after this pharmacologic treatment period all the women underwent ultrasonography-guided transvaginal cyst aspiration. Thereafter we started an ovarian stimulation protocol with gonadotropins and antagonist. After the ovarian pick-up all the women restart dienogest therapy while waiting for definitive surgery.

Results

Median oocyte retrieval rate was 6,62.

Conclusions

Dienogest and ultrasonography-guided endometriomas transvaginal aspiration can be an interval surgical strategy in symptomatic patients waiting for radical surgery in order to preserve their fertility and improve oocytes retrieval.

**ES28-0646 -
Free Communication 1**

Preoperative diagnosis of ureteral medial deviation secondary to deep endometriosis by transvaginal ultrasound examination

Alessandra De Cicco Nardone¹, Carfagna Pietro¹, De Cicco Nardone Fiorenzo¹, Marana Riccardo¹

¹Fondazione Policlinico Universitario Agostino Gemelli-IRCSS,

Scienze Della Salute Della Donna e Del Bambino e Di Sanita Pubblica - Area Salute della Donna, Rome, Italy

Background

Ureteral endometriosis is classified into two types: intrinsic, which infiltrates the muscle and/or mucosal layer of the ureter; and extrinsic, which involves the adjacent peritoneum, uterosacral ligament (USL), and ovary and bowel. Extrinsic ureter involvement has increased in its incidence, secondary to the greater awareness and ability of surgeons to recognise the disease. An optimal surgical management requires that the diagnosis of ureteral extrinsic involvement should be made preoperatively. The objective of this study is to evaluate the accuracy of transvaginal sonography for preoperative detection of ureteral extrinsic involvement.

Methods

This was a prospective study of 111 consecutive patients undergoing surgery for deep endometriosis, evaluated between February 2018 and February 2019 at a tertiary endometriosis Center, Fondazione Policlinico Universitario A. Gemelli, IRCCS Rome, Italy. Preoperative transvaginal ultrasound was performed with ureters evaluation. Medial deviation of the ureter was considered when there was a deviation from the usual path toward the cervix at the level of the cross with uterine artery. Laparoscopy was performed, with identification and examination of the diameter and course of both ureters in the pelvis. The ureter was judged to be pathologically involved by endometriosis when it was freed from the enclosing periureteral tissue responsible for ureteral distortion and medial deviation, with out involvement of ureteral wall. Surgical and histological finding were retrospectively compared with the ultrasonographic preoperative diagnosis.

Results

Both ureters were visualized in all 111 the patients by transvaginal ultrasound. At laparoscopy there was ureter medial deviation in 49 patients. 53 patients were diagnosed ureter medial deviation by TVS and 49 of which were confirmed by the laparoscopy. The sensitivity, specificity of TVS for diagnosing ureter medial deviation were 94%, 88%, respectively. The more frequent endometriosis involved locations was the bowel

Conclusions

In this study we establish a correlation between ultrasound evaluation of ureter course and the risk of ureteral involvement by endometriosis. Therefore, it is strongly recommended that not only the calibre, but also the course of the ureters should be evaluated preoperative before surgery for deep endometriosis, especially in women with bowel localisation of the disease.

**ES28-0083 -
Free Communication 2**

Models to predict unsuccessful endometrial ablation: external validation

Kelly Stevens¹, Iris Muller², Saskia Houterman³, Stevens Weyers⁴, Dick Schoot¹

¹Catharina Ziekenhuis, Obstetrics and Gynaecology, Eindhoven, The Netherlands

²ZGT Almelo, Obstetrics and Gynaecology, Almelo, The Netherlands

³Catharina Ziekenhuis, Education and Research, Eindhoven, The Netherlands

⁴Women's Clinic- Ghent University Hospital, Obstetrics and Gynaecology, Ghent, Belgium

Background

Endometrial Ablation (EA) is a treatment frequently used for complaints of abnormal uterine bleeding. This is mainly due to the low risks, low costs and short recovery time associated with the procedure. On the short term it seems successful, on the long term however, we see decreasing patient satisfaction as well as treatment efficacy. There even is a post-ablation hysterectomy rate up to 21%. Multiple factors seem to influence the outcome of EA. We combined these factors in our previously presented prediction models. These models help counsel patients for failure of EA or surgical re-intervention within 2 years after EA. The models are only internally validated, therefore we designed this study to perform an external validation of these previously presented prediction models.

Methods

We designed a retrospective cohort study, with a minimal follow-up time of 2 years. Data used for external validation was collected from Medisch Spectrum Twente, Enschede and Ziekenhuisgroep Twente, Almelo/Hengelo, both non-university teaching hospitals in the Netherlands. We selected premenopausal women (18+) who had an EA for complaints of heavy menstrual bleeding between January 2010 & November 2012. A total number of 329 patients were eligible for analysis. Used interventions were Novasure (Hologic, Marlborough, Massachusetts, US) and ThermaChoice III (Ethicon, Sommerville, US). Both interventions had the same outcomes according to the literature.

Results

Data-analysis was done by using IBM SPSS statistics software version 21.0 (IBM Corp., Armonk, NY, USA). Final results showed an area under the curve (AUC) of 0.59 for the outcome of failure within 2 years. Variables in this model were dysmenorrhea, low age, parity ≥ 5 and preoperative menorrhagia. The AUC for the outcome of surgical reintervention within 2 years was 0.45. Variables in this model were dysmenorrhea, low age, menstrual duration > 7 days, parity ≥ 5 and a previous caesarean section. In both models the Hosmer-Lemeshow showed no significant difference between the observed and predicted outcome.

Conclusions

The failure-model can be used to predict the outcome of EA within two years. This model can contribute to improve shared decision-making regarding EA in the general population. The reintervention model appeared to be not useful after external validation, but can still be used in our hospital because of previous internal validation. We are working on a big data model that is able to support this most personalised form of patient counselling, so that both prediction models can be used in the general population. Furthermore, we're investigating the influence of prediction-outcomes on the decision-making of both the patient and doctor.

ES28-0110 - Free Communication 2

Clinical prediction of unsuccessful endometrial ablation: random forest vs logistic regression

Liesbet Lagaert^{1,2}, Kelly Stevens^{1,2}, Tom Bakkess³, Malou Gelderblom², Saskia Houterman⁴, Dick Schoot^{1,2,3}

¹*Ghent University, Women's Clinic- Ghent University Hospital, Ghent, Belgium*

²*Catharina Hospital, Department of Obstetrics and Gynaecology, Eindhoven, The Netherlands*

³*Technical University Eindhoven, Department of Electrical Engineering, Eindhoven, The Netherlands*

⁴*Catharina Hospital, Department of Education and Research, Eindhoven, The Netherlands*

Background

Abnormal uterine bleeding is a common complaint in premenopausal women. About one in 20 women experiences complaints of abnormal uterine bleeding. One of the treatment options for this common problem is endometrial ablation (EA). To optimise the counselling of patients with abnormal uterine bleeding, Stevens et al developed a multivariate logistic regression prediction model based on the combined influence of possible predictors on the failure-rate of this procedure.

In recent years different machine learning methods have been sporadically used in the development of clinical prediction models. Potential advantage of the machine learning methods compared to statistical strategies is the possibility of capturing complex, nonlinear relationships in the data. The aim of this study was to compare the performance of the multivariate logistic regression model of surgical re-intervention within 2 years after endometrial ablation (EA) with a multivariate random forest model (machine learning).

Methods

This is a retrospective two-centred cohort study, with a minimal follow-up time of 2 years. Data from Catharina Hospital, Eindhoven and Elkerliek Hospital, Helmond, both non-university teaching hospitals in the Netherlands, were used. Premenopausal women (18+) who have had an EA for heavy menstrual bleeding between January 2004 & April 2013 were included. A total number of 446 patients were eligible for analysis. Used ablation methods were Cavatherm® (Veldana Medical SA, Morges, Switzerland), Gynecare Thermachoice® (Ethicon, Sommerville, US.) and Thermablate EAS® (Idoman, Ireland). Used interventions and other ablation techniques had the same outcomes according to previously published literature.

Data-analysis was done by using IBM SPSS statistics software version 21.0 (IBM Corp., Armonk, NY, USA). The random forest model was trained in MATLAB (2018b) using the TreeBagger function in the statistics and machine learning toolbox.

Results

The prediction model based on a multivariate logistic regression analysis had an AUC of 0.71. The machine learning model had an AUC of 0.63 and an AUC of 0.65 after hyperparameter optimization.

Conclusions

Based on the preliminary results, we can conclude that the random forest model in this case is not better than the logistic regression model to predict the outcome of surgical re-intervention within two years after EA. In summary, the performance of a random forest clinical prediction model is not necessarily superior to a logistic regression model. The performance of each model is influenced by the sample size, the number of predictors, hyperparameter tuning and the linearity of associations.

ES28-0116 - Free Communication 2

Evaluation of hysteroscopic resection of endometrial growth using Myosure in a “see and treat” outpatient setting

Anita Dutta¹, Madhulika Josh², Anita Rao Copipisetty¹, Vidya Thakur¹

¹Broomfield Hospital -Mid Essex Hospital NHS Trust Essex United Kingdom, Gynaecology, Chelmsford, United Kingdom

²Broomfield Hospital- Mid Essex Hospital NHS Trust- Essex. United Kingdom, Gynaecology, Chelmsford, United Kingdom

Background

Innovation in technology has transformed outpatient hysteroscopy service from being simply a diagnostic tool to minimally invasive, time efficient and safe outpatient operative procedure. We introduced the use of myosure to treat endometrial polyps/ fibroid in the outpatient setting.

Objective: to evaluate the efficiency of the Myosure, patient experience and pain score in the outpatient setting.

Methods

A prospective clinical study of women who underwent out patient Myosure resection of endometrial polyp/fibroid between 1st March 2018- 31st March 2019. Women were referred on cancer pathway following postmenopausal bleeding, abnormal bleeding or incidental finding of increased endometrial thickness. Those who were found to have endometrial polyps/fibroid and opted for resection in the outpatient were included in the study. The cervix was infiltrated with 6ml of 2% lignocaine prior to commencing the procedure.

Results

Data entry was undertaken immediately following the procedure. This was collected on printed paper performa. There were 64 Myosure carried out during the period of study of which 50 records were available for analysis.

Indication for referral for hysteroscopy N=50

	PMB-Polyp	Asymptomatic/incidental Endometrial thickness	Abnormal bleeding	Follow up Complex hyperplasia
Number	20	14	14	2
Percentage	40%	28%	28%	4%

Cutting time

	Up to 1 minute	Over 1to 5 minutes	Over 5 minutes	Not Recorded
Number	27	20	1	2
Percentage	54%	40%	2%	4%

Fluid Deficit

	Less than 100ml	100-500ml	500-1000ml	Over 1000ml	Not recorded
Number	13	23	5	2	7
Percentage	26%	46%	10%	4%	14%

Histology

	Benign Endometrial Polyp	Leiomyomy	Complex Hyperplasia	Complex Hyperplasia with atypia	Endometrial cancer
Number		44	3	1	1
Percentage		88%	6%	2%	2%

One procedure was incomplete due to the fluid deficit exceeding 2000mls; no adverse outcome complication or inpatient admission.

Conclusions

Myosure is a hysteroscopic tissue removal system carried out under direct vision, mechanically removes and suction tissue fragments into a trap. This is precise and ensures that the polyp is removed completely. In our study, over half of patients had the cutting time under 1 minute.

Use of normal saline as distension media, minimises risk of complication due to fluid. In our study over 75% of the procedure reported a fluid deficit of less than 500mls. The outcome of our study supports the use of outpatient operative procedure specifically in advanced age the associated medical co morbidities is a high risk for general anaesthetic.

A single visit "see and treat" clinic using Myosure with Aquillex Fluid Management is a clinically effective and safe method of treating endometrial polyps in outpatient.

ES28-0212 - Free Communication 2

Does previous uterine scar(s) affect the outcome of Novasure endometrial ablation for the management of heavy menstrual bleeding? A case-controlled study

Shamma Al-Inizj¹, Neelam Agrawa²

¹Consultant Obstetrician and Gynaecologist, Obstetrics and Gynaecology - South Tyneside NHS Foundation Trust, South Shields, United Kingdom

²South Tyneside Hospital, Obstetrics and Gynaecology, South Shields, United Kingdom

Background

Heavy menstrual bleeding (HMB) is a common gynaecological problem affecting around 20% of women of reproductive age. It has a major adverse effect on the quality of life of many women which accounts for around 15% of all secondary care gynaecological referrals in the UK. Nearly 60% of women were estimated to have a hysterectomy as the first-line management for HMB in the early 1990s, which has dramatically declined due to the availability of the Mirena IUS and first/second generation endometrial ablation techniques.

The impedance bipolar radiofrequency ablation (Novasure) is a second-generation technique, compared with those of the first, is non-resectoscopic and only ablates/destroys the functioning endometrium, thus preventing cyclical endometrial regeneration. It is easier to learn and perform and has lower rates of serious complications with shorter operating times and fewer perioperative adverse effects.

Novasure endometrial ablation has been reported to be very successful in the management of HMB. There is no previous data to indicate the effect of having a scarred uterus on the outcome and performance of this procedure in women with HMB. We have compared women with scarred uterus to those without previous caesarean section (C/S) scar who underwent Novasure ablation for HMB.

Methods

A retrospective case controlled study was conducted on women who underwent ?Novasure endometrial ablation for HMB between November 2015 and December 2018 at South Tyneside hospital. Women with scarred and unscarred uterus were compared and data regarding procedure completion, complications, hospital stay, success rate and failure of procedure necessitating hysterectomy was retrieved.

Results

146 women were included in the study. 26 had previous C/S scars. 18 had one C/S, 5 had two, one had 3 and two had 4 previous C/S scars. A control group of 120 women who did not have a uterine scar was included. 84% of women with scarred uterus, the procedure was completed, the rest of which it was abandoned. 96% of women with unscarred uterus the procedure was completed. Success rate was 68% in the scarred uterus group and 31% needed hysterectomy due to continuing heavy periods or pain. In the unscarred uterus group, 91% (109/120) had a successful procedure and only 6/120 (5%) had hysterectomy due to continuing heavy periods. One woman in the scarred uterus group had uterine perforation (3.8%) needing overnight admission, all the rest of cases were performed as a day procedure.

Conclusions

Novasure endometrial ablation is more successful in women with unscarred uterus compared to those with previous C/S scars with higher procedure completion rate, less complications and less need for hysterectomy for failed procedure.

ES28-0245 - Free Communication 2

Myosure for endometrial polypectomy in the outpatient setting: a retrospective study and cost analysis

Katalin Lastak¹, Urmila Singh¹, Reeta Limbu Subba¹

¹Dartford and Gravesham NHS Trust, Obstetrics and Gynaecology, Dartford, United Kingdom

Background

A study to evaluate and examine the outcomes of the Myosure procedure for polypectomy under local anaesthetic, including cost-effectiveness compared to other routinely offered management.

Methods

A single centre retrospective analysis was completed of all women undergoing a Myosure procedure for polyp removal between November 2016 and April 2019. Data was collected from physical paper records, electronic noting and patient/family feedback questionnaires (including a routine 48-hour telephone follow-up). A variety of outcomes were measured including basic demographics, intraoperative findings, complications and patient satisfaction. An additional cost analysis was conducted comparing the Myosure procedure to next line management (polypectomy under general anaesthetic).

Results

A total of 135 patients were identified from records. Initial presenting complaint to gynaecology clinic was predominantly postmenopausal bleeding (35%), followed by intermenstrual bleeding (18%) and menorrhagia (16%). Successful resections were completed in 131 patients (96%). Four procedures were abandoned due to patient discomfort and a further one due to an unresectable fibroid. Translation from procedural to histological findings was found to be 90%. Seven samples initially identified as polypoid returned as endometrial hyperplasia. The majority of patients suffered no intra- or postoperative complications (69%). 30% of women found that they had controllable pain and bleeding which self-terminated. Two patients accessed emergency services due to heavy bleeding, both of which were controlled with conservative therapies. 114 feedback questionnaires were collected from patients and their next of kin. Of these, 95% were "very likely" to recommend the procedure to others and 5% were "likely" to. The procedure was found to be cost-effective, saving an estimated £41,317 over the 2 years performed.

Conclusions

Myosure presents a cost-effective, low risk alternative to other conventional therapies for polypectomy whilst offering a high rate of patient satisfaction. Further work will focus on creating a "one stop" clinic for endometrial polyps and expanding the service to offer Novasure endometrial ablation under local anaesthetic.

**ES28-0368 -
Free Communication 2**

Hysterectomy after failed endometrial resection and endometrial ablation techniques. Can we predict when ablation will fail?

Christopher Skelly¹, Emma Sheehan², Kathy Niblock³, Mageed Abdelrahman², Keith Johnston²

¹*Obstetrics and Gynaecology, Craigavon Area Hospital, Craigavon, United Kingdom*

²*Antrim Area Hospital, Obstetrics and Gynaecology, Antrim, United Kingdom*

³*Craigavon Area Hospital, Obstetrics and Gynaecology, Craigavon, United Kingdom*

Background

Heavy Menstrual Bleeding is the most common reason for gynaecological consultation in the United Kingdom. We aimed to identify factors that may contribute to failed ablation/resection of endometrium, to improve future patient selection and counselling.

Methods

A retrospective audit was performed for 85 women who underwent hysterectomy in the Northern Health and Social Care Trust, Northern Ireland between January 2012 - December 2018, following a Thermablate™, NovaSure®, or transcervical resection of endometrium (TCRE). Patients were identified by clinical coding department

Results

Mean age at hysterectomy was 43 years (range 35-52), Average body mass index (BMI) was 32 kg/m² (range 22-47). 87% (n=74) underwent a pre-operative pelvic ultrasound scan, of these 32% (n = 24) had fibroids detected. 72% (n=61) underwent endometrial ablation using Thermablate™; 16.4% (n=14) NovaSure®; 2.35% (n=2) Thermablate™ followed by NovaSure®; 2.35% (n=2) had Thermablate™ twice, performed nine months apart; and 7% (n=6) patients had transcervical resection of the endometrium. 47% (n=40) had a trial of Mirena IUS prior to ablation.

Mean ablation to hysterectomy interval was 23 months (range 11-38). The main indication for hysterectomy was heavy menstrual bleeding (75%), followed by pelvic pain (13%), then both heavy menstrual bleeding and pelvic pain (11%). Mean specimen weight at hysterectomy was 183g. Abnormal pathology was confirmed in 70% of hysterectomy specimens (Fibroids 54%, adenomyosis 14% and combined pathology including fibroids, adenomyosis, simple hyperplasia and endometriosis in 32%). Dysmenorrhoea, parity, previous normal vaginal deliveries/caesarean section, BMI and type of ablation did not reach clinical significance in terms of predictive parameters.

Conclusions

When ablation/ resection fails our results demonstrated that the preoperative demographics above were a poor predictor. Associated identified pathologies particularly fibroids and adenomyosis suggests that preoperative diagnosis of these would be valuable in optimising patient selection and counselling.

**ES28-0425 -
Free Communication 2**

Will hysteroscopic morcellation be the death of resection?

Christine Foster¹, James Moohan²

¹*Antrim Area Hospital- Northern Ireland, Gynaecology, Belfast, United Kingdom*

²*Altnagelvin Hospital, Obstetrics and Gynaecology, Londonderry, United Kingdom*

Background

The introduction of 2nd and 3rd generation endometrial ablation devices resulted in a dramatic fall in the number of endometrial resections/ablations performed for the treatment of heavy periods. The recent introduction of hysteroscopic morcellation devices for the treatment of endometrial polyps and fibroids may lead to a further reduction in the number of hysteroscopic resection procedures performed, so that such procedures become the domain of an ever decreasing number of gynaecological endoscopists. An inevitable consequence of these changes in practice is that trainees and future consultants will gain less exposure and experience in hysteroscopic resection procedures.

Methods

An anonymised questionnaire survey was distributed via survey monkey to all trainees in the Northern Ireland deanery and practising members of the Ulster obstetric and gynaecological society.

Results

A total of 60 gynaecologists completed the questionnaire. 70% of the respondents were consultant gynaecologists, 20% trainees and 10% non-consultant specialists. Less than half of the respondents actually performed outpatient hysteroscopy. Of those performing outpatient hysteroscopy, the preferred method of entry to the uterine cavity was a vaginoscopic approach in 47%. Of those performing outpatient hysteroscopy only 35.7% were operative. Of the operative procedures 76.5% were for small polyps or fibroids (Wamsteker type 0/1), 17.6% ablation and only 3.9% were for large polyps or fibroids (Wamsteker type 2 or more). Surprisingly the chosen method for treating small polyps or fibroids was blind avulsion in 48% with 28% being treated by morcellation and 24% by resection. Premedications were only given in 23% of patients. Although saline was used in 96.3% of cases to distend the uterine cavity, electrolytes were only checked in 28% of cases. a fluid management system was used in 60% of cases.

Conclusions

It is clear that hysteroscopic morcellation is now the preferred method of treatment for intra-cavity polyps and fibroids. This will inevitably lead to trainees gaining less exposure to hysteroscopic resection. Indeed it is possible that trainees will not ever see hysteroscopic resection. As the current hysteroscopic resectionists reach the end of their careers there is a danger that this skill will become the domain of a few and this will have inevitable consequences for patients. It is imperative that training programmes ensure that a dedicated number of trainees are encouraged to learn the skills of resection and that programmes are designed to facilitate adequate exposure to resection procedures on both simulators and patients.

ES28-0461 - Free Communication 2

Outpatient endometrial ablation - outcomes and patient satisfaction

Ayesha Ajmi¹, Sangeeta Das¹

¹Bolton Foundation NHS Trust, Obstetrics and Gynaecology, Bolton, United Kingdom

Background

Heavy menstrual bleeding affects one in five premenopausal women and significantly impairs quality of life. There is evidence to offer endometrial ablation as a first choice surgical option for the management of heavy menstrual bleeding. Bipolar radiofrequency endometrial ablation is the most widely used second generation device in the UK. Endometrial ablation in outpatient setting is associated with shorter hospital stay, quicker recovery, avoidance of anaesthesia and reduced cost. The primary outcome of the study was completion of procedure and acceptability of outpatient endometrial ablation; secondary outcome measures were pain during the procedure, the need for rescue analgesia and complications.

Methods

This prospective audit was conducted in outpatient women's health treatment clinic of a large district hospital in UK between March 2015 and July 2017. The audit was registered with the clinical effectiveness unit of the hospital. This audit was conducted in women with heavy menstrual bleeding who agreed to have outpatient endometrial ablation under local anaesthetic. Preparation for outpatient procedure includes analgesia and breakfast at home. Patients are given informative leaflets prior to the procedure. They are given paracervical block for local anaesthesia. Data of patients undergoing outpatient endometrial ablation with bipolar radiofrequency device Novasure® was entered prospectively by the operators and analysed by the author on Microsoft excel sheet

Results

151 cases were performed in the outpatient setting. 100% of women of outpatient endometrial ablation (OAE) had analgesia at home and 9% were given rescue analgesia.

Cervical block with 3% mepivacaine was used in all cases. Once initiated, the procedure was completed in 100% cases. The median time for procedure was 78.5 seconds with range (34-120 sec). The median intraoperative pain score was 8 (range 0-10). The median immediate post op pain score was 2, with range 0-9. On post op hysteroscopy, cavity was intact in all. Post op analgesia was required in only 2% cases. 89% were discharged immediately, 10 % had to be rested and observed for 30-60 min. None had serious complications. 90 % were satisfied

with outpatient service and would recommend to friends and family. 10% preferred GA for future hysteroscopy procedures.

Conclusions

Outpatient endometrial ablation is successful and highly acceptable with minimal risks and complications. The development of newer (second generation) endometrial ablative techniques has enabled clinicians to set up a comprehensive outpatient service to treat heavy menstrual bleeding effectively without the need for general anaesthetic or conscious sedation.

ES28-0553 - Free Communication 2

Preoperative treatment with Ulipristal Acetate (UPA) before outpatient hysteroscopic resection of submucosal uterine myomas: a prospective comparative study

Simone Ferrero¹, Carolina Scala¹, Fabio Barra¹

¹IRCCS Ospedale Policlinico San Martino- University of Genoa, Academic Unit of Obstetrics and Gynecology, Genoa, Italy

Background

Outpatient hysteroscopic myomectomy can be usually performed in case of single submucosal myoma with largest diameter up to about two centimetres. The volume of the myoma has a critical role in outpatient myomectomy because larger myomas require a longer resection time and, thus, these procedures may be less tolerated by the patients. One of the major advantages of some preoperative therapy is to decrease the volume of uterine myomas.

Methods

This prospective non-randomised study included patients of reproductive age requiring hysteroscopic resection of single FIGO type 0-1 myoma with largest diameter <2 cm. The indications for surgery were: heavy menstrual bleeding, infertility and/or recurrent miscarriages. Exclusion criteria for the study were: previous surgical treatment of uterine myomas, previous administration of hormonal therapies for uterine myomas (UPA, gonadotropin releasing hormone antagonists), additional endometrial conditions requiring hysteroscopic treatment (such as uterine polyps and synechiae) and suspicion of malignancy. Study patients underwent either preoperative treatment with UPA (5 mg/day) for 3 months or immediate surgery (without preoperative hormonal therapy) using the electrosurgical Versapoint system (Gynecare, Ethicon Inc., NJ, USA). The choice of using preoperative treatment was based on patients' preference. All patients underwent transvaginal ultrasonography (TVS) at our institution before the surgical treatment; patients receiving UPA underwent TVS before starting the hormonal treatment and in the interval between the completion of the hormonal treatment and the surgical treatment.

Results

Overall, 83 patients were included in the study; 38 were treated with UPA and 45 underwent hysteroscopic myomectomy without receiving preoperative UPA treatment. At baseline the characteristics of the myomas were similar in the two study groups. UPA treatment caused a significant reduction in the volume of uterine myomas (baseline, $1.5 \pm 1.0 \text{ cm}^3$; after 3-month treatment, $1.2 \pm 0.8 \text{ cm}^3$; $p < 0.001$). At the completion of the 3-month treatment, the mean (\pm SD) reduction in myoma volume was 21.0 % ($\pm 10.1\%$). However, before surgery, there was no significant difference in myoma volume between patients treated with UPA ($1.2 \pm 0.8 \text{ cm}^3$) and those who underwent direct surgery ($1.5 \pm 0.9 \text{ cm}^3$; $p = 0.246$). The percentage of complete resection was significantly higher in patients treated with UPA (34/38; 89.5%; 95%CI, 75.2%-97.1%) than in those who underwent direct surgery (31/45; 68.9%; 95%CI, 53.4%-81.8%) ($p = 0.046$). Preoperative UPA treatment decreased the operative time ($p = 0.031$) and the volume of fluid infused ($p = 0.028$) but it did not significantly affect the volume of fluid absorbed ($p = 0.013$).

Conclusions

This is the first study investigating the use of preoperative hormonal therapy in patients undergoing outpatient hysteroscopic myomectomy. This study suggests that UPA improves the surgical outcomes, particularly the rate of single-step complete resections.

**ES28-0058 -
Free Communication 3**

Misoprostol as a haemostatic agent in laparoscopic myomectomy: can it fill the gap of the condemned-in many countries-vasopressin?

Athanasios Protopapas¹, Nikolaos Kathopoulos¹, Ioannis Chatzipapas¹, Stavros Athanasiou¹, Themistoklis Grigoriadis¹, Dimitrios Loutradis¹

¹Endoscopic Surgery Unit, 1st Department of Obstetrics & Gynecology Medical School National & Kapodistrian University of Athens, Athens, Greece

Background

Myomectomy is a common procedure in gynaecological surgery and it may be associated with considerable blood loss. We conducted this study to investigate whether vaginal misoprostol is an effective and safe haemostatic agent when administered an hour before laparoscopic myomectomy and compare it with a) intraoperative administration of vasopressin and b) no medical pre-treatment

Methods

We included 200 patients undergoing laparoscopic myomectomy (-ies) in a Gynaecologic Endoscopy Unit of a tertiary University Hospital. Of these, 50 were operated one hour after vaginal application of 400mg of misoprostol (group 1), 100 treated with intraoperative intra-myometrial injection of dilute vasopressin (20IU/100mls normal saline) (group 2) and 50 were treated without use of any vasoconstrictive agent (group 3). A retrospective comparison of prospectively collected data spanning a period of 8 years (2011-2019) was performed

Results

We compared group 1 with group 2 and 3 in terms of size, type, and number of fibroids, estimated blood loss (EBL), procedure length (PL), transfusion rates, laparo-conversion rates and rates of complications. No laparo-conversions occurred in group 1 and 2, vs. 2 (4%) in group 3. Overall, mean EBL was 179.7mls in group 1, compared with 147.8mls in group 2 ($p=0.793$) and 321.8mls in group 3 ($p=0.003$). EBL was significantly higher in all 3 groups with increasing size and number of fibroids and in cases with intramural tumours. In general, mean EBL was higher in group 1, compared with group 2 and significantly less compared with group 3, in the majority of patient subgroups. Average length of procedure did not differ significantly between the 3 groups (127.9 vs. 100.6 vs. 130.8 minutes, respectively). Risk factors for prolongation of the procedure were size and number of fibroids, independently of the use of a haemostatic agent or not. Rates of hypercapnia (HPC) in particular and subcutaneous emphysema (SCE) were less in group 1 compared with both group 2 and 3. Risk factors for HPC and SCE included size and intramural position of the largest fibroid. Neither misoprostol nor vasopressin were associated with serious adverse events.

Conclusions

Misoprostol may be an effective and safe alternative to vasopressin in patients undergoing laparoscopic myomectomy. Although on average blood loss is increased compared with vasopressin, it is still significantly less compared with that observed when no haemostatic agents are used. The decreased rates of HPC may be explained by the drug's pharmacokinetics leading to a sustained uterine contraction

**ES28-0040 -
Free Communication 3**

Improvement in 24-month health-related quality of life and work productivity after ultrasound-guided transcervical, intrauterine radiofrequency ablation of uterine fibroids in the SONATA pivotal IDE trial

David Toub¹, Elizabeth Brooks², Gretchen Makai³

¹Gynesonics, Medical Director, Wyncote, USA

²TTi Health Research & Economics, n/a, Westminster, USA

³Christiana Care Health Services, Obstetrics and Gynecology, Newark, USA

Background

To establish the long-term improvement in health-related quality of life and work productivity after use of ultrasound-guided transcervical, intrauterine radiofrequency (RF) ablation in the treatment of symptomatic uterine fibroids.

Methods

Premenopausal women between the ages of 25 and 50 with heavy menstrual bleeding secondary to fibroids treated prospectively with transcervical RF ablation using the Sonata® system in a prospective, multicentre, single-arm clinical trial (the SONATA trial) at 22 clinical sites (21 in the in the US and 1 in Mexico). The EuroQOL EQ-5D-3L (which measures health utility) and Work Productivity and Activity Impairment (WPAI) surveys were administered at baseline, as well as at 24 months post-intervention. Paired t-tests were conducted to evaluate improvement in health utility and work productivity from baseline through 24 months.

Results

One hundred forty-seven (147) patients were enrolled and followed through 24 months. Mean patient health utility significantly increased from 0.72 at baseline to 0.89 ($p < 0.0001$). In addition, the WPAI measured statistically significant improvement in all 4 components of work productivity from baseline to 24 months post-procedure: absenteeism decreased from 2.9% to 1.3%; presenteeism decreased from 50.0% to 13.2%; overall work impairment decreased from 50.9% at baseline to 13.8%; impairment in daily activities decreased from 57.9% at baseline to 13.2% (all $p < 0.0001$).

Conclusions

Ultrasound-guided transcervical, intrauterine RF ablation with the Sonata system was shown to significantly increase patient health utility and work productivity during the first 24 months post-treatment.

ES28-0200 -

Free Communication 3

Identification of the patient demographic, clinical and imaging characteristics that affect short-term outcome following laparoscopic myomectomy

Alison Amoah¹, Stephen Quinn¹

¹Imperial College NHS Trust, Obstetrics and Gynaecology, London, United Kingdom

Background

Fibroids are a heterogenous condition. Anatomical variances in clinical fibroid presentation can vary between patients massively, with variations in size, number, topographical position and axial location. Although fibroids are frequently mapped with imaging, the ideal criteria for patient case selection for laparoscopic myomectomy remains undefined. Increasingly patients are opting for this approach as a minimally-invasive fertility-sparing treatment of their fibroids. It is important that these factors are identified in order to minimise complications and subsequent reintervention. The aim of this study was to identify the patient demographic, clinical factors and fibroid imaging characteristics that impact upon operating time, estimated blood loss and length of stay following laparoscopic myomectomy.

Methods

The study design was a retrospective case series. 118 patients were identified that underwent laparoscopic myomectomy at a single tertiary centre hospital between 2015 and 2019. Data was collected regarding patient demographics, clinical history, preoperative fibroid imaging characteristics and operation procedure and outcomes that include operative time, estimated blood loss and postoperative length of stay. Descriptive statistics including ANOVA for categorical variables and Pearson's correlation for continuous variables were carried out. Hierarchical multiple regression was then carried out on factors identified as being statistically significant on univariate analysis. Statistical significance was defined as $p < 0.05$.

Results

Preoperative uterine gestational size ($p < 0.0001$), uterine inferior-superior length ($p < 0.0001$), fibroid number ($p = 0.003$), dominant fibroid location ($p = 0.026$) and dominant fibroid size ($p < 0.001$) all were significantly associated with increasing operative time. After multivariate analysis, only uterine gestational size ($p = 0.017$) and number of fibroids ($p = 0.012$) were significant. Patient age, race, body mass index, parity, predominant symptom, history of ablative therapy, previous caesarean section, previous laparotomy, submucosal involvement of fibroid, dominant fibroid FIGO score and imaging evidence of adenomyosis, degeneration or calcification were all not significantly associated with operative time.

Preoperative gestational size ($p < 0.001$), uterine inferior superior length ($p < 0.0004$) and dominant fibroid size ($p < 0.009$) were all significantly associated with increasing estimated blood loss. After multivariate analysis, only

uterine gestational size ($p < 0.0001$) was significantly associated. No patient demographic or imaging characteristics were statistically associated with increasing length of stay on univariate analysis.

Conclusions

We have identified some important patient clinical and imaging factors that are associated with increasing operative time and estimated blood loss at laparoscopic myomectomy. Identification of these factors will allow improved patient counselling preoperatively. Additionally, there is a role for identifying these factors as contributing to increased surgical complexity because of the impact on surgical training and scheduling of operating lists.

ES28-0255 -

Free Communication 3

Transvaginal in-bag specimen extraction after laparoscopic myomectomy seems to reduce postoperative hospital stay compared to transumbilical in-bag specimen morcellation

Rocco Guerrisi¹, Antonio Simone Laganà¹, Jvan Casarin¹, Ciro Pinelli¹, Giuseppe De Francesco², Fabio Ghezzi¹

¹University of Insubria, Department of Obstetrics and Gynecology - "Filippo Del Ponte" Hospital, Varese, Italy

²Evangelical Hospital "Villa Betania", Department of Obstetrics and Gynecology, Naples, Italy

Background

To compare intra- and postoperative surgical outcomes between transvaginal in-bag specimen extraction and standard transumbilical in-bag specimen morcellation after laparoscopic myomectomy.

Methods

Retrospective analysis of prospectively collected data, between January 2004 and December 2018. The laparoscopic myomectomy was performed in a standard fashion. We subdivided patients into two groups: one underwent transvaginal in-bag specimen extraction; the other underwent standard transumbilical in-bag specimen morcellation. A careful gross inspection of bag integrity was always performed for both groups, filling the bag with saline solution. For each patient, we retrieved data about age, Body Mass Index (BMI), largest myoma size, myoma(s) weight, operative time, intraoperative blood loss and hospital stay. The study design was approved by an independent institutional review board and each patient signed informed consent to allow data collection for research purpose.

Results

During the study period, we collected a total of 453 women who underwent laparoscopic myomectomy. Transvaginal in-bag specimen extraction was performed in 314 women and standard transumbilical in-bag specimen morcellation was performed in 113 patients. In the transvaginal group, the mean age was 35.7 ± 6.7 years and mean BMI was 22.5 ± 2.7 . The mean largest myoma size was 67.5 ± 18.9 mm, mean myoma(s) weight was 171.4 ± 109.3 gr, mean operative time was 79.7 ± 32.1 minutes, and mean blood loss was 167.8 ± 154.1 ml. The median hospital stay was 2 (1–7) days. In the transabdominal group, the mean age was 36.8 ± 5.9 years and mean BMI was 24.1 ± 4.5 . The mean largest myoma size was 63.8 ± 22.7 mm, mean myoma(s) weight was 169.5 ± 152.6 gr, mean operative time was 75.9 ± 29.4 minutes and mean blood loss was 181.9 ± 165.2 ml. The median hospital stay was 3 (1–7) days. The hospital stay was significantly reduced ($p < 0.001$) in the transvaginal group respect to the transabdominal one, in a median of one day. We did not find significant differences for all the other analyzed parameters (age, BMI, largest myoma size, myoma(s) weight, operative time, intraoperative blood loss).

Conclusions

The transvaginal in-bag specimen extraction after laparoscopic myomectomy seems to reduce the hospital stay.

**ES28-0465 -
Free Communication 3**

Rate of leiomyosarcomas morcellation during surgery for uterine fibroids: 8-year experience of a single centre

Dimitrios Tsolakidis¹, Dimitrios Zouzoulas¹, Panagiotis Pappas¹, Olia Pavlidi¹, George Pados¹, Grigoris Grimbizis¹
¹Papageorgiou General Hospital, 1st Department of Obstetrics & Gynecology - AUTH, Thessaloniki, Greece

Background

Uterine fibroids are the most common neoplasms that arise from the female genital tract. The majority of them are benign and often the surgical approach of choice is laparoscopic myomectomy with morcellation. Recently, fibroid morcellation has become a controversial issue, due to the risk of unintended morcellation of an occult malignant mesenchymal tumour (endometrial stromal sarcoma and leiomyosarcoma) and the possible spread of cancerous cells in the peritoneal cavity. The aim of this study is to investigate the prevalence of occult potentially malignant and malignant mesenchymal tumors, in patients operated for uterine fibroids, in relation to the surgical approach (open or laparoscopic) and the type of operation, to identify the potential risk of fibroid's morcellation.

Methods

We retrospectively reviewed the medical records of all patients that underwent surgery with the indication "uterine fibroids" between January 2011 and December 2018). The surgical approach and the clinicopathological characteristics were described.

Results

A total of 914 patients were operated: 219 (24%) of them by laparoscopy, 680 (74,4%) by laparotomy and 15 (1,6%) vaginally. Overall, 3066 uterine fibroids were removed: 436 (47,7%) patients had solitary and, 478 (52,3%) multiple uterine fibroids. The mean patient's age was 44,85 ± 8,85 years old. Laparoscopy was offered to younger patients with fewer and smaller uterine fibroids and was associated with statistically significant shorter hospital stay. Furthermore, 478 (52,3%) patients underwent hysterectomy and 436 (47,7%) myomectomy, with statistically significant younger patients, fewer and smaller uterine fibroids and also shorter hospital stay in the myomectomy group. The most common location, 546 (59,7%) was intramural, almost equally distributed as anterior, posterior or fundal. The pathological reports revealed: 778 (85,1%) benign leiomyomas, 39 (4,3%) cellular leiomyomas, 36 (3,9%) degenerated leiomyomas, 27 (3%) adenomyomas, 22 (2,4%) atypical-bizarre leiomyomas, 1 (0,01%) STUMP, 5 (0,55%) endometrial stromal sarcomas and 6 (0,65%) cases of leiomyosarcomas. The mean age of women with LMS was 65,83 ± 13,54 years old, the mean diameter of the tumour was 104 ± 52 mm and all presented as solitary "fibroids". All LMS cases were preoperatively characterised as suspicious and underwent abdominal hysterectomy (laparotomy). Morcellation was used only in two cases of atypical leiomyomas (bizarre and STUMP), with no morcellation associated complication.

Conclusions

Laparoscopy is a valuable surgical approach for young patients with less in number and diameter fibroids, associated with shorter hospital stay. The risk of unintended morcellation of LMS seems to be very low and can be eliminated with careful preoperative work-up.

**ES28-0518 -
Free Communication 3**

Examination of parasitic myoma which were underwent surgery at our hospital

Shiori Takeuchi¹, Mari Kitade¹, Yukiko Okada¹, Keisuke Murakami¹, Yu Kawasaki¹, Jun Kumakiri²
¹Juntendo University School of Medicine, Obstetrics and Gynecology, Tokyo, Japan
²Tokyo Women's Medical University, Obstetrics and Gynecology, Tokyo, Japan

Background

Parasitic myoma (PM) is a tumour in which uterine myoma that have lost continuity with the uterus engraft at other sites and acquire and grow feeding vessels. Iatrogenic PM is considered to develop with a part of the fibroid tissue fragment that has been minced by a motorised morcer during laparoscopic myopectomy (laparoscopic myomectomy (LM)) remaining in the abdominal cavity. In order to understand the characteristics of PM, retrospective examination was performed on 18 cases of PM operated at our department.

Methods

We examined 18 patients with PM who underwent surgery for 9 years from April 2010 to March 2019, and examined the patient's background, surgical findings and postoperative course.

Results

Of the 18 cases, 15 cases (83.3%) had LM history, 2 cases (11.1%) had PM resection history, and the median time from onset of LM was 92 months (range 22-143 months). Symptoms of PM were noted in 6 cases (33.3%), including 4 cases of abdominal pain (22.2%) and 2 cases of feeling of mass (11.1%). There were 2 cases (11.1%) who underwent emergency surgery due to acute abdominal disease, but 1 case each had PM torsion and infection. There are 9 cases (50%) where multiple PM were observed. The localisation of PM was 9 cases of vesicouterine excavation, 8 cases of abdominal wall (2 cases of port part, 6 cases other than port part), 5 cases of Douglas's pit, 2 cases of Pervic side wall, 2 cases of broadligament, 3 cases of peritoneum (1 case of sigmoid, 2 cases of ileum), 1 case of rectum, liver surface and greater omentum. Adhesion around PM was observed in 8 cases (44.4%), and the adhesion organs was 2 rectum, 5 colon, 2 ileum, 4 omentum, 3 peritoeum and 1 ovarian duct. There were no complications at the time of PM resection, and all cases had a favourable postoperative course.

Conclusions

Although it is difficult to completely prevent PM, it may be necessary to perform an emergency operation due to stem torsion or infection, so it is important to reduce the incidence of PM as much as possible by devising the recovery of myoma nucleus at LM.

ES28-0528 - Free Communication 3

Retrospective case-control study investigating clinical, imaging and procedural risk factors for infective complications post-uterine fibroid embolization

Josephine Mollier¹, Alison Amoah¹, Neeral Pate², Mohamad Hamady², Stephen Quinn¹

¹St Mary's Hospital, Obstetrics and Gynaecology, London, United Kingdom

²St Mary's Hospital, Interventional Radiology, London, United Kingdom

Background

An important complication of uterine fibroid embolisation (UFE) is intrauterine infection, occurring in up to 17% of procedures. Around 0.25-1.6% of UFE patients develop overwhelming sepsis requiring emergency hysterectomy. Some investigators have suggested that factors such as size of fibroid, uterine volume, submucosal fibroid location or quantity and type of embolisation agent used may affect the risk of infection, but the risk factors for post-procedure infection and progression to sepsis are not fully understood. This study aimed to determine the clinical, imaging and procedural risk factors which significantly impact upon the risk of post-UFE intrauterine infection.

Methods

A retrospective case-control study of 336 UFE procedures between January 2013 and December 2018 was conducted at a single centre. Cases were patients who developed post-procedure infection, and controls were the background UFE population without infection. Infection was distinguished from post-embolisation syndrome by the presence of a high-grade fever and symptom presentation or persistence more than 10 days post UFE. Descriptive statistics were undertaken. Univariate (Chi squared test of independence) and multivariate logistical regression were used to analyse age, parity, ethnicity, presenting symptoms, size and type of particles used for embolisation, dominant fibroid size and type, fibroid number, endometrial involvement and uterine volume as possible predictors for infection. Anterior wall fat thickness measurement on MRI was used as a surrogate for BMI.

Results

Infection occurred after 25 procedures (7.5%). Three patients required emergency hysterectomy due to sepsis (0.9%). Post-UFE infection was associated with clinical obesity (OR 3.5, 95% confidence interval: 1.4–8.6) and uterine volume greater than 1000cm³ (OR 3.0, 95% confidence interval: 1.2–7.7). No other factors including large dominant fibroid or increased amount of embolisation agent used were significantly associated with post-procedure infection. All three emergency hysterectomy patients were clinically obese, and two out of three had uteri greater than 1000cm³ in volume.

Conclusions

Obese patients and patients with large volume uteri may be at increased risk of post-UFE infection. These patients therefore require pre-procedure counselling of their infection risk and thorough post-procedure follow-up to diagnose infection early. BMI and uterine volume should be routinely assessed in UFE patients to assess infection risk. Future work could involve investigation of the efficacy of pre-procedure prophylactic antibiotics.

ES28-0643 -

Free Communication 3

Single layer suturing in intracapsular myomectomy of intramural myomas is sufficient for a normal wound healing

Stamatios Petousis¹, Yannis Prapas¹, Panagiotis Xiromeritis¹, Konstantinos Ravanos¹, Nikolaos Prapas¹

¹Iakentro, Infertility Treatment Center, Thessaloniki, Greece

Background

Laparoscopic intracapsular myomectomy (LIM) as well as laparoscopically assisted intracapsular myomectomy (LAIM) represent two alternative procedures to perform minimally invasive myomectomy. However, in both type of surgeries, the debate Single-Layer versus Double-Layer Closure in order to avoid a uterine rupture during future pregnancy, labour or delivery still remains a matter of discussions in many congresses. Main objective of the study was to evaluate all postsurgical parameters and compare the two methods in terms of efficacy and safety.

Methods

A prospective cohort study was conducted between January 2010 and December 2018 in order to evaluate the short and long term outcomes after a laparoscopic (LIM) or laparoscopic assisted intracapsular myomectomy (LAIM). The number, size and location of myomas as well as the demographic characteristics such as woman age, body mass index, kg/m² (BMI), parity, previous medical and surgical history and indication of myomectomy (abnormal uterine bleeding, infertility, rapid growth of myoma size) were recorded for each patient. Short term outcomes such as intraoperative [operative time (min), estimated blood loss (EBL, ml), length of skin and uterine incision (cm)] and postoperative (reactivity of bowel peristalsis, hospitalization, fully recuperate activity) characteristics were recorded.

Results

Three hundred and three premenopausal women were recruited for the study but finally 273 were included, 242 in the LIM group (group 1) and 31 in the LAIM group (group 2). Mean number of extracted myomas was 2.2 for group I and 3.5 for group II while the mean diameter of the largest myoma was 77 mm in group I and 110 mm in group II. Suprapubic skin incision ($P < .001$), uterine initial and final incisions ($P = .03$), estimated blood loss ($P < .001$), operative time ($P < .001$), bowel peristalsis ($P = .04$) and pain score at 2 hours were significantly improved in cases treated with LIM ($P = .03$). In contrary, postoperative anaemia and pain score at 8 minutes were not significantly different between two groups. Caesarean section was suggested in any future pregnancy and 121 of the studied women had pregnancy 3-36 months after myomectomy. No uterine rupture during the pregnancy were reported in any case although in 10 out of 121 cases the vaginal delivery was chosen.

Conclusions

This prospective cohort study indicated that laparoscopic intracapsular myomectomy may be safe when performing single layer closure and may have superior outcomes compared with laparoscopically assisted intracapsular myomectomy.

**ES28-0029 -
Free Communication 4**

Where does the uterine artery come from? A laparoscopic anatomical observational study

Adnan Orhan MD.¹, Kemal Ozerkan¹, Isil Kasapoglu¹, Cagatay Taskiran², Erdogan Sendemir³, Gurkan Uncu¹

¹Uludag University, Obstetrics and Gynecology, Bursa, Turkey

²Koc University American Hospital, Obstetrics and Gynecology, Bursa, Turkey

³Uludag University, Human Anatomy, Bursa, Turkey

Background

The anatomy, origin, and variations of the uterine artery (UA) differ in the anatomy, radiology and gynaecology literature. This study aims to demonstrate the origin of the uterine artery and its anatomical variations during dissection of the uterine artery in laparoscopic hysterectomies.

Methods

This research was a laparoscopic anatomical observational study in which the retroperitoneal surgical dissections of the uterine arteries from iliac bifurcation to the uterine artery origin were analysed prospectively during laparoscopic hysterectomies between 18 March 2014 and 13 October 2018 in women who underwent laparoscopic hysterectomy with benign gynaecological indications in the Department of Obstetrics and Gynecology of Faculty of Medicine, Bursa Uludağ University Hospital, Turkey.

Results

A total of 378 laparoscopic hysterectomy patients who underwent UA dissection bilaterally were included in the study. Of the 756 UAs that were evaluated, 92.6% were classifiable types and 7.4% of surgical dissections were inconclusive. The first artery branching from the IIA anterior division was found to be UA in 612 of 756 (Type-1, 80.9%) uterine artery dissections. The classification was as follows: type-2, 3.7%; type-3, 3.1% and type-4, 7.4%. A table, a figure with illustrations, a laparoscopic retroperitoneal dissection video at the time of laparoscopic hysterectomy for the origin of the uterine artery and a laparoscopic fresh cadaver dissection for the origin of the uterine artery will be demonstrated at the time of presentation).

Conclusions

During a laparoscopic hysterectomy, meticulous surgical retroperitoneal dissection can be performed safely from iliac bifurcation to the uterine artery. Although there is no consensus between anatomy, radiology and gynaecology disciplines, the first artery from the anterior division of IIA will be the UA with a probability of 80.9% with a retroperitoneal dissection.

**ES28-0059 -
Free Communication 4**

Percutaneous versus laparoscopic hysterectomy: a prospective comparison

Emanuele Perrone¹, Salvatore Gueli Alletti², Cristiano Rossitto³, Stefano Cianci², Fanfani Francesco², Giovanni Scambia⁴

¹Universita' Cattolica del Sacro Cuore- Fondazione Policlinico Universitario A. Gemelli IRCCS, Department Woman and Child Health Sciences- Division of Gynecologic Oncology, Rome, Italy

²Fondazione Policlinico Universitario A. Gemelli IRCCS, Division of Gynecologic Oncology, Rome, Italy

³San Carlo di Nancy Hospital, Division of Gynecology, Rome, Italy

⁴Fondazione Policlinico Universitario A. Gemelli IRCCS,

Department Woman and Child Health Sciences- Division of Gynecologic Oncology, Rome, Italy

Background

To evaluate the feasibility of percutaneous approach, we prospectively compared our experience in percutaneous hysterectomy (PPS-H) with a series of laparoscopic hysterectomies (LPS-H).

Methods

In this multicentric comparative prospective study, Fondazione Policlinico Universitario A. Gemelli IRCCS, in Rome, was the coordinator centre. From May 2015 to September 2017, 160 patients affected by benign and malignant gynaecological conditions were considered eligible for minimally invasive surgery (MIS). Eighty patients received PSS-

H and 80 LPS-H. In each group, 30 cases of low/intermediate risk endometrial cancer were enrolled. Patients from both groups undergoing surgical intervention, had either a total or radical class. A hysterectomy with or without bilateral salpingo-oophorectomy or a lymph nodal assessment, as clinically indicated. For both groups, we documented the total operative time (OT), vaginal cuff closure time and other intra and postoperative data. Postoperative pain was evaluated for each patient, using Visual Analog Pain Scale (VAS). We evaluated cosmetic outcomes at the moment of discharge and 30 days after surgery by assessing size, appearance and healing of scars and by patient satisfaction.

Results

No statistically significant differences were noted in baseline characteristics or OT between the two groups. We observed significant differences in estimated blood loss (EBL): median of 50 cc (PSS-H) and 100 cc (LPS-H), $P=0.0001$. In LPS-H, we reported 4 (5.0%) intraoperative complications and one (1.3%) in PSS-H. Thirty-day complications were 4 (5%) in PSS-H and 11 (13.8%) in LPS-H, $P=0.058$. No significant differences were found in Visual Analogue Scale (VAS) score, despite a relevant disparity in cosmetic outcomes ($P=0.0001$). For oncological cases, the two techniques had comparable intraoperative outcomes and oncological accuracy. The two techniques seem to be comparable in capacity to remove the same lymph nodes amount, a median of 16 (range 13-45) for percutaneous instruments and a median of 17 (range 13-45) for LPS ($P=0.784$). No intraoperative complications were recorded for both approaches. Five (16.7%) 30-days complications occurred ($P=0.052$) in LPS-H. No significant differences were noted in FIGO stage or postoperative management. After a follow-up time, with a median of 16 months for group PSS-H and 19 months for group LPS-H, we recorded 1 pelvic relapse in each group. All patients enrolled were alive at the time of follow-up.

Conclusions

The PSS-H is comparable to the LPS-H for intra and perioperative outcomes and postoperative pain. Our study indicates PSS-H is superior to LPS-H in cosmetic outcomes and patient satisfaction, but future studies need to confirm these findings. In conclusion, this is the first prospective study comparing the PSS to the LPS approach and we demonstrated that PSS-H may represent a valid alternative in ultra-MIS for benign and oncological diseases in gynaecology.

ES28-0094 - Free Communication 4

The usefulness of uterine manipulation simulation among OB-GYN residents as bottom person prior to assisting a total laparoscopic hysterectomy: a Quirino Memorial Medical Centre experience

Maria Rica Baltazar¹, Prudence Aquino-Aquino¹

¹Quirino Memorial Medical Center, Obstetrics and Gynecology, Quezon City, Philippines

Background

An essential part to a successfully performed minimally invasive gynaecologic procedure, such as Total Laparoscopic Hysterectomy (TLH), is a proper uterine manipulation by bottom person. The ability to optimally position the uterus within the pelvis is critical to a safe and efficient surgical dissection. The training of the bottom person to manipulate the uterus is often overlooked. The aim of this study is to compare the efficiency of uterine manipulation during total laparoscopic hysterectomies for those with and without prior simulation training of uterine manipulation in the laparoscopic pelvic trainer box described as Procedure-Specific Task Performance.

Methods

This single-blinded randomised controlled trial enrolled 33 obstetric-gynecologic residents of Quirino Memorial Medical Center with no background on laparoscopy but have been assisting and doing abdominal hysterectomies. Patients included were females within the age group of 20 to 55 years old, with history of sexual contact, scheduled for elective total laparoscopic hysterectomy and adnexectomy for benign uterine or ovarian pathologies. The residents were randomly grouped into two. Group A consisted of sixteen residents who underwent uterine manipulation training using the pelvic trainer box and Group B consisted of seventeen residents who did not undergo training. Group A was given procedure-specific tasks which were performed in 5 repetitions in one session. After a week, they were asked to scrub-in on an actual procedure with the same instructor commanding the tasks and recording the time.

Results

Based on the study, there was significant difference between the two groups. With p-value equal to 0.000, significant differences in time was observed. Time spent by group A residents was statistically lower as compared to control group in performing the procedure-specific tasks. There has also been a significant decrease in time to perform 1st to

5th specific task with p-values equal to 0.000. The correlation coefficient was significant with p-value of 0.023 and a negative correlation coefficient of -0.200, this means that as the negative time difference to perform from the first to the fifth specific tasks increases, the actual time decreases.

Conclusions

One of the essential components of a successful minimally invasive gynaecologic surgery, specifically total laparoscopic hysterectomy is the correct and proper way of uterine manipulation. For safe and efficient pelvic dissection, the ability to optimally position the uterus is very critical. Studies have proven that acquisition of basic laparoscopic skills is through the use of laparoscopic simulators or trainer box. Based on this study, we have shown that uterine manipulation exercises in the pelvic trainer box is effective in the proper performance of residents as bottom person for uterine manipulation during TLH. The battle of performing a proper TLH is half conquered if your bottom person is well-versed with right uterine positions at the right time.

ES28-0226 - Free Communication 4

Comparison of the VCare uterine manipulator with the Mangeshikar uterine manipulator in total laparoscopic hysterectomy

Aysel Nalçakan¹, Omer Lutfi Tapisiz¹, Sadiman Kiykac Altinbas¹, Fulya Kayikcioglu¹, Ozlem Moraloglu Tekin¹
¹University of Health Sciences- Etlik Zubeyde Hanim Women's Health Training and Research Hospital, Gynecology Clinic, Ankara, Turkey

Background

The aim of the study was to determine the advantages and disadvantages of the two uterine manipulators, VCare and Mangeshikar, during total laparoscopic hysterectomy.

Methods

Patients, undergoing total laparoscopic hysterectomy for benign conditions, was conducted at the gynaecology department of a tertiary research and education hospital. All operations were performed by two expert endoscopic surgeons using either the VCare or the Mangeshikar uterine manipulator depending on surgeon preferences. Patients, who were diagnosed to have malignancy, previous pelvic inflammatory disease, tuba-ovarian abscess and endometriosis were excluded. The primary end points were time for insertion of the manipulator, performance of the movement of the uterus, complications due to the manipulator, time for colpotomy, maintenance of the pneumoperitoneum and duration of the total surgery. Preoperative and postoperative vaginal length and postoperative pain scores were measured. Variables were compared between the two groups.

Results

A total of 40 patients (18 patients in the VCare group, 22 patients in the Mangeshikar group) were analysed. Patients' demographic characteristics were comparable between the groups ($p > 0.05$). Compared to the VCare group, time for insertion of the manipulator was shorter (4.1 vs 6.8 min, $p=0.013$); the ability to manipulate the uterus to anteversion/retroversion was better ($p = 0.026$); the overall uterine manipulation was easier ($p=0.036$) in the Mangeshikar group. The maintenance of the pneumoperitoneum during colpotomy and the removal of the materials were better in the Mangeshikar group ($p=0.040$, $p=0.028$, respectively). Compared in terms of complications, uterine perforation was observed in the Vcare group ($n=4$) whereas no complications were observed in the Mangeshikar group ($p=0.033$). There was no difference between the groups in terms of uterine elevation, ability to move in lateral directions, duration of colpotomy, removal of the uterine manipulator, operation time, duration of hospitalisation, preoperative-postoperative haemoglobin change and vaginal length change and VAS scores ($p > 0.05$).

Conclusions

Although both manipulators seem to be appropriate for uterine manipulation during laparoscopic hysterectomy, the Mangeshikar uterine manipulator was found to be superior to VCare uterine manipulator. Especially in difficult cases such as the history of previous pelvic surgery, large uterine size, endometriosis, pelvic inflammatory disease where the uterine manipulator may affect the total of the surgery, the Mangeshikar uterine manipulator may be a good preference depending on the condition.

**ES28-0273 -
Free Communication 4**

Total laparoscopic hysterectomy without uterine manipulator: an 8 years' experience

Dimitrios Zygouris¹, Nektarios Chalvatzas¹, Antonios Gkoutzioulis¹, Georgios Anastasiou², Andreas Kavallaris^{1,2}

¹St Luke's Hospital, Department of Gynecologic Oncology and Minimally Invasive Gynecology, Thessaloniki, Greece

²Mother and Child Medical Centre, Department of Gynecologic Oncology and Minimally Invasive Gynecology, Nikosia, Cyprus

Background

The objective of this retrospective study was to evaluate the safety, intraoperative and postoperative morbidity of Total Laparoscopic Hysterectomy (TLH) without manipulator or any vaginal tube.

Methods

Between January 2011 and January 2019 we performed 886 total laparoscopic hysterectomies, without using any kind of uterine manipulator. We analysed retrospectively perioperative and postoperative outcomes. During the operation we used bipolar forceps and laparoscopic Ligasure™ and vagina was laparoscopically sutured with absorbable individual sutures.

Results

The average age was 54.3 years and BMI 26,4 kg/m², while the uterus weight was 226,5 gram. Overall outcomes included mean estimated blood loss 85ml mean operative time 78 min and mean hospital 1.2 days. In 9 cases blood transfusion was made with one or two red blood cells units and in 1 case transurethral catheter was not removed the first postoperative day as bladder was opened and sutured laparoscopically. The overall complications rate is 1.2%.

Conclusions

Uterine manipulator is used routinely in all cases of TLH. To our knowledge this is the first report of a case series of TLH without using uterine manipulator. This technique seems feasible and safe when performed by well trained and experienced laparoscopic surgeons. We believe this method is necessary to become a standard enrichment in classic technique of TLH even in benign cases. In that way all new doctors will get better trained in benign diseases in order to continue in laparoscopic radical hysterectomy without uterine manipulator.

**ES28-0442 -
Free Communication 4**

Difficult total laparoscopic hysterectomy (TLH) for concurrent "frozen pelvis" due to retrocervical endometriosis

Islam Magalov¹, Nargiz Nagiyeva¹, Rahshanda Aliyeva¹, Arzu Poluxova¹

¹Azerbaijan Medical University, 1st Department of Obstetric and Gynecology, Baku, Azerbaijan

Background

Endometriosis may hamper performing of traditional steps of TLH due to adhesions and retroperitoneal fibrosis which distort normal anatomy. In order to estimate this negative influence we have reviewed the video records of the surgeries performed in 2016-2018.

Methods

353 TLH-s were performed within the mentioned period. The indications for surgery were enlargement of uterus and/or uterine bleeding. In 15 cases there was revealed as intraoperational finding severe endometriosis with "frozen pelvis" and retrocervical deep infiltration.

Results

In cases of endometriosis the duration of surgery was 1,5 times longer since it required adhesion- and ureterolysis, preliminary clipping of uterine arteries, dissection of rectovaginal septum and "shaving" of rectal foci (2 cases). There was no significant difference in intraoperational blood loss and postoperative recovery.

Conclusions

Unexpected severe endometriosis is an unpleasant surprise during surgery since it is rarely prognosed before TLH for elder age group of patients and different indications. Nevertheless, this fact stresses the necessity of proper readiness to this kind of surgery which integrates the knowledge of retroperitoneal anatomy and skills of dissection.

ES28-0564 -
Free Communication 4

Total laparoscopic hysterectomy with prior uterine artery clipping at its origin versus conventional total laparoscopic hysterectomy

Hossam El-Mansy¹, Ahmed A.Allah², Mohamed Magdy³, Usama AboHashem⁴, Walaa El-Bassiony⁴, Rashed Mohammed Rashed⁴

¹Helwan University Hospitals, Obs/Gyn Department, Cairo, Egypt

²Cairo University Hospitals, Gynecology, Cairo, Egypt

³Ministry of Health, Gynecology, Mansoura, Egypt

⁴Azhar University Hospitals, Gynecology, New Damietta, Egypt

Background

It was suggested that attacking the uterine artery at its origin decrease the blood loss in Total Laparoscopic Hysterectomy (TLH). The aim of this randomised controlled study was to compare TLH with prior uterine artery clipping using Hem-O-Lok Clip at its origin versus conventional TLH as regard of blood loss, operative time, intraoperative complications and postoperative follow up.

Methods

It is a multicentric prospective RCT performed in Helwan & Azhar University Hospitals in Egypt. During the study period from February 2018 to April 2019, 50 patients who underwent TLH for benign conditions with uterus no more than 14 weeks were enrolled in the study. Patients were randomly divided into two groups : group A : 25 cases, study group using Hem-O-Lok ® clip (WECK EFX; Teleflex, Research Triangle Park, NC, USA) and group B 25 cases, control group using Ligasure ® (Valleylab,Bouleder,CO).

The only difference in the two techniques was attacking the uterine artery. In the control group Ligasure was used perpendicular to the uterus at the level of the internal os. In the study group, the origin of the uterine artery was reached by adequate dissection and identifying the ureter. Two Hem-O-Lok clip were inserted at the origin of the uterine artery and cut in-between by scissors. Blood loss was calculated using the suction apparatus. The time of the surgery was calculated in minutes, from insertion of the last trocar till removal of the last trocar. Intraoperative and postoperative complications were recorded.

Results

Blood loss was not statistically significant between both groups (study group 64 +18 ml versus control group 70 + 20 ml, P value 0.257). Operative time was not statistically significant between both groups (study group 50 + 11 minutes versus control group 54 +13 ml, P value 0.169). Two cases of the study group was technically difficult to perform and completed traditionally. All cases went uneventful postoperatively.

Conclusions

Clipping the uterine artery at its origin using Hem-O-Lok clip seems to be effective and safe. No statistically significant difference regarding the operative time and blood loss compared to the traditional method.

**ES28-0585 -
Free Communication 4**

Hysterectomy for benign disease in elderly patients: surgical outcomes and complications

Anna Di Siena¹, Angelica Rizzato¹, Ciro Pinelli¹, Baldo Emanuele Gisone¹, Valeria Artuso¹, Fabio Ghezzi¹

¹Department of Obstetrics and Gynaecology - Del Ponte Hospital, University of Insubria, Varese, Italy

Background

Older age is often considered a surgical risk factor for patients undergoing hysterectomy for both benign and malignant diseases. Indeed, gynaecologic surgeons are usually reluctant in performing laparoscopic hysterectomy in elderly patients. We here report a detailed analysis on a large series of elderly patients, who underwent total hysterectomy in a tertiary gynaecologic minimally invasive Italian referral centre over the last two decades.

Methods

Data of consecutive patients who underwent total hysterectomy for benign disease at Del Ponte Women's and Children Hospital (Varese, Italy – University of Insubria) between January 2000 and December 2018 have been recorded. Indication for pelvic organ prolapse was considered as exclusion criteria. The analysis was performed comparing patients who were >60 years old at surgery (Group1), compared to those < 60 years old (Group2). Surgical approaches were recorded as follow: vaginal, laparoscopic or open surgery. Indications of surgery were registered. Surgical details such as estimated blood loss (EBL), operative time (OT), uterus weight, intraoperative and postoperative complications (Clavien Dindo >2), and hospital stay were collected.

Results

Overall, 3521 patients were included, 3206 and 315 in Group1 and Group2, respectively. Indication for surgery was statistically different between the groups (Group1 vs. Group2): fibromatosis (31,1% vs. 79,1%), endometriosis (0% vs. 4,4%), precancerous lesions (32,7% vs. 6,4%), pelvic pain/other (33,3 vs. 6,2%) (all $p < 0,001$). No differences in the rates of actual surgical approach was registered (laparoscopic: 77,5% vs. 75,1%, $p = 0,37$; Open: 9,5% vs. 7,6%, $p = 0,23$; Vaginal: 13,0% vs. 17,3%). Rate of uterine weight >250grams (18.7% vs. 54.3%) and >1000grams (3.8% vs. 8.9%) were significantly higher in Group2. Operative time (70 min vs. 72 min) and EBL (50 ml vs. 100ml) were significantly lower in Group1. Rate of both intraoperative complications (Group1 0,6% vs. Group2 1,9%, $p = 0,12$), and postoperative complications (Group1 3,8% vs. Group 2 6,4%, $p = 0,08$) did not significantly differ between the groups, while hospital stay was significantly longer in elderly patients ($p < 0,001$). Among elderly patients, the comparison of the different surgical approaches did not show significant differences in terms of intraoperative and postoperative complications, however laparoscopy was associated with shorter hospital stay (median 1 vs. 2 vs. 4 days for laparoscopy, vaginal and open, respectively; $p < 0,001$).

Conclusions

Laparoscopy represents a safe option also in elderly patients undergoing total hysterectomy for benign disease. This approach did not show any difference in terms of surgical-related complications compared to open or vaginal approach. However, the shorter hospital stay and faster recovery should support the use of laparoscopy also in this setting of patients.

**ES28-0014 -
Free Communication 5**

Factors associated with long-term pessary use in women with symptomatic pelvic organ prolapse

Lan Zhu¹, Meng Mao¹

¹Peking Union Medical College Hospital- Beijing, Department of Obstetrics and Gynecology, Beijing, China

Background

Pelvic organ prolapse (POP) is a highly prevalent problem in women. Vaginal pessary has been used as a conservative treatment for POP. However, the rationales for pessary discontinuation are quite different from those for unsuccessful pessary fitting. In addition, based on the limited existing literature regarding long-term pessary use, a wide variation exists in the pessary continuation rate. The aims of this study were to evaluate the continuation rate and to identify predictive factors of long-term pessary use.

Methods

This prospective observational study included 277 patients who had successful pessary fittings between April 2015 and November 2016. All patients were followed until April 2018. Data analysis was performed with independent samples *t* tests, nonparametric tests, chi-square tests, logistic regression, receiver operating characteristic curves.

Results

The median (range) follow-up time was 26 (17-36) months; 76.5% of patients continued to use pessaries at the study endpoint. Sixty-one patients discontinued pessary use, and almost all of them (55/61, 90.2%) discontinued pessary use within the first 12 months after the successful pessary fitting. TVL < 7.5 cm (OR 0.181, 95% CI 0.062-0.524, *P*=0.002) and a lower POPDI-6 score at baseline (OR 0.974, 95% CI 0.954-0.994, *P*=0.013) were independent predictors of pessary discontinuation. Patients who had baseline POPDI-6 scores higher than 35 were more likely to continue pessary use (sensitivity=0.587, specificity=0.735).

Conclusions

TVL ≥ 7.5 cm and a higher POPDI-6 score at baseline were independent predictors of long-term pessary use after successful fitting in women with symptomatic POP.

ES28-0032 -

Free Communication 5

Laparoscopic sacrocolpopexy plus colporrhaphy with SIS graft versus transvaginal mesh for advanced prolapse: a retrospective cohort study

*Xiaojuan Wang*¹, *Yisong Chen*¹, *Keqin Hua*¹

¹The Obstetrics and Gynecology Hospital of Fudan University, Gynecology Department, Shanghai, China

Background

Transvaginal mesh (TVM) results in greater anatomic cure and also in more complications. We aim to compare laparoscopic sacrocolpopexy (LSC) plus colporrhaphy with small intestine submucosa (SIS) graft versus TVM for advanced pelvic organ prolapse (POP).

Methods

The patients with advanced POP who underwent LSC plus colporrhaphy with SIS graft or TVM at a centre between September 2015 and November 2016 were recorded. Anatomical outcomes were evaluated using POP-quantification (POP-Q). Functional outcomes related to POP and sexual life were evaluated using the Pelvic Floor Distress Inventory (PFDI-20) and the Pelvic Floor Impact Questionnaire (PFIQ-7). Data regarding surgical procedures and patient demographic variables were recorded. Chi-square and Students *t*-tests were used for two independent samples.

Results

A total of 76 patients were enrolled, 26 to LSC plus colporrhaphy with SIS (group A) and 50 to TVM (group B). Blood loss during surgery was similar in both groups. However, the operation time was significantly longer in group A than that in group B (*p* < 0.001). No blood transfusion in either group. All patients of both groups demonstrated significant improvement in anatomical outcomes after surgery (*p* < 0.05). 9 patients (34.6%) of group A experienced vaginal apical infection, which significantly was more than those of group B (7 (14%)) (*p* = 0.038). The postoperative hospital stay of group A was significantly longer than those of group B (*p* < 0.0001). Mesh exposure was occurred in both groups, 8 (30.7%) in group A, 5 (10%) in group B, given mesh excision at outpatient successfully, which was significantly different (*p* = 0.027). PFDI-20 scores were significantly improved 12 months after surgery in both groups (*p* < 0.001). PISQ-12 scores were significant improvement in these patients after surgery, especially those of group A (*p* < 0.001).

Conclusions

Even though both surgeries showed excellent results for subjective and objective outcomes, the use of SIS might increase the exposure of mesh exposure. We don't recommend LSC plus colporrhaphy with SIS graft for advanced multiple-compartments prolapse.

**ES28-0107 -
Free Communication 5**

A prospective, controlled study comparing single port laparoscopic sacrospinous fixation and transvaginal sacrospinous fixation in the treatment of pelvic organ prolapse

Wei Zhang¹

¹Zhongnan Hospital of Wuhan University, Obstetrics and Gynecology, Wuhan, China

Background

The objective of the study was to compare recurrence and complication rates for single port laparoscopic sacrospinous fixation (SSF) and transvaginal SSF for the primary treatment of pelvic organ prolapse.

Methods

Patients undergoing surgery for pelvic organ prolapse were included in a randomised, controlled study comparing single port laparoscopic SSF or transvaginal sacrospinous fixation. The examination included operative time, intraoperative blood loss, operative complication and pelvic organ prolapse quantification, urodynamics, ultrasound and quality-of-life (QoL) questionnaires before and 3 and 12 months after surgery.

Results

Of 20 randomised patients in Zhongnan Hospital of Wuhan University, from Jan.2018 to Mar.2019, 10 underwent single port laparoscopic SSF and 10 transvaginal SSF. All the operations were completed successfully. The operative time in the single port laparoscopic group (117.0±20.0 min) was longer than the transvaginal group (75.2±24.3 min). The intraoperative blood loss (54.9±24.1 ml) was less than the transvaginal group (87.6±12.3 min). The incidence of operative complications in the single port laparoscopic group (n=3) was lower than transvaginal group (n=5). There was no difference between the single port laparoscopic group and the transvaginal group in prolapse recurrence after 12 months occurred ($P > 0.05$). No difference in QoL improvement as well as of de novo stress urinary incontinence and overactive bladder onset was found.

Conclusions

Single port laparoscopic sacrospinous fixation is safe and feasible in the treatment of pelvic organ prolapse.

**ES28-0290 -
Free Communication 5**

Laparoscopic and robotic colposacropexy in the surgical treatment of vaginal vault prolapse: clinical and surgical outcomes

Fabrizio Romano¹, Gabriele Siesto¹, Cinzia Bulletti¹, Rosa Alba Valentina Portuesi¹, Andrea Finco¹, Domenico Vitobello¹

¹Humanitas Clinical and Research Center, Gynecology, Rozzano - Milan, Italy

Background

Vaginal vault prolapse (VVP) occurs in approximately 2-40% of patients after hysterectomy. In case of young and sexually active patients, the gold standard for surgery is colposacropexy. In the last decade the mini-invasive surgical approach (laparoscopic, LCS, and robotic, RCS) has overtaken the abdominal technique for better clinical and surgical outcomes; however, the superiority of one of these minimally invasive technique is still debated. The objective of our study was to establish the most appropriate surgical procedure by analysing the intra-, peri- and postoperative complications of the two techniques, anatomical and functional patients' outcomes and cure rates

Methods

A prospective monocentric observational study was conducted on RCS at Humanitas Clinical and Research Center (Rozzano, Milan) between January 2014 and January 2016 with a 36-month follow-up and compared with a systematic review of the literature on LCS. Case-control, cohort, prospective, retrospective, observational and randomised studies published between 2000 and 2017 (MEDLINE) have been included. Clinical and demographic variables and surgical complications were analysed by logistic regression; the clinical-demographic variables and surgical time by linear regression; the difference between the data of our cohort and the data reported in the literature was analysed by t-test.

Results

Our cohort included 32 patients who underwent RCS, whose outcomes were compared with 1586 patients who underwent LCS (20 studies included from the literature). The difference between RCS and LCS was not statistically significant in terms of average length of hospital stay (2.9 vs 3.2 days; $p=0.43$), and surgical times (184 vs 173 minutes respectively; $p=0.45$). The rate of vaginal erosion from mesh was significantly higher in RCS compared with LCS ($p=0.01$).

Conclusions

LCS and RCS have proved to be equally a valid and effective surgical procedure in the treatment of VVP with similar outcomes, apart from vaginal mesh erosion which was more frequent in RCS. Even considering low number of our cohort, we suggest LCS as a surgical approach, if performed in advanced centres due to its major complexity. In case of less laparoscopic skills, RCS represents the safest and most effective approach for the treatment of vaginal vault prolapse in young and sexually active patients.

ES28-0297 -

Free Communication 5

Transvaginal single-port laparoscopic sacrocolpopexy (vlsc): following up of 42 cases

Li Junwei¹, Yisong Chen¹, Keqin Hua¹

¹Obstetrics & Gynecology Hospital of Fudan University, Gynecology, Shanghai, China

Background

Transvaginal single port laparoscopy has been greatly developed these years. This study describes the early stage experience and outcomes of transvaginal single-port laparoscopic sacrocolpopexy (VLSC) for severe middle compartment prolapse.

Methods

42 patients presenting severe middle compartment prolapse in China were consented to transvaginal single-port laparoscopic sacrocolpopexy from May 2017 to Mar 2019. The perioperative characteristics of VAS pain score, cosmetic score, POP-Q score, PFID-20 and FSFI-19 were observed.

Results

The mean age was 56.52 ± 7.72 years. The operative time was 141.88 ± 31.71 min. The estimated blood loss was 106.34 ± 58.21 ml and postoperative hospital stay was 5.83 ± 0.91 days. VAS pain score 24h after surgery was 1.86 ± 0.95 , which means mild pain. Patients felt well self-confidence and satisfaction after surgery, with the cosmetic score of 36.71 ± 2.61 , and no perioperative complications were observed. The following up time were 10.91 ± 7.47 (1-23) months. One patient complained of slight vaginal bleeding and recovered after vaginal estrogen supplement. One was suffered from new mild SUI, no need to surgery. 2 patients had constipation, who recovered after medicine. One patient had prolapse recurrence 9 months after surgery. There was no mesh erosion, infection or hematoma. The pre- and postoperative PFID-20 score was 51.72 ± 21.35 vs. 8.19 ± 11.71 ($P=0.000$). For the patients resuming sexual relations postoperatively, the pre- and postoperative FSFI-19 score was 23.53 ± 8.76 vs. 23.44 ± 10.86 ($P=0.98$). The Aa point, 1.00 ± 1.81 vs. -2.55 ± 1.51 , and for the C point, 3.50 ± 2.50 vs. -6.03 ± 1.74 postoperatively, $P < 0.05$. But for TVL, 7.21 ± 1.04 vs. 7.16 ± 1.15 postoperatively, no difference was seen.

Conclusions

VLSC sound likes a considerable choice for severe middle compartment prolapse, because of its good safety and efficacy. More cases and additional studies are still required.

**ES28-0407 -
Free Communication 5**

Robotic vs. laparoscopic sacropexy! Learning curve, safety and outcome

Ralf Joukhadar¹, Achim Woeckel¹, Dimitrios Balafoutas¹

¹Wuerzburg University Hospital, Obstetrics & Gynaecology, Wuerzburg, Germany

Background

Laparoscopic sacrocolpopexy is currently regarded as the gold standard procedure for the treatment of pelvic organ prolapse (POP). Robotic systems, however, offer higher technical support, thus facilitating shorter learning curves and higher feasibility along with lower rates of conversion to laparotomy.

Methods

We present a retrospective evaluation of the perioperative data of the first consecutive 50 robotic sacrocolpopexies after implementing a robotic program at a tertiary, high volume, university centre with high laparoscopic proficiency.

The data of these robotic sacrocolpopexies were compared with the data of preceding consecutive 100 laparoscopic sacrocolpopexies.

Age, body mass index, operative time, estimated blood loss (EBL), hospital stay as well as intra- and postoperative complications were collected. Complications were classified according to Clavien-Dindo (C-D) System.

Results

Fifty robotic sacropexies (RSC) were compared with 100 laparoscopic sacropexies (LSC). Mean operative times were RSC, 174 ± 42 minutes, and LSC, 155 ± 51 minutes. The EBL, hospital stay, intraoperative complications as well as postoperative complications were low in both groups without statistical significant differences. No conversion to laparotomy was performed.

The anatomical success rate, defined as POP-Q Stage ≤ I at 3-Months follow-up was 100% for the apical and 95% for the anterior compartment.

Conclusions

Our data suggest that RSC is comparable to LSC in terms of safety and efficacy. The robotic technique has a short learning curve.

**ES28-0428 -
Free Communication 5**

Outcomes after laparoscopic colposuspension

Charlotte Goumalatsou¹, Gillian Coyle¹, Benedetto Mondelli¹, Andrew Kent¹

¹Royal Surrey County Hospital, Obstetrics and Gynaecology, Guildford, United Kingdom

Background

Before the TVT, Burch colposuspension was the operation of choice for stress urinary incontinence (SUI), cystocele and prolapse (Burch 1961). The use of vaginal mesh in the UK is on hold, bringing colposuspension back to the fore of SUI surgery. LC offers an alternative to open colposuspension and TVT with similar outcomes and trends towards a shorter stay, quicker recovery and fewer complications (Dean 2017). LC has been offered in Guildford since 2006. We use 4 ports and a transperitoneal approach, delivered as part of an ERP. Two Ethibond sutures are placed bilaterally and the small peritoneal defects closed (Kent 2009, 2014). The catheter is removed before discharge. We aimed to assess the subjective cure rate of SUI. Secondary outcomes include peri- and postoperative complications (blood loss, bladder injury, failure of TWOC, infection); length of stay; requirement for re-operation; and patient satisfaction.

Methods

Case notes were retrospectively analysed between 2006 and 2015 to assess demographic data, indication for surgery, presence of urinary and prolapse symptoms, urodynamic study (UDS) results, intra- and postoperative complications as well as postoperative cure at initial follow-up, and any further procedures between their index

procedure and currently. Patients were then sent postal questionnaires to assess long-term subjective cure and patient satisfaction. Data were anonymised and collected onto an encrypted database. Statistical analysis was carried out using SPSS. NRES South East Coast advised that this study did not require submission for formal ethics review.

Results

Patients had a mean age of 51.3 years, with mean BMI of 27.7kg/m². 97% of women were parous, with the majority having delivered vaginally (78%). 97.5% of women presented with SUI symptoms, and 61% were also symptomatic of prolapse. Urinary urge was present in 29.3% of women, but on UDS none had detrusor instability. 90.2% had genuine stress incontinence and in 10% no urinary incontinence of any form was demonstrated. 51% of women had only a LC, with the remainder also having adhesiolysis (20%), LH (10%), posterior repair (10%) or other (10%). 90.2% of patients were discharged after 1 night. Complications included intraoperative bladder injury, failure of first TWOC (29.3%), infection (9.3%), DO symptoms (12.2%), and long-term retention (9.6%) which are in line with or lower than BSUG quoted risks (BSUG 2018). The subjective cure rate at first follow-up was 87.8%.

Conclusions

LC is a safe and effective alternative to open colposuspension and the TVT. Women need to be counselled appropriately regarding the risks and benefits as with any procedure. More recent data may reveal a lower complication rate reflecting the learning curve in action.

ES28-0450 -

Free Communication 5

Laparoscopic sacrocolpopexy with polypropylene meshes - our learning curve

Raxshanda Aliyeva¹, Islam Mahalov², Arzu Poluxova², Nagiyeva Nargis²

¹Azerbaijan Medical University, Department of Obstetrics and Gynecology, Wuppertal, Germany

²Azerbaijan Medical University, Department of Obstetrics and Gynecology, Baku, Azerbaijan

Background

Laparoscopic sacrocolpopexy is considered the gold standard for the pelvic organ prolapses repair. However, necessity to dissect the area of promontory full of vascular and nervous pathways can lead to major complications and life-threatening haemorrhage. Besides, the possibility of long-term so-called minor complications like de novo bowel, urinary and sexual disfunctions because of nerves damage may lead to hesitations of surgeons at the time of prolapse repair choose. The aim of our study is to show our way of "fast and safe" learning curve for laparoscopic sacrocolpopexy from first operations with use of takers, one mesh and long operating time (approximately 200 minutes) to standardized 90-minutes two mesh repair.

Methods

Our group have performed 104 laparoscopic sacrocolpopexies between 2012- 2018 for grade 3 and 4 apical and anterior compartment prolapses (POP-Q classification). From them -for 37 women was performed hysteropexy, for 52 -cervicosacropexy and for 15- culdopexy (10 for recurrent prolapses). Firstly, operation technique includes promontory dissection, opening the parietal peritoneum medially to the right ureter, the rectovaginal plane dissection, placement of one mesh posteriorly on the cervix and upper 1/3 part of vagina with irregular "intuitive" number of absorbable and non-absorbable sutures and fixation of mesh to promontory with takers.

Results

Our first operations had long operation time (approximately 200 minutes) and relatively poor anatomical outcomes. Later, we start to use two meshes with fixation of the posterior mesh at the upper 2/3 of vagina without sutures on levator ani muscle and fixation of mesh in the upper 2/3 anterior compartment, standardise place and number of sutures at the anterior and posterior vaginal walls, cutting the anterior mesh, fixation of the posterior long mesh on promontory and stop to use takers at promontory, replacing them with non-absorbable 1 or 2 sutures. Consequently, after possible standardisation of sacropexy, operation time have decreased to 90 minutes with better anatomical outcomes. No major complications occurred.

Conclusions

Laparoscopic sacropexy is an operation with protracted learning curve. Standardisation of technique may reduce the operation time and lead to better anatomical and functional outcomes.

Robotic pectopexy for treatment of apical prolapse: analysis of the first 50 cases

Dimitrios Bolovis¹, Cosima Brucker¹

¹University Hospital Nürnberg - Paracelsus Medical School Nürnberg- Germany,
Department of Obstetrics and Gynecology, Nürnberg, Germany

Background

Pectopexy is a new innovative method to surgically correct apical prolapse. In contrast to colposacropexy, it uses bilateral fixation of the cervix or vaginal cuff to the pectineal ligament via a synthetic mesh (PVDF). The method was first described using conventional laparoscopy (1,2). For laparoscopic pectopexy data are scarce. We have been the first to describe the robotic application of this new method (3). Here we present initial data on the first series of 50 consecutive patients who received pelvic floor reconstruction using robotic pectopexy.

Methods

50 consecutive patients treated with robotically assisted pectopexy using the daVinci Xi system (Intuitive Surgical) were evaluated retrospectively. Included were all patients presenting with symptomatic isolated or combined apical prolapse POP 2-4. In order to evaluate the general applicability of the method there were no exclusion criteria. If combined prolapse was present, correction of remaining cystocele and/or rectocele was conducted vaginally during the same procedure. We evaluated surgical outcome 12 weeks and 12 months postoperatively.

Results

Mean age of patients treated robotically was 60.2 years (range 37-85), mean BMI was 26.2 kg/m². Robotic pectopexy was possible in all 50 patients without conversion. Mean operating time for pectopexy was 90.3 min (range 50-131 min). There was no significant blood loss (<5ml). All patients were dismissed 3 days following surgery and no major complications or readmissions were observed. During follow-up, we had 5 cases with descensus in the anterior compartment with 4 interventions, 4 cases with descensus in the posterior compartment with 3 interventions. There was no apical relapse.

Conclusions

Robotically assisted bilateral fixation at the pectineal ligament is a safe, anatomical, innovative surgical method to correct apical descensus. The operation can be conducted safely laparoscopically, however, the use of the robotic technology can reduce trauma and the compromise of conventional laparoscopical manoeuvres as well as operating time, offering an excellent ergonomomy. Shortcomings of this initial evaluation of the method are the retrospective nature of our evaluation, the small patient number and short observation period. Pectopexy will prove an important addition to already existing procedures for correction of apical descensus, and can be safely, anatomically and atraumatically conducted using robotic assistance.

¹Pektopenie: ein vielversprechendes verfahren zur korrektur des vaginalen deszensus. Anapolski, Banerjee, Rulinski, Noé; Geb Fra 2011; 71 – A46

²Laparoscopic Pectopexy: a randomised comparative clinical trial of standard laparoscopic sacral colpo-cervicopexy to the new laparoscopic pectopexy. Short-term postoperative results. Noé, Spüntrup, Anapolski; Arch Gynecol Obstet 2012; 287: 272-280

³robotic pectopexy for treatment of apical prolapse: first description of robotic approach. Bolovis D, Brucker C; SERGS Sofia 2019; Abstract, subm.

**ES28-0504 -
Free Communication 5**

Tendon-transplantation for genital prolapse

Amadeus Hornemann¹, Benjamin Hoch¹, Marc Sütterlin¹

¹University Hospital Mannheim, Obstetrics and Gynecology, Mannheim, Germany

Background

Due to known complications with synthetic materials and the FDA and NHS warnings for vaginal meshes, patients often ask for alternative methods. We describe a prospective non-comparative clinical study on prolapse surgery with a semitendinosus tendon autograft as it is used for decades in orthopaedic surgery since anterior crucial ligament (ACL) reconstruction.

Methods

In 12 patients with genital prolapse a semitendinosus autograft was transplanted intraabdominally and replaced a synthetic mesh for vaginal, cervical or uterine suspension.

Results

In the first patient a sacrocervicopexy was done, in the other patients the tendon was fixed bilaterally to the pectineal ligament (pectopexy).

In every patient the transplantation was done successfully. All patients recovered quickly and were discharged between the second and third day. In 8 patients the tendon was removed from the right leg, in 4 patients it was harvested from the left leg.

Vaginal control examinations demonstrated the intended elevation of the vagina. Mobility and power of the operated leg did not change. The patients were highly satisfied and confirmed that they would recommend to procedure to other affected women.

So far no serious adverse events occurred.

Conclusions

Our pilot study demonstrates the feasibility of intraabdominal/retroperitoneal transplantation of a tendon autograft for patients with pelvic organ prolapse. As the procedure of stripping the tendon is established in orthopaedic surgery and not really challenging, we see a huge potential in replacing synthetic meshes with tendon tissue in women with prolapse.

Fixation to os sacrum is possible but fixation to ligamentum pectineale is easier and just as efficacious.

**ES28-0229 -
Free Communication 6**

The impact of pre-treatment laparoscopic staging and debulking of positive lymph nodes in patients with locally advanced cervical cancer (LACC)

Borut Kobal¹, Branko Cvjetičanin¹, Matija Barbič¹, Leon Meglič¹, Barbara Šegedin², Barbara Zobec Logar Helena²

¹University Medical Centre Ljubljana, Ob/Gyn, Ljubljana, Slovenia

²Institute of Oncology, Department of Radiotherapy, Ljubljana, Slovenia

Background

Pretreatment laparoscopic surgical staging can be added to radiologic staging in locally advanced cervical cancer (LACC) for better directing of radiotherapy. If eradication of positive lymph nodes might improve the progression free survival (PFS) and overall survival (OS) remains controversial. We present short and long term complication of pretreatment transperitoneal laparoscopic lymphadenectomy and the oncologic outcomes.

Methods

Observational retrospective study of patients with LACC (FIGO stage IB2 to IV) referred to our centre between June 2009 - June 2017. The early protocol required only pelvic lymphadenectomy. All patients had pretreatment radiologic

staging and laparoscopic surgical staging and debulking of pelvic lymph nodes prior to standard radio chemotherapy, followed with another radiologic staging. Primary endpoint was to compare patients with negative lymph nodes (group A) with those who had completely debulked positive lymph nodes (group B) and those with residual positive lymph nodes (group C) in term of progression free survival (PFS) and overall survival (OS). Secondary endpoint was to evaluate the surgical outcome and the presence of lymphedema (grade I-III).

Results

A total number of 154 patients were included in data analysis. Limits of pelvic surgical staging were achieved in all cases, 10 patients with incomplete surgical debulking were included in group C together with those having positive lymph nodes in other regions (para-aortic, presacral, inguinal).

Recurrence was reported in 6/61 (9,8%) patients in group A versus 14/48 (29,2%) in group B and 16/45 (35,6%) patients in group C.

Regional disease progress was present in 1 (1,6%) patient in group A comparing to 6 (12,8%) patients in group B and 8 (18,6%) patients group C. 4 (10,8%) patients in group A, 12 (35,3%) in group B and 18 (46,2%) in group C died of the disease during the follow up.

Comparing group A with group B and group C we found significant differences in term of OS (81,8 months versus 65,2 months and 54,7 months) and PFS (77,4 months versus 62,5 months and 57,6 months). When only FIGO stage IIB patients (62 patients) were analysed the OS was significantly better for group B versus group C (68% versus 40%).

Regarding perioperative and early postoperative complications there was one bladder injury, one patient had A-V block during surgery and one patient had second surgery because of post-operative bleeding. 61 (39,6%) patients complained for grade 1 and 4 (2,5%) patients for grade 2 lymphedema of the legs after completing the treatment.

Conclusions

Pretreatment laparoscopic pelvic lymphadenectomy in LACC patients combined with pretreatment radiological staging is feasible and safe. The later can further direct surgeon to optimal debulking of suspect lymph nodes. According to our results complete debulking may prolong PFS and improve OS especially in patients with FIGO stage IIB.

ES28-0315 - Free Communication 6

Hidden blood loss and its risk factors in patients with cervical cancer undergoing open radical hysterectomy

Qiong Zhang¹, Yu Zhao¹, Yue Hu¹

¹The Second Affiliated Hospital and Yuying Children's Hospital of Wenzhou Medical University, Department of Obstetrics and Gynaecology, Wenzhou, China

Background

This study calculated the amount of hidden blood loss (HBL) through the open radical hysterectomy (ORH) and tried to determine its risk factors so as to provide more comprehensive suggestions when making blood re-infusion strategies.

Methods

Fifty-six patients who were treated with ORH were enrolled in this study. Their height, weight, preoperative Hct and postoperative Hct were recorded in order to calculate the amount of HBL according to Gross's formula. Multiple linear regression analysis was adopted further to determine the risk factors of HBL.

Results

The visible blood loss (VBL) was 389 ± 175 mL through the perioperative duration. At the same time, the hidden blood loss was 310 ± 297 mL, which was nearly the same amount of VBL and accounted for $40.5 \pm 17.6\%$ of the total blood loss (TBL). According to the result of multiple linear regression analysis, the age ($P=0.047$), number of lymph nodes ($P=0.000$), surgical time ($P=0.015$) and pathological tumour type ($P=0.041$) were independent risk factors contributing to the HBL.

Conclusions

The amount of HBL is seriously underestimated in the open radical hysterectomy. And the age, number of lymph nodes, surgical time and pathological tumour type are independent risk factors of HBL. When making blood transfusion strategies, we should take HBL into consideration to ensure patients' safety and improve postoperative rehabilitation.

Triage by methylation versus colposcopy biopsy who test HPV-positive or abnormal LBC results on cervical samples to triage cervical cancer and HSIL for further treatment

Yuan Yuan Gu¹, Guannan Zhou¹, Jingxin Ding¹, Keqin Hua¹

¹Fudan University, Gynecology - The Obstetrics and Gynecology Hospital, Shanghai, China

Background

While colposcopy screening was successful in screening cervical cancer, it has limitations like subjectivity, interobserver variability, modest sensitivity. The study aims to evaluate the efficacy of colposcopy and CareMe Pluse methylation for triage cervical cancer and HSIL for future treatment.

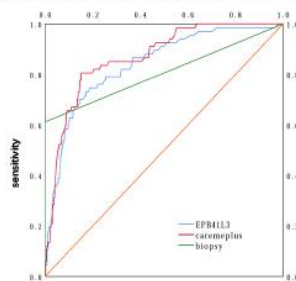
Methods

In the prospective observational multicentre study, 4 070 patients with HPV-positive or abnormal LBC results underwent colposcopy-examination to identify the grade of cervical lesion, meanwhile the cervical scrapes were tested for DNA methylations. 607 women diagnosed as \geq HSIL via colposcopy-biopsy and then underwent LEEP (Loop Eelectrosurgical Excision Procedure). Depending on the pathology after LEEP as golden standard, the predictive performance of methylation analysis and colposcopy-biopsy were compared. The sensitivity and specificity of several other methylation tests were analysed to determine the optimal methylation strategy.

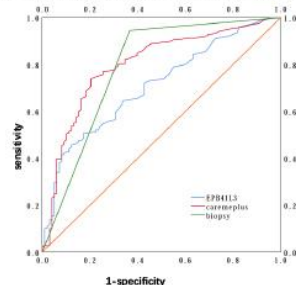
Results

The predictive performance of CareMe-plus methylation was evaluated by comparing the sensitivity and specificity of methylation tests and colposcopy biopsy in patients who underwent LEEP (n=607). Depending on the pathology after LEEP as golden standard, the predictive performance of CareMe-plus methylation was significantly greater than colposcopy-biopsy for cervical cancer, CareMe-plus methylation analysis revealed a significant discrimination of women with cervical cancer from those with \leq HSIL (P=0.022). ROC curve analysis showed an AUC of 0.869. The predictive performance of CareMe-plus methylation was significantly greater than colposcopy-biopsy for HSIL+, CareMe-plus methylation analysis revealed a significant discrimination of women with HSIL+ from those with \leq LSIL (P=0.026). The CareMe-plus methylation analysis was superior to other alternative methylations to triage patients for

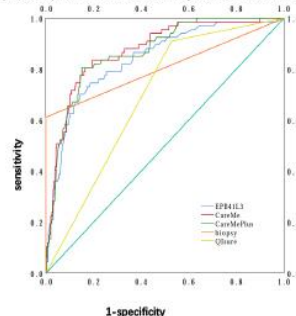
A predictive performance of CareMe-plus methylation for Cervical cancer



B predictive performance of CareMe-plus methylation for HSIL+



C predictive performance of several methylation tests for Cervical cancer



further treatment. When compared the predictive performance of several methylation tests for cervical cancer, CareMe and CareMe-plus is greater than EPB41L3 and QIsure.

Conclusions

CareMe-plus methylation assay may be applicable to identify HPV-positive or abnormal LBC women with a high-risk of high grade lesion or cervical cancer. It may triage patients for accurate further treatment when combining with colposcopy biopsy.

ES28-0490 - Free Communication 6

Clear cell adenocarcinoma of the cervix: a retrospective analysis of clinical characteristics from a single-institution

Ting Wang¹, Ying Zhi Lu¹, Dan Xiao Zhang¹, Keqin Hua¹

¹Fudan University, Department of Gynecology - Obstetrics and Gynecology hospital, Shanghai, China

Background

Clear cell adenocarcinoma of the cervix (CCAC) is a rare pathological type of cervical cancer. The aim of this study was to analyse the clinical characteristics and outcomes of this disease and reflect on the pattern of strategy treatments.

Methods

We performed a retrospective review of all patients with CCAC who were diagnosed and surgically treated at the obstetrics and gynaecology hospital of Fudan University from January 2003 to December 2017. Clinicopathological data and surgical treatment information were collected and analysed. Kaplan–Meier method and univariate and multivariate cox regression analyses were performed to determine prognostic factors associated with survival.

Results

A total of 54 patients were included in this study. The overall 5-year progression-free survival (PFS) and overall survival (OS) were 53.30% and 58.10%, respectively. 49 patients (90.74%) received adjuvant treatment. Early tumour stage (IA2-IB1), small tumour size (≤ 4 cm) and negative PLN had positive effects on OS and PFS ($P < 0.05$). Adjuvant chemotherapy (CT) alone or concurrent chemoradiation therapy (CCRT) did not affect PFS or OS in patients ($P > 0.05$). With our multivariate analysis we found that International Federation of Gynecology and Obstetrics (FIGO) stage ($P = 0.002$, hazard ratio [HR]: 2.360, 95% confidence interval [CI]: 1.515-3.675) and lymph node status ($P = 0.028$, HR: 3.053, 95%CI: 1.125-8.282) were independent factors associated with survival analysis. In addition, our study showed that there are wide diversity in adjuvant treatments and survival rates after primary surgery.

Conclusions

FIGO stage and lymph node status were prognostic factors for survival in patients with CCAC. Postoperative adjuvant therapy for CCAC requires individualised treatment, which cannot be completely referred to the standard of cervical squamous cell carcinoma. Postoperative CT for CCAC has a certain advantage, with relatively small side effects and the effect is not less effective than CCRT.

ES28-0501 - Free Communication 6

Successful laparoscopic treatment of chylous ascites after pelvic lymphadenectomy

Shuhong Yao¹

¹1st Affiliated Hospital of Sun Yat-Sen University, Gynecology, Guangzhou, China

Background

Chylous ascites is a rare form of nonmalignant ascites referring to the pathologic accumulation of chylous fluid in the peritoneal cavity. It can occur secondary to congenital abnormalities or other diseases that occlude the retroperitoneal lymphatic. It can also be an uncommon complication following lymphadenectomy in the management of gynaecologic

malignancies as a result of direct surgical trauma of the cisterna chyli or of its major lymphatic channels. Diagnosis of chylous ascites involved history of operation, symptoms and analysis of ascites. Treatment modalities include serial paracentesis, medium-chain triglyceride diet, total parenteral nutrition and somatostatin as conservative management and peritoneovenous shunting. The patients who don't respond to conservative treatment are candidates for surgery. One of the most difficult parts of the surgery is how to identify the leaking site. Several methods of dyeing have been reported with no consensus. Here we present a case of refractory chylous ascites successfully treated with laparoscopy after using a novel way to mark the leaking site.

Methods

A 23-year-old female patient with refractory chylous ascites was successfully treated with laparoscopic ligation of the ruptured lymphatic vessel. A 23-year-old female patient developed abdominal distention after right side pelvic lymph node dissection for dysgerminoma of the ovary. Conservative management options failed in treating chylous ascites. Peanut oil was orally administered, and laparoscopy revealed the presence of a whitish fluid in the abdominal cavity, and a stream of the fluid was noticed. The responsible lesion of the chylous ascites was detected in the right obturator fossa and ligated with HEM-O-LOK.

Results

The patient experienced an uneventful recovery and had been completely free of the symptoms for 3 months.

Conclusions

Conclusion: Laparoscopic surgery should be considered as a treatment of choice for intractable chylous ascites and peanut oil could be used before surgery as an effective way to facilitate detection of the leakage during surgery.

ES28-0538 - Free Communication 6

Mini-laparoscopy for gynaecologic cancer

Cagatay Taskiran¹, Dogan Vatansever¹, Burak Giray², Selim Misirlioglu¹, Tuncer Kumcular³, Macit Arvas⁴

¹Koc University School of Medicine, Department of Obstetrics and Gynaecology - Division of Gynaecologic Oncology-, Istanbul, Turkey

²Zeynep Kamil Women and Children's Health Training and Research Hospital, Department of Obstetrics and Gynaecology- Division of Gynaecologic Oncology, Istanbul, Turkey

³VKF American Hospital, Department of Obstetrics and Gynaecology, Istanbul, Turkey

⁴Istanbul University - Cerrahpasa Faculty of Medicine, Department of Obstetrics and Gynaecology - Division of Gynaecologic Oncology, Istanbul, Turkey

Background

Laparoscopic surgery has been shown to be a safe and effective approach for many surgical procedures in gynaecology and it is used for many benign and malignant procedures. Mini-laparoscopic surgery is described as endoscopic surgery using instruments with a smaller diameter (3-mm or less) and optics (5-mm or less). We aimed to analyse the preliminary experience of mini-laparoscopy in women with gynaecologic cancer.

Methods

Twenty-seven patients with gynaecologic cancer who underwent mini-laparoscopic surgery between April 2016 and 2019 were included to the study. Mini-laparoscopy was performed through one optical trans-umbilical 5-mm trocar, one 5-mm ancillary port on the right lower quadrant, either one 2.4-mm percutaneous endoscopic instrument or 3-mm mini-laparoscopic port on the right upper quadrant and when necessary one 3-mm ancillary port on the left-lower quadrant. Integrated bipolar and/or ultrasonic technology were used.

Results

A total of 27 patients were included. The median age was 54 years (range, 21-80 years), and the body-mass index was 25.4 kg/m² (range, 19.1-39.8 kg/m²). Twenty-three of the patients had endometrial cancer; 2 patients had invasive cervical cancer; 1 patient had microinvasive cervical cancer; and the remaining 1 patient had borderline ovarian tumour. The median operating time was 190 minutes (range, 90-330 minutes). There was no intraoperative complication. Two patients had postoperative fever which started on postoperative day 1 and day 2. One patient experienced bradycardia during the early postoperative period. Conversion to laparotomy or transfusion were not required. The median hospital stay was 3 days (range, 1-7 days).

Conclusions

The preliminary data suggest that mini-laparoscopic approach is a feasible and safe surgical modality for gynaecologic cancer.

ES28-0567 -

Free Communication 6

Pelvic laparoscopic lymphadenectomy vs radiotherapy in vulvar cancer

Eleftherios Klonos¹, Jalid Sehoul¹, Jumana Muallem¹, Imad Hatoum¹, Mustafa Zelal Muallem¹

¹Charite Campus, Klinik für Gynäkologie mit Zentrum für Onkologische Chirurgie, Berlin, Germany

Background

Vulvar Cancer is diagnosed in approximately 27,000 women each year worldwide and constitutes 5.1% of all gynaecologic malignancies. The treatment is mainly based on the surgical approach, but it should be always individually oriented according to the type of the lesion. In particular, the management of such patients should always be based on finding the most effective surgical treatment. The surgical treatment is divided into three categories: (a) the excision of the primary disease, (b) the lymphadenectomy when there is a suspicion or even more an evidence of the existence of positive nodes (c) the reconstruction of the operated area. In the treatment of vulvar cancer postoperative radiation also plays an important role due to the high risk of local recurrence of the disease, or due the existence of positive nodes which were surgically excluded and is usually performed to the pelvic - inguinal area.

Methods

From January 2015 to December 2017, after vulvectomy pelvic lymph nodes were removed in seven patients (n = 7), five of whom were laparoscopic performed and in two with laparotomy. All patients received on – shot antibiotic prophylaxis (cefuroxime 1.5g intravenously) preoperatively and for 5 days postoperatively. In addition they received perioperative low molecular weight Fraxiparin (0.3 ml/24h) subcutaneously 12 h before the operation and postoperative for all the days of the hospitalisation. Four patients (n = 4) were stage T1b, two (n = 2) T2p and one patient T1a. The age of the patients ranges from 44 to 81 with an average age of 63.3. All operations were performed at the Charite Campus Wirchow Berlin in Gynaecology Oncology Department by the same surgeon. The including criteria for undergoing pelvic lymphadenectomy were : i) ≥ 2 positive inguinal lymphnodes, ii) 1 inguinal lymphnode with size ≥ 10 mm or iii) 1 lymph node with extracapsular spread . Blood loss for pelvic lymphadenectomy was round 100 ml and it was estimated by subtracting the volume of the irrigation fluid from the total amount of fluid in the suction apparatus.

Results

In our study we present a clear number of patients, who were radical vulvectomy as well as inguinal and pelvic lymphadenectomy operated. In the case of positive inguinal and negative pelvic lymph nodes , postoperative radiation was limited locally only in the inguinal area and not in the pelvic, since only pelvic lymphnodes excision was sufficient and the patients showed an excellent follow-up without complications

Conclusions

The above results indicate the need of further research with more patients of this issue, as if laparoscopy could leave behind radiotherapy in the pelvic area with good follow-up, it would improve the quality of life of the patients avoiding possible radiation-related complications.

A European survey on tubal surgery and infertility treatment: how, why, when

Angelos Daniilidis¹, George Pados², Stephan Gordts³, Harald Krentel⁴, Michelle Nisolle⁵

¹Hippokratio General Hospital Aristotle University, 2nd University Department of Obstetrics and Gynecology, Thessaloniki, Greece

²Papageorgiou Hospital Aristotle University, 1st University Department of Obstetrics and Gynecology, Thessaloniki, Greece

³Leuven Instituut voor Fertiliteit en Embryologie, Leuven, Belgium

⁴Academic Teaching Hospital of the University Düsseldorf, Head of Department of Clinic for Gynecology- Obstetrics- Gynecological Oncology & Senology in Academic Teaching Hospital, Düsseldorf, Germany

⁵Université de Liège, Chef de Service de Gynécologie-

Obstétrique CHR de la Citadelle Présidente du Département de Gynécologie-Obstétrique, Liège, Belgium

Background

The decision on how to treat tubal diseases, specifically hydrosalpinx, is a difficult one. It involves surgical, medical, social, emotional and economic factors.

This questionnaire based survey among members of ESGE aims to increase awareness of tubal disease diagnosis and treatment with tubal surgery or vitro fertilization (IVF).

Methods

20 questions regarding dilemmas about techniques, strategy, treatment options of tubal infertility were sent between January and March 2019, via email to ESGE members, with various expertise on the field of endoscopic surgery and infertility treatment. Participants answered anonymously. The survey strategy and statistical analysis of the responses was conducted by with Survey Monkey.

Results

50% of the participants were experts performing >90 interventions per year, 26% with advanced experience (60-90 interventions), 20% with moderate experience (31-60 interventions) and 4% with minimal clinical practice (0-30). The most frequent performed procedures were salpingectomy (60%), neosalpingostomy (18%), tubal anastomosis (12%) and tubal occlusion (4%). As for the energy used 58% opted for bipolar, 24% for monopolar diathermy, 12% for ultracision, 4% laser. In case of an incidental finding of hydrosalpinx, 42% always treated it, and 36% occasionally, while 8% only when bilateral and 12% answered never. As for routine administration of antibiotics 46% never used and 30% occasionally, with a 39.5% choosing combination of two antibiotics (25% of doxycyclin or 27% cephalosporines only). No clear outcome was given regarding performing a test for ovarian reserve before surgery (22% always before, occasionally 34%), while the most common test used was. Antimulerian hormone levels (79.59%). Laparoscopy was considered the best method for staging tubal disease in 86% and in case of hydrosalpinx 75.5% used to perform salpingectomy or tubal occlusion always before 1st IVF attempt. As for the best surgical method for the treatment of hydrosalpinx in respect to ovarian reserve for 46% was salpingectomy, for 34% tubal occlusion, for 12% salpingostomy and for 6% hysteroscopic occlusion. The best surgical method regarding IVF outcome was 80% for salpingectomy, and 16% for tubal occlusion. 60% considered the outcome of tubal surgery similar to IVF in case of mild tubal disease, 38% for moderate and 10% for severe tubal disease. Cost effectiveness was for IVF (22%), laparoscopy (32%) and combination of both (44%). Stage of the disease (40%), age of the patient (32%) and male fertility factor (28%), are factors to be considered regarding the strategy for treating infertility.

Conclusions

First-line treatment for women less than 35 years old with minor tubal pathology, is tubal surgery. IVF should be offered if there are other factors in a couple's subfertility, if the patient is >38 years old, if moderate to severe tubal disease is present, and if it has been more than 12 months post surgery.

Laparoscopic cervical cerclage for women with cervical insufficiency – 4 year study at a tertiary hospital in Hyderabad, India

*Niraj Yanamandra*¹

¹Rainbow Hospitals, Obstetrics & Gynaecology, Hyderabad, India

Background

Cervical cerclage has been shown to reduce the incidence of mid-trimester miscarriage and preterm birth with varying degrees of success. Cerclage can be placed via transvaginal or transabdominal approach. Transabdominal cerclage is indicated in cases of congenital short cervix, amputated cervix, marked cervical scarring and previous failed vaginal cerclage. Advances in the field of minimally invasive surgery resulted in development of a new approach to cervical cerclage placement.

Methods

This is a prospective study conducted between December 2014 – November 2018. All surgeries were performed by single surgeon (NY). Women who underwent laparoscopic cervical cerclage for cervical insufficiency in our institution were included in the study. Data were collected from patient's medical records.

Laparoscopic abdominal cerclage was carried out either prior to conception or during early pregnancy. Surgery was performed under general anaesthesia. 5 mm mersilene tape was inserted at the level of isthmus medial to uterine arteries on either side. The knot was tied either anteriorly or posteriorly. All women were discharged within 24 hours of surgery.

Successful outcome was defined as one where the pregnancy resulted in birth of a live baby with no long-term neonatal morbidity. Surgical morbidity including blood loss, perioperative complications and length of hospital stay were also evaluated.

Results

42 women underwent laparoscopic cervical cerclage during the study period. Of these, 6 were pregnant at the time of cerclage while 36 had interval cerclage. Mean duration of surgery was 60 ± 10 minutes. No serious intra- or postoperative complication occurred.

In the interval group 30 (83.33%) women got pregnant within 12 months. 3 pregnancies ended in miscarriage at <12 weeks of gestation. Out of the remaining 27 women, 23 (85.18%) underwent caesarean section between 28 – 38 weeks. At the time of submitting this article, there were 4 ongoing pregnancies.

Of the 23 women who had caesarean section, 2 (8.69%) had developed premature rupture of membranes followed by labour pains needing early preterm delivery at 28 and 31 weeks. Four (17.39%) needed delivery between 34-37 weeks due to medical co-morbidities while 17 (73.91%) had term caesarean delivery.

In those who carried pregnancy beyond first trimester, foetal survival rate was 100%. All neonates had favourable outcome with no long-term morbidity or mortality.

Of the six women who underwent cerclage in early pregnancy, one needed removal of cerclage following severe pelvic infection postoperatively. Five women (83.33%) had term caesarean section.

There were no short-term surgical complications. One woman who had knot tied posteriorly developed recto-vaginal fistula after 3 years. This was repaired laparoscopically.

Conclusions

Laparoscopic cervical cerclage is a safe procedure that results in favourable obstetric outcome in women with cervical insufficiency. It needs advanced laparoscopic surgical skills. Because of small sample size, further studies are needed to confirm our findings.

Spontaneous fertility rate in women with untreated rectosigmoid endometriosis

Simone Ferrero¹, Carolina Scala¹, Umberto Leone Roberti Maggiore¹, Valerio Gaetano Vellone², Cesare Stabilin², Fabio Barra¹

¹IRCCS Ospedale Policlinico San Martino- University of Genoa, Academic Unit of Obstetrics and Gynecology, Genoa, Italy

²IRCCS Ospedale Policlinico San Martino- University of Genoa, Department of Surgical and Diagnostic Sciences, Genoa, Italy

Background

This study primary aimed to detect the pregnancy rate in patients with rectosigmoid endometriosis not undergoing surgical treatment and secondly to evaluate the mode of conception and the modality of delivery in the study population.

Methods

This study was based on the retrospective analysis of data collected prospectively. Inclusion criteria were: diagnosis of recto-sigmoid endometriosis by transvaginal ultrasonography and magnetic resonance imaging enema and desire to conceive. Exclusion criteria were: previous surgery for endometriosis, estimated bowel stenosis >70%, subocclusive symptoms, ultrasonographic diagnosis of hydrosalpinx, history of infertility, previous conception, ureteral stricture, doubtful ovarian cysts or abnormal semen parameters of male partners. At our institution all patients with deep endometriosis desiring to conceive undergo a prenatal consultation aiming to identify the risk factors for infertility. Ovarian reserve is investigated by assessing basal FSH and AMH. Patients are offered to opportunity to investigate tubal patency (by either hysterosalpingography or hysterosonography). Male partners are requested to undergo a semen analysis. Fertility status was investigated at follow-up consultations (every 6 months from the beginning of the attempts to conceive). Women are also invited to immediately inform us in case of conception by email or by a telephone call. Pregnancy was defined as the ultrasonographic diagnosis of intrauterine gestational sac.

Results

The study included 192 women, with a mean (\pm SD) age of 33.4 (\pm 4.1 years). 183 patients were using hormonal therapies to treat endometriosis-related symptoms before trying to conceive. 25 patients (13.0%, 95% C.I., 8.6-18.6%) discontinued the research of the pregnancy because of change of partner (n=9), health problems (n=7) or change of plans (n=9). In these patients, the median length of research of pregnancy was 7 months (range, 2–18 months). 65 patients conceived spontaneously (33.9%; 95% C.I., 27.2-41.0%). The median time required to conceive spontaneously was 10 months (range, 2-34 months). Among the 102 patients who did not conceive spontaneously, 83 underwent infertility treatments. Among 32 patients who underwent intrauterine inseminations (IUI), 9 conceived; the median time to conception was 11 months (range, 9–18 months). Among 68 patients who underwent IVF either immediately (n=51) or after IUI failure (n=17), 29 patients conceived (42.6%), with a median time to conceive of 26 months (range, 10-46 months). The time to conception was significantly higher in patients who conceived by IVF than in those who conceived spontaneously ($p<0.001$) or by IUI ($p<0.001$). Therefore, the total pregnancy rate of the study population was 53.6% (103/192; 95%C.I., 46.3-60.9%). There were 4 miscarriages, 1 termination of pregnancy and 1 ectopic pregnancy. 71 patients delivered vaginally and 26 by caesarean section.

Conclusions

This study shows that in patients affected by rectosigmoid endometriosis without subocclusive symptoms and with bowel stenosis < 70% can be offered to opportunity to conceive without undergoing surgical treatment.

**ES28-0598 -
Free Communication 7**

Laparoscopic cerclage for cervical insufficiency

Ciprian Andrei Coroleuca¹, Diana Elena Comandaşu¹, Cătălin Bogdan Coroleucă¹, Diana Mihai¹, Cornel Petre Brătilă², Elvira Brătilă¹

¹Panait Sirbu Clinical Obstetrics and Gynecology Hospital - Carol Davila University of Medicine and Pharmacy, Obstetrics and Gynecology, Bucharest, Romania

²Euroclinic Regina Maria Minimally Invasive Surgery Hospital - Carol Davila University of Medicine and Pharmacy, Obstetrics and Gynecology, Bucharest, Romania

Background

Laparoscopic cerclage is an alternative surgical procedure for the treatment of cervical insufficiency, which creates a safe cervical canal obliteration. Laparoscopic cerclage is indicated for patients with a history of repeatedly failed transvaginal cerclage or very short cervix due to congenital or surgical abnormalities. Laparoscopic cerclage can be performed prior to conception (prophylactically) or during pregnancy (prophylactically or as an emergency solution). The paper aims to present the technique of laparoscopic cerclage as well as surgical intervention and pregnancy results.

Methods

The study was conducted from March 2017 to March 2019 in two obstetrics and gynaecology clinics and the surgical interventions were performed by two experienced surgeons. The data were collected from patients' observation records.

Results

The study included seventeen patients in which laparoscopic cerclage was performed. Patient history included: recurrent abortions over sixteen weeks of pregnancy through repeatedly failed transvaginal cerclage and short postsurgical cervix. Twelve patients were pregnant at the time of surgery and another five patients were not pregnant at the time of the intervention and achieved a subsequent pregnancy. The average duration of the procedure was 50 minutes (+/- 7 minutes). All patients were discharged at 2.3 days postoperatively. There were no intraoperative or postoperative complications. All patients delivered on term (> 37 weeks of gestation) through caesarean section and no maternal or foetal complications were reported. The cerclage band was maintained in all patients for a future pregnancy.

Conclusions

Laparoscopic cerclage is a safe procedure for the treatment of cervical incompetence and is associated with low maternal morbidity and excellent foetal outcomes. Laparoscopic cerclage is the first line therapeutic solution in specific selected cases with increased obstetrical risk.

**ES28-0637 -
Free Communication 7**

Hysteroscopic chromopertubation- an adjuvant investigation to laparoscopic chromopertubation

Laura Nieder¹, Jürgen Hucke², Mathias Hesselning³

¹Agaplesion Bethesda Krankenhaus, Gynäkologie und Geburtshilfe, Wuppertal, Germany

²Agaplesion Bethesda, Obstetrics and Gynaecology, Wuppertal, Germany

³Agaplesion Bethesda Krankenhaus, Zentrum für Ambulante Gynäkologie, Wuppertal, Germany

Background

Both diagnostic hysteroscopy and laparoscopy including laparoscopic chromopertubation (LCP) are the gold standard operative investigations in patients with infertility. Tubal patency is not only limited by intrinsic tubal disease or extrinsic compression but can also occur in a transient fashion as a result of tubal peristaltic dysfunction and spasm. This does not get accounted for in laparoscopic chromopertubation and can lead to false negative results. We assessed the feasibility of hysterochrompertubation (HCP) as an adjunct investigation to LCP to avoid potential false negative results of LCP.

Methods

All (n= 406) women underwent diagnostic hysteroscopy under anaesthesia using a 5 mm Storz hysteroscope with saline as a distention medium. Spontaneous flow was assessed for. Then 2-5 ml methylenblue was instilled into the uterine cavity and 1-2 minutes time passed. Now diagnostic laparoscopy using a 7mm Storz laparoscope was undertaken. Presence or absence of blue dye in the Pouch of Douglas was assessed for. Then again chromopertubation using the Cohen device was undertaken. Additionally in macroscopic unremarkable tubes hysteroscopy was again performed where the tubes did not transmit the dye. For this a catheter was inserted into the tube under laparoscopic control and pertubation was again performed again assessing for tubal patency.

Results

Patients N=404

Age average: 33,2 (Range 21-44)

Hysteroscopic Flow (normal saline only): Patent on right: n=264 (65%) Patent on left: n=256 (63%)

Hysteroscopic flow of methylene blue: Patent on right: n=349 (85%) Patent on left n=342 (84%)

Laparoscopic flow of methylene blue: Patent on right: n=341 (83%) Patent on left: n= 339 (83%)

Hysteroscopic catheter performed in 7 patients. Patent on right n = 2, Patent on left n=5, both closed n=2

Conclusions

We found a good concordance between the hysteroscopic assessment of tubal patency using methylene blue compared to the laparoscopic chromopertubation. However as our patient demographics have revealed many patients have concordant disease such as endometriosis, adhesions, polycystic ovaries or hydrosalpinges. These conditions in the context of subfertility often render treatment necessary. The exact diagnosis and subsequent treatment such as adhesiolysis, ovarian drilling and excision of endometriotic lesions or coagulation of such is only possible during laparoscopy. Moreover we do not all suggest to replace LCP with HCP, however, we believe it may be a valuable adjunct investigation that is time and cost effective to assess tubal patency. Potential causes of a false negative result at LCP such as tubal spasm may be overcome through this method thus avoiding a misdiagnosis that may lead to the avenue of potentially unnecessary assisted reproductive medicine treatment

ES28-0006 -

Free Communication 8

Two-step hysteroscopy for management of morbidly adherent retained products of conception

Noam Smorgick¹, Ira Rabinovitch¹, Orna Levinsohn-Tavor¹, Ron Maymon¹, Zvi Vaknin¹, Moty Pansky¹

¹Assaf Harofeh Medical Center - Affiliated with Tel-Aviv University - Sackler school of Medicine, Department of Obstetrics and Gynecology, Rishon Lezion, Israel

Background

Retained products of conception (RPOC) may occur as a result of morbidly adherent placenta. In these cases, the hysteroscopic removal of RPOC may be technically challenging. We propose a two-step hysteroscopic approach for the management of these complex cases, with the aim of achieving low rates of postoperative intrauterine adhesions.

Methods

A retrospective review of all cases of RPOC managed by hysteroscopy from 1/2013 to 3/2018. We sought to compare the clinical and surgical characteristics of cases managed by a single procedure versus the two-step hysteroscopy approach.

Results

Of the 358 women who underwent hysteroscopy for removal of RPOC during the study period, a two-step procedure was required in 11 (3.9%) cases. On comparison of the two-step and the single procedure groups, patients were significantly older and the mean RPOC size was significantly larger in the two-step group (35.5 ± 4.1 years versus 30.7 ± 5.9 years, $p=0.01$, and 38.6 ± 9.8 mm versus 22.3 ± 7.5 mm, $p<0.001$, respectively). While the rates of

intraoperative complications were similar between groups, readmission for postoperative fever was more common in the two-step group (18.2% versus 2.0%, respectively, $p=0.03$). Postoperative intrauterine adhesions were diagnosed in 20.0% and 5.2%, respectively ($p=0.05$).

Conclusions

Complex cases of RPOC may be managed by hysteroscopy using a two-step procedure. Although the two-step procedure is associated with increased rates of postoperative fever and intrauterine adhesions, this approach enables the use of hysteroscopy for large and adherent RPOC masses which may have otherwise required uterine curettage.

ES28-0222 - Free Communication 8

Outpatient hysteroscopy service: performance and documentation

David Ejenobo¹, Karim Abdallah¹, Mary Connor¹

¹Sheffield Teaching Hospital NHS foundation trust, Obstetrics and Gynaecology, Sheffield, United Kingdom

Background

The data collection proforma used at the outpatient hysteroscopy clinic has helped to organise patient care and improve patient safety and satisfaction during the procedure. Maintenance and improvement of the standards of care is essential to continued provision of service that meets and surpasses the expectation of our clients.

This service evaluation project sought to evaluate the performance of the data collection proforma used and to suggest improvements that direct its focus to more relevant areas of patient care and safety.

Methods

It was a retrospective study conducted at the outpatient hysteroscopy services of the Sheffield Teaching Hospital NHS foundation trust. We reviewed fifty-two randomly selected proforma of cases done within the year 2017.

Results

A total of 35 variables for the proforma were reviewed. Fourteen (40%) variables were completed in at least 90% of cases and were considered to be excellent parts of the proforma. Twelve (34.3%) variables were completed in 50 to 89% of cases and were considered to be acceptable while 9 (25.7%) variables were completed in less than 50% of cases.

Excellent parts were preop ultrasound, ultrasound description of polyp and fibroids, age, source of referral, previous vaginal delivery, menopausal status, type of hysteroscopy used, distension media, cervical dilatation, aesthetic used vasovagal response, view of the endometrial cavity and diagnosis.

Acceptable parts were LMP, pipelle biopsy before procedure, medication, HRT, pipelle during the procedure, endo cervical appearance, description of endometrial pathology, management and follow up plan.

Poor parts were having had plain killer and information leaflet before procedure, indications for referral, normal endometrium and endometrial thickness on ultrasound scan, history of cone biopsy and D&C and cavity length assessment.

Conclusions

To improve the performance of the proforma, the poor parts of the proforma were reviewed to simplify entry of data or removed where such information is no longer appropriate. The acceptable parts were reviewed to make entry of the information simpler. The proforma was also be made electronic to ensure that all required fields have prompts to fill the information.

**ES28-0340 -
Free Communication 8**

Retrospective study to assess the use of Myosure for removal of endometrial pathology in the outpatient setting

Mohammed Shehata¹, Mamta Pathak², Pratibha Arya¹, Fida Ali¹

¹*Worcestershire Acute Hospitals, Obstetrics and Gynecology, Worcester, United Kingdom*

²*Worcestershire Acute Hospitals, Obstetrics and Gynaecology, Worcester, United Kingdom*

Background

The Myosure resectoscope has been in use since 2009. Our unit has conducted this study to assess the feasibility of performing Myosure resection of endometrial pathology in the outpatient setting in term of success rate and adverse outcomes. Secondary objectives included evaluating patient's acceptability of the procedure and also assessing any cost savings incurred when compared to inpatient day surgery under general anaesthetics.

Methods

This was a retrospective study assessing outpatient cases of Myosure resection procedures performed in a large UK unit. This was conducted over a two year period between January 2016-2018. Reasons for referrals included postmenopausal bleeding, menorrhagia and incidental finding of thickened endometrium. The procedures were performed by three consultants.

Data was collected from our Myosure database, patient's electronic records and outpatient records. Various data were collected including patient's demographics such as age, menopausal status, BMI and co-morbidities. The indication for use of Myosure (polyp vs fibroid); success rate and the incidence of complications were documented.

Patient questionnaires were also handed following the procedure. The questionnaire included a visual analogue scale to assess pain experienced during and post procedure. The second component included questions regarding acceptability of the procedure and whether it would be recommended to others. There was also a free text space for additional comments.

Results

During the study period there were 120 cases treated in our unit. The age range was 28- 90 years of age. 40% of our cohort had a BMI >40 with a range from 20-61. 88% of cases had polyps resected and the remainder were fibroids or fibroid polyps.

Our success rate was 97%. There were no significant complications noted. 97% of patients said they would have the procedure done again and would recommend it to a friend.

There is also great cost saving of over four folds for day case procedure compared to outpatient procedure per case.

Conclusions

Myosure resection is a safe, effective and cost saving outpatient procedure. It also has a great patient acceptability. It should be more widely employed for resection of endometrial polyps and small fibroids.

**ES28-0411 -
Free Communication 8**

Anticipated vs actual pain during outpatient diagnostic and operative hysteroscopic procedures

Kostis Nikolopoulos¹, Manolis Nikolopoulos¹, Dorothea Saragli¹, Chorouk Kohler-Boureq², Pandelis Athanasias¹

¹*Epsom and St Helier Hospitals NHS, Obstetrics and Gynaecology, London, United Kingdom*

²*Epsom and St Helier Hospitals, Obstetrics and Gynaecology, London, United Kingdom*

Background

Hysteroscopy is an established method of investigation and treatment for intrauterine pathologies and abnormal menstrual bleeding. Reduced diameter hysteroscopes and modern hysteroscopic devices allowed the procedures to be performed in an outpatient setting, without the need for general anaesthesia, even when operative interventions are required. Nevertheless, fear of pain can be a deterrent factor for the patients. (1,2) The objectives of this study were to assess the women's perception of pain for diagnostic and operative outpatient hysteroscopy procedures.

Methods

A prospective cohort study was conducted in our office gynaecology unit (St Helier Hospital, London). The cohort consists of 100 women referred for outpatient hysteroscopy between January and May 2019.

50 patients underwent diagnostic OPH and 50 underwent polypectomies with the Myosure hysteroscopic morcellator.

Three experienced specialists performed the procedures, implementing the same technique for all patients. Diagnostic hysteroscopies were performed vaginoscopically with a Karl Storz rigid Bettocchi hysteroscope (Telescope 30°, diameter 2 mm, length 26 cm).

Polypectomies were performed with the Myosure Lite or Reach device through a 6.25 mm rigid hysteroscope. The polyps varied in size from 5 to 35 mm.

A visual analogue scale (VAS) was used for the pain assessment which consisted of 10cm line and range from no pain (left end, numeric value 0) to maximum pain (right end, numeric value 10).

The patients prior to the procedure were asked to document the anticipated intensity of pain or discomfort and post-operatively were asked to report the pain that they experienced during the procedure.

All patients had 1gr Paracetamol and 400mg Ibuprofen 1 hour before the procedure. The patients who underwent polypectomies had 2 ampules of intra and paracervical Lignospan and Instillagel in the cervical canal.

The results then were assessed against patient's menopausal status, parity and duration of the procedure.

Results

Diagnostic hysteroscopy

The actual pain score was significantly lower than the anticipated pain score.

Median anticipated pain: 3.9

Median reported pain: 1.7

Operative hysteroscopy

The actual pain score was lower than the anticipated pain score in all categories.

Median anticipated pain: 5.8

Median reported pain: 2.3

The severity of experienced pain was affected by the menopausal status (higher than average, 2.9) and parity (lower than average in multiparous women, 1.9) in both groups but not by the duration of the procedure.

Conclusions

The pain experienced during operative and diagnostic procedures was significantly lower compared to the anticipated pain. All patients were given information leaflets and the procedures were explained in detail at initial appointment. Patients' education and explanation of the individual unit's statistics should be considered. Fear of the procedure due to unawareness of the pain usually experienced by the patients can lead to women avoiding outpatient operative hysteroscopic treatments.

The future of hysteroscopic surgery for cervical synechiae and stenosis. 24 months of advanced techniques for endocervical recanalization: the case series

Alexander Lazaridis¹, Stewart Disu¹

¹Northwick Park Hospital, Gynaecology, London, United Kingdom

Background

The term cervical stenosis (from Ancient Greek στενός, "narrow") is clinically defined as cervical narrowing that prevents the insertion of a 2 or 3mm wide dilator. The condition may be congenital or acquired, secondary to infection, surgical trauma, postpartum bleeding or pathological processes. The more severe the stenosis, the more likely it is to be symptomatic.

Methods

This retrospective study aims to report on 15 cases of intraoperative diagnosis of cervical synechiae or stenosis, which were successfully managed with an innovative hysteroscopic approach using the Gynecare Versapoint Bipolar Electrosurgery System.

For this technique a 30° 2.9mm miniature hysteroscope with 5mm outer sheath and a 5Fr operative instrument channel (Bettocchi®Karl Storz™) was used. This instrument has been previously described for the successful treatment of over 500 cases with intrauterine pathology by Bettocchi et al. Diagnosis of synechiae or stenosis was established either after a 360° visual assessment of the endocervix or once hydrodilatation techniques failed to achieve passage of the scope alone through the cervical canal. The division of the cervical synechiae was achieved either with grasping forceps or a Versapoint™ twizzle tip electrode (1.6mm nom.) through the 5 Fr channel with settings as per manufacturer (VC1 100 DES 50). An alternative technique once adequate space was created (3mm) was the use of the scissors via the 5 Fr channel.

The most common approach using the Versapoint twizzle was a short, low transverse bipolar energy application between 5 and 7 o'clock of the cervical os, while constantly assessing the endocervical canal by rotating the 30° hysteroscope via the light lead.

During the procedure, energy is delivered from the generator to the tissue through the active electrode. Saline acts as a 'valve', automatically returning the electrosurgical current to prevent overtreatment or carbonisation. This is a safety property of the Versapoint system, which is harmless outside the NaCl 0,9% fluid pocket.

Quarter (90°) or semi-circle (180°) rotation and careful manual hysteroscopic advancement manoeuvres, using the advantage of the oval shaped sheath of the Bettocchi®scope aid in the establishment of the pathway following the division of the synechiae or stenosis. The mean time of the endocervical recanalization procedure was approx. 2 minutes. Average amount of fluid required for this process never exceeded 200mls of NaCl 0,9%. This is due to constant manual control of fluid flow and pressures, which also enables countertraction within the endocervix.

Results

Vaginoscopy and advanced hysteroscopic techniques facilitated synechiolysis in all cases, without significant complications.

Conclusions

The described approach allows access to the endometrial cavity for a variety of purposes or investigations during outpatient/office hysteroscopy or hysteroscopy under general anaesthesia. This innovative technique demonstrates the current advancements in hysteroscopic surgery and should be considered by modern gynaecologists.

<https://player.vimeo.com/video/336452677?autoplay=1>

**ES28-0558 -
Free Communication 8**

Cervical ectopic pregnancy: conservative treatment with methotrexate and uterine artery embolization

Andrey Kozachenko¹, Dmitri Akinfiyev², Leila Adamyan¹

¹National Scientific Center for Obstetrics- Gynecology and Perinatology, Operative Gynecology, Moscow, Russia

²National Scientific Centre for Obstetrics- Gynecology and Perinatology, Radiology Department, Moscow, Russia

Background

Preserving fertility in patients with cervical ectopic pregnancy especially after IVF is serious problem in operative gynaecology.

Methods

63 Women with cervical pregnancies (ages 25-47 years) treated in the operative gynaecology department during 13 recent years were enrolled in prospective and retrospective study. 35 of them underwent combined therapy with preoperative systemic methotrexate chemotherapy with resectoscopic evacuation of embryo; in 16 cases with chorion invasion into the cervix we used selective uterine artery embolization (SUAE) following with minimal invasive surgery for preserving fertility. Additional laparoscopic removal of ovarian teratoma was performed in one case.

Results

Clinical protocol included transvaginal ultrasound investigation with transducer for colour doppler mapping, MRI to visualise gestational sac, boundaries between the chorion and stroma of the cervix; assessment of the blood flow in the chorion, the evaluation of β -hCG in blood serum. In 60 cases diagnostic hysteroscopy followed by resectoscopic removal of the chorion and coagulation of the vessels was performed. The term of pregnancy ranged from 5 to 9 weeks of gestation and the average term was $6,8 \pm 0,9$ weeks. Patients with cervical pregnancy received i/v methotrexate at an average of 50 mg/every 48 hours, 6 mg of leucovorin administered i/m after 28 hours after methotrexate injection. The total dose of administered methotrexate ranged from 200 to 300 mg and depended on the patient's body weight, week of gestation, level of β -hCG and intensity of chorion blood flow. Surgical procedure started at decreased level of β -hCG about 4000-7000 IU/l. SUAE on both sides applied in 12 cases through the right femoral approach and in 4 cases through the right radial artery. Hysterectomy was performed in 3 cases. The effectiveness of organ-sparing treatment of cervical pregnancy is 95,2%.

Conclusions

The results of our study suggest that resectoscopic removing of embryo with previous cytostatic therapy with methotrexate allows to save fertility in young women with early cervical pregnancy. SUAE provides minimal operative bloodloss, more shorter hospital stay and doesn't hurt reproductive function.

**ES28-0264 -
Free Communication 9**

Analysis of the surgical performance and ergonomics of three different robotic laparoscopic needle holders

Francisco Margallo¹, Juan A. Sánchez-Margallo²

¹Minimally Invasive Surgery Center, Laparoscopy, Caceres, Spain

²Minimally Invasive Surgery Center, Bioengineering and Health Technologies Unit, Caceres, Spain

Background

There is a continuous development of robotic devices designed to deal with some of the technical limitations in laparoscopic surgery, which must be exhaustively analysed prior to use in surgical practice. The objective of this work is to evaluate the surgical performance and surgeon's ergonomics using three types of robotic handheld laparoscopic needle holders.

Methods

Kymerax® (Terumo), DEX® (Dextérité Surgical) and Jaimy® (Endocontrol) robotic needle holders were used in this study. Twelve surgeons with different experience in laparoscopic surgery were randomly organised into three groups:

Using the Kymerax® (group A), the DEX® (group B) or the Jaimy® (group C) device. They performed ten repetitions of a precision task, as well as different suturing tasks on organic tissue. Tasks were performed in a random fashion using both robotic (Rob) and conventional (Conv) needle holder. Execution time, precision using the surgical needle and ergonomics of the surgeon were evaluated.

Results

All groups significantly improved execution time after the training period and showed a suturing accuracy during the precision task similar to that obtained with conventional instruments. Regarding the ergonomics, there were no differences in the wrist posture of the surgeons using the robotic and the conventional laparoscopic needle holder on group A. However, elbow extension ($134.681 \pm 14.35^\circ$ vs. $120.631 \pm 13.134^\circ$) and shoulder flexion ($26.122 \pm 7.411^\circ$ vs. $18.475 \pm 14.166^\circ$) were significantly lower with the robotic instrument. Wrist flexion was significantly lower using the handheld device ($-23.723 \pm 11.98^\circ$ vs. $-7.279 \pm 16.372^\circ$) on group B. Group C showed a remarkable reduction of the time with acute back flexion while using the robotic instrument ($44.332 \pm 17.418\%$ of total time vs. $30.297 \pm 7.991\%$ of total time).

Conclusions

The use of robotic handheld needle holders shows a positive learning curve in terms of execution time and precision during laparoscopic suturing. Besides, the use of these devices appears to improve the surgeon's ergonomics compared to conventional laparoscopic instruments.

ES28-0356 - Free Communication 9

Laparoscopic excision of recto-sigmoid duplication cyst

Huseyin Kiyak¹, Kerem Doga Seckin¹, Pinar Kadirogullari¹, Lale Karakis²

¹*Kanuni Sultan Süleyman Teaching and Research Hospital, Obstetric and Gynecology, İstanbul, Turkey*

²*Bahceci IVF Center, Obstetrics and Gynecology, İstanbul, Turkey*

Background

Gastrointestinal system duplication anomalies are rare congenital abnormalities which can be encountered along the gastrointestinal tract from the oral mucosa to the anus. The majority of duplications are cystic 80 % are diagnosed during the first 2 years of age. Colonic duplications comprise 6.8% of gastrointestinal duplications. Rarely, they become symptomatic in adulthood. In this case presentation we aimed to describe the laparoscopic excision of a recto-sigmoid duplication cyst which was preoperatively misinterpreted as an adnexial cyst on MRI.

Methods

A 28 year old G0P0 patient presented to the gynaecology clinic with pelvic pain, dysmenorrhea, dyspareunia and rectal discomfort. MRI revealed a 10x12cm right adnexial mass consistent with an endometrioma. Laparoscopic excision of the endometrioma was planned. On laparoscopic exploration, the 10x12 cm mass was found to be located retroperitoneally within the right paravesical space. Dissection was carried out laterally to the right obliterated umbilical artery. The cyst capsule was reached. Following incision of the capsule, purulent cystic content was observed and the abscess was drained. The inner lining of the cyst resembled bowel mucosa. A colorectal surgeon was invited intraoperatively for consultation. The presence of a sinus tract was suspected on the pararectal side of the cyst wall. To determine if a rectovaginal fistula was present air was injected into the rectum and methylene blue was injected into the cyst. No fistulas were detected. The whole cyst capsule was excised successfully.

Results

The patient was discharged from hospital on the 3rd postoperative day without complications. Histopathological examination of the cyst wall was consistent with a colonic duplication cyst.

Conclusions

Recto-sigmoid duplication cysts are rarely encountered masses which may present as adnexial cysts in adulthood. Knowledge of the pelvic anatomy is imperative for the successful excision of the cyst without complications. Laparoscopy allows a more thorough exploration of the deep pelvis. Even though the excision of infected cysts deep within the pelvis may be challenging, laparoscopy is a safe and effective treatment modality.

**ES28-0049 -
Free Communication 10**

A snapshot of hormone replacement therapy prescribing habits in severe endometriosis patients by BSGE members

Daniel Prekop¹, Oliver O'Donovan¹, Amanda Jefferys¹

¹St Michael's Hospital – Bristol - UK, Gynaecology, Bristol, United Kingdom

Background

Severe endometriosis patients are regularly prescribed hormone replacement therapy (HRT) for bone protection and climacteric symptom relief, but may increase the risk of disease and symptom recurrence. A large systematic review (Gemmell, L.C. et al, 2017) surmised that no definitive conclusions can be drawn as to which form is preferable given the sparse high-quality evidence available. Therefore there is no clear guidance. This study's purpose is to gather data on current practice and gain insight into the rationale behind clinician's prescribing.

Methods

All members of the British Society for Gynaecological Endoscopy (BSGE) were invited to participate in an anonymous online survey. The results were collated and analysed.

Results

There were 159 participants, of whom 50% work in endometriosis centres. Whether menopause is surgical or natural, 48% receive combined HRT and 42% tibolone. Patients who have undergone natural menopause without a uterus receive tibolone in 35% combined HRT in 31% and oestrogen only in 28% of cases. If menopause is surgical the results were similar; 35% receive tibolone, 33% combined HRT and 24% oestrogen only. With gonadotrophin releasing hormone agonist use 83% receive tibolone and 9% combined HRT with a uterus, and 64% tibolone, 10% combined HRT and 17% oestrogen only without. There are varying theoretical rationales behind choices.

Conclusions

This survey demonstrates the variation in prescribing habits for HRT in patients with severe endometriosis, and explores the clinician's reasoning behind their choices. High quality research is required to enable clear guidance to benefit patients.

**ES28-0125 -
Free Communication 10**

Defecation disorders and their association with quality of life among women after (recto)sigmoid resection due to deep infiltrating endometriosis

Aia Al-Saidi¹, Ellen Klinkert², Froukje Hoogenboom¹, Monika Trzpis¹, Paul Broens¹

¹University of Groningen - University Medical Center Groningen, Surgery, Groningen, The Netherlands

²University of Groningen - University Medical Center Groningen, Obstetrics & Gynecology, Groningen, The Netherlands

Background

Deep infiltrating endometriosis (DIE) negatively affects women's quality of life (QoL) and bowel functions. To improve the condition of the patients (recto)sigmoid resection is often performed. The QoL of the patients however still tends to be poorer after the treatment than in a control group. This study explores the relationship between the QoL and fecal problems in women after (recto)sigmoid resection due to DIE.

Methods

In this cross-sectional study we prospectively collected data of 124 adult female patients treated with a (recto)sigmoid resection at the University Medical Centre Groningen between January 2005 and December 2015. All patients completed the validated Groningen Defecation and Fecal Continence questionnaire (DeFec) and the Endometriosis Health Profile (EHP-30) core questionnaire. The core of the EHP-30 questionnaire covers the following domains: "pain", "Control and powerlessness", "emotions", "social support" and "self-image". The score per domain ranges from 0-100, and the lowest scores correspond to the best quality of life. Constipation, fecal incontinence (FI) and irritable bowel syndrome (IBS) were defined according to the Rome IV criteria. Patients with comorbidities, which are known to influence defecation and fecal continence, were excluded from analysis.

Results

Patients had the lowest mean score in case of the domain "control and powerlessness" (33.7, SD +/- 42.8) and the highest in case of the domain "Emotions" (42.8, SD +/- 16.3). When looking at patients with exclusively one fecal disorder, we found that solely constipated patients had significantly higher scores than non-constipated patients in the core domains of EHP-30 ($P < 0.003$ for all the domains). Patients who suffered from exclusively IBS had significantly higher scores in three core domains: "pain" ($P = 0.018$), "emotions" ($P = 0.006$) and "self-image" ($P = 0.035$), when compared to patients without IBS (and neither constipation/FI). FI was not associated with increased scores in any of the EHP-30-core domains. Multiple regression analysis confirmed that constipation and IBS significantly contributed to the prediction of "Pain", "Emotions" and "Self-Image". Furthermore, we found that the constipation symptoms such as "straining", "hard stools", "incomplete evacuation", "blockage sensation", and "<three bowel movements per week" significantly increased the EHP-30 score in case of the "self-image" domain.

Conclusions

Constipation and IBS are the major factors which negatively contribute to decreased QoL among women who had undergone surgery for DIE. It is however still unclear whether the disease, the surgery or both contribute directly to the fecal disorders among women who were treated with (recto)sigmoid resection due DIE. We recommend that following (recto)sigmoid resection due to DIE, attention must be paid to constipation problems and that patients should be offered adequate therapy, such as laxation or pelvic floor muscle training to try to improve the quality of life.

ES28-0143 - Free Communication 10

Deep infiltrating endometriosis conventional laparoscopy versus robotic-assisted laparoscopy: a real debate of the last decade

Eleni Karatrasoglou¹, Vasiliki Hatzirafail¹, Alike Tserkezoglou¹, Marta Maria Kemp²

¹*Euroclinic Hospital, Department of Gynecologic Surgery, Athens, Greece*

²*Federal University of Sao Paulo, Department of Gynecology, Sao Paulo, Brazil*

Background

We have reviewed the latest data regarding patients with deep infiltrating endometriosis who underwent laparoscopic surgery versus the ones who underwent robotic-assisted laparoscopy

Methods

Literature review

Results

Conventional laparoscopy has been the gold standard for endometriosis surgery, including deep infiltrating cases of the disease. Severe endometriosis requires a highly skilled team of surgeons due to the complex surgical procedures that are required. Robotic surgery, despite the higher cost, offers specific technical advantages such as 3D vision, tremor filtration, delicacy of movements, that could improve surgical outcome and decrease the risk of laparo-conversion. First full-length studies demonstrated no significant difference between the conventional laparoscopy and robotic assisted laparoscopy regarding blood loss, postoperative pain and complications. Some of them even suggested that the use of robotic platform may be associated with longer hospitalisation. However, latest data focusing on delayed complications suggest that robotics can reduce bowel leaks and fistulas. Similarly, to bowel leakage, it may be the accuracy of movements that confers a reduced risk of ureteric dissection and leads to fewer urinary leaks and fistulas. In addition, nerve-sparing surgery is an emerging technique for surgery-related dysfunction in deep endometriosis. Robotic platform seems to be advantageous in highly complex procedures where extensive dissection and proper anatomy re-establishment is required. First preliminary results show that robot -assisted surgery could be associated with better preservation of urinary function, sexual well-being and less symptoms of visceral pain.

Conclusions

As a new minimally invasive technique, robotic surgery is safe and efficient alternative to conventional laparoscopy in the treatment of deep infiltrating endometriosis. The latest benefits of robotic technology remain uncertain and the need of new comparative studies is mandatory.

**ES28-0150 -
Free Communication 10**

Laparoscopic management of left endometrioma extending over to the left external iliac artery in a woman who had previous total laparoscopic hysterectomy (TLH)

Ahmet Tevfik Yoldemir¹

¹Marmara University Hospital, Obstetrics and Gynaecology, Istanbul, Turkey

Background

Laparoscopic management of adnexial mass (possible diagnosis being endometrioma extending over to the left external iliac artery) in a premenopausal woman who had previous total laparoscopic hysterectomy (TLH) should be managed bearing in mind the possibility of malignancy as differential diagnosis.

Methods

A 47 year old woman was admitted with the diagnosis of 65mm x 65 mm left adnexial cystic mass with multiple septate. She had a history of chronic pelvic pain. Palpation of the vaginal cuff and rectovaginal septum revealed no pain nor tenderness. Vaginal examination revealed a tender semi-mobile cystic mass on the left adnexial area. Serum CA-125 level was 21.8 U/ml. Bilateral ooforectomy was planned after the patient's consent. During operation the left endometrioma was seen to be attached to the pelvic side wall, even extending over to the left external iliac artery. Sharp and blunt dissection was used to free the endometrioma from the bowel adhesions and from the left external iliac artery. Right ovary was not adherent to the pelvic side wall. Bilateral ooforectomy was done.

Results

The patient was discharged on the postoperative second day. The pathology result came out as left ovary with endometrioma, left hemaosalpinx, fibrotic nodule (from left sacrouterine ligament excision).

Conclusions

Prevalence of endometriosis over the age of 45 is 16 per 1000 (BJOG 2018;125:55-62). The symptoms during that age are mostly non-menstrual pelvic pain or dyspareunia (Gynecol Obstet Invest 2017;82(5):453-461). Age related differences in the sonographic characteristics of endometrioma should be taken into consideration (HR 2016;31(8):1723-31). Before surgical planning predicting the risk of malignancy in adnexial mass should be evaluated (Am J Obstet Gynecol 2016; 214:424-437). For those women who had hysterectomy for adenomyosis or endometriosis, ovary conservation is associated with a relative risk for pain recurrence of 6.1 (95% confidence interval [CI] 2.5–14.6) compared with patients with oophorectomy. The relative risk for a second intervention in patients with ovary conservation is 8.1 (95% CI 2.1–31.3) (Climacteric, 2017;20:2:138-143). In our case, management of deep infiltrating endometriosis by laparoscopic surgery was successful.

<https://player.vimeo.com/video/335694658?autoplay=1>

**ES28-0221 -
Free Communication 10**

Plasma angiogenic biomarkers in endometriosis

Taisiia Melnychuk¹, Carlos Lopez-Gil², Josep Castellvi³, Eva Colas², Elena Suarez-Salvador¹, Antonio Gil-Moreno¹

¹Vall d'Hebron University Hospital, Gynecology, Barcelona, Spain

²Vall Hebron Research Institute, Biomedical Research in Gynecology, Barcelona, Spain

³Vall d'Hebron University Hospital, Pathology, Barcelona, Spain

Background

Neo-angiogenesis has been described to play a role in endometriosis. There is a need for detection of non-invasive diagnostic tools to improve early and accurate diagnosis. The aim of this study was to assess the behaviour of soluble vascular endothelial growth factor receptor-1 (sVEGFR-1), placental growth factor (PIGF) and soluble endoglin (s-

Endoglin) in the plasma of patients with different types of endometriosis and compare them with healthy controls in order to evaluate their potential use as diagnostic biomarkers of endometriosis.

Methods

A prospective study carried out from 2014 and 2018 at a multidisciplinary unit of endometriosis at Vall d'Hebron University Hospital, Barcelona, Spain. Ethics committee approval of Vall d'Hebron Hospital was obtained. 65 patients were included. Out of 65, 39 patients with endometriosis pathology proven were included in group A (endometriosis group: 20 deep endometriosis, 19 ovarian endometriosis) and 26 patients with visual absence of endometriosis confirmed at laparoscopic surgery were included in group B (control group). Blood samples were obtained from all patients preoperatively. Plasma samples were analysed for each factor (sVEGFR-1, PIGF, and s-Endoglin) using commercially available ELISA kits (DVR100C, DPG00, DNDG00; R&D system). Results were normalised using a pool of samples in each plate. Statistical analysis was performed in GraphPad Prism Software (GraphPad version 6.0, San Diego, CA, USA). The non-parametric Mann-Whitney U test was used for comparison between groups. The p-values lower than 0.05 were considered statistically significant.

Results

sVEGFR-1 was significantly higher in the plasma of patients with endometriosis (group A: 19) compared to controls (group B: 10): $403,5 \pm 398$ pg/mL vs $104,3 \pm 114,7$ pg/mL, $P = 0,0118$. Also in the endometriosis groups, classified in ovarian and deep endometriosis, were compared individually to controls. 10 Ovarian endometriosis: $484,4 \pm 471$ pg/mL vs 10 Controls: $104,3 \pm 114,7$; $P = 0,0354$ and 9 Deep endometriosis: $313,6 \pm 299,2$ pg/mL vs 10 Controls: $104,3 \pm 114,7$; $P = 0,0331$. PIGF did not show statistical significance in the plasma of patients with endometriosis (group A: 13) compared to controls (group B: 18): $12,55 \pm 5,351$ pg/mL vs $13,61 \pm 6,203$ pg/mL, or even between the different groups of endometriosis. Finally, s-Endoglin did not show statistical significance in the plasma of patients with endometriosis (group A: 39) compared to controls (group B: 26): $2,796 \pm 0,6408$ ng/mL vs $2,824 \pm 0,5614$ ng/mL, $P = 0,7572$.

Conclusions

The levels of plasma sVEGFR-1 were overexpressed in endometriosis compared to controls, being more prominent in the group of ovarian endometriosis. PIGF and s-Endoglin levels failed to discriminate endometriosis patients. These results represent an approach toward the identification of potential non-invasive diagnostic markers for endometriosis. Further studies are needed with larger number of patients to confirm these results.

ES28-0416 - Free Communication 10

Intraoperative assessment of ureteral perfusion using NIR-ICG in women with ureteral involvement by deep endometriosis after conservative urological procedure: a preliminary study

Giulia Borghese¹, Manuela Mastronardi¹, Diego Raimondo¹, Giulia Mattioli¹, Maria Cofano¹, Renato Seracchioli¹

¹Unit of Gynecology and Human Reproduction Physiopathology,

Dipartimento di Scienze Mediche e Chirurgiche DIMEC- S. Orsola Hospital- University of Bologna, Bologna, Italy

Background

Ureteral involvement (UI) is frequent in women with deeply infiltrating endometriosis (DIE), particularly in those affected by rectovaginal and parametrial endometriosis. This condition is usually asymptomatic, but it can lead to urinary obstruction, hydronephrosis and silent kidney loss. Up to date, the gold standard diagnostic method to investigate the presence of UI remains retroperitoneal dissection with direct isolation and inspection of diameter, course and consistency of both ureters. Concerning its surgical management, if conservative procedures (ureterolysis, nodule removal) fails to restore ureteral anatomy, a ureteral resection followed by either uretero-neo-cystostomy or end-to-end anastomosis is required. Despite good surgical outcomes, surgery for ureteral procedures implies a consistent risk of ureteral complications, such as postoperative hydronephrosis, fistulae and need for secondary ureteral surgery. These latter could be partially due to possible ureteral devascularization during ureteral procedure. Indocyanine green (ICG) is an anionic tricarboyanine molecule, able to bind to plasma proteins into the vascular system and to become fluorescent if excited by near-infrared light (NIR), allowing to intraoperatively visualise tissue vascularization. To the best of our knowledge, this is the first study reporting of NIR-ICG employment in UI surgical treatment for DIE.

Methods

This is a pilot, prospective, mono-centric study on symptomatic and consecutive patients subjected to ureteral surgery for DIE between December 2018 and March 2019. NIR-ICG imaging was used to evaluate perfusion of the affected

tract of the ureter after urological procedure. Twenty-five milligrams of ICG Pulsion® was diluted in 10 ml of soluble water and a bolus of 0.25 mg/Kg was injected intravenously. A near-infrared camera-head was used to visualise the ureteral vascularization. Exclusion criteria were known or suspected allergy to iodide and hyperthyroidism. Ureteral perfusion was intraoperatively evaluated and defined as “absent fluorescence”, “low fluorescence” or “regular fluorescence”.

Results

Twenty patients subjected to ureteral surgery for DIE and NIR-ICG after ureteral procedure were analysed. Of them, 6 (30%) patients had preoperative unilateral ureteral obstruction and dilatation; of them, 2 (10%) had mild hydronephrosis. Ten (50%) patients presented unilateral UI, while the remaining 10 (50%) women a bilateral involvement. Totally, we performed 24 (80%) ureterolysis procedures and 6 (20%) nodule removals. No adverse effects related to ICG use were noted. After ICG injection, the real-time direct visualization of ureteral perfusion showed 28 (93.3%) ureters with a “regular fluorescence”. One (3.3%) ureter exhibited a “low fluorescence” after ureterolysis; in this case we decided to place a double J ureteral stent. One (3.3%) ureter presented an “absent fluorescence” after nodule removal; a ureteral resection with uretero-neo-cystostomy was performed. Conclusion: NIR-ICG imaging is a feasible and safe technique allowing to assess ureteral perfusion after ureteral surgery for UI in women with DIE in order to help surgeon decision.

Conclusions

NIR-ICG imaging is a feasible and safe technique allowing to assess ureteral perfusion after ureteral surgery for UI in women with DIE in order to help surgeon decision.

ES28-0436 - Free Communication 10

An evaluation of multi-disciplinary team meetings in the management of deep infiltrating endometriosis in BSGE endometriosis specialist centres

Caryl Thomas¹, Angharad Jones¹, Richard Penketh¹

¹University Hospital of Wales, Obstetrics and Gynaecology, Cardiff, United Kingdom

Background

Referral to an endometriosis specialist centre in the United Kingdom is indicated if there is suspected or confirmed deep endometriosis involving the ureter, bladder or bowel. The aim is to deliver a holistic approach by offering all available treatment options in a multidisciplinary context. Centres can obtain full accreditation through the British Society of Gynaecological Endoscopy (BSGE) as endometriosis centres. This requires working within a multidisciplinary team and providing a service which includes regular multidisciplinary team meetings.

Methods

A survey was designed to evaluate the provision of multidisciplinary team meetings delivered in both accredited and provisional BSGE Endometriosis centres. The survey assessed details including the appointment of a lead clinician and MDT co-ordinator, the frequency and duration of meetings, financial resourcing, multidisciplinary attendance, referral pathways and protocols, preoperative planning, patient involvement and feedback. This was distributed to all BSGE accredited and provisional centres via email with the use of an online survey.

Results

A total of 73 endometriosis centres were contacted (60 accredited; 13 provisional centres). 36 centres completed the survey with a response rate of 49%. 92% had a designated clinical lead with 74% having a designated MDT co-ordinator. Most MDTs were held on a monthly basis (69%). There were variations in both duration of meetings and financial resourcing (44% were included in job-plans). There were marked variations in the frequency of attendance of specialists at meetings with physiotherapists and clinical psychologists attending on invitation only to discuss particular cases. 'Always in attendance' at the MDTs were the Gynaecologist (100%), Endometriosis nurse specialist (86%), colorectal surgeon (50%), radiologist (77%), administrative support (35%), urology (9%), pain expert (21%), specialist trainees (48%), physiotherapist (0%), clinical psychologist (0%).

Conclusions

Multidisciplinary management is instrumental in providing high quality care for patients with deep infiltrating endometriosis. Co-ordinating and running efficacious endometriosis MDTs relies on effective team work, adequate funding, protected time and appropriate resources. There are variations in the current provision of MDTs within endometriosis centres in the UK. Establishing quality indicators in endometriosis MDTs will reduce variation in clinical practice and help further improve the provision of care.

**ES28-0073 -
Free Communication 11**

Comparison of neovaginoplasty using acellular porcine small intestinal submucosa graft or interceed in patients with Mayer-Rokitansky-Küster-Hauser syndrome

Xuyin Zhang¹, Ding Jingxin¹, Hua Keqin¹

¹Gyn@Obs Hospital - Fudan University, Gynecology, Shanghai, China

Background

Mayer-Rokitansky-Küster-Hauser (MRKH) syndrome is a rare abnormality. The most significant therapy for MRKH syndrome was the creation of a neovagina. In recent years, we performed neovaginoplasty according to Wharton-Sheares-George technique. And we have reported an acellular porcine small intestinal submucosa (SIS) graft for reconstruction of the vagina. On the other hand, as a substitute for the freshly prepared amnion, an absorbable oxidized regenerated cellulose (the interceed) was used in the vaginoplasty. The purpose was to compare using the SIS graft or the interceed in patients with MRKH syndrome undergoing creation of a neovagina.

Methods

In this retrospective study, patients with MRKH syndrome undergoing creation of a neovagina from 2016 to 2018 were retrospectively investigated. Wharton-Sheares-George neovaginoplasty was performed using the acellular porcine small intestinal submucosa (SIS) graft or the Interceed. Patient and surgical data, follow-up information and the female sexual function index (FSFI) scores in the two groups were analysed and compared.

Results

Overall 67 patients were included (24 for the SIS graft, 43 for the Interceed) for analysis. The operating time, the estimated blood loss and return of bowel activity in the SIS graft group were similar with that in the interceed group. However, the total cost in the SIS group was significantly higher than that in the interceed group due to the cost of the SIS graft (\$2570 per graft). All patients had a continuous mould wearing time for 6 months postoperatively and then returned for their follow-up. The mean length and width of the neovagina in the SIS graft group were similar with the interceed group (7.0±0.6 cm vs 7.1±0.8 cm, P=.54, 2.8±0.3 cm vs 2.7±0.5 cm, P=.74, respectively). However, the incidence of granulation at the vaginal apex was higher in the SIS graft group than that in the interceed group (6/24 vs 4/43, p<.001). Sixteen (66.7%) patients in the SIS group and thirty-one (72.1%) in the interceed group subsequently had a sexual partner. There was no statistically significant difference in the total FSFI scores (27.54±4.50 vs 26.81±3.21, p=.71) between the two groups.

Conclusions

Our results demonstrated that Wharton-Sheares-George provided the patients to have satisfactory sexual intercourse. The Interceed played a role in the reconstruction of neovagina no less than the SIS graft.

**ES28-0206 -
Free Communication 11**

Combined surgical technique (laparotomic-hysteroscopic approach) for the complete septate and asymmetric uterus: brief description of a novel technique

Recai Pabuçcu¹, Emre Göksan Pabuçcu¹, Tufan Arslanca¹

¹Ufuk University Faculty of Medicine, Department of Obstetrics and Gynecology, Ankara, Turkey

Background

To describe the novel surgical technique for the correction of complete septate and asymmetric uterus using both laparotomic and hysteroscopic skills concurrently for the correction of endometrial and uterine anatomic texture.

Methods

Medical record of a patient who was diagnosed with a complete septate uterus was reviewed and surgery was decided. A brief explanation of the surgical method is described below.

Results

A 37-year-old woman (gravida 0) was admitted to our clinic with primary infertility. Her medical history was unremarkable except for prior hysteroscopy, appendectomy and right renal agenesis. In her history, she had an unsuccessful hysteroscopic (H/S) attempt due to the surgeon who was not able to find the left cavity but reached the other one. Her hysterosalpingogram (HSG) examination revealed right tubal patency and suspicious right unicorn uterus. The vaginal sonogram revealed single uterine fundus with a large septum dividing the cavity where the appearance was inconsistent with unicornuate uterus. In order to differentiate the diagnosis, we evaluated the uterus via laparoscopy and found that fundus was sole and both Fallopian tubes and ovaries were in natural appearance. In light of these findings, we performed H/S and found the right cavity without a septum. After identification of the right cavity, we were unable to locate the left cavity and the ending part of septum towards cervix at the level of the internal os. According to these findings, we decided to locate the left cavity through the abdomen using laparoscopic incision of the left cornual area. However, lack of tactile sensor during laparoscopy restricted us from locating the left cornual region precisely and we decided to do a mini-laparotomy to perform the procedure. During laparotomy, bilateral 1 mm incisions were performed through uterine corns and hysteroscopes were placed towards the cervical channel and internal os. Both hysteroscopes were pushed through the cervix in order to locate both uterine cavities accurately. Under the guidance of hysteroscope, a small incision was performed by mechanical scissors from left to right cavity and then operative H/S was performed using bipolar electrocautery to incise large and asymmetric septum. At the end of the surgery, adequate single uterine cavity was formed. One month after surgery, HSG was performed and a normal uterine cavity was identified.

Conclusions

We underlined two important aspects in this case:

Firstly, suspicious unicornuate uterus image in HSG should be carefully evaluated since not all cases are diagnosed with unicornuate and such cases may hinder large atypical septum.

Secondly; in the presence of a large septate uterus, surgical exposure may not be suitable for septum resection and a surgeon may locate separate uterine cavities by inserting a device from the corneal region in order to locate the septum precisely. Eventually, our patient is 28 weeks pregnant.

ES28-0582 - Free Communication 11

Peritoneal graft for cervicovaginal reconstruction in nineteen patients with congenital uterine cervical vaginal atresia

*Hongxin Pan*¹

¹*Luohu People's Hospital, Gynaecology, Shenzhen, China*

Background

Congenital cervical and vaginal malformations is a rare müllerian malformation of the female reproductive tract. Delays in the diagnosis and treatment of this condition can result in endometriosis, which can cause irreversible reproductive damage. The management of cervical atresia remains controversial because there is no guideline nor carefully designed cohort or randomised trials to support a best surgical practice. Uterovaginal anastomosis is the restoration of the genital tract by direct suturing of the isthmus uteri to the vagina. It offers an alternative for patients to maintain menstruation. However, the experience from reconstructive uterovaginal anastomosis is limited. To assess the efficacy, safety, and functional outcomes of a novel laparoscopic uterovaginal reconstruction (Luohu III procedure) in patients with congenital uterine cervical vaginal atresia.

Methods

From January 2015 to January 2017, a total of 19 patients (mean [SD] age, 15.5 [4.8] years) with congenital vaginal atresia underwent laparoscopic cervicovaginal reconstruction (Luohu III procedure). In cases with associated vaginal aplasia, laparoscopic peritoneal vaginoplasty was performed concomitantly. Follow-up assessment was performed at 1, 3, and 6 months, and then yearly.

Results

Of 19 patients with congenital uterine cervical vaginal atresia, cervical dysgenesis and vaginal agenesis was observed in 13 (68.4%), and vaginal dysgenesis in 6 (31.6%). The Procedure was successfully completed in all patients. Mean

(SD) follow-up after surgery was 1.1(0.6) years. Vaginal length was 8.5 (1.5) at 6-month follow-up. 6 patients are sexually active, and report it to be satisfactory. One patient conceived after reconstruction.

Conclusions

Peritoneal graft for cervicovaginal reconstruction may be regarded as a fast, effective and minimally traumatic technique that has satisfactory anatomical and functional outcomes for patients with congenital uterine cervical vaginal atresia, and radical treatment such as hysterectomy can be averted. However, long-term reproductive outcome in these young girls will require further follow-up.

ES28-0056 - Free Communication 12

Cold scissors ploughing technique in hysteroscopic adhesiolysis: a comparative study

Dabao Xu¹, Xingping Zhao¹, Bingsi Gao¹, Qiong Pan¹, Chunxia Cheng¹

¹The 3rd Xiangya Hospital of Central South University, Gynecology, Changsha City, China

Background

The standard intrauterine adhesion (IUA) treatment method is hysteroscopic adhesiolysis (HA, also called transcervical adhesion resection, TCAR). However, there is no consensus on which hysteroscopic method is preferable (energy based using of an electrode or mechanically using a cold scissors?). The scar tissue on the surface of the intrauterine cavity is a critical issue as it might prevent the blood supply to the endometrium and cause the uterine cavity to shrink as well. Neither are there a consensus on the method of how to deal with the scar tissue on the surface of the intrauterine cavity (cut the scar into several parts using a ploughing technique or resect and remove the scar tissue, or just leave the scar tissue alone?). This study is to explore the efficacy, feasibility and safety of cold scissors ploughing technique in HA for intrauterine adhesions.

Methods

Between January 2016 and October 2017, 179 IUA patients who had undergone HA at the Third Xiangya Hospital of Central South University were retrospectively enrolled in this study. They were collected into three groups according to the surgical technique used. The groups were: cold scissors Ploughing Group (PG: use cold scissors to dissect the adhesion and cut the scar tissue using a ploughing technique) (n=81); Traditional Group (TG: use cold scissors to dissect the adhesion, but not deal with the scar tissue) (n=42); and, Electrosurgical Group (EG: use resectoscope to dissect the adhesion with an energy L-hook electrode, and not deal with the scar tissue) (n=56). American Fertility Society (AFS) scores before and after HA, along with postoperative pregnancy rates and live birth rates were studied to determine surgical efficacy. Feasibility was evaluated by technique replacement rates. Safety was evaluated by intra- and postoperative complication rates.

Results

There is no statistical difference between the groups regarding preoperative information ($P>0.05$). While there were significant differences between PG and TG, as well as PG and EG in: postoperative AFS scores (PG vs TG: 2.53 ± 1.07 vs 3.17 ± 1.45 , $p=0.007$; PG vs EG: 2.53 ± 1.07 vs 3.32 ± 1.29 , $p<0.001$.); pregnancy rates (PG vs TG: 58 (71.6%) vs 20 (47.7%), $p=0.019$; PG vs EG: 58 (71.6%) vs 23 (41.1%), $p<0.001$); and live birth rates (PG vs TG: 46 (56.8%) vs 16 (38.1%), $p=0.039$; PG vs EG: 46 (56.8%) vs 13 (23.2%), $p<0.001$). In PG, there were no surgical complications such as uterine perforations, moderate or severe fluid overload, heavy uterine bleeding, nor any surgical technique replacements (for example, transfer to use a resectoscope).

Conclusions

Cold scissors ploughing technique in HA is effective, feasible, and safe, which is worth further study.

**ES28-0045 -
Free Communication 12**

Prospective study of the effect of drug preconditioning on the prognosis of patients with intrauterine adhesions

Limin Feng¹, Zhang Qi¹

¹Beijing Tiantan Hospital, Obstetrics and Gynaecology, Beijing, China

Background

To compare the clinical observational study between the preoperative application and the prognosis of intrauterine adhesions between the two groups without preoperative hormone therapy.

Methods

From July 2016 to October 2018, admitted to Beijing Tiantan Hospital Capital Medical University. Patients with moderate to severe adhesions were randomly included in the preoperative medication group and the preoperative non-medication group and the basic information of the patients was collected. After 2 months of pre-treatment with hormone and nutrient endometrial drugs, the patient's PBAC score and AFS score were evaluated again, in parallel with TCRA. Patients in the non-drug group were treated with TCRA directly. The PBAC score and AFS score were evaluated after 2 cycles of co-nutrition endometrium. The pregnancy status and prognosis of the two groups were followed up.

Results

1. A total of 121 patients were followed up and randomised to the two groups. The baseline balance between the two groups was comparable ($P>0.05$). In the preoperative group, the AFS score of 37 patients decreased (52.11%), and 15 of the 23 amenorrhea patients (65.22%) recovered menstrual cramps to varying degrees. A total of 43 patients (89.58%) had menstrual flow. The improvement was significantly different between AFS score and PBAC score before and after medication ($P<0.01$). 3. The length of operation, the amount of perfusate, the difference of AFS scores and the PBAC scores between the two groups were statistically significant ($P<0.01$). 5. 31 patients in the medication group had a successful pregnancy (56.36%). In the non-medicated group, 20 patients had successful pregnancy (48.78%) and the last menstrual period of pregnancy was 8.32 ± 7.65 months from the last operation time. There was no significant difference in pregnancy rate, the improvement of AFS score and PBAC score with the pregnancy rate, the incidence of postpartum and postpartum complications and the abortion rate between the two groups ($P>0.05$).

Conclusions

1. Preoperative preconditioning can effectively reduce the preoperative AFS score and improve the patient's menstrual flow. 2. Preoperative pretreatment can significantly reduce the operation time of patients and reduce the amount of perfusion solution. 3. Preoperative preconditioning can effectively improve the final AFS score of patients with intrauterine adhesions. 4. Preoperative preconditioning can significantly improve the degree of menstrual rehydration and improve the patient's menstrual pattern. 5. Preoperative pretreatment is not superior to untreated patients in terms of increased pregnancy rate and decreased abortion rate. 6. According to the curve of pregnancy-related pregnancy rate, the probability of success of pregnancy is significantly decreased after prolonged intrauterine adhesions. 7. The pregnancy rate after intrauterine adhesions was not significantly correlated with the degree of AFS score reduction and the improvement of PBAC score. 8. Preoperative preconditioning does not reduce the incidence of obstetric-related complications.

**ES28-0152 -
Free Communication 12**

Hysteroscopic enlargement metroplasty for hypoplastic uterus

Perrine Capmas¹, Marie Emmanuelle Neveu¹, Elsa Scetbun¹, Hervé Fernandez¹

¹Hopital Bicetre, Gynecology, Le Kremlin Bicetre, France

Background

Women with hypoplastic uterus sometimes have impairment in obstetrical outcomes. Diagnosis of hypoplastic uterus is often performed by hysterosonography. Operative hysteroscopy for metroplasty can be performed in these cases. Aim of this study is to evaluate enlargement metroplasty on obstetrical outcome and fertility in women with hypoplastic uterus.

Methods

This study is a monocentric retrospective study which took place from 2012 to 2018 in the gynaecologic department of a teaching hospital. Women who had a hysteroscopic enlargement metroplasty for hypoplastic uterus were included. Hysteroscopic enlargement metroplasty were performed using a 5mm operating hysteroscope with a bipolar versapoint electrode. The myometrium was incised on both sides from the fundus to the isthmus. Incisions were less than 7mm.

Results

Thirty three women were included. Mean age was 36 (+/- 0.85) years old. Before enlargement metroplasty, 29 women (85%) had an infertility with a previous IVF failure in 9 women (31%). Out of these 29 women, 19 didn't achieve any pregnancies, 8 had one or more previous early foetal loss and 2 had a previous late foetal loss. Only 4 women had a living child, one with a premature delivery between 24 and 31, 2 with a delivery between 32 and 36 and one after 37 weeks of gestation.

After enlargement metroplasty, 1 woman was lost for follow-up and 4 didn't try to be pregnant. Out of the 28 remaining women, 15 were pregnant (54%) and gave birth to 19 living children (11 were spontaneous (60%) and 8 after IVF including 5 after oocyte donation) and 2 are still pregnant, 2 had only early or late foetal loss (11%), 1 had an ectopic pregnancy and 10 didn't achieve pregnancy (4 despite IVF including 2 oocyte donation).

Conclusions

Enlargement metroplasty for hypoplastic uterus seems useful to achieve spontaneous or post IVF pregnancies. It also seems to improve obstetrical outcomes.

ES28-0569 -

Free Communication 12

Uterine didelphys - a case of uterine rupture at 14 weeks gestation

Laura Beatty¹, Adeeb Hassan¹

¹NHS Lanarkshire, Gynaecology, Glasgow, United Kingdom

Background

27 year primarous female, fit and well with nil past medical or family history of note. Booking scan revealed a uterine didelphys with an ongoing intrauterine pregnancy of 12 weeks gestation within the left uterine horn. Patient had been due to attend for consultant antenatal booking review however presented acutely to maternity triage at 14 weeks gestation. Patient presented with acute severe abdominal pain and clinical shock. Bedside ultrasound scan revealed a large volume haemoperitoneum with an empty uterus and the foetus present in the abdominal cavity with nil foetal heart visualised. Patient was transferred urgently to emergency theatre for resuscitation and laparoscopy and proceed for treatment of a suspected ruptured left horn of uterine didelphys.

Methods

Patients antenatal records, scan and theatre findings, operation notes, postoperative recovery, postoperative imaging and ongoing management plan discussed.

Results

Patient transferred to emergency theatre for resuscitation and laparoscopy and proceed for suspected ruptured left horn of uterine didelphys. Routine entry into abdomen revealed a 3 litre haemoperitoneum and a 14 week foetus with no signs of life free in the upper abdomen. Uterine didelphys with ruptured left horn, placental tissue and active bleeding visualised. In view of haemodynamic instability and gestational age, laparoscopy was abandoned and decision made to proceed to laparotomy and removal of left ruptured horn. 3 litres of blood clot, foetus with nil signs of life and placental tissue removed. Left ruptured horn removed and left salpingectomy performed with haemostasis achieved. Patient received 7 units packed red cells, 4 units fresh frozen plasma and 1 unit cryoprecipitate intraoperatively. Patient transferred to High Dependency Unit for postoperative care. Patient was subsequently discharged home 1 week postoperatively with bereavement support.

Conclusions

Patient underwent an uneventful postoperative recovery, along with bereavement support. Follow up MRI 2 months postoperative revealed an anteverted right horn of uterus, normal ovaries and nil evidence of any congenital anomalies. Scarring was noted at the previous surgery site at the left side of internal os, the stroma appeared intact

however no overlying myometrium was visualised. A targeted ultrasound was advised following discussion with radiology. Ultrasound revealed thick myometrium from the fundus to cervix with all measurements >10mm thickness. At the level of internal os, the left side was slightly thinned in comparison to right, however myometrium was visualised at the internal os, with right side measuring 7.6mm, and left side 6.1mm. Following postoperative imaging, patient and partner were reassured that a further pregnancy was not contraindicated however were advised to abstain from further conception for a 1 year period. In future pregnancy a plan is in place for consultant led antenatal care throughout pregnancy with serial scans and elective preterm delivery via caesarean section.

ES28-0632 - Free Communication 12

Hysteroscopic septoplasty: an efficient surgery in infertility? A retrospective study

Linda Tebache¹, Laetitia Rousseau¹, Géraldine Brichant¹, François Closon¹, Stavros Karampelas¹, Michelle Nisolle¹
¹University of Liege, Obstetrics and Gynecology, Liège, Belgium

Background

Septate uterus are the most common anomaly found in women with a poor reproductive history such as numerous spontaneous abortion, primary infertility. Hysteroscopic septoplasty restores the uterine anatomy and is a safe procedure. The aim of this study was to determine the obstetric outcome after hysteroscopic septoplasty in women with primary infertility or recurrent pregnancy loss

Methods

In an observational single centre study, we retrospectively evaluated the reproductive outcome after hysteroscopic septoplasty in 48 women with septate uterus and primary infertility or recurrent pregnancy loss. The surgeries took place in the University of Liège gynaecologic department – CHR de la Citadelle- from July 2015 to December 2018. We further analysed the peroperative and postoperative complications as secondary outcome. We separated the patients into three different groups depending on the main complaint: primary infertility, recurrent pregnancy loss or other surgical indications or adverse obstetrical pathologies.

Results

Forty-eight women were treated by hysteroscopic septoplasty. The treatment resulted in an overall pregnancy rate for all groups of 58.33% (28/48). The overall life birth rate was 31.25% (15/48) (with 7 ongoing pregnancies, 22/48: 45.83%). The median time interval between surgery and pregnancy was 6 months. In the sub-groups, the overall pregnancy rate was 68.4 % (13/19) for the women presenting a primary infertility and 76.92% (10/13) and for those with recurrent pregnancy loss. In the third group (all other indications for surgery and other obstetrical pathologies) the overall pregnancy rate was 26.3 % (5/19) and the life birth rate was 21.0% (4/19). We further examined the per- and postoperative complications and had a complications rate of 4% (2 uterine perforations/48). Seventy-five percent of the patients had a postoperative office hysteroscopy with 10% of surgical revision by scissors during the procedure.

Conclusions

Hysteroscopic septoplasty is a safe and simple technique with few complications that can improve the obstetrical outcome in patients presenting a septate uterus with history of recurrent pregnancy loss or primary infertility. We strongly recommend treating those women by minimal invasive surgery.

ES28-0220 - Free Communication 13

A case of spontaneous bowel perforation in labour secondary to endometriosis

Hannah Draper¹, Thomas Keith Cunningham¹, Kevin Phillips¹

¹Hull University Teaching Hospitals NHS Trust, Obstetrics & Gynaecology, Cottingham, United Kingdom

Background

We report the case of a 33 year old lady with spontaneous bowel perforation during a vaginal delivery secondary to known endometriosis. Recent laparoscopy had demonstrated significant endometriosis involving both uterosacral ligaments, with bowel fixed to both sides and the left ovary fixed to both bowel, pelvic side wall and uterosacral

ligaments. It was noted that the bowel was adhered to the posterior aspect of the uterus. Following laparoscopic treatment of endometriosis, bilateral uterolysis, adhesiolysis, resection of endometriosis off bowel and left salpingectomy for hydrosalpinx she underwent successful IVF treatment for primary subfertility. Following an uneventful antenatal course, induction of labour was commenced at 38 weeks due to mild foetal growth restriction and diminished foetal movements. Shortly after insertion of cervical balloon catheter her membranes spontaneously ruptured and she progressed rapidly in labour. She had a spontaneous vaginal delivery of a 2940g healthy baby girl after a 12 minute second stage.

Day 1 postnatally she became unwell with sudden onset chest pain, shortness of breath, cough and hypoxia. She was commenced on treatment dose low molecular weight heparin for a suspected pulmonary embolism whilst investigations were arranged. Chest x-ray and computed tomography (CT) pulmonary angiography demonstrated no pulmonary embolism but noted a pneumoperitoneum. Subsequently a CT abdomen/pelvis demonstrated multiple gas locules anterior to the liver, within the bowel mesentery and tracking along the hypertrophied uterus within the deep pelvis together with an extraluminal pocket of gas within the distal sigmoid colon at the junction with the rectum suggestive of bowel perforation. She underwent exploratory laparotomy, washout and loop sigmoid colostomy for rectosigmoid perforation with purulent peritonitis. The previously noted distal loop of sigmoid plastered to the back of the uterus was found to be perforated, and it was felt that the adhered colon had perforated due to traction in labour. She subsequently made a good post-operative recovery.

Life-threatening complications of endometriosis occurring in pregnancy such as uterine rupture, bowel perforation and spontaneous haemoperitoneum are rare. However, it is likely that they are under reported in the literature and could be expected to increase due to the continuing success of assisted reproductive technologies in women with deep infiltrating endometriosis. There is currently insufficient evidence to suggest prophylactic surgery, however, this case raises interesting questions in the prenatal optimisation of women with endometriosis seeking fertility.

ES28-0371 -

Free Communication 13

Decidualisation of adenomyoma mimicking cornual pregnancy

Tolga Karacan¹, Huseyin Kiyak², Kerem Doga Seckin², Lale Susan Karakis³

¹Bagcilar Education and Research Hospital, Obstetrics & Gynecology, Istanbul, Turkey

²Kanuni Sultan Suleyman Teaching and Research Hospital, Obstetrics and Gynecology, Istanbul, Turkey

³Bahceci IFV center, Obstetrics and Gynecology, Istanbul, Turkey

Background

Adenomyosis is defined as the presence of endometrial stroma and glands within the myometium with various degrees of smooth muscle hypertrophy surrounding these areas.

Adenomyosis maybe focal or diffuse. Adenomyomas, cystic juvenile adenomyosis and polipoid adenomyosis are focal forms of adenomyosis. Adenomyomas appear as ovoid masses with ill defined borders within the myometrium.

Here we present the laparoscopic management of a case of focal adenomyosis with decidualisation misdiagnosed as a cornual pregnancy.

Methods

A 27 year old gravida 2 parity 1 patient with a history of one caesarean delivery was admitted to the emergency department with delayed menses and pelvic pain. No intrauterine sac was visible despite a beta hCG level above 1500 lu. A mass resembling a cornual pregnancy was visualised on the right cornual area. The patient was hospitalised and a single intramuscular dose of methotrexate was administered. A second dose of methotrexate was administered one week later as the beta hCG levels did not decline. On the 12th day of methotrexate, the patient reported increasing abdominal pain and the decision to perform a laparoscopy was made as free pelvic fluid was visualised on ultrasonography.

On laparoscopic exploration, a left sided tubal ectopic pregnancy was detected. On the right cornual area a 4cm mass resembling a fibroid was observed. A right salpingectomy was performed. The fibroid like mass on the right cornual area was resected to avoid the possibility of misdiagnoses in the future. The fibroid was divided into two with ultrasonic energy and the two halves of the fibroid were excised. The myometrium was sutured in double layers.

Results

The patient was discharged from hospital 24 hours postoperatively without any complications. The histopathologic examination revealed adenomyoma with decidual changes. She reported considerable improvement in her dysmenorrhea in the 3rd-4th months postoperatively.

Conclusions

Decidualisation of ectopic endometrial tissue within adenomyotic foci or endometriomas may lead to misinterpretation of findings and misdiagnoses. In the present case, based on ultrasonographic findings, the ectopic pregnancy was thought to be located in the right cornual area when in fact it was found to be situated within the left fallopian tube. Endometriomas harbouring decidual changes may appear to have papillary projections with the central blood flow on ultrasonography, leading to the suspicions of ovarian cancer. Reevaluation of pathological findings after the decidual changes have subsided may lead to more accurate diagnoses

<https://player.vimeo.com/video/336435686?autoplay=1>

ES28-0681 -

Free Communication 14

Optimum first-line therapy for treating heavy menstrual bleeding associated with von Willebrand Disease

*Ozlem Turan*¹

¹*Katharine Dormandy Haemophilia and Thrombosis Centre - Royal Free Hospital NHS Trust, Gynaecology- Haemophilia and Thrombosis, London, United Kingdom*

Background

Previous studies have shown that 78–92% of women with VWD suffer from heavy menstrual bleeding (HMB), compared with a 25% prevalence among women of reproductive age. The National Heavy Menstrual Bleeding Audit, 2013, has revealed that 18% of women reported not having received any treatment in the first year following their outpatient visit. This is likely to include a proportion of women with a bleeding disorder.

An unpublished local data has shown that 3/10 Consultant Gynaecologists have encountered a woman with HMB associated with a form of haemophilia in the preceding three years and they all involved a Haematologist in order to plan the first line of treatment.

We performed a retrospective observational study looking at management and outcomes of HMB associated with moderate-severe VWD.

Our aim is to present these findings and use it as a tool to educate primary/secondary care clinicians on how to formulate treatment plans to help avoid delay in initiating optimum first-line therapy.

Methods

Retrospective observational study including 51 women seen in the joint Gynaecology/ Haematology Outpatient Clinic at Katharine Dormandy Haemophilia and Thrombosis Centre, Royal Free Hospital NHS Trust, London

Data collected included information on diagnosis of VWD, presenting problem and other medical background, PBAC and ISTH BAT score. Management plans and outcomes were also collected

Data from the medical records was entered onto a database and statistically analysed.

Results

The main symptoms leading to diagnosis were epistaxis and easy cutaneous bruising in the severe cohort and HMB in the moderate cohort. The average pictorial blood loss assessment score was 1058 and 363 in the severe and moderate cohorts respectively. 58% severe and 50% moderate women had a history of anaemia requiring iron therapy. Haemorrhagic ovarian cysts were reported in 64% of women with severe VWD and 12% of women with moderate VWD; 38% required treatment.

All women were given mainly single agent First Line Therapy (FLT) for HMB, including Tranexamic acid (TXA) or hormonal contraceptive (COC).

63% and 71% of women from the severe and moderate cohorts, respectively, did not respond to FLT, thereby requiring mainly double agent second line therapy (SLT), including COC + TXA or Mirena IUS + TXA as the top two choices across both groups of disease severity.

41% and 35% of women from the severe and moderate cohorts, progressed to requiring combination third line therapy, including TXA with COC and / or Desmopressin, Mirena IUS with TXA and factor concentrate, endometrial ablation with insertion of Mirena IUS.

Hysterectomy was performed in 3 (6%) of women.

Conclusions

Provision of combination therapy can reduce the need for surgical intervention. Optimum combination therapy involves TXA + Mirena IUS/ hormonal therapy. If this is inadequate, then a Haematologist can be consulted for discussion regarding addition of Desmopressin or factor concentrate.

ES28-0653 -

Free Communication 14

Pilot study for the evaluation of feasibility and effectiveness of a hysteroscopic resection of G0 submucous myomas with double-wave diode laser in outpatients setting

Gaetano Perrini¹, Pietro Simone Filitto¹, Nicoletta Biglia¹

¹"Ordine Mauriziano di Torino" Hospital, University of Turin- Department of Obstetrics and Gynaecology, Torino, Italy

Background

Hysteroscopic treatment of submucous myomas is an effective and minimally invasive treatment, but the technique depends on the intramural extension of the myoma. Resectoscopic myomectomy by slicing still represents the "gold standard" but there are highly effective treatment techniques in "office" setting: hysteroscopic resection with bipolar electrodes or mechanical morcellation. The availability of double-wave diode laser in hysteroscopy takes to consider another potential effective tool to achieve the destruction of uterine fibroids. Our aim is to analyse the feasibility and effectiveness of G0 myomas laser-resection in outpatients setting (in order to replace the bipolar myomectomy, standard treatment of our Outpatients Hysteroscopy Centre).

Methods

Pilot study including 22 women, all our 2018 cases of G0 submucous myomas, undergoing office laser-myomectomy. Hysteroscopy was performed using a 4.7 mm continuous-flow operative office hysteroscope; vaginoscopic approach, saline as distension medium. Neither anaesthesia nor analgesia were used. We approached the myoma with a typical resection, using the fibre apex to cut tissue obtaining slices (with simultaneous haemostasis), removed with 5 Fr graspin forcep/tenaculum. We considered the success rates of procedures (completed hysteroscopy, completed myomectomy, solved AUB), procedural data, pain (through Numeral Rating Scale 0-10) and complications. Follow-up: transvaginal-ultrasounds at 1 month and, if still evidence, second office hysteroscopic "see & treat" procedure at 2 months.

Results

Mean age 46.5 years, 77% non-menopausal; 45% with history of dysmenorrhea and/or chronic pelvic pain, 64% with AUB. Suspected/detected fibroid in 68%. Mean fibroids size: 22 ± 10 mm; 36% < 20 mm, 50% 20-29 mm, 14% ≥ 30 mm. Site: 18% fundus, 5% anterior, 27% posterior, 45% lateral walls, 5% isthmus. Success in 100% of cases; no interrupted procedures. Complete removal: 1 procedure in 68%, 2 in 32%. Number of cervical hysteroscope passages: 3 ± 1; mean inflow pressure: 93 ± 14 mmHg. Pain means: 6.2 ± 1.7 (expected), 2.8 ± 1.9 (average), 4.2 ± 2.3 (maximum), 0.6 ± 0.6 (discharge); slight sensation of heat when prolonged laser action and/or onto the fibroid base. Mean operative time: 22 ± 13 min. Mean observation time: 46 ± 17 min. No complications; butilscolamine given in 2 cases. 4 patients would have preferred sedation. AUB solved in 100%.

Conclusions

Hysteroscopic myomectomy is the most minimally invasive treatment for submucous myomas: safe, tolerable and effective procedures either in case of a "see & treat" approach or after endometrial preparation. Double-wave diode laser can be fully considered one possible device to perform resolute fibroid resections (but also myolysis): the focused energy at 1470 nm cut-vaporises tissue and at 980 nm coagulates blood vessels in the area. Aware of still

possible concerns, studies to investigate and compare this approach are needed, in order to deepen and establish the procedural parameters related to laser use (settings and techniques).

ES28-0636 - Free Communication 14

Diagnostic vs operative office hysteroscopy in infertile women: a retrospective analysis of the in-vitro fertilization (IVF) outcomes and the embryological data

Anastasios Makedos¹, George Pados¹, Leonidas Zepeiridis¹, Anastasia Desli¹, Grigoris Grimbizis¹, Efstratios Kolibianakis¹

¹Aristotle University of Thessaloniki, 1st Department of Obstetrics and Gynaecology, Thessaloniki, Greece

Background

Diagnostic hysteroscopy doesn't seem to improve the IVF outcome according to recent randomised controlled studies. There is very low evidence that correction of minor intrauterine pathology may lead to pregnancy by IVF. We would like to study if the correction of minor intrauterine lesions by office hysteroscopy can improve the IVF outcomes, compared to diagnostic office hysteroscopy only, taking into consideration the embryological characteristics of the IVF cycle that led to pregnancy or live birth.

Methods

We studied the data of infertile women who underwent office hysteroscopy, during the last 3 years in our Unit of Human Reproduction, due to failed implantations after IVF and/or ultrasonographic findings of endometrial pathology. In Group A (N= 56, mean age= 37.6 years) no endometrial pathology was found (diagnostic office hysteroscopy group) and in Group B (N=50, mean age= 37.5 years) minor endometrial lesions (polyps, minor septums, adhesions) were detected and corrected (operative office hysteroscopy group). All women further underwent one or multiple IVF cycles with fresh or frozen embryo transfers until pregnancy.

Results

Between the two groups (Group A vs Group B) no difference was found regarding the age (37.6 vs 37.5 years, $p=0.89$), the number of embryos transferred at the cycle with a positive pregnancy test as an outcome (1.92 ± 0.12 vs 1.76 ± 0.13 , $p=0.439$), the number of embryo-transfers needed after hysteroscopy to achieve positive pregnancy test (1.64 ± 0.16 vs 1.47 ± 0.17 , $p=0.46$) or ongoing pregnancy (1.75 ± 0.27 vs 1.66 ± 0.28 , $p=0.87$) after embryo transfer. No statistical significant differences were also found between the two groups when embryos at a blastocyst stage were transferred. In Group A, 50.8% of the women had negative and 49.1% positive pregnancy test and in Group B, 51.1% had negative and 48.3% positive pregnancy test, after one or multiple embryo-transfers, without statistical significant difference ($p=0.947$).

Conclusions

In this study all women were exposed to the possible effect of office hysteroscopy on the final outcome of IVF, guided either by previous failed implantation or ultrasonographic findings. The results indicate that the removal of minor endometrial pathology doesn't improve the IVF outcome or decrease the number of embryo-transfers needed to achieve pregnancy.

ES28-0640 - Free Communication 14

Hysteroscopic ambulatory surgery – a 24h follow-up

Matilde Martins¹, Sara Cunha¹, Inês Reis¹, António Lanhoso¹, Cristina Costa¹, Mak Foo¹

¹Entre o Douro e Vouga Hospital Center, Gynecology and Obstetrics Department, Santa Maria da Feira, Portugal

Background

Medical advances have allowed adequate ambulatory surgical (AS) programmes promoting a rational and cost-effective use of resources. Simultaneously, health care humanisation and patient satisfaction is enhanced, in part by improving compatibility between recovery and family and social activity.

Operative hysteroscopy is a minimally invasive gynaecological procedure in which an endoscopic optical lens is inserted through the cervix into the endometrial cavity to direct treatment of various types of intrauterine pathology, such as endometrial polyps and uterine myomas (the most frequent).

One of the tools used to evaluate the healthcare quality and safety is the 24-hour after-surgery phone call, to obtain information about the patient (clinical evolution, possible complications, degree of functional activity and immediate care satisfaction).

This study aims to identify postoperative complications in the first 24 hours after a hysteroscopic procedure, to assess the degree of functional activity and to understand if the given information and prescribed analgesia were adequate.

Methods

A retrospective analysis of the data collected from the 24-hour phone call after gynaecologic surgery in our AS Unit from 01/07/2014 to 28/02/2019 was conducted.

Results

1871 gynaecological ambulatory surgeries were performed, of which 816 (43,6%) were hysteroscopic myomectomy or polypectomy with bipolar resectoscope under general anaesthesia. 28,2% did not answer the phone call.

The most frequent complications were: pain (n=206, 35,2%), requiring analgesic therapy in 78,2%; mild haemorrhage (n=111, 18,9%); dizziness (n=15, 2,6%), headache (n=11, 1,9%) and nausea and vomiting (n=7, 1,2%).

Most patients reported that the information provided (n=580, 99%) and prescribed analgesia (n=578, 98,6%) were satisfactory.

Regarding the degree of functional activity in the first 24 hours, most patients (n=415, 70,8%) reported some limitation while moving; total disability was reported in only 1 case.

In the first 24 hours, 99.49% of the patients had no clinical concerns (n=583) although 3 patients were instructed to visit a healthcare unit (1 to an emergency department).

Conclusions

Global patient satisfaction was high. This study shows that in the first 24 hours most patients had no clinical concerns, had only some movement limitations and the most frequent complications were minor (minor pain and mild haemorrhage), which supports the safety of the ambulatory approach for hysteroscopic procedures. On the other hand, information provided, and analgesia prescribed were considered adequate by the patients.

Operative hysteroscopy for polyps and myomas is an accepted and useful tool. Increased clinician training, smaller diameter hysteroscopes have allowed operative hysteroscopy to become a safe, effective and less invasive procedure.

ES28-0647 -

Free Communication 14

REMOVe 5: Resectr® 5fr for the morcellation of endometrial polyps: preliminary results

Steffi van Wessel¹, Tjalina Hamerlynck², Steven Weyers², Celine Blank², Huib van Vliet³, Dick Schoot³

¹*Ghent Universital Hospital, Gynaecology, Ghent, Belgium*

²*Ghent University Hospital, Women's clinic, Ghent, Belgium*

³*Catharina Hospital, Gynaecology, Eindhoven, The Netherlands*

Background

The hysteroscopic morcellator has been reported as an effective, fast and safe technique with no major complications for removal of intrauterine polyps. Improvements of the devices and innovations have led to newer mechanical motor-driven tissue removal systems.

However, the development of devices continues and a new, mechanical hand driven device (Resectr®), which is recently launched, is effective in in-vitro and in-vivo setting, tested, and safe. Up till date, no large prospective trial has been performed using the new, small hand driven tissue removal system (Resectr® 5.0 fr).

Our objective is to investigate the feasibility of a new 5fr. hysteroscopic device, a hand driven morcellator (Resectr® 5fr), for the removal of smaller endometrial polyps ($\leq 8\text{mm}$) in an office setting.

Methods

This prospective study is conducted in the Catharina Hospital (Eindhoven, the Netherlands) and the Ghent University Hospital (Ghent, Belgium). Inclusion has started in October 2018. Women ≥ 18 years with an endometrial polyp on saline-infusion-sonohysterography (SIS) and/or diagnostic hysteroscopy are included. The polyp is removed using a hand driven morcellator, Resectr® 5fr, in an office setting. The primary outcome is resection time. The secondary outcomes are patient's pain score and surgeon's convenience score (both on a 5-point Likert's scale), completeness of resection and availability of tissue for pathology analysis. We aim to include 100 cases.

The Netherlands National Trial Register (NTR): 7119.

Results

The current sample size contains 21 women. The median age is 49 year (interquartile range (IQR) 45 – 64 year). The median polyp size is 7mm (IQR 5 – 8 mm). The polyp location is: fundal (29%), anterior (24%), in lateral (19%), in posterior (14%) and cervical (14%). The median resection time is 69 seconds (IQR 36 – 135 seconds). The median pain score and surgeon's convenience score on a 5-point Likert's scale are 1 (IQR 0 – 2) and 5 (IQR 4-5), respectively. Complete polyp resection is achieved in all the cases, and in 91% the polyp is confirmed on pathology. In 10% the amount of tissue was insufficient for pathology analysis.

In case of abstract selection, the results will be updated until the end of September 2019.

Conclusions

These preliminary results show that it is feasible to remove smaller polyps in an office setting using the hysteroscopic hand driven morcellator, Resectr 5fr. The resection time is short, the patient's pain score is low and the surgeon's convenience score is high. Even fundal polyps, which are difficult to reach, can be removed using this new 5fr hysteroscopic device. It is important to flush the tubings in order to obtain all tissue for pathology analysis.

ES28-0050 -

Free Communication 15

Standardising simulation based basic laparoscopic training for gynaecology trainees

Jessica Preshaw¹, Susannah Hogg¹, Sophie Moloney-Geany¹, Haj Kamali¹, Christy Burden¹

¹Southmead Hospital, Gynaecology, Bristol, United Kingdom

Background

Despite laparoscopy becoming the prime surgical modality in gynaecology, training in this field is often highlighted as inadequate and inconsistent. This project was launched with the following objectives:

1. To design and develop a basic laparoscopic surgery (LS) course utilising simulation.
2. To deliver standardised basic laparoscopic tuition to junior gynaecology trainees.
3. To assess participant perceptions on the training package.

Methods

A one-day interactive course entitled Essential Laparoscopic Skills (ELS) was designed around a research-based curriculum and delivered in the South West of England in 2019. The programme comprises (1) lectures covering fundamentals of LS including preoperative considerations, benefits and risks alongside consent, set-up, entry, energy, pelvic survey and documentation and (2) box trainer stations. Trainees rotated through 10 different stations practicing skills including camera navigation, hand-eye coordination, instrument navigation and grasping, lifting and transfer. We operated with a ratio of 1 trainer per 3-4 trainees.

Trainees completed an online questionnaire post training to assess their perceptions on ELS. Statements were judged on a Likert scale and written feedback was also collected.

Results

All 22 junior gynaecology trainees in the region were invited to attend. Over 2 days 17 completed ELS (77%).

100% agreed ELS relevant, improved confidence in LS and that skills learnt can be applied in clinical practice. 100% deemed trainers prepared, knowledgeable and confident. 100% felt materials were presented in a way that facilitated learning. 100% judged the day excellent, want to attend similar study days and would recommend ELS to peers.

Qualitative feedback was overwhelmingly positive, with the day 'well surpassing expectation'. Thematic analysis of comments submitted on the best elements of the course identified 6 key areas: the practical sessions, enthusiastic non-judgemental faculty, theoretical component, learning environment, well balanced programme, topics and tasks pitched at the correct beginner level. Themes were illustrated by raw data quotes.

Trainees felt the course as a whole 'perfect', with no improvements or modifications required. Learning objectives were met but further practical sessions would be beneficial to enhance and maintain skill acquisition.

Conclusions

ELS was well received and deemed excellent by all trainees. The theoretical component combined with multiple practical simulation stations delivered in an interactive style within a supportive environment was praised. Moving forward expansion is planned in neighbouring regions. A train-the-trainers model, an established and successful model of dissemination, is proposed. Using low fidelity box trainers which are easily accessible and low cost is advantageous.

This pilot demonstrates that delivery of ELS is achievable. We envisage further expansion nationally and ultimately internationally to ensure standardised high quality simulation based fundamental laparoscopy training to all junior gynaecologists. ELS aims to improve surgical competence and confidence that will translate to more hands on opportunity in theatre and an improvement in patient safety.

ES28-0100 - Free Communication 15

Hemodynamic outcome of different ventilation modes in laparoscopic surgery with exaggerated Trendelenburg: a randomised controlled trial

Hakan Yilmaz¹, Baturay Kansu Kazbek¹, Ülkü Ceren Köksoy¹, Ahmet Murat Gül¹, Perihan Ekmekçi¹, Gamze Sinem Çağlar²

¹*Ufuk University, Anesthesiology and Reanimation, Ankara, Turkey*

²*Ufuk University, Obstetrics and Gynecology, Ankara, Turkey*

Background

The increase in intraabdominal pressure caused by carbon dioxide (CO₂) insufflation and exaggerated Trendelenburg position causes adverse effects in the cardiovascular and other systems mandating close monitoring. Laparoscopy and mechanical ventilation cause hemodynamic changes. Pressure controlled - volume guaranteed (PCV-VG) ventilation and volume controlled (VCV) ventilation modes are two modes of mechanical ventilation used in laparoscopic gynaecologic surgeries. This study aims to compare hemodynamic effects of two different modes of ventilation (volume controlled vs pressure controlled volume guaranteed) in patients undergoing laparoscopic gynaecology surgeries with exaggerated Trendelenburg position (>30° head down tilt).

Methods

Thirty patients undergoing laparoscopic gynaecology operations were randomised into two groups either ventilated using either volume controlled (group V) (n=15) or pressure controlled volume guaranteed mode (group P) (n=15), by closed envelope method. Hemodynamic variables were measured using Pressure Recording Analytical Method (PRAM) which is minimally invasive and allows to measure, heart rate (HR), mean arterial pressure (MAP) systemic vascular resistance (SVRI), stroke volume index (SVI), cardiac index (CI), cardiac cycle efficiency (CCE) and maximal pressure/time (dP/dt) using data derived from the arterial pulse recorded by radial artery cannulation. Peak and mean airway pressures and expired tidal volume for different time points were also recorded.

Results

When two groups were compared, no significant difference was found in the duration of surgery, anaesthesia and pneumoperitoneum (p>0.05). The change in MAP, HR, SVRI, SVI, CCE, dP/dt, and

SVV were similar throughout the operation. The only remarkable parameter was detected at CI which showed less variations at all times intraoperatively in group P compared to group V (group P vs group V, p=0,043). Expired tidal volume increased in group V while peak airway pressure was lower in group P.

The expired tidal volume was significantly higher at all times in group V than group P (p=0,025).

Conclusions

To our knowledge, this is the first study in the literature which compares PCV-VG and VCV in the exaggerated Trendelenburg position in laparoscopic surgery concerning hemodynamic parameters with PRAM method. Between the two compared ventilation modes, PCV-VG causes less hemodynamic perturbations as measured by PRAM and allows better intraoperative hemodynamic control in exaggerated Trendelenburg position in laparoscopic surgery. A more stable cardiac index throughout the operation in PCV-VG group can be explained by lower intra-thoracic pressure in PCV-VG than VCV mode, which provides a better preload and PCV-VG might be a better option in patients with low cardiac reserve.

ES28-0375 -

Free Communication 15

Implementation of robotic surgery at a German university hospital. Patient's safety during the first 100 procedures

Dimitrios Balafoutas¹, Achim Woeckel¹, Ralf Joukhadar¹

¹Würzburg University Hospital, Obstetrics & Gynecology, Würzburg, Germany

Background

Minimally invasive surgery currently represents the most favourable access in gynaecological surgery for most benign diseases and numerous malignant conditions. Robotic surgical systems offer higher technical support, thus facilitating shorter learning curves and higher feasibility along with lower rates of conversion to laparotomy. The implementation of new surgical techniques, however, represents a challenge in terms of quality and safety. The aim of this study was to critically analyse perioperative adverse events during the first 100 robotic procedures.

Methods

We present a retrospective evaluation of the perioperative data of the first 100 procedures after implementation of a robotic program at a tertiary, high volume, university centre with high laparoscopic proficiency. Age, body mass index, operative time, estimated blood loss (EBL) as well as intra and postoperative complications were collected. Complications were classified according to Clavien-Dindo (C-D) System.

Results

From June 2017 until May 2019, 100 robotic procedures were performed: 39 total hysterectomies (TLH) for benign conditions, 43 sacropexies, 8 cases of deep infiltrating endometriosis (DIE), 7 TLH with sentinel lymph node biopsies for uterine malignancies and 3 myomectomies. The EBL was 34 ± 27 ml, intraoperative complications occurred in 3%, rates of C-D grade I, grade II, grade IIIa and grade IIIb postoperative surgical complications were 11%, 5%, 0% and 2%, respectively. However, no conversion to laparotomy was performed.

Conclusions

Robotic surgery is a feasible and safe technique with a short learning curve.

**ES28-0388 -
Free Communication 15**

Ovarian hypertelorism

Diaa Abdelhalim¹, Sayed El-Akhras², Mohamed Salama³, Mohamed Aboelenein⁴, Vasilios Tanos⁵

¹*El-Galaa Teaching Hospital, Gynaecology and Obstetrics, Cairo, Egypt*

²*Omam Hospital, Minimally Invasive Surgery, Cairo, Egypt*

³*Ain Shams Faculty of Medicine, Gynaecology and Obstetrics, Cairo, Egypt*

⁴*Omam Hospital, Research and Development, Cairo, Egypt*

⁵*University of Nicosia- Medical School and Aretaeio Hospital, Gynaecology and Obstetrics, Nicosia, Cyprus*

Background

Although hypertelorism usually refers to ocular hypertelorism due to its wide clinical use in this particular context, the definition of the word is excessive distance between any paired organs. As a consequence, ovarian hypertelorism means excessive distance between ovaries.

Methods

Ovarian hypertelorism occurs due to failure of migration of ovaries to their normal position in the pelvis during embryological development. Normally, this migration results partially from the massive growth of the upper abdominal region in comparison with the pelvic area, in addition to the influence of the lower gubernaculum in this process. In these cases, ovaries are found in the lower paracolic gutters or in the upper pelvis lateral or anterolateral to the psoas muscle.

Results

We noticed the occurrence of this condition more frequently among patients complaining of pelvi-abdominal pain and infertility, as well as women with Mullerian duct anomalies such as uterus didelphys and uterus bicornis. The abnormal position of the ovaries in these women has many clinical implications. The abnormal tubo-ovarian relationship in these patients could be a contributing factor of infertility. In addition, during in-vitro fertilisation, folliculometry and ovum pickup could be difficult or inaccessible transvaginally due to the extra-pelvic location of the ovaries. In case of pain symptoms originating from the adnexa, the presence of the ovaries in the paracolic gutters may lead to delayed or wrong diagnosis. Ovarian torsion or pathology may be misdiagnosed as a gastrointestinal or urological condition and interpretation of radiological findings in these cases may also be misleading.

Conclusions

Although ovarian hypertelorism is a rare condition, it needs clinical attention to avoid misinterpretation of patient's symptoms and radiological findings. Misdiagnosis can delay management and increase patient's suffering and morbidity. Surgical attempt to reposition ovaries back to their normal anatomical position in the ovarian fossa is a matter of controversy, which needs research and discussion of its pros and cons. This can be done laparoscopically by dissecting the suspensory ligament of the ovary, and in the same time conserving ovarian blood supply to preserve ovarian function. Repositioning ovaries back to their normal anatomical site should correct tubo-ovarian relationship improving chances of spontaneous pregnancy, facilitate access to ovaries during ovum pickup, relieve pain and avoid misdiagnosis in the future.

**ES28-0661 -
Free Communication 15**

Standards of diagnostic laparoscopy at a large University Teaching Hospital

Lufti Shamsuddin¹, Heritage Oluwarounke², Caryl Thomas¹, Angharad Jones¹, Anthony Griffiths¹, Richard Penketh¹

¹*University Hospital of Wales, Obstetrics & Gynaecology, Cardiff, United Kingdom*

²*Cardiff University, Undergraduate Department, Cardiff, United Kingdom*

Background

Currently there are no set guidelines as to what a Diagnostic Laparoscopy entails. Although trainees in the UK undergo structured Objective Structured Assessment of Technical Skills (OSATS) for diagnostic laparoscopy as part of their training, the standard can vary depending on a multitude of factors. As the standard varies across surgeons, interpreting operation notes can lead to confusion and misrepresentation leading to missed details and misdiagnosis. This study aims to review whether there is a variation in standards for diagnostic laparoscopy at a large teaching hospital with multiple operators of various surgical experience and interest.

Methods

A retrospective analysis of Diagnostic Laparoscopy of 1 year was performed in the unit. Operation notes were viewed against an arbitrary set standard of what a diagnostic laparoscopy notes should contain and audited against this standard. As notes were retrospectively analysed operating surgeons were unaware their notes were scrutinised. Operation notes were viewed along with photographs taken during the operation. Data on operative findings (positive and negative), and evidence of systematic checks were gathered. Quality of photographs were also reviewed.

Results

Provisional results confirm the standard of diagnostic laparoscopy varies amongst surgeons at this large university teaching hospital. Operation notes were frequently hand written and often were illegible. A high number of cases showed no photographic evidence were taken during laparoscopy to confirm the written operative findings. Photographs that were taken were often poor quality (not in focus, areas of interest not seen).

Conclusions

As standard of Diagnostic Laparoscopy varied amongst surgeons, this can lead to misinterpretation and misdiagnosis. This audit concludes there needs to a set guideline on Diagnostic Laparoscopy to ensure minimum standards are reached when performing this invasive procedure and surgeons are adequately trained to do this.

ES28-0217 -

Free Communication 16

Laparoscopy for Kartagener's syndrome, operative and anaesthetic challenges

Sayed Elakhras¹, Mohamed Salama², Dina Abdelhalim³, Ahmed Fawaz⁴, Adel Selim⁵, Mohamed Elenein⁶

¹*Omam Hospital, Minimally Invasive Surgery, Cairo, Egypt*

²*Ain Shams Faculty of Medicine, Dept. of Obstetrics and Gynaecology, Cairo, Egypt*

³*Al Galaa Teaching Hospital, Dept. of Obstetrics and Gynaecology, Cairo, Egypt*

⁴*Ain Shams Faculty of Medicine, Dept. of Anaesthesia and ICU, Cairo, Egypt*

⁵*Omam Hospital, Dept. of Anaesthesia, Cairo, Egypt*

⁶*Omam Hospital, Dept. of Cardiology, Cairo, Egypt*

Background

Kartagener's syndrome, also known as primary ciliary dyskinesia, is a rare, autosomal recessive genetic disorder leading to defects in the action of cilia lining the respiratory tract, fallopian tubes, and testis. It is characterised by early progressive bronchiectasis, recurrent sinusitis and sometimes infertility.

When accompanied by situs inversus totalis, it is known as Kartagener syndrome (only 50% of primary ciliary dyskinesia cases). Sometimes, only isolated dextrocardia is encountered.

Because of its association with male and female subfertility, both minimally invasive surgeons and anaesthetists encounter such cases during laparoscopy.

Surgical challenges with these cases require awareness of the possibility of situs inversus totalis mirrored anatomy. The liver, stomach and spleen in the upper abdomen have swapped places, and the sigmoid colon and caecum also did in the pelvis.

Anaesthesia for Kartagener's syndrome is very challenging. This is because of the associated dextrocardia, and more importantly, the upper and lower respiratory functions.

Methods

We describe our experience with three cases of this very rare condition, who presented to our centre complaining of infertility. The preoperative assessment and preparation to improve the anaesthetic performance are discussed, as well as the intra- and postoperative challenges during induction, maintenance, recovery and monitoring of such complicated cases. Also, the interesting laparoscopic finding of the reversed, mirrored anatomy are displayed.

Results

Performance of safe surgery on high-risk patients require good knowledge of the elements of such conditions and wise planning for both the laparoscopic and anaesthetic procedures. This is especially important in laparoscopic surgery, which is considered in itself a haemodynamic and respiratory status challenge, with the pneumo-peritoneum and Trendelenburg position.

Preoperative evaluation should assess the respiratory functions, the cardiac performance and treat any co-existing infections. Intraoperative maintenance and meticulous monitoring is of paramount importance in these situations. Postoperative follow up is vital to ensure safe recovery.

Surgically, familiarity with normal and reversed anatomy are essential in such cases. Also, efficient and skilled procedure is a must to minimise the operative time and risk exposure in such complicated cases.

Conclusions

Although rare, cases with Kartagener's syndrome are occasionally met by the minimally invasive gynaecological surgeons. Efficient laparoscopic and anaesthetic expertise is vital in this scenario to ensure safe conduct and recovery in such challenging situation.

ES28-0258 - Free Communication 16

Uterine rupture and factors associated with severe outcomes

Stefania Finnsdottir¹, Kristen Pepin¹, Parmida Maghsoudlou¹, Daniela Carus², Jon Einarsson¹, Sarah Cohen¹

¹Brigham and Women's Hospital, Division of Minimally Invasive Gynecologic Surgery, Boston, USA

²Brigham and Women's Hospital, Department of Obstetrics and Gynecology, Boston, USA

Background

Uterine rupture is a rare but serious obstetric complication most often associated with prior C-section, but in recent years also linked to prior myomectomy. Our objective was to evaluate the number of patients with uterine rupture who had a history of myomectomy and analyse risk factors associated with severe outcomes.

Methods

This study was a retrospective chart review of all cases of complete uterine rupture diagnosed at Brigham and Women's Hospital, Massachusetts General Hospital and other partners hospitals from January 1st 2004 through December 31st 2018. Medical records were reviewed for baseline characteristics, prior surgical history and outcomes. The data were analysed using descriptive statistics and multivariable logistic regression used to estimate the association between prior uterine surgeries and severe outcomes. Regression models were adjusted for possible confounders.

Results

A total of 132 cases of uterine rupture were identified at partners hospitals from 2004 through 2018. Among the patients, 23 (17.4%) had an unscarred uterus and 108 (81.8%) had a history of at least one prior uterine surgery. The majority (106, 80.3%) had a prior C-section, while 6 patients (4.6%) had a history of myomectomy. 4 patients (3.0%) had a prior C-section as well as a prior myomectomy. Most ruptures occurred during labour (111, 84.1%), while 21 (15.9%) presented before onset of labour.

Of the 6 cases of uterine rupture after myomectomy, 2 occurred in the same patient with a history of hysteroscopic resection of a pedunculated fibroid, 2 patients had prior laparoscopic myomectomy done outside of the USA and 2 had prior abdominal myomectomy. 3 ruptures occurred before onset of labour and 3 during labour. Only 2 required blood transfusion and all were resolved with uterine repair.

Severe outcomes included 17 hysterectomies (12.9%), 39 blood transfusions (29.6%), 8 foetal or neonatal deaths (6.1%), 18 Apgar scores of lower than 5 at 5 minutes (13.6%), 14 bladder or ureteral injuries (10.6%) and 5 reoperations (3.8%). The mean estimated blood loss (EBL) was 1598±1765 mL and 35 patients (26.5%) had EBL greater than 1500 mL. Previous uterine surgery was associated with decreased risk of transfusion (OR 0.35, 95% CI 0.14-0.89) and hysterectomy (OR 0.20, 95% CI 0.06-0.73) compared with an unscarred uterus.

Conclusions

The most common risk factor for uterine rupture in our cohort was prior uterine surgery, most commonly a C-section. Severe outcomes occurred in 59 patients (44.7%), but prior uterine surgery was associated with less risk of severe outcomes.

ES28-0318 - Free Communication 16

Application of multi-direction stitching technology in laparoscopic suturing teaching

Yu Zhao¹, Qiong Chen¹, Qiong Zhang¹, Linzhi Yan¹, Yue Hu¹

¹The Second Affiliated Hospital and Yuying Children's Hospital of Wenzhou Medical University, Department of Obstetrics and Gynaecology, Wenzhou, China

Background

To evaluate the feasibility and effectiveness of multi-direction stitching technology in laparoscopic suturing teaching.

Methods

We selected 40 residents in the second affiliated hospital of Wenzhou Medical University within two years after graduation to assess the special teaching of laparoscopic suture under laparoscopic simulators. The 40 students were randomly divided into two groups, the experimental group and the control group, 20 in each group, the scores before and after teaching were calculated. The experimental group used the multi-directional needle teaching method and the control group used the traditional suture teaching method. The suture score, the total suture time and the length of the suture line were all calculated. A designed circular suture training module was used in the experimental group. There were four incisions in different directions. We designed that the point where the needle stitching in and out was a little dot with a diameter of 0.5cm on both sides of the incision and a vertical distance of 0.75cm from the centre of the dot to the incision. No.1,26mm,1/2c ROUND BODIED needle (provided by ETHICON.LLC company) with 20 cm long needle thread will be provided.

Results

We selected 40 residents in the second affiliated hospital of Wenzhou Medical University within two years after graduation to assess the special teaching of laparoscopic suture under laparoscopic simulators. The 40 students were randomly divided into two groups, the experimental group and the control group, 20 in each group, the scores before and after teaching were calculated. The experimental group used the multi-directional needle teaching method, and the control group used the traditional suture teaching method. The suture score, the total suture time and the length of the suture line were all calculated. A designed circular suture training module was used in the experimental group. There were four incisions in different directions. We designed that the point where the needle stitching in and out was a little dot with a diameter of 0.5cm on both sides of the incision and a vertical distance of 0.75cm from the centre of the dot to the incision. No.1,26mm,1/2c round bodied needle (provided by ETHICON.LLC company) with 20 cm long needle thread will be provided.

Conclusions

Multi-direction stitching technology effectively improves the quality of laparoscopic suture teaching.

ES28-0079 - Free Communication 17

Risk factors for caesarean scar defect (CSD) and comparison of evaluation efficacy between transvaginal sonography and magnetic resonance imaging: which is better?

Xiaoyan Tang¹, Jue Wang², Yan Du², Junjun Qiu¹, Xuyin Zhang¹, Keqin Hua¹

¹Obstetrics and Gynecology Hospital of Fudan University, Department of Gynecology, Shanghai, China

²Obstetrics and Gynecology Hospital of Fudan University, Office of Clinical Epidemiology, Shanghai, China

Background

The aim of this study is to determine the risk factors for development of caesarean scar defect (CSD), to compare the efficacy of transvaginal ultrasound (TVS) and magnetic resonance imaging (MRI) for CSD assessment, further to investigate the association between CSD size and clinical symptoms.

Methods

A total of 189 CSD patients and 378 non-CSD women with a history of caesarean section (CS) in Obstetrics and Gynaecology Hospital of Fudan University from January 2008 to February 2016 were enrolled. The potential risk factors for CSD were investigated with multivariable logistic regression analysis. The TVS and MRI were performed for

CSD measurements, including residual myometrium thickness, depth, length and width of CSD. The association between CSD size through TVS/MRI and symptoms were evaluated respectively.

Results

The operation time of CS ≥ 85 min, peripartum fever or infection, retroflexed uterine were risk factors for CSD. And age at time of last CS < 30 years old, intraoperative blood loss < 150 ml, double-layer closure were protective factors for CSD. Prolonged menstruation, dysmenorrhea, chronic pelvic pain and infertility are main clinical manifestation. Women with larger size of CSD presented with more prolonged menstruation. Compared with TVS, measurements by MRI shows a better prediction of clinical symptoms of CSD.

Conclusions

Multi-factors contribute to development of CSD. Prevention of peripartum infection, shortening operation time, reducing blood loss and a more careful uterine closure are needed to decrease the risk of developing CSD. MRI is a reliable method for diagnosis and measurement of CSD and can be utilised in clinical practice.

ES28-0159 -

Free Communication 17

Changes in quality of life three and twelve months after laparoscopic niche resection

Sanne Stegwee¹, Wouter Hehenkamp¹, Robert de Leeuw¹, Christianne de Groot¹, Judith Huirne¹

¹Amsterdam UMC - Vrije Universiteit, Amsterdam Reproduction & Development - Obstetrics and Gynaecology, Amsterdam, The Netherlands

Background

Laparoscopic niche resection can be performed in women with a large niche after caesarean section (CS) to improve gynaecological symptoms and subfertility. The objective of this study was to evaluate changes in physical and mental summary scores and individual subdomains of quality of life (QOL) in the first year after laparoscopic niche resection.

Methods

We conducted a prospective cohort study among women with a symptomatic large niche (residual myometrium thickness < 3.0 mm) who underwent laparoscopic niche resection in a University hospital in The Netherlands between May 2010 and January 2018. This study was approved by the ethics committee of Amsterdam UMC – location VUmc (2011.297). Women were included consecutively. Short form Health Survey 36 (SF-36) questionnaire to measure generic QOL was filled out at baseline, three months and twelve months after surgery. All participants that filled out the questionnaire at baseline and at least one follow-up moment were included in the analyses. Physical (PCS) and mental component summary (MCS) were calculated; these are summarised scores that represent physical and mental QOL compared to the Dutch reference population with a mean score of 50 and a standard deviation of 10. Changes in PCS and MCS as well as in individual subdomains (physical functioning, role limitations due to physical health, bodily pain, general health, role limitations due to emotional problems, vitality, social functioning and mental health; scale 0-100) were analysed over time using Wilcoxon signed rank test.

Results

166 women underwent a laparoscopic niche resection at least 12 months ago. Of them, 136 (81.9%) responded to the SF-36 at baseline, 120 (72.3%) at three months and 106 (63.9%) at twelve months follow-up. At three months follow-up, median physical component summary improved from 52.5 to 55.1 ($p=0.031$) and median mental component summary improved from 48.4 to 50.4 ($p=0.009$) compared to baseline. Three out of eight subdomains improved compared to baseline: bodily pain (median 69.4 to 89.8, $p<0.001$), mental health (median 76.0 to 80.0, $p=0.002$) and social functioning (median 75.0 to 87.5, $p=0.005$). At twelve months follow-up, mental component summary still improved (median to 51.3, $p=0.015$), whereas change in physical component summary did not reach statistical significance (median to 55.8, $p=0.087$). The same subdomains bodily pain (median to 89.8, $p<0.001$), mental health (median to 80.0, $p=0.002$) and social functioning (median to 87.5, $p=0.008$) improved at 12 months follow-up.

Conclusions

Laparoscopic niche resection improves QOL in physical and mental domains after three and twelve months compared to baseline. The physical subdomain bodily pain shows the best improvement.

**ES28-0166 -
Free Communication 17**

Exosomes derived from human umbilical cord mesenchymal stem cells accelerate growth of VK2 vaginal epithelial cells through MicroRNAs in vitro

Zhongyi Zhu¹, Ligang Wu², Jingxin Ding¹, Keqin Hua¹

¹The Obstetrics and Gynecology Hospital of Fudan University, Department of Gynecology, Shanghai, China

²Chinese Academy of Sciences, Shanghai Institutes for Biological Sciences, Shanghai, China

Background

To investigate whether and how human umbilical cord mesenchymal stem cell-derived exosomes (hucMSC-Ex) could accelerate vaginal epithelium cell (VK2) growth.

Methods

VK2 cells were co-cultured with hucMSC whose paracrine effect on the viability, cell cycle and cell apoptosis of VK2 vaginal epithelial cells was further assessed by the CCK-8 assay and flow cytometry. HucMSC-Ex isolated from culture medium by ultracentrifuge were characterised by transmission electron microscopy, nanoparticle tracking analysis and Western blot. HucMSC-Ex at different concentrations and HFF-1 exosomes were used to treat VK2 cells. High-throughput RNA sequencing was utilised to reveal the profile of microRNAs in hucMSC, hucMSC-Ex, HFF-1 and HFF-1 exosomes and GO analysis was applied to demonstrate their functions. To evaluate the function of these specific microRNAs in hucMSC-Ex, VK2 cells were treated with RNA-interfered-hucMSC-Ex (RNAi-hucMSC-Ex) and their proliferation was measured by Label-free Real-time Cellular Analysis System.

Results

The study showed that hucMSC stimulate VK2 cell growth possibly through a paracrine route by promoting cell cycle and inhibiting apoptosis. Compared with control and low dose groups, hucMSC-Ex of high concentration (more than 1000 ng/ml) significantly increased VK2's growth after treatment in a dose-depended manner ($P < 0.05$). HucMSC-Ex raised the proportion of cells in S-phase and reduced the percentage of apoptotic cells in VK2 cells in comparison with the HFF-1 exosomes and control groups ($P < 0.05$). microRNAs, including miR-100 (16.92%), miR-146a (9.21%), miR-21 (6.67%), miR-221 (6.39%) and miR-143 (4.63%), were found to be specifically enriched ($P < 0.05$) in hucMSC-Ex and their functions concentrated on cell cycle, development and differentiation.

Conclusions

Collectively, our findings indicate that hucMSC-Ex may play a significant role in accelerating VK2's proliferation by promoting cell cycle and inhibiting apoptosis through exosomal microRNAs in vitro. This finding supports the potential use of hucMSC-Ex as a cell-free therapy of Meyer–Rokitansky–Küster–Hauser syndrome (MRKHS) after vaginoplasty.

This study was supported by the Chinese National Nature Sciences Foundation (grant number 91440107, 81471416 and 81771524) and the Strategic Priority Research Program of the Chinese Academy of Sciences (XDB19040102).

**ES28-0677 -
Free Communication 17**

Does surgery improve IVF outcomes in endometriosis-related infertility? A single centre observational retrospective analysis

Maria Elena Obino¹, Francesca Papini¹, Elisabetta Micelli¹, Chiara Vacca¹, Paolo Giovanni Artini¹, Vito Cela¹

¹University of Pisa, Clinical and Experimental Medicine, Pisa, Italy

Background

Endometriosis is a disease known to be detrimental to fertility. Assisted reproductive technology (ART) is one of the therapeutic options offered to achieve a pregnancy. To date, published data on ART outcome in women affected by endometriosis are conflicting and the determinant factors for pregnancy chances unclear. Women affected by endometriosis represent a dilemma when choosing the appropriate therapy: surgery or IVF. The risks of surgery and its potential damage to ovarian reserve have to be balanced with the complications associated with the persistence of the endometriosis during ART. The objective of the present study is to determine the impact of endometrioma, surgery for endometrioma, deep infiltrating endometriosis and surgery for deep endometriosis on IVF/ICSI outcome and pregnancy rate. To determine the impact of surgery after IVF failure on IVF/ICSI outcomes and pregnancy rate.

Methods

Retrospective observational cohort study, including 78 endometriosis patients undergoing 132 in vitro fertilization (IVF) or intra-cytoplasmic sperm injection (ICSI) cycles from January 2010 to December 2018 at the centre of infertility and assisted reproduction of the department of clinical and experimental medicine of pisa. Infertile women were classified on the basis of endometriosis phenotype and subclassified in patients who underwent prior ART or prior surgical treatment followed by ART. Patients who not had previous surgery were classified in two main phenotypes: patients who had endometrioma (OMA) and patients with deep infiltrating endometriosis with or without associated endometrioma (DIE +/- OMA). women who had previous surgery were also classified in two phenotypes: patients who had previous surgery for endometrioma only (OMA surgery) and patients who had previous surgery for deep infiltrating endometriosis with or without endometrioma (DIE +/- OMA surgery).

Results

Pregnancy rate in the OMA group (first line IVF) and in the OMA surgery group are 37% and 39% respectively. Pregnancy rate in the DIE +/- OMA group (first line IVF) and in DIE +/-OMA surgery group are 21% and 57% respectively. All patients who underwent surgery after IVF had a pregnancy ($p=0,003$).

Conclusions

First line surgery in infertile patients with OMA does not improves chance of pregnancy. First line surgery seems to be a good option for infertile patients with DIE. After IVF failure surgery should be considered.

ES28-0263 -

Free Communication 17

Impact of intramural and submucosal fibroid removing on uterine peristaltis, fertility and reproduction

Anton Fedorov¹, Alexander Popov², Yulia Sopova², Ruslan Barto², Marina Chechneva², Alexey Kova²

¹Moscow Regional Research Institute O/G, Endoscopy, Moscow, Russia

²Moscow Regional Research Institute O/G, Ultrasound, Moscow, Russia

Background

In Russia, the average age of a woman with uterine fibroids is 32 years. Due to the trend towards a later realisation of the reproductive function of women (after 35 years), the question of the impact of uterine fibroids on fertility is becoming increasingly important. According to modern publications in the genesis of infertility, fibroids as a direct cause is detected only in 3% of cases, but its impact on reproductive function is not limited. Numerous studies have shown that the greatest negative role is played by submucous uterine fibroids of type 0, 1, 2, 2-5 according to FIGO classification. Presumably the main pathophysiological mechanism of infertility in submucous uterine myoma is a violation of implantation due to the presence of increased contractility of the inner layer of the endometrium and non-physiological orientation of peristaltic waves. In our study, the dynamics of changes in peristaltic activity of the uterus before and after myomectomy was traced.

The aim of the study was to optimise the tactics of management of patients with submucous uterine myoma type G0, 1, 2, 2-5 classification of FIGO with the aim of assessing the impact of myomectomy on fertility.

Methods

the study involved 30 patients aged 28 to 44 years (mean age 36, 8 years) planning pregnancy and having symptomatic uterine fibroids according to the classification FIGO type G 0,1,2, 2-5. The average size of fibroids was 36 mm. All patients underwent dynamic ultrasound examination of peristaltic activity of the uterus on the 19-21 day of the menstrual cycle. Before surgery, the average frequency of peristaltic waves was 2.8 waves per minute. Laparoscopic myomectomy was performed in 14 patients. Resectoscopy in 15 patients. One patient managed to avoid surgical treatment due to migration of myomatous node into interstitial on the background of drug therapy. After surgical treatment, a control measurement of peristaltic activity of the uterus was performed. After myomectomy, the average velocity of peristaltic waves was 1.25 waves per minute. The obtained data suggest that enhanced uterine peristalsis may be a factor of infertility in the presence of submucous uterine fibroids.

Results

In 30 patients (100%) who underwent laparoscopic or transcervical myomectomy, regardless of the method of myomectomy, the average peristaltic activity of the inner layer of the myometrium decreased by an average of 2 times. One patient (3%) became pregnant after performing a transcervical myomectomy.

Conclusions

Dynamic measurement of peristaltic activity of the inner layer of the myometrium allows to assess the presence or absence of hyperperistalsis of the uterus, to determine the indications for myomectomy in the presence of increased contractile activity of the myometrium, which increases the likelihood of pregnancy in both the natural cycle and in the IVF program.

ES28-0339 -

Free Communication 17

Robotic caesarean section scar ectopic pregnancy excision with repair of scar defect: 3 case reports

Yichen Chuang¹, Hsin Mei Liu¹

¹Far Eastern Memorial Hospital, Obstetrics and Gynecology, New Taipei City, Taiwan

Background

The symptomatic caesarean section scar defect (CSSD) had increased due to global increase caesarean section (C/S) rate. A rare form of caesarean scar ectopic pregnancy (CSEP) with a high rate of morbidity were also reported increasingly. The management of CSEP varied from medical treatment to dilation and curettage, transcervical resection, transarterial embolization to laparotomy and even hysterectomy. Here we present our experience of robotic excision of CSEP and repair of CSSD and showed the video of surgical procedures.

Methods

We present 3 cases with previous caesarean section who were diagnosed by transvaginal ultrasound and MRI with live pregnancy implanted at the level of the caesarean scar. We performed the robot assisted laparoscopic and combined hysteroscopic surgical treatment, aiming to extract the pregnancy and repair the scar defect simultaneously.

With 4-port Da Vinci robotic technique and in order to reduce the blood loss, the bilateral uterine arteries origin were traced from internal iliac artery and temporary block with Bulldog. Then we shift to hysteroscopic phase to do transcervical removal of gestational tissue as possible as we can. Then, back to robotic phase, we excised the C/S scar lesion and suture repair the CSSD by using a 1-0 V-Loc™ wound closure device. The final step was removal of the Bulldogs. The CSEP gestational tissue was identified and excised.

Results

We recorded the operation time, blood loss and followed the beta-hCG level until it became to normal level. The mean operative time was 143±35 minutes with blood loss of about 300±100 mL. The mean beta-hCG level on the next day of operation is 4239±2500 mIU/mL. The patients recovered well and were discharged 2 days after the procedure. The mean days for beta-hCG level decrease to normal level was 19±3 days.

Conclusions

Robotic-assisted laparoscopic removal of residual CSEP with repair of CSSD is a feasible and safe procedure.

Outcomes of surgical management of niche on 22 patients and myometrial outcome of caesarean section in three patients with previous reparation of the uterine scar

Stavros Karampelas¹, Linda Tebache², Laurent De Landsheere², Michelle Nisolle²

¹University of Liege Hospital La Citadelle, Gynecology and Obstetrics, Tervuren, Belgium

²University of Liege, Gynecology and Obstetrics, Liege, Belgium

Background

Retrospective study concerning the postoperative results of the correction of caesarean scar defect. The criteria of inclusion were residual myometrium of less than 3 mm and symptomatology of metrorrhagia, chronic pelvic pain or secondary infertility.

Methods

This retrospective study consists of twenty two patients. Thirteen of them had only one caesarean section (59%), two had two caesarean sections (9%), four had three caesarean sections (18%) and three had four caesarean sections (14%). A caesarean section was required for the following reasons: maternal-fetal disproportion (76%), for breech presentation (8%) for twin pregnancy (8%) or for abnormal foetal heart rate (8%). The main complaints were metrorrhagia (41%), chronic pelvic pain (18%) and secondary infertility (54%). The average residual myometrium was less than two millimeter measured by an endovaginal ultrasound. Some patients also had pelvic MRIs confirming the development of an isthmocele.

Fifteen patients underwent a laparoscopic and seven a robotic approach.

After one month and three months respectively, a control was planned for each of the patients: during this, an endovaginal ultrasound was performed and at the control of three months a saline infusion sonohysterography.

Results

Six out of seven patients with metrorrhagia were symptom free after the operation (86%).

Six out of eight patients with secondary infertility (one of the patients was 44 years old) had a successful pregnancy (75%).

All patients with chronic pelvic pain were relieved of their symptoms.(100%)

Three patients had an endovaginal ultrasound for the residual myometrium in the uterine scar after caesarean section performed post niche laparoscopy and the result was an increase in residual myometrium in comparison to the residual myometrium prior to the uterine scar repair.

Conclusions

The uterine scar repair has excellent results in symptomatic patients with metrorrhagia and chronic pelvic pain. It should always be considered as an option in case of secondary infertility that cannot be explained otherwise and its advantage to hysteroscopy is the increase in the thickness of the myometrium on the site of the scar. Repairing the uterine scar laparoscopically may have favourable long term results, with an increase of the residual myometrium after the next caesarian section.

VIDEO PRESENTATIONS (33)

ES28-0129 -
Free Communication 1

Laparoscopic excision of uterosacral ligament and retrocervical deep infiltrative endometriosis with bowel shaving.

Dimitrios Miligkos¹

¹Southampton University Hospitals NHS Trust, Obstetrics and Gynaecology, Hampshire, United Kingdom

Background

This is the case of a 32 year old patient who presents with dysmenorrhoea, deep dyspareunia and menstrual dyschezia. Transvaginal USS showed a 2 cm deep endometriotic nodule on the left uterosacral ligament (USL) and retrocervix extending to a plaque of deep infiltrative endometriosis (DIE) to the outer muscularis of the upper rectum. This video presentation outlines the surgical steps of laparoscopic excision in a systematic approach.

Methods

Laparoscopy demonstrated DIE involving the left USL, retrocervix and upper rectum. The nodule is in close proximity to the left hypogastric nerve.

A standard 4 port laparoscopy is undertaken and a systematic approach is followed. Surgery begins with division of the physiological sigmoid colon adhesions. The left ureter is visualised at the pelvic brim. The left pararectal space is opened medial to the left hypogastric nerve and then the right pararectal space is dissected. The dissection starts in normal tissue close to the nodule and extends caudally in the rectovaginal septum until normal tissue below the nodule is reached. Dissection follows the gas of the pneumoperitoneum in the avascular planes. The perirectal fat stays medially with the rectum and the disease is centrally isolated. The nodule is shaved from the rectum with cold scissors and short bursts of bipolar energy to avoid thermal injury to the bowel. Vaginal and rectal examination during the dissection assists in identifying the correct plane.

Left ureterolysis is undertaken and the USL nodule is dissected with preservation of the left hypogastric nerve. The nodule is excised en bloc. At the end of the operation the bowel integrity is checked with an under water leak test which was negative.

Results

The patient made an uncomplicated recovery and was discharged on day 1 post operatively. Endometriosis was confirmed on histology.

Conclusions

A systematic approach for the surgical excision of DIE is followed in this video. Careful dissection and identification of the anatomical landmarks in the pelvis is necessary to allow complete excision of DIE and achieve the best clinical outcomes with low complication rate.

<https://player.vimeo.com/video/334195979?autoplay=1>

ES28-0506 - Free Communication 1

Ovarian endometrioma related to a Rokitansky Kuster Hauser with a rudimentary functional uterine horn

Marion Petrolati¹, Aline Host¹, Victor Gabriele¹, Olivier Garbin¹

¹Gynaecology, Bas Rhin, Strasbourg, France

Background

Introduction

The Rokitansky Kuster Hauser syndrome is a rare disease (1-5 women/10 000) characterised by a vaginal and uterine aplasia more or less complete. In contrast endometriosis is a common disease affecting one in ten women. Both diseases can be managed by surgery.

Objectives

The aim of this study was to report the case of a patient with a Rokitansky-Kutser-Hauser syndrome associated to a voluminous ovarian endometrioma.

Methods

A 42 year old woman with has in his medical history two ovarian cystectomy.

She presents a primary amenorrhea with chronic pelvic pain. The clinical examination finds vaginal aplasia. The abdominal ultrasounds finds a finely echogenic adnexal cyst, about 10 cm. The pelvic MRI shows vaginal aplasia and a right rudimentary uterine horn with functional endometrium.

We suspect a Rokitansky kuster Hauser syndrome with functional rudimentary horn and reflux endometriosis. We started a treatment with analogues and add back therapy and decided to perform an annexectomy and cornuectomy by laparoscopy.

The exploration finds a very adherent pelvis. We begin with anterior adhesiolysis and ovariolysis. The endometria is drained. We continue with right ureterolysis. We coagulate the right lombo ovarian ligament and pediculise annex on the rudimentary horn. We coagulate and cut the right uterine artery which is far from the ureter. The block uterine horn and right annex is free and fragmented. We can see the contralateral ovary which is normal. The left trunk is missing. There is a left rudimentary horn which is not functional.

Results

Operative time was 110 minutes. There were no intraoperative or postoperative complications. The anatomopathology analysis conclude to endometriosis.

Conclusions

Laparoscopic surgery was a good treatment for both ovarian endometrioma and Rokitansky-Kuster-Hauser syndrome without complication.

<https://player.vimeo.com/video/338828556?autoplay=1>

ES28-0508 - Free Communication 2

Acquired uterine Arteriovenous Malformation (AVM): a case report

Ursula Catena¹, Antonia Iacovelli¹, Ilaria De Blasis¹, Ilaria Romito¹, Carmine Di Stasi², Giovanni Scambia¹

¹Fondazione Policlinico Universitario Agostino Gemelli IRCCS, Department for Women's Health Gemelli, Roma, Italy

²Fondazione Policlinico Universitario Agostino Gemelli IRCCS, Department of Bioimaging- Interventional Radiology, Roma, Italy

Background

Uterine Arteriovenous malformations are rare but potentially life-threatening lesions, consisting of abnormally connected vessels. Congenital cases are rare. The acquired form is the most common and is often subsequent to a

pregnancy event, usually after an invasive procedure such as curettage and caesarean section. Abnormal uterine bleeding is the most common symptom. Identification of the disease allows a correct pre-planned management. We aim to propose a combined method (interventional radiology and hysteroscopy) to treat arteriovenous malformation in women who wish to preserve fertility, to obtain a rapid resolution of symptoms and to rapidly restore a normal uterine cavity. Furthermore we aim to assess the role of post-embolization ultrasound to evaluate the safety of hysteroscopic resection.

Methods

A 33 years old woman was admitted to our department due to persistent uterine bleeding after a late pregnancy loss. Ultrasonography revealed a uterine cavity occupied by an abnormal hypervascular area in the myometrium and endometrium. CT angiography confirmed the diagnosis. The patient was referred for unilateral embolization of the uterine artery. The day after ultrasonographic success was defined by the disappearance of the hypervascular area. The patients underwent surgical hysteroscopy under general anaesthesia. Hysteroscopic resection of the lesion and clots was performed. The duration of hysteroscopic surgery was 30 minutes and the estimated blood loss was less than 50 mL.

Results

Ultrasonography was performed immediately after surgery and two weeks later, showing no residual disease. The histologic analysis found clots, chorionic villi with necrotic degeneration and necrotic decidual tissue.

Conclusions

Hysteroscopic surgery after unilateral uterine artery embolization was safe and successful to rapidly relief symptoms and to restore a normal uterine cavity to preserve future fertility. Colour doppler ultrasonography successfully predicts the absence of flow in the residual lesion.

<https://player.vimeo.com/video/338842780?autoplay=1>

ES28-0080 -

Free Communication 3

Laparoscopic vessel occlusion at myomectomy - uterine, ovarian and Sampson's vessels

Neeraj Kulkarni¹, Saloni Maria Deepti Pinto Rosario¹, Rok Sumak¹, Andres Viguera Smith¹, Helder Ferreira¹

¹Centro Maternidade Infantil do Norte- Porto- Portugal, Minimal Invasive Surgery, Porto, Portugal

Background

Uterine artery occlusion at myomectomy has been shown to be efficient at limiting blood loss and need for blood transfusion. Extensive anastomoses exist between the uterine artery and ovarian artery. We propose additional occlusion of both the infundibulo-pelvic and round ligaments at myomectomy to transiently occlude the ovarian artery and Sampson's artery. This will serve as a simple mean of further limiting blood loss.

Methods

A stepwise demonstration of the procedure, with explanation and surgical video. Two patients undergoing laparoscopic myomectomy for a ten centimetre myopia and multiple myomas.

Results

After a survey, it was decided to use the lateral approach to uterine artery occlusion. The landmark was identified with traction on the medial umbilical ligament. The peritoneum was incised and the ureter and uterine artery were exposed with careful blunt dissection. Temporary surgical clips were placed on bilateral uterine arteries. Subsequently, bilateral IP and round ligaments were similarly occluded.

With devascularisation achieved, a linear incision was made over the myoma using a unipolar hook. Enucleation was completed with the aid of tooth forceps. Myometrium was repaired in two layers by a continuous suture using the baseball technique for the superficial layer.

Surgical clips were successfully removed from the uterine arteries and both IP and round ligaments. Peritoneal lavage was carried out and an Interceed barrier (Ethicon, Johnson & Johnson, Neuchatel, Switzerland) was placed over the incision site. There were no intraoperative or immediate postoperative complications.

Conclusions

Occlusion both the infundibulo-pelvic and round ligaments prior to laparoscopic myomectomy is a simple, reversible procedure and does not significantly increase operative times. When used in conjunction with transient uterine artery occlusion, it may serve to further limit blood loss during surgery and hasten recovery. Larger studies are needed to define surgical outcomes and recognise short and long term complications, if any.

<https://player.vimeo.com/video/333970702?autoplay=1>

ES28-0087 -

Free Communication 3

Laparoscopic myomectomy after bilateral uterine artery clipping and contained morcellation

Konstantinos Syrios¹, Petros Syrios¹

¹Mitera Hospital, Obstetrics and Gynaecology, Athens, Greece

Background

Laparoscopic myomectomy is one of the most common gynaecological interventions worldwide. Major concern is given to blood loss during the procedure as well as to power morcellation. In our video we demonstrate the safety and efficacy of bilateral uterine artery clipping, prior to laparoscopic myomectomy.

The patient is a 37 year old secundipara with a history of left laparoscopic adnexectomy for benign disease and 2 C-sections for arrested labour. During consultation, an 8 cm posterior intramural myoma deforming the endometrial cavity is diagnosed. A laparoscopic resection is decided because of desire of a third pregnancy.

The first step is to identify the right uterine artery after opening the peritoneum at the level of the right ovarian fossa. The right uterine artery is identified and dissected. The right ureter runs parallelly and medially to the right uterine artery and is easily identified. The same procedure is performed to the left side. The left obliterated umbilical artery is used as a landmark to identify the left uterine artery which is dissected from the left uterine vein. The left ureter is clearly seen medially to the vessels. A 10 mm titanium clip is inserted to both uterine arteries.

The myomectomy is then initiated by a vertical incision, using the monopolar hook. In order to reduce smoke production, the ultracision scalpel is then used to facilitate dissection. Two layer separate sutures with braided polyfilament n0 1 are performed with minimal blood loss. A contained power morcellation is then initiated so as to avoid spillage of any potential malignant cells. The uterine clips are removed bilaterally to avoid any theoretical effect on future fertility, even though it is demonstrated that clipping does not compromise conception or pregnancy.

Haemostasis is assured. The postoperative course was uneventful and the final histology confirmed a leiomyoma.

Methods

Video presentation

Results

Video presentation

Conclusions

Video presentation

<https://player.vimeo.com/video/334131647?autoplay=1>

**ES28-0259 -
Free Communication 3**

Reduced port laparoscopic myomectomy: a novel technique using a subcutaneous abdominal wall lifting method

Hiroe Ito¹, Yasufumi Ohishi¹, Thapa Yelungka¹, Keiichi Isaka¹

¹Tokyo Medical University Hospital, Obstetrics and Gynaecology, Tokyo, Japan

Background

The reduced port laparoscopic myomectomy (LM) is a novel technique using a subcutaneous abdominal wall lifting method (SAWL). It is fundamentally different to conventional laparoscopic LM. The purpose of this video is to evaluate the usefulness of the reduced port LM.

Methods

1001 cases of reduced port LM were performed at our hospital between 2005 and 2016. The procedures of SAWL are as follows. After a 1.2 mm stainless steel wire was inserted subcutaneously in the middle of the abdominal wall and the abdominal wall was lifted and fixed, an abdominal wall incision 1.5 cm in size was made on the right side using open procedure, then the lap protector® was fixed in it. And then, the trocar for a 5mm endoscope was punctured at the navel fold under the surveillance of the endoscope. LM was performed using one operated hole and enucleated fibroids were extracted using a scalpel.

Results

Patient's average operation time was 163 minutes, blood loss was 163 ml, and number of extracted fibroids was 4.9. There were three cases converted to 3 ports LM and four cases carried out autologous blood transfusion. However, there was no case converted to open surgery and carried out re-operation and cross blood transfusion.

Conclusions

Reduced port LM has many advantages that do not exist with the pneumoperitoneum method such as strong traction by single prong tenaculum forceps, morcellation of the uterine fibroids by the scalpel and easier suture ligation, therefore this method is considered a superior surgical technique in terms of safety, operability, and economically.

<https://player.vimeo.com/video/336245539?autoplay=1>

**ES28-0402 -
Free Communication 3**

Tips and tricks for laparoscopic myomectomy

Benedetto Mondelli¹, Charlotte Goumalatsou¹, Andrew Kent¹, Gill Coyle¹

¹Royal Surrey Country Hospital, Obstetrics and Gynaecology, Guildford, United Kingdom

Background

Uterine leiomyoma represents the most common benign tumour in women, with a lifetime prevalence of 30%. The presenting symptoms are varied but may include heavy menstrual bleeding, dyspareunia, pressure and urinary symptoms and they have been associated with subfertility.

Laparoscopic myomectomy is the gold standard and has shown the benefits, in comparison with laparotomy, of reduced blood loss, postoperative pain and fever as well as decreased hospital stay or recovery time in comparison with the open approach. Laparoscopy is also associated with fewer intra-abdominal adhesions and has similar pregnancy and live-birth rates when compared to open myomectomy.

Methods

This video presentation shows tips and tricks for laparoscopic myomectomy using multiple anonymised videos of women undergoing laparoscopic myomectomy. Patients are thoroughly worked up using pre-operative MRI to rule out leiomyosarcoma and fibroid size varies from 3-10cm. No uterotonics or vasopressin is used.

This presentation highlights the flexibility of the Harmonic scalpel for dissecting and enucleating fibroids efficiently and with minimal blood loss. Uterine defects are then closed with a multilayer Stratafix technique or with vicryl 1.0.

Results

Laparoscopic myomectomy is the gold standard approach for removal of uterine fibroids and is a feasible option also for large ones with excellent recovery and a risk of peri-operative complications no higher to the open approach.

<https://player.vimeo.com/video/338865166?autoplay=1>

ES28-0603 - Free Communication 4

Laparoscopic hysterectomy of a huge uterus with deep infiltrating endometriosis involving the bowel

Sebile Guler Cekic¹, Burcu Yilmaz Hanege¹, Dogan Vatansever¹, Engin Turkgeldi¹, Baris Ata²

¹Koc University Hospital, Obstetrics and Gynaecology, Istanbul, Turkey

²Koc Medical School, Obstetrics and Gynaecology, Istanbul, Turkey

Background

Total laparoscopic hysterectomy (TLH) in patients with huge adenomyotic uterus and deep infiltrating endometriosis is a demanding and technically challenging procedure. Knowledge of the retroperitoneal anatomy and extensive laparoscopic experience are of paramount importance to avoid serious complications. This video of a 47 years old patient with severe pelvic pain, dysmenorrhea and menorrhagia. She had a history of endometrioma excision with laparotomy 8 years ago. Her magnetic resonance imaging revealed 93x121x114 mm sized uterus involving a 103x67x89 mm lesion resembling adenomyosis, multiple intramural myomas and bowel adhesions on the left side of the uterus.

Methods

Entry was through Palmer's point due to large size of the uterus and suspected adhesions. Five ports : 5 mm left and right ports at the level of the umbilicus and inguinal regions and 10 mm umbilical port. First , complete adhesiolysis using Ligasure 5 mm of the dense omental adhesions everywhere in the abdomen. After adhesiolysis it was observed that uterus was as large as 16 weeks gravid uterus. On the left side the bowels together with the ovaries and adnexa were densely adhered to the uterus. Douglas was obliterated and frozen pelvic was inspected. Lateral retroperitoneal spaces were dissected and both ureters were dissected to the point where they cross with uterine arteries. Uterine arteries were clamped. Adhesions on the left side were dissected and bowels were liberated. Bowels were separated from the posterior of the uterus. Right oophorectomy was performed and hysterectomy was completed. Pararectal adipose tissues were cleared with Ligasure. Low anterior resection with end to end anastomosis of the rectum was performed. Vasculature around the rectum was observed with indocyanine green imaging. The pelvic anatomy was remarkable.

Results

The operation lasted for 4 hours. The patient was discharged in 4 days. There were no complications during and after surgery. Postoperative recovery was remarkable.

Conclusions

Although laparoscopic approach to huge uterus with deep infiltrating endometriosis lasts longer than laparotomy, the patient recovery is so remarkable that these patients should have the chance for laparoscopy. Knowledge of the retroperitoneal anatomy and extensive laparoscopic experience are of paramount importance to avoid serious complications.

<https://player.vimeo.com/video/339168014?autoplay=1>

**ES28-0363 -
Free Communication 5**

Laparoscopic extraperitoneal burch colposuspension

Evren Akmut¹, Emre Volkan Kasımoğulları², Hakan Güraslan², Pınar Kadirogulları³, Hanife Birben¹

¹Rize Government Hospital, Obstetrics and Gynaecology, Rize, Turkey

²Bağcılar Training and Research Hospital, Obstetrics and Gynaecology, Istanbul, Turkey

³Kanuni Sultan Süleyman Training and Research Hospital, Obstetrics and Gynaecology, Istanbul, Turkey

Background

To describe other laparoscopic burch colposuspension technic ; extraperitoneal approach using mesh fixed with tacks.

Methods

A 40 year old woman who was suffering from stress urinary incontinence without detrusor instability and low urethral closure pressure, had been underwent uretropexy operation by having extraperitoneal approach using mesh fixed with tacks. 1,5 cm transverse incision near umbilicus was made down to the rectus fascia. Rectus fascia opened midline manner and the rectus muscle was lateralised. Below the rectus muscle and above the posterior rectus sheath, balloon dissector system was placed down to the symphysis pubis. After the balloon was 30-40 times pumped, retzius space was insufflated CO2 at 12 mmHg pressure. Two pieces 5mm trochars were placed above the pubic hairline by taking care of bilateral epigastric arteries traces. After dissecting paravaginal areas, two pieces 1,5 x 4 cm polypropylene mesh was fixed to vaginal fascias with 2.0 prolene sutures. Then mesh was stretched up to ipsilateral coopers ligament and fixated with three pieces of helical tacks to each side. Intraoperative cytoscopy was performed.

Results

The patient whose recovery time was well was discharged on the first day of the operation.

Conclusions

Despite not being cost effective, this procedure can be performed with the advantages of shorter hospital stay, faster recovery time and high success rate like transperitoneal burch colposuspension especially when the patient has history of previous abdominal surgeries with firm adhesions in the pelvis.

<https://player.vimeo.com/video/336429315?autoplay=1>

**ES28-0051 -
Free Communication 6**

Robotic laparoendoscopic single-site radical hysterectomy and pelvic lymphadenectomy with conventional surgical instruments in cervical cancer

Jingxin Ding¹, Xiaoqing Li¹, Xuyin Zhang¹, Keqin Hua¹

¹The Obstetrics and Gynaecology Hospital of Fudan University, Department of Gynaecology, Shanghai, China

Background

To describe and demonstrate the feasibility and safety of robotic laparoendoscopic single-site radical hysterectomy and pelvic lymphadenectomy with conventional robotic surgical instruments.

Methods

Patients: A 50-year-old postmenopausal woman with a diagnosis of cervical squamous carcinoma FIGO staging IB1.

Interventions: Robotic laparoendoscopic single-site radical hysterectomy and pelvic lymphadenectomy with conventional robotic surgical instruments. All of the interventions were performed using a Da Vinci Si surgical system and all the surgery instruments were conventional robotic instruments. By adopting the principle of the chopstick technique for R-LESS, a 30° robotic lens was placed in the upward configuration to reduce collision and achieve a better view.

Results

A single 3-cm vertical umbilical incision was made and the wound retractor of LAGIPORT Kit (LAGIS endo-surgical devices, TRL80-0220R-N, Taiwan) was inserted into the incision with the internal ring. The four-channel single-port system was then attached to the retractor with the lever lock engaged.

The procedure started from bilateral salpingo-oophorectomy and pelvic lymphadenectomy. Then the recto-vaginal space were dissected and developed para-rectal space and dissected the utero-sacral ligament. After developing the pararectal space and paravesical space, the uterine artery is reflected medially over the ureter. We coagulated with bipolar forceps and transected the uterine artery at its origin. After transection of round ligament and incision the peritoneal reflection of the vesico-cervical, the space between the anterior wall of the vagina and the posterior wall of bladder was developed. The next step was to lift the cut end of the uterine artery, develop the ureteral tunnel and the para-vaginal space, then dissected the superficial layer of the vesicouterine ligament. Then dissected the deep layer of the vesicouterine ligament and the ureter was isolated. Finally, parametrium and para-vaginal tissues were dissected and extirpated the uterus.

Moreover, the uterus and the adnexa were extracted throughout the vagina, the vaginal vault was closed with a delayed absorbable suture in a running or interrupted fashion and each layer of the access port was sutured separately.

There were no intra-operative complications or conversion to multiport in the surgery. The patient was discharged on day +5 and 15 days later started pelvic external-beam radiation therapy (EBRT) and concurrent platinum-containing chemotherapy. At a 6-month follow-up, the patient was disease-free and in good general condition.

Conclusions

Our preliminary experience has demonstrated that with experienced laparoscopic skills, R-LESS with the Da Vinci Si system is a feasible and safe surgical approach for performance of radical hysterectomy and pelvic lymphadenectomy with conventional robotic surgical instruments. Further studies with greater number of patients in multiple settings will help us to fully elucidate the role of da Vinci Si surgical system in single-site gynaecologic surgery.

<https://player.vimeo.com/video/331569629?autoplay=1>

ES28-0172 - Free Communication 6

Laparoscopic radical hysterectomy and pelvic lymphadenectomy without vaginal uterine manipulator

Liufeng Xu¹, Ying Zheng¹, Ling Min¹

¹West China Second Hospital- SCU, Gynaecologic Oncology, Chengdu, China

Background

To demonstrate the procedure of laparoscopic radical hysterectomy and pelvic lymphadenectomy without vaginal uterine manipulator.

Methods

A 47-year-old woman presented with irregular vaginal bleeding for 2 months. Vaginal examination revealed that the cervix was smooth, enlarged and barrel-shaped. The left parametrium was shortened and thickened, but still elastic. No abnormalities were palpated in the right parametrium. Enhancement CT showed a 3.5 x 3.2 cm low-density mass in the cervical canal. And 1 right obturator lymph node was enlarged and measured 1.5 x 0.9 cm in size. No other positive results were found. Cervical biopsy found moderately differentiated mucinous adenocarcinoma. The FIGO2018 staging was I B2. The operation begins with the right pelvic lymphadenectomy. Frozen section result revealed 9 lymph nodes were negative. Then laparoscopic radical hysterectomy, with left salpingo-oophorectomy and pelvic lymphadenectomy, was performed by an experienced gynaecologic oncologist. In order to avoid tumour spillage and squeezing, no vaginal uterine manipulator was used intraoperatively. Surgical field was exposed clearly by effective traction.

Results

The surgery lasted 290 min, the volume of blood loss was 200 ml in total, without intra and postoperative complications. The postoperative pathology was moderately differentiated adenocarcinoma (endocervical), meanwhile

it revealed deep one-third cervical stromal and lymphovascular space invasions, without parametrial involvement. Twenty-five lymph nodes were dissected in total and 1 obturator lymph node was positive. Therefore, the final FIGO2018 staging was III C1. The patient recovered quickly, exhaust time was 2 days after operation and adjuvant chemoradiotherapy was supplemented.

Conclusions

Through effective intra-abdominal traction by the first assist and enclosed colpotomy, we performed the standard laparoscopic radical hysterectomy successfully. Compared with conventional minimally invasive surgery, radical hysterectomy without vaginal uterine manipulator provides a safer and tumour-free method for the patients with cervical cancer.

<https://player.vimeo.com/video/335921613?autoplay=1>

ES28-0287 - Free Communication 6

Single-site laparoscopic staging surgery with infrarenal para-aortic lymphadenectomy for grade 3 endometrial cancer

Shimeng Dong¹, Lin Chen¹, Ling Min¹, Liufeng Xu¹, Sijing Chen¹, Ying Zheng¹

¹West China Second Hospital- SCU, Gynaecologic Oncology, Chengdu, China

Background

To present the laparoendoscopic single-site (LESS) staging surgery with infrarenal para-aortic lymphadenectomy for grade 3 endometrial cancer using suture-suspension.

Methods

A 50-year-old woman complained of postmenopausal haemorrhage for 6 months. Her pathological report of diagnostic curettage from local hospital presented poorly differentiated adenocarcinoma. The uterus was almost 12 gestational weeks size on bimanual examination. Magnetic resonance imaging (MRI) scan revealed an occupying lesion with abnormal signal intensity (53×57×47mm) in uterine cavity, junctional zone was involved and depth of myometrial invasion <1/2. No lymph node enlargement and cervical stromal or glandular involvement were found. We performed extrafascial hysterectomy plus pelvic and infrarenal para-aortic lymphadenectomy for the patient, utilising useful suture-suspension to expose operative regions.

Results

The total operative time was 260 min and the estimated blood loss was 100 mL. The time to first flatus was on day 1 post-operation and the patient was discharged on day 3. Final histopathologic examination revealed a poorly-differentiated adenocarcinoma, depth of myometrial invasion <1/2. 26 pelvic lymph nodes, 20 para-aortic lymph nodes and margins were all negative, with no cervical stromal or glandular invasion.

Conclusions

We successfully performed a LESS staging surgery with infrarenal para-aortic lymphadenectomy for grade 3 endometrial cancer. It demonstrated the definite safety and feasibility of LESS malignant gynaecologic surgery facilitated by suture-suspension. Although the total operative time was 260 min for now, it will be shortened as the innovation and evolution of instruments and methods, especially the application of auto-smoke evacuator devices. Compared with multiport laparoscopy (MPL), LESS approach for the endometrial cancer demonstrates benefits in better cosmetic outcomes, less postoperative pain and faster recovery.

<https://player.vimeo.com/video/336307268?autoplay=1>

**ES28-0408 -
Free Communication 6**

Case report and video presentation: laparoscopic approach for symptomatic pelvic lymphocele

Anna Luzarraga¹, Pia Español¹, Rocio Luna¹, Cristina Soler¹, Ramon Rovira¹

¹Gynaecology, Hospital de la Santa Creu i Sant Pau, Barcelona, Spain

Background

To describe laparoscopic approach for symptomatic pelvic lymphocele after gynaecological cancer surgery.

Methods

A 64-year-old woman diagnosed with endometrial carcinosarcoma was surgically staged by laparoscopy performing a total hysterectomy, bilateral adnexectomy and bilateral pelvic and para-aortic lymphadenectomy (extraperitoneal technique). Number of removed nodes were 19 and 14 respectively, postoperative course was uneventful and the patient was discharged on 2nd-day.

Three weeks later and during the course of adjuvant chemotherapy the patient referred a persistent burning-type pain running low back down left groin achieving *visual analogue Scale for pain score* of 8/10. CT scan revealed the presence of a 100 x 76 mm hypodense image surrounding left external iliacs vessels suggestive of pelvic lymphocele. Once radicular compression was discarded, the gynaecology-oncology committee evaluation decided a surgical treatment consisting on laparoscopic marsupialisation.

Laparoscopic management of this complication results in minimal patient morbidity, allows for rapid recovery and has shown a lower rate of recurrence when compared with laparotomy or aspiration in the literature (8% vs 16% vs 59%).

Results

Standard four-port placement configuration was used. Exploration of the abdominal cavity enabled the identification of numerous intra-abdominal adhesions and a prominent bi-lobulated mass in left pelvic wall corresponding to the lymphocele.

Surgical strategy initially consisted in adhesiolysis and reestablishment of anatomy landmarks in left paravesical fossa. An incision along the peritoneal surface over the lower aspect of the lymphocel was performed and the opening was widened to allow the lymph to drain into the abdominal cavity. The procedure was repeated in the second lobule and a drain was placed in the pelvis.

Operation time was 50 minutes and after two-days hospitalisation the patient was discharged explaining totally resolution of the symptoms, no collections were found in CT control examinations.

Conclusions

Owing the minimal morbidity and the optimal results, laparoscopic marsupialisation should be considered an effective treatment for symptomatic pelvic lymphocel after gynaecological cancer surgery.

<https://player.vimeo.com/video/336451709?autoplay=1>

**ES28-0098 -
Free Communication 7**

Laparoscopic management of tubal disease to improve fertility outcomes

Aarathi Cholkery¹, Charles Miller²

¹The Advanced Gynaecologic Surgery Institute, Minimally Invasive Gynaecology, Naperville, USA

²The Advanced Gynaecologic Surgery Institute, Minimally Invasive Gynaecologic surgery, Naperville, USA

Background

This video demonstrates decision making and surgical techniques for tubal disease to improve fertility outcomes.

Methods

Three scenarios are shown demonstrating laparoscopic surgical techniques of fallopian tubes deemed to have good, intermediate and poor prognosis.

Results

Successful management of tubal disease in various scenarios.

Conclusions

Tubal disease is responsible for 25-30% of all female infertility. Several risk factors exist. The utilisation of pre-operative assessment tools as well as intra-operative findings, can allow a surgeon to make an informed decision of whether to repair and restore versus remove the fallopian tube to improve fertility outcome.

<https://player.vimeo.com/video/334698446?autoplay=1>

ES28-0140 - Free Communication 7

Minilaparoscopic tubal reanastomosis

Rok Sumak¹, Andres Viguera Smith¹, Neeraj Kulkarni¹, Deepti Pinto Rosario¹, Helder Ferreira¹
¹Gynaecology, Centro Hospitalar Universitário do Porto, Porto, Portugal

Background

The purpose of this video is to demonstrate minilaparoscopic tubal reanastomosis procedure.

Methods

This is the case of 38 year old multiparous woman, G2P2, after 2 caesarean sections and tubal ligation. She presented to our centre with high desire of pregnancy. She had no comorbidities, preoperative work-up exams were normal. She underwent minilaparoscopic tubal reanastomosis. This is the case of 38 year old multiparous woman, G2P2, after 2 caesarean sections and tubal ligation. She presented to our centre with high desire of pregnancy. She had no comorbidities, preoperative work-up exams were normal. She underwent minilaparoscopic tubal reanastomosis.

Results

In this procedure we used 6mm optical trocar with 5mm zero degrees endoscope and additional three 3mm trocars. One placed suprapubically and two laterally. Tubal stumps were identified. One polyglactine 2/0 suture was placed at the level of mesosalpinx, to approximate the proximal and distal stumps and reduce tissue tension. Mesosalpinx was infiltrated with diluted vasopressin for hydrodissection and prevention of bleeding. Scar tissue in the mesosalpinx and tubal stumps was resected by using grasper and cold scissors. Proximal and distal stumps were transected at the point of obstruction and tubal opening was identified. Finally, the muscle layer of the two stumps was sutured with four simple interrupted sutures using a polyglycaprone 4/0 suture by placing it at three, six, nine and twelve o'clock. Contralateral tube was operated in the same manner.

Conclusions

Minilaparoscopy is a feasible and safe approach for tubal reanastomosis.

<https://player.vimeo.com/video/335668433?autoplay=1>

**ES28-0671 -
Free Communication 7**

Transabdominal cerclage cutting into the cervix after dilatation and evacuation: laparoscopic removal and re-insertion

Martin Hirsch¹, Dan Reisel¹, Ertan Saridogan¹

¹University College London Hospital, Gynaecology, London, United Kingdom

Background

Transabdominal cerclage (TAC) is a recognised treatment for cervical incompetence. This can be performed via an open procedure or a laparoscopic technique. Complications include failure and suture migration.

Methods

We present a video abstract of hysteroscopic assessment and freeing of suture of a TAC followed by laparoscopic retrieval and re-insertion.

Results

This technique uses a modified curved to straight blunt needle with mersilene tape.

Conclusions

Transabdominal cerclage migration following dilation and evacuation is a rare but recognised complication. Hysteroscopic freeing and laparoscopic retrieval of a migrated TAC is a feasible surgical approach.

<https://player.vimeo.com/video/339220449?autoplay=1>

**ES28-0294 -
Free Communication 9**

An easy and safe procedure via laparoendoscopic single-site surgery for large ovary cyst

Yawen Wang¹, Ying Zheng¹, Sijing Chen¹, Liufeng Xu¹, Lin Chen¹, Na Wang¹

¹West China Second Hospital- SCU, Gynaecologic Oncology, Chengdu, China

Background

We performed a giant ovarian cystectomy through laparoendoscopic single-site (LESS) approach in a new procedure, extracorporeal cystectomy by using a multiple channel port through a transumbilical access, and we demonstrated LESS is safer and more feasible for large ovarian cysts with benign features.

Methods

A 24-year-old woman presented with large pelvic mass on gynaecologic examination. CT scan covered a cystic components (14.4 × 9.3 × 15.2cm) arising from right ovary. Tumour markers including CA125 and CA19.9 were normal. A benign ovarian cyst was suspected. Subsequently, LESS ovarian cystectomy was performed by an experienced surgeon in our department.

Results

The surgery continued 100 minutes, the volume of blood loss was 50 ml, without either spillage of the cyst contents or intra/postoperative complications. We did plastic surgery of umbilicus perfectly for cosmetic outcome.

Conclusions

Our video covered that LESS approach combined extracorporeal cystectomy and intracorporeal procedures while overcame the limitations of conventional laparoscopy, like possibility of rupture in enterocoelia, the difficulty in inserting trocar and removing surgical specimen, etc. Management of large adnexal tumours by LESS surgery with a wound retractor also reduced the potential incisional morbidity, practiced tumour-free principle strictly and got more cosmic outcomes compared with laparotomy.

<https://player.vimeo.com/video/336299291?autoplay=1>

Laparoscopic cystectomy for ovarian teratoma in 10 steps

Sara Paracchini¹, Valentina Fava², Pauline Chauvet³, Lucy Jaillet⁴, Michel Canis⁵, Nicolas Bourdel⁶

¹AOU Città della Scienza e della Salute - University of Torino, Department of surgical sciences, Torino, Italy

²University of Catania, Department of general surgery and medical surgical specialities, Catania, Italy

³CHU Estaing- EnCoV Université Clermont Auvergne, Department of gynaecological surgery, Clermont-Ferrand, France

⁴CHU Estaing, Department of gynaecological surgery, Clermont-Ferrand, France

⁵CHU Estaing - EnCoV Université Clermont Auvergne, Department of gynaecological surgery, Clermont-Ferrand, France

⁶CHU Estaing - EnCoV Université Clermont Auvergne, Department of gynaecological surgery, Clermont-Ferrand, France

Background

Laparoscopic cystectomy for ovarian teratomas has the advantages of a minimally invasive approach. The standardisation and description of the technique are the main objectives of this video. We described the surgery in 10 steps, which could help make this procedure easier and safer.

Methods

A French university tertiary care hospital.

Patients with ovarian teratomas with indication for laparoscopic cystectomy. The local institutional review board ruled that approval was not required for this video article because the video describes a technique and does not report a clinical case.

Intervention:

Standardised laparoscopic cystectomy were recorded to realise the video.

Results

This video presents a systematic approach to cystectomy for teratoma clearly divided into 10 steps: (1) planning of the surgery; (2) ergonomics and materials; (3) exploration and cytology; (4) prevention of peritoneal spillage; (5) mobilization of the ovary; (6) incision of the ovary; (7) dissection; (8) haemostasis; (9) exteriorisation of the cyst; (10) washing and exploration.

Conclusions

Standardization of laparoscopic cystectomy for ovarian teratoma could make this procedure easier and safer to perform. The 10 steps presented help to perform each part of surgery in logical sequence making the procedure ergonomic and easier to adopt and learn. Moreover, the standardisation of the surgical techniques could reduce the learning curve.

<https://player.vimeo.com/video/336272519?autoplay=1>

ES28-0353 - VP045
Free Communication 9

The triple lift: ovarian and uterine suspension for laparoscopic excision of DIE. The CEMIG method

Michael Adamczyk¹, Shaheen Khazali¹

¹Cemig- St Peter's Hospital, Gynaecology, Chertsey, United Kingdom

Background

In this video, we demonstrate a case of deep infiltrating endometriosis involving bowel and invading into the vagina. This was managed laparoscopically by a multidisciplinary team performing segmental bowel resection, excision of a full-thickness vaginal nodule, bilateral salpingectomy, bilateral ureterolysis and primary repair of left ureteric injury.

Methods

Following extensive adhesiolysis and restoring anatomy, laparoscopic suspension of the uterus and both ovaries was performed to improve surgical access. In our experience, this straightforward step is crucial for surgical comfort and manoeuvrability. Lifting the ovaries provides more desirable operating space, giving clear and direct access to the pelvic sidewalls.

Results

This technique enables the assistant to retract tissue medially when performing ureterolysis and, in this case, repair of left ureteric injury. It also allows the ovaries to be temporarily suspended during recovery to prevent adhesions. The uterus was then suspended at a 90-degree angle from its most distal posterior aspect providing exposure and traction when dissecting the rectum. The amount of traction can be easily adjusted by tightening of the suture.

Conclusions

We believe that this type of uterine manipulation is superior to most commercially available uterine manipulators when performing bowel dissection. By suspending the uterus, we also eliminate the need for a third assistant. At the end of the operation omental flap was pulled towards the pelvis and sutured bilaterally to uterosacral ligaments. In theory, this step will minimize the risk of recto-vaginal fistula formation.

<https://player.vimeo.com/video/336426121?autoplay=1>

ES28-0552 -
Free Communication 9

Laparoscopic excision of ovarian remnant causing chronic pelvic

Angharad Jones¹, Caryl Thomas¹, Richard Penketh¹

¹University Hospital of Wales, Obstetrics and Gynaecology, Cardiff, United Kingdom

Background

A 38-year-old G0 was diagnosed with endometriosis aged 17, subsequently undergoing 37 laparoscopies for pelvic pain. Total laparoscopic hysterectomy and bilateral salpingo-oophorectomy was performed aged 32, reported as technically difficult due to deep infiltrating endometriosis and dense adhesions. She continued to suffer with pelvic pain, having multiple admissions with subacute small bowel obstruction and becoming opiate dependent. A trial of progesterone and GnRH was unsuccessful due to side effects. In 2017 ultrasound showed a cystic structure in the right pelvis, suggesting ovarian remnant confirmed by FSH and oestradiol levels.

Methods

Laparoscopic adhesiolysis and excision of ovarian remnant was scheduled and Clomiphene 50mg prescribed 2 weeks preoperatively to stimulate the ovarian tissue, aiming to facilitate visual identification and excision. Intraoperative ultrasound demonstrated the desired effect of increased ovarian volume. On entry there were dense adhesions obliterating the pelvis. Methodical adhesiolysis was achieved with a mixture of blunt dissection and monopolar energy. The ovarian remnant was visualised in the right pelvis surrounded by thickened peritoneum. The ureter was identified, unexpectedly pulled medially by bowel adhesions. Ureterolysis was performed down to the ovarian remnant, which was dissected at its lateral border to allow the ureter to fall to a lateral place of safety. A finger in the vagina allowed

further counter-traction of tissues and visualisation of the medial borders. The ovarian remnant was safely excised and placed in a retrieval bag, with the cystic elements aspirated to reduce the specimen volume, facilitating removal via the 5mm right iliac fossa port incision.

Results

The remnant ovarian tissue was excised in its entirety, with the pelvic anatomy restored and the bowel mobile at the end of the procedure. The patient was discharged within 24 hours postoperatively and has had significant improvement in symptoms on follow-up.

Conclusions

Consider remnant ovarian tissue in endometriosis patients who have had prior difficult hysterectomy and bilateral salpingoophorectomy who report continued pain. Clomiphene effectively enlarges remnant ovary to aid identification and facilitate complete excision. Before excising pathology, when presented with distorted anatomy it is important to identify and restore key anatomical structures to ensure the safest approach.

<https://player.vimeo.com/video/339009487?autoplay=1>

ES28-0602 - Free Communication 9

A rare case of omental pregnancy laparoscopically treated

Alessandra Borgia¹, Federica Manzara¹, Paolo Salucci¹, Eugenia Degli Esposti¹, Diego Raimondo¹, Renato Seracchioli¹

¹Sant'Orsola Hospital, University of Bologna- Gynaecology and Human Reproduction Physiopathology, Bologna, Italy

Background

Ectopic pregnancy (EP) represents 1,5 to 2% of all pregnancies. It may represent a gynaecologic emergency and it is the most frequent cause of maternal death during the first trimester of gestation. Abdominal and omental pregnancies are the rarest forms of EP, with an estimated incidence of 1.4 % among EP. The mortality rate of omental pregnancy is particularly high, due to the increased risk of rupture and consequently of haemorrhagic shock.

Methods

A healthy 19-year-old woman looking for spontaneous pregnancy, with a previous history of one spontaneous delivery, was referred to our emergency unit complaining of acute pelvic pain and minimal vaginal bleeding. She reported a positive pregnancy test. The physical examination showed stable vital signs, diffuse abdominal tenderness, with a negative Blumberg's sign. The transvaginal ultrasound did not demonstrate any signs of regular pregnancy inside the uterus. The endometrium was hyperechogenic and measured 10 mm of maximum thickness. Near the right ovary a 12 mm round anechoic structure (bagel sign) containing an embryo with cardiac activity was observed. The patient was scheduled for laparoscopy and informed consent was obtained.

Results

Intraoperatively, a small amount of blood was reported in the Douglas pouch. The diagnostic laparoscopy showed no enlargement or distortion of the fallopian tubes. A bloody structure was noticed on the greater omentum suspicious for omental pregnancy. A partial omental resection was therefore performed. The patient was discharged after three days with negative physical examination, normal blood exams and a decreasing serum human chorionic gonadotropin. The presence of omental pregnancy was confirmed by histological examination.

Conclusions

Omental pregnancy is a rare form of EP and its preoperative diagnosis can be very challenging, since it often mimics another kind of ectopic pregnancy. Despite this, laparoscopy can successfully diagnose omental pregnancy, representing at the same time a feasible and safe treatment.

<https://player.vimeo.com/video/339167940?autoplay=1>

**ES28-0064 -
Free Communication 10**

Surgical removal of a symptomatic abdominal wall endometriosis nodule: a new pre-aponeurosis endoscopic approach

Helder Ferreira¹, Andres Vigeras Smith¹

¹*Centro Hospitalar Universitário do Porto, Minimally Invasive Gynaecological Surgery Unit, Porto, Portugal*

Background

Video Objective: to demonstrate the surgical technique of laparoscopic pre-aponeurotic resection of anterior abdominal wall deep endometriosis nodule.

Setting: Deep endometriosis implants involving the anterior abdominal wall are uncommon (0.03-3.5%) and mainly related to previous uterine surgery as a caesarean delivery, allowing the endometrial tissue transplantation. Clinical diagnosis is often difficult due the lack of suspicion by the physician who may mistake for other benign conditions as granulomas or incisional hernias. Imaging is a key part on diagnosis suspicion (ultrasound/MRI). Surgery is the treatment of choice for symptomatic nodules in whom medical options are ineffective or not suitable.

Methods

Interventions: An endoscopic approach to the deep endometriotic nodule was performed. Under general anaesthesia, the patient was placed in 0 degrees dorsal decubitus with her arms alongside her body. Pre-aponeurotic Co2 insufflation and dissection was performed using four trocars: a 10-mm trocar at the left para-median line, about 2 cm upper to the bi-iliac line, for zero-degree laparoscope; a 10-mm trocar in the middle third of the caesarean scar; a 5-mm trocar in right-lateral third of the caesarean scar and a 5-mm trocar in the left-lateral third of the caesarean scar. Pre-aponeurosis dissection was performed using blunt and sharp dissection with cold scissors and ultrasonic energy.

Results

Complete resection of deep endo nodule was done after complete identification and dissection. Extraction was done using an endobag and fascial defect was closed by using 2-0 barbed suture. Patient was discharge in the first day postoperatively without any complications and remain asymptomatic up to 10 months of follow up, with excellent cosmetically result.

Conclusions

Conclusion: Anterior abdominal wall endometriosis is an uncommon but symptomatic localisation. The laparoscopic pre-aponeurotic resection is a feasible and effective technique, avoiding large abdominal incisions. In this patient, nodule resection was performed laparoscopically without any intra or post-operative complications

<https://player.vimeo.com/video/332852925?autoplay=1>

**ES28-0373 -
Free Communication 11**

Intraoperative endoscopic ultrasound-guided surgical treatment of Herlyn-Werner-Wunderlich syndrome - a case report of a rare syndrome

Mara Albanese¹, Maria Cristina Moruzzi¹, Giulia Bolomini¹, Ursula Catena¹, Antonia Carla Testa¹, Giovanni Scambia¹

¹*Fondazione Policlinico Universitario Agostino Gemelli- IRCCS,*

Dipartimento Scienze della Salute della Donna- del Bambino e di Sanità Pubblica- UOC di Ginecologia Oncologica, Roma, Italy

Background

Herlyn-Werner-Wunderlich (HWW) syndrome is a rare congenital anomaly characterized by uterus didelphys, obstructed hemivagina and ipsilateral renal-ureteral agenesis. We illustrate clinical presentation, diagnostic management and successfully fertility-sparing minimally invasive treatment of a case, supported by full time intraoperative endoscopic ultrasound guidance.

Methods

A twenty-year-old woman was admitted to our department with 1-month history of lower abdominal pain. At ultrasonography, an abdominal regular mass of 197x83x120 mm, tender to the push of ultrasound probe and with a "jelly like" content was revealed. Absent flow at Doppler examination. The mass was connected to the uterine body which was dislocated in the right hypochondrium. The right kidney was absent.

Herlyn-Werner-Wunderlich syndrome was hypothesized by magnetic resonance imaging in consideration of the right renal agenesis, uterus didelphys and unilateral obstructed hemivagina with resultant hematocolpos. Diagnostic laparoscopy revealed normal ovaries and fallopian tubes, but two uterine bodies (uterus didelphys) and the presence of the abdominal mass, soft by laparoscopic forceps. An intraoperative ultrasound exam was required to clarify the origin of the formation, to guide surgeon during transvaginal incision with drainage of hematocolpos and then during hysteroscopy.

Hysteroscopy showed a left external uterine ostium with a regular cervix, a left hemicavity with a single fallopian tube ostium and on the right side, after the incision of the septum, a right external uterine ostium with a regular cervix, leading to a right hemicavity with a single fallopian tube ostium.

Results

The procedure took 30 minutes, without any surgical complications. After the procedure an ultrasound was performed showing two regular uterine hemicavities and the complete resolution of hematocolpos.

Conclusions

The purpose of full-time endoscopic ultrasound guidance, during minimally invasive surgical treatment of a HWW case in a young woman, is to support the surgeon during difficult procedures, to prevent surgical complications and to realize a fertility sparing minimally invasive treatment.

<https://player.vimeo.com/video/336434090?autoplay=1>

ES28-0494 - Free Communication 11

Laparoscopic excision of an obstructed noncommunicating cavity in a unicornuate uterus

Madalena Tavares¹, Sónia Barata², Marta Magro², João Alves², Filipa Osorio²

¹*Hospital Vila Franca de Xira, Obstetrics-Gynaecology, Lisbon, Portugal*

²*Hospital da Luz Lisboa, Obstetrics-Gynaecology, Lisbon, Portugal*

Background

Congenital uterine anomalies are defined as deviations from the normal uterine anatomy that develop during embryonic life. Unicornuate uterus is a rare congenital uterine anomaly. Its incidence was reported to be approximately 2.4–13.7% of all uterine malformations (Engmann et al., 2004), although its accurate incidence is unknown because some cases are never identified and reported prevalence varies according to the studied population.

Methods

We present a video demonstrating the case of an 18-year-old teenager with unremarkable medical and familial history referred to our clinic due to moderate dysmenorrhea (6/10). Her clinical exam showed no anomalies, namely vaginal or cervical. The ultrasound and magnetic resonance revealed a unicornuate uterus with a rudimentary right cavity with approximately 40x30mm. Both ovaries were normal.

The patient was scheduled for a diagnostic laparoscopy with eventual surgical treatment.

Results

Laparoscopy confirmed the diagnosis of a unicornuate or hemi-uterus with an obstructed noncommunicating cavity on the right side (Class U4a, according to 2013 ESHRE/ESGE classification).

The hemi-uterus, both fallopian tubes and ovaries were normal.

It was performed an excision of the rudimentary cavity and right salpingectomy with visualisation of chocolate fluid compatible with old blood from the obstructed cavity. Blue dye testing was made confirming the cervix-hemi-uterus

communication and permeability of the left fallopian tube. The patient recovered uneventfully and is asymptomatic. Pathology confirmed rudimentary hemi-uterus.

Conclusions

In teenagers with pelvic cyclic pain, the ultrasound is a fundamental tool to detect a possible congenital uterine anomaly. In case of doubt, magnetic resonance may complement the diagnosis.

In case of an unicornuate or hemi-uterus with an obstructed non-communicating cavity, the gold standard treatment is the laparoscopic removal of the obstructed rudimentary uterine horn to resolve the patient's symptoms.

<https://player.vimeo.com/video/338706028?autoplay=1>

ES28-0648 - Free Communication 11

A complex case of complete septate uterus with double cervix, partial longitudinal vaginal septum (U2bC2V1a ESHRE/ESGE Classification) and intramural myoma: diagnosis and treatment

Antonella D'Apollito¹, Luigi Della Corte¹, Alfonso Manzi¹, Pierluigi Giampaolino², Valentino De Vivo¹, Giuseppe Bifulco²

¹University of Naples Federico II,

Department of Neuroscience- Reproductive Sciences and Dentistry- School of Medicine- University of Naples Federico II- Naples- Italy, Naples, Italy

²University of Naples Federico II,

Department of Public Health- School of Medicine- University of Naples Federico II- Naples- Italy, Naples, Italy

Background

We report a successful hysteroscopic treatment of a complete septate uterus with double cervix and partial longitudinal vaginal septum (U2bC2V1a ESHRE/ESGE Classification) and intramural-submucosal myoma

Methods

A 37-year-old patient referred to our Department of Obstetrics and Gynaecology for menorrhagia and dyspareunia. Bimanual pelvic examination showed a partial longitudinal vaginal septum. 2D Pelvic ultrasound showed a myoma of the anterior wall (size:32x30 mm); the axial scan evinced a doubling of the endometrial profile. 3D Pelvic ultrasound showed a complete septate uterus with double cervix. During an office hysteroscopy, the suspicion was confirmed. The patient was then scheduled for an in-patient hysteroscopy.

Results

The partial longitudinal vaginal septum was removed by 5 Fr bipolar electrode. According to the traditional approach we excluded the cervical canal from any resection, thus initiating resection from the isthmic portion of the septum. According to this approach, the cervix of the larger uterine hemicavity was gradually dilated.

Operative hysteroscopic metroplasty with 5 Fr bipolar electrode and 5 Fr blunt scissors was performed until the visualization of both uterine tubal ostia. The intrauterine palpator allowed precisely measure that portion of the septum that has already been sectioned. The uterine myoma with 26 Fr resectoscope was removed.

At the end of procedure an antiadhesive gel based autocross link hyaluronic acid was applied. A single normal endometrial cavity was obtained.

At 3 months follow up office hysteroscopy, we could detect a normal, single, uterine cavity without postsurgical adhesions with only a residual scar tissue in myoma fovea which was treated with 16 Fr miniresectoscope.

Conclusions

Operative hysteroscopy is the gold standard in the treatment of Mullerian anomalies amenable to surgical correction in order to restore the physiological uterine cavity so as to increase the fertility outcomes.

<https://player.vimeo.com/video/339208252?autoplay=1>

OHVIRA syndrome: a case series of a rare Mullerian anomaly

Elakhras Sayed¹, Mohamed Salama², Daa Ali³

¹*Omam Hospital, Minimally Invasive Surgery, Cairo, Egypt*

²*Ain Shams Faculty of Medicine, Obstetrics and Gynaecology, Cairo, Egypt*

³*Al Galaa Teaching Hospital, Obstetrics and Gynaecology, Cairo, Egypt*

Background

Herlyn-Werner-Wunderlich syndrome, also known as OHVIRA (Obstructed hemivagina and ipsilateral renal anomaly) is an extremely rare syndrome characterized by a congenital defect of the lower abdominal and pelvic organs.

It is a type of abnormality of the Müllerian ducts. In most cases, OHVIRA presents as a double uterus with unilateral obstructed (or blind) hemivagina and ipsilateral renal agenesis. It can also affect the urethra, ureters, bladder and spleen. Although the true incidence is unknown, it has been reported to be 0.1-3%

Methods

We hereby present a case series of 3 cases of this rare Mullerian anomaly. Two were adult females in their twenties, presented with dyspareunia, chronic pelvic pain, and infertility.

One of them, that we are hereby highlighting, underwent laparotomy twice, attempting to perform unification metroplasty for the mis-diagnosis of a bicornuate uterus. She has had a second laparotomy to re-cannulate the previously formed communication of the 2 horns, alongside incision of a newly-discovered transverse vaginal septum. When this lady presented to us, we decided for laparoscopy, especially that the MRI showed 2 uterine horns, and a 5x6 cystic pelvic structure. Additionally, a single kidney was identified. Laparoscopic findings are as follows in the results section.

The second case we hint on was an eleven years old girl, who presented with pelvic pain and dysmenorrhea. The radiological findings reported an apparently chocolate ovarian cyst, for which diagnosis, she was submitted to laparoscopy.

Results

EUA and Hysteroscopy of the first case revealed a single vagina and cervix, leading to a hemi-uterus, with a tubal ostium.

Cystoscopy revealed a single ureteric orifice on the right.

Laparoscopy revealed extensive omental and bowel adhesions that were dissected, revealing 2 uterine horns, overlying a pelvic cystic structure. The left hemi-uterus was then dissected from the anterior abdominal wall and the urinary bladder. By combined laparoscopic visualisation and digital vaginal examination, the diagnosis of OHVIRA syndrome was suspected.

A laparoscopic aspiration needle was introduced into what turned out to be a haematocolpos. A large amount of retained blood was drained. This puncture site was extended to pass an instrument, under guidance of the vaginal finger, to come out at the introitus. This opening through the oblique longitudinal septum was then widened and sutured vaginally, thus, unifying the vaginal lumen.

Hysteroscopy through this vagina revealed another cervix leading to the left hemi-uterus.

The findings in the second case were similar, but with widespread endometriotic lesions.

Conclusions

OHVIRA syndrome is a rare complex Mullerian anomaly, that can present with progressive pelvic pain, dysmenorrhea and hematocolpos. Due to the unfamiliarity with this syndrome, and the overlap with other developmental anomalies, diagnosis can be missed, and consequently management may be misdirected.

In most cases, the blind hemi-vagina is opened, and the fluid drained through a combined laparoscopic and hysteroscopic approach by a multidisciplinary team.

**ES28-0178 -
Free Communication 13**

From chaos to order: restoring anatomy in a frozen pelvis

Konstantinos Kyriakopoulos¹, Shaheen Khazali¹, Vasileios Minas¹, Matthiew Errity¹

¹NHS, Centre for Endometriosis and Minimal Invasive Gynaecology, Chertsey, United Kingdom

Background

Frozen pelvis/deep infiltrating endometriosis is one of the most intimidating spectacles a gynaecologist can come across during a laparoscopy. In this video we demonstrate our structured approach used in our unit in order to restore anatomy in cases of frozen pelvis.

Methods

This is an edited video of a procedure performed at our unit in Chertsey, UK, CEMIG (Centre for Endometriosis and Minimal Invasive Gynaecology).

Results

We follow a structured approach which we call by the mnemonic “**SO SURE Resection**”. Depending on the case there may be an adjustment on the above order but in general the acronym itself is a well structured approach that facilitates the procedure.

The stages of the excision are as following:

1. **S**urvey of lower and upper abdomen and **S**igmoid mobilization
2. **O**varian mobilization (combination of sharp/blunt dissection)
4. a. **S**uspension of uterus using sutures
b. **S**uspension of ovaries
 1. **U**reterolysis
 2. **R**ectovaginal septum entry (disease is left on the uterus and normal tissue is entered in the rectovaginal space)
 3. **E**nter into pararectal space
8. **R**esection of the endometriotic nodule/nodules (care is taken to lateralise the hypogastric nerve)

At the end of the procedure we perform the Michellin test to ensure the integrity of rectal wall.

Conclusions

Following a structured approach ensures a safer and quicker procedure. It also provides a cleaner and more satisfying surgical field where all anatomical structures, including the hypogastric nerves) can be easily seen and preserved.

<https://player.vimeo.com/video/335960559?autoplay=1>

**ES28-0293 -
Free Communication 13**

Laparoscopic approach for bladder endometriosis

Laura Balcells¹, Pia Español Lloret¹, Rocío Luna Guibourg¹, Cristina Soler Moreno¹, Ramón Rovira Negre¹

¹Hospital Sant Pau i de la Santa Creu, Gynaecology and Obstetrics, Barcelona, Spain

Background

The objective of this abstract is to describe surgical approach and strategy in laparoscopic excision of deep infiltrating bladder endometriosis through a clinical case.

Methods

A 28-year-old woman was referred to our centre presenting 12-months history of dysuria and tenesmus on a background of 3-years of dysmenorrhea.

Transvaginal-ultrasound performed by a specialised sonographer showed a 26x25mm nodule invading posterior bladder wall, a 6cm right ovarian cyst and a left utero-sacral nodule compatible with DIE. No hydronephrosis signs were noticed and MRN shown similar findings.

The patient had no other relevant medical/surgical history; she was on contraceptive treatment during 7years but she stopped because she wanted to look for pregnancy.

After discussion in the endometriosis-committee, it was decided to perform a laparoscopic excision of the bladder nodule, the utero-sacral nodule and the ovarian cyst. A bilateral ureteric-stent was placed before the procedure.

Results

Imaging tests findings were confirmed in the laparoscopic procedure.

Surgical strategy of bladder endometriosis nodule initially consisted in bilateral paravesical fossae dissection, identification of both ureters and development of vesico-vaginal space (Yabuki's space) in the left side. Then, a transversal cystostomy in the medial part of the bladder body was performed, identifying nodule limits and ureteral insertion in the posterior bladder wall.

After Retzius space dissection, the defect was sutured using interrupted absorbable suture. Surgical procedure was completed with utero-sacral nodule resection and right ovarian cystectomy.

Postoperative course was uneventful and the patient was discharged on 4th-day. A vesical catheter was left in situ for 2-weeks; before removing bladder catheter a cystography to exclude bladder suture defect was performed. Histopathological analysis of the lesion confirmed endometriosis. After 4 weeks, the patient describes resolution of urinary symptoms.

Conclusions

Laparoscopic excision of deep infiltrating bladder endometriosis is a safe and feasible procedure in referral centres.

<https://player.vimeo.com/video/336328938?autoplay=1>

**ES28-0514 -
Free Communication 13**

Intra-operative decision making: rectal shave versus bowel resection

Janet Berry¹, Denis Tsepov², Priya Narayanan²

¹Queen Alexandra Hospital, Gynaecology, Portsmouth, United Kingdom

²Harley Street BSGE Endometriosis Centre- The Harley Street Clinic, Gynaecology, London, United Kingdom

Background

Surgery for deeply infiltrating endometriosis of the rectum/rectosigmoid aims to remove all disease whilst minimising surgical morbidity to improve pain symptoms (dysmenorrhoea, dyspareunia and dyschesia). Shaving gives a lower risk of immediate complications than resection, with better functional bowel outcomes and should be considered first line treatment for non-infiltrating rectal/recto-sigmoid colon nodules. The nodule characteristics (size, depth of invasion into the bowel muscularis, distance from the anal verge) are key factors in determining surgical strategy.

Pre-operative MRI can be useful in planning surgery by anticipating both type of bowel excision and degree of multidisciplinary support required. This is important for counselling and consenting the patient and in planning efficient use of resources.

This patient's pre-operative MRI suggested that full excision would be achievable with shaving, as a fat plane was preserved between the nodule and the rectal muscularis. The patient was accordingly planned for fertility sparing laparoscopic excision of endometriosis and rectal shave however colorectal support was available if required.

Methods

This video shows standard steps of ureterolysis to lateralise the ureters away from the nodule and pararectal space dissection with preservation of the hypogastric nerves to isolate the rectal nodule. Preliminary shaving of the rectovaginal nodule to determine the size and depth of invasion is shown, followed by full thickness vaginal nodule excision, closure with a 2/0 barbed suture, and completed excision of rectal nodule with shaving.

Results

Intra-operatively the rectovaginal nodule appeared larger and more invasive than expected. Initially we thought removal may require a disc or segmental resection. With preliminary shaving, the fat plane described by the MRI was demonstrated between the nodule and muscularis and complete excision of the nodule was achieved with shaving.

Conclusions

This video demonstrates correlation between the pre-operative mri and intra-operative findings, allowing complete excision of endometriosis by the rectal shaving.

<https://player.vimeo.com/video/338897384?autoplay=1>

ES28-0676 - Free Communication 15

Laparoscopic removal of migrated Essure® device after two surgeries: knowing what and where to look for

Ignacio Garitano¹, Javier Álvarez-Sala¹, Laura Barbero¹, Andrea Puente¹, Lorena Reka², Gabriel Martínez-Aragón²

¹Hospital Universitario de Álava, Gynaecology and Obstetrics, Vitoria-Gasteiz, Spain

²Hospital Universitario de Álava, General Surgery, Vitoria-Gasteiz, Spain

Background

Surgeries aiming at removing Essure® intratubal devices are increasing in our region. Secondary effects like chronic pelvic pain as well as fear after media releases are the main causes. We present a case of a patient with pelvic pain and suspect of having remaining parts of an Essure® device within her upper abdomen. She came from a neighbouring province asking for a second opinion after two surgeries and an office hysteroscopy for successful Essure® removal.

Methods

Full medical history from other hospital is presented. Symptoms remained and the patient insisted in surgical search and removal of foreign body. We conducted complete anamnesis, examination, image studies as well as cultures and HPV detection

Results

A metallic foreign body was detected by abdominopelvic CT scan and abdomen X-Ray. MRI did not strongly suspect foreign body and ultrasound examination was normal. We planned a surgery for laparoscopic search and removal of metallic foreign body as well as total hysterectomy and left oophorectomy.

Conclusions

Our team of gynaecologists and general surgeons performed a laparoscopic operation that found and removed an ensure device from the colon splenic angle.

<https://player.vimeo.com/video/339244283?autoplay=1>

**ES28-0320 -
Free Communication 15**

Laparoscopic salpingo-oophorectomy with mini laparotomy in a 17-year-old nulligravid with sclerosing stromal tumour (SST) of the ovary: a case report

Sharma Paquirigan¹, Jennifer Aranzamendez¹, Maria Rica Baltazar¹

¹Quirino Memorial Medical Centre, Obstetrics and Gynaecology- Section of Minimally Invasive Surgery, Quezon City- NCR, Philippines

Background

Sclerosing stromal tumour (SST) is a rare benign sex cord-stromal ovarian tumour typically encountered in young females and is amenable to treatment by minimally invasive surgery. These tumours are hormonally inactive and usually present with nonspecific symptoms. This case report described laparoscopic removal of the tumour with mini laparotomy in a 17-year-old patient presented with secondary amenorrhea with limited preoperative assessment consisting only of series of transrectal ultrasound, gynaecologic oncology service evaluation and ovarian serum tumour markers.

Methods

The contemplated procedure was a laparoscopic oophorocystectomy on the left ovary. A custom made endoscopic specimen bag was placed under the left ovary prior to oophorocystectomy to prevent spillage in the peritoneal cavity. During laparoscopy, the adherence of the capsule to the ovary and the solid nature of the mass caused difficulty in performing oophorocystectomy hence an unilateral salpingo-ooplectomy was done instead. Due to the concrete nature of the ovarian mass not being amenable for manual morcellation and the unavailability of a laparoscopic morcellator, a mini laparotomy was done to retrieve the specimen. An anti-adhesive tool was placed on the left adnexa to decreased risk of postoperative adhesions and incisional wounds were closed in layers with a delayed absorbable suture.

Results

She had an uneventful postoperative course and had her regular period a month after the surgery. The histopathological examination of the tumour was characterized by cellular pseudolobules, prominent interlobular fibrosis, marked vascularity and dual cell population, collagen producing spindle cells and lipid containing round or ovoid cells confirmed the diagnosis of sclerosing stromal tumor of the ovary.

Conclusions

The preoperative assessment of SST in a financially challenge patient and inadequately equipped institution may include a referral to gynaecologic oncology service which provides a significant aid to rule out malignancy and proceed to a laparoscopic procedure for a benign ovarian mass.

<https://player.vimeo.com/video/336380826?autoplay=1>

**ES28-0139 -
Free Communication 16**

The injuries of colon and its repair under transvaginal single port laparoscopy

Yisong Chen¹, Xiaojuan Wang¹

¹The Obstetrics and Gynaecology Hospital of Fudan University, Gynaecology Department, Shanghai, China

Background

With the application of transvaginal single-port laparoscopy, its related complications have attracted more and more attention, including injuries of colon.

Methods

Describe the injuries of colon and its repair under transvaginal laparoscopy step by step.

Results

Firstly, the fresh blood was found in left pelvic cavity, but the injury wasn't found and bleeding continued. Secondly, the colon was washed by water, but the injury wasn't still found, and flushing fluid was stained blood. Thirdly, the colon was turned over again and there were two holes on the seromuscular layer of colon. Fourthly, the injuries were repaired by absorbable thread. But the third injury was made when the colon was checked dismayingly, so the colon was repaired again. At last, it was found that the injuries were made possibly at the process of the exposure of pelvic, and the colon was clamped by acute angle, after the whole video was play backed.

Conclusions

It should be avoided that the colon was clamped by acute angle and the adhesion of colon with left pelvic should be separated carefully.

<https://player.vimeo.com/video/336565041?autoplay=1>

ES28-0323 -

Free Communication 16

Obturator nerve resection

Margarita Montrimaitė¹, Mindaugas Silkunas¹, Daiva Bartkeviciene¹, Vilius Rudaitis¹

¹Vilnius University Hospital Santaros Klinikos, Gynaecology, Vilnius, Lithuania

Background

Pelvic lymphadenectomy is a major component of the surgical staging procedure for several gynaecologic malignancies as well as lymphadenectomy has a therapeutic goal in conditions in which removing nodes harbouring metastatic disease improves survival. Obturator nerve injury occurs in ~0,7 percent lymphadenectomies. Symptoms include numbness and paraesthesia on the medial aspect of the thigh, weakness in adduction of the thigh, posture and gait problems.

Methods

55 year-old woman presented with post-menopausal bleeding. After performing hysteroscopy and biopsy, histologic examination showed uterine well differentiated endometrioid adenocarcinoma. Laparoscopic total hysterectomy with bilateral salpingo-oophorectomy, pelvic and paraaortic lymphadenectomy and diaphragmatic peritoneal biopsy was performed. Histology confirmed uterine well differentiated endometrioid adenocarcinoma pT1bN1 and diaphragmatic peritoneal metastasis. Uterine carcinoma stage IVB by FIGO was diagnosed. 6 cycles of paclitaxel and carboplatin adjuvant chemotherapy were given. Afterwards the patient continued Megestrol acetate hormone therapy. Two years later Ca125 marker increased from 30,8 to 96,2 kU/l. Computed tomography and magnetic resonance imaging showed high risk of subcapsular liver metastasis and disease progression in right obturator fossa. Laparoscopy revealed several metastatic foci on right diaphragm peritoneum and one < 1 cm metastasis on left diaphragmatic peritoneum. ~2,5 cm diameter metastatic tumour was found infiltrating right obturator nerve and internal iliac vessels, also in close relationship with right external iliac vein and ureter. To ensure optimal treatment right pelvic metastasectomy with obturator nerve and internal iliac artery resection en bloc was performed. Laparoscopic right diaphragmatic peritonectomy, left diaphragmatic peritoneal metastasectomy and omentectomy were performed as well.

Results

After the surgery neither right leg sensory nor motor function were impaired. The patient claimed to feel no difference in both her leg's skin sensation and did not have any difficulty walking.

Conclusions

Clinical expression of obturator nerve injury can include motor deficits, sensory symptoms, or both. In patients who have undergone complete nerve resection, spontaneous recovery, when it occurs, is likely to result from a compensatory response by other thigh muscles or from the presence of an accessory obturator nerve. In selected cases, when benefit outweighs the risk, obturator nerve can be sacrificed in order to perform a complete resection of a tumour as there is a possibility that it will not cause any discomfort for the patient and improve survival.

<https://player.vimeo.com/video/336388720?autoplay=1>

BEST ePOSTER (32)

ES28-0047 - P*002
Selected E-Poster

Analysis on occurrence of placenta accreta at caesarean section of 125 cases of pregnancy after laparoscopic myomectomy

*Shinichiro Wada*¹, *Yoshiyuki Fukushi*¹, *Sachiko Matsumoto*¹, *Mai Nishimura*¹, *Yasuhiro Ohara*¹, *Takafumi Fujino*¹
¹*Teine Keijinkai Hospital, Obstetrics & Gynecology, Sapporo, Japan*

Background

Placenta accreta (PA) is a disease resulting in massive haemorrhage at delivery, however, it is difficult to predict before delivery. Myomectomy is supposed to cause PA, however, reports on analysis of the patients' background are not seen so much. Hereby we report the analysis an occurrence of PA after laparoscopic myomectomy (LM).

Methods

The subjects are 125 patients undergoing caesarean section (CS) during January, 2014 to March, 2018, who underwent LM in our institution before pregnancy. We analysed the patients' background, such as age, BMI, pregnancy by assisted reproductive technology (ART), history of operation of previous surgeries of uterus (two times of LM, abdominal myomectomy (AM), transcervical myomectomy (TCRM), transcervical polypectomy (TCRP), D&C, CS) and findings of LM (number of resected myoma nodule, weight of total myoma nodules, operation time, amount of haemorrhage, perforation of endometrium, insertion of uterine manipulator).

Results

PA occurred in eight cases (6.4%) in total. Univariate analysis revealed pregnancy by ART (18.5%), history of two times of LM (66.7%), history of TCRP (27.3%), perforation of endometrium (35.7%) showed significant difference. For those selected four factors, perforation of endometrium was selected as a factor influencing PA by multivariate analysis. Its odds ratio was 16.5, and 95% confidential interval was 2.47 to 110.

Conclusions

Endometrial perforation on LM is suggested to be a factor causing PA, therefore, we must prepare for massive haemorrhage at CS in such cases.

<https://esge.covr.be/cmdocumentmanagement/conferencemanager/documents/api/getdocument/4980/cmabstms/000070740/d06e2bd2f51ccfcb5937d9a51e0ad4a49a35e320948fcb6a91d2f7383cc4d110>

ES28-0061 - P*003
Selected E-Poster

Repeated ultrasound evaluation of the uterine caesarean niche during pregnancy: changes before and after laparoscopic niche repair and during subsequent pregnancy

*Inge Jordans*¹, *Wouter Hehenkamp*¹, *Jos Twisk*², *Robert de Leeuw*¹, *Christianne de Groot*¹, *Judith Huirne*¹
¹*Amsterdam UMC- location VUmc, Obstetrics & Gynaecology, Amsterdam, The Netherlands*
²*VU University, Epidemiology and Biostatistics, Amsterdam, The Netherlands*

Background

To evaluate the effect of laparoscopic niche repair on residual myometrium thickness (RMT) and niche size after surgery and in subsequent pregnancy compared to patients without previous niche surgery.

Methods

Prospective cohort study conducted at Amsterdam UMC, location VUmc, Amsterdam, The Netherlands, between February 2012 and May 2019. All pregnant women with a previous caesarean section (CS), who were diagnosed with a niche and received a laparoscopic niche resection prior to their current pregnancy, were included. Also pregnant women with a niche diagnosed before pregnancy, who did not receive niche repair because of minimal symptoms or relatively small niche (RMT >2 mm) were included. Participants underwent a transvaginal ultrasound (TVUS) at 12, 20 and 30 weeks of gestation to examine the CS scar. Niche measurements including length, depth and width, and RMT were performed.

Results

Preliminary analysis was performed in 86 patients, including 56 pregnant women with a previous laparoscopic niche repair (group 1) and 30 without a previous niche repair (group 2). Mean age of the total group at time of the first trimester ultrasound was 34,5 years and 63% had undergone 2 previous CSs or more. In group 1 the mean RMT increased at three months after surgery compared to baseline pre-surgery and retained its thickness in the first trimester. In group 2 the mean RMT before pregnancy and in the first trimester of pregnancy were also comparable. In both groups RMT decreased gradually during the pregnancy, however in the laparoscopic niche resection group the absolute RMT at 30 weeks of gestation was thicker than the control group. The results of mixed model analyses showed that RMT was significantly thicker in the intervention group in both first and second trimester. Also, the depth measured in the third trimester was significant smaller in the intervention group. Currently known pregnancy outcomes showed that 92% women in group 1 and 90% in group 2 received a planned CS. Median time of delivery of both groups was 38+1 weeks of gestation. Uterine dehiscence was seen during the CS in five patients (1/5 in group 1 and 4/5 in group 2). No uterine rupture was reported.

Conclusions

Laparoscopic repair of the uterine niche increases RMT after surgery and seems to have a positive influence on the RMT in subsequent pregnancy. In the first and second trimester there was less decrease of RMT compared to the control group without niche repair.

<https://esge.covr.be/cmdocumentmanagement/conferencemanager/documents/api/getdocument/5099/cmabstsms/000164460/99a39b6224f61ceae8a1079e517e4a1ed319813f0f5278ab0f30ed349c1ecb26>

ES28-0113 - P*004

Selected E-Poster

Outcome of impedance bipolar radiofrequency ablation (Novasure) for the management of heavy menstrual bleeding (HMB) in patients with scarred uterus

Shamma Al-Inizi¹, Neelam Agrawal²

¹Consultant obstetrician and gynaecologist, Obstetrics and Gynaecology- South Tyneside NHS Foundation Trust, South Shields, United Kingdom

²South Tyneside NHS Foundation Trust, Obstetrics and Gynaecology, South Shields, United Kingdom

Background

Outcome and limitations of Novasure ablation in women with scarred uterus over 3 year period was identified.

Methods

A retrospective case notes review of patients who underwent Novasure endometrial ablation for the management of HMB at South Tyneside hospital between November 2015 and December 2018. Outcome including successful completion of procedure, complications, hospital stay, readmission and reoperation (hysterectomy) were determined.

Results

Twenty six women with previous caesarean section (C/S) were included in the study. Eighteen women (69%) had one C/S, 5 women had two, one had three and two women (8%) had four C/S. Age ranged between 32 – 53 years. Most of procedures were uneventfully completed (22/26)/(84%), however, in four cases the procedure could not be performed due to: small sized cavity (1 case), patulous os (1 case), uterine perforation (1 case) or machine problem (1 case). All women went home same day apart from the one who had uterine perforation, stayed overnight for observation. Laparoscopic bilateral salpingectomy was performed in one out of 5 patients for permanent contraception. Nearly two third of women (15/22)-(68%) were very pleased with the outcome of procedure at 3 and 6

months follow up however; a third (7/22)-(31%) of women required a hysterectomy for persistent heavy bleeding or pelvic pain. The histology of the removed uterus confirmed leiomyomas with or without adenomyosis in all the cases explaining the possible cause of failed Novasure ablation.

Conclusions

Novasure endometrial ablation is a safe procedure for the management of HMB in women with scarred uterus with a high completion and success rates. However a cautious approach should be taken in selection of patients especially in women with uterine fibroids and adenomyosis as success rate might decline necessitating hysterectomy.

<https://esge.covr.be/cmdocumentmanagement/conferencemanager/documents/api/getdocument/5005/cmabstms/000164940/9412bc84719515990c8896d0b6b9415c8701deac75e39c094d8edcfcf99f79e4>

ES28-0128 - P*005

Selected E-Poster

Endometriosis in adolescence

Orestis Tsonis¹, Zoi Barmpalia¹, Fani Gkrozou¹, Ektoras Gazos², Minas Paschopoulos¹

¹*University Hospital of Ioannina, Obstetrics and Gynecology, Ioannina, Greece*

²*General Hospital of Karditsa, Obstetrics and Gynecology, Karditsa, Greece*

Background

Little is known about endometriosis in adolescents and its prevalence is yet to be estimated. Adolescents with a history of dysmenorrhea and chronic pelvic pain (CPP) imply findings suggestive of endometriosis. The severity of the disease is variable, from superficial endometriosis to deep endometriotic lesions or even ovarian endometriomas. The course of the disease also suggests the necessity of a more personalised approach since among adolescents, endometriosis could resolve or even aggravate with no particular pathophysiological pattern.

Methods

For this study, a review of the literature was conducted using 3 major search engines: PubMed, MEDLINE and Google and Google Scholar. The keywords in use were: endometriosis; adolescence; chronic pelvic pain; teenagers; More than 35 scientific papers on the subject were included providing essential information on signs and symptoms, pathogenesis, risk factors, management, diagnosis, recurrence and last but not least its association with adult endometriosis.

Results

Recent data proposes that these diseases do not have many similar aspects as once believed. Data suggests, that the adolescent variant, also known as Early-Onset Endometriosis (EOE), originates from Neonatal Uterine Bleeding (NUB), occurring approximately in 5% of neonates, and the possible pathophysiology of the disease involves endometrial progenitor cells infiltrating the pelvic cavity of a young women. These cells are proposed to be activated around thelarche. The disease seems to have more severe progression. Furthermore, risk factors are not quite similar. Thus adequate knowledge on the endometriosis variants is needed in order to establish effective management and personalized diagnosis. Symptoms on adult endometriosis expand further that CPP, involving primary infertility issues. The necessity of altered management in the teenagers is implied by the threat of future infertility and the presence of non-specific symptomatology. In adolescent endometriosis the diagnostic delay and the possible difference in the origins of the disease could explain cases of teenagers suffering from endometriosis, having severe symptoms especially when the ovaries are affected. The presentation of the disease in these 2 variants is also different. In adolescent endometriosis atypical, reddish, clear/polypoid or even vesicular lesions are common, whereas, in the adult form, typical "powder-burn" lesions are more likely to occur.

Conclusions

The pathogenesis of adolescent endometriosis as of adult endometriosis remain unclarified. Studies suggest that the prevalence is much higher than once believed. Focusing on adolescent endometriosis could reveal key factors of the origins of the disease and could facilitate an earlier diagnosis and a more effective management.

<https://esge.covr.be/cmdocumentmanagement/conferencemanager/documents/api/getdocument/4967/cmabstms/000164870/bd687b38c0d028c16a300d62aa614e0bc31f9bae8114fee2e56a9b22c3a03773>

Hysteroscopic treatment of retained placental tissue: case report and review of the literature

Angelos Danilidis¹, Anastasios Limperis², Roxani Dampali¹, George Pratilas¹, Christos Michalopoulos¹, Konstantinos Dinas¹

¹Hippokratio General Hospital Aristotle University, 2nd university Department of Obstetrics and Gynecology, Thessaloniki, Greece

²Hippokratio General Hospital Aristotle University, 2nd University Clinic in Obstetrics and Gynecology, Thessaloniki, Greece

Background

Retained placenta is one of the major causes of post partum haemorrhage. Treatment of placenta accreta is often a challenge and requires hysteroscopic skills.

Methods

We report a case of a primigravida who underwent emergency caesarean section, dilatation and curettage due to postpartum haemorrhage. Postnatally she was found to have placental remnants infiltrating myometrium and was subsequently treated with hysteroscopy.

A 40 years old nulliparous woman with no previous gynaecological operations underwent at 39 weeks an emergency caesarean section due to pathologic foetal electrocardiography (NST). The operation was standard and uncomplicated. 24 hour postnatally she developed post partum haemorrhage (PPH). She was managed medically with syntosynon, ergometrin and dilatation and curettage (D&C). Retained placental tissue was removed. She was discharged home uneventfully. 40 days later, on her postnatal follow-up, she complained for persistent spot bleeding. Transvaginal ultrasound was performed. An hyperhypoic unhomogenic structure within the fundus and posterior part of the endometrial cavity infiltrating also myomytrium up to 1cm from uterine serosa was found. B-hCG assay was negative. She underwent a hysteroscopy which confirmed the presence of placental tissue. With the help of the bipolar resectoscope we completely removed the placental remnants which was confirmed by histopathology. Energy was used to minimum and most of the operation was performed with blunt dissection use of the resectoscope. The patient was fully recovered.

Results

Hysteroscopic evacuation of placental tissue is the best option in cases of retained placental tissue. Hysteroscopy provides better visualisation and thus complete removal of the remnant when compared with the blind curettage with less risk of uterine perforation especially when infiltration in the myometrium is present.

Conclusions

In most cases of retained placenta curettage is sufficient but failure to empty the endometrial cavity reaches 7% especially when infiltration of the myometrium is involved. In such cases, the hysteroscopic evacuation is a feasible and safe option, with minimal energy use and mechanical blunt dissection with the resectoscope under vision. The case report shows the efficacy of the procedure.

<https://esge.covr.be/cmdocumentmanagement/conferencemanager/documents/api/getdocument/4924/cmabstsms/000044250/eae38df8b8b4c35a417fb3c47c269f2068dfae3c4fce7f2e95438dc30387229f>

Post-hysterectomy vault hematoma: incidence and correlation to postoperative pain score

Pia Damgaard Colding¹, Louise Arenholt², Anya Eidhammer²

¹Aalborg University Hospital, Dept. of Obstetrics and Gynecology, Aalborg, Denmark

²North Denmark Regional Hospital- Hjoerring, Dept. of Obstetrics and Gynecology, Hjoerring, Denmark

Background

Post hysterectomy vault hematoma is common, but the incidence (between 25% and 98%) and the significance of a vault hematoma is described with great inconsistency.

The correlation between the presence of a vault hematoma and postoperative pain has not previously been described.

Aim: To determine the incidence of vault hematoma after hysterectomy and to determine any correlation between vault hematoma and pain score/need of analgesics.

Methods

Women admitted for hysterectomy for benign causes were included in this prospective cohort-study study, from June 2017 to June 2018 in the department of obstetrics and gynecology, North Denmark Regional Hospital, Denmark.

Endovaginal ultrasound examination was performed three to five days after surgery. If a vault hematoma was present it was measured in three dimensions and the volume calculated. Depending on hematoma volume the women were divided in two groups:

Group one: No hematoma or hematoma < 5ml

Group two: Hematoma ≥ 5ml

The women filled out a questionnaire regarding daily pain score and use of analgesics for 14 days postoperative.

Results

Seventy-six women were invited, 56 women were included and had the ultrasound scan performed. In all, 51 questionnaires were returned. The distribution in operation procedure was: Forty-one women received total laparoscopic hysterectomy, 13 received total abdominal hysterectomy and two received vaginal hysterectomy.

The incidence of a vault hematoma ≥ 5ml was 34% (19/56), median volume: 13.4 ml, iqr: [6.6-29.8ml], largest: 64.9ml.

The women in group two were significantly younger (median=44 years) than in group one (median=48 years) $p=0.045$. Otherwise, no differences concerning pre- and peri-operative parameters were found between the two groups.

Daily patient reported pain-score was not significantly different between groups. The use of analgesics was higher among women with a hematoma above 5ml, this was statistically significant on day 13 regarding paracetamol ($p=0.04$) and at day 14 regarding ibuprofen ($p=0.02$).

No difference was seen on postoperative complications and the re-admission rate.

Conclusions

The incidence of vault hematoma above 5ml was 34%. The presence of a vault hematoma did not cause higher pain-score or re-admission, but a higher use of analgesics.

This result will help the clinicians to evaluate patients with vault hematoma found after hysterectomy.

ES28-0187 - P*008
Selected E-Poster

Patient factors impacting indocyanine green sentinel lymph node mapping in endometrial cancer patients in Western Australia

Lachlan Baxter¹, King Man Wan², Chloe Ayres², Ganendraraj Raj Kader Al², Paul Cohen², Yee Leung²

¹King Edward Memorial Hospital, O&G, Perth, Australia

²King Edward Memorial Hospital, Gynaecological Oncology, Perth, Australia

Background

Sentinel lymph node evaluation in endometrial cancer offers the possibility of avoiding the surgical and post-operative complications associated with full pelvic lymphadenectomy in early stages of disease, however this relies upon successful lymph node mapping. Multiple factors have been described as influencing the success of sentinel lymph node mapping using indocyanine green (ICG). This study sought to determine the impact previous abdomino-pelvic surgery and body mass index had upon sentinel lymph node mapping in endometrial cancer patients undergoing intra cervical injection for endometrial cancer in Perth Western Australia.

Methods

A retrospective analysis of 43 patients having undergone laparoscopic sentinel lymph node mapping for endometrial cancer in Perth, Western using patient's medical records. Data was analysed using SPSS (TM IBM). Univariate analyses were performed including an independent student t-test and chi-square test. A stepwise logistic regression was used to evaluate possible predictors of possible SLN detection. The level of significance for all analyses was two tailed $p < 0.05$.

Results

Of the 43 cases analysed 34 (74%) had documented previous abdominopelvic surgery, most commonly caesarean sections. Average BMI was 30.2kg/m², with 28 cases showing a BMI >35kg/m² and 8 cases showing a BMI >40kg/m². There was no demonstrated impact of previous abdominopelvic surgery ($P = 0.7$) nor BMI ($P=0.08$) on unsuccessful sentinel lymph node mapping using ICG (which failed to map bilaterally in 2 (4.6%) of cases and mapped unilaterally in 7 cases (16%)).

Conclusions

Whilst sentinel lymph node mapping offers great promise in minimising extensive pelvic lymphadenectomy in early stage endometrial cancers more research is required to determine the cause of unsuccessful or unilateral lymph node mapping.

<https://esge.covr.be/cmdocumentmanagement/conferencemanager/documents/api/getdocument/5120/cmabstsms/00158810/5dc6ce6621a4535d1156e27de59b479071ae2d83c10c306a226b624ab6a858ca>

ES28-0189 - P*009
Selected E-Poster

Observation of the histological anatomy around the cervix for nerve-sparing radical hysterectomy

Haili Li¹, Mei L², Ping Yan²

¹Shenzhen People's Hospital, Gynecology, Shenzhen, China

²Hebei General Hospital, Gynecology, Shijiazhuang, China

Background

This study, aiming at providing further histological evidence for nerve-sparing radical hysterectomy(NSRH), is designed to describe the structures around the cervix and to examine which type of relevant nerves are.

Methods

Hematoxylin and eosin (HE) staining and immunohistochemical staining were used to make serial paraffin sections, which were then photographed by Olympus imaging at different cross-sectional levels to enable morphological observations.

Results

1 The superficial layer of the cardinal ligament (CL) contained a large number of blood vessels. The nerve part located at the deep layer of the CL and the dorsal side of the deep uterine vein(DUV) was the inferior hypogastric plexus (IHP).

2 Hypogastric nerves (HN) went through the dorsolateral side of the uterosacral ligament (UL) .The UL continued as the Denonvilliers fascia.

3 The deep layer of the vesicocervical ligament (VCL) had a large number of vesical vessels and nerves. The sections of the vesical nerves were mainly located at the dorsomedial side of the vesical vessels and at the ventrolateral side of the vagina.

4 HN, mainly located at the dorsolateral side of the UL, were sympathetic nerves.

5 The IHP contained both sympathetic and parasympathetic nerves. At the level of the cervical isthmus, the parasympathetic nerves were mainly located at the superficial dorsal DUV. Both the dorsolateral side of cervix and the deep dorsal DUV contained sympathetic nerves. At the level of the posterior vaginal fornix section, the parasympathetic nerves were mainly located at the dorsal side of inferior rectal artery and the sympathetic nerves were mainly located at the lateral side of cervix and the UL. At the level of ureterovesical orifice section, the parasympathetic nerves were mainly distributed in the dorsolateral side of the Denonvilliers fascia.

6 The vesical nerves also contained both sympathetic nerves and parasympathetic nerves. At the level of ureterovesical orifice section, the vesical nerves distributed along the dorsolateral side of ureterovesical orifice and the dorsomedial side of the vesical veins were mainly sympathetic nerves and those along the vaginal wall were mainly parasympathetic nerves.

Conclusions

1 The DUV is a viable anatomical landmark to preserve the nerves of the CL.

2 When cutting off the deep layer of the VCL, the vesical veins can serve as landmarks to reduce the chance of injury of that vesical nerves that are located at the dorsomedial side of the veins.

3 Denonvilliers fascia can serve as a landmark to retain the IHP, which is distributed along the ventrolateral side of the Denonvilliers fascia.

4 The IHP and its bladder nerves contain both sympathetic nerves and parasympathetic nerves and the sympathetic nerves are located at the ventral side of the parasympathetic nerves.

5 NSRH retains most of the parasympathetic nerves and some sympathetic nerves.

<https://esge.covr.be/cmdocumentmanagement/conferencemanager/documents/api/getdocument/5046/cmabstsms/000168780/463af9749e044ab096c3a851933b715c2fbe835dfd6e564fed28e5f1990d80f8>

Prognostic factors and impact of the minimally invasive surgery in early stage neuroendocrine carcinoma of cervix

Ju-Hyun Kim¹, Jeong-Yeol Park¹, Kim Dae-Yeon¹, Jong-Hyeok Kim¹, Yong-Man Kim¹, Young-Tak Kim¹

¹Asan Medical Center, Obstetrics and Gynecology, Seoul, Korea- Republic Of

Background

We investigate prognostic factors and impact of the minimally invasive surgery (MIS) in surgically treated early-stage high-grade (HG) neuroendocrine cervical carcinoma (NECC).

Methods

Between 1993 and 2017, 47 patients with FIGO (2009) stage IA-IIA HG NECC were initially treated with radical hysterectomy. Clinicopathological variables of the patients were retrospectively reviewed from electronic medical records. Cox proportional hazards regression was used to identify potential prognostic factors. According to surgical approach, survival curves were compared using the Kaplan–Meier method with log rank test.

Results

The median follow-up period was 28.2 months (range, 3.83–202.5). Stage IB1 disease was the most common (70.2%). Twenty-nine patients (61.7%) underwent RH *via* MIS. The overall survival (OS) rate was 63.8.0% and the disease-free survival (DFS) rate was 38.3%. Lymph-node (LN) metastasis was an independent significant risk factor for OS (HR, 2.594; 95% CI, 1.152-5.842; P=0.021) and DFS (HR, 3.236; 95% CI, 1.188-8.815; P=0.022). The Kaplan–Meier survival curves revealed that there was no significant difference in OS and DFS between the laparotomy group and MIS group (50% vs. 72.4% log-rank p value=0.196, 38.9% vs. 37.9% p= 0.975). Moreover, the type of surgical approach was not a risk factor for OS (HR, 0.467; 95% CI, 0.714-1.257; P=0.132) and DFS (HR, 1.048; 95% CI, 0.494-2.224; P=0.093).

Conclusions

LN metastasis was a poor prognostic factor of survival outcomes in initially surgically treated early-stage HG NECC. There was no difference in survival between the MIS and laparotomy approached.

<https://esge.covr.be/cmdocumentmanagement/conferencemanager/documents/api/getdocument/5121/cmabstsms/000092340/1afeec661be88b617470ad36266618194d115f262631380ec285fce4eaa00a43>

Conclusions about the use of a uterine manipulator in robot-assisted surgery for endometrial cancer

Hiroe Ito¹, Yasufumi Ooishi², Keiichi Isaka²

¹Tokyo Medical University, Obstetrics and Gynecology, Tokyo, Japan

²Hitachi General Hospital, Obstetrics and Gynecology, Tokyo, Japan

Background

To investigate the effects of uterine manipulator use in robot-assisted surgery for endometrial cancer on postoperative recurrence and survival rates.

Methods

Among 152 cases diagnosed with FIGO advanced stage I endometrial cancer at Tokyo Medical University Hospital from April 2009 to December 2014, robot-assisted surgery was performed in 86 cases (robot group) and open surgery (laparotomy group) in 66 patients and the operation time, bleeding volume, hospitalization period, perioperative complications, open transition, recurrence rate, survival rate were compared and analysed. In all cases of robotic surgery, uterine manipulators were used.

Informed consent was obtained from all patients

Results

There was no significant difference between the two groups in regards to patient background. The robot group showed a significant prolongation (261 vs 205 minutes) in operation time, but significant reduction in blood loss (33 vs 515 ml) and significant shortening of hospitalisation period (5.5 vs 20.0 days). In addition, the robot group had significantly fewer complications (7.0 vs 20.9 %) than the open group and there were no open surgery cases. There was no significant difference between the two groups in terms of progression-free survival and overall survival.

Conclusions

Uterine manipulator use during robotic surgery in early stage endometrial cancer does not seem to affect recurrence or survival.

<https://esge.covr.be/cmdocumentmanagement/conferencemanager/documents/api/getdocument/5084/cmabstsms/0000165050/ce44f1e2f2bb1311d5226ef17c027d4433bfe9da35a7e9866de729efbf32a46c>

ES28-0224 - P*012 Selected E-Poster

Novel laparoscopic cornual resection of interstitial pregnancy using the Endo GIA™ Universal Stapler (Medtronic): a series of 10 cases

Christina Neophytou¹, Wasim Lodhi¹, Lester De Silva¹, Cheong Wai Yoong¹

¹North Middlesex University Hospital, Obstetrics & Gynaecology, London, United Kingdom

Background

The mortality rate of interstitial pregnancy is up to 5 times greater than other types of ectopic gestation due to potential torrential haemorrhage. Minimal access surgical techniques comprise cornual resection and cornuostomy, and usually require laparoscopic suturing skills. We describe a novel laparoscopic approach using an automatic stapling device with reloadable cartridges to resect the cornu: this enables surgeons less familiar with intracorporeal suturing to avoid a laparotomy when managing interstitial pregnancy.

Methods

We performed a prospective observational study over seven years on patients diagnosed with interstitial pregnancy and managed surgically with laparoscopic cornual resection using the Endo GIA™ Universal Stapler (Medtronic). Outcome measures include serum hβCG levels at the time of presentation, successful laparoscopic completion of the procedure, estimated blood loss, intra-and post-operative complications and length of admission.

Results

Ten women underwent laparoscopic cornual resections using the Endo GIA™ Universal Stapler (Medtronic). The median age was 31 years (range: 20-44) and the median gestation at surgery was 8 weeks (range: 5-12). All were live interstitial gestations and five out of ten were ruptured at the time of operation. Four of the ten cases had evidence of significant haemoperitoneum at time of laparoscopy. The median blood loss was 400 mls (range 50-3500) and 5 patients had blood loss of more than 500 mls. The median serum hβCG level was 6429 iu/l (range: 1800-58690) and the median size of the ectopic was 4 centimetres (range 2-6). All cases were successfully completed and there were no intra- or post-operative complications. Median length of admission was 40 hours (range: 30-66). Long term follow up data was difficult to obtain due to the transient itinerant nature of London's population.

Conclusions

The Endo GIA™ Universal Stapler may provide on a novel laparoscopic approach for the management of interstitial pregnancy. This method offers the benefit of minimising the need for laparoscopic intra-corporeal suturing, as it simultaneously staples and transects the tissues.

<https://esge.covr.be/cmdocumentmanagement/conferencemanager/documents/api/getdocument/4998/cmabstsms/0000165390/61b8977edbb1dc3e25dec93a445ef03b27026641828fe8b2ff797187c7de827f>

ES28-0225 - P*013

Selected E-Poster

Laparoscopic pectopexy and laparoscopic native tissue repair: experience of first operations in a single centre, perioperative complications and short-term follow-up outcome

Anneli Linnamägi¹, Tiina Petäjä¹

¹The Hospital District of South Ostrobothnia, Gynecological, Seinäjoki, Finland

Background

Laparoscopic pectopexy and laparoscopic native tissue repair are fairly new surgical techniques developed for vaginal apical, anterior and posterior wall prolapse repair. The aim of this study was to show the results and perioperative complications of first 15 operations in a single centre.

Methods

During the period 8/2017-12/2018 fifteen laparoscopic pectopexy surgeries were performed by one surgeon. Prolapse was assessed by POP-Q classification and subjective symptoms were noted before and after surgery. Surgery was done to patients who had stage ≥ 2 POP-Q vaginal or uterine prolapse. Apical prolapse was treated with 3*15 cm Polyvinylidene Fluoride Mesh (PVDF, DynaMesh®-PRP soft or DynaMesh®-PRP visible). Laparoscopic anterior and posterior colporrhaphy was performed by exposing the anterior or posterior pelvic fascia of vagina similarly to the preparation of an extended sacral colpopexy. Then the fascia was plicated from side to side by Vicryl 1 single sutures. Mean follow-up period was 4,7 months (2,6 - 14,7).

Results

The age range of the patients was 43-79 years. Mean BMI 24,3 (21,05-34,63). Apical prolapse suspension was performed to 14 vaginal and 1 uterine prolapse patients. Posterior colporrhaphy was made laparoscopically to 6 patients and vaginally to 1 patient. Laparoscopic anterior colporrhaphy was made to 5 patients. Apical prolapse recurrence developed to one patient (6,7%), who suffered intense cough during post-op period. Rectocele recurrence developed 4/6 patients (67%) in the laparoscopy group and 0/1 (0%) in vaginal group. The recurrent rectocele is treated by vaginal posterior colporrhaphy. No recurrence appeared in laparoscopic anterior colporrhaphy group. There were no major or minor intraoperative complications. The mean blood loss was 88 ml (20-200 ml). The mean operation time 211 min (172-280 min). Postoperative complications: one haematoma (6,7%) that resolved spontaneously; one urosepsis (6,7%) caused by underlying urological condition. There was improvement in several symptoms: sense of bulge improved in 10/15 (66,7%), stress urinary incontinence (SUI) in 1/3 (33%) patient and urinary retention in 7/7 (100%) patients . There was little improvement in urge urinary incontinence (UUI) - in 1/5 (20%) and difficult defecation in 1/6 (16,7%) patient. None of the patients developed *de novo* UUI or difficult defecation symptoms. *De novo* SUI developed to one patient, SUI resolved after pelvic floor physiotherapy.

Conclusions

Laparoscopic pectopexy is a treatment option for vaginal apical prolapse patients. Laparoscopic native tissue repair is more challenging and more research is needed to prove its efficacy.

<https://esge.covr.be/cmdocumentmanagement/conferencemanager/documents/api/getdocument/4937/cmabstms/0000075280/7a357a6713941139c1469c89209015841d4e3efff39b4f6d51fd499d108244eb>

ES28-0234 - P*014

Selected E-Poster

Clinical significance of IL-6 level in plasma and peritoneal fluid in patients with ovarian cancer

Monika Bilska¹, Iwona Wertel¹, Mateusz Bilski², Anna Pawłowska¹, Dorota Suszczyk¹, Kotarski Jan¹

¹Medical University of Lublin, 1st Chair and Department of Oncological Gynecology and Gynecology, Lublin, Poland

²Nu-Med- Center of Oncology Diagnostics and Therapy, Radiation Therapy Department, Zamość, Poland

Background

Ovarian cancer (OC) is diagnosed in most of cases in advanced stages. The prognosis of OC is still poor. Growth of OC is angiogenesis-dependent. Angiogenesis plays crucial role in the spreading of cancer. This process depends on

a large variety of immune factors, like interleukin 6 (IL-6). The aim of study was analysis evaluation of IL-6 concentration in plasma and peritoneal fluid (PF) in patients with OC.

Methods

The clinical material was plasma and PF from 71 OC patients. The patients were operated in 1st Chair and department of oncological gynecology and gynecology of Medical University of Lublin. The studies were also conducted in benign ovarian tumours (n=35). The concentration of IL-6 in plasma and PF were determined by ELISA (enzyme linked immunosorbent assay).

Results

The peritoneal fluid IL-6 level in OC patients was higher than in plasma ($p < 0,0001$). In patients with OC the level of IL-6 in PF was significantly higher than in patients with benign ovarian tumour ($p < 0,0001$). The level of peritoneal fluid IL-6 was higher in patients with high grade (G3) than in patients with G2 ovarian cancer ($p = 0,002$). The survival of OC patients with higher level of IL-6 in the PF was shorter (median: 17 vs 56 months) than patients with lower IL-6 concentration.

Conclusions

There are differences in the concentration of IL-6 in OC patients depending on microenvironment. IL-6 level of OC patients was higher in the PF than in plasma. There are significant differences in the IL-6 level in relation to OC grade. This result may be crucial for stimulation of angiogenesis in ovarian tumour. Higher IL-6 level in the PF correlates with shorter survival of OC patients.

<https://esge.covr.be/cmdocumentmanagement/conferencemanager/documents/api/getdocument/5155/cmabstms/000165900/5b5dc67b138cd383e61697a5d33f72d3759c5390733c4685da97883b70b41b43>

ES28-0244 - P*015

Selected E-Poster

Are patients keen to prehabilitate? Report of a pre-trial to evaluate the recruitment ratio

Volz Sophia¹, de Gregorio Nikolaus¹, de Gregorio Amelie¹, Otto Stephanie², Steinacker Jürgen², Florian Ebner³

¹*Universität Ulm, Department of Obstetrics and Gynecology, Ulm, Germany*

²*Universität Ulm, Division of Sports and Rehabilitation Medicine, Ulm, Germany*

³*Helios Amper Klinikum, O&G, Dachau, Germany*

Background

The most common elective gynaecological surgery is the hysterectomy. No randomised prehabilitation study of elective hysterectomy is available to date [1]. The benefits of prehabilitation could be well established in this physical fit age group (45-55y). A targeted training program can be easily implemented to cover a possible time delay to the surgical appointment. In regards to the impairment that a hysterectomy imposes on the individual a 6-week training programme has been put together for prehabilitation [2]. According to our hypothesis, physical training may positively influence the recovery time in terms of pain reduction, time back to work and patient satisfaction. In order to evaluate these effects a pre trial evaluating the possible recruitment rate was conducted since 1. January 2019.

Methods

For this single centre, longitudinal prospective study 60 patients will be asked to participate in the training programme. The primary objective was to evaluate the recruitment rate of patients meeting the inclusion criteria (surgical treatment of uterine fibroids, aged 40 to 60y). The patients were asked whether they would be interested in prehabilitation and offered a free 6 week physical intervention in the in-hospital rehab studio. If they declined the reasons were noted on a questionnaire. This questionnaire was part of an information leaflet about the benefits of prehabilitation/ERAS concept. Ethics was granted by the local ethics committee and a support grand from the 'Helios Forschungsförderung' to cover the insurance cost was granted.

Results

In the first 4 months two patients participated, one completing the course and surgery, the second one caught a mild infection and stopped training for 4 weeks before continuing and completing the course. 13 patients answered the questionnaire declining the free of charge prehabilitation course. The most common reasons (multiple answers

possible) were too time consuming (n=8), did not want surgery to be postponed for 6 weeks (n=7). Along with 'just myomectomy' (n=2) and need for combined descensus and hysterectomy (n=2).

Conclusions

Our current recruitment rate of 2/15 with the reasons given show the need for more patient education. Elective surgery should be seen more like a sports event (like a marathon) which participants train months beforehand. Currently patients have an expectation for immediate treatment in elective surgery in Germany.

<https://esge.covr.be/cmdocumentmanagement/conferencemanager/documents/api/getdocument/4916/cmabstms/0000101170/8a67b21c87e8d3fd411d11dfd499f813ab943217552c75117e3a5756b93f96d3>

ES28-0248 - P*016

Selected E-Poster

Immunohistochemical assessment of lymphangiogenesis marker in patients with endometriosis

Malgorzata Sobstyl¹, Marcin Bobiński Stanisław², Wiesława Bednarek², Bartłomiej Barczyński², Lechosław Putowski¹, Jan Kotarski²

¹Chair and Department of Gynaecology and Gynaecological Endocrinology- Medical University, Department of Gynaecology and Gynaecological Endocrinology- Medical University, Lublin, Poland

²1st Chair and Department of Gynaecological Oncology and Gynaecology- Medical University, Department of Gynaecological Oncology and Gynaecology- Medical University, Lublin, Poland

Background

The pathogenesis of lymphangiogenesis in the endometriosis is still unknown. However, lymphatic system appears to play a major role in the progression of the disease. The density of the lymphatic vessels might also be a predictor for the risk of malignant transformation. Prox-1 (prospero homeobox protein 1) is considered to be one of the markers of lymphatic endothelial cells. Protein occurs in the early stages of lymphatic vessels development before such markers as LYVE-1, podoplanin, VEGFR-3. The aim of the study was to assess the expression of Prox -1 in endometriotic lesion among the patients with various stage of endometriosis.

Methods

Tissue samples were collected from of 95 patients with endometriosis and paraffin specimens were prepared and stained with Prox-1 antibody. The patients with endometriosis were divided into two groups: I, II stages of endometriosis and III, IV stages of endometriosis. The lymphatic vessels density (LVD) was assessed for each sample and calculated as the number of LV/mm². Concentration of 125 ca and HE4 was determined in the blood serum.

Results

The presence of lymphatic vessels was confirmed, understood as the occurrence of Prox1 vessels+ in all examined samples. No significant differences between the groups were detected. In patients with low endometriosis, a statistically significant correlation was found between serum concentration of CA-125 marker and lymphatic vessels density (LVD) Prox1 +.

Conclusions

The presence of lymphatic vessels in all endometriotic tissues may suggest that lymphangiogenesis plays an important role in etiopatogenesis of this disease. Demonstrated correlation between prox-1 and CA-125 suggests the involvement of lymphangiogenesis in the early stages of endometriosis. Moreover, lack of correlation in III and IV stage proves that there are differences in metabolism relied to classifying the extent of spread.

<https://esge.covr.be/cmdocumentmanagement/conferencemanager/documents/api/getdocument/5086/cmabstms/0000163400/06cf0c3f9f4da55700cd14b5ce705b815045e4d6bcb10a06fcbab98764c83822>

ES28-0306 - P*017
Selected E-Poster

The association of endometriosis with obstetric complications

Shiori Takeuchi¹, Mari Kitade¹, Kesuke Murakami¹, Yu Kawasaki¹, Jun Kumakiri²

¹*Juntendo University School of Medicine, Obstetrics and Gynecology, Tokyo, Japan*

²*Tokyo Women's Medical University, Obstetrics and Gynecology, Tokyo, Japan*

Background

Endometriosis induces various of pain and infertility. It has also been reported its relation to chronic disease or perinatal complication in recent years. I will demonstrate the analysis of perinatal complications associated with endometriosis.

Methods

We evaluated the effect of endometriosis on perinatal complications in a cohort of 7,623 patients who delivered at our hospital between 2011 and 2017. We divided them into 2 groups (endometriosis group : 161 women, control groups : 7,462) women and investigated the correlation of endometriosis and gestational age by multivariate regression analysis (Investigation 1). And the association between endometriosis and perinatal complications was also evaluated by logistic regression analysis (Investigation 2).

Results

Investigation 1) Multivariate regression analysis showed a negative correlation between presence of endometriosis and gestational age at delivery. Investigation 2) As the events associated of endometrioma directly, there were 1 case of rupture, 1 case of torsion and 1 case of infection out of them. And women with endometriosis had a higher risk of hypertensive disorder (OR : 2.108, 95 % CI : 1.126-3.947), placenta previae (OR : 2.743, 95 % CI : 1.021-7.639), chorioamnionitis (OR : 3.544, 95 % CI : 1.762-7.128) and emergency caesarean delivery (OR : 1.697, 95 % CI : 1.158-2.486) by logistic regression analysis. Patients with previous surgery for endometrioma had a significantly lower risk of premature rupture of the membrane than patients who had not done.

Conclusions

It was suggested that pregnant women with endometriosis tended to deliver earlier and had high risk of some perinatal complications than women without endometriosis.

<https://esge.covr.be/cmdocumentmanagement/conferencemanager/documents/api/getdocument/5219/cmabstsms/0000166050/05bbaf3be040853c04d17fea989010ab212c3d5fc4fd92f7a5da8c0654a17fbf>

ES28-0328 - P*018
Selected E-Poster

Extrinsic ureteral endometriosis and its transition into intrinsic and intraluminal growth pattern - a case report

Elisabeth Janschek¹, Julia Steiner Christina², Ulrike Hager¹, Julia Pfeifer³, Rüdiger Hochstätter⁴, Günter Janetschek⁵

¹*Hospital of Villach, Gynecology and Obstetrics, Villach, Austria*

²*Medical University Graz, Gynecology and Obstetrics, Graz, Austria*

³*Hospital of Villach, Department of Pathology, Villach, Austria*

⁴*Medical University of Graz, Gynecology and Obstetrics, Graz, Austria*

⁵*Wehrle-Diakonissen Hospital, Department of Urology, Salzburg, Austria*

Background

Deeply infiltrating endometriosis (DIE) mostly affects the connective tissue of the pelvis but is also capable of invading adjacent organs and structures leading to a variety of symptoms and even impairing organ function. Among patients with DIE 0,3 to 12% have a urinary tract involvement, affecting the bladder (80%), the ureter (14%) or the kidney (4%) respectively.

Methods

Case report

Results

A 37-year-old patient first presented to the gynaecological department with mild dysmenorrhoea (NAS 3) and deep dyspareunia (NAS 4), dyschesia and katamenial mucous and blood discharges on stool. On pelvic examination, the uterus was in fixed retroflexion. In the posterior fornix, a painful induration of 2cm involving both uteroacral ligaments (USL) could be palpated. The transvaginal sonography (TVS) demonstrated an adenomyotic uterus, a thickening of the muscularis of 3,2cm at the rectosigmoid junction the left USL. The right kidney was transformed into a hydronephrotic sac, the ureter 3cm distended. Loss of function was confirmed by radio-isotope renogram. Since the patient denied surgery she received a combined oral contraceptive in continuous mode which completely relieved symptoms. However, hypertension was diagnosed and did not improve on gestagen only regimen, so that the patient was put on antihypertensive drugs. She remained stable from her endometriosis until she quit her hormonal therapy for loss of libido. She came back to the department two years later for ascending right flank pain and cystitis. The sonography showed an increased distension of the affected ureter and kidney sac. The distal portion of the right ureter revealed a vascularised solid tumour arising from the stenosis and expanding into the bladder. TVS revealed a widening of the stenosis allowing some urine flow into the sacculated kidney. Cystoscopy confirmed the presence of a polypoid tumour extruding out of the right ostium so that a nephrectomy along with a total ureterectomy were performed. Endometriotic tissue of the right parametrium had to be removed including the affected right fallopian tube. Since the patient denied any further removal of endometriosis, a thorough intraoperative exploration of the pelvis finished the surgery. The postoperative course was uneventful; the patient is now symptom free on gestagens.

Conclusions

Ureteric endometriosis is a rare form of DIE that can lead to silent renal failure. To our knowledge this is the first documented case of an extrinsic endometriosis progressing into an intrinsic form with final intraluminal growth. We also want to emphasize the importance of treating patients with UTE in an interdisciplinary approach by a team of professionals committed to a rigorous preoperative planning and an individualised surgical strategy. Careful preoperative assessment of the ureter including the distal part per TVS is mandatory for proper planning of surgery, counselling and follow up of the patient.

<https://esge.covr.be/cmdocumentmanagement/conferencemanager/documents/api/getdocument/5023/cmabstsms/0000169000/822afce34ea7b168add0ef0baa02c91c5af860c9cf7fcc4762415a18d63841cf>

ES28-0337 - P*019

Selected E-Poster

A prospective audit of the outpatient hysteroscopy service at Queen Alexandra Hospital, Portsmouth, UK

Isabel McLuskie¹, Elizabeth Goodier¹, Janet Berry¹, Florence Saddler¹, Denis Tsepov¹

¹Queen Alexandra Hospital, Gynaecology, Portsmouth, United Kingdom

Background

We set out to audit our outpatient hysteroscopy service against the joint British Society for Gynaecological Endoscopy (BSGE)/Royal College of Obstetricians and Gynaecologists (RCOG) guideline 'best practice in out-patient hysteroscopy' and identify any areas for improvement, with the aim of reducing the number of women undergoing unnecessary general anaesthetic, and increasing capacity in theatres and outpatient hysteroscopy by reducing theatre time used for hysteroscopies.

Methods

This prospective data collection covered 1/4/19 to 30/4/19, and included all outpatient hysteroscopy appointments in this district general hospital within the National Health Service (NHS). Data was collected using an audit proforma completed contemporaneously by the clinician in clinic, or by the audit team after clinic using notes and clinic letters. Data was analysed using Excel.

Results

There were 220 appointments, of which 21/220 (9.5%) were not attended. Of the remaining 199 appointments, 140/220 (63.6%) were for post menopausal bleeding (PMB) and 59/220 (26.8%) were benign ambulatory hysteroscopy appointments (AMB). The indications for referral included intermenstrual bleeding (IMB) 14/199 (7.4%),

menorrhagia 20/199 (10.1%), IMB/menorrhagia 7/199 (3.5%), PMB 108/199 (54.3%), incidental thickening of endometrium on ultrasound 8/199 (4%) and Mirena related issues 3/199 (1.5%). 124/199 (62.3%) appointments had an attempted hysteroscopy and 118/124 (95%) of these were successful. 5/199 (6.5%) had a failed hysteroscopy due to the patient not tolerating the examination. 1/199 (0.5%) failed because the cavity wasn't seen. Hysteroscopy was not attempted at 75/199 (37.7%) of appointments. 57/199 (28.6%) because they were not required, 4/199 (2%) declined, and 7/199 (3.5%) due to staffing. Of the operative procedures the failure rate was 0%, in the diagnostic group failure rate was 12/90 (13%). Both diagnostic (90/124, 72.6%) and operative (27/124, 21.8%) hysteroscopies were performed in outpatient setting including 25 Myosure resections and 2 Novasure ablations. Other procedures included Mirena IUS insertion and biopsies. There were no complications recorded for any of the procedures. 56/90 (62%) diagnostic hysteroscopies were documented as using a vaginoscopic approach. Cervical dilation was documented in 18/90 (20%) of the diagnostic hysteroscopies and 26/27 (96.2%) of the operative procedures. 112/199 (56.3%) of patients were discharged from clinic, however 50/199 (25.2%) required a further hysteroscopy appointment with 26/199 (13.1%) returning to ambulatory clinic and 24/199 (12.1%) booked in theatre. 28/199 (14.1%) required gynaecology out-patient follow up and/or imaging.

Conclusions

Our outpatient hysteroscopy success rates of 95% are comparable with published data and provide further evidence that this is safe and well tolerated. To adhere more closely to the guidelines we could increase our number of vaginoscopic diagnostic hysteroscopies. The need for 13.1% patients to return for a second outpatient hysteroscopy appointment supports our business case for a fully 'one-stop' clinic to accommodate the increase in hysteroscopies and reduce the pressure on operating theatres.

<https://esge.covr.be/cmdocumentmanagement/conferencemanager/documents/api/getdocument/5270/cmabstsms/000165130/5cf8a85dd9f5f5fda7a00a68b40bf627a83c6bb4c88e8b633983d29f0447e5bd>

ES28-0383 - P*020 Selected E-Poster

Laparoscopic appendicectomy in the third trimester of pregnancy. Is it feasible and safe?

Manolis Nikolopoulos¹, Kostis Nikolopoulos¹, Dorothea Saragli¹, Chorouk Kohler-Boureq¹, Pandelis Athanasias¹

¹St Helier Hospital, Obstetrics and Gynaecology, London, United Kingdom

Background

The reported incidence of acute appendicitis during pregnancy ranges between 1:800 to 1:1500 pregnancies. 15-50% of cases occur during the third trimester.

Methods

We present two cases in the 3rd trimester who were treated laparoscopically, discussing precautions, technique, tips and outcomes.

Results

Case 1

A 39 year old 34 weeks pregnant woman presented with right sided abdominal pain. She was afebrile with heart rate 105bpm. Her blood results were WBC 16.1, CRP 116 and the CT scan revealed subtle inflammatory fat stranding and fluid in the right iliac fossa the cause of which was not clearly delineated.

This woman had a laparoscopic appendicectomy, recovered well and was discharged home on day 2 post-operatively, however she presented at 35/40 with rupture of membranes and had a vaginal delivery.

Case 2

A 29 year old 32+1/40 weeks pregnant woman presented with right lower abdominal pain and fever. Her blood results were WBC 21.8, CRP 104.

This woman has not had imaging and underwent a diagnostic laparoscopy. Ruptured appendix was identified and a successful appendicectomy was performed. She recovered well and was discharged home on day 3 post-operatively. She had a term vaginal delivery.

A senior laparoscopic general surgeon performed both operations. Hasson technique was used for entry. Three ports were used, one umbilical 10mm and two at the right upper quadrant 5mm each. CO2 insufflation of 10-15 mmHg was maintained throughout the procedure. Both patients were on a left tilt during the procedure and the obstetric and neonatal teams were stand by in case of an obstetric emergency necessitating urgent intervention.

Conclusions

Risks related to operations in pregnancy include, preterm labour, fetal loss and thromboembolic events. Specifically, laparoscopy has been associated with injury to the uterus during entry and fetal acidosis due to conversion of carbon dioxide to carbonic acid which could lead to fetal demise even if maternal CO2 levels are maintained within normal range. However, most reports in the literature state that the above complications of a laparoscopic operation are rare and definitely not more common than complications related to laparotomy.

The Society of American Gastrointestinal and Endoscopic Surgeons recommend that laparoscopy can be performed at any gestation. Left tilt can decrease the compression on the vena cava and improve cardiac return. The open Hassan technique is recommended for entry. Also, intraoperative abdominal pressure should be maintained less than 15mmHg while in Trendelenberg position, in order to ensure adequate venous return and uteroplacental sufficiency.

There is no indication for prophylactic tocolysis. Laparoscopic appendectomy in pregnancy seems to be a relatively safe choice, however the experience of the surgeon should always be considered in such procedures and modified operative techniques should be taken into consideration. Future studies need to evaluate the superiority of the laparoscopic approach.

<https://esge.covr.be/cmdocumentmanagement/conferencemanager/documents/api/getdocument/5250/cmabstsms/000166130/37d5a7d85536e1f00915fb4db8f5dff446f6d4acf51a57194c37a12ecaf80292>

ES28-0424 - P*021

Selected E-Poster

Laparoscopic surgical management of caesarean scar defect (niche) with hysteroscopic assistance

Ana Ranc¹, Branka Verdnik Golob¹

¹Slovenian, Department of Gynecology and Obstetrics- General Hospital Slovenj Gradec-, Slovenj Gradec, Slovenia

Background

The incidence of caesarean section (CS) is increasing worldwide. In Slovenia the rate is about 20%. The caesarean scar defect or isthmocele or 'niche' is an important feature, that is associated with future complications, such as abnormal uterine bleeding, dysmenorrhea and subfertility. The prevalence of isthmocele at the site of caesarean delivery is estimated from 24% and 70%.

Surgical procedure should be considered in symptomatic women that are willing to preserve their fertility; hysteroscopic resection in isthmocele with residual myometrium(RM) ≥ 3 mm and laparoscopic resection in women with large isthmocele with RM ≤ 3 mm.

The aim of the current presentation is to share our good experience of laparoscopic management of large isthmocele with hysteroscopic assistance in 33 years old patient with 4 year lasting symptoms after second CS: intermenstrual spotting, dysmenorrhea, dyspareunia, chronic pelvic pain, vaginal discharge. Large isthmocele was identified with transvaginal ultrasonography in sagittal and transversal plane with measures 13x16 x 32 mm and residual myometrim (RM) less than 1 mm. Hysteroscopy was performed to exclude other reasons for irregular bleeding. Oral contraceptive drugs were not successful in treatment of symptoms.

Methods

Surgical management was started after filling the bladder with blue dye solution with hysteroscopy for the evaluation and exact location of the isthmocele. Laparoscopy was followed placing umbilical and suprapubic trocar and two side ports in the lower abdomen. Lumination by the hysteroscopic light allowed recognition of the thinnest point of the isthmocele and helped to prevent the bladder injury during adhesiolysis. Dissection of dense fibrotic adhesions attached between bladder and the top of the 3 cm wide isthmocele was made by Thunderbeat device (Olympus). The isthmocele was then opened and completely excised using a cold scissor.

The well vascularised myometrium was sutured in two layers with three separate resorbable sutures (0 Novosyn) in each layer. The peritonum was closed using running suture (third layer). Intrauterine hysteroscope was used to preserve the continuity of the cervical canal with the uterine cavity and as manipulator. At the end of surgery hysteroscopy was performed to visualize the repair of the cervical canal.

Results

At the end of surgery normal patency of cervix and complete correction of isthmocele was seen.

The patient was discharged from the hospital after 2 days. We did not register any perioperative or early postoperative complications.

One month after the operation the patient was free of previous symptoms.

Conclusions

Laparoscopical surgical management of isthmocele is a good method in treatment of large, symptomatic isthmoceles non responding to conservative treatment. Hysteroscopy is an excellent support method in almost all steps of laparoscopic surgery of isthmocele. For performing hysteroscopy at the same time as laparoscopy complete endoscopic system for both should be available. Experienced gynaecologist as the second assistant is needed.

<https://esge.covr.be/cmdocumentmanagement/conferencemanager/documents/api/getdocument/5245/cmabstsms/000166240/d02bd15f06222cf44ea91132ccb08b977c5d843fe0fac7cb5ef59eb62a4f4072>

ES28-0545 - P*023

Selected E-Poster

Fertility preservation strategies for endometriosis: how to choose

Gloria Calagna¹, Luigi Della Corte², Luigi Giampaolino², Marianna Maranto³, Mariachiara De Angelis², Antonino Perino³

¹University of Palermo, Department of Obstetrics and Gynecology- "Villa Sofia Cervello" Hospital, Partinico, Italy

²School of Medicine- University of Naples Federico II,

Departments of Public Health and Neuroscience and Reproductive and Odontostomatological Sciences, Naples, Italy

³University of Palermo, Department of Obstetrics and Gynecology- "Villa Sofia Cervello" Hospital, Palermo, Italy

Background

Endometriosis is often associated with a compromised ovarian reserve, caused by several mechanisms involved in the progressive follicular depletion. The aim of this review is to summarise the current evidences on the fertility preservation techniques for patients with severe endometriosis, focusing on advantages and disadvantages.

Methods

All original papers, published until March 2019, reporting specific experiences data on fertility preservation (FP) strategies applied to endometriosis patients, were considered for the analysis. All reports related to experimental studies conducted on in vitro or animal models were excluded from the analysis. Available strategies include well-established techniques such as oocytes cryopreservation (OOC), embryos freezing and ovarian tissue cryopreservation (OTC), although the latter is still considered experimental.

Results

Four papers were included in the review: 2 case reports, 1 case series (2 cases), 1 prospective longitudinal analysis (only one case with criteria for inclusion in the review). Only 1 article described OOC approach and 3 articles described the OTC strategy. Four patients had a surgical history: 3 cases for endometriosis and 1 case for struma ovarii associated with endometrioma. In one case, OOC was performed though 3 cycles of ovarian stimulation and successive ovarian pick-up. Regarding OTC, 4 patients underwent orthotopic reimplantation: in 2 cases it was an orthotopic reimplantation of fresh ovarian cortex. In the case of patient with history of struma ovarii, the first orthotopic reimplantation failed and a second heterotopic transplantation on abdominal wall was performed. Positive outcomes were reported in only 3 patients: 1 case of pregnancy after in vitro fertilisation; 1 case of normal ovarian tissue with a follicle at laparoscopic follow-up; 1 case of endocrine function and ovulation.

Conclusions

Many conditions are related to the high risk of premature ovarian failure and severe endometriosis is certainly a strong indication for fertility preservation. In single women, OOC could be offered: it requires ovarian stimulation, but not a partner. On the other hand, OTC has the main target of pre-pubertal girls and it can be performed at any time of the menstrual cycle without ovarian stimulation, although it requires two surgical procedures. Anyway, further studies are needed to evaluate the best option for endometriosis patients concerning risks, benefits and cost-effectiveness.

<https://esge.covr.be/cmdocumentmanagement/conferencemanager/documents/api/getdocument/5008/cmabstms/0000142900/985ff1aa21e8df34101e300db76cef573b1c04abe53e9f68d825907ac185c2b8>

ES28-0575 - P*024

Selected E-Poster

Laparoscopic peritoneal vaginoplasty (Luohu Procedure) in MRKH syndrome: 10 years' experience in 885 patients

Hongxin Pan¹, Luo Guangnan¹

¹Luohu People's Hospital, Gynaecology, Shenzhen, China

Background

Numerous nonsurgical and surgical techniques have been described for the creation of a neovagina in patients with Mayer–Rokitansky–Küster–Hauser syndrome (MRKH syndrome) which suggests there is no single superior surgical technique.

This study aims to demonstrate that a novel laparoscopic peritoneal vaginoplasty (Luohu II procedure) provides adequate anatomic and functional outcomes in terms of stable length over time and sexual function in one of the largest cohort studies of patients with MRKH syndrome.

Methods

From January 2007 to December 2016, a total of 885 patients with MRKH syndrome underwent Laparoscopic peritoneal vaginoplasty (Luohu procedure).

Randomly selected frequency-matched age-comparable healthy women were serving as controls (n =653). Intraoperative parameters, postoperative parameters, and anatomical outcomes were recorded. Sexual satisfactions were assessed by the Female Sexual Function Index (FSFI) questionnaire and were compared with the controls.

Results

Laparoscopic peritoneal vaginoplasty (Luohu procedure) was successfully performed in all 885 patients. The mean operative time and intraoperative blood loss were, respectively, 57.4±20.5 minutes and 13.0±9.7 ml. During median follow-up for 28 (range 8-96) months, mean functional neovaginal was 9.9±0.6 cm, including those who had no sexual intercourse. Vaginal biopsy showed complete epithelialisation of vaginal mucosa. At 12 months after surgery, functional success, as assessed by the FSFI questionnaire, was achieved in 96.7% of patients. The FSFI scores did not differ significantly between patients with MRKH syndrome and controls. No common long-term complications occurred.

Conclusions

To the best of our knowledge, this study is the largest cohort study of patients with MRKH syndrome. Our technique (Luohu procedure) creates a neovagina of adequate size and secretory capacity for normal coitus, the procedure may be regarded as a fast, effective and minimally traumatic technique that has satisfactory anatomical and functional outcomes for patients with MRKH syndrome.

<https://esge.covr.be/cmdocumentmanagement/conferencemanager/documents/api/getdocument/5073/cmabstms/0000149090/2cba7189393deca801b87a8b3be69492ae8568c115ba2e5157a750e1c7f8d69e>

Reproductive outcomes in infertile endometriosis patients treated by laparoscopic surgery

Carlotta Giuliani¹, Silvia Pirarba², Danilo Deiana¹, Emanuela Stochino Loi³, Alessandro Loddo¹, Stefano Angioni¹

¹University of Cagliari, Surgical Science, Cagliari, Italy

²Lanusei Hospital, Obstetrics and Gynecology, Lanusei, Italy

³Hospital Cantonal HFR, Obstetrics and Gynecology, Fribourg, Switzerland

Background

Endometriosis is a benign gynaecological disease defined by the histological presence of endometrial glands and stroma outside the uterine cavity and has been estimated to affect up to 10–15% of reproductive aged women. It can cause pain, dysmenorrhea, dyspareunia, chronic pelvic pain and infertility. From 30 to 50% of women with endometriosis have infertility and the fecundity rate in women with untreated endometriosis is 2-10%. Different studies show that surgery seems to improve the success of fertility in patient with DIE without involvement of the bowel and to reduce the risk of rare but severe complication as spontaneous hemoperitoneum and rectal perforation during pregnancy. The relationship between the management of ovarian endometriomas and infertility feeds its largely debated for the risk of post-operative ovarian reserve impairment but today surgery management of ovarian endometriomas is recommended. The aim of our study was to assess the pregnancy outcomes in women managed for ovarian endometriomas and deep endometriosis.

Methods

Retrospective study. 299 patients operated by laparoscopy from January 2011 to December 2014 in the Department of Gynaecology of Cagliari University Hospital in Italy, for endometriosis and infertility. 63 patients were excluded because follow up was not possible or because surgery was converted to laparotomy. Of the remaining 236 patients, 125 were infertile for at least 2 years and had expressed pregnancy intention before surgery. Of 125 patients included in the study, 123 patients had been treated by multiport laparoscopy and 2 by single port laparoscopy: in all of them adhesiolysis and peritoneal superficial resection were performed. Endometriomas were treated by cystectomy. Deep endometriosis' lesions were treated by conservative and radical approach. Statistical analysis was performed by Binomial Logistic Regression with Stepwise method and Multiple Linear Regression with Stepwise method. For correlation it was calculated the index Rho of Spearman. Chi² test and Odds Ratio were used to compare qualitative variables, t Student test were used to compare continuous variables. P < 0.05 was considered statistically significant. Statistical analysis was performed using SPSS 20.0.

Results

125 patients were included. Pregnancy was achieved by 69 patients (55.2%). 9 (7.2%) miscarriage occurred. Conception was spontaneous in 86.2% of them (n=50) and 13.8% patients (n=8) had benefited of postoperative assisted reproductive technology (ART). Correlations with several variables will be presented.

Conclusions

The treatment of endometriosis is still a very complex challenge. Radical surgery seems the best choice for patient with pregnancy desire in order to restore normal anatomy and increase fertility's chances.

<https://esge.covr.be/cmdocumentmanagement/conferencemanager/documents/api/getdocument/5209/cmabstms/000166740/39ab3d96c16e32915ca17419f990158c7e19f9b24e553f1cef1179c118d7a3d0>

ES28-0625 - P*026
Selected E-Poster

Laparoscopic management of class U4a (ESHRE/ ESGE classification) congenital malformations

Theodoros Theodoridis¹, Leonidas Zepiridis¹, Panagiotis Pappas¹, Stamatia Papadopoulos¹, Dimitra Aivazi¹, Grigoris Grimbizis¹

¹*Aristotle University Thessaloniki, 1st Dept. Ob&gyn, Thessaloniki, Greece*

Background

To describe our experience in laparoscopic management of cavitated uterine rudimentary horns and their complications (Class U4a ESHRE/ ESGE classification for congenital malformations)

Methods

Six patients between 22 and 32 years old were diagnosed to have uterine rudimentary horns (Class U4a ESHRE/ ESGE classification). As diagnostic imaging tool transvaginal ultrasound (TVS) and/or magnetic Resonance Imaging (MRI) were used. In two cases hysterosalpingography (HSG) was also performed. In all cases the rudimentary horn was in the left side with a right unicornuate uterus. The main symptom was severe dysmenorrhea (5/6 patients) and infertility (2/6 patients). One patient was diagnosed to have ectopic pregnancy in the left uterine rudimentary horn.

Results

All patients were successfully managed laparoscopically. In one case the rudimentary horn was firmly attached to the unicornuate uterus while in 5 cases the rudimentary horn was attached to the hemi-uterus by a band of tissue. Bipolar energy and scissors were used in all cases and ultrasonic assisted in two cases. The excised rudimentary horn, including the one with the ectopic pregnancy, were removed from the peritoneal cavity intact, through an enlargement of the suprapubic trocar incision. There were no intraoperative or postoperative complications.

Conclusions

Congenital anomalies can be managed endoscopically. After careful preoperative evaluation the laparoscopic removal of the cavitated rudimentary horn (Class U4a ESHRE/ ESGE classification) congenital malformations is safe and should be the treatment of choice.

<https://esge.covr.be/cmdocumentmanagement/conferencemanager/documents/api/getdocument/5105/cmabstms/000044560/9f5f1fca8466b9d9c03fc4ed1834109ccc6db80d033f0414b24fa580ab0d989c>

ES28-0035 - P*027
Selected E-Poster

Development and face validity of a laparoscopic simulation model for colposacropexy

Blanca Fernández-Tomé¹, Belén Moreno Naranjo², Idoia Díaz-Güemes Martín-Portugués³, Luis López-Fandón⁴, Miguel Sánchez-Hurtado², Sánchez-Margallo Francisco Miguel⁵

¹*Jesús Usón Minimally Invasive Surgery Center, Laparoscopy, Cáceres, Spain*

²*Centro de cirugía de Mínima Invasión Jesús Usón., Laparoscopy, Cáceres, Spain*

³*Centro de cirugía de Mínima Invasión Jesús Usón. N-521. Km41-8, Laparoscopy, Cáceres, Spain*

⁴*Hospital universitario Ramón y Cajal, Unidad de Patología Vesical Funcional y Oncológica, Madrid, Spain*

⁵*Centro de cirugía de Mínima Invasión Jesús Usón. N-521. Km41-8, Dirección, Cáceres, Spain*

Background

It is currently difficult to acquire a model that simulates the anatomy of the woman pelvic floor. The models used in simulation to laparoscopic mesh placement are very limited. The objective of this study is to describe and present a preliminary validation of a specific simulator which allows to training the stitches to the mesh placement in the laparoscopic colposacropexy (LCP).

Methods

The material selected was polyurethane resin and the pig abdominal wall to simulate the pelvis and the pelvic floor. In this study participated 16 expert gynaecologists performed the stitches of the LCP in the simulator. Once finished, they completed a questionnaire about the anatomical integrity and the stitches assessment in the mesh placement. A 5 point Likert scale was used for this evaluation.

Results

Participants considered with $4,2 \pm 0,31$ the reproducibility of the pelvic size, with $4,5 \pm 0,74$ the stitches on *levator ani muscles*, with $4,8 \pm 0,24$ the reproducibility of *sacrospinous ligament*. They also rated the utility of the model for previous training with 4.8 ± 0.31 . Finally, the overall assessment of the model obtained a score of 9.1 ± 0.41 out of 10.

Conclusions

This novel laparoscopic surgical simulation shows a preliminary validity and allows practice the mesh placement stitches in the LCP.

<https://esge.covr.be/cmdocumentmanagement/conferencemanager/documents/api/getdocument/4944/cmabstms/000048170/5faaef092eb144fac7a8e2b6a5733f67fa2e339d40a168281ca54b6c8b64e37d>

ES28-0209 - P*028

Selected E-Poster

Laparoscopic treatment of minimal or moderate endometriosis and pregnancy rate

*Lela Iremadze*¹, *Arsen Gvenetadze*², *Vasilios Tanos*³, *Lela Sichinava*², *Lela Tandashvili*²

¹Reproductive Clinic of Zurab Sabakhtarashvili, Reproductology- Gynecology, Tbilisi, Georgia

²Reproductive Clinic of Zurab Sabakhtarashvili - Endometriosis Center of Excellence. Tbilisi State University, Gynecology-Surgery, Tbilisi, Georgia

³University of Nicosia- Medical School- and Aretaeio Hospital, Gynecology-Surgery, Nicosia, Cyprus

Background

Minimal and moderate pelvic endometriosis is frequently diagnosed in infertile women. Ablation of the endometriosis lesions often improves fertility potential by 50-70%. A retrospective evaluation of the pregnancy rate (PR) of infertile women diagnosed and treated by laparoscopy for endometriosis is presented

Methods

From January 2012 to July 2018, 778 infertile women, age 21 to 42, with excluded male factor, underwent laparoscopy and methylene blue dye test evaluating tubal patency and staged for minimal or moderate endometriosis according to rASRM classification. Women with minimal endometriosis were treated by ablation of the visible lesions using bipolar diathermy. Patients with moderate disease underwent excision of the endometriosis implants using scissors and bipolar probe for haemostasis. The PR and time from surgery to spontaneous conception was evaluated.

Results

Among 778 laparoscopies performed, 384 (49,3%) of minimal or moderate endometriosis were diagnosed and confirmed by histopathological biopsies. Bipolar ablation of the endometriotic lesions was performed in 220 cases while in 164 patients excision of the endometriosis implants was necessary. Concomitant pathologies were noted, 20.3% had fibroids, 9.5% endometrial polyps, 11,1% adhesions. Subtle lesions like Morgani tubal cysts were found in 45.2% and cervical polyps in 8.5% of the cases. Among all patients with confirmed patent tubes 69/202 (34%) treated for minimal endometriosis and 74/164 (45,1%) with moderate disease had a spontaneous pregnancy within 40 weeks after operation. The overall PR after spontaneous conception up to 12 months post operatively was (69/220) 34.2% for the minimal endometriosis treated by ablation, and (74/164) 45.1% for the moderate disease, endometriosis implants treated by excision.

Conclusions

The significant difference in PR, after spontaneous conception, between the 2 treatment groups, probably reflects the difficulty to occasionally distinguish between minimal and moderate endometriosis and consequently under treatment of the disease

<https://esge.covr.be/cmdocumentmanagement/conferencemanager/documents/api/getdocument/5165/cmabstms/00150870/81fabb4a8470bc13e397cb661637713e4ac805f8f8531c28e0b0caaf2b2a889b>

ES28-0232 - P*029

Selected E-Poster

Successful management of symptomatic submucosal myoma located in an isthmocele: a case report

Marina Picon¹, Julia Ercilla Orbañanos¹, Gloria Isabel Ruiz Barrañón¹, Juan Antonio Solano Calvo¹, Juan José Delgado Espeja¹, Álvaro Zapico Goñi¹

¹Hospital Príncipe de Asturias, Obstetrics and Gynecology, Alcalá de Henares, Spain

Background

To describe our experience treating a symptomatic submucosal myoma located in an isthmocele.

Methods

A patient with a diagnosis of a submucosal myoma and isthmocele was selected for this case. No similar cases are reported in the literature (Pubmed).

Results

A 48-year-old woman with a history of 2 previous caesareans was referred to our gynaecological service complaining about abnormal uterine bleeding. It was identified a polymyomatous uterus at the transvaginal ultrasound examination. One of the myomas stood out above the rest, it was a 16x16mm submucosal myoma that was located coinciding with a caesarean scar defect (isthmocele). The residual myometrial thickness over the defect was 16mm. Few days before the surgery, a 3D ultrasound was made to identify the exact location of the myoma as well as the isthmocele and the myometrial thickness.

Hysteroscopic approach was performed to do the resection of the submucosal myoma and secondly correct the caesarean scar defect that was hidden behind. No complications occurred during the surgery. The patient has a satisfactory postoperative and could go home the same day of the surgery. Two weeks after surgery we could check that the symptoms were mostly disappear and the transvaginal ultrasound showed the restore of the uterine defect.

Conclusions

Hysteroscopic approach is accepted as an effective and safe technique to correct isthmocèles with myometrial thickness over 3mm, but there is nothing reported in the literature about isthmocele coexisting with a submucosal myoma. In our patient, hysteroscopic approach allowed both clinical and ultrasound improvement in just a few weeks.

<https://esge.covr.be/cmdocumentmanagement/conferencemanager/documents/api/getdocument/5242/cmabstms/00165880/29420d0c0d2d52cd0893ddd30bc082a5eb3b87e9c51f965e822abb34a00fda2a>

Accuracy of hysteroscopy in the diagnosis of endometrial hyperplasia in premenopausal women: a descriptive retrospective study

Julia Ercilla¹, G. Isabel Ruiz Barrajon¹, Victoria Quintero¹, J. José Delgado¹, J. Antonio Solano¹, Álvaro Zapico¹
¹Hospital Universitario Príncipe de Asturias, Gynecology, Madrid, Spain

Background

The aim of the present retrospective study was to assess our experience regarding the accuracy of hysteroscopic view in diagnosing simple/complex endometrial hyperplasia in premenopausal women.

Methods

We evaluate the data collected in our diagnostic hysteroscopy database. We made a systematic and retrospective review of the 5618 patients who underwent office-based hysteroscopy from 2012 to 2019. Our research identified 415 premenopausal patients with histological diagnosis of endometrial hyperplasia in blind or hysteroscopically targeted endometrial biopsy.

Results

The main hysteroscopic features that were considered for the hysteroscopic diagnosis of endometrial hyperplasia were: focal or extensive endometrial thickening, irregular vascular network, architectural distortion and crowding of gland openings and gland cyst.

We calculated the sensitivity, specificity, negative predictive values (NPV) and positive predictive values (PPV) of office-based hysteroscopy for the diagnosis of both simple and complex endometrial hyperplasia in premenopausal women. Histological samples detected simple endometrial hyperplasia in 398 patients (97%), complex hyperplasia in 13 patients (2.3%) and atypical hyperplasia in 4 patients (0.7%) from the total of 5618 hysteroscopies registered in our database. To predict the diagnosis of simple hyperplasia in premenopausal, hysteroscopy showed an overall sensitivity, specificity, PPV and NPV of 31.1%, 94.5%, 46.3%, and 90.1%, respectively. If we focus on complex hyperplasia the sensitivity, specificity, PPV and NPV were 71.4%, 99.8%, 71.4% and 99.8%, respectively.

We found 281 patients in which hysteroscopic appearance underdiagnosed simple endometrial hyperplasia. The diagnoses made by hysteroscopic view were the following:

- Atrophic endometrium: 8 (2%)
- Functional endometrium: 200 (71%)
- Proliferative endometrium: 31 (11%)
- Secretor endometrium: 15 (5%)

In 20 patients (6%) the hysteroscopy was not assessed due to complications derived from a bad distention of the cavity or partial cervical stenosis. On the other hand, if we focus on complex hyperplasia, there were 4 situations in which hysteroscopic view made an insufficient diagnosis:

- Functional endometrium: 3 (66%)
- Secretor endometrium: 1 (5%)

Conclusions

The prediction of simple/complex endometrial hyperplasia by hysteroscopy has turned out to be one of the main difficulties we find in our practice. Our results conclude that hysteroscopy is not a sensitive test for diagnosis of simple endometrial hyperplasia, nevertheless it presents a high specificity. It is also saw how sensitivity increases as the complexity of the histological sample does.

Thickened endometrium in asymptomatic postmenopausal women: hysteroscopic and histological results
Victoria Quintero Morillo¹, Marina Picón¹, Julia Ercilla¹, Juan José Delgado¹, Juan Antonio Solano¹, Álvaro Zapico¹
¹Hospital Universitario Príncipe de Asturias, Gynecology, Alcalá de Henares- Madrid, Spain

Background

Uterine cancer is the most common gynaecologic malignancy in developed countries. Postmenopausal bleeding is the cardinal symptom of endometrial carcinoma and occurs in approximately 90% affected patients. However there are a 5-20% of women diagnosed who have no symptoms.

Hysteroscopy allows a direct view of the endometrium and take directed biopsies of suspicious lesions. This histological samples must always be taken to determine the definitive diagnosis.

The aim of this study is to research the prevalence of endometrial pathology in asymptomatic postmenopausal women, by endometrial direct view with the hysteroscope and histological examination.

Methods

This is a prospective observational study in a university hospital. Over 2500 postmenopausal women underwent an office hysteroscopy between January 1, 2014 and December 31, 2018, for abnormal uterine bleeding or an abnormal ultrasound. Of these, 45 had a thickened endometrium (>4mm) measurement by transvaginal ultrasonography and no abnormal bleeding.

Results

For the 45 asymptomatic postmenopausal women the mean age was 60,06 years. The range of endometrial measurements was 4 to 32mm (mean: 9,53mm).

Hysteroscopy diagnoses included 34 polyps, 7 benign-appearing endometrium, 2 patients with uterine synechiae and 2 patients with hyperplasia.

Of the women with an endometrial polyp, subsequently underwent a polypectomy. The histological examination showed no uterine cancer and only one patient had hyperplasia with atypia on the final pathology (endometrial measurement: 11mm).

11 endometrial biopsies were performed, 2 patients had simple hyperplasia without atypia, 1 endometritis, 3 endometrial polyps and 5 inactive endometrium.

Conclusions

Hysteroscopy represents an effective method for the assessment of asymptomatic postmenopausal women with thickened endometrium found with transvaginal ultrasound.

Endometrial cancer and atypia are uncommon in postmenopausal women without abnormal uterine bleeding.

Endometrial polyps are the most frequently observed lesions in our cohort.

It is questioned whether incidental finding of thickened endometrium is enough to indicate more invasive testing like hysteroscopy in asymptomatic postmenopausal women.

Why are women cancelling mesh procedures: a multicentre patient survey

Christopher Skelly¹, Susan Wilson², Katherine Niblock³, Keith Johnston⁴

¹*Obstetrics and Gynaecology, Craigavon Area Hospital, Craigavon, United Kingdom*

²*Craigavon Area Hospital, Craigavon Area Hospital, Craigavon, United Kingdom*

³*Craigavon Area Hospital, Obstetrics and Gynaecology, Craigavon, United Kingdom*

⁴*Antrim Area Hospital, Obstetrics and Gynaecology, Antrim, United Kingdom*

Background

With the current wave of negative publicity over the use of mesh in gynaecology, significant numbers of patients are cancelling apical suspension mesh procedures and mid urethral tape incontinence operations. This potentially compromises optimal patient management and quality of life, as well as affecting surgical training. We explored the main reasons for this and determined if alternative non-mesh treatment was offered or undertaken.

Methods

A multi-centre study of 20 patients known to have cancelled mesh procedures in the previous 12 months. The patients were contacted by telephone, and completed a 10 questions survey, designed to ascertain the factors, patients knowledge base and specialist influence that resulted in them withdrawing from the mesh procedure.

Results

74% of procedures cancelled were for stress urinary incontinence (SUI), 21% for pelvic organ prolapse (POP), 5% for both. All patients were parous and aged between 34-74 years old. 74% of patients had material concerns over the use of mesh. Decision-making was overwhelmingly negatively impacted by popular and social media. Specialist surgeon advice was highly regarded but rarely changed patients' decisions. 68% of women proceeded to an alternative procedure in the form of paraurethral injection or colposuspension for SUI, or sacrospinous ligament fixation for prolapse. 47% of women surveyed claimed they would be very unlikely to ever consider a mesh procedure in the future, with a further 21% stating they would "definitely not".

Conclusions

An embedded culture of anxiety exists over the risks, permanence and irreversibility of mesh procedures. Patients feel they receive conflicting information regarding gynaecological mesh procedures. There was little understanding of the difference in the nature and rates of complications between abdominal and vaginal mesh. Women should be made aware of all the available treatment options and provided with the information they need in order to make informed choices appropriate to their lifestyle. Meticulous informed consent and patient education is paramount. There is an urgent need for gynaecology units undertaking mesh procedures to audit their own specific outcomes and complications. Prospective data collection through the BSUG database is important to provide comprehensive information to women and healthcare professionals about the benefits and risks of urogynaecological procedures. Long-term, this skewed negative publicity will result in surgeons having to retrain in traditional approaches (from who?) and RCOG ATSM reconfiguration.

<https://esge.covr.be/cmdocumentmanagement/conferencemanager/documents/api/getdocument/5195/cmabstms/000155990/a5db30e7aab1225c1c1fd6edf7a8d3f610663bb548bed987385bbeed768f22b0>

Normalisation of hysteroscopic and histological features in women with chronic endometritis after antibiotic treatment: a blatant proof of the infectious nature of this subtle pathology

Ettore Cicinelli¹, Amerigo Vitagliano², Pasquale Capuano¹, Paola Traversi¹, Rossella Cannone¹, Rossana Cicinelli¹

¹2nd Unit of Obstetrics and Gynecology, Department of Biomedical and Human Oncologic Science, Bari, Italy

²University of Padua, Women's and Children's Health, Padua, Italy

Background

Chronic endometritis (CE) is a chronic inflammation of endometrial lining. In recent years, a great interest has been focused on CE as it may account for infertility and recurrent pregnancy loss. Histology is the gold standard for CE diagnosis, where plasma cells are identified in the endometrial stromal compartment. CE may be diagnosed at fluid hysteroscopy by the detection of subtle endometrial abnormalities like hyperemia, polypoid appearance and micropolyps. To date, there is still no adequate evidence on the effects of antibiotic treatment on endometrial features at hysteroscopy and histology in women with CE. In this retrospective study, we aimed to evaluate the effects of antibiotic treatment on both histological and hysteroscopic aspects in women with CE.

Methods

64 infertile women referred to our centre due to hysteroscopic diagnosis of CE were included. All patients were submitted to a repeated hysteroscopy plus endometrial biopsy (for histological and microbiological analyses). Diagnosis of CE at hysteroscopy was based on published criteria. Histological diagnosis of CE was performed by traditional H&E staining and by CD138 immunohistochemistry (presence of ≥ 1 plasmacell /section). All patients with a diagnosis of CE were treated with culture-oriented antibiotic therapy and re-evaluated by histology and hysteroscopy.

Results

Repeat hysteroscopy confirmed in all cases the diagnosis of CE. In 38 (59.4%) women histology confirmed the presence of CE. Cultures were positive 43 cases (67.2%). In 33 (51.5%) cases histology and cultures were consistent. Notably, in 34 out 38 (89.5%) women after therapy (no more than 3 courses) both hysteroscopic and histological signs disappeared, while CE was persistent in 4 cases.

Conclusions

The hysteroscopic diagnosis of CE showed a high interobserver reproducibility. In most cases, after culture oriented antibiotic therapy both hysteroscopic and histological signs of CE disappeared. Our findings clearly demonstrate that CE is due to infectious agents and that adequate antibiotic therapy may result in normalization of endometrial features at hysteroscopy and histology.

<https://esge.covr.be/cmdocumentmanagement/conferencemanager/documents/api/getdocument/5193/cmabstms/000166810/03eb61721733135926f4ff3ba14fc2e70834084671ea0bfdbeeabc216517f43f>

Thickened endometrium in asymptomatic postmenopausal women – determining an optimum threshold for prediction of atypical hyperplasia and cancer

Eftychia Papachatzopoulou¹, Andreas Zouridis¹, Nikos Vlahos¹, Panagiotis Vakas¹, Efthimios Deligeoroglou¹, Theodoros Panoskaltsis¹

¹National and Kapodistrian University of Athens- Aretaieio Hospital, Second Department of Obstetrics and Gynecology, Athens, Greece

Background

To assess the correlation between endometrial thickness and diagnosis of endometrial cancer and/or endometrial atypical hyperplasia in asymptomatic postmenopausal women (patients with absence of postmenopausal bleeding).

Methods

Retrospective study on a cohort of 859 consecutive patients admitted to our department during the five-year period 2014-2018. All patients had a pre-admission transvaginal ultrasound (TVU). Indications for hysteroscopy included thickened endometrium, abnormal uterine bleeding and presence of endometrial polyps or fibroids. In this cohort, we identified 98 asymptomatic postmenopausal women with thickened endometrium on TVU. Demographic and clinical data concerning risk factors for endometrial cancer and/or endometrial atypical hyperplasia were collected (age, parity, Body Mass Index [BMI], history of hypertension and/or diabetes and age of menarche and menopause). Receiver operating characteristic (ROC) curve was used to evaluate predictive ability. Fisher's exact tests were used for the comparison of proportions.

Results

The mean age of the study group (98 asymptomatic postmenopausal patients) was 62.6 years (SD=8.3). Hysteroscopy had 33.3% sensitivity and 95.6% specificity for the detection of endometrial cancer and/or atypical hyperplasia, while positive and negative predictive values were 20% and 97.7%, respectively. TVU and hysteroscopy findings were associated with the presence of endometrial cancer and/or hyperplasia found on histology and only thickness from TVS showed a significant association. The mean thickness of the endometrium was significantly greater in cases with endometrial cancer and/or atypical hyperplasia (15.5±3mm vs. 10.1±4.0mm, p=0.030). ROC curve analysis showed that the optimal cut-off of thickness for the prediction of endometrial cancer and/or hyperplasia was 11.2mm with 75% sensitivity and 73% specificity. The area under the curve (AUC) was 0.80 (95% CI: 0.66-0.94) which significantly differs from 0.5 (p=0.044). After adjusting for age, nulliparity, hypertension, diabetes, age of menarch and menopause, on logistic regression analysis, thickness of the endometrium (OR=1.16, 95% CI: 0.76-1.78, P=0.491) was no longer significantly associated with endometrial cancer and/or endometrial atypical hyperplasia. Although, BMI was recorded in 51 patients, when BMI was taken into account there was no difference in the results.

Conclusions

In asymptomatic postmenopausal women, a TVU endometrial thickness >11mm is highly suggestive of endometrial cancer and/or atypical hyperplasia.

<https://esge.covr.be/cmdocumentmanagement/conferencemanager/documents/api/getdocument/5137/cmabstms/000043730/ab32c52d0b77a06825d1714a76d8b00033c8f34815c1f3e3f8807b78b6789a57>

ePOSTER (250)

ES28-0028 - P041

E-Poster

LncRNA RP11-395G23.3, as a competitive endogenous RNA, regulate PTEN expression by sponging miR-205-5p in the progression of endometrial cancer

Weijuan Xin¹, Keqin Hua¹, Jingxin Ding¹

¹Obstetric and Gynaecologic Hospital of Fudan University, Obstetric and Gynaecologic, Shanghai, China

Background

This study was to investigate the role of lncRNA RP11-395G23.3 associated competitive endogenous RNAs (ceRNAs) network in the endometrial cancer (EC).

Methods

A total of 40 primary endometrial cancer tissues and 20 normal endometrial tissues (NE) were recruited into this study. NE was obtained from women who underwent a hysterectomy or endometrial curettage for endometrial-unrelated diseases (such as uterine myoma or prolapse). The expression of RP11-395G23.3, miR-205-5p and their targets were assessed by RT-PCR, qRT-PCR and western-blot. Functional significance of RP11-395G23.3 and miR-205-5p on tumor proliferation and migration in vitro were examined by CCK-8, flow cytometry, wound healing and transwell assays.

Results

RP11-395G23.3 expression was significantly decreased both in human EC tissues and cell lines compared with the control. miR-205-5p expression was significantly increased, and the mRNA and protein expressions of PTEN were markedly reduced in EC tissues and cell lines compared with the control. We examined the correlation of RP11-395G23.3 expression in human EC tissues with EC patients' clinical features. Moreover, RP11-395G23.3 expression was negatively related to miR-205-5p in human EC tissues. Our results also showed that RP11-395G23.3 overexpression considerably attenuated the viability, migration and invasion of Ishikawa and HEC-1A cells in vitro. In addition, through its miRNA response elements (MREs) to compete for miR-205-5p, RP11-395G23.3 was confirmed to regulate the expression of PTEN and the viability, migration and invasion of Ishikawa and HEC-1A cells in vitro.

Conclusions

We for the first time identify that RP11-395G23.3 is effective ceRNAs associated with miR-205-5p-PTEN network. To our knowledge, it is also the first time to demonstrate that RP11-395G23.3 regulates EC development by deriving miR-205-5p and provide important clues for understanding the key roles of lncRNA-miRNA functional network in EC.

<https://esge.covr.be/cmdocumentmanagement/conferencemanager/documents/api/getdocument/5307/cmabstsms/000150460/b169622d8bd2ffa3b5cd72cdf32a9be2c96a88afcecaa69857f69d3dd62d629>

Surgical management and outcomes after surgery for deep endometriosis infiltrating the rectum

Celine Bafort^{1,2}, Albert Wolthuis³, Christel Meuleman^{1,2}, Annouschka Laenen⁴, André D'Hoore³, Carla Tomassetti^{1,2}

¹UZ Leuven, Obstetrics and Gynaecology/Leuven University Fertility Center, Leuven, Belgium

²KU Leuven, Department of Development and Regeneration, Leuven, Belgium

³UZ Leuven, Department of Colorectal Surgery, Leuven, Belgium

⁴KU Leuven, Department of Public Health- Interuniversity Center for Biostatistics and Statistical Bioinformatics, Leuven, Belgium

Background

The best surgical technique for treatment of deep endometriosis of the rectum is still controversial; two surgical techniques can be applied: a radical approach where colorectal segmental resection is performed and a conservative approach aiming at preserving the rectal ampulla (either by shaving or (partial/full thickness) disc excision).

Trading off between presumed higher completeness and therefore potential lower recurrence rates (in case of segmental resection) versus the possibility of less postoperative complications (in case of conservative management) has up to now resulted in ongoing discussion between different surgical schools.

The aim of this study was to evaluate the rate of postoperative complications between conservative and radical surgery in patients with deep endometriosis infiltrating the rectum.

Methods

Single center retrospective study in patients scheduled for endometriosis surgery in a tertiary referral center. Included patients were managed for deep endometriosis infiltrating the rectum up to 15cm from the anus with at least involvement of the muscularis layer of the rectum.

All patients underwent complete CO₂-laser laparoscopic excision of any rASRM-stage endometriosis. During the study period (January 2010-December 2014), 966 patients underwent endometriosis surgery in our unit, of whom 232 met the inclusion criteria. Subgroup analysis was done in patients without previous therapeutic laparoscopy for endometriosis (n=108).

Results

Of 232 patients, 61(26,29%) underwent conservative surgery and 171(73,71%) radical surgery. Patients' baseline characteristics (age, BMI, reason for intervention, pre-operative pain symptoms and clinical examination), were similar in both groups with the exception of the rate of severe dysmenorrhea (higher in the group undergoing radical surgery (P<0,001)). In the radical surgery group, a higher rASRM total score and higher rASRM stage was found (P<0,001).

The primary outcome studied was the rate of postoperative complications. Clavien-Dindo type-1 postoperative complications were recorded in 4/232 patients (2,34%), all in the radical surgery group (P=0,575). Clavien-Dindo type-2 complications did not differ between both groups (30/232(12,93%) total group: 7/61(11,48%) conservative versus 23/171(13,45%) radical (P=0,826)). Clavien-Dindo type-3 complications were more frequent in the radical group (19/232(8,19%) total: 1/61(1,64%) conservative versus 18/171(10,53%) radical (P=0,029)). However, a subgroup analysis on patients without previous therapeutic laparoscopy couldn't confirm this difference (n=108: 1/27(3,70%) conservative versus 5/81(6,17%) radical (P=1)). Although all surgical procedures were performed on the rectal ampulla, a low rate of temporary diverting ileostomy was recorded: 23/232 patients (9,91%), all in the segmental resection group (23/171(13,45%)).

Secondary outcomes (pain improvement, pregnancy, recurrence) also showed no difference between both groups after a mean follow-up time of 39 months.

Conclusions

Our data demonstrates no significant difference in complication rate, regardless of the surgical technique used, in patients without previous therapeutic laparoscopy. This suggests that past surgery increases the risk of subsequent repeat surgery, but it also emphasizes the importance of a well-executed first surgery.

The effect of hyperproduction of cytokine balance in peritoneal liquid and allelic variants of genes in the proposed patients on angiogenesis and endometriosis stage

Zoia Savina¹, Yevdokymova Viktoriya Volodymyrivna²

¹Surgery, Gynecologist in a Private Clinic, Kyiv, Ukraine

²Surgery, Gynecology, Odessa, Ukraine

Background

Endometriosis (ES) is a common, mysterious (Baskakov V.P.) and actual gynecological disease in modern gynecology, where endometrial cells grow outside in women organism of reproductive age.

Methods

In the Military Medical Clinical Center of the Southern Region and Odessa National Medical University, over a period of last 5 years, were examined 300 patients a woman (20-45 y.o.) with ES and laparoscopically operated. Each of them was intraoperatively sampled by a peritoneal fluid (PF). Immunoassay analysis using the NE-Life Science (Sweden) test systems, Cytoimmune science inc (USA), examined the overexpression of cytokines (IL-6, IL-8, TNF- α) and hypervascular geneses (VEGF).

Results

Our analysis of the observed, expected frequencies of genotypes for the studied genes IL-6, IL-8, TNF- α , VEGF showed that in the I (control) and III groups the distribution of homozygot and heterozygot varieties of -405GC polymorphism of the VEGF gene was uneven ($\chi^2=0.98$, $p>0.05$); -308GA of the TNF- α gene in the II and III groups - uniform ($\chi^2=0.09$, $\chi^2=0.22$), and in the I group - differed from the equilibrium state ($\chi^2 = 5.3$, $p>0.05$); -174GC gene of IL-6 ($\chi^2=23.5$ for $p>0.05$) I group, $\chi^2 = 14.4$ - for the II group and $\chi^2=0.53$ - for the III group. Also, in group I, the heterozygot by deletion polymorphism of -251TA IL-8 gene was 23.6% less than the actual one.

Conclusions

The level of expression of the VEGF and cytokines determines the severity of clinical manifestations of ES. Hyperproduction in the PF of cytokines TNF- α , IL-6, IL-8 characterized a cytokine balance disorder, and VEGF overexpression showed IV stage of ES, which creates favorable conditions for the onset, development and progression of the disease. The definition of "functionally weakened" allelic variants of the genes IL-6, IL-8, TNF- α , VEGF allows predicting the development of ES. In the presence of homozygot conditions along pathologically burdened alleles of polymorphisms -450ST of VEGF gene, -308GA gene TNF- α , -174TA gene IL-6 - the risk of development of ES. An increase in the level in the PF of IL-6, IL-8, TNF- α , VEGF and a decrease in TNF- α indicates a high activity of ES, which requires adequate immunomodulate therapy.

<https://esge.covr.be/cmdocumentmanagement/conferencemanager/documents/api/getdocument/5287/cmabstms/000166500/f6190adf50135afb53ba0d60a9890c92ddb7c7688103960063acb3540ec2d606>

ES28-0009 - P045

E-Poster

Randomized clinical trial of bowel preparation with 2L polyethylene glycol plus castor oil versus 1L polyethylene glycol plus castor oil and ascorbic acid before colonoscopy

Xu Tian¹, Wei-Qing Chen¹

¹Chongqing University Cancer Hospital, Department of Gastroenterology, Chongqing, China

Background

Ascorbic acid (Asc) and castor oil (CaO) have potential of halving liquid loading. Our aim was to evaluate efficacy and safety of 30mL CaO alone or plus Asc in bowel preparation before colonoscopy.

Methods

Two hundred and forty six patients were enrolled and allocated randomly to drink 2L PEG with 30mL CaO, 1L PEG with 30mL CaO plus 5g Asc, or 3L PEG. We used Boston Bowel Preparation Scale (BBPS) to evaluate bowel preparation efficacy. We also determined procedure time, polyp or adenoma detection rate, patients' satisfaction, compliance and willingness to repeat colonoscopy, and adverse events (AEs).

Results

Of 282 patients recruited, 36 were excluded. Groups were matched for baseline characteristics except weight ($P = 0.020$) and body mass index (BMI) ($P = 0.003$). There were no differences in cecal intubation success rate ($P = 0.343$), cecal intubation time ($P = 0.463$), withdraw time ($P = 0.864$), total BBPS score ($P = 0.062$) or incidence of AEs. Patient's satisfaction was higher in 2L PEG-CaO ($P = 0.016$) and 1L PEG-CaO-Asc groups ($P = 0.017$). Patients' compliance was 67.5%, 71.4% and 80.5% in 3L PEG, 2L PEG-CaO and 1L PEG-CaO-Asc groups ($P = 0.014$). Adequate bowel preparation rate was 75%, 78.57% and 53.66% in 3L PEG, 2L PEG-CaO and 1L PEG-CaO-Asc groups ($P = 0.021$).

Conclusions

Despite an increase in patients' satisfaction and compliance, 1L PEG-CaO-Asc regime significantly decreased adequate bowel preparation rate. However, 2L PEG-CaO improved the patients' satisfaction and compliance and increased adequate bowel preparation rate.

ES28-0016 - P046

E-Poster

Tension-free vaginal tape-obturator for the treatment of stress urinary incontinence: a 12-year prospective follow-up

Lan Zhu¹, Ye Zhang¹

¹Peking Union Medical College Hospital- Beijing, Department of Obstetrics and Gynecology, Beijing, China

Background

The long-term safety and effectiveness of inside-out transobturator tape (tension-free vaginal tape-obturator, TVT-O) for the treatment of stress urinary incontinence (SUI) has yet to be evaluated in detail.

Methods

Between August 2004 and August 2006, 87 consecutive patients with SUI who underwent TVT-O were enrolled in this prospective cohort study. Patients with mixed UI or pelvic organ prolapse requiring surgery, were excluded. Data relating to long-term postoperative complications, subjective satisfaction rate (Patient Global Impression of Improvement), objective cure rate (stress test), quality of life (QoL) and sexual function, were collected during follow-up. The Incontinence Impact Questionnaire (IIQ-7) and Pelvic Organ Prolapse/ Urinary Incontinence Sexual Questionnaire (PISQ-12) were used to assess QoL and sexual function, respectively. Statistical analyses were performed using paired-sample t-tests.

Results

At the 12-year follow-up, 73 patients (84%) were available for evaluation. Overall, the long-term complication rate was 45.2%. *De novo* overactive bladder was observed in 12.3% of patients. None of the patients reported severe voiding dysfunction that required treatment by tape removal or catheterisation. However, 16 patients (16/73, 21.9%) had voiding changes compared with their preoperative status. Persistent groin pain was reported in 1.4% of the patients

and tape exposure occurred in 5.5%. The subjective satisfaction rate and objective cure rate were 80.8% and 82.2%, respectively. Compared with preoperative scores, the IIQ-7 score decreased significantly ($P < 0.05$), whilst there was no significant difference in the PISQ-12 score ($P = 0.893$).

Conclusions

This 12-year follow-up study showed that TVT-O is a highly effective procedure for the treatment of SUI. The long-term complication rate appears to be slightly high, which should raise concern.

ES28-0017 - P047

E-Poster

Study on depressive symptoms in patients with mayer-rokitansky-küster-hauser syndrome: an analysis of 141 cases

Lan Zhu¹, Shuang Song¹, Na Chen¹

¹Peking Union Medical College Hospital- Beijing, Department of Obstetrics and Gynecology, Beijing, China

Background

Mayer-Rokitansky-Küster-Hauser (MRKH) syndrome is a rare congenital disease characterized by uterovaginal agenesis. The diagnosis of MRKH syndrome generally leads to considerable emotional burdens on patients. However, studies focusing on the psychological influence on patients are limited and of unsatisfactory quality.

Methods

Between January 2018 and July 2018, 141 patients with MRKH syndrome were enrolled. Depressive symptoms were assessed by the Chinese version of the Patient Health Questionnaire-9 (PHQ-9). Other parameters, such as sociodemographic characteristics, treatment histories, personality traits, and attitudes toward femininity and offspring, were also gathered in the self-administered questionnaire.

Results

A total of 75.2% of respondents suffered from depressive symptoms, and 34.0% of respondents reached a moderate to severe level. Compared with other age groups, women in their 20s scored higher on the PHQ-9. Moreover, women with anxiety symptoms, higher neuroticism levels in personality traits and negative self-evaluation of femininity were more likely to exhibit depressive symptoms.

Conclusions

Three-quarters of MRKH patients show depressive symptoms, and one-third of these individuals are even at risk for depressive disorders. Therefore, depressive symptom screening and proper psychotherapy in MRKH patients are of great importance.

ES28-0013 - P048

E-Poster

Laparoscopic sacrohysteropexy modification with polyester fiber strip suture: a meshless procedure with second-year outcomes

Adnan Orhan¹, Kemal Ozerkan¹, Isil Kasapoglu¹, Gurkan Uncu¹

¹Uludag University,

Department of Obstetrics and Gynecology- Division of Urogynecology and Pelvic Reconstructive Surgery, Bursa, Turkey

Background

Laparoscopic sacrohysteropexy is one of the gold standard operations in pelvic organ prolapse. However, in recent years a growing mesh debate has become a threat to every procedure using mesh in urogynecology. For instance, the Food and Drug Administration (FDA) went into extensive restrictions on vaginal mesh applications in 2013. While in 2018, National Health Services (NHS) announced that all vaginal mesh applications for pelvic organ prolapse and mid-urethral sling operations for stress urinary incontinence were paused entirely. This study aims to describe and review a new modification of laparoscopic sacrohysteropexy and report the two-year outcomes of the procedure.

Methods

A prospective surgical pilot study enrolling patients who were diagnosed as stage ≥ 2 apical pelvic organ prolapse was conducted to evaluate this laparoscopic sacrohysteropexy modification as a surgical treatment for pelvic organ prolapse from May 2016 to October 2018 in Bursa Uludag University Hospital, Turkey. The primary outcome was the anatomic success of the repair, with success defined as objective parameters using the pelvic organ prolapse quantification (POP-Q) system (Stage 0 or 1). Secondary outcomes were subjective outcomes which were assessed by the quality of life scales such as Pelvic Floor Distress Inventory short Form (PFDI-20) and Pelvic Floor Impact Questionnaire short form 7 (PFIQ-7). Our Institutional review board approval was obtained for a prospective surgical study of this laparoscopic sacrohysteropexy modification (UU/SUAM-IRB-2013-13/11). A video containing the details of the procedure will be shown during the presentation.

Results

Thirty-seven women who were recruited and consented to the procedure followed up to two years. 34 of 37 patients had stage 0 or 1 prolapse at the end of the second year according to the primary outcomes. The anatomical success rate was 91.8%. In secondary outcomes, two patients were not satisfied with their pelvic floor after the second year. The subjective cure rate was 94.5%. There was a statistically significant improvement in both POP-Q scores and quality of life scores in the postoperative second year. Mean operating time was 84.6 minutes and mean estimated blood loss was 21.3 milliliters. There were no suture exposure, bladder or bowel complications in the postoperative follow-up.

Conclusions

We have shown that laparoscopic sacrohysteropexy can be performed safely and efficiently with a different modification in apical pelvic organ prolapse. With the introduction of this modification, a urogynecologist can perform the laparoscopic sacrohysteropexy procedure in a reasonable operation time avoiding mesh complications. Although we have only successful second-year outcomes, we will be able to prove the effectiveness and reliability of this new technique with further research in the future.

<https://esge.covr.be/cmdocumentmanagement/conferencemanager/documents/api/getdocument/4970/cmabstsms/000070000/eaaa135eb5f8f27dc0ae03848c5cd3151ccc927fe750b7e18145d59c72b4496b>

ES28-0144 - P049 E-Poster

The impact of haptic feedback instruments in relation to visual feedback in recognition of tissue

Vleugels Michael¹, Esther Spanjer², Dominique Clevers²

¹Hospital Clinica Benidorm, Gynaecology, Finestrat, Spain

²Demcon, Advanced Mechatronics, Enschede, The Netherlands

Background

Haptic feedback is viewed as a potential step forward in regaining accurate tissue identification and accurate control of applied forces during tissue manipulation in laparoscopy as well as in robotic surgery. The surgeon now has to rely mostly on visual feedback and experience to estimate the appropriate amount of grasping force. Through experience, visual information can be interpreted as haptic information. However, providing both visual and force feedback leads to better tissue characterization than only visual feedback or only force feedback. Earlier studies with haptic feedback instruments based on optical integrated technology (Optigrip) proved less applied force while manipulating tissue. A second force reflecting instrument with minimal internal friction has been developed for recognition of pulsations (Optitouch). Tissue recognition was tested for these two types of instruments in comparison to the conventional grasper.

Methods

Three studies were performed with three set ups; A: comparison of Optigrip with conventional graspers on biological cadaver specimens at the animal laboratory without visual feedback. (n=20) B: Optigrip compared to conventional graspers on non- biological materials with visual feedback; (n=20) C: Optigrip and Optitouch compared to conventional graspers on non- biological materials with visual and without visual feedback. (n=25). All studies were performed with surgeons, residents or medical students.

Results

Recognition of tissue was significantly better with the haptic feedback Instrument Optigrip compared to the conventional graspers in cadaver tissue without visual feedback (study a). In the non- biological materials with visual feedback (study b) the correct comparisons were not significantly better but the confidence levels of the given answers were higher and time to feel the differences was also shorter. Both differences were significant compared to the conventional grasper. In both studies, participants were residents or experienced surgeons. In the third study (c) the performance of the conventional grasper decreased significantly when there was no visual feedback while the Optigrip and the Optitouch performed equally well with and without visual feedback again the level of confidence was higher with both new devices. In this group also non- medical participants were included.

Conclusions

The conventional grasper, Optigrip® and Optitouch performed equally well on interpreting tissue consistency when visual feedback was present. Nevertheless the level of confidence of the surgeon in recognition of the tissue differences and the speed to recognise these differences was higher with the Optigrip. The performance of the grasper tool significantly decreases without visual feedback. Visual feedback is important for performance of the conventional tool, whereas for the Optigrip® and Optitouch removing visual feedback does not influence performance. This finding is important for the clinical practice since complicated laparoscopic procedures are often hampered by a limited view on delicate structures. Moreover, recognition of structures automatically reduces the applied forces as has been published earlier.

<https://esge.covr.be/cmdocumentmanagement/conferencemanager/documents/api/getdocument/4940/cmabstms/000070450/c8315b2d0756d6e6a79dda042a2cdfc76c6ae550d9d35bb7e712407ae575c3f>

ES28-0033 - P050 E-Poster

Is hysteroscopy the best surgical approach for removal of retained products of conception following surgical termination of pregnancy?

Sergey Kostin¹, Zvi Vaknin¹, Tamar Tzur¹, Yoav Guilburd¹, Noam Smorgick¹

¹Assaf Harofeh Medical Center- Affiliated with Tel-Aviv University, Obstetrics and Gynecology, Beer Yacov, Israel

Background

Retained products of conception (RPOC) may occur following surgical termination of pregnancy. Previously, removal of RPOC by repeat curettage was associated with high rates of intrauterine adhesions. We investigated the rates of intrauterine adhesions following hysteroscopy for removal of RPOC in these cases.

Methods

A retrospective review of all cases of RPOC following surgical termination of pregnancy removed by hysteroscopy from 1/2013 to 12/2018. The rates of postoperative intrauterine were assessed by office hysteroscopy.

Results

85 cases of RPOC following surgical termination of pregnancy removed by hysteroscopy were identified. Of those, 46 (54.1%) RPOC cases were diagnosed following curettage for induced abortion, and 39 (45.9%) occurred following curettage for missed abortion. The mean RPOC size of hysteroscopy was 1.9 ± 0.9 cm and the mean from the curettage from the hysteroscopy was 1.4 ± 0.8 months. All hysteroscopy procedures were completed without intra-operative complications, while one patient (1.2%) was re-admitted for post-operative fever. Post-operative office hysteroscopy follow-up was available for 47 (55.3%) cases. Of those, a normal uterine cavity was observed in 45 (95.7%), while 2 (4.3%) patients were diagnosed with mild intrauterine adhesions.

Conclusions

Hysteroscopy for removal of RPOC following surgical termination of pregnancy is associated with low rates of post-operative intrauterine adhesions compared with repeat curettage.

<https://esge.covr.be/cmdocumentmanagement/conferencemanager/documents/api/getdocument/5212/cmabstms/000155600/9eb06e51908bd51a925b14a80371d7908a4e1403edcae7d1d7acb74b96450a14>

ES28-0036 - P051

E-Poster

Surgical skills improvement using a specific laparoscopic colposacropexy simulator

Blanca Fernández-Tomé¹, Belén Moreno- Naranjo¹, Idoia Díaz-Güemes Martín- Portugués¹, Enciso-Sanz Silvia¹, Luis López-Fandó², Sánchez-Margallo Francisco Miguel³

¹Centro de cirugía de Mínima Invasión Jesús Usón., Laparoscopy, Cáceres, Spain

²Hospital Universitario Ramón y Cajal, Unidad de Patología Vesical Funcional y Oncológica, Madrid, Spain

³Centro de cirugía de Mínima Invasión Jesús Usón, Director, Cáceres, Spain

Background

Vaginal-vault prolapse is effectively treated using laparoscopic sacrocolpopexy (LSCP). This technique initially requires a high level of psychomotor skills on the part of the surgeon to decrease this time, suture training can be implemented ahead using simulators.

The aim is to demonstrate if simulator training reduces the surgical times and improves the suturing performance of mesh fixation in sheep model practice.

Methods

In this study participated 16 experienced gynecologists in performing laparoscopic intracorporeal suturing. The specialists were divided into two groups. Group 1 carried out 10 single stitches in a horizontal incision in the simulator. Group 2 perform 5 single stitches in a horizontal incision and 3 specific stitches in LSCP pelvic simulator. In this simulator, they have done the most difficult stitches to fix the mesh: 2 stitches, one for each *levator ani* muscles and 1 stitch for the *sacrospinous ligament*. Afterward, in the sheep model, the assistants place the mesh and the stitches were timed and evaluated with a checklist.

Results

Regarding results, the times obtained in the right *levator anis* stitch were G1: 7.61 ± 1.44 minutes and G2: 4.23 ± 1.04 minutes, observing statistically significant differences. In the left *levator anis* stitches were G1: 5.61 ± 2.03 minutes and G2: 4.23 ± 4.04 minutes, without significant differences. On the other hand, the *sacrospinous ligament stitch* not presented statistically significant differences. As for checklist results, only the right *elevator anis* stitch in G1 present statistically significant differences respect to G2 (G1:27 vs G2:23).

Conclusions

In conclusion, the training with LSCP specific simulator reduces surgical times and improves the quality of knotting in the realization of the first point of mesh fixation.

<https://esge.covr.be/cmdocumentmanagement/conferencemanager/documents/api/getdocument/4942/cmabstsms/000048170/a5d88664d359d5d29dd90917061467cf968065296e662dd011e6d4d54fa71078>

ES28-0038 - P052

E-Poster

Clinical analysis and experience of 156 cases of hysteroscopic transcervical resection of septum

Limin Feng¹

¹Beijing Tiantan Hospital, Obstetrics & Gynaecology, Beijing, China

Background

To investigate and analyze the prevention of perioperative and long-term complications and reproductive prognosis of transcervical resection of septum (TCRS) .

Methods

We collected 156 patients with septate uterus in Beijing Tiantan Hospital affiliated to Capital Medical University from January 2011 to December 2016. All of the patients were followed up for 1 to 6 years. Preoperative and postoperative pregnancy outcomes and obstetric outcomes, predictive factors of residual septum were analyzed.

Results

1. There was no significant difference in the length and width of uterine septum and residual septum. There were 10 cases with residual septum length of 0.3-0.8 cm, no second resection, 1 case without pregnancy and 9 cases were all pregnant to full-term delivery.
2. Preventive excision of uterine septum was performed in 25 patients with fertility requirements. 22 cases (88.0%) were pregnant after operation. Among them, 16 cases (64.0%) delivered and 6 cases (24.08%) had abortion. There was a significant difference between preoperative abortion rate and live birth rate ($P < 0.05$).
3. No uterine perforation, bleeding and transurethral resection of the prostate (TURP) syndrome occurred during the operation. No uterine rupture occurred after operation. 5 cases (3.2%) had intrauterine adhesions, all of which were slight adhesions.
4. After TCRS, the rate of infertility, spontaneous abortion and missed abortion decreased from 19.1%, 19.8%, and 26.0% before surgery to 5.3%, 8.4%, and 6.1%, respectively, while full-term delivery rate and live birth rate were 1.5% before surgery 2.3% rose to 49.6%, 54.2%, the difference was statistically significant before and after surgery ($P < 0.05$).

Conclusions

1. All patients with TCRS need second hysteroscopic examinations 2 months after operation to evaluate the condition of uterine cavity.
2. Preventive excision of uterine septum is recommended for patients with fertility requirements diagnosed as uterine septum.
3. Pregnancy after TCRS is a high-risk pregnancy, which has the risk of uterine rupture during pregnancy and requires close follow-up.
4. Oral estrogen and progesterone artificial cycle therapy is not needed to prevent intrauterine adhesions after TCRS.
5. TCRS is minimally invasive, safe and effective, and can significantly improve the pregnancy outcome.

<https://esge.covr.be/cmdocumentmanagement/conferencemanager/documents/api/getdocument/5019/cmabstms/000058260/3d0d7b300ccaec40c5433ddf3f2ac78fe40ec31c016a235e6d5be7cdb62b4da6>

ES28-0037 - P053

E-Poster

Factors in the information of cesarean scar defect

*Limin Feng*¹

¹Beijing Tiantan Hospital, Obstetrics & Gynaecology, Beijing, China

Background

The objective of this study was to evaluate the prevalence of cesarean scar defect. Through the continuous observation of the uterine incision caused by the previous cesarean section during the pregnancy based on the ultrasound and that in the second-time cesarean section, the review of medical history and the comparison of obstetric outcomes, this study aimed to analyze the necessity of surgical intervention for the cesarean scar defect.

Methods

A total of 203 patients in our hospital who underwent cesarean section for the second time from February 2016 to December 2018, were selected for the current study. The scar healing of cesarean incision, intraoperative adhesions and bleeding were observed. All patients underwent ultrasound examination for the thickness and continuity of the muscle of lower uterine segment during third trimester. The previous cesarean section was tracked to retrospectively analyze the clinical data so as to investigate the factors that lead to poor healing of the uterine incision. 116 patients

were observed by abdominal ultrasonography for the thickness and continuity of the incision during the whole pregnancy, including the first trimester (before 14 weeks), second trimester (20-24 weeks), third trimester (after 32 weeks).

Results

203 patients were divided into two groups based on the observation in cesarean section. Group I contained cases of well-healed incision (no thinning of the lower uterine segment or thinning of the lower uterine segment yet with no fetal hair and fetal fat seen in the naked eye); Group II contained cases of poorly-healed incision (thinning of the lower uterine segment or loss of muscular layer with fetal hair and fetal fat seen in the naked eye, incomplete uterine rupture and uterine rupture). There were 172 cases of well-healed incision and 31 cases of poorly-healed incision. In terms of the association between the healing of uterine incision with age, body mass index, times of undergoing cesarean section, premature rupture of membranes, anemia, prolonged labor, selective operation, etc., $P > 0.05$, indicating no significant correlation. In terms of pelvic adhesions and position of uterine, $P < 0.01$, indicating that the difference was statistically significant. Poor healing of uterine incision has association with pelvic adhesions and position of uterine. There was no abnormal uterine hemorrhage in 203 patients.

Conclusions

The risk for cesarean scar defect increases for patients with uterus retroposition and severe pelvic adhesions. The healing of incision could be better observed through ultrasound in the second and third trimester. The ultrasound in the third trimester revealed that the thickness of the incision was 0.97 ± 0.46 mm. None of the pregnant women with poor healing incision without surgical intervention, had obstetric adverse outcomes.

<https://esge.covr.be/cmdocumentmanagement/conferencemanager/documents/api/getdocument/5020/cmabstsms/000058260/cfd1d46c206b92d512d79fc23f42cd0225b7c75309eb9ed7e2a93808aeac06e0>

ES28-0039 - P054 E-Poster

The INSPIRE comparative cost study: one-year medical resource utilization and payer cost analysis associated with hysterectomy and myomectomy compared to sonography-guided transcervical uterine fibroid ablation

Elizabeth Brooks¹, David Toub²

¹TTi Health Research & Economics, n/a, Westminster, USA

²Gynesonics, Medical Director, Wyncote, USA

Background

The INSPIRE study compared health care resource utilization (HCRU) and payor costs associated with transcervical radiofrequency (RF) ablation, hysterectomy, and myomectomy.

Methods

Premenopausal women between the ages of 25 and 50 with heavy menstrual bleeding secondary to fibroids treated prospectively with transcervical RF ablation using the Sonata® system at 6 clinical sites in the United States. Matched hysterectomy and myomectomy procedures of interest for uterine fibroids were derived from the Truven Health MarketScan Commercial Claims Database and identified using appropriate diagnostic and procedural codes.

Results

Mean total payor cost for treatment with Sonata and associated 12-month postoperative HCRU (\$8,941) were significantly lower than that for hysterectomy (\$24,156) or myomectomy (\$22,784). Furthermore, the mean payor cost for the 12-month postoperative HCRU associated with Sonata (\$143) was significantly lower than that associated with hysterectomy (\$699) or myomectomy (\$1,444). Finally, Sonata patients had lower costs associated with complications, prescription medication and radiology studies than either hysterectomy or myomectomy patients.

Conclusions

Transcervical RF ablation using the Sonata system is a lower-cost alternative to hysterectomy and myomectomy for the treatment of symptomatic uterine fibroids.

<https://esge.covr.be/cmdocumentmanagement/conferencemanager/documents/api/getdocument/4917/cmabstsms/000043420/28d339fc47feac321bb6b840b9c6cb0c15bf3cc6a3e919f5a1843cf7411fded4>

ES28-0041 - P055
E-Poster

Term delivery in an infertile patient after transcervical radiofrequency fibroid ablation and assisted reproductive technology

Gregor Pschadka¹, Matthias Engelhardt¹, Caroline Niehoff², David Toub³

¹*Josephs-Hospital Warendorf, Obstetrics and Gynecology, Warendorf, Germany*

²*MVZ Kinderwunsch-und Hormonzentrum Münster, n/a, Münster, Germany*

³*Gynesonics, Medical Director, Wyncote, USA*

Background

Transcervical radiofrequency ablation of uterine fibroids is an incisionless procedure to treat nonpedunculated uterine fibroids, including those that are not amenable to operative hysteroscopy. However, its safety and effectiveness regarding fertility and fecundity have not been established, including among women with infertility. This is a report of a pregnancy that occurred in a woman after transcervical radiofrequency (RF) ablation of uterine fibroids and assisted reproductive technology (ART).

Methods

A 38-year-old nullipara with infertility since 2008 and a recent complaint of refractory dysmenorrhea in association with a uterine fibroid underwent transcervical RF ablation with the Sonata® system to treat the symptomatic myoma. Unsuccessful ART (intracytoplasmic sperm injection/embryo transfer; ICSI/ET) as confirmed by negative pregnancy testing had been attempted 1 month pre-ablation and a second embryo transfer after thawing of the previously cryopreserved pronuclei was carried out 7 months post-ablation.

Results

Transcervical RF ablation resulted in a 68% reduction in fibroid volume by sonography at 2 months post-treatment along with resolution of the patient's dysmenorrhea and there was no residual fibroid noted on sonography at 7 months post-ablation. The second attempt at assisted reproduction produced an uncomplicated pregnancy that resulted in the vacuum-assisted vaginal delivery of a liveborn infant at term weighing 3670 gms with Apgar scores of 9/10/10. Pelvic sonography four months postpartum revealed an unremarkable uterus, again with no evidence of a fibroid remnant.

Conclusions

This is the first report of a pregnancy and delivery in an infertile couple who underwent transcervical RF ablation of a uterine fibroid followed by ART.

<https://esge.covr.be/cmdocumentmanagement/conferencemanager/documents/api/getdocument/4918/cmabstms/000043420/d604b395c0c1850337acb3afdb380bfffce260ba347f3d3edd2c630fa159f3527>

ES28-0042 - P056
E-Poster

Transcervical radiofrequency ablation of symptomatic uterine fibroids: 2-year results of the SONATA pivotal trial

Charles Miller¹, Khadra Osman², Khaled Sakhel³, David Toub⁴

¹*The Advanced Gynecologic Surgical Institute, n/a, Schaumburg, USA*

²*Fort Lauderdale Women Care, n/a, Ft. Lauderdale, USA*

³*Inova Fairfax Hospital, Obstetrics and Gynecology, Falls Church, USA*

⁴*Gynesonics, Medical Director, Wyncote, USA*

Background

To report 2-year results of sonography-guided transcervical radiofrequency (RF) ablation using the Sonata® system in women with symptomatic uterine fibroids.

Methods

This was a prospective, multicenter, single-arm, interventional trial in premenopausal women with up to 10 clinically relevant uterine fibroids, each ranging from 1 to 5 cm in diameter. Treatment was provided at 22 clinical sites (21 in the US and 1 in Mexico). Patients were treated on an outpatient basis and returned for regular follow-up visits over 2 years. Assessed outcomes included changes in symptom severity, health-related quality of life, general health status, work and activity limitations, treatment satisfaction, adverse events, surgical reintervention and occurrence of pregnancy and associated outcomes.

Results

Among 147 enrolled women, 125 (85%) returned for follow-up at 2 years. Compared to baseline, symptom severity decreased from 55 ± 19 to 23 ± 19 ($p<0.001$), health-related quality of life increased from 40 ± 21 to 83 ± 19 ($p<0.001$) and EQ-5D scores increased from 0.72 ± 0.21 to 0.89 ± 0.14 ($p<0.001$). Overall treatment satisfaction at 2 years was 94%. The mean percentage of missed work time, overall work impairment and activity impairment significantly decreased at follow-up. Through 2 years, surgical reintervention for heavy menstrual bleeding was performed in 5.6% of patients. One singleton pregnancy occurred with a normal peripartum outcome.

Conclusions

Treatment with the Sonata system provides significant clinical improvement through 2 years post-ablation, with a low incidence of surgical reintervention. Other favorable outcomes included a rapid return to work and substantial improvements in quality of life, symptom severity, work productivity and activity levels.

<https://esge.covr.be/cmdocumentmanagement/conferencemanager/documents/api/getdocument/4919/cmabstms/000047070/449f7adbd422c13e362963276e8c690b497973341e5c8e6723954cd2388f1341>

ES28-0085 - P057

E-Poster

Complications following surgery for rectovaginal endometriosis – experience in a UK endometriosis centre

Dimitrios Miligkos¹, Monisha Dhar², Matthew Dipper¹, Paul Nichols³, Adam Moors¹

¹Southampton University Hospitals NHS Trust, Obstetrics and Gynaecology, Southampton, United Kingdom

²University of Southampton, School of Medicine, Southampton, United Kingdom

³Southampton University Hospitals NHS Trust, General Surgery, Southampton, United Kingdom

Background

Endometriosis affects 10% of women of reproductive age. Deep infiltrative endometriosis (DIE) affects 20% of women with endometriosis of which 5-12% will have bowel involvement. Laparoscopic excision is the treatment of choice for symptomatic DIE with bowel involvement. A multidisciplinary team of endometriosis specialist gynaecologists and colorectal surgeons is recommended to optimise clinical outcomes and reduce complications and surgical morbidity. The aim of this study was to evaluate the complication rate following surgery for rectovaginal endometriosis in Princess Anne Hospital (PAH), Southampton and compare this to national and international standards.

Methods

All women who underwent laparoscopic excision of rectovaginal endometriosis between January 2013 and August 2018 in PAH were included in the study. Demographic and surgical data as well as intra/post-operative complications were collected from electronic patient records. Post operative complications were recorded using the Clavien-Dindo classification system. Basic descriptive techniques were used for statistical analysis.

Results

A total of 69 women were operated during the study period with a median age of 39 years (range 20,52). All women had bowel involvement and needed dissection of the pararectal spaces to complete the procedure. Two patients underwent bowel resection. Laparoscopic surgery was performed in 65 women (94%); two (3%) women underwent laparotomy and two (3%) had conversion from laparoscopy to laparotomy, one for transverse colon perforation during entry and one due to severe pelvic adhesions.

Four (5.8%) patients sustained major complications classified as grade IIIb. Two developed post-operative pelvic haematomas needing surgical drainage, one had bowel leak and rectovaginal fistula and one vesicovaginal fistula.

Conclusions

Our results support that this challenging area of surgery can be carried out with low rate of major complications. Our results are comparable to national standards and the literature. Reporting individual centre clinical outcomes can facilitate patient counselling and the decision making for complex endometriosis surgery.

<https://esge.covr.be/cmdocumentmanagement/conferencemanager/documents/api/getdocument/4952/cmabstsms/000006890/da9a446fcfa0f12120c7765d69f9b20e730360338c34ab46a79399997d246>

ES28-0044 - P058

E-Poster

The effect of estrogen on the coagulation and ovarian function in intrauterine adhesions

*Limin Feng*¹

¹*Beijing Tiantan Hospital, Obstetrics & Gynaecology, Beijing, China*

Background

To study the safety of estrogen in the treatment of intrauterine adhesions.

Methods

Patients were treated with intrauterine adhesions at Beijing Tiantan Hospital, Capital Medical University from July 2016 to August 2018 were recruited. Estrogen combined with progesterone, aspirin, vitamin C, vitamin E and Kirin pills were used in these people. Before and after drug treatment, some blood test include biochemistry, coagulation, platelet count, thrombophilia screening (antithrombin III, protein S activity, protein C) and anti-Mullerian hormone (AMH) were measured respectively, and select the corresponding control group. The data obtained using SPSS23 statistical software for data processing and analysis. Serum progesterone levels on days 20-23 of menstruation were followed up in patients who returned to normal uterine morphology and menstrual pattern after hysteroscopy. After the follow-up medication, the patient developed general adverse reactions such as nausea, vomiting and breast tenderness.

Results

1. A total of 115 patients were enrolled, after 2 months of treatment, we find that the partially activated prothrombin time (APTT) was declined, from 31.10 ± 4.24 to 30.30 ± 4.43 . The paired t-test was performed and the results were statistically significant ($p < 0.05$). The remaining indicators were not statistically significant ($p > 0.05$); There were 40 cases used drugs treatment till four months and there was no statistically significant difference between before and after ($p < 0.05$).

2. We divided 115 patients in groups with supplemental doses, there are 45 patients used 6 mg estrogen and 59 cases use 8mg instead, the others use 4mg. There were no significant differences in liver and kidney function, coagulation and platelet counts between the two groups. ($p > 0.05$). Compared with the 6mg group, we found the Fbg value decreased in the 8mg group (2.39 ± 0.53 , $p < 0.05$); prothrombin time (TT) prolongation (17.27 ± 1.83 , $p < 0.05$); alanine aminotransferase (ALT) increased (18.38 ± 8.85 , $p < 0.05$) These three indicators were statistically significant, and the remaining indicators were not statistically significant.

Conclusions

1. Patients with intrauterine adhesions have elevated coagulation parameters after estrogen treatment, but all are within the normal range, and there is no change in liver and kidney function after administration.

2. Compared with 6mg group, we found that 8 mg estrogen group fibrinogen decreased and liver function increased but there was no thrombosis and severe liver function damage cases in clinical.

3. Some patients have general adverse reactions such as nausea after medication and these were all grade 1 adverse reactions according to CTCAE grade and with the prolongation of medication time, reduced the dose of estrogen or stopped the drug, these adverse reactions were disappeared.

4. Patients with intrauterine adhesions have lower AMH levels than normal people, and AMH levels have decreased after administration but no statistical significance and does not affect ovulation after administration. However, there still needs to expand the sample size and follow up the corresponding pregnancy outcome.

<https://esge.covr.be/cmdocumentmanagement/conferencemanager/documents/api/getdocument/5021/cmabstsms/00058260/608a54afc8cec31645321367d32773c93c3e56f4b90797de2d80b55ddec4b8b2>

ES28-0055 - P059
E-Poster

Comparative study between robotic laparoscopic myomectomy and abdominal myomectomy: clinical evaluation and the cost analysis

Magdi Hanafi¹

¹*Gyn & Fertility Specialists- Emory St. Joseph's Hospital- Emory University, Gynecology, Atlanta, USA*

Background

To compare postoperative clinical outcomes and cost of Abdominal (AM) and Robotic Laparoscopic (RLM) Myomectomy.

Methods

Retrospective, single-center study. Surgeries were performed by the author at Emory Saint Joseph's Hospital. All myomectomies performed during the study period were symptomatic ultrasound confirmed Leiomyoma patients. The cases were grouped into Abdominal Myomectomy (AM) and Robotic Laparoscopic Myomectomy (RLM). 419 cases of RLM and 65 cases of AM were identified from January 1st, 2009 to December 31st, 2017. Personal and clinical data were collected from EMR. All patients were administered post-operative questionnaire (297/484 completed, 61.4%). All Statistical analyses were performed using *JMP 13.1.0* software (SAS Institute, Cary NC).

Results

A total of 484 cases were analyzed. Study compared total operative time, total estimated blood loss (EBL), length of hospital stay and cost of procedure as well as post operative outcomes including pain level, days of analgesic use, days until self-care, weeks until return to work, days until first post-operative bowel movement and weeks until resuming sexual intercourse. No significant difference between the AM and RLM regarding age, BMI, gravidity, parity, operative time and hospital charges was observed. AM had significantly longer hospital stay (2.3 days Vs 1.4 days) and significantly higher EBL (178.5 mL Vs 105.9 mL) than RLM. Post-operative pain level and days of analgesic use were lower in RLM than in AM, but not significant. RLM had significantly fewer number of weeks to return to work (4.2 weeks Vs 5.7 weeks), significantly fewer number of weeks until resuming sexual activity (7.1 weeks Vs 11.2 weeks) and significantly fewer days until independent self-care (7.7 days Vs 10.4 days) than AM. AM had significantly greater number of days until first bowel movement after surgery (5.2 days Vs 2.7 days) than RLM. Mean aggregate weight of myoma removed in AM group was significantly higher than RLM.

Conclusions

RLM has advantages clinically and technically over AM. AM is considered a more involved operation and is associated with higher morbidity, blood loss and adhesion formation rates. RLM provides surgeons with improved optics, three dimensional view and increased dexterity and precision. This facilitates excision of tumors and repair of uterine incisions. In some cases, AM is the only practical option technically to perform myomectomy, for example when dealing with very large fibroid tumors, extensive pelvic and/or abdominal endometriosis, severe pelvic/abdominal bowel adhesions and very short stature patients. In these cases, use of laparoscopy increases the risk of injury to vital pelvic and abdominal organs. Cost is higher in AM than in RLM but not significant.

<https://esge.covr.be/cmdocumentmanagement/conferencemanager/documents/api/getdocument/4922/cmabstms/000042360/8cc93f95a91d4f0a5898651e16132f0bab13583ed69864078ad378569b39e330>

ES28-0053 - P060
E-Poster

Delivery outcome in the third trimester after hysteroscopic adhesiolysis

Dabao Xu¹, Bingsi Gao¹, Qing Feng¹, Xiaoming Guan²

¹*The Xiangya Hospital of Central South University, Gynecology, Changsha City, China*

²*Baylor College, Department of Obstetrics and Gynecology, Houston, USA*

Background

Intrauterine adhesions (IUA), is caused by adhesion of the uterine cavity due to damage of endometrium. The factors of it including surgical abortion, cesarean section, uterine myomectomy, hysteroscopic resection of endometrial polyps (HREP), intrauterine contraceptive device (IUD) placing or delivery, endometrial tuberculosis, uterine artery ligation or

embolization and pelvic radiotherapy. IUA patients may have a low pregnancy rate in receiving assisted reproduction (ARTs). During the last two decades, the advent of hysteroscopy has revolutionized the diagnosis and management of IUA. The latest reports have recorded pregnancy status after transcervical resection of adhesion (TCRA) to be 79.0% in women wishing to conceive and the chance of live birth is 63.7%. Several studies have been carried out to evaluate reproductive outcome in cases after hysteroscopic adhesiolysis (HA). Although HA is considered reasonably safe, its effects on obstetrical outcomes remain uncertain. Previous studies primarily focused on pregnancy status in patients with HA, including pregnancy rates, abortion rates and gestational time. However, its case number was relatively small. Therefore, it's significant to investigate the delivery outcome of women in the third trimester who previously underwent HA.

Methods

A total of 254 women with a positive and negative history of HA before pregnancy and delivery in the third trimester from May 2011 to May 2018 in the department of gynecology and obstetrics of the Third Xiangya Hospital of Central South University were enrolled. Demographic characteristics, obstetrics parameters and the parameters of infant parameters were investigated to evaluate the history of HA and its effects on the third trimester delivery outcomes.

Results

There was neither significant difference between the Study and Control Groups in delivery gestational age (38.71 ± 2.3 weeks versus 38.71 ± 3.0 weeks), nor in birth outcomes of the newborn ($P > 0.05$). However, the cesarean section rate in the study group was significantly higher than that of the control group (60.0% versus 44.1%, $P < 0.05$). In addition, when compared to the control group, women who had a history of HA had a higher risk of placental problems ($P < 0.05$), such as placenta previa (11.8% versus 3.2%), difficulty in placental separation (43.3% versus 8.7%), placenta implantation (20.5 % versus 0%), placental adhesion (26.0% versus 3.1%) and placental residue (6.3% versus 3.9%). The women who had a history of HA may undergo additional postpartum curettage (51.2% versus 4.7%, $P < 0.05$) when compared with the control group, accompanied by additional postpartum hemorrhage (11% versus 0.8%, $P < 0.05$). Such cases were more likely to be found in patients with severe intrauterine adhesion compared with those with mild to moderate adhesions ($P < 0.05$).

Conclusions

The history of HA might be an important risk factor inducing placental problems and postpartum hemorrhage in the third trimester. More attention should be paid to the labor of pregnant women with a history of HA.

<https://esge.covr.be/cmdocumentmanagement/conferencemanager/documents/api/getdocument/5300/cmabstsms/000150850/bc70935272fb330d9118bf8f8161caacca7b50e69593f69d9303cd436f5cb41d>

ES28-0084 - P061

E-Poster

Ultrasound imaging of deep infiltrative endometriosis: looking beyond the tip of the iceberg

Dimitrios Miliqkos¹, Susanne Johnson², Sameer Umranikar², Natalia Rosello², Adam Moors²

¹Southampton University Hospitals NHS Trust, Obstetrics and Gynaecology, Hampshire, United Kingdom

²Southampton University Hospitals NHS Trust, Obstetrics and Gynaecology, Southampton, United Kingdom

Background

Twenty percent of women with endometriosis have deep infiltrative disease (DIE), with bowel involvement in more than half of them. Evaluation of the extent of DIE is essential in planning definitive surgery and counselling the patient. Diagnostic laparoscopy is not always helpful as the true extent of DIE can only be appreciated after dissection of the affected structures. Transvaginal ultrasound has been shown to be an accurate non-invasive test for the detection of DIE. We present the ultrasound features of different locations of DIE using IDEA (International Deep Endometriosis Analysis group) terminology and the correlation of these with the associated surgical findings.

Methods

A systematic sonographic pelvic survey is described, assessing the anterior compartment, the uterus, the lateral compartment and the posterior compartment. Cases of DIE are presented with the relevant videos of the USS examination and the associated surgical videos/images.

Results

The correlation between USS and surgical findings is demonstrated.

Conclusions

Transvaginal ultrasound is a non-invasive diagnostic tool with good accuracy on the pre-operative detection of DIE. It can assist in the pre-operative planning of surgery with the appropriate surgical team and facilitate patient counselling on the extent of the operation needed.

<https://esge.covr.be/cmdocumentmanagement/conferencemanager/documents/api/getdocument/5029/cmabstms/000006890/1d17fbfb1e534b0d45fe4098c423abcc3bff11793193d603da6ccdd38079d355>

ES28-0062 - P062

E-Poster

Laparoscopic combined hysteroscopic management of cesarean scar pregnancy with temporary occlusion of bilateral internal iliac arteries: a retrospective cohort study

Wenzhi Xu¹

*¹Sir Run Run Shaw Hospital- School of Medicine- Zhejiang University,
Assisted Reproduction Unit- Department of Obstetrics and Gynecology, Hangzhou, China*

Background

To report on our experience of surgery of cesarean scar pregnancy with temporary occlusion of the bilateral internal iliac arteries.

Methods

Single center, retrospective review of patients who were diagnosed as cesarean scar pregnancy between December 2017 and December 2018. All patients were managed by laparoscopic cornuostomy and simultaneously repair the defect with temporary occlusion of the bilateral internal iliac arteries, followed by hysteroscopy to confirm no remnants of the pregnancy and deal with intrauterine lesions synchronously.

Results

5 patients were enrolled, the vital signs of all the patients were stable. All 5 patients were managed by laparoscopic cornuostomy and simultaneously repair the defect with temporary occlusion of the bilateral internal iliac arteries, followed by hysteroscopy to confirm no remnants of the pregnancy and 3 patients free intrauterine adhesions synchronously. No one was converted to laparotomy. Intra-operative bleeding was minimal and the postoperative recoveries were uneventful. Human chorionic gonadotropin was normalized after 3-4 weeks.

Conclusions

Laparoscopy with temporary internal iliac artery occlusion technique offers effective surgical management of cesarean scar pregnancy, and hysteroscopy is necessary to deal with intrauterine lesions.

<https://esge.covr.be/cmdocumentmanagement/conferencemanager/documents/api/getdocument/4957/cmabstms/000164650/0600274b9266ab3c1ef31a54e270dcf7d72292e244ac0d7aad7f3b16b4936af4>

ES28-0065 - P063
E-Poster

Combination of non-invasive methods in diagnosis of infertile women with minimal or mild endometriosis

Xiaona Lin¹, Huaying Yu¹

¹*Sir Run Run Shaw Hospital- Medical School- Zhejiang University, Reproductive Medicine Center, Hangzhou, China*

Background

Endometriosis has been proved to be closely related to female infertility, while the optimal means of accurately diagnosing in a timely manner is controversial. The present non-invasive methods have limited capacity to diagnose superficial peritoneal disease and endometriosis-associated adhesions, so that these patients are often classified as unexplained infertility and referred to IVF. The aim of this study was to investigate a combination of non-invasive methods in diagnosis of infertile women with minimal or mild endometriosis expecting to narrow down the range of laparoscopic exploration for female infertility.

Methods

Totally 447 patients who were regarded as unexplained infertility before surgery were eligible for this study between May 2012 and February 2017. Of these, 299 patients had laparoscopy-proven minimal or mild endometriosis, whereas the remaining 148 served as a control group (normal pelvis). Preoperative age, duration of infertility, type of infertility, body mass index, baseline follicle-stimulating hormone, anti-Müllerian hormone, serum CA₁₂₅, clinical symptoms and findings on vagino-recto-abdominal examinations had been recorded. Each of these variables and their combinations were assessed to identify diagnostic indicators.

Results

The cutoff value for CA₁₂₅ was 19.25 IU/L. Any single variable had limited diagnostic value. Parallel testing had a higher sensitivity at 81.3%. Serial tests of vagino-recto-abdominal examination combined with dysmenorrhea or positive CA₁₂₅ got reasonable sensitivity (51.4% and 49%), remarkable high specificities (95.7% and 100%) and Positive Predictive Value (96.4% and 100%). Stepwise forward logistic regression identified the following variables in decreasing order of importance: (1) vagino-recto-abdominal examinations, (2) CA₁₂₅, (3) dysmenorrhea.

Conclusions

A combination of non-invasive methods may improve accuracy of diagnosis of infertile women with minimal or mild endometriosis and narrow down the range of laparoscopic exploration for female infertility, especially the vagino-recto-abdominal examination plus dysmenorrhea symptom or elevated CA₁₂₅. A cut off value for CA₁₂₅ (19.25 IU/L) has a higher sensitivity than the usual one (35 IU/L).

<https://esge.covr.be/cmdocumentmanagement/conferencemanager/documents/api/getdocument/4960/cmabstsms/000066630/67cc0c96e744a01ce5e320ccea1b9206c8a384e6b0a5fae7e90cb8e52faf6294>

ES28-0066 - P064
E-Poster

High levels of serum Ante Müllerian Hormone (AMH) in Polycystic Ovarian Syndrome (PCOS) patients have a high risk of having Uterine Anomalies (uterine septum/subseptate /arcuate uterus)

Amogh Chimote¹, Rajendra Sankpa², Riju Chimote³, Nishad Chimote⁴

¹*Vaunshdhara Fertility Centre pvt.ltd, Gynaecological Endoscopy, Nagpur, India*

²*SAGE Hospital, Gynaecological Endoscopy, Mumbai, India*

³*Vaunshdhara Fertility Centre pvt.ltd, Reproductive Medicine, Nagpur, India*

⁴*Vaunshdhara Fertility Centre pvt. Ltd., Clinical Embryology, Nagpur, India*

Background

The incidence of congenital uterine anomalies in the general female population is ~5 per 1000 and that is more frequent in infertile women (35–63/1000). No AMH is expressed during foetal development in females, where the paramesonephric or Müllerian duct grows into the oviducts, uterus, cervix, and the upper 75% of the vagina. AMH is produced at low levels in ovarian granulosa cells during the perinatal period through menopause. Serum AMH levels in adult females are normally <3.5 ng/ml and decrease over time. However serum AMH levels in women having uterine malformations have not been previously determined.

Methods

Study design:

A Retrospective study of infertile women (n = 174) with primary and secondary infertility were evaluated for their association of serum AMH levels with uterine anomalies. The study was conducted between August 2016 to December 2017 at our private endoscopic unit.

Participants, material, methods: fasting samples of all the 174 participants were collected on day 3 of the menstrual cycle for estimation of serum AMH level and subsequently subjected to transvaginal ultrasound. Patients were divided into three groups depending on AMH levels (ng/ml) as, low (<2.73) moderate (2.74- 6.00) and High (>6.00) and labelled PCOS according to Rotterdam criteria and AMH levels. All patients were subjected to hysteroscopy to assess the uterine cavity for Mullerian anomalies .

Results

Day 3 serum AMH levels in all 174 patients (range : 0.81-14.6 ng/ml) with infertility (mean age 31.28 ± 4.2 yrs.),& divided into primary(n = 106) and secondary(n= 68) infertility(1-2 early trimester pregnancy loss) categories

Both categories were divided into group (A) Low (non PCOS), (B) Moderate(PCOS) and (C) High AMH levels (PCOS) subgroups. Patients in primary infertility in group A and B had a low incidence of uterine anomalies (18/26 & 14/26). Contingency analysis for abnormal cavity Fischer exact test p value: 0.149 & 0.812, odd's ratio 2.25 & 1.167, Positive predictive value (PPV) 69.23% & 53.58 % respectively. Group C showed a high incidence of diagnosis of Uterine anomalies (46/50). Fischer exact test p value <0.0001 & odd's ratio 11.5, ,sensitivity 47.9 % , Specificity 92.6 % , PPV 92% .

Secondary Infertility patients in group A & B also showed a low incidence of uterine anomaly (13/17 & 20/28) Fischer exact test p value 0.0815 & 0.067, odds ratio 3.25 & 2.5,PPV 25.5 % & 28% respectively. While group C Showed a high incidence(22/24) of uterine anomalies Fischer Exact test p value 0.0005, odds ratio 0.09, sensitivity 47% specificity 92.3 % , PPV 91.6 %.

Conclusions

A serum AMH levels of > 6 ng/ml in both the primary as well as secondary infertility with PCOS has a higher specificity for uterine anomaly i.e either a septate/ sub-septate or an arcuate uterus

<https://esge.covr.be/cmdocumentmanagement/conferencemanager/documents/api/getdocument/5098/cmabstms/0000164670/15e324ce9b1b2e38f67982dbef185e4e098d703616104d96ee67de589f6ca6db>

ES28-0145 - P065

E-Poster

Detection of arterial pulsations and their smallest diameter compared between conventional grasper and two types of haptic feedback instruments

Michael Vleugels¹, Esther Spanjer², Clevers Dominique²

¹Hospital Clinica Benidorm, Gynaecology, Finestrat, Spain

²Demcon, Advanced Mechatronics, Enschede, The Netherlands

Background

During laparoscopic procedures, it is important to recognize arterial vessels which are critical during preparation of the underlying pathology. These arteries are situated outside the different body parts (e.g. muscles) or organs (e.g. liver). Haptic feedback is viewed as a potential step forward in regaining accurate tissue identification and detecting small arteries in laparoscopy as well as in robotic surgery. The surgeon now has to rely on visual feedback which is not always sufficient once arteries are hidden by fatty or pathological tissue. The Optigrip with real time haptic feedback, creating real touch, has proven to detect arterial pulsations in a clinical setting. A second force reflecting instrument with minimal internal friction has been developed for recognition of pulsations; the Optitouch. Sensitivity of each device to detect pulsations has been tested.

Methods

The effects of haptic feedback on the ability to detect arterial pulsations have been investigated in two models; a) the Optigrip, Optitouch and a conventional grasper were compared in an artificial artery setup with different artificial artery diameters. Participants were OR staff, medical students, residents and & surgeons (N=229); b) the Optigrip and Optitouch were tested in a POP simulator with a pulsating porcine model to compare. Participants were experienced surgeons (N=8).

Results

The results, depicted as correct answers (Friedman test) revealed that there were significant differences between the three tools ($p < 0.001$). Post hoc testing using the Wilcoxon signed rank test with Holm-Bonferroni correction demonstrated a significant difference between the Optigrip and conventional tool ($p < 0.001$) and between the Optitouch and conventional tool ($p < 0.001$). The conventional tool only scored 0.03% correct answers in pulsating arteries, showing that with this tool no pulsations can be felt.

The tube diameter in which a pulsation could be felt was smaller for the Optitouch compared to the Optigrip (Wilcoxon signed rank test: 2.0 mm vs. 2.8 mm; $p = 0.007$). In the simulation tests both felt pulsations in the renal artery; time to detect the artery did not differ. Evaluation of the usability by questionnaires indicated that the surgeons could feel the pulsations by both instruments but the direct feedback in the gripper of the Optigrip is more appreciated compared to the pulsating pin of the Optitouch.

Conclusions

Both the Optigrip and Optitouch can clearly feel pulsations, while the conventional tool cannot feel pulsations. The Optitouch is more sensitive to pulsations in smaller diameter tubes than the Optigrip. The Optitouch needs to be further optimized to decrease the number of false positives. The way of creating the feedback differs between both instruments which might result in different application areas.

<https://esge.covr.be/cmdocumentmanagement/conferencemanager/documents/api/getdocument/5146/cmabstms/000070450/1c2b5df6ff6eed166ee47a643116287256600b66d3fc618b20e83b838112657b>

ES28-0067 - P066

E-Poster

Myxoid degeneration of ovarian tumor in young patient. Laparoscopic approach

Chrisostomos Sofoudis¹, Evangelos Dedoulis², Konstantinos Zioris³

¹Konstandopoulou General Hospital Athens Greece, Department of Obstetrics and Gynecology, Athens, Greece

²Mitera Marenal Hospital, Obstetrics and Gynecology, Athens, Greece

³Mitera Maternal Hospital, Obstetrics and Gynecology, Athens, Greece

Background

Myxoid degeneration of ovarian tumors represent a rare distinctive benign ovarian stromal neoplasm that occurs predominantly in young women and is hormonally inactive. In many cases of recent bibliography, the pathogenesis remains controversial. Many studies express the strong belief of myxoid ovarian tumors with genetic abnormalities. Benign condition of the tumor consists the ultimate key of therapeutic strategy. This issue represents, especially in premenopausal patients, the gold standard. Tumor markers remain in normal range. Abdomen MRI, after the transvaginal ultrasound can differentiate and depict the imaging findings of the ovarian tumor.

Methods

Depiction, assiduous representation and proper diagnosis of such tumors especially in young patients. We present a case of 36-year-old patient, (para 3, gravida 3) with atomic history of three cesarean sections, complaining of episodes of abdominal pain the last three months. Pap smear free of malignancy. The transvaginal ultrasound revealed a well formed tumor at the anatomic region of right ovary. The tumor consisted of maximal diameter of 6 cm, slightly cystic degenerated. Tumor markers in normal range. Abdominal MRI confirmed the imaging findings of transvaginal ultrasound. With ultimate goal, the preservation of ovarian facilities, patient underwent laparoscopic approach. With insertion in the abdominal cavity, a well performed ovarian tumor of right ovary was diagnosed. During laparoscopic detachment of the tumor from the ovary, there was a small tumor abruption. In front of myxoid liquid abruption, a laparoscopic dissection of right adnexa was performed. The specimen was sent for frozen biopsy.

Histological result revealed an ovarian serous cystadenoma mixed structure and texture filled with cystic and mostly myxoid degeneration. Final histologic report confirmed the frozen biopsy. The patient discharged from the hospital the following day in good clinical condition.

Results

Myxoid degeneration of the ovary consists a rare entity, in premenopausal patients. Such tumors must be differentiated from other ovarian alterations. Ultimate goal remains as part of therapeutic mapping the preservation of ovarian facilities. These tumors originate from ovarian stroma with increased cellularity. In many studies the biological behavior remains controversial. In cases of extremely increased cellularity and proliferating index, there is always a moment of low grade malignant transformation.

Myxoid degenerated ovarian tumors can be malignant transformed into myxoid leiomyosarcomas of the ovary with extremely metastatic possibilities. Assiduous atomic history, proper laboratory and imaging findings consist the gold standard of therapeutic mapping especially in cases of premenopausal patients.

Conclusions

Myxoid degeneration as main component in serous ovarian cystadenomas describe benign condition carrying low proliferation index. Multidisciplinary approach is mandatory in order to achieve a proper diagnosis and treatment.

<https://esge.covr.be/cmdocumentmanagement/conferencemanager/documents/api/getdocument/5060/cmabstsms/000040750/8e40800541f7f19ef27041fa6599171ee5fa6cff668ed40b839cbea614bc1e71>

ES28-0069 - P068

E-Poster

Enlarged degenerated uterine fibroid in nulliparous young patient. Laparoscopic approach

Chrisostomos Sofoudis¹, Evangelos Dedoulis², Konstantinos Zioris²

¹*Konstandopoulio General Hospital Athens Greece, Department of Obstetrics and Gynecology, Athens, Greece*

²*Mitera Maternal Hospital, Obstetrics and Gynecology, Athens, Greece*

Background

The incidence of uterine fibroid tumors increases as women grow older and they may occur in more than 30 percent of women 40 to 60 years of age. Risk factors include nulliparity, obesity, family history, black race and hypertension. Many tumors are asymptomatic and may be diagnosed incidentally. Many studies have indicated the proper therapeutic mapping in cases of nulliparous young patients. Therapeutic strategy is strongly accompanied with age and fertility capacity of the patient. In cases of degenerated uterine fibroids in nulliparous patients, laparoscopic approach represents the gold standard of surgical confrontation.

Methods

29-year-old female patient (gravida 0, para 0) admitted at our department with episodes of abdominal pain and tenderness to palpation. Pap smear free for malignancy. Physical examination and transvaginal ultrasound revealed enlarged uterus followed with presence of intramural uterine fibroid maximal diameter 7cm. Abdominal MRI confirmed the imaging findings of transvaginal ultrasound. Remarkable finding consisted areas of cystic degeneration. Tumor markers revealed no sign of malignancy. Due to age and the nulliparity of the patient, considered as gold standard the laparoscopic approach. Patient underwent laparoscopic dissection of intramural uterine fibroid diameter almost 6 cm. filled with areas of cystic degeneration. Intraoperatively injection of pitressin solution inside the fibroid cavity was performed in order to decrease and minimize any operative bleeding. We must mention the difficulty of detachment of uterine fibroid intraoperatively. During the procedure clinical view and texture of fibroid simulated cystic degeneration. Final histological report confirmed all preoperative findings. Patient discharged from the hospital the following day in good clinical condition.

Results

Leiomyomas are the most common female reproductive tract tumors. They are probably of unicellular origin and their growth rate is influenced by estrogen, growth hormone and progesterone. They are more common with increasing age but shrink after the menopause; they occur in 30 per cent of women in their 30s and 50 per cent of women in their 40s. There are 5 different classifications of fibroids: intramural, subserosal, submucosal, intracavity and cervix fibroids. Therapeutic mapping depends on the size, number, anatomic location of the uterine fibroids, the clinical

symptomatology, the age and fertility capacity of the patient. In our case, respecting the nulliparity of the patient, we tried to underline the significance of laparoscopic approach. In many cases, bizarre fibroids can over the years transform into leiomyosarcoma with more aggressive approach and metastatic potential. In such cases there is a decrease of overall free survival and quality of life of the patient.

Conclusions

Degeneration of uterine fibroids consists a controversial clinical condition which requires an assiduous therapeutic strategy. Many studies must be conducted to establish proper therapeutic mapping especially in nulliparous patients. Multidisciplinary approach is mandatory in order to achieve an ultimate surgical confrontation.

<https://esge.covr.be/cmdocumentmanagement/conferencemanager/documents/api/getdocument/5062/cmabstsms/0000040750/a6e278c5f32de9ee15fabb7eb8331802d81d664559e03d4589dd8fd9b873817a>

ES28-0070 - P069

E-Poster

Subcutaneous emphysema complicating gynecologic laparoscopic procedures: therapeutic strategy

Chrisostomos Sofoudis¹, Konstantinos Manes², Milena Dinic³, Konstantinos Zioris⁴, Minas Paschopoulos⁵

¹Konstandopoulou General Hospital Athens Greece, Department of Obstetrics and Gynecology, Athens, Greece

²Konstandopoulou General Hospital, Department of Surgery, Athens, Greece

³Konstandopoulou General Hospital, Department of Anesthesiology, Athens, Greece

⁴Mitera Maternal Hospital, Department of Obstetrics and Gynecology, Athens, Greece

⁵University of Ioannina, Department of Obstetrics and Gynecology, Athens, Greece

Background

Safe gynecologic laparoscopic procedures are strongly related with iatrogenic experience and structured surgical equipment. Knowledge of the circumstances that increase the potential for subcutaneous emphysema are mandatory factors of secure surgical mapping.

Gas travel through laparoscopic procedures is essential factor during laparoscopic surgery. Many factors are similar to this intraoperative procedure.

Trocar installation and angle, incision, gas pressure, flow rate, gas volume, abdominal wall compliance and insufflator experience consist ultimate goals towards subcutaneous emphysema.

Methods

Presentation, depiction and proper diagnosis and treatment of such intraoperative procedures. Review of the literature through enlarged medical data bases such as PubMed and Cochrane data base.

Results

Subcutaneous emphysema (SE) during laparoscopic procedures remains a controversial issue with proper diagnosis and treatment. Mandatory and critical factor reflects the experience of the anesthesiologist. Optimal intraabdominal pressure varies from 12 to 14 mmHg. The extension of this issue reflects outside the peritoneal cavity with areas of chest and thorax, head and neck.

Incidence of SE varies to 2,5% through current bibliography. Besides the mentioned associated factors, extended surgical period and increased age of the patient, can led to SE. Great percentage can remain undetectable, diagnosed the following postoperative days.

Murdock et al. consisted incidence ranges of 5,5% relating hypercarbia, 2,3% relating SE and 1,9% relating pneumothorax as intraoperative complications of gynecologic laparoscopic procedures. Most characteristic clinical sign reflects the sensation of palpation as the gas infiltrates the tissues. In such cases, a blood analysis can reveal the range of hypercarbia, electrolytic disorders and gas exchange.

Proper clinical treatment of such cases consist of increasing the minute ventilation and tidal volume in order to wash off the increased CO₂.

Conclusions

Subcutaneous emphysema (SE) is strongly associated with intraoperative complication during laparoscopic procedures. Many factors, as mentioned above, can lead to this clinical situation.

Multidisciplinary cooperation, proper insufflator settings and avoidance of torquing of trocars are mandatory factors in order to achieve a safe surgical strategy.

<https://esge.covr.be/cmdocumentmanagement/conferencemanager/documents/api/getdocument/5063/cmabstms/000040750/eba92e2a07185bfe81344e4ea54a0a98341d7ccdca54d33303f8d80bcd5c6e60>

ES28-0071 - P070

E-Poster

Laparoscopic resection of the cecal fundus in necrotizing appendicitis, with insecure appendiceal stump-a novel technique

Konstantinos Manes¹, Chrisostomos Sofoudis², Milena Dinic³, Konstantinos Zioris⁴, Minas Paschopoulos⁵

¹Konstandopoulio General Hospital Athens Greece, Department of Surgery, Athens, Greece

²Konstandopoulio General Hospital Athens Greece, Department of Obstetrics and Gynecology, Athens, Greece

³Konstandopoulio General Hospital Athens Greece, Department of Anesthesiology, Athens, Greece

⁴Mitera Maternal Hospital, Department of Obstetrics and Gynecology, Athens, Greece

⁵University of Ioannina, Department of Obstetrics and Gynecology, Ioannina, Greece

Background

Appendectomy represents a common urgent surgical procedure, affecting with increased incidence and most of all young people with enormous fertility capacities. According to recent bibliography, therapeutic mapping of such cases remains controversial. Many systematic reviews and meta-analyses compare and depict lap versus open procedure. We present our experience in dealing with the so called “insecure” appendiceal stump, with a novel technique.

Methods

Assiduous presentation and depiction of the mentioned novel technique. Our study reflects a retrospective analysis from September 2013 till September 2018. We collected the data of 10 female patients operated laparoscopically, by the same surgeon, for acute complicated appendicitis. Two of them were pregnant in the second trimester of gestation. Intraoperatively, all the patients had perforated appendicitis with difficulties in closing the appendiceal stump due to inflamed tissues. The options in such cases is either performing a purse string, ileocectomy or even right hemicolectomy.

Results

We present our series of doing in all ten patients a limited cecectomy (partial), by performing laparoscopic resection of just the fundus of the cecum. The fundus of the cecum is a cul de sac without mesocolon. This allows us to resect it fearlessly. So, by dissecting in a limited fashion the right paracolic gutter, towards Toldt's fascia, the fundus of the cecum is easily resected laparoscopically using a stapler. All ten female patients had an uneventful recovery and were discharged on the 2nd postoperative day. Follow up revealed no complications demonstrating any clinical diversion compared to current bibliography.

Conclusions

Perforated appendicitis especially in young patients consists proper diagnosis and assiduous therapeutic strategy. Our goal, remains depiction of new feasible and technically easily surgical procedures as laparoscopic dissection of cecal fundus, in order to prevent serious complications of this clinical status.

<https://esge.covr.be/cmdocumentmanagement/conferencemanager/documents/api/getdocument/5064/cmabstms/000040750/3ef48981e5e9c83a296b2f50f9746bca20a64f159dd0528a2cea3d78668d548a>

Latrogenic right ureteral injury after laparoscopic anterior resection-case report and review of the literature

Konstantinos Manes¹, Chrisostomos Sofoudis², Milena Dinic³, Panagiotis Filios⁴

¹*Konstandopoulio General Hospital Athens Greece, Department of Surgery, Athens, Greece*

²*Konstandopoulio General Hospital Athens Greece, Department of Obstetrics and Gynecology, Athens, Greece*

³*Konstandopoulio General Hospital Athens Greece, Department of Anesthesiology, Athens, Greece*

⁴*Konstandopoulio General Hospital Athens Greece, Department of Urology, Athens, Greece*

Background

Latrogenic ureteral injuries (IUI) are rare complications of abdominopelvic operations, which unfortunately have severe sequelae. IUI most commonly occur after gynecological interventions (0.075% - 1.7%) followed by colorectal procedures (0,025%-1,1%).

Intraoperative recognition (15-30%) is related with reduced morbidity. IUI after colorectal surgery most often occur following abdominoperineal resection and low anterior resection (LAR). Most often intraoperative causes consist devascularization, laceration, ligation, resection or thermal injury.

Methods

Proper surgical diagnosis and treatment of such cases.

We report a case of an obese female patient (BMI:40), who underwent a laparoscopic LAR and was presented 1 month postop with urinoma. Imaging evaluation revealed injury of the lower right ureter, an uncommon complication after laparoscopic colorectal surgery. Usually, the left ureter is injured followed colorectal surgery.

Possible cause a thermal injury during medial dissection of the retroperitoneum towards the Inferior mesenteric artery (IMA), with the use of ultracision device. Through abdominal CT and procedure of right nephrostomy, patient underwent insertion of stent inside right ureter. Final step towards patient restoration, considered proper the re-infiltration of ureter inside the bladder wall.

Results

A recent population-based study by Halabi et al. found an incidence of 0.28% IUI in more than two million colorectal surgeries in the USA. Patient risk factors for IUI included cancer with nodal or metastatic involvement, malnutrition and steroid use. Open surgery revealed higher rates of IUI compared to laparoscopic surgery. However, as there was no patient stratification, open cases presumably represent more difficult procedures due to reoperations and adhesions. In contrast, Palanniapa et al. reviewed 5729 colectomies for IUI. In their series, there was a statistically significant increase in IUI occurring after laparoscopic versus open procedures (0.66% vs. 0.15%, respectively; $p = 0.007$).

Andersen et al. reviewed the Danish National Colorectal Cancer database (DCCG) with 18,474 patients following resection for colorectal cancer. The rate of ureteral injuries was 0.44%, with 37 (0.59%) injuries in the laparoscopic ($n = 6,291$) and 45 (0.37%) in the open group ($n = 12,183$) ($p = 0.03$). In rectal cancer patients ($n = 5,959$), the laparoscopic approach was used in 1899 patients of whom 19 (1.0%) sustained ureteral injuries, whereas 17 (0.42%) of 4060 patients who underwent an open resection had a ureteral injury. In multivariate analysis adjusted for age, gender, ASA score, body mass index, tumor stage and preoperative chemoradiation the laparoscopic approach was associated with an increased risk of ureteral injury (OR = 2.67; 95% CI = 1.26-5.65).

Conclusions

Latrogenic ureteral injuries after laparoscopic procedures represent a controversial issue with many conducted studies. Multidisciplinary approach, proper diagnosis and treatment are mandatory factors of accurate surgical strategy.

ES28-0299 - P072

E-Poster

Pre-evaluation of satisfaction degree with secondary cytoreductive surgery for platinum-sensitive recurrent ovarian cancer

Li Li¹, Zhang Shu¹, Zhao Huanhuan¹, Shao Xiao¹

¹The 4th Hospital of Hebei Medical University, Gynaecology, Shijiazhuang, China

Background

Satisfied secondary cytoreductive surgery (SCRS) is very important to the prognosis of platinum-sensitive recurrent ovarian cancer. The study was to explore the factors affecting the satisfaction degree of SCRS and to provide a reference for the clinical selection of appropriate surgical patients.

Methods

From January 2016 to October 2018, 34 patients with platinum-sensitive recurrent ovarian cancer underwent secondary cytoreductive surgery in the fourth hospital of Hebei Medical University was retrospectively analyzed. Logistic regression analysis was used to analyze the factors influencing the outcome of the operation.

Results

27 patients achieved complete cytoreduction (R0: no gross residual), accounting for 79.4% of the total 34 patients underwent secondary cytoreductive surgery. Satisfactory cytoreduction was achieved in 7 cases (R1), accounting for 20.6%. Multivariate Logistic regression analysis showed that the independent risk factors affecting surgical outcomes were: the number of recurrent disease diagnosed before operation ($P=0.036$, $OR=13.272$, $95\%CI=1.180-149.279$). 5 patients underwent laparoscopic exploration and 4 patients got R0.

Conclusions

ECOG score, ascites and the number of recurrent disease before operation were risk factors affecting the outcome of secondary cytoreductive surgery. Laparoscopic exploration combined with multi-disciplinary team is of great significance for the feasibility of cytoreductive surgery and the decision-making of surgical methods.

<https://esge.covr.be/cmdocumentmanagement/conferencemanager/documents/api/getdocument/4961/cmabstms/000148370/e8cc349bfdccec71e45647bc4faa14acc8e9b9f70179983dd6defdcc31f1ebc>

ES28-0121 - P073

E-Poster

The impact of uterine artery embolisation on ovarian reserve: a systematic review and meta-analysis

Tarek El Shamy¹, Saad Amer², Ahmed Mohamed³, Cathryn James⁴, Kannamanadiar Jayaprakasan²

¹West Middlesex University Hospital, Obstetrics and Gynaecology Department, London, United Kingdom

²University Hospitals of Derby and Burton NHS Foundation Trust, Derby Fertility Unit, Derby, United Kingdom

³Assiut University, Obstetrics and Gynaecology Department, Assiut, Egypt

⁴University Hospitals of Derby and Burton NHS Foundation Trust, Library & Knowledge Service, Derby, United Kingdom

Background

Uterine fibroids are the most common benign pelvic neoplasm in women with a variation in reported prevalence (25% - 80%) in the literature. They are frequently associated with distressing symptoms such as menorrhagia, dysmenorrhoea, bloating and pressure symptoms. Other problems include subfertility and adverse pregnancy outcome. Treatment options include, expectant management, symptomatic treatment, hormonal therapy, hysteroscopic resection, myomectomy, hysterectomy and uterine artery embolisation (UAE). Since its first introduction in 1995, UAE has gradually been established as an effective and minimally invasive treatment modality for uterine fibroids. However, there have been concerns over its potential impact on ovarian reserve due to possible unintended embolisation of the utero-ovarian collateral circulation leading to impairment of ovarian blood supply with subsequent decline in ovarian reserve.

The aim of this systematic review and meta-analysis was to investigate the impact of UAE on ovarian reserve as determined by circulating serum concentrations of Anti-Müllerian hormone (AMH).

Methods

This meta-analysis included all published cohort, cross-sectional and case-control studies as well as randomised trials that investigated the impact of UAE on circulating AMH. Data sources included MEDLINE, EMBASE, Dynamed Plus, ScienceDirect, TRIP database, ClinicalTrials.gov and the Cochrane Library from January 2000 to February 2019. AMH and other data were extracted from the individual articles and entered into RevMan software to calculate the weighted mean difference (WMD) between pre- and post-embolisation values.

Results

This review included three cohort and three case-control studies (n=353). The duration of follow up ranged between three and 12 months. Overall pooled analysis of all studies showed no significant effect of UAE on serum AMH levels (WMD -0.58 ng/ml; 95% CI -1.52, 0.36, I²=95%). Subgroup analysis according to follow-up duration at 3, 6 and 12-month showed no significant change in post-embolisation circulating AMH. Pooled analysis of serum FSH concentrations (four studies, n=248) revealed no statistically significant change after UAE (WMD 4.32; 95% CI -0.53 to 9.17; I²= 95%). Analysis of two studies (n=62) measuring AFC showed a significant decline at 3-months follow up (WMD -3.28; 95% CI -5.62 to -0.93; I²= 94%).

Conclusions

Uterine artery embolisation does not seem to affect ovarian reserve as measured by serum AMH and FSH levels. However, given the low quality of studies included in this review, further research is needed with a larger population of women under 40 years of age to allow a firm conclusion.

<https://esge.covr.be/cmdocumentmanagement/conferencemanager/documents/api/getdocument/5215/cmabstsms/000090470/67fb27005689ba7fb45116cfd8b0dce62e5a60db3328f0d53f335254f142f827>

ES28-0088 - P074

E-Poster

Successful delivery after minimal invasive surgery for sequential tubal re-anastomosis and cesarean scar pregnancy - a case report

Yichen Chuang¹, Hsin Mei Liu¹

¹*Far Eastern Memorial Hospital, Obs&Gyn, New Taipei, Taiwan*

Background

We present a case of a 29-year-old woman with three previous caesarean deliveries and bilateral tubal ligation, who underwent a Da Vinci robotic tubal re-anastomosis in our hospital 6 months ago. She became pregnant spontaneously, but the fetus implanted in the previous cesarean scar in the lower uterine segment, which we termed a cesarean scar ectopic pregnancy (CSP). The CSP was diagnosed from her trans-vaginal ultrasonography. The initial beta-hCG level was 41,787 mIU/mL on the day before surgical intervention.

Methods

In the operating theater, the patient was put on lithotomy position and a 4-port technique, 2 x 5mm, 2 x 10 mm trocars were used. Under laparoscopic view, bilateral uterine arteries were identified through retrograde tracking of the umbilical ligaments and ligated with hem-o-loks(temporal vessel occlusion device). The gestational tissue was removed via trans-cervical resectohysteroscopy. Later, the bladder flap was dissected laparoscopically and the cesarean scar defect was excised and repaired with 1-0 V-Loc sutures.

Results

The operation time was about 2 hours and 30 minutes and the estimated blood loss was 200 cc. The patient tolerated the procedure well and her post-operative course was uneventful. The post-operative beta-hCG drop to 8.0 mIU/ml. in 10 days. She regained her menstrual cycle 2 months after the operation and wishes to try pregnancy again. She got pregnant spontaneously 6 months later and delivered a 2200 gm at 34 weeks gestational age by C section .

Conclusions

This patient reminds us that ectopic pregnancy could happen in the cesarean scar defect. The tubal surgery history is not the only risk factor of ectopic pregnancy. Minimal invasive surgery could preserve the patient's reproductive potential.

ES28-0090 - P075

E-Poster

Laparoscopic female sterilization in ambulatory setting - an evaluation

Sara Bernardes Da Cunha¹, Matilde Martins², Cátia Rasteiro³, Cristina Costa⁴, António Lanhoso⁵, Paula Sarmiento⁶

¹*Centro Hospitalar de Entre o Douro e Vouga, Obstetrics and Gynecology, Feira, Portugal*

²*Cebtro Hospitalar Entre Douro e Vouga, Obstetrics and Gynecology, Feira, Portugal*

³*Centro Hospitalar de Entre Douro e Vouga, Obstetrics and Gynecology, Feira, Portugal*

⁴*Centro Hospitalar de Entre o Douro e Vouga, Obstetrics and Gynecology, Feira, Portugal*

⁵*Centro Hospitalar entre douro e vouga, Obstetrics and Gynecology, Feira, Portugal*

⁶*Centro Hospitalar entre Douro e Vouga, anesthesiology, Feira, Portugal*

Background

To evaluate patient clinical status and satisfaction in laparoscopic tubal ligation (LTL) performed in our ambulatory surgery (AS) unit.

Methods

A retrospective analysis of the information collected from the 24-hour phone call after gynecology surgery in our AS Unit from 2014 to 2018 was conducted. Records included pain, hemorrhage, functional status and patient perceived adequacy of prescribed analgesia and given information.

Results

A total of 646 procedures were performed, corresponding to 47% of the AS activity of the time studied. Eight cases (1,2%) of fever were reported. In 22 cases (3,4%) and 2 cases (0,3%) bleeding was described by the patient as mild and moderate respectively. Pain medication adequacy was considered sufficient by the patient in 95,8 % of the cases. Severe limitation (only basic hygiene needs performed) was recorded in only 2,2% of patients. Most of the patients moved with some limitations 497 (76,9%) and 101 (15,6) without any limitation reported. 1,9% of patients presented normal daily activity.

Pain medication was considered insufficient in 2,5% of patients. Information supplied was perceived unsatisfactory in 1,1% of patients. Only 3 patients had clinical concern motivating instruction to visit a health unit.

Conclusions

Global satisfaction was high. More than 95,5% of patients revealed that medication and information provided was sufficient. Only minor complications were reported.

To accomplish the advantages of AS, it is important to look back to our patients. One of the tools used to evaluate the healthcare quality and safety is the 24-hour after-surgery phone call. Assuring that our practice is adequate and searching improvement is essential. By this 24-h phone call we ensure patient satisfaction and analyse complications.

<https://esge.covr.be/cmdocumentmanagement/conferencemanager/documents/api/getdocument/5048/cmabstsms/000164850/f66cd2836a3530e9c123f8b2d973570c6ca45b9335065c0b7802eb75b8ab319d>

ES28-0678 - P077

E-Poster

Strategies to reduce surgical time / laparoscopic cervico-sacrocolpopexy for advanced pelvic organ prolapse

Pilar Alvarez Alvarez¹, Paloma Lobo Abascal¹, Paula Salazar Lujan¹, M^a Luisa Loayza Escalante¹, Susana Gámir Anderson¹, Julio Alvarez Bernardi¹

¹*Hospital Universitario Infanta Sofía, Obstetricia y Ginecología, San Sebastián de los Reyes. Madrid, Spain*

Background

To assess whether strategies in the laparoscopic approach of pelvic floor pathology in our centre reduce surgical time without modifying the results or increasing complications.

Methods

Longitudinal, retrospective study analysing the laparoscopic cervicosacropexies and colposacropexies performed in our Hospital between the years 2010 - 2018, including a total of 98 patients. The classic technique was performed with dissection of vesicovaginal and rectovaginal spaces to elevators, with modifications of mesh fixation with tackers and the use of retroperitoneal tunnelling device (RTD-Ney). The variables under study were age, BMI, parity, pre-surgery exploration, concomitant surgeries performed, surgical time, complications during the intervention, and short and long-term objective complications in the follow-up consultation.

Results

The average age of our patients was 56, 45 +/- 5.5 years. 88% were post-menopausal. The average of vaginal births was 2.31. BMI > 30 in 46%. In 80.4% of cases we performed subtotal hysterectomy with cervicosacropexy. The remaining 19.6% of surgeries were colposacropexy due to vaginal vault prolapse. In 81.96% there was a previous compartment defect, severe in 68% of the cases. Hysterocele in 77%; severe in 63.83%. Rectocele in the 44.26% of patients. Enterocele in 9.8% of patients. Concomitant anti-incontinence and / or vaginal correction techniques were performed with colpoplasties and / or perineorrhaphy in 7 cases.

We quantified the surgical time from the beginning of the incision to the last point of surgical suture, observing a decrease of at least 30 minutes.

Regarding the long-term results, in 81.96% of the patients an anatomical correction of the prolapse was achieved. In the 18.03% of those that reported bulge a low-grade cystoceles were observed. A 16.39% of postoperative urinary incontinence was recorded. In the posterior compartment, one patient had rectal tenesmus and two referred constipation. Second surgery was required due to recurrence in one of the compartments in 4 patients. Non-symptomatic anatomical recurrences were recorded: cystocele 22.95%, rectocele 4.91%, enterocele 6.55% all of them grade I or II. As long-term complications, we recorded a supraumbilical incisional hernia and two mesh extrusions.

Conclusions

The laparoscopic colpo or cervicosacropexy is a technique with low morbidity, few intraoperative complications and excellent short and medium term results. The percentage of anatomical corrections of the prolapse is high and in case of persistence or reappearance of defects are usually of anterior compartment, low grade and asymptomatic. The strategies performed in our Department reduce the surgical time and the results are adjusted to the expected percentage with the classic approach. The simplification of some aspects of the surgical technique facilitates the same and shortens the learning curve favouring the introduction of the technique in other centers in which a laparoscopic approach of the pelvic floor pathology is not performed.

<https://esge.covr.be/cmdocumentmanagement/conferencemanager/documents/api/getdocument/5003/cmabstms/0000166970/c20bfa7922dbb64069269f466dccb7df073cee36011cd93d1a3bf6fa9c1b1d5b>

ES28-0095 - P078
E-Poster

Report of a rare case of inguinal ovary in an adult female; laparoscopic management and literature review

Ioannis Tsimpanakos¹, Natalia Barbaneagra¹, Sandra Ampomah¹, Hemant Vakharia¹

¹Royal Free London- Barnet Hospital, Obstetrics & Gynaecology, London, United Kingdom

Background

Ovarian hernias are extremely rare. We report the case of an inguinal ovarian hernia in a premenopausal woman with a 12-month-history of chronic pelvic who had multiple attendances to the emergency department and required potent and frequent analgesia prior to the diagnosis and management. We herein present the case, laparoscopic procedure and review of the literature.

Methods

Case report: A 24-year-old woman presented with a 12-month history of pelvic pain. Her past medical history included a miscarriage and significant rapid weight loss following a gastric band surgery. She had multiple, over 52 admissions to A&E for pain management with analgesia including opioids. When she presented to our hospital, she was in distress due to pain but stable haemodynamically. Her systemic examination and biochemical results were normal. Although she had a reportedly normal pelvic ultrasound scan 2 years ago, her recent USS showed a normal left ovary but the right ovary was seen high in the abdomen. The patient underwent a diagnostic laparoscopy which revealed a normal uterus, left ovary and Pouch of Douglas. The right ovary and fallopian tube were not seen initially, but following adhesiolysis it was revealed that the right ovary was atypically located and findings were consistent with

an ovarian hernia. A joint procedure with the surgical and gynaecology team was then scheduled for the following day for definitive management.

Results

Discussion and literature review: In adults ovarian inguinal hernias are rare, with 12 cases reported so far. Most cases actually have been reported in infants/small children with or without other genital tract anomalies. Risk factors are fluid or pressure in the abdomen, heavy lifting, constipation and straining, chronic cough, pregnancy, obesity, surgery and smoking. The majority presented with a palpable groin mass (Tagliaabue 2011; Machado & Machado 2011; Mandel et al 2010; Alzaraa 2011). One woman presented with pelvic pain and was found on laparoscopy to have a rudimentary uterine horn and ovary herniated through the inguinal canal (Al Omari et al 2011). One hypothesis for their development is a possible weakness of the broad ligaments or ovarian suspensory ligaments which could lead to the ovarian herniation to the inguinal canal.

Conclusions

The inguinal ovary requires multidisciplinary approach. Most of these cases are corrected laparoscopically in a joint procedure with either freeing the ovary or performing oophorectomy and repairing the hernia orifice. Although extremely rare, the possibility of ovarian hernia should be considered as one of the differential diagnosis in a woman with ongoing pelvic pain.

<https://esge.covr.be/cmdocumentmanagement/conferencemanager/documents/api/getdocument/5225/cmabstsms/000073390/b2cd16935c693dfc93e9d378114c68c6a57631b98b3e1be5237d057e7d34b070>

ES28-0096 - P079

E-Poster

Increasing diagnostics for postmenopausal bleeding, less is more?

Lizzy-Sara Zollner¹, David van der Ham¹, Erwin Geuken², Jorien Woolderink¹

¹Martini Hospital, Gynaecology, Groningen, The Netherlands

²Martini Hospital, Pathology, Groningen, The Netherlands

Background

In November 2015 the Dutch Society of Obstetrics and Gynecology (NVOG) published a new guideline on diagnosis and management of postmenopausal bleeding. In the previous guideline of 2003, patients with endometrial thickness over 4 mm and a normal endometrial aspiration biopsy received no additional procedures, except for those with recurrent vaginal blood loss. In contrast the new guideline introduced in 2015 recommends to perform an additional gel or saline infusion sonography (GIS/SIS) or a hysteroscopy in all women with endometrial thickness above 4mm to identify intrauterine pathology and advises to remove this pathology in order to reduce the number of missed (pre)malignancies. This study examines whether the implementation of this new 2015-guideline, advising an additional number of diagnostic and therapeutic interventions, will result in an increase of found (pre)malignancies in everyday practice.

Methods

A retrospective observational cohort study.

Between 1-1-2015 and 31-12-2015 (2003-group) and 1-1-2016 and 31-12-2016 (2015 group), all patients referred to the Martini hospital in Groningen, The Netherlands, with postmenopausal bleeding were selected. Patients who had had a hysterectomy and patients with a previous episode of postmenopausal bleeding within one year prior to the current episode were excluded.

Results

In total, 337 women were included in a group that were treated based on the 2003 guideline (2003-group) and 344 women were treated based on the 2015 guideline (2015-group). Baseline characteristics were similar. In the 2003-group a significant proportion (15%) of patients underwent more diagnostic or therapeutic interventions than was recommended in the 2003-guideline. In the 2015-group in (22%) of the patients not all recommended steps were offered/executed. (Pre)malignancies were found with 11 (3,3%) patients in the 2003-guideline group, versus 14 (4,1%) in the 2015-guideline group (95%CI: 0,57 to 2,70). Significantly more benign intrauterine pathology was found in the 2015-group. In this 2015 group, a GIS or hysteroscopy was more often (56% vs 29%) performed and the average number of consultations per patient was higher than in the 2003-group (2.9 vs 2.3). The incidence of complications by hysteroscopy was similar. However, as more hysteroscopies were performed in de 2015-group, the number of

complications (uterine perforations, a failed intervention, longer duration of intervention or incomplete intervention), was significantly higher in the 2015-group (5.0% vs 2.7%, $p = 0,026$).

Conclusions

Implementation of the new guideline on diagnosis and management of postmenopausal bleeding seems to lead to an increase in diagnostic tests, treatments and costs. However, this study did not find an increase in the detection rate of (pre)malignancies of the endometrium. We suggest a nationwide implementation study for this guideline. As health care budget is limited and costs and burdens increase, the new guideline should at least result in a favorable outcome for the patient.

<https://esge.covr.be/cmdocumentmanagement/conferencemanager/documents/api/getdocument/4929/cmabstms/0000158570/423a4fe039f925a3d092d14b5cb4de514c7a6745f3512ed62a6dbd5b876b5c4c>

ES28-0099 - P080

E-Poster

Sliding leiomyoma after treatment with ulipristalacetat – a case report

Ksenija Kardos Mohorko¹, Katja Juvan¹

¹General hospital Slovenj Gradec, Department of Gynecology and Obstetrics, Slovenj Gradec, Slovenia

Background

Uterine leiomyomas are the most common tumours occurring in 20 - 40 % of women of reproductive age. The treatment of choice is surgery. Ulipristalacetat is a possible medical treatment. The goals are size reduction and amenorrhoea. Clinical case reports have shown a specific and unexpected effect of ulipristalacetat, which could cause a migration of leiomyomas.

The aim of this case report is to share our experience, where combined laparoscopic and vaginal surgery was needed for the treatment of uterus leiomyomatosis.

Methods

A 41-year-old multiparous woman was diagnosed with an intramural leiomyoma on ultrasound, 47 x 30 mm in size. An intrauterine device with levonorgestrel was administrated. After two years, she was presented to our hospital because of an enlarged leiomyoma and a dislocated intrauterine device. Ultrasound confirmed an intramural leiomyoma of anterior uterine wall, 47 x 49 mm in size. During hysteroscopy no involvement of uterine mucosa was determined. In the next three months, she developed heavy bleeding and mild pelvic pain. Laparoscopic myomectomy was scheduled. MRI scanning was not carried out due to no availability. Multiple leiomyomas and a very enlarged uterus were determined intraoperatively. In accordance with her consent, only an extensive adhesiolysis was performed and postoperative treatment with ulipristalacetat was administrated. After three months of therapy, ultrasound showed no reduction in size of the leiomyoma, so the treatment was suspended. Diagnostic hysteroscopy was performed and a normal uterine cavity and no histological abnormalities were found. After 6 months she was admitted with heavy bleeding, pelvic cramping and anaemia. By vaginal examination a sliding leiomyoma in the cervix, 42 x 68 mm in size was found and confirmed by ultrasound. Consent for hysterectomy was obtained and the operation was performed. Laparoscopic supracervical hysterectomy was done in combination with vaginal enucleation of sliding leiomyoma, firmly attached to anterior cervical wall. We sutured the myoma bed vaginally and measured the cervix. It was 6 cm in length.

Results

There were no complications postoperatively and anaemia was successfully treated with iron supplementation. After 4 weeks on check-up, the cervix measured 37 x 33 mm, without abnormalities in the lower abdomen. Histologically, no abnormalities were found.

Conclusions

Ulipristalacetat has a proapoptotic and anti-proliferative effect on leiomyoma cells. These mechanisms could induce a migration of leiomyomas. In our case an intramural leiomyoma migrated via the cervical canal and became a sliding leiomyoma. A combination of laparoscopic and vaginal surgery was performed to obtain an optimal outcome.

Migration of leiomyomas after treatment with ulipristalacetat should be taken into consideration when planning a surgery.

<https://esge.covr.be/cmdocumentmanagement/conferencemanager/documents/api/getdocument/5100/cmabstsms/0000164910/865303c3fab3ce0bf0a2af68c75d6d5196284b5df77e959b0eba76c19adf4fab>

ES28-0097 - P081
E-Poster

Peritoneal dissemination after single-port laparoscopic para-aortic lymphadenectomy in locally advanced cervical cancer

Ah-Ra Lee¹, Kim Jin-Hw²

¹*The Catholic University of Korea- Uijeongbu ST. Mary's Hospital, Obstetrics and Gynecology, Uijeongbu, Korea- Republic Of*

²*Uijeongbu St. Mary's Hospital- Catholic University, Department of Obstetrics and Gynecology, Uijeongbu, Korea- Republic Of*

Background

The risk of wound metastasis after laparoscopic operation for gynecologic malignancy is well known. But there are few data on peritoneal carcinomatosis of cervical squamous carcinoma after laparoscopy, especially single port PALND (para aortic lymph node dissection).

Methods

A 43-year-old Korean woman had stage IIB uterine cervical squamous cell carcinoma. A preoperative PET–CT scan revealed suspicion of metastatic LN in the right obturator area but there is no evidence of PA node metastasis. She underwent single-port laparoscopic PAL and had no metastasis. 6 cycles of cisplatin chemo-radiation was administered (45Gy) and ICR was performed consecutively (30Gy). 15 months later, peritoneal recurrence was suspicion through the follow-up PET-CT and pathologically invasive squamous carcinoma was confirmed by diagnostic laparoscopy.

Results

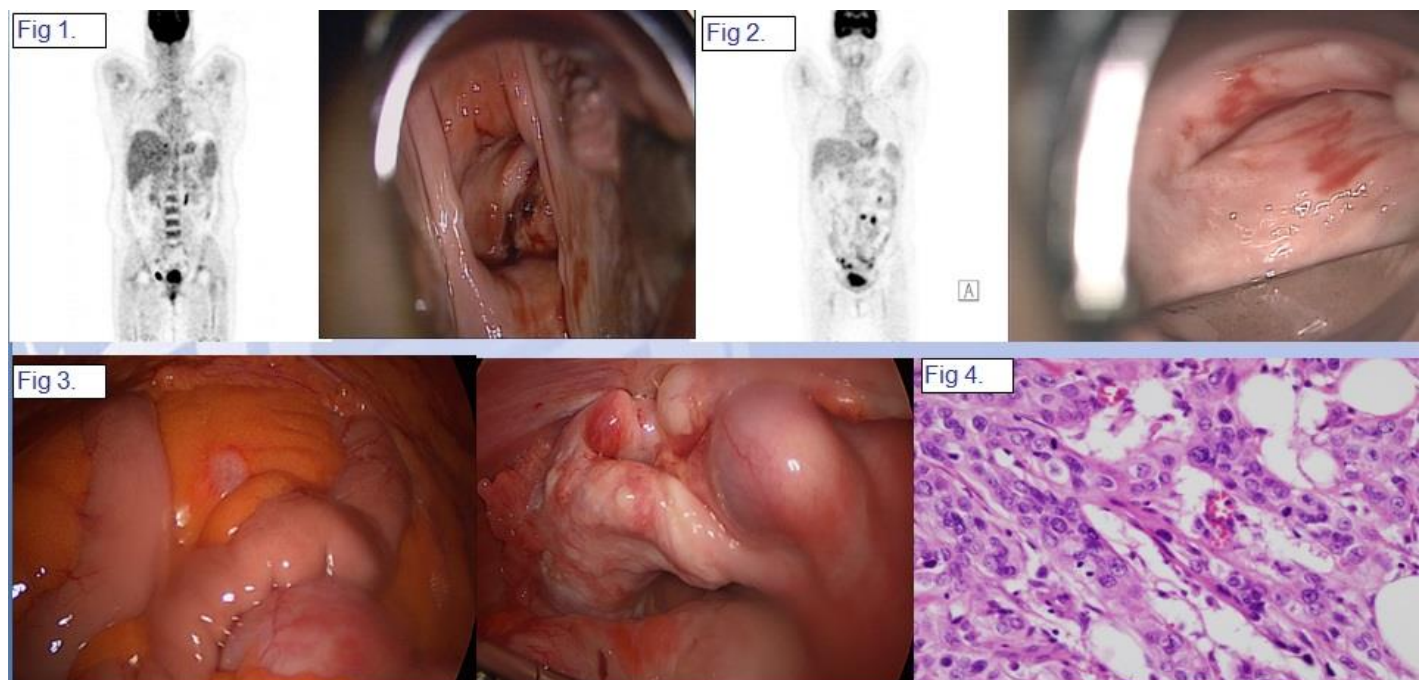


Fig 1. Initial PET-CT, colposcopy shows stage IIB uterine cervical cancer.

Fig 2. 15months later, follow-up PET-CT and colposcopy. Imaging revealed suspicion of peritoneal carcinomatosis.

Fig 3. Under diagnostic laparoscopy for pathologic confirmation, multiple malignant nodules were noted from omentum and peritoneum.

Fig 4. pathologically, invasive squamous cell carcinoma was confirmed.

Conclusions

Single-port laparoscopic PALND for locally advanced cervical squamous carcinoma may carry a risk of peritoneal dissemination even though imaging and pathology of para aortic LN was negative.

<https://esge.covr.be/cmdocumentmanagement/conferencemanager/documents/api/getdocument/4907/cmabstms/000164920/b76de6a5045612a940c183ea62931609c0ebdaba24b16c65c81ff605fb8c76b9>

ES28-0101 - P082

E-Poster

Methylated PAX1 test as triage biomarker for high risk HPV and ASCUS of cytology women: important clinical results and cost effectiveness analysis

Mian Huang¹

¹Fuzhou No.1 Affiliated Hospital of Fujian Medical University, Dept. of Obstetrics & Gynecology, Fuzhou City- Fujian Province, China

Background

Further on the presentation - *clinical application Value of PAX1 methylated gene for cervical cancer*, which was made by Dr. Huang in ESGE 27th Annual Congress in 2018, more than 450 cases (testing set) were enrolled to validate the clinical efficacy of *PAX1^m* and to determine the best cost-effective model, for adopting the *PAX1^m* test as the primary or triage biomarker for cervical cancer screening.

Methods

Following the GCP guidance, the subjects were recruited in the First Hospital of Fuzhou, China from 2016 to 2019. The inclusion criteria were females aged ≥ 20 and with sexual experience. The exclusion criteria included that women had history of cancer related to reproductive tract, had therapy for cervical lesions, had received HPV vaccination or at pregnancy. The results of the methylated *PAX1* gene were determined by qPCR. Sensitivity, specificity and accuracy for cytology, hrHPV and the *PAX1* methylation level were analyzed. EpiData 3.1 was used for data entry and SPSS 18.0 software was used for statistical analysis.

Results

Total 450 case-control subjects were recruited and more than 250 hrHPV subjects were analyzed in the study. The final diagnoses were confirmed by histological reports. The results showed that the *PAX1^m* was significantly higher in hrHPV patients with CIN3 and worse lesions than those with CIN1, CIN2 and normal cervix ($P < 0.0001$). The sensitivity of *PAX1^m* for CIN2+ were more than 75% and the specificity and accuracy were more than 90%, respectively. *PAX1^m* still showed good results for clinical application in ASCUS and hrHPV triage in the study. *PAX1^m* test reduced more than 20% colposcopy referral rate than cytology did when hrHPV were used as primary screening method.

The cost effectiveness of cytology, hrHPV and *PAX1^m* as primary screening or the combination tests were analyzed and showed *PAX1^m* test incurred the lower life cost ($>10,000$ Yuan) than the other two methods for cervical cancer screening.

Conclusions

The current results indicate that the *PAX1^m* test is a promising triage biomarker following hrHPV test or cytology as cervical cancer primary screening in Chinese population. The single center clinical evidence can improve the clinical effectiveness and decrease the costs of cervical cancer screening and follow-up in the study.

<https://esge.covr.be/cmdocumentmanagement/conferencemanager/documents/api/getdocument/5118/cmabstms/000148660/8d1cdb99ac4f4e0c2e68f9e976e156b2c69b16fb23e352ef1ce9df5974f85de7>

Prevalence of uterine anatomical malformations diagnosed by hysteroscopy in Greek women with recurrent pregnancy loss

Ektoras Gazos¹, Charalambos Goulas², Orestis Tsonis³, Thomas Vrekousis⁴, Ioardanis Navrozoglou³, Minas Paschopoulos³

¹General Hospital of Karditsa, Obstetrics and Gynecology Department, Karditsa, Greece

²University of Patrai, Computer Engineering and Informatics Department, Patrai, Greece

³University Hospital of Ioannina, Obstetrics and Gynecology Department, Ioannina, Greece

⁴University Hospital of Heraklion, Obstetrics and Gynecology Department, Heraklion, Greece

Background

In the region of Greece, the data concerning the prevalence of uterine anatomical malformations as a direct or indirect cause of recurrent pregnancy loss (RPL) remains limited. The aim of this study is to identify the prevalence and the types of uterine anatomical malformations in Greek women with a history of RPL. All women underwent hysteroscopy in order to set the diagnosis of uterine anatomical malformations.

Methods

A retrospective study was conducted in the endoscopic and infertility department of the University Hospital of Ioannina. This unit covers a wide region of Greece, regarding more than 5% of its population.

In this retrospective study data was collected from year 1998 till 2013 over a period spanning more than 15 years. The patients who were included in the study had a history of 2 or more consecutive miscarriages or at least 3 spontaneous miscarriages in total. All patients underwent a full investigation concerning the most common causes of infertility. A control group was also included, regarding women with at least one successful pregnancy, with no history of RPL, who underwent hysteroscopy within the same time period due to various others indications.

Different hysteroscopic findings were categorized as followed: a) congenital uterine malformations (unicornuate, bicornuate uterus, uterine septum, etc.), b) acquired anatomical uterine malformations (endometrial polyps, adhesions, submucous fibroids, etc.) c) subtle (functional) endometrial lesions (micropolyposis of endocervix, chronic – subclinical endometritis, adenomyosis, etc.).

Results

Three hundred women with RPL and a control-group of four hundred and four women were included. Pathological hysteroscopic findings were present in more than 70% of women with RPL, but less than 60% of the control-group. The hysteroscopic findings in the RPL-group were mostly: a) congenital uterine malformations such as uterine septum, b) uterine adhesions, c) and chronic endometritis. In a great part of women suffering from RPL, hysteroscopy showed the presence of endometrial polyps and micropolyposis of the endocervix. These findings were identified in the control-group but with a higher incidence. Hysteroscopic findings in women with more than 2 spontaneous miscarriages were similar to those with a history of more than 3 spontaneous miscarriages.

Conclusions

The prevalence of uterine anatomical malformations, acquired or congenital, in Greek women suffering with RPL is quite high. In order to facilitate the appropriate management for these women, the categorization of the uterine anatomical malformations in 3 groups a) congenital, b) acquired and c) subtle endometrial lesions, seems to be useful. In the latter group, hysteroscopy seems to play an important role. This study underlines the importance of hysteroscopy in the management of reproductive failure and proposes the use of hysteroscopy, as a valid screening tool, even in women with no more than 2 spontaneous miscarriages.

<https://esge.covr.be/cmdocumentmanagement/conferencemanager/documents/api/getdocument/4969/cmabstms/000164580/1bbf804b48391d946452a5b6880e1fb39bbb6bcde8d04120b5efbf423d9c2c48>

Hysteroscopy training: study and proposal of a hysteroscopic skills training curriculum, for groups and individuals in order to achieve progress and to offer self-evaluation

Ektoras Gazos¹, Homer-Dimitrios Chiotakos², Orestis Tsonis³, Konstantinos Grapatsas⁴, Minas Paschopoulos³, Afrodite Aggelopoulou¹

¹General Hospital of Karditsa, Obstetrics and Gynecology Department, Karditsa, Greece

²University of Thessaly, Medical Laboratories Department- School of Health Sciences, Larisa, Greece

³University Hospital of Ioannina, Obstetrics and Gynecology Department, Ioannina, Greece

⁴University Hospital of Freiburg, Thoracic Surgery Department, Freiburg, Germany

Background

Adequate education in diagnostic and operative hysteroscopy should be a part of the training curriculum of all doctors, especially under a training position. A well-structured training program is essential not only for the surgeon but also for his working team. The aim of the study is to identify quantitative and qualitative aspects of efficacy of one endoscopic unit and through this, to evaluate the subjective and objective criteria in the evaluation and education of the hysteroscopist and the hysteroscopic team.

Methods

Nowadays in Greece, there is no systematic approach when it comes to the education and training skills in hysteroscopy. Furthermore, it is especially important that the process of education and evaluation contains inclusively all the members that participate, from the team of surgeons till the team of nurses and other personnel.

At the developing research have been included till now more than 80 cases of hysteroscopy with the participation of 3 doctors-hysteroscopists and more than 10 nurses.

The Objective Structured Assessment of Technical Skills (OSATS) are used in order to evaluate the theoretic and practical level of the surgeons and of the surgical team involved:

- Initial classification of the participants hysteroscopists and other personnel based on the already gained theoretical and practical knowledge and experience.
- The correlation of hysteroscopic with the pathological diagnosis.
- The number of hysteroscopies performed analogically to the kind of procedure (diagnostic, operative).
- The time of the procedure.
- The cumulative path length.
- The overall quantity of the distension media in use during the procedure.
- The frequency of the loss of the surgical site and the loss of the navigation.
- The frequency of complications.
- The pitfalls during hysteroscopy.
- The use of distension of the cervix as a tool prior to hysteroscopy.
- The need for post-operative analgesia.

Moreover, the surgical team and hysteroscopists would be evaluated vice versa as well as self-evaluated at the end of the procedure. All the data above will be collected, stored and processed statistically and temporally.

Results

The data so far demonstrates the validity of these objective criteria. The progress of the learning curve of training in hysteroscopy is well-documented and demonstrated in relation to these criteria. This curriculum also shows common pitfalls during hysteroscopy that could be taken into consideration for future progress.

Conclusions

This training protocol-curriculum could potentially offer a well-structured training system aiming to the improvement of the technique and the thorough evaluation of the participants. Last but not least, through these questionnaires, audits could be conducted in order to improve the technique and increase its efficacy.

ES28-0106 - P085
E-Poster

Clinical application value of the methylated PAX1 gene at type 3 transformation zone patients: the non-invasive strategy for colposcopy unsatisfactory patients

Wei Zhang¹

¹Zhongnan Hospital of Wuhan University, Obstetrics and Gynecology, Wuhan, China

Background

It is difficult to diagnosis the cervical lesion of type 3 transformation zone (TZ) by colposcopic examination or colposcopy directed punch biopsy. The object of the study is to decrease the missed diagnosis of cervical neoplasia from colposcopy unsatisfactory patients using, the non-invasive method, methylated *PAX1* gene (*PAX1^m*) detected from the residual cervical cells.

Methods

The colposcopy unsatisfactory patients were enrolled for the study. The inclusion criteria were female with age ≥ 20 and sexual experience. The exclusion criteria included: women had history of cancer related to reproductive tract, had therapy for cervical lesions, had received HPV vaccination or at pregnancy. *PAX1^m* was determined by using Q-PCR. HPV genotyping was determined by cobas 4800 (Roche, Germany). Sensitivity, specificity, and accuracy for cytology, hrHPV, and *PAX1^m* level were analyzed.

Results

The TZ of cervix moves to the cervical canal with the increase of age, fluctuation and decline of hormone levels and so on. Neither naked eye nor colposcopy can observe the complete TZ is unsatisfactory. Almost all cervical lesions develop within the cervical TZ, identification of the entire/partial TZ and the squamous columnar junction (SCJ) as its upper limit is a crucial step in cervical cancer prevention.

Total 105 colposcopy unsatisfactory patients were enrolled and analyzed in the study. The final diagnosis was confirmed by histological reports which was from colposcopy directed biopsy, conization or 6 month follow-up. The results showed that the *PAX1^m* was significantly high with CIN3 and worse lesions than those with CIN1, CIN2, and normal cervix ($P < 0.0001$). The sensitivity and specificity of *PAX1^m* (CIN3+ detection by pathology results) were both higher than 80%, respective. Compared to the efficacy of cytology results were 84% specificity but with lower sensitivity (less than 50%). The sensitivity of hrHPV testing was more than 90% but low in specificity. The pathology results of punch biopsy were more than 95% specificity but less than 40% sensitivity, respective.

Conclusions

Conization of cervix, dual role of diagnosis and therapy, is one of the main treatment methods of cervical precancerous lesions. Most of the missed diagnosis of cervical lesion at colposcope examination were type 3 TZ form.

The current results indicated that the *PAX1^m* real time PCR-based testing from the residual cervical cells is promising for cervical neoplasia CIN3+ detection for colposcopy unsatisfactory patients.

ES28-0111 - P087
E-Poster

Repercussion of training in the implantation of laparoscopic surgery in gynaecology

Belén Moreno-Naranjo¹, Idoia Díaz-Güemes², Blanca Fernández-Tomé¹, Miguel Ángel Sánchez-Hurtado¹, Javier Sáchez-Fernández³, Francisco Miguel Sánchez-Margallo⁴

¹Jesús Usón Minimally Invasive Surgery Centre, Laparoscopic Department, Cáceres, Spain

²Jesús Usón Minimally Invasive Surgery Centre, Laparoscopic Department Coordinator, Cáceres, Spain

³Jesús Usón Minimally Invasive Surgery Centre, Training Coordinator & Quality Assurance, Cáceres, Spain

⁴Jesús Usón Minimally Invasive Surgery Centre, Scientific Director, Cáceres, Spain

Background

During more than 20 years in the *Jesús Usón Minimally Invasive Surgery Centre (JUMISC)*, training activities in the field of gynaecology aimed at learning laparoscopic surgery have been developed. The goal of our work was to evaluate the usefulness of our courses as a shuttle to establish laparoscopic surgery as the approach of choice in hospitals in our country

Methods

At the beginning of the year 2019 a survey was developed through the survey monkey platform. The survey consisted of 22 items divided into three blocks: population, training and experience in laparoscopic surgery. A total of 365 emails were sent to the participants of the courses developed in our centre between the years 2010 and 2018.

Results

The response rate was 25%, although only 73% fully completed the survey. Regarding the training in minimally invasive surgery that they have, 45.07% of the respondents indicated the option of "hands-on experimental model" compared to 19.72% that have a pelvitrainer course or the 16.90% that have of a Master. Even so, 66.67% of the respondents considered it necessary to expand their training. And among the most valued options as training elements, they pointed out the pelvitrainer, the theory and the combination of theory, pelvitrainer and practice in experimental model. In this sense, it is of interest that 72.22% of the respondents confirmed that they do not have any means of training in CL in their respective hospitals, which makes it necessary the existence of training centres where surgeons can acquire knowledge and improve their skills. 84.51% already performed CL before going to the JUMISC course and 84.29% of them agreed that the training received during the course had improved their ability and confidence when performing the procedures. However, 66.67% considered it necessary to expand their knowledge in advanced techniques before implementing them in clinical practice.

Conclusions

Training sessions taught in our courses help to reduce the learning curve in different procedures improving the skills and confidence of the surgeon before applying them in clinical practice.

<https://esge.covr.be/cmdocumentmanagement/conferencemanager/documents/api/getdocument/4950/cmabstsms/000048170/7d1eb37bbd393a487d27596123b854d0c440b77e4297c633fee7b9f20bc91231>

ES28-0117 - P088

E-Poster

Patient satisfaction survey with Myosure in ambulatory setting

Anita Dutta¹

¹Broomfield Hospital -Mid Essex Hospital NHS Trust Essex United Kingdom, Gynaecology, Chelmsford, United Kingdom

Background

To assess patient experience and pain score for the use of Myosure in the outpatient setting.

Methods

A survey of patient experience and pain score was undertaken following the Myosure procedure in the outpatient. An 8 -itemed anonymous questionnaire was retrospectively handed to all women (n = 31) attending the ambulatory hysteroscopy service at the Mid Essex Hospital Trust (MEHT), UK from 1st March 2018 to 31st March 2019. Women were asked to complete the questionnaire immediately after the procedure.

Results

Following the procedure, patients were asked to record the worst pain on a visual analogue scale from 0 (no pain) to 10 (worst pain possible). Women who completed and returned the questionnaires: N=33. All women (N=33) stated they will have the same procedure repeated in the future if clinically needed and all would recommend it to their friends. All women affirmed that the staffs were welcoming and supportive, the procedure was well explained and dignity was maintained during the procedure 21 women recorded an overall pain score of less than 5, 11 reported a score 5 -8. Although 1 woman described the pain experienced during the procedure to be severe (score>8), the pain was transient and settled quickly

Pain Score of 5 =21	65.6%
Acceptability=33	100%
Staff feedback=33	100%
Recommend to friend =33	100%

Conclusions

Office diagnostic and use of Myosure resection is associated with high overall satisfaction rate. Our study illustrates that appropriate communication: verbal & written and trained and supportive staff contributed to the successful outcome.

<https://esge.covr.be/cmdocumentmanagement/conferencemanager/documents/api/getdocument/5290/cmabstsms/00145460/42e3fd34b69224a280a060818e345cb5fd77d5f187ec65088f60399296757f3b>

ES28-0131 - P090

E-Poster

Endometrial stromal sarcoma presented as endometrial polyp: a rare case

Angelos Daniilidis¹, Anastasios Limperis², Roxani Dampali¹, Panagiotis Papandreou³, Konstantinos Dinas¹, Alexis Papanikolaou¹

¹Hippokratio General Hospital Aristotle University, 2nd university Department of Obstetrics and Gynecology, Thessaloniki, Greece

²Hippokratio General Hospital Aristotle University, 2nd University Clinic in Obstetrics and Gynecology, Thessaloniki, Greece

Background

The presence of uterine sarcoma in young 40 years old women is quite rare. Preoperative diagnosis is usually difficult and demanding. We report an uncommon case of a 40-years-old woman who presented with irregular vaginal bleeding. The clinical impression was that of an endometrial polyp, whereas histological examination showed endometrial stromal sarcoma (ESS) .

Methods

A 40-year old woman was referred to our centre due to abnormal vaginal bleeding. The transvaginal ultrasound examination suggested a large endometrial polyp and its hysteroscopic removal was scheduled. Grossly, the tumor measured 3x2x2cm and was a well circumscribed, lobulated and capsulated pedunculated oval mass. Although the hysteroscopic impression was that of an endometrial polyp and it was removed with monopolar resectoscope, the histological examination showed ESS and total hysterectomy with bilateral salpingo-oophorectomy was performed following histology.

Results

Total hysterectomy with bilateral salpingo-oophorectomy was performed laparoscopically with no intraoperative or postoperative complications. The patient opted for adnexectomy also. The final histological examination showed no residual disease, implying that the tumor was totally resected during hysteroscopy

Conclusions

ESS is the second most common malignant uterine mesenchymal tumor and is said to account for approximately 10-15% of all uterine sarcomas. Generally, sarcomas make up for approximately 3-7% of all uterine cancers and only 1% of all female genital tract malignancies. ESSs usually affect middle-aged women and commonly manifest as abnormal uterine bleeding, an enlarged uterus or pelvic pain.

The case report highlights that ESS is to be included in the differential diagnosis of endometrial polyp though rare.

<https://esge.covr.be/cmdocumentmanagement/conferencemanager/documents/api/getdocument/4913/cmabstsms/000044250/93de0e1cb99ca8aa307f41dfdcfefc2d443646c8d3df141d80635b9804f9fb05>

Should all endometriotic cysts be removed? How, why, when? A narrative review of the literature

Angelos Daniilidis¹, Panagiotis Papandreou¹, Evangelia Mareti¹, Christos Michalopoulos¹, Alexis Papanikolaou¹, Konstantinos Dinas¹

¹Hippokratio General Hospital Aristotle University, 2nd University Department of Obstetrics and Gynecology, Thessaloniki, Greece

Background

Treatment of endometriomas is always a challenge for physicians. A lot of issues should be taken into account before deciding treatment or not.

The present review of recent published articles aims to clarify some gray areas regarding clinical decisions and endometriotic cysts. How significant is actually the size of the cyst, should they be removed in order to improve fecundity rates or ART (artificial reproductive treatment)? Lastly is there really a risk of malignancy to justify surgical removal in all cases?

Methods

All relevant literature on the aforementioned subject written in English language the last 10 years and published in PubMed has been reviewed for this paper.

Results

Size of endometrioma less than 3 cm should not be routinely surgically removed before ART, unless there are other symptoms like pain in present. It seems that endometriosis increases the risk of ovarian cancer in women up to 1.9%, while for histological cancer-related subtypes, such as endometrioid and clear cell carcinoma, the risk is doubled and tripled respectively. At the same time, the risk of precancerous cellular atypia in endometriomas amounts to 1-3%. Therefore, counselling for women in the perimenopausal age over 45 years with typical benign endometriomas less than 5 cm, should include the alternatives of both surgical treatment and conservative progesterone therapy in combination with regular monitoring. Surgical treatment, including removal of the ovaries suffering from endometriosis and bilateral salpingectomy, significantly reduces the risk of ovarian cancer. For women with a history of endometriosis, with no active disease in their ovaries, the majority should be directed to conservative progesterone treatment and regular monitoring unless there are high-risk factors in their history for developing ovarian malignancy. In this case, bilateral salphingo-ophorectomy is recommended.

Conclusions

Regarding fertility treatment in a disease so diverse like endometriosis a personalized approach should be considered according to the patient's needs, history, age other fertility factors, social and economic status and religion. Proper surgical treatment will enhance fecundity in a lot of cases, while routinely removal of endometrioma before ART cannot be justified just to improve assisted reproductive outcome. Preservation of healthy ovarian tissue is of outmost importance and thus should be taken into account before counselling for an operation and choosing the appropriate technique. Overall, endometriosis patients above 45 may be at higher risk of cancer. We need more well-designed research with validated and detailed data, particularly on subtypes, in order to minimize bias and produce clear answers.

<https://esge.covr.be/cmdocumentmanagement/conferencemanager/documents/api/getdocument/4912/cmabstms/000044250/cd0c13897e427b5094a97ed746eeae1d1b29f8dd905936805e81b3fe7dc65b2>

Sjögren syndrome as an independent factor for abdominal adhesions: a case report and review of the literature

Angelos Daniilidis¹, George Pratilas¹, Antonios Goutzioulis¹, Nikolaos Tsambazis¹, Vanta Sardaridou¹, Konstantinos Dinas¹

¹Hippokratio General Hospital Aristotle University, 2nd University Department of Obstetrics and Gynaecology, Thessaloniki, Greece

Background

Sjögren syndrome is a systemic chronic inflammatory disorder characterized by lymphocytic infiltrates in exocrine organs. The disorder mostly affects women (50 to 60 years old). Most individuals with Sjögren syndrome present with sicca symptoms, such as xerophthalmia (dry eyes), xerostomia (dry mouth) and parotid gland enlargement. Other extra glandular features may develop such as arthralgia, arthritis, myalgia, gastrointestinal disease, anemia, neuropathy, renal tubular acidosis, raynaud phenomenon, pulmonary disease, leucopenia, lymphadenopathy, vasculitis and lymphoma. Complications related to Sjögren syndrome include systemic lupus erythematosus (SLE) and rheumatoid arthritis (RA), infection of the parotid gland, typically staphylococcal, streptococcal, or pneumococcal, emergence of parotid tumors, fetal loss in pregnant patients with antiRo/SS-A antibodies, emergence of pseudolymphomas and non-Hodgkin B-cell lymphomas.

We present a case of incidental finding of extensive intraabdominal adhesions during laparoscopic adnexectomy, in a patient with Sjögren syndrome and no history of operations or sexually transmitted diseases.

Methods

We report a case of a para 1-normal delivery 50 years old married woman with known Sjögren syndrome. She did not have any other past medical history and was not a smoker. Most importantly she did not have any prior abdominal surgery. The patient suffered from benign looking unilateral ovarian cyst of 8 cm and was scheduled for an elective laparoscopic adnexectomy.

Results

As per protocol we performed pneumoperitoneum via palmer point. During laparoscopy extensive thick intraabdominal adhesions between the omentum and peritoneum covering practically the entire pelvis and the abdomen above the level of the umbilicus were recognized. Extensive adhesiolysis had to be performed with bipolar and scissors prior completing laparoscopic adnexectomy.

Conclusions

This case report has led us to question whether Sjögren syndrome and the occurrence of adhesions, like the ones we encountered, can be connected. Relevant research of PubMed and Scopus databases revealed no similar cases reported. Also by researching classical textbooks there was no connection between the two medical entities. Thus we believe that there is a need for further investigation, regarding the pathophysiology and the pathogenetic path which could connect the occurrence of intraabdominal adhesions with the Sjögren syndrome either directly or indirectly as an independent factor.

<https://esge.covr.be/cmdocumentmanagement/conferencemanager/documents/api/getdocument/4911/cmabstsms/000044250/bd71d3863c3c63b3cfa8f4000505761d0f0168e77dfb7426edb52d1c99b8f41f>

ES28-0136 - P093

E-Poster

Surgical management of cervical pregnancy

*Istvan Szabo*¹

¹Semmelweis University, Department of Obstetrics and Gynecology, Budapest, Hungary

Background

Due to the popularity of IVF procedures, the number of reports about cervical pregnancy is increasing. Beside the conservative treatments, such as using the Folinic acid antagonist methotrexate, there are some cases which require a skilled surgeon in the management of this unusual but potentially life-threatening complication of pregnancy.

Methods

We are reporting one case of cervical pregnancy, diagnosed in the first trimester. The patient was admitted to our clinic from a public hospital with the diagnosis of an intact cervical pregnancy (9th gestational week). The patient expressed desire to maintain her reproductive capability. We attempted to treat the patient conservatively, but it was unsuccessful. We decided to manage the case on the surgical way by doing an interruption under laparoscopic surveillance. We review the steps of the laparoscopic procedure required to the unique cervical surgical interventions including in the rare cases of cervical pregnancy.

Results

The patient was successfully operated and we were able to emit her on the third post operative day. In a year after the surgery she became pregnant and delivered by caesarean section on the 39,G.w.

Conclusions

The suggested steps of the laparoscopic procedure required to the unique cervical surgical interventions (including cervical fibroid, cervical pregnancy, caesarean section scar pathologies...) can be useful in gynaecological surgical practice.

ES28-0137 - P094

E-Poster

Conservative therapies of endometriosis: a narrative review and comparison of eight guidelines

*Angelos Daniilidis*¹, *Dimitrios Rafail Kalaitzopoulos*², *Evangelia Mareti*¹, *Georgios Kolovos*³, *Eleftherios Pierre Samartzis*⁴, *Konstantinos Dinas*¹

¹Hippokratio General Hospital Aristotle University, 2nd University Department of Obstetrics and Gynecology, Thessaloniki, Greece

²Department of Gynecology and Obstetrics-Canton Hospital Schaffhausen-Switzerland, Department of Gynecology and Obstetrics-Canton Hospital, Schaffhausen, Switzerland

³National and Kapodistrian University of Athens, Medical School, Athens, Greece

⁴University Hospital Zurich, Department of Gynecology- University Hospital Zurich, Zurich, Switzerland

Background

Endometriosis, the presence of endometrial-like tissue outside the uterus, is a common clinical entity between women of reproductive age, with a prevalence of 5-10%. Because of the variety of endometriosis-associated symptoms there are different conservative strategies.

The aim of this narrative review is to give an uptodate view of the now available conservative therapies (medical, surgical and non-medical) of endometriosis and to critically present and find out the discrepancies between the widely used guidelines of the 8 national and international societies.

Methods

6 nationals (College National des Gynecologues et Obstetriciens Francais, National German Guideline (S2k), Society of Obstetricians and Gynaecologists of Canada, American College of Obstetricians (ACOG) and Gynecologists, American Society for Reproductive Medicine and National Institute for Health and Care) and 2 international (World Endometriosis Society, European Society of Human Reproduction and Embryology) guidelines are included in this review. Search for eligible studies was conducted in threeselectronic databases, MEDLINE, EMBASE and CINAHL, for original human research published in any language.

Results

All the above guidelines agree that the combined oral contraceptive pill, progestagens and GnRH are recommended for endometriosis associated pain and that surgery improves fertility in patients with endometriosis-associated subfertility.

Conclusions

The majority of the discrepancies between the recommendations are in second line and supplementary therapies of endometriosis.

<https://esge.covr.be/cmdocumentmanagement/conferencemanager/documents/api/getdocument/4910/cmabstsms/000044250/8da9e2c8cb41e11ac5359476f0a51c67a719192b9cb5a1b0056448c48bd99567>

ES28-0141 - P095

E-Poster

Large disseminated leiomyoma of the appendix after laparoscopic myomectomy with morcellation

Eleni Karatrasoglou¹, Vasiliki Hatzirafail¹, Alikei Tserkezoglou¹, Gerasimoula Thomou¹

¹Euroclinic Hospital, Department of Gynecologic Surgery, Athens, Greece

Background

We describe the case of a parasitic myoma of the appendix in a patient with previous history of laparoscopic myomectomy and power morcellation without the use of containment bag

Methods

Case report

Results

Patient with a previous history of laparoscopic myomectomy with the use of morcellator, reported abdominal pain, bulk symptoms and sexual dysfunction. 12 years post-myomectomy, the findings, indicated a 7 cm heterogeneous and well limited pelvic mass, that seemed attached to the right ovary. The patient underwent diagnostic laparoscopy which revealed a 7 cm tumour of the appendix. There were no remarkable findings from the uterus and the adnexa. The appendix including the tumour was removed intact from the abdominal cavity with the use of an endobag. The histology revealed a typical leiomyoma

Conclusions

Parasitic leiomyomas of the appendix are a rather rare complication combined with power morcellation during laparoscopic myomectomy. Caution should be taken during morcellation in order to prevent excessive fragmentation of the tissue, which could be implanted in various areas of the abdominal cavity and result to parasitic myomas. Whenever possible, the use of a containment bag is required.

<https://esge.covr.be/cmdocumentmanagement/conferencemanager/documents/api/getdocument/4933/cmabstsms/00165080/ea8a222c3d685c82b63eebd3e3af089c21a8fc7aa7d076b3b0b722bc753d594a>

ES28-0151 - P096

E-Poster

Ulipristal acetate for adenomyosis: a multicentre randomized trial

Perrine Capmas¹, Jean Luc Brun², Guillaume Legendre³, Martin Koskas⁴, philippe merviel⁵, Herve Fernandez¹

¹Hopital Bicetre, Gynecologie, Le Kremlin Bicetre, France

²CHU Bordeaux, Gynecologic Department, Bordeaux, France

³CHU Angers, Gynecologic Department, Angers, France

⁴Hopital Bichat, Gynecologic Department, Paris, France

⁵CHU Amiens, Gynecologic Department, Amiens, France

Background

Ulipristal acetate has been demonstrated to be useful in the management of abnormal uterine bleeding due to myoma. Some preclinical data on animals showed interesting results of selective progesterone receptor mediators in adenomyosis. Aim of this study is to evaluate efficacy of a 3 months course of ulipristal acetate on abnormal uterine bleeding in adenomyosis.

Methods

This multicentre randomized trial with a 3:1 ratio took place in five different teaching hospitals. Women with adenomyosis confirmed on MRI or sonography and abnormal uterine bleeding with PBAC score more than 100 were included in this study. They were then randomly assigned for a 3 months course of either 10mg Ulipristal acetate or a placebo. Main objective was the rate of women with a PBAC score under 75 after 3 months of treatment. The secondary objectives included rate of PBAC score under 75 at 6 months, rate of amenorrhea at 3 and 6 months, evolution of the pain and of the quality of life at 3 and 6 months and finally, tolerance.

Results

Forty women were included, 30 in the UPA group and 10 in the placebo group. The two groups were comparable particularly for PBAC score and analgesic consumption before the treatment.

At 3 months, none of the women in the placebo group had a PBAC score under 75 whereas, 95.2% of the women in the UPA group had a PBAC score under 75 ($p < 0.01$). At 6 months, there was not anymore significant difference for rate of PABC score under 75 in the two groups. The rate of amenorrhea was also significantly higher at three months (95% versus 0%, $p < 0.01$). At 3 months, a significant decrease in pain was observed in the UPA group ($p < 0.01$) but not at 6 months. There was no significant difference between groups for quality of life.

Tolerance was good, no hepatic disorders were found in this study.

Conclusions

Ulipristal acetate seems to stop abnormal uterine bleeding due to adenomyosis but also pain during a three months course but both of these symptoms reappeared at the stop of the medication. Other studies are needed to conclude and to try different doses.

<https://esge.covr.be/cmdocumentmanagement/conferencemanager/documents/api/getdocument/5274/cmabstsms/000072200/a95bf132a0c6b11baaffaef60c63c80c35559ff4884a940470d9e4559ce20157>

ES28-0205 - P097

E-Poster

Pyomyoma with tubo-ovarian abscess managed by laparoscopic procedure - a case report

Tepei Suzuki¹, Takuji Ueno¹, Takuma Yamada¹, Takehiko Takeda¹, Yasuyuki Kishigami¹, Hidenori Oguchi¹

¹Toyota Memorial Hospital, Obstetrics and Gynecology, Aichi, Japan

Background

Pyomyoma (suppurative leiomyoma of the uterus) is a rare condition resulting from infection of a leiomyoma. It is more usual in perinatal period, after uterine artery embolization, or while using intra uterine device. In this report, we present a case of pyomyoma without such risk factors.

Methods

Case

A 40 year-old G0P0 woman presented to our hospital with a 3-day history of fever. Her medical history included uterine myomas. Her blood pressure was 72/33 mmHg, pulse 97 bpm and temperature 38.9°C. Although there was no abdominal tenderness, she had the uterine and adnexal tenderness on pelvic examination. Blood cultures revealed the presence of *Escherichia coli*. CT scan and MR imaging revealed multiple uterine myomas and right tubo-ovarian abscess. On MR imaging, the largest myoma was 10 cm in diameter, inhomogeneous hypointense on T2-weighted images, hypointense on T1-weighted images, partially hyperintense on diffusion-weighted images and partially hypointense on apparent diffusion coefficient maps. We diagnosed degenerated myoma and right tubo-ovarian abscess. Despite antimicrobial therapy, her fever did not resolve. We performed laparoscopic surgery for the purpose of drainage of the abscess. Since it was assumed that the myoma would obstruct intraoperative view, we planned right salpingo-oophorectomy following myomectomy. When the myoma was dissected, large amount of pus flowed out. Pus was also pooled in right adnexa. We diagnosed pyomyoma and right tubo-ovarian abscess, and performed laparoscopic myomectomy and right salpingo-oophorectomy. Pathological findings showed pyomyoma and right tubo-ovarian abscess. Cultures of the pus revealed the presence of *Escherichia coli*. The postoperative course was uneventful.

Discussion

Pyomyoma is a rare condition that may cause sepsis and mortality. Although the intratumoral gas formation on CT scan may be suggestive of pyomyoma, it was not observed in our case. On MR imaging, the presence of hyperintensity on diffusion-weighted images and low apparent diffusion coefficient values may suggest the presence of pus in the pyomyoma.

Conclusions

The diagnosis of pyomyoma should be considered in women with tubo-ovarian abscess and uterine myomas. Surgical intervention including myomectomy or hysterectomy is the primary method of the treatment.

<https://esge.covr.be/cmdocumentmanagement/conferencemanager/documents/api/getdocument/5014/cmabstms/000071200/689f162fcf2a245da6b66ba777c530bbf6ebf04929294a5265c4f8597294d06c>

ES28-0283 - P098 E-Poster

Utility of the ninth-intercostal microlaparoscopic approach

Yu Kawasaki¹, Ayako Masuda², Rie Ozaki¹, Keisuke Murakami¹, Mari Kitade¹, Atsuo Itakura¹

¹*Juntendo University Graduate School of Medicine, Department of Obstetrics and Gynecology, Tokyo, Japan*

²*Juntendo University Graduate School of Medicine, Department of Obstetrics and Gynecology, Tokyo, Japan*

Background

The first incision to the umbilical region or below the umbilical ring in gynecologic laparoscopic surgery is often blind, putting the patient at risk of complications such as damage to organs or large blood vessels. At our facility, the "ninth-intercostal microlaparoscopic approach" in which the first incision is made to the ninth-intercostal space, where there are no parenchymal organs present and which can be punctured relatively easily, and where the insertion of ports into the umbilical fold can be performed under scope through the insertion of a thin-diameter scope, is adopted in patients in whom preoperative intraperitoneal adhesion is considered likely in order to avoid complications associated with the first incision. However, this method requires a certain amount of specific training. Moreover, the criteria required for adoption need to be clarified since preparatory activities, such as additional necessary devices, are needed.

Methods

We retrospectively investigated the cause of adhesions in patients on whom the ninth-intercostal microlaparoscopic approach was performed or who experienced periumbilical adhesions after undergoing cesarean section with the usual approach between January 2016 and December 2018.

Results

A total of 30 patients chose the ninth-intercostal incision approach, and periumbilical adhesions were observed in 5 out of the 30 patients, all of whom had prior surgeries. Although the ninth-intercostal microlaparoscopic approach was not adopted, there were 4 patients in whom adhesion was observed in the area around the umbilical region, 1 patient in whom the complication of urachal remnant was reported, and 3 patients with a prior history of surgery. Among patients in whom adhesion due to prior surgeries was recognized, the surgical wound was a median incision to the lower abdomen in 5 patients, the most prevalent prior surgical method was abdominal myomectomy in 3 patients, cesarean section in 2 patients, appendectomy in 2 patients and laparoscopic cholecystectomy in 1 patient. The postoperative course was good and intraoperative complications were not observed in all patients who underwent the ninth-intercostal microlaparoscopic approach. However, in patients in whom the approach was not adopted, the expected duration of surgery was longer and the patient with urachal remnants developed postoperative wound infection.

Conclusions

The ninth-intercostal microlaparoscopic approach is a very useful approach, particularly for patients who have previously undergone lower abdominal midline approach myomectomy or cesarean section, and those with urachal remnants.

<https://esge.covr.be/cmdocumentmanagement/conferencemanager/documents/api/getdocument/5083/cmabstsms/000165210/0b536ca7b0b3bc36ef5ea30bf9978cd79825506e0e577eeddf8d5527f05f76ac>

ES28-0165 - P099 E-Poster

New method of lifting uterus in laparoscopic radical hysterectomy: two level lifting by ligation without uterine manipulator-based on the principle of no tumors

*Jie Chen*¹

¹*Fujian Provincial People's Hospital, Gynecology Department, Fuzhou, China*

Background

Recent studies have shown that the traditional laparoscopic had lower tumour-free and overall survival rates, higher recurrence rates and higher fatality rates than the open abdominal group. This is an important warning for laparoscopic radical hysterectomy. The use of uterine manipulator may violate the principle of tumour-free surgery.

Methods

1. We give up using uterine manipulator and switch to using surgical suture to ligate the isthmus of uterus. We can control the uterus by traction during the procedure. This method provides a good exposure of parametrial tissues and can successfully perform surgical dissection.
2. Ligating the vagina to reduce cancer exposure to the pelvic cavity.

Results

After 30 cases of surgical operation, we could perform laparoscopic radical hysterectomy well with no-uterine manipulator procedure. The length of the vagina and the width of the parametrium were all up to standard.

Conclusions

This method reflects the tumor free surgical principle. Maybe these are the two key steps to safely perform laparoscopic radical hysterectomy.

The effectiveness of laparoscopic surgery theoretical training for junior gynaecology trainees

Hajeb Kamali¹, Susannah Hogg¹, Sophie Moloney-Geany¹, Christy Burden², Jessica Preshaw¹

¹Southmead Hospital- North Bristol NHS Trust, Department of Gynaecology, Bristol, United Kingdom

²University of Bristol, Women's Health, Bristol, United Kingdom

Background

To assess the effectiveness of a theoretical teaching component within a basic laparoscopic surgery (LS) course.

Methods

Obstetrics and Gynaecology trainees attending a one-day course entitled 'Essential Laparoscopic Skills' (ELS) comprising both a theoretical and practical element, in the South West of England were assessed before and after the course on their theoretical knowledge.

A research derived curriculum (1) comprising of 4 key component areas covering the basics of laparoscopic surgery (pre-operative, theatre, operative and theory of operations) was used to dictate the content of the theoretical educational material. Adopting an interactive lecture-based approach, a faculty of senior Obstetricians and Gynaecologists delivered teaching on pre-operative considerations of LS, laparoscopic entry, energy and performing a pelvic survey in group sizes of up to 10 trainees at a time.

Trainees completed a multiple-choice question (MCQ) test before and directly after the ELS course. The test consisted of 12 questions based wholly around content delivered during the theoretical component of the course.

Results were collated across 5 separate sessions attended by trainees new to the course each time. Teaching material and faculty remained consistent across all sessions. There was an equal spread of trainee experience across all sessions from year one to three training grades.

Results

In total, 40 tests were included in the analysis. Out of a maximum of 12, scores ranged from 4 to 12 and 10 to 12 for pre and post-test scores respectively. Interquartile range was 3 for pre-test and 1 for post-test scores. The mean pre-test score increased from 9.35 to 11.6 post-test while the median increased from 9.5 to 12. The median individual improvement in test score was 2.

A non-parametric analysis performed using Wilcoxon matched-pairs signed rank test revealed a statistically significant improvement in median test scores following training with $p < 0.0001$.

Conclusions

There was a statistically significant improvement in median test scores following attendance at the course with an improvement in mean score of approximately 20%. Importantly, the reduction in range and interquartile range following teaching suggests improved consistency and standardisation in knowledge level amongst trainees of similar grade following training.

Given the test questions were based on content of the teaching material, these results serve as firm reassurance that the teaching was effective in delivering this theoretical content. Furthermore, given that the content was based around a research derived curriculum created using a modified Delphi method of national experts, it is hoped that this improvement in theoretical knowledge will translate to improvement in clinical care.

Further work will focus on the retention of this knowledge, the direct impact this has on daily clinical practice and exploration of alternative methods for evaluating deeper learning and knowledge application of gynaecology trainees attending this course.

Obstacles in initial experience of transvaginal natural orifice transluminal endoscopic surgery (NOTES) total hysterectomy

Ferry Darmawan¹, Ichnandy Arief Rachman¹, Surya Adi Pramono¹, Gunawan Dwi Prayitno¹, Sita Ayu Arumi¹, Rizka Yurianda¹

¹Indonesia Army Central Hospital Gatot Soebroto, Obstetrics & Gynecology, Jakarta, Indonesia

Background

Transvaginal natural orifice transluminal endoscopic surgery (NOTES) had been performed as an approach for total hysterectomy that came with benefit in aesthetics, less pain, and less length of hospital stay. This technique required new learning curve. In mastering NOTES total hysterectomy, there were some obstacles that need to be managed and evaluated. The aim of this study is to identify the obstacles and to evaluate how to manage and prevent problems from the initial experience of NOTES total hysterectomy.

Methods

This was the first ten case series of NOTES total hysterectomy performed in Indonesia. All NOTES total hysterectomy procedures were performed using manufactured glove port system, reusable conventional laparoscopic instrument and smart bipolar. All cases were evaluated retrospectively.

Results

The mean operation time was 91.2 (65 – 125) minutes. Blood loss was 110.5 (75 – 150) ml. No complications found in all procedures. Visual analog score on day-1 post operation was 1.4 (1 - 3) with NSAIDs therapy. All patients were discharged from hospital one day after surgery. One procedure was attributed with single incision laparoscopic surgery. Obstacles were evaluated.

NOTES total hysterectomy procedures that consumed more than 90 minutes of surgery were adenomyosis cases, cases with history of cesarean section and a case that using curved flexible smart bipolar. In case of adenomyosis, the shape of uterus and adhesions limited the space for operation therefore consumed more time.

One case of 750-grams-adenomyosis needed evaluation by single port laparoscopy. There was abdominal distension caused by suspected bowel injury during operation. After evaluation, it was found out the distension only caused by gas entrapment in the abdomen caused by the ball-valve phenomenon of the uterus itself.

Another time consuming operation were two cases with prior C-section. In prevention of bladder injury, anterior colpotomy were performed under direct vision of camera. These procedures considered safe but consumed more time than performing direct anterior colpotomy before insertion of the glove port. The use of flexible smart bipolar was also considered consume more time. This device was more penetrable but less effective because sealed less and less handy than the straight smart bipolar.

Conclusions

NOTES total hysterectomy is feasible but need learning curve. Obstacles can be found in process of mastering NOTES total hysterectomy. Good case selection is essential to start NOTES total hysterectomy procedures. Avoid adhesion and adenomyosis case. The cases with no prior operation are good candidate for initial experience. The use of smart bipolar is also considered helpful and effective in NOTES total hysterectomy.

<https://esge.covr.be/cmdocumentmanagement/conferencemanager/documents/api/getdocument/5183/cmabstsms/000143840/957e7b58f32b780354838984cb185cd1044a2c1fe58667de4035f8d74aa272d1>

ES28-0175 - P104

E-Poster

Robotics in gynaecological surgery: experience of a tertiary gynaecological oncology referral centre

Georgios Grigoriadis¹, Susanne Booth¹, Sarah Robertson¹, Gediminas Juknevicus², Theodoros Giannopoulos¹

¹Hull University Teaching Hospitals NHS Trust, Gynaecological Oncology, Hull, United Kingdom

²Hull University Teaching Hospitals NHS Trust, Anaesthetics, Hull, United Kingdom

Background

The use of robotics in gynaecological surgery has gained increasing popularity in recent years. The indications for its use include benign hysterectomy, myomectomy, tubal re-anastomosis, radical hysterectomy, lymphadenectomy and sacrocolpopexy. Evidence supports the feasibility of this surgical approach. We describe our 3-year experience with the use of the DaVinci Intuitive Surgical System®.

Methods

We retrospectively reviewed the electronic medical records of all patients that underwent gynaecological surgery using the DaVinci Intuitive Surgical System® between 2016 (start of use) and January 2019.

Results

We included a total of 134 patients. 92 cases were done for gynaecological malignancy, the majority of which (83) were endometrial malignancies. 42 cases were done for a variety of non-cancerous indications, most common of which (14) was persistent cervical dyskaryosis. 105 patients were post-menopausal. A variety of gynaecological procedures were performed, including hysterectomy and bilateral salpingectomy/ salpingo-oophorectomy, radical hysterectomy as well as lymphadenectomy/lymph-node sampling. All cases were performed by appropriately trained gynaecological oncologists with the assistance of a staff nurse or a doctor in training. Information on Body Mass Index was not available for all patients, however, 17 patients had Body Mass Index above 40, with the highest Body Mass Index being 68.

The overall conversion to laparotomy rate was 9.7% (13 out of 134 cases). 2 cases of uterine perforation by the RUMI II manipulator® and 2 cases of subcutaneous emphysema were noted. There were no major complications in our group of patients. The mean drop in Hb was 1.58 grams per decilitre (g/dL). No patients needed blood transfusion. The majority of patients (88) were discharged home on day 0-2.

Conclusions

Robotic surgery can be used safely for a variety of surgical procedures, both in benign gynaecology as well as gynaecological oncology. Our data support its feasibility and association with low complication rate, low conversion rate and early discharge.

<https://esge.covr.be/cmdocumentmanagement/conferencemanager/documents/api/getdocument/4973/cmabstsms/000108570/1e2aa78353791274a8f7a55006444e7f9cd6539f8563e82ac599812a9ae74ed2>

ES28-0456 - P105

E-Poster

Uterine and vaginal polyps as metastasis of renal clear cell adenocarcinoma: about two cases

Julien Bakenga¹, Genestie Catherine², Nivet Julien³

¹Clinique du Fief de Grimoire, Gynecologic Oncology, Poitiers, France

²Gustav Roussy, pathology, Villejuif, France

³Polyclinique de Poitiers, Urology, Poitiers, France

Background

Secondary cervical adenocarcinomas are most commonly seen in relation to the extension of primary endometrial adenocarcinoma

Metastatic tumors from other sites are rather uncommon and when seen, are most frequently from the ovaries, gastrointestinal tract or breast.

We report a case of renal cell carcinoma, clear cell variant, to cervix and to vagina which presented as a cervical polyp in post menopausal female

Methods

Those two clinical cases are fully described.
The first symptom was metrorrhagia.
In one case, a pediculated polyps was discovered in the cervix.
In the second case, the polyps was in the vagina.

Results

The pathology revealed a metastasis of possible renal origin.
A CT scan and MRI revealed a lower pole tumor of kidney.
Patients underwent for urologic nephrectomy.
Those two cases are described.
literature had been reviewed.

Conclusions

This cases seem to be only the fourth described in literature. Very bad prognosis seem to be related with the occurrence of vaginal or cervix metastasis in clear cell renal adenocarcinoma.

<https://esge.covr.be/cmdocumentmanagement/conferencemanager/documents/api/getdocument/5101/cmabstms/0000166290/72ea58f55aacb227b804a529defe6810374087e0943e3f8b7e23112d16f45800>

ES28-0181 - P106

E-Poster

Laparoscopic sacropexy correction of pelvic organ prolapse: retrospective review

Irene Lopez Carrasco¹, Elena Cabezas López², María Miró Matos³, Nerea Montero Pastor¹, Mónica Novelle García¹, Enrique Moratalla Bartolomé²

¹H M Hospitales Gine 4 Medical Team, Gynecology and Obstetrics, Madrid- Spain, Spain

²H M Hospitales Gine 4 medical team. Ramon y Cajal Hospital, Gynecology and Obstetrics, Madrid, Spain

³H M Hospitales Gynecology and Obstetrics, Madrid, Spain

Background

Pelvic prolapse is a common diagnosis. Laparoscopic correction technique is ideal to treat apical and anterior prolapse. The aim of this study is to assess the safety and outcomes of laparoscopic colposacropexy as a surgical treatment for pelvic organ prolapse.

Methods

The main objective of this technique is the reconstruction of the anatomic structures that normally hold in place the pelvic organs (the uterosacral and cardinal ligaments). A prolene mesh is used to attach the vaginal vault or the cervix to the sacral promontory.

Descriptive, retrospective analysis.

117 Patients undergoing laparoscopic sacropexies performed for apical prolapse correction between September 2014 and April 2019.

Results

117 women underwent laparoscopic sacropexy to correct symptomatic apical prolapse. The mean age at the intervention was 55,86 years and mean parity was 2.07 deliveries, 60,68% of women were multipara. Regarding previous gynaecologic operations, 13 patients (11,11%) had undergone previous hysterectomy (6 vaginals, 4 laparoscopies, 3 abdominals), and 5 patients had previous pelvic floor repair surgery because of pelvic organ prolapse: 3 anterior colporrhafies, one Total Prolift and one Manchester. Physical examination revealed that 77,35% had cystocele ³grade II, 90,56% hysterocele³grade II, rectocele and vault prolapse were less frequent 14,52% in both cases. 18 patients (15,38%) had undergone sacropexy with mesh attachment to the apex of the vagina, 97 (82.90%) to the cervix and 2 patients had peptoxia. The mean time required for the intervention was 135,37 minutes and the mean length of time admitted to the hospital was 2.4 days. Just two postoperative complications occurred, one

bladder damage and a retroperitoneal haematoma. Six months after surgery, the hit rate (prolapse grade < II) was 94% while the one year and two year follow-up revealed positive outcomes in 89.74% and 88.03%, respectively.

Conclusions

Laparoscopic sacropexy seems to be effective to correct apical prolapse as it has low rates of intraoperative complications and recurrences. However, further following-up should be done to generalize this technique.

<https://esge.covr.be/cmdocumentmanagement/conferencemanager/documents/api/getdocument/5197/cmabstms/00165300/e43e083fe1b5180bccce7069d3e01939ca56f01e3d4bb674084e8644f7eb3805>

ES28-0488 - P107

E-Poster

Recurrence and reoperation after laparoscopic myomectomy

Noriko Yamamoto¹, Chisato Noji¹, Hiroyuki Kobori¹

¹Medical Topia Soka Hospital, Department of Gynecology, Soka City, Japan

Background

Although laparoscopic myomectomy (LM) allows preservation of fertility, there is a risk of recurrence. Recurrence of leiomyoma causes many symptoms and sometimes requires reoperation. The aim of this study was to analyze the incidence and risk factors of recurrence and reoperation after LM.

Methods

Between January 2011 and December 2015, 745 patients underwent LM in our hospital. We evaluated 580 patients who could be followed up for 12 months. Recurrence was defined as the appearance of a leiomyoma node measuring > 2 cm on ultrasound examination.

Results

The mean duration of follow-up in this study was 49.8 months. The number of myomas removed per patient was 4.5, and the mean diameter of the myoma was 7.1 cm. Residual leiomyoma was identified in 83 patients, and five patients subsequently underwent reoperation [total laparoscopic hysterectomy (TLH), three; LM, one; and transcervical resection (TCR), one]. We noted 115 recurrences (23.1%) and 14 reoperations (2.8%) in 497 patients. The mean time to recurrence was 37.7 months and the mean time to reoperation was 60.6 months. The cumulative recurrence rate was 14.3% at 3 years and 32.3% at 5 years; the cumulative reoperation rate was 1.2% at 3 years and 2.5% at 5 years. We examined the following covariates: age (20's vs. 30's vs. 40's), history of delivery in the preoperative period, number of myomas removed (one vs. multiple), the maximum diameter of myoma (≤ 6 cm vs. ≥ 7 cm) and postoperative pregnancy. The recurrence rate was less with one myoma, myoma of ≤ 6 cm diameter, and postoperative pregnancy. There was no difference in the reoperation rate. The distribution of the 14 cases undergoing reoperation was as follows: three cases of LM, six cases of TCR, one case of LM + TCR, and four cases of TLH. The chief complaints at the time of reoperation were excessive menstruation and anemia (nine cases), dysmenorrhea (three cases), tumor regrowth (one case) and infertility (one case). The sites of recurrence were as follows: submucous myoma (five cases), submucous myoma + intramural myoma (four cases), submucous myoma + subserous myoma (two cases), intramural myoma (one case) and intramural myoma + subserous myoma (two cases).

Conclusions

Recurrence after LM was associated with the number of myomas removed, the maximum diameter of myomas and postoperative pregnancy. However, there was no fixed trend for reoperation. Therefore, the findings at the time of recurrence of uterine fibroids are important.

<https://esge.covr.be/cmdocumentmanagement/conferencemanager/documents/api/getdocument/5007/cmabstms/00150590/d1a2f9cf2d1237aa435bec8a33e94a69a66d327f7eaa190b8ca4b9b695357970>

ES28-0190 - P108

E-Poster

Oncologic outcomes of laparoscopic radical trachelectomy versus laparoscopic radical hysterectomy for early-stage cervical cancer

Ju-Hyun Kim¹, Jeong-Yeol Park¹, Dae-Yeon Kim¹, Jong-Hyeok Kim¹, Yong-Man Kim¹, Young-Tak Kim¹

¹Asan Medical Center, Obstetrics and Gynecology, Seoul, Korea- Republic Of

Background

We aimed to compare the oncologic outcomes between laparoscopic radical trachelectomy (LRT) versus laparoscopic radical hysterectomy (LRH) for early-stage IB1 cervical cancer

Methods

Between 2011 and 2018, total 622 patients with FIGO stage IA2-IIA1 cervical cancer (CC) were initially surgically treated by laparoscopy in Asan Medical Center. The cases of prior neoadjuvant chemotherapy for CC or intraoperative converted laparotomy were excluded. Clinicopathological variables of the patients were retrospectively reviewed from electronic medical records. Survival curves were compared using the Kaplan–Meier method with log-rank test.

Results

All patients were divided into LRT (n=69) and LRH (n=563). The median follow-up period was 32.4 months (range, 2.5–85.1). Stage IB1 disease was the most common (67.0%). Between two group, there were no significantly different clinicopathologic characteristics. In tumor size \leq 2cm there was no significant difference in OS (94.4 % vs. 96.3%, p value=0.156) and DFS (97.2% vs. 98.5% p=0.698) between the LRT and LRH group. Moreover, in tumor size over 2cm below 4cm, LRT group has similar OS (86.6% vs. 86.4%, p=0.715) and DFS (100% vs. 92.5%, p=0.730) compared with LRH group.

Conclusions

In tumor size below 4cm in early-stage CC, oncologic outcomes are similar between LRT and LRH group. In selective CC patients, LRT could be a feasible and safe choice.

<https://esge.covr.be/cmdocumentmanagement/conferencemanager/documents/api/getdocument/5122/cmabstms/000092340/9eb352dd45aef94c3e6767fbb6a6c0f892da67a106b584cf84c167907932a1de>

ES28-0192 - P109

E-Poster

The preferred route of hysterectomy in women without pelvic organ prolapse in a poorly resourced setting

Andreas Chrysostomou¹, Dusan Djokovic²

¹Witwatersrand University, Obstetrics & Gynaecology, Johannesburg, South Africa

²Department of Obstetrics and Gynecology- Nova Medical School - Faculdade de Ciências Médicas- Nova University of Lisbon- Lisbon- Portugal, Obstetrics & Gynaecology, Portugal, Portugal

Background

This study was undertaken at the department of obstetrics and gynecology of the Charlotte Maxeke Johannesburg Academic Hospital to determine if the use of formal guidelines, a clinical decision algorithm tree and a standardized surgical technique as well as the incorporation of the guidelines into the resident training program would increase the rate of vaginal hysterectomy (VH) and result in an overall decline in open abdominal hysterectomy (AH).

Methods

All women admitted between July 2001 and December 2014 for hysterectomy due to benign conditions, meeting the guidelines criteria (vaginally accessible uterus and uterine size \leq 12 weeks of gestation or \leq 280 g), were included. The surgical route was determined using the study algorithm. In cases where the pathology was not confined to the uterus or success in VH was uncertain, laparoscopic assisted vaginal hysterectomy (LAVH) was performed. The VH procedures were performed by the residents in training, under the supervision of specialists with large experience in vaginal surgery. In addition to the patient characteristics and surgical approach to hysterectomy, length of hospital stay, intra-operative and immediate post-operative complications were also recorded and analyzed

Results

A total of 1272 patients were enrolled in the study. The most common indications were uterine fibroids, dysmenorrhea or abnormal uterine bleeding refractory to conservative treatment, cervical dysplasia and endometriosis causing pelvic pain. Before the beginning of the study, the percentage of VH was 9.8% and VH was mainly performed for utero-vaginal prolapse. Introducing formal guidelines, a clinical decision algorithm tree and a standardized surgical technique resulted in an increase in the rate of VH to 48.3% and overall decline in open AH from 91.2% to 51.7%. Thus, VH to AH ratio was 1:10 at the beginning and 1:2 the end of the study. A sharp increase in LAVH was observed from 2001 to 2004, where almost half of the VH were facilitated by the laparoscopic assistance. As experience was gained with the procedure, the total number of VH increased and a decrease in the need for LAVH was evidenced. All VHs were successfully accomplished without major complications

Conclusions

VH for non-prolapse uterus is a feasible and safe alternative for a large group of women predominantly operated via the abdominal route. The use of guidelines/clinical decision algorithms and standardized surgical technique may result in an increased number of VHs performed by the residents in training, as it was a case in our setting

<https://esge.covr.be/cmdocumentmanagement/conferencemanager/documents/api/getdocument/4971/cmabstsms/000031910/33b29850613d5ae21bccb54fd99380d5760dc923903aa8408e576669e9e1181b>

ES28-0194 - P110

E-Poster

Uteromap – a standardized method for measurement of the uterus as part of the preoperative work-up

Péter Török¹, Jakab Attila¹, Erdődi Balázs¹, Lampé Rudolf¹

¹UDMHSC, Obstetrics and Gynaecology, Debrecen, Hungary

Background

Uterine morphology is not uniform and ultrasound reports of gynecologic patients are diverse. However, in clinical situations (consultation, preoperative planning, during surgery) detailed parameters, dimensions, pathology location are important to reconstruct the situation. Our aim was to develop a new systematic way of ultrasound description of the uterus that is using predefined and standard values (Uteromap). This standardized method is more useful in planning the proper surgical procedure.

Methods

Normal gynecological ultrasonographic examination were performed in 30 cases, as the part of the gynecological examination in gynecologic ultrasound unit of a tertiary referral academic centre. All examinations and uterine descriptions were performed by expert sonographers. Then an independent examiner made the measurements according to the Uteromap. Briefly, Uteromap includes 9 values for general cases and 24 values for special pathologies. 3D volume served as controls, which was analyzed later off-line. Duration of both examinations were recorded, as well. Equipment used was Philips Affiniti.

Results

Compared to the 3D volume analysis, Uteromap records gave more accurate description and position of the focal uterine pathology and served more data about the uterus. The Uteromap parameters were reproducible in the 3D volumes. Duration of Uteromap measurements was not significantly longer after the tenth examination.

Conclusions

Standardized measurements using the Uteromap system during the transvaginal ultrasound examinations give more accurate description the uterine pathology morphometry. Uteromap is a reproducible and quick method for the accurate localization of focal uterine pathologies and description of malformations and minimize the interrater interpretations. It helps the surgeon to choose the proper way of surgery, to maintain the normal uterine cavity and wall.

<https://esge.covr.be/cmdocumentmanagement/conferencemanager/documents/api/getdocument/5074/cmabstsms/000046590/3e848ddf734c5d242494de75fa26084cc388d94bb71763f676ddb77b4e686688>

Laparoscopic treatment of deeply infiltrating endometriosis with diode laser: a pilot study

Maurizio D'Alterio¹, Alessandro Pontis², Luigi Nappi³, Felice Sorrentino³, Valeria Ghisu¹, Stefano Angioni¹

¹University of Cagliari, Surgical Science, Cagliari, Italy

²San Francesco Hospital, Obstetrics and Gynecology, Nuoro, Italy

³University of Foggia, Medical and Surgical Science, Foggia, Italy

Background

Deep infiltrating endometriosis is defined by the European Society of Human Reproduction and Embryology (ESHRE) as a peritoneal infiltration of more than 5 mm deep by the endometrial tissue. DIE frequently presents with nodules involving the rectovaginal space, the bladder, pelvic nerves, ureters, and/or the bowel and rarely other locations like abdominal wall or thorax. Many studies agree that surgical resection of DIE improves pain, quality of life. A wide range of surgical procedures may be adopted for the management of DIE in particular to perform excision of nodules from ureter and bowel. Cold scissor, plasma energy or CO₂ lasers have been proposed and it seems that in expert hands they achieve good results and low complications rates. Recently diode lasers have been proposed in endoscopic gynecological surgery. The aim of this study was to assess the feasibility, safety and efficacy of the diode laser in the treatment of deep infiltrating endometriosis.

Methods

This Pilot study included 25 women with DE diagnosed in the Endometriosis and Chronic pelvic pain Centre of the University of Cagliari between November 2017 and November 2018. Before the surgery they presented following symptoms: pregnancy wish, chronic pelvic pain, dysmenorrhea, dyspareunia, dyschezia, dysuria and 15 of them reported previous surgical treatments without employment. Clinical patient characteristics including age, body mass index (BMI), pre-surgical clinical staging, visual analog score for chronic pain measurement, comorbidity, prior abdominal surgery, and intraoperative parameters including operative time, blood loss, conversion rate, and complications were recorded. Postoperative parameters included short-term (within 30 days of the procedure) complications and length of hospital stay. Complications were measured by the Clavien-Dindo scale. In detail, during the laparoscopic surgery were performed using the DWLS, with a conic fiber of 1000 micron (Biolitec®, Leonardo®, wavelength of 980 nm and 1470 nm): 20 adhesiolysis, 20 uretolytic, 2 ureter stent, 10 cystectomy, 3 high rectosigmoid resection (with end-to-end anastomosis) and 15 resection of posterior fornix.

Results

Median patients' age was 31 (range 22–42), and body mass index was 23 kg/m² (range 21–33). The mean operative time was 155 min (range 112–175). No intraoperative complications and early complications (< 30 days) occurred, and all patients were discharged within 3 days mean (range 2-8 days) of surgery. Improvement of pain was statistically significant at three months follow-up.

Conclusions

Diode laser seems to be another useful device for endometriosis treatment. The shaving surgical approach with a diode laser system leads to a safe and effective laparoscopic dissection of deep endometriotic lesions. The results in term of efficacy and pregnancy outcomes need further larger randomized studies.

<https://esge.covr.be/cmdocumentmanagement/conferencemanager/documents/api/getdocument/4941/cmabstms/000073700/919dece299a2b47a0a2b4ca0fa0b7d294784660782ad6faec7eee5d8378fac4d>

"A track to the crack" - a new theory for the development of uterine niche

Sayed Elakhras¹, Mohamed Salama², Daa Abdelhalim³, Mohamed Elsemary³, Vasilios Tanos^{4,5}, Nafissa El-Badawy⁶

¹*Omam Hospital, Minimally invasive surgery, Cairo, Egypt*

²*Ain Shams Faculty of Medicine, Dept. of Obstetrics and Gynaecology, Cairo, Egypt*

³*Al Galaa Teaching Hospital, Dept. of Obstetrics and Gynaecology, Cairo, Egypt*

⁴*University of Nicosia- Medical School- and Aretaeio Hospital- Nicosia- Cyprus, Dept. of Obstetrics and Gynaecology, Nicosia, Cyprus*

⁵*Omam Hospital, Research and Development Dept., Cairo, Egypt*

⁶*Ain Shams Faculty of Medicine, Dept. of Pathology, Cairo, Egypt*

Background

Uterine niche is a defect of the myometrial continuity mostly following cesarean sections (CS). With the global rise of the rate of CS, uterine niches are increasingly being recognised as a problem.

Uterine niches can present with many symptoms, including post-menstrual and post-coital bleeding, recurrent vaginal discharge, pelvic pain and urinary symptoms.

Different etiologies were proposed as causes of this condition. The main etiology is suggested to be faulty healing of the uterine scar repair, leading to a myometrial defect. There is a debate in literature as to which uterine closure techniques best avoid the development of uterine niche.

We hereby propose a possible etiological factor for the development of uterine niches.

Methods

We hereby present a case series of observations in patients with post-CS uterine niches. In all of our patients in this series, dense uter-vesical adhesions are encountered, as well as uterine adhesions with the anterior abdominal wall. Upon dissection of these adhesions, we expose a track connecting the uterine niche deeper down, all the way to the anterior abdominal wall.

We perform dissection of this track, from the deepest part of the uterine niche, till the abdominal wall. Then, we freshen the edges of the scarred myometrium and resuture them either in 1 or 2 layers.

The uterine niche, the abdominal wall insertion site and the connecting track are all sent for histopathology.

Results

Histopathological examination of the specimens revealed the presence of myometrial and fibrous elements, along with endometriotic and adenomyotic tissues interdispersed within.

The post-operative courses of our patients ran smoothly and they experienced remarkable relief of their pre-surgery symptoms.

In our theory, faulty repair of the CS uterine incision, leads to leakage of endometrial tissue, blood and debris. This invites adhesion formation, that eventually result in a track being formed between the endometrial cavity and the deep layers of the abdominal wall. Along this track, endometriotic tissues implant, leading to the formation of uterine niche, focal adenomyosis and even parietal endometriosis of the deep layers of the anterior abdominal wall.

Conclusions

Improper repair of the uterine incision during cesarean section leads to the formation of an abnormal track, through which, endometriotic implants can find a way out of the uterus. Eventually, uterine niches, focal adenomyosis and even parietal endometriosis develop.

Proper techniques of uterine closure could prevent this sequence. Efficient surgical procedure to correct all these abnormalities when they develop result in remarkable symptomatic improvement for the patients.

Laparoscopic myomectomy for broad ligament fibroids

Alison Amoah¹, Stephen Quinn¹

¹Imperial College NHS Trust, Obstetrics and Gynaecology, London, United Kingdom

Background

Broad ligament fibroids are uncommon with an incidence of less than 1%. Preoperative identification of these fibroids can be difficult. Currently there is a paucity of literature that relates to surgical outcomes following laparoscopic myomectomy for broad ligament fibroids. It has not been fully elucidated as to whether resection of these fibroids at myomectomy is associated with worsened perioperative outcomes. There is particular concern regarding ureteric injury. Increasingly patients are opting for minimally-invasive uterine-sparing approaches for treatment of their fibroids. The aim of this study was to compare short-term surgical outcomes following laparoscopic myomectomy of patients with broad ligament fibroids versus patients with no broad ligament fibroids.

Methods

The study design was a retrospective case series. 16 patients were identified that underwent laparoscopic myomectomy for treatment of a broad ligament fibroid at a single centre between 2013 and 2019. 102 patients were identified during the same time period that underwent laparoscopic myomectomy not involving treatment of a broad ligament fibroid. Patient demographic data, clinical and fibroid imaging characteristics were collected in addition to operative procedure data and outcome data regarding operative time, estimated blood loss and length of postoperative stay. Descriptive statistics were carried out and Mann-Whitney U was carried out using SPSS to compare medians between the two groups. Statistical significance was defined as $p < 0.05$.

Results

For those with a broad ligament fibroid 86.7% presented with pressure symptoms and 40% heavy menstrual bleeding symptoms. Median size of broad ligament fibroid resected was 8cm (range 2-20cm). The range of number of all fibroids resected during myomectomy ranged from 2-8. One broad ligament fibroid was identified on pre-operative imaging. There were no cases of ureteric injury intraoperatively. There was no statistical difference between those with a broad ligament fibroid resected and those with no broad ligament resected in operative time (median 119 vs 123 minutes respectively; $p=0.280$), total fibroid weight resected (median 293 vs 301 grams respectively; $p=0.582$), estimated blood loss (median 150 vs 200 millilitres respectively; $p=0.176$) and length of stay (median 2 vs 2 days respectively; $p=0.698$).

Conclusions

We have shown that treatment of broad ligament fibroids by laparoscopic myomectomy can result in favourable short-term surgical outcomes. Further work should aim to collect outcome data prospectively and in regards to short-term and long-term outcomes.

<https://esge.covr.be/cmdocumentmanagement/conferencemanager/documents/api/getdocument/5176/cmabstms/000154350/c0cb9204dad7f5f9dd696f7245817f69956e7620c7cdfeaafe5141b192c7f5b5>

Allen Masters syndrome revisited

Sayed Elakhras¹, Mohamed Salama², Daa Abdelhalim³, Vasilios Tanos^{4,5}, Mohamed Elsemary³

¹*Omam Hospital, Minimally invasive surgery, Cairo, Egypt*

²*Ain Shams Faculty of Medicine, Dept. of Obstetrics and Gynaecology, Cairo, Egypt*

³*Al Galaa Teaching Hospital, Dept. of Obstetrics and Gynaecology, Cairo, Egypt*

⁴*University of Nicosia- Medical School- and Aretaeio Hospital- Nicosia- Cyprus, Dept. of Obstetrics and Gynaecology, Nicosia, Cyprus*

⁵*Omam Hospital, Research and Development Dept., Cairo, Egypt*

Background

Allen Masters syndrome was first described in the 1980's. It refers to peritoneal defects, initially described following labour. It was first proposed to be a result of mechanical shearing force, disrupting the continuity of the pelvic peritoneum. Later on, when awareness about this condition developed, it was found to be present in nulliparous women as well, indicating another possible etiology for this condition.

These peritoneal defects are encountered in patients with infertility, pelvic pain and even lower limb pain. This condition may also resent with urinary symptoms, as urgency and dysuria, when there is bladder involvement.

The laparoscopic findings in these cases consists of thinned out peritoneum, or even complete peritoneal defects, mainly over the utero-sacral ligaments and the base of the broad ligaments.

Methods

We present a case series of patients who underwent laparoscopy for pelvic pain, urinary symptoms, or even infertility, in whom the findings consistent with Allen Masters syndrome were encountered. The main symptoms of these patients were chronic pelvic pain, often radiating to the upper thigh, as well as urinary manifestations in the form of urgency, frequency and dysuria, for which, no definite urological explanations were found.

In these patients, we have performed laparoscopic excision of the defective, thinned out peritoneum over the utero-sacral ligaments and/or the base of the broad ligaments, until healthy peritoneum was reached. This was followed by re-approximation of the healthy edges. Frequently, we encountered endometriotic typical, or subtle lesions at the base of these defects. In some cases, these peritoneal defects formed deep outpouches that reached deep into the para-rectal spaces. In some cases, where the peritoneal defects were small, we performed bipolar coagulation of the diseased peritoneum, hoping that it will be replaced by new layer from the healthy surrounding edges. The excised samples were sent for histopathological evaluation.

Results

Following laparoscopic excision of the diseased peritoneal defects, patients reported marked improvement of their pre-operative symptoms, both pain and urinary complaints. Histopathological examination revealed fibrosis underneath the mesothelial layer, and in many case, findings consistent with peritoneal endometriosis, in the form of endometriotic stroma and glands. We propose a theory that these peritoneal defects are "cracks" in the peritoneum, through which, endometriotic tissues, e.g. from retrograde menstruation, could gain access into the peritoneal layer, and even sub-peritoneally, and may predispose to deep infiltrating endometriosis (DIE). This suggested etiological theory of DIE is supported by the findings of endometriotic tissues in the bases of these lesions, and also by the presence of associated implants elsewhere in the pelvis.

Conclusions

Allen Masters syndrome may be an etiological cause of chronic pelvic pain, lower limb pain, and urinary complaints. Laparoscopic repair of it provides significant symptomatic relief.

Further investigations into this condition may provide a possible theory for the development of pelvic DIE.

<https://esge.covr.be/cmdocumentmanagement/conferencemanager/documents/api/getdocument/5136/cmabstms/000165330/c972bc37d934f24f28c2bab0f091dbcbb3702d65b06ad9807c8182ea8b3e26dd>

Multimodal multidisciplinary treatment of fibroids with a large submucosal component

Alison Amoah¹, Josephine Mollier², Mohamad Hamady³, Stephen Quinn¹

¹Imperial College NHS Trust, Obstetrics and Gynaecology, London, United Kingdom

²Imperial College London, Medicine, London, United Kingdom

³Imperial College NHS Trust, Interventional Radiology, London, United Kingdom

Background

Treatment of fibroids with a large submucosal component can be complex. Studies are conflicting as to whether uterine fibroid embolization (UFE) of such fibroids increase infective complications and risk of subsequent emergency hysterectomy post-procedurally. Additionally, patients may be at increased risk of complications such as fibroid expulsion and protracted vaginal discharge. Transcervical resection of fibroid (TCRF) may be technically difficult with increased risk of fluid overload, bleeding and a multi-staged operation in these patients. The aim of this study was to evaluate treatment outcomes for patients undergoing planned elective TCRF for treatment of a fibroid with a large submucosal component following UFE.

Methods

The study design was a retrospective case series. Nine patients were identified that underwent planned TCRF within 4-18 months of UFE. These patients had either a large submucosal fibroid or a large intramural fibroid with significant submucosal involvement or multiple submucosal fibroids. Data regarding patient characteristics, fibroid imaging characteristics and procedure and operative outcomes were collected. Descriptive statistics were calculated using SPSS.

Results

Mean age was 48. Five patients were nulliparous. 87.5% of patients presented with heavy menstrual bleeding. Total number of fibroids treated per patient ranged from 1-40. Mean diameter of submucosal fibroid before treatment was 5.96cm and mean volume of fibroid(s) with submucosal involvement per patient was 107.36cm³. Mean length of stay following UFE was 1.56 days. Two patients described protracted vaginal discharge following UFE and one underwent fibroid expulsion. One patient had a TCRF abandoned because of cervical stenosis. Otherwise, mean operative time was 32 minutes. There were no cases of fluid overload. Mean estimated blood loss was 91mls. All patients were discharged home on the same day following TCRF. One patient required a 2-stage TCRF, with one patient awaiting clinical review with a view to deciding regarding possible further hysteroscopic operation. All other cases were completed in one-stage. Histology showed evidence of hyalinisation for the majority of patients where results were available. Change in uterine fibroid quality-of-life scores are presented where available. Follow up ranged from 6 months to 5 years. No patients have required reintervention. One patient has had a pregnancy.

Conclusions

These results indicate that patients with fibroids with a large submucosal component can be successfully treated with elective TCRF following UFE without complication. This is in keeping with other presented case series. Future work should aim to compare outcomes for those undergoing TCRF following UFE and those undergoing UFE alone. Additionally, more work needs to be done to identify the impact of such treatment on the endometrium for those wanting to conserve fertility.

<https://esge.covr.be/cmdocumentmanagement/conferencemanager/documents/api/getdocument/5192/cmabstms/000154350/cbd4219c7a4a06657872b40a40a8633b5fc0dfed91c4de7b6b764b59f71dfa0c>

Save womens' ovaries: conservative management of ovarian torsion should always be the rule

Mohamed Salama¹, Sayed Elakhras², Daa Abdelhalim³

¹Ain Shams Faculty of Medicine, Dept. of Obstetrics and Gynaecology, Cairo, Egypt

²Omam Hospital, Minimally Invasive Surgery, Cairo, Egypt

³Al Galaa Teaching Hospital, Dept. of Obstetrics and Gynaecology, Cairo, Egypt

Background

Torsion of the ovary often present in acute emergency situations. In such circumstances, the necessary expertise for a wise, minimally-invasive conservative surgery may be lacking. Additionally, delays in presentation and/or intervention may contribute to further compromise of the ovarian blood supply, and hence, its vitality. Currently, there is no definite diagnostic or prognostic method to confirm the vitality of the torsed ovary. Often, the surgeon are tricked by the bluish/blackish discoloration into performing the aggressive intervention of oophorectomy.

This invasive intervention obviously leads to a drastic deterioration of the ovarian reserve of these poor women, many of them are either nulliparous girls, or low-parity ladies. This not only affects their fertility potential, but also pushes them into the menopause earlier than their peers, with all its adverse outcomes and possible complications.

Methods

We present our experience with a case series of patients presenting with acute and sub-acute torsion of the ovary. Various clinical presentations were met with in these cases, some of which hindered early diagnosis and intervention before they were sent to our centre.

Laparoscopic exploration of such cases was the rule and we have almost always adopted a conservative approach in dealing with the twisted ovaries. In most cases, we performed a second-look laparoscopy, 6-8 weeks following the primary procedure, especially when there was a background pelvic pathology. In a few cases we performed earlier second-look laparoscopy as indicated by the clinical situation, one was even as early as 24 hours after the initial procedure.

Results

Despite the apparently lifeless appearances of the twisted ovaries, ovarian function still persists. The dark discoloration of the ovaries may initially persist as seen in early second-look laparoscopy, but not the tissue edema and ovarian swelling. Delayed second-look laparoscopy often revealed restoration of the normal ovarian volume and colour, during which time, additional operative procedures may be attempted to deal with the causative and/or associated pelvic pathology.

Histopathological examination of the ovarian biopsy specimens taken during the primary procedures showed variable degrees of interstitial edema and haemorrhages, along with some areas of necrosis. However, most the ovarian tissues did not show extensive infarction, confirming the rationale of ovarian conservation despite the gross laparoscopic appearance.

No cases of complicating peritoneal infection, or need for re-exploration were encountered in our series.

Conclusions

Ovarian torsion is an emergency situation in a population of young and low-parity women. In those patients, preservation of ovarian function is of a paramount importance.

We believe, based on our experience, as well as others', that conservative management of ovarian torsion should always be the rule in managing such cases, even if the laparoscopic appearance is suspicious of loss of ovarian function, because this will be restored after cessation of the initial acute tissue reaction.

Observations on increased advantages of reduced port surgery using a subcutaneous abdominal wall lifting method

Hiroe Ito¹, Yasufumi Ooishi², Keiichi Isaka²

¹*Tokyo Medical University, Obstetrics and Gynecology, Tokyo, Japan*

²*Hitachi General Hospital, Obstetrics and Gynecology, Tokyo, Japan*

Background

In the laparoscopic surgery of an ovarian tumor, although three treatment ports are generally prepared in addition to the endoscopic port, it cannot be said that it is cosmetically satisfying. On the other hand, although the single-hole type excels cosmetically excellent, it cannot be denied that the forceps operability is inferior. We have performed lifting laparoscopic surgery with a 5 mm trocar for endoscopic use and a single procedure hole, but for smaller procedure holes or bilateral tumors, forceps operation from one location requires advanced technical skills. This time, by using small diameter forceps, we have developed reduced port surgery, which is excellent in both operability and cosmetic properties.

Methods

We compared and examined 15 cases in which this surgery was performed for bilateral ovarian tumors at Sakuramachi General Hospital and 65 cases in which conventional lifting surgery was performed. The lower part of the lower midline was punctured with a Kirschner steel wire subcutaneously to raise the abdominal wall and a 12 mm treatment hole was made in either the left or right lower abdomen and a Lap Protector® was inserted. Thereafter, an endoscopic trocar was punctured from the umbilical region. For surgery, in addition to conventional surgical forceps, thin relief forceps Endo Relief or MiniLap® were used. Informed consent was obtained from all patients

Results

There was no significant difference in the background of the cases and the operation time (87 vs 134 minutes) and the amount of bleeding (60 vs 141 ml) were significantly shortened or reduced in particular with dermoid cysts and salpingo-oophorectomy. By inserting thin forceps from the contralateral side, the contralateral ovary can easily be sutured and removed. Furthermore, since the interference between the forceps that occurs when inserting a plurality of forceps from a single treatment hole is sufficiently eliminated, smooth forceps operation is possible.

Conclusions

By using thin forceps, easy surgical operation can be performed without loss of cosmetic properties and it is considered to be highly useful, especially for highly difficult cases.

<https://esge.covr.be/cmdocumentmanagement/conferencemanager/documents/api/getdocument/5268/cmabstsms/0000165050/b19ea75342c96ac8ac61cc4440e3034dac0e4d01d1938d8e5aa07d84189f14c1>

Types and viral load of human papillomavirus in vaginal intraepithelial neoplasia: a cross-section study

Fangyue Zhou¹, Jingxin Ding¹

¹*Obstetrics and Gynecology Hospital of Fudan University, Gynecology, Shanghai, China*

Background

It is widely acknowledged that infection with human papillomavirus (HPV) is a significant risk factor for vaginal lesions. Previous studies regarding HPV types in vaginal intraepithelial neoplasia (VAIN) and vaginal cancer indicated inconsistent conclusions and did not explore the correlation of HPV viral load and vaginal lesions.

Methods

A total of 176 women who underwent examining for lower genital tract lesions were enrolled in this cross-sectional study with definite pathological diagnosis, among which, 99 patients with vaginal lesions and 77 patients without

vaginal lesions were included. HPV types and viral load were detected by BioPerfectus Multiplex Real-Time PCR assay, and 109 cases were HPV positive, which included separate vaginal lesions (n=44), negative for intraepithelial lesion or malignancy (NILM, n=31), separate cervical lesions (n=16) and vaginal lesions concomitant with cervical lesions (n=18). The relevance was analyzed between viral loads and vaginal lesions.

Results

In patients with vaginal lesions, the HPV detection rate was 89.7% (87/99). Women with VAIN2/3 (n=12) or vaginal cancer (n=2) were all HPV positive and 57.14% (8/14) were HPV16 positive. Top five leading HPV types of vaginal lesions were HPV16 (24.2%), HPV52 (24.2%), HPV53 (16.1%), HPV58 (14.5%) and HPV66 (14.5%). Compared with histopathologically normal cases, separate vaginal lesions had a higher rate of HPV multiple infection (47.7% vs 29.0%). Besides, the viral load of HPV type 16, 52, 58 appeared higher for women with separate vaginal lesions than those with NILM ($P=0.026, 0.002, 0.013$ respectively). For women with cervical lesions, the viral load of HPV showed little difference whether there was coexistence of vaginal lesions or not.

Conclusions

Our findings suggest that HPV16, 52, 53, 58, 66 are more prevalent in vaginal lesions and infection with HPV16 may have a higher risk of VAIN2/3 or vaginal cancer. Some type-specific HPV viral load may provide indication for vaginal lesions.

<https://esge.covr.be/cmdocumentmanagement/conferencemanager/documents/api/getdocument/5067/cmabstsms/0000164640/1af0f3f08f0ce6941037a9f149ea2850d79688966dddb19727f418dfb05a3dfd>

ES28-0219 - P121

E-Poster

Fertility and surgical outcome in postoperative deep infiltrating endometriosis

Ning Zhang¹, Shugen Sun¹, Keqin Hua¹, Ying Zhang¹

¹The Obstetrics and Gynecology Hospital of Fudan University, Department of Gynecology, Shanghai, China

Background

This study is to summarize and analyze clinical characteristics and reproductive outcome in postoperative deep infiltrating endometriosis.

Methods

From January 2009 to June 2017, a total of 55 patients of productive age who were diagnosed of deep infiltrating endometriosis and undergone resection surgery in our tertiary-care university medical hospital were included. All these patients wished to conceive and any plausible infertility factor or abnormalities of partner's semen analysis were excluded. Clinical characteristics and reproductive outcomes were followed up and analyzed.

Results

Average patient age was 30.22 ± 3.62 and there was no difference between pregnancy and non-pregnancy group. Average follow up was 26.57 ± 14.51 months. There were 34 pregnancies (61.82%) with 24 (70.59%) spontaneous pregnancies and 10 (29.41%) in-vitro fertilization (IVF). 28 patients (82.35%) were term deliveries except one missed abortion, 2 spontaneous abortions and 3 induced abortions. The interval between operation and pregnancy was 10.33 ± 5.6 (1-26) months. The pregnancy group had higher EFI (endometriosis fertility index, EFI) scores and more patients had cautery procedure in non-pregnancy group ($p<0.05$), while there was no difference in the phase of rAFS between two groups. In univariate analysis, lower EFI score ($\text{EFI}<8$) was found to be a risk factor of infertility ($\text{OR}:3.17(1.15-10.14)$, $P=0.044$). Meanwhile there was no difference in number and size of lesion, lesion location (rectum, rectovaginal septum or utero-sacral ligament), lesion involvement (ovary/adenomyosis), lesion residual, operation type, operation time, blood loss, postoperative usage of GnRHa (gonadotropin releasing hormone agonist, GnRHa) and level of preoperative CA125 between pregnancy and non-pregnancy groups. However, For the patients having in-complete surgery, administration of postoperative GnRHa improved the pregnant rate ($p<0.05$). For evaluation of life quality, there was significant improvement ($p<0.05$) in postoperative scores of EHP-30 (endometriosis health profile questionnaire-30, EHP-30), KESS (Knowles-Eccersley-Scott Symptom questionnaire, KESS) and CMSS (cox menstrual symptom scale, CMSS) compared with preoperative in both groups. Although there was no obvious difference of FSFI (female sexual function index, FSFI) scores, significant improvement in postoperative scores of dyspareunia was observed compared with preoperative ($p<0.05$).

Conclusions

In our study, the postoperative pregnancy rate of deep infiltrating endometriosis is 61.82%. Surgical management of DIE for patients with painful complaints and pregnancy intention were feasible and effective. Once surgery is decided, complete excision of DIE could be the first choice (avoiding cauterization). For incomplete excision of DIE, administration of postoperative GnRHa is suggested which isn't advocated for complete excision. The patient with lower EFI score (EFI<8) shouldn't be suggested long-term expectant treatment and postoperative IVF-ET may be a good choice for them. However, more cases should be included and additional studies are required.

ES28-0276 - P122
E-Poster

Complications after hysterosalpingography with oil or water-based contrast: results of a nationwide survey

Inez Roest¹, Nienke van Welie², Velja Mijatovic², Marlies Bongers¹, Carolien Koks¹, Ben Willem Mo³

¹Maxima Medical Center, Department of Gynaecology, Veldhoven/Eindhoven, The Netherlands

²Amsterdam UMC- Vrije Universiteit Amsterdam, Department of Reproductive Medicine, Amsterdam, The Netherlands

³University of Monash, Department of Obstetrics and Gynaecology, Melbourne, Australia

Background

A hysterosalpingography (HSG) with oil-based contrast increases pregnancy rates in women with infertility. However, there have been some concerns regarding complications. Most importantly are the possible risk of intravasation of the contrast medium, oil-embolism and maternal or fetal thyroid dysfunction. Here, we present the incidence of complications after hysterosalpingography with different types of contrast.

Methods

In January 2018 an electronic survey was sent to all 73 clinics in The Netherlands that perform HSGs. The survey consisted of 12 questions, about the number of HSGs performed in 2017, the amount and type of contrast medium used, post-procedural complications and what their consequences were. The clinics who did not respond were sent reminders. Data were analysed descriptively.

Results

The response rate was 92%. In total 3212 HSGs with oil-based contrast and 1804 HSGs with water-based contrast were performed in 2017. The median amount of oil-based contrast used was 8.0mL (IQR 7.0-10.0) and 10.0mL of water-based contrast (IQR 8.0 -10.0). Antibiotic prophylaxis was administered in 63% of the clinics. Intravasation occurred in 4.7% (152/3212) of the HSGs with oil-based contrast and in 1.4% (25/1804) of the HSGs with water-based contrast. Pulmonary embolism or death did not occur. Pelvic inflammatory disease occurred in similar rates, in 0.3% (9/3212) of the HSGs performed with oil-based and 0.4% (7/1804) of the HSG performed with water-based contrast media and in 0.03% (1/3212) of the HSGs performed with oil-based contrast allergic reactions were seen, compared to 0.1% (2/1804) of the HSGs performed with water-based contrast. Maternal or fetal thyroid dysfunctions after HSG were not noted, in most clinics screening of thyroid function after HSG was not standard care.

Conclusions

Although the incidence of the HSG related complications in this survey was partly based on the recall of the clinician, the estimated rates in the clinics with and without systematic registration did not differ. The prevalence of intravasation was 4.7% in the clinics with oil-based contrast and 1.4% in the clinics with water-based contrast, without leading to embolization or death. This is in line with the results of a recent network meta-analysis (Wang et al., 2019). Since we did not find a high rate of complications, safety concerns should not be a reason to deny the use of oil-based contrast.

<https://esge.covr.be/cmdocumentmanagement/conferencemanager/documents/api/getdocument/4939/cmabstsms/000164820/15b8d6a03a2600cf42cd6c5c9719303f77e0e8dcfa5135b06b1dbf35e07cbd9d>

Transvaginal natural orifice transluminal endoscopic surgery with a low-cost self-constructed NOTES port: experience of 38 cases

Oğuzhan Yağdı¹, Gökay Özçeltik¹, İsmet Hortu¹, Ahmet Özgür Yeniel¹, İsmail Mete İtil¹

¹Ege University School of Medicine, Department of Obstetrics and Gynecology, Izmir, Turkey

Background

The objective is to share and present our experience of transvaginal natural orifice transluminal endoscopic surgery using our low-cost self-constructed NOTES port for benign gynecological conditions .

Methods

Hospital records were evaluated to identify surgeries carried out via NOTES approach. Between December 2018 and May 2019 total of 38 surgeries were identified. All procedures were performed by the same team of two surgeons. To gain abdominal access, a self-constructed NOTES port was utilized. Our NOTES port was made of materials that are virtually available in every hospital where laparoscopic surgery was performed which consist of powder-free surgical gloves, three re-useable 5 mm trocars, one 10 mm trocar and a pessary. The use of a pessary to form an inner ring for the NOTES port in our setup removed the necessity of using a wound retractor which is utilized by many surgeons performing NOTES.

NOTES port was introduced generally after completing a vaginal hysterectomy. NOTES port was placed just beyond the vaginal cuff and pneumoperitoneum was achieved. Surgeries were then carried out using conventional laparoscopic instruments. Standard outcome measures (operative time, blood loss, postoperative pain scores and types and rates of complications) were evaluated.

Results

Out of 38 patients, 14 female-to-male transgenders underwent vaginal hysterectomy followed by NOTES bilateral salpingo-oophorectomy (BSO), 13 patients who had pelvic organ prolapse underwent NOTES BSO following vaginal hysterectomy, 7 patients who had pelvic organ prolapse underwent NOTES BSO/salpingectomy and high uterosacral ligament fixation following vaginal hysterectomy , three patient who had myoma underwent NOTES BSO/salpingectomy and one patient who had subserous myoma underwent NOTES myomectomy via anterior colpotomy.

There were no conversion to open surgery or to conventional laparoscopy and no operative complications were observed. Postoperative pain scores (VAS) were very low. The hospital stays were uneventful and all the patients were discharged from the hospital on the second day following surgery .There were no postoperative complications observed. Post-operative 1-month and 3 months examinations (in available patients) and survey results showed us high patient satisfaction in terms of quality of life.

Conclusions

Our experience shows that transvaginal NOTES can be used to perform various benign gynecological procedures in a safe, minimally invasive manner and that it can be performed in a low-cost setting without the need for extra instruments. This surgical approach has the potential to have even more clinical applications in the future.

<https://esge.covr.be/cmdocumentmanagement/conferencemanager/documents/api/getdocument/5263/cmabstsms/000165100/d50ed4c2b381068af0e13871ae39a2cf4543d10687b1dcc247b6a7bdee521c02>

ES28-0230 - P124

E-Poster

Literature review: opportunistic bilateral salpingectomy as primary prevention of ovarian cancer

Anne-Sophie Maryns¹, Bart De Vree²

¹ZNA Middelheim, Gynaecology and Obstetrics, Heusden O.-VL., Belgium

²ZNA Middelheim, Gynaecology and Obstetrics, Antwerpen, Belgium

Background

Opportunistic bilateral salpingectomy (OBS or OS) during pelvic surgery could reduce lifetime risk of ovarian cancer in the low risk population. In Belgium there is not yet a consensus about routinely performing opportunistic salpingectomy and women are not informed about the advantages of tubal resection instead of tubal ligation if there is a desire for permanent contraception.

Methods

Literature search was performed in PubMed and Web of Science with search strings “opportunistic salpingectomy” and “prophylactic bilateral salpingectomy”. A narrative review was performed.

Results

The knowledge of STIC lesions (serous tubal intra-epithelial carcinoma) in the salpinx that derive into high-grade serous ovarian carcinoma's (HGSOC) has led to the concept of opportunistic bilateral salpingectomy. These precursor lesions were found in 0.8-3.1% of patients in low risk population for ovarian cancer. More and more opportunistic bilateral salpingectomy are performed in women with a completed family because of the possible prevention of ovarian cancer.

A meta-analysis concluded a 49% risk reduction of ovarian cancer following OBS. A number needed to treat of 273 during hysterectomy and a number needed to treat of 336 during surgical sterilization were calculated to prevent one case of ovarian cancer. There is insufficient evidence about long term impact on ovarian function. But seemingly the rate or premature menopause is low. Analysis based on the published hazard ratios demonstrated cost-effectiveness.

Conclusions

Patients in the low-risk population for ovarian cancer should be counselled about performing opportunistic salpingectomy when planning pelvic surgery because of the possible risk reduction for development of ovarian carcinoma. Currently the level of evidence is still scarce, long term data are lacking. In Flandres a consensus text is considered by the society of gynecologist to routinely counsel these patients.

<https://esge.covr.be/cmdocumentmanagement/conferencemanager/documents/api/getdocument/5173/cmabstms/000137980/5327340dcf738767bfcbe51d59c25e0cf48e2f9b5d23a86879ca97533c5c096e>

ES28-0231 - P125

E-Poster

Deep pelvic endometriosis involving the rectovaginal space in a young patient: describing anatomical landmarks and avoiding surgical pitfalls

Pantelis Trompoukis¹, Vassilios Pergialiotis²

¹IASO Group of hospitals, Endoscopic Surgery, Marousi Athens, Greece

²Attikon University Hospitals, 3rd of Obs&Gyn, Athens, Greece

Background

Deep pelvic endometriosis represents a clinical challenge for most gynecologists. Patient symptoms may help guide diagnosis; however, in certain cases the patients` clinical status may mask the severity of the disease. In depth knowledge of surgical anatomy of the pelvis is crucial in these cases to help fully eradicate the disease, together minimizing the possibility of perioperative complications.

Methods

We present the case of a 22 year old woman with deep pelvic endometriosis involving the rectum that has already performed two previous procedures to alleviate her symptoms

Results

Dense adhesions were identified in the left hemipelvis that extended in the pouch of Douglas and bilateral endometriomas were also detected. Extensive symphysiolysis of the left hemipelvis permitted adequate visualization of the left parametrium and the infiltrated pouch of Douglas was approached using a lateral approach to minimize the possibility of bowel injury. Endometriotic lesions were completely excised and restoration of the pelvic physiology was possible. Bowel integrity was ensured and the patient returned to her daily activities within 48 hours.

Conclusions

Deep pelvic endometriosis remains a surgical challenge for the gynecological surgeon. A lateral to central approach is necessary to minimize the possibility of ureteral and bowel damage and maximize resection of disease with safety.

<https://esge.covr.be/cmdocumentmanagement/conferencemanager/documents/api/getdocument/5171/cmabstsms/000056540/aa3f40536d5de1dfaf9b4887221aa93c4d7a3beac1fcb2d7ccb560f360831de7>

ES28-0236 - P126 E-Poster

Vascularity scores of myomectomy materials of women with or without menorrhagia

Asli Yarci Gursoy¹, Didem Cakmak¹, Gulsah Akgu², Mine Kiseli¹, Haldun Umudum², Gamze Sinem Caglar¹

¹Ufuk University Faculty of Medicine, Obstetrics and Gynecology, Ankara, Turkey

²Ufuk University Faculty of Medicine, Pathology, Ankara, Turkey

Background

Uterine leiomyomas are more often asymptomatic. When symptomatic, menorrhagia, chronic pelvic pain/pressure and obstetric complications can be listed among complaints (Stewart EA, 2001). Menorrhagia is due to many factors such as: the increment in the uterine surface area, increment in vascularity and vascular flow into the uterus, reduction in myometrial contractility particularly of the inner junctional zone and compression of the venous plexus within the myometrium leading to congestion (Hapangama DK, 2016). This study is designed to evaluate whether women symptomatic for menorrhagia have higher vascularity scores compared to those without menorrhagia.

Methods

Records of thirty one women who were operated in the University Hospital Gynecology Department for leiomyomas with laparotomy or laparoscopy were evaluated. The cases were evaluated in two groups either symptomatic (n=16) or asymptomatic for menorrhagia (n=15). For this purpose, myomectomy materials of these women were re-examined and processed with CD34, an endothelial cell marker, for immunohistochemical evaluation. The most dense vascular area, the least dense vascular area and central areas representing the leiomyoma were marked and Image J programme (Image J 1.52a, Wayne Rasband National Institutes of Health, USA) was used for measurement of vascularity percentile in each specimen for three different areas semiquantitatively. Vessel diameter above 3 mm were defined as large vessels and presence of large vessels in < 5 areas or ≥5 areas was also recorded.

Results

Demographic variables were compared for two groups. Symptomatic women were significantly older (45.3±6.6 vs 39.1±6.9; p=0.015 respectively), had higher gravidity (p<0.001) than asymptomatic women. Preoperative Hb values were similar between two groups (p=0,354). Number and dimensions of excised leiomyomas were similar between two groups (p=0.412). Likewise, type of leiomyomas were similar between two groups. Percentile of vascular areas in each specimen were statistically similar between two groups for the most dense, the least dense and the central areas (p>0.05). Although number of large vessels were higher in symptomatic group compared to asymptomatic group, the difference did not reach statistical significance (p>0.05).

Conclusions

There is fair amount of literature concerning the vasculature of leiomyomas, most of which consist of comparisons with myometrium or classifications according to size or location. Previous studies have shown that, leiomyomas have reduced blood flow compared to adjacent myometrium (Fleischer R, 2008) but vascular density of leiomyomas has not been compared in respect to symptomatology. The vascular density of the leiomyomas did not differ regarding the sampling sections of the myomas or regarding the symptomatology. Although the small sample size is a limitation of this study, the results indicate that menorrhagia is related with other factors far beyond vascularity.

<https://esge.covr.be/cmdocumentmanagement/conferencemanager/documents/api/getdocument/5058/cmabstsms/000064210/1300319cdb7b2dff550d4eabe906a4cdabd330c964275739fad172f517b285b8>

ES28-0241 - P127 E-Poster

The necessity for repetitive hysteroscopy sessions

Asli Yarci GURSOY¹, Didem Cakmak¹, Nede Destina İbrahim¹, Muge Keskin¹, Emre Pabuccu¹, Gamze Sinem Caglar¹
¹Ufuk University Faculty of Medicine, Obstetrics and Gynecology, Ankara, Turkey

Background

Hysteroscopy is considered as the gold standard for intracavitary pathologies in all age groups of women letting both see and treat strategy. Ease and quite low complication rate of the procedure has led to widespread use in the clinical settings of gynecology practice. This study aims to discover the etiologies and indications for cases who were treated with repetitive hysteroscopy sessions within a 6 year period in a single gynecology department.

Methods

Hysteroscopy procedures held between 2013-2019 in an university gynecology department were reviewed. Among 810 procedures, 28 patients were found to have repetitive hysteroscopies. For 28 cases, 60 hysteroscopy sessions were held. Demographic variables, complaints at admittance and indications for repetitive cases were reviewed. Histopathological records of the cases were reviewed.

Results

Mean age of patients who were treated with recurrent hysteroscopy was 39. None of the patients were on tamoxifen therapy or any hormonal contraception, only one was on antihypertensive therapy while seven were postmenopausal. When categorized according to the admittance complaints, menometrorrhagia (n=15) was the most common complaint, followed by infertility (n=9) and lastly secondary amenorrhea (n=4). Among the indications for hysteroscopies, most common was endometrial polyp (n=26) followed by, intrauterine synechiae (n=13), submucous leiomyomas (n=9), infertility (n=6), retained products of conception (n=4) and uterine anomalies like septate and T shaped uterus (n=2). Among the cases included in the study, 4 patients required three sessions of hysteroscopy (2 cases for intrauterine synechiae, 2 cases for recurrent endometrial polyps) during the study period while the remaining 24 underwent two sessions of hysteroscopy. No malignancy was reported histopathologically. Endometrial hyperplasia without atypia was reported in histopathological examination of 3 endometrial polyp cases.

Conclusions

In gynecological practice, synechiae and leiomyomas (Type 0, 1, 2) are common indications which necessitate repetitive hysteroscopy sessions for complete cure. The unexpectedly documented data from this study is that, endometrial polyps might reoccur in time and might require repetitive hysteroscopy sessions. After complete excision of a polyp, exact incidence of recurrent consistency of a new polyp in the same patient is not reported. The possible mechanisms for development of endometrial polyps are expression of estrogen and progesterone receptors (Jovanovic AS, 1996), overexpression of endomerial aromatase (Maia H Jr, 2006; Pal L, 2008) and some gene mutations (Dal Cin P, 1995; Nogueira AA, 2006). The lack of data about these promoting factors in patients with repetitive formation of polyps is a limitation of this study. Future prospectively designed studies might clarify this issue.

<https://esge.covr.be/cmdocumentmanagement/conferencemanager/documents/api/getdocument/5059/cmabstsms/000064210/faaae0382e418242bcab9c0a1ffad1b944e526780f7530ae02e53d27e3944413>

Correlation between hysteroscopic diagnosis and histopathology for endometrial hyperplasia: a prospective observational study

Gaetano Riemma¹, Nicola Colacurci¹, Nicola Fortunato¹, Marco La Verde¹, Antonio Schiattarella¹, Pasquale De Franciscis¹

¹University of Campania 'Luigi Vanvitelli', Department of Woman- Child and General and Specialized Surgery, Naples, Italy

Background

To assess the correlation between the clinical diagnosis of Endometrial Hyperplasia (EH), suspected by senior gynecologists throughout outpatient office hysteroscopy and the results from the histopathological examination, in order to evaluate hysteroscopic accuracy for EH.

Methods

A prospective observational study at a Tertiary University Hospital on 425 women undergoing office hysteroscopy: 92 with abnormal uterine bleeding (group AUB), 107 with a pre-menopause ultrasonographic endometrial thickening (group PreM-ET); 225 with a post-menopause thickening (group PostM-ET); 11 with tamoxifen administration (Group TMX). Outpatient office hysteroscopy was performed after the menstrual phase (day 6 to 10) of a spontaneous menstrual cycle, without any premedication and/or anesthesia, by 5mm hysteroscope with vaginoscopic approach and miniaturized 5Fr grasp forceps. Surgeons were asked to propose a suggestive histological diagnosis with a questionnaire in order to standardize the assessment. This was made of a progressive number which identified the biopsy and a multiple-choice question. Operators were asked to choose one from the following answers: Benign (including atrophic endometrium, proliferative endometrium, endometrial polyp/s); endometrial hyperplasia (simple or complex hyperplasia); atypical hyperplasia/carcinoma (including atypical endometrial hyperplasia and adenocarcinoma)

Results

Considering the whole number of patients, the 58,4% (170/292) of EH were successfully predicted by operators. The 86,2 (112/130) percent of the hysteroscopic impressions were concordant to histopathology in case of benign disease or a normal endometrium.

Stratified by clinical indication, highest concordance noted was in diagnosing EH in women with pre-menopausal endometrial thickening (69,8%), the lowest in post-menopause (51,6%).

Overall sensibility for EH was 90.4% with a negative predictive value (NPV) of 86,6%. Although misdiagnosed EH led to discover that specificity and positive predictive value (PPV) were just low-moderate (respectively 48,9 and 44,2%). Highest sensitivity could be found in TMX group (100%) and PostM-ET group (97,9%). NPV, for those two groups, was respectively 100 and 95,9%. Negative likelihood ratio for hysteroscopic identification EH was <0,1, especially in PostM-ET group (0,05).

Although a reasonably low number of findings concerning endometrial adenocarcinomas or atypical endometrial hyperplasia (14/435), the clinical and histopathological examinations were concordant in every case (100%).

Conclusions

Diagnostic accuracy of office hysteroscopy in the diagnosis and in the prediction of endometrial hyperplasia is high. Senior operators could foresee EHs in more than half the cases.

A low negative likelihood ratio, combined with a high NPV, shows that the clinical hysteroscopic diagnosis could be really useful in excluding EH. Nonetheless, it is therefore necessary to improve not only the predictive morphological hysteroscopic criteria of endometrial hyperplasia, but also a wider consensus is needed to standardize the clinical criteria for such disease.

ES28-0455 - P129

E-Poster

From atypical myoma to uterine sarcoma: about three clinical cases

Julien Bakenga¹, Genestie Catherine²

¹*Clinique du Fief de Grimoire, Gynecologic Oncology, Poitiers, France*

²*Gustav Roussy, Pathology, Villejuif, France*

Background

To identify the characteristics of uterine sarcoma and assess the complexity of pre operative diagnosis

Methods

A case report study

Three patients with suspected myoma in MRI and ultrasound had been operated in our center in 2018

All descriptive data, including diagnosis imaging, type of surgery, clinical and pathological data were reviewed

Pathological findings are analyzed and criticized

Results

Those three cases are fully analyzed. The most common symptom in diagnosis was metrorrhagia

Imaging findings related about "suspected vascularisation of the myoma"

The indication for surgery was related to myopia growth and myopia modifications

Open surgery was performed to prevent morcellation risk

Two of those three patients had prior myomectomy (one by hysteroscopy, the other by laparoscopy)

At final pathologic analysis, two of three patients had low grade sarcoma

one of those three patient went for post operative radiotherapy

literature had been reviewed and discussion on the importance of MRI description

the non predictability of MRI in suspected myopia is noticed

Conclusions

Taking into account the negative impact of morcellation in sarcoma, all suspected myomas in women without childbearing have led to total hysterectomy by laparotomy

the only one patient who had no children at 44 years old was found to have low grade sarcoma and underwent for post operative radiotherapy

<https://esge.covr.be/cmdocumentmanagement/conferencemanager/documents/api/getdocument/5102/cmabstms/0000166290/8a777e039bd1279c8c6a0e1cf1d0b262ba99a93703b7944d8497eba489b15530>

ES28-0257 - P130

E-Poster

Development of pedicled left ovarian endometria during pregnancy: a case report

Toshiyuki Kanno¹, Shuko Murata¹, Yu Horibe¹, Yuki Abe¹, Jun Kumakiri¹, Tsutomu Tabata¹

¹*Gynecology & Obstetrics, Tokyo Women's University, Tokyo, Japan*

Background

Ovarian endometrioma is commonly presented as a cyst surrounded by ovarian cortex. We report a rare case with a pedicled left ovarian cyst which were histopathologically confirmed endometriosis.

Methods

A 39-year-old primiparous woman with multiple uterine myoma became pregnant and visited to a hospital. At 31 weeks of gestation, she was admitted to our hospital because of severe abdominal pain. A huge cystic mass was detected in ultrasound. A pelvic MRI revealed a 12-cm cystic mass with high intensity in T2-weighted image. Her blood examination was not detected coagulation disorders causing bleeding tendency and there were no signs of preterm in labor and of fetal distress. She was discharged at 33 weeks of her gestation because the abdominal pain was gradually improved. At 38 weeks of the gestation, she was delivered with elective induction of labor and the course was uneventful. At 22 months of postpartum, laparoscopic surgery was performed, because the cystic mass observed by ultrasound every 3 months was not shrunked.

Results

In laparoscopic surgery, it was observed a 12-cm dark purple cystic mass occupied in the abdominal cavity. It had a pedicle developed from her left ovary and 2 feeding vessels connected to her left abdominal wall nearby her navel. Filmy adhesions were observed around the bilateral fimbriae of Fallopian tubes. After the vessels and the pedicle were coagulated by bipolar, the cystic mass was removed. Six and four cm endometriotic cysts were found in both ovaries, so removed and sprayed with anti-adhesion agent in the pelvis. Her postoperative course was not eventful and she was discharged on the 4th postoperative day. The cystic mass was histopathologically diagnosed endometriosis after the laparoscopic surgery.

Conclusions

It was considered that the endometrioma might be atypically developed by the alteration of her abdominal circumstance influenced by the pregnancy. Further similar cases are required to elucidate the pathogenesis of the development of ovarian endometrioma in particular conditions.

<https://esge.covr.be/cmdocumentmanagement/conferencemanager/documents/api/getdocument/5016/cmabstms/000165950/07f9b22612700698dd70b34d37fb8fa18f3710dc83b60dc7b14c4b4d3b3b837f>

ES28-0405 - P131

E-Poster

Laparoscopic removal of non-communicating horn ectopic pregnancy - a rarity and its modern management – a case report

James Thiesen-Nash¹, Katie Brooks², David Rae¹

¹University Hospital- Crosshouse- Ayrshire- Scotland, Obstetrics and Gynaecology, Kilmarnock, United Kingdom

²Dundee University, Medical School, Dundee, United Kingdom

Background

Whilst unicornuate uterus with a non-communicating or rudimentary horn is an unusual form of müllerian duct anomaly occurring in less than 1% of the female population, an even rarer associated pregnancy (incidence < 1/75000 to 1/150000) and its initial and / or delayed presentation may not be straightforward. This can spell disaster for the patient if the pregnancy ruptures. Traditionally managed via laparotomy, more recent surgical management has shown resolution is possible via minimally invasive techniques.

Methods

Case report:

A 20 year old underwent medical termination of pregnancy with misoprostol and mifepristone at 10 weeks. A second medical termination was then attempted but was also unsuccessful. She was subsequently referred for a surgical termination of pregnancy and at 11+4 weeks when minimal tissue was obtained via suction under ultrasound guidance a presumed diagnosis of extrauterine pregnancy was made. During subsequent laparoscopy a diagnosis was made of a pregnancy in a non-communicating right uterine horn which was attached to the right round ligament and right fallopian tube. A normal uterus and left adnexa was also seen. Laparoscopic excision of the non-communicating right uterine horn (with pregnancy) and right fallopian tube was performed using harmonic and bipolar energy with the specimen retrieved via a mini port and extraction bag.

Discussion

The primary management of unwanted pregnancy in a rudimentary uterine horn is surgery. Traditionally this has been performed via laparotomy but more recently has been undertaken laparoscopically, as in this case, made further possible in that the pregnancy was still in the first trimester. Advantages of laparoscopy compared with open procedures include less morbidity and a more rapid recovery time. The Thunderbeat device used in this particular case was employed due to its combination of harmonic and bipolar properties for an otherwise potentially haemostatically difficult case. Morcellation of a 12 week pregnancy might mean intraperitoneal dissemination, therefore utilisation of a Bert Bag and Alexis miniport avoided the need for a large abdominal port incision for specimen retrieval.

Conclusions

A non-communicating rudimentary horn is a rare congenital abnormality of the uterus in which a pregnancy can develop. Diagnosis of pregnancy in a non-communicating rudimentary horn is often made late when the horn ruptures and the patient presents acutely. It can be diagnosed by ultrasound and MRI but it is often missed. The outcome of

the majority of these pregnancies is poor with rupture in the second trimester in 80-90% of cases. If diagnosed in the first trimester and the pregnancy is unwanted, then the primary management is surgical excision of the pregnancy-containing horn and ipsilateral fallopian tube in order to prevent the life-threatening complications associated with rupture and future pregnancies occurring in the horn.

<https://esge.covr.be/cmdocumentmanagement/conferencemanager/documents/api/getdocument/5267/cmabstsms/000153900/37ff04d65d3db9b94e1fd34bb22d76de123055017aca6b81d74916cbcfb9a277>

ES28-0458 - P132

E-Poster

Fibroid centers to promote early intervention for uterine fibroids

*Michael Lau*¹

¹*Edmonds Women's Clinic, Urogynecology, Edmonds, USA*

Background

There is a four years delay before women would seek treatment for symptomatic fibroids. A key reason is due to the common notion that surgery, especially hysterectomy, is what one would face if seeking treatment for fibroids - 80% women with uterine fibroids prefer no invasive treatment. Paradoxically, the delay in seeking treatment often results in needing more invasive measures due to the increase in fibroid burdens during the delay. The objective of this study is to explore options that would enable women with symptomatic uterine fibroids to seek professional help early on to avoid more invasive treatments, ideally in the setting of a fibroid center.

Methods

Explore the concept of fibroid centers that are designed to educate the public to change the mindset that symptomatic fibroid means surgery, especially hysterectomy. Explore the options of non-invasive treatments that the fibroid centers can provide to cost-effectively treat the women with symptomatic fibroids at an earlier stage, and therefore decrease the need of invasive procedures, risks, and healthcare costs and burdens associated with uterine fibroids. Review of non-invasive treatment options in treating symptomatic uterine fibroids, including the latest procedural technologies.

Results

An ideal fibroid center concept is developed to enable women with symptomatic uterine fibroids to gain access to comprehensive assessment, counselling, and treatment at an earlier stage. New non-invasive technologies, including the use of cost-effective office-based high-speed ultrasound guided High Intensity Focused Ultrasound (HIFU) ablation of uterine fibroids, could be effective.

Conclusions

Using fibroid centers to educate and change the mindset of women with symptomatic fibroids, and to offer early non-invasive treatment options, it is possible to decrease the need of costly invasive interventions for those women and the associated personal healthcare costs and the public health burdens for a condition affecting up to 25% of women in the reproductive age group.

<https://esge.covr.be/cmdocumentmanagement/conferencemanager/documents/api/getdocument/5081/cmabstsms/000056890/fa7e6a22f5d939e04a1bf3dc0513d477f9c1b0fab82037f972ebe729795c0368>

ES28-0265 - P133

E-Poster

Influence of body position on intraabdominal space during gynecologic laparoscopic surgery in Korea

*Sung-Ho Park*¹

¹*Hallym University, Obstetrics and Gynecology, Seoul, Korea- Republic Of*

Background

To evaluate the association between the patient's body position and the intraabdominal workspace in gynecologic laparoscopic surgery.

Methods

The inflated volume of carbon dioxide was measured for 40 patients underwent laparoscopic surgery between July 2017 and January 2018 prospectively. The four positions were (1) table horizontal with legs placed in lithotomy position (1st supine position), (2) table in 20° reverse Trendelenburg with legs placed in lithotomy position 45° upward at hips (beach chair position), (3) table in 20° Trendelenburg with the legs placed in lithotomy position and (4) repeated supine position in the last order (2nd supine position).

Results

A significant difference in inflated volume was found according to the positions ($P= 0.02$). The mean inflated volume of Trendelenburg position was the greatest (3.28 ± 1.50 L). The mean inflated volume increased by 400mL when the patient's body was placed in Trendelenburg compared to the volume in 1st supine position.

Conclusions

The Trendelenburg position for gynecologic surgery effectively improved the workspace in Korean women, in the full muscle relaxation.

<https://esge.covr.be/cmdocumentmanagement/conferencemanager/documents/api/getdocument/5057/cmabstsms/000045950/75a6638e67d23f8c720a7d12b1135447f055a52e6ff3ddd4bd5094f8929c29aa>

ES28-0300 - P134

E-Poster

Essure® removal: perioperative data

*Dieuwertje Horsten*¹, *Daniëlle van Gastel*¹, *Liselotte Maasser*², *Sebastiaan Veersema*², *Marlies Bongers*¹

¹*Máxima Medisch Centrum, Gynaecology and Obstetrics, Veldhoven, The Netherlands*

²*UMC Utrecht, Gynaecology and Obstetrics, Utrecht, The Netherlands*

Background

Essure® (Bayer AG, Leverkusen, Germany) is a sterilization method in which a spiral shaped device is inserted into each fallopian tube by means of hysteroscopy. A large amount of patients who underwent an Essure® procedure report various symptoms that they relate to the Essure® devices and request to undergo surgery to have them removed. The study objective is to analyze perioperative parameters regarding surgical removal of Essure® sterilization devices.

Methods

All patients with a request for surgical removal of Essure® devices between March 2016 and November 2018 were subsequently included in 26 hospitals in The Netherlands. Data about the preoperative transvaginal ultrasound, preoperative x-ray investigation of the pelvis, the removal procedure and complications was entered into an online database by the surgeon. An interim analysis of data from the Máxima Medical Centre (MMC) was performed.

Results

A total of 295 patients were included in the selected period in the MMC. In 18.8% of cases localization of the Essure® device was classified as normal on transvaginal ultrasound. Often devices were positioned slightly distal (47.3%) or very distal (14.3%) in the fallopian tube. Pre-operative x-ray investigation of the pelvis showed a normal position of Essure® devices in 89.2% of cases. Of all participants 94% underwent surgery. The devices were removed predominantly through laparoscopic extraction followed by tubectomy (91.3%). In 7.3% of cases a hysterectomy with

tubectomy was done. During laparoscopic inspection, in 73.4% of fallopian tubes no abnormalities were seen. In 14.6% of cases a chicken wing sign was seen (fallopian tube folds over most distal part of the device). Tubal perforation and migration of the device outside of the fallopian tube were seen in respectively 1.8% (n=10) and 0.2% (n=1) of cases. Of all devices 92.9% was removed completely. In 4.7% of cases a cornual excision was required for complete removal. The remaining 7.1% was not completely removed due to, among other things, breaking off of the fourth marker. Minor complications occurred during or after surgery in respectively 2.2% (n=6) and 5.5% (n=15) of cases.

Conclusions

In 18.8% of cases localization of the Essure® device was normal on ultrasound. The devices were removed predominantly through laparoscopic extraction followed by tubectomy (91.3%). During laparoscopic inspection, in 73.4% of fallopian tubes no abnormalities were seen. In 14.6% of cases a chicken wing sign was seen. Of all devices 92.9% was removed completely. Participants had a minor complication during or after surgery in respectively 2.2% and 5.5% of cases.

<https://esge.covr.be/cmdocumentmanagement/conferencemanager/documents/api/getdocument/5182/cmabstms/000165980/e78055464190918057971dfbb6cfdb98c56c10ebbb2cabb45e6f404a94667a8b>

ES28-0471 - P135

E-Poster

Efficacy of continuous suturing using STRATAFIX® for vaginal cuff closure in total laparoscopic hysterectomy

Chisato Noji¹, Noriko Yamamoto¹, Hiroyuki Kobori¹

¹Medical Topia Soka Hospital, Gynecology, Soka-Saitama, Japan

Background

Ligation and suturing in total laparoscopic hysterectomy (TLH) is a time-consuming procedure, especially for vaginal cuff closure, but an accurate technique is required for prevention of vaginal cuff dehiscence and hematoma. Since October 2017, we have used a barbed suture (STRATAFIX®), which enables easy and equal tension suturing in a short period of time. The objective of this clinical study was to compare the time required between continuous suturing using STRATAFIX® and single interrupted suturing.

Methods

A total of 59 patients who underwent TLH at our hospital from January to March 2017 were divided into groups treated with single interrupted suturing (n=24) or continuous suturing using STRATAFIX® (n=35). In single interrupted suturing, both ends of the vaginal cuff were Z-stitched with VICRYL PLUS® and the center of the stump was single ligation sutured. In continuous suturing, both ends of the vaginal cuff were similarly Z-stitched with VICRYL PLUS®, the ligatures at the left end were left for pulling the vaginal cuff and continuous suturing with 15 cm of STRATAFIX® was started from the right end. After suturing to the left end, suture in the reverse direction was performed twice.

Results

The time required for vaginal cuff suture was significantly shorter with continuous suture compared to that with single ligation (547 s (400-688 s) vs. 755 s (525-986 s), P <0.01).

Conclusions

The STRATAFIX® barbs are oriented in one direction to allow tissue approximation without the need to tie surgical knots. The advantage is that the time required for vaginal cuff suture is short compared to that using a single knot suture, and unlike continuous suture without barbed suture, tension can be maintained even when the ligature is cut due to a condition such as infection. However, barbed suture may be implicated as a cause of bowel obstruction and rupture of intestines. This complication may be avoided if there is no exposure of the free end of the barbed suture in the peritoneal cavity. If the stump cannot be covered with the retroperitoneum, we suggest that it is better not to use barbed suture. Stitching using STRATAFIX® maintained equal tension easily and in a shorter period of time compared with single knot suture, which suggests the utility of STRATAFIX® for vaginal cuff suture.

<https://esge.covr.be/cmdocumentmanagement/conferencemanager/documents/api/getdocument/4982/cmabstms/000165200/3824510fe64a4aa1a592027ecd1405de6c648205fd647686d0b237cb44f2f039>

ePAQ-MPH as a patient reported outcome measure (PROM) for women following treatment for heavy menstrual bleeding

Anna Shakespeare¹, Stephen Radley², Georgina Jones³, Mary Connor⁴

¹University of Sheffield, Department of Oncology and Metabolism, Sheffield, United Kingdom

²Sheffield Teaching Hospitals NHS Foundation Trust, Urogynaecology Unit- Jessop Wing, Sheffield, United Kingdom

³University of Sheffield, School of Health and Related Research Scharr, Sheffield, United Kingdom

⁴Sheffield Teaching Hospitals NHS Foundation Trust, Department of Obstetrics- Gynaecology and Neonatology, Sheffield, United Kingdom

Background

Heavy menstrual bleeding (HMB) is one of the commonest reasons for women of reproductive age to be referred to a gynaecology clinic. Not only does it have a significant impact on a person's physical wellbeing, but also on their quality of life (QoL). Treatment for HMB is often symptom-based focusing on improving a patient's QoL, so the use of a Patient Reported Outcome Measure (PROM) to monitor the effectiveness of these interventions is potentially beneficial. The electronic Personal Assessment Questionnaire for Menstrual, Pelvic pain and Hormonal disorders (ePAQ-MPH) is a validated web-based questionnaire aimed at women with these conditions. It was designed as an assessment tool and outcome measure and assesses these by exploring four dimensions – menstruation, pelvic pain, cyclical hormonal symptoms and sexual function.

This study aims to use ePAQ-MPH with patients pre- and post- treatment who attend a gynaecology clinic for HMB and receive one of the three main treatment options: (1) Levonorgestrel intrauterine device (LNG-IUD), (2) endometrial ablation or (3) hysterectomy in order to assess the effectiveness of ePAQ-MPH as a PROM in these treatment groups, interrogate patient acceptability of ePAQ-MPH with the validated questionnaire QQ-10 and assess whether the tool demonstrates significant changes in their symptom profile and QoL scores post-treatment.

Methods

Patients who have completed ePAQ-MPH in the preceding year, April 2018 to February 2019, and had subsequently undergone one of the three main treatment options were identified and asked to complete a second ePAQ-MPH, following at least three months post-treatment for hysterectomies and four months post-treatment for endometrial ablation and LNG-IUD insertion. Patients attending either general gynaecology or hysteroscopy clinics between 1st March 2019 to 1st July 2019 for one of the specified treatments or follow up for treatment were identified and asked to complete an ePAQ-MPH either at home or prior to consultation in clinic. Following ePAQ-MPH completion patients were also asked to fill out a second questionnaire, QQ-10, to assess the acceptability of ePAQ-MPH and how well it addressed patients' concerns.

Results

The projected number of patients to have completed pre-treatment and post-treatment questionnaires is 50, with a minimum of 12 patients per treatment group. To date the cohort comprises of 13 patients with 3 following endometrial ablation, 4 after hysterectomy and 6 with LNG-IUD insertions. Full data analysis will take place at the end of the data collection period.

Conclusions

It is hypothesised that the ePAQ-MPH will serve as a useful PROM for HMB. If this is confirmed then ePAQ-MPH will be used for routine clinical practice in secondary care as a PROM and could potentially be tested in a primary care setting for the initial assessment.

<https://esge.covr.be/cmdocumentmanagement/conferencemanager/documents/api/getdocument/5138/cmabstsms/000164930/7d4ca226718b1b82cf7d4f2cce2adfe2020504031e978a0c167a9d63f6e68039>

ES28-0269 - P137

E-Poster

A retrospective study of ovarian function after laparoscopic surgery of ovarian torsion

Koharu Iwase¹, Mari Kitade¹, Keisuke Murakami¹, Yu Kawasaki¹, Shiori Takeuchi¹, Jun Kumakiri²

¹*Juntendo University School of Medicine, Obstetrics and Gynecology, Tokyo, Japan*

²*Tokyo Women's Medical University, Obstetrics and Gynecology, Tokyo, Japan*

Background

In cases of ovarian torsion happened frequently in young women, maintaining ovarian function after surgery is very important. This report shows the study of ovarian function after emergency laparoscopic surgery for ovarian torsion.

Methods

A retrospective review of 16 patients who desire to get pregnant in future with ovarian torsion performed emergency laparoscopic surgery in our hospital between 2012 and 2017 was investigated. We divided and examined in each group as visible ischemic change or not, recovering blood flow after re-torsion or not and changes or pathological state or not.

Results

Median of age was 29.5 (range:20-41) years old and diameter of tumor was 95.0 (range:50-200)mm, time from onset from surgery was 10.0 (range:3-170) hours. Mature cystic teratoma was diagnosed in most cases (12/16 cases) and there were any malignancy or borderline tumor. In 11 cases (11/16 cases), ischemic changes were identified during surgery. Time from onset from surgery and blood examination before operation did not differ significantly between visible-ischemic-group and non-visible-ischemic group. In ischemic-change-group, 6 cases (6/11 cases) were diagnosed ischemic changes pathologically. Diameter of tumor of pathological-ischemic-group was significantly larger than non-pathological-ischemic group's one($p=0.02$). Other objects described previously did not differ significantly between pathological-ischemic-group and non-pathological-ischemic group. All of 15 cases which were performed laparoscopic cystectomy were found follicles in the ovary of diseased side after surgery.

Conclusions

In the case of ovarian torsion, releasing torsion as soon as possible is effective procedure to maintain ovarian function although ischemic changes are identified

<https://esge.covr.be/cmdocumentmanagement/conferencemanager/documents/api/getdocument/5117/cmabstms/000165990/63a221cc969f70c43575eb348a4bc349f116825e300527bff43ff7f4a817a3>

ES28-0275 - P138

E-Poster

Laparoscopic myomectomy: a retrospective review of 155 cases

Dimitrios Zygouris¹, Nektarios Chalvatzas¹, Antonis Gkoutzioulis¹, Georgios Anastasiou², Andreas Kavallaris^{1,2}

¹*St Luke's Hospital, Department of Gynecologic Oncology and Minimally Invasive Gynecology, Thessaloniki, Greece*

²*Mother and Child Medical Centre, Department of Gynecologic Oncology and Minimally Invasive Gynecology, Nikosia, Cyprus*

Background

The aim of this retrospective study is to evaluate surgical outcomes and histopathological findings after laparoscopic myomectomy. The incidence of malignancy is a main concern for cases treated laparoscopically.

Methods

In the time period January 2013 – January 2019 155 women with one or more myomas were operated. We collected retrospectively demographic and surgical data. All surgeries were completed laparoscopically and after myoma enucleation and uterus suturing, myomas were removed mainly by power morcellation.

Results

The median number of removed myomas was 2.23 and the median diameter of dominant myoma measured on preoperative ultrasound was 7.3 cm. The median estimated blood loss was 92 ml and the median hospital stay was 1.3 days. One case of low grade endometrial stromal sarcoma was found. There was no major complication and the overall complication rate was (3.1%).

Conclusions

Laparoscopic myomectomy is a feasible and safe approach, even in cases of big myomas with very low complication rate. Of course a very careful pre-operative assessment is necessary for minimizing the chance of an unexpected malignancy.

<https://esge.covr.be/cmdocumentmanagement/conferencemanager/documents/api/getdocument/5304/cmabstsms/000041260/9da6eda9ba3690172aa768066e5f6c9e464c3d1beac779a490a73b0d13c4eee5>

ES28-0278 - P139

E-Poster

Isolated tubal torsion – laparoscopic management and review of literature

Smita Jindal¹, Bernard Chern²

¹*KK Women's and Children's Hospital, Obstetrics and Gynecology, Singapore*

²*KK women's and Children's Hospital, Minimally Invasive Surgery, Singapore*

Background

Ovarian torsion has been described in many patients. Torsion of the fallopian tube without ovarian torsion is a rare cause of lower abdominal pain in reproductive-age women with an incidence of 1 in 1.5 million women. Isolated fallopian tube torsion primarily affects adolescents but can also affect older ovulating women and very rarely in post-menopausal women. Usually causes acute pelvic pain in women. There are no pathognomonic symptoms; clinical, imaging, or laboratory findings. Diagnosis can rarely be made before operation and laparoscopy is necessary to establish the diagnosis. Unfortunately, surgery often is performed too late for tube conservation. Isolated fallopian tube torsion should be suspected in case of acute pelvic pain and prompt intervention is necessary.

Methods

A 35-year-old, para 2 woman presented to the gynecological emergency room with complaint of severe, constant low abdominal pain on left side. She denied any radiation of pain, fever, chills, nausea, or vomiting. No urinary symptoms, vaginal discharge, or bleeding were presented. She was in middle of cycle and UPT negative. On physical examination, focal tenderness was presented in the left lower quadrant. On pelvic examination, left fornix tenderness was noted and there was no cervical motion tenderness. Complete blood count and urinalysis were normal and urine pregnancy test was negative. Endocervical swabs were obtained and were negative. Ultrasound pelvis was suggestive of 7 cm left paraovarian anechoic cyst, 2.4 cm soft tissue mass adjacent to the cyst which may represent a vascular pedicle. She underwent laparoscopy which was suggestive of left tubal cyst 8 cm x 6 cm, torsion with 3 turns, necrotic and hemorrhagic. Left ovary was normal. Uterus and right adnexa was normal. A Left salpingectomy was performed. Histopathology confirmed diagnosis of hydrosalpinx and tubal torsion.

Results

Patient recovered well postoperatively. The patient was counselled and was discharged home the following day.

Conclusions

Although rare, it is important to recognize the possibility of isolated tubal torsion in the setting of hydrosalpinx with a sonographically normal ovary in a patient with acute pain, as delay in diagnosis and treatment may result in increased morbidity. High index of suspicion is required. The diagnosis is generally made at time of surgical exploration. Prompt consideration of this diagnosis and surgical detorsion may prevent irreversible vascular changes.

<https://esge.covr.be/cmdocumentmanagement/conferencemanager/documents/api/getdocument/5177/cmabstsms/000152610/e4e0ffc51ab4120ca9a06209524d4f22fa4802cdef242ae2668f43cc65fa41bb>

ES28-0279 - P140
E-Poster

Laparoscopic radical hysterectomy without uterine manipulator: surgical technique and follow up data

Dimitrios Zygouris¹, Nektarios Chalvatzas¹, Antonis Gkoutzioulis¹, Georgios Anastasiou², Andreas Kavallaris^{1,2}

¹*St Luke's Hospital, Department of Gynecologic Oncology and Minimally Invasive Gynecology, Thessaloniki, Greece*

²*Mother and Child Medical Centre, Department of Gynecologic Oncology and Minimally Invasive Gynecology, Nikosia, Cyprus*

Background

Survival of patients with cervical cancer stage IB - IIA is highly variable. Recent publication of LACC trial showed better results for open surgery compared to minimally invasive approach. We evaluated the outcome after surgical treatment and survival of patients who underwent laparoscopic radical hysterectomy without uterine manipulator.

Methods

In time period of 1/2011 to 01/2019 58 patients underwent laparoscopic radical hysterectomy without using uterine manipulator for cervical cancer. Preoperatively all patients had undergone clinical staging and MRI for the evaluation of lymph node status.

Results

51 patients with stage IB and 7 patients with stage IIA disease underwent laparoscopic radical nerve sparing radical hysterectomy without uterine manipulator. No patient had any major complication and the mean blood loss was 188 ml (100 - 300 ml). Patients were mobilized the first postoperative day and the catheter was removed on the third postoperative day with residual urine volume less than 50 ml. The mean follow-up is 53 months (3 - 86). The recurrence rate was 6.9 % (4 pts) and the mortality rate was 1.7 %.

Conclusions

Laparoscopic nerve sparing radical hysterectomy without uterine manipulator is feasible and safe in patients with cervical cancer St. IB - IIA. It offers oncological safety and the advantages of laparoscopy and nerve sparing technique and might be the next step in minimally invasive surgery in cervical cancer.

<https://esge.covr.be/cmdocumentmanagement/conferencemanager/documents/api/getdocument/5305/cmabstms/000041260/e84fb4a1679aaee7268a9211c2663b7a07d61441866f96059935f724ddd6ce4a>

ES28-0285 - P143
E-Poster

A retrospective study analyzing factors associated with surgical difficulties in laparoscopic hysterectomy and myomectomy

Keisuke Murakami¹, Mari Kitade¹, Rie Ozaki¹, Shinichiro Ikuma¹, Yukiko Okada¹, Itakura Atsuo¹

¹*Juntendo University, Obstetrics and Gynecology, Tokyo, Japan*

Background

Total laparoscopic hysterectomy (TLH) and myomectomy (LM) are frequently performed procedures, however, these surgical difficulties can be affected by several patient factors. Understanding the factors associated with difficulties is an important step in the appropriate case selection and improvement of own surgical technique. We aimed to identify such factors in TLH and LM.

Methods

We included in this retrospective study 377 patients who underwent TLH (n=152) and LM (n=225) for fibroids or adenomyosis at our hospital in 2017. Factors associated with increased operative duration and intraoperative blood loss were reviewed. Patient factors were as follows: age, body mass index (BMI), previous history of vaginal delivery, previous history of laparotomy/laparoscopic surgery, fibroids or adenomyosis, uterine weight, diameter of the largest fibroid, number of enucleated fibroids, adnexal adhesion score and presence of cul-de-sac obliteration. Multiple regression analysis was used to assess the association of these factors.

Results

In TLH, average operative duration was 156±44 minutes and blood loss was 73±102 ml. Uterine weight, adnexal adhesion score and previous history of laparotomy significantly increased the operative duration and blood loss, while a previous history of vaginal delivery decreased operative duration. Previous history of laparoscopic surgery did not increase the operative duration and blood loss. In LM, average operative duration was 132±48 minutes and blood loss was 92±127 ml. The diameter of the largest fibroid and number of enucleated fibroids significantly increased operative duration and blood loss and high BMI also increased operative duration.

Conclusions

Surgical difficulties can be affected by several factors, such as tumor size and the presence of adhesion. Understanding the factors associated with surgical difficulties could be helpful in appropriate case selection depending on the individual surgeon's skills and in ensuring own surgical techniques safely.

<https://esge.covr.be/cmdocumentmanagement/conferencemanager/documents/api/getdocument/5077/cmabstms/000073520/281f13bba5ef58f7337a6d08723fc8d1782eadd2dcd6bee40b93dcf6f40b2159>

ES28-0288 - P144

E-Poster

Reproductive outcomes in infiltrative endometriosis

Alexander Popov¹, Kseniya Krasnopol'skaya², Anton Fedorov¹, Stefan Zingan¹, Albina Kamalova¹, Ruslan Barto¹

¹Moscow Regional State Reserch Institute of Obstetrics and Gynaecology, Endoscopic, Moscow, Russia

²Moscow Regional State Reserch Institute of Obstetrics and Gynaecology, Reproductive, Moscow, Russia

Aim

To develop monitoring of infertile patients associated with different types of infiltrative endometriosis post operation.

Background

The effectiveness of the surgical treatment of infiltrative endometriosis in overcoming infertility in patients of reproductive age, as well as relief of pain after surgical treatment with laparoscopic and robot-assisted access is presented.

Materials / Patients

146 surgeries were performed in infertile patients with diagnosis of infiltrative endometriosis from 2013 to 2018. Average age was 33,28 years old. Average BMI – 21,65. The most frequent location of infiltrate is retrocervical -113 patients (77,6%). Among them the wall of the large bowel was involved in 74 patients (50,3%). In 34 cases (23,7%) rectovaginal walls were involved in pathological process. In 10 cases (6,9%) the wall of the urinary bladder was damaged, in 8 patients (5,5%) the wall of ureter was also damaged

Methods / Results

In 146 patients primary infertility is indicated in 68,49% (100 patients), secondary infertility - в 31,51% (46 patients). Patency of fallopian tubes indicated in 63,7% (93 patients). The frequency of spontaneous pregnancy made 45.16%, irrelevant to the surgical approach. IVF effectiveness made 45.9%. In 8.9% cases there were postoperative complications, the frequency of which was 7 times less in robotic group. Pain relief in 75.85% patients did not depend on the kind of surgical procedure.

Conclusion

laparoscopical and robotic approaches are effective in treatment of infertile patients with infiltrative endometriosis. Highly effective is also pain relief in patients with endometriosis- associated pelvic pain.

Impact to patients' health

Both conventional laparoscopic and robotical surgery are increase pregnancy rate in patient with DIE and infertility.

<https://esge.covr.be/cmdocumentmanagement/conferencemanager/documents/api/getdocument/5000/cmabstms/000065090/e3c2bd48c30c507d87b877b2c212c0e25459d3c2f1f56408809487456434771a>

Protocol: A randomised controlled trial comparing endometrial ablation plus levonorgestrel-releasing intrauterine system versus endometrial ablation alone in women with heavy menstrual bleeding (MIRA 2 trial)

Tamara Oderkerk¹, Peggy Geomini¹, Marlies Bongers¹

¹Maxima Medisch Centrum, Gynaecology and Obstetrics, Veldhoven, The Netherlands

Background

12-25% of the women undergoing a Endometrial Ablation (EA) are dissatisfied, because of persisting abnormal uterine bleeding (AUB) and/or dysmenorrhea and most of these symptomatic women ultimately undergo a hysterectomy. Adding a levonorgestrel releasing intrauterine system may inactivate the residual or regenerative endometrial tissue. Probably this will reduce cyclical pelvic 'period' pain and minimise or eradicate iatrogenic pelvic pain induced by intrauterine adhesion formation associated with endometrial ablative treatment.

We hypothesize that the combination of endometrial ablation and LNG-IUS is superior to endometrial ablation alone in terms of substantially reducing subsequent rates of hysterectomy and alleviating pain and heavy menstrual bleeding.

Methods

Objective: to determine whether the introduction of a levonorgestrel-releasing intrauterine system (LNG-IUS) directly after endometrial ablation (EA) reduces the need for subsequent hysterectomy and alleviates pain and heavy menstrual bleeding compared with endometrial ablation alone.

Study design: Systematic review and multicentre randomized superiority trial.

Study population: Women suffering from heavy menstrual bleeding without contraindications for use of the LNG-IUS who opt for treatment with EA.

Intervention: Endometrial ablation and LNG-IUS combined.

Usual care: Endometrial ablation alone.

Main study parameters

Primary: hysterectomy rate after 2 years of follow-up.

Secondary: patient satisfaction, re-interventions, complications, side-effects.

Results

Four studies were found in literature comparing the treatment with EA and LNG-IUS versus EA alone. The highest described treatment failure was 8.7% in the EA + LNG-IUS group versus 29.2% in the EA group. No hysterectomies were performed in de EA + LNG-IUS group versus 24% in de EA group. The hysterectomies have been performed due to either persistent pain (50%), persistent pain and bleeding (25%) or persistent/ recurrent heavy bleeding (25%).

Conclusions

The conclusion of this literary search is that the combined treatment of EA + LNG-IUS might lead to a decrease in re-intervention. For that reason, in the present study we will investigate the combined treatment of EA + LNG-IUS versus EA alone. This study will be performed under trial number: NL69895.015.19.

<https://esge.covr.be/cmdocumentmanagement/conferencemanager/documents/api/getdocument/4948/cmabstsms/000165650/b192c8610966e0632d16a222c78f9cb08e5ed47c66abf655268eec6eb87a1718>

ES28-0301 - P146

E-Poster

Functional results of promontofixation and mesh-assisted POP surgery

Alexander Popov¹, Elena Efremova², Alexey KovaP, Svetlana Tyurina², Alexander Idashkin², Oksana Fomenko³

¹Moscow Regional Scientific Research Obstetrics and Gynecology, Endoscopic Surgery, Moscow, Russia

²Moscow Regional Scientific Research Institute of Obstetrics and Gynecology, Endoscopic Department, Moscow, Russia

³The State Research Center of Coloproctology, Laboratory of Clinical Pathophysiology, Moscow, Russia

Background

Prevalence of rectocele among all forms of genital prolapse reaches 80% and 77% of women associate first symptoms with delivery. Defecation disorder is found in 55% of patients, that is the reason of decrease of functional capacity and sexual dysfunctional. Frequency of obstructive defecation symptom in patients with rectocele is 50%. Besides rectocele, the reason for obstructive defecation is internal invagination of rectum.

Functional disorders of defecation are the reason why patients are dissatisfied with results of surgery treatment.

Methods

We examined 17 patients with defecation functional disorder, who had reconstructive surgery of pelvic floor because of various forms of genital prolapse. The average age of patients was 56,6 years old. The first group contained 12 patients who had underwent laparoscopic sacrocolpopexy due to apical prolapse. The second group contained 7 patients who had underwent mesh-surgery due to isolated rectocele. Patients from both groups had complex observation including patients history taking, physical examination, defecography, high resistant anal manometry, sphincterometry, exploration of pudendal nerve conduction.

Results

58% of patients from the first group and 100% of patients from the second group had defecation functionals disorders of various patterns. In the first group domination of the 3 pattern of defecation disorder was recorded, in the second group - 1. Neuropathy of pudendal nerve was registered in all examined patients. After surgery in patients from the group 1 domination transformation pattern of defecation disorder into type 3 was diagnosed. Patients from second group didn't show any signs of functional defecation disorder. All patients had a significant improvement in the quality of life in 6 months after surgery in the aspect of proctological complains.

Conclusions

Diagnostic algorithm of any patient with rectocele for exposure of functional defecation disorders should include detecting complaints about rectal function, physical examination, HRAM, defecography, exploration of pudendal nerve conduction, sphincterometry, what will allow to prognose defecation disorder in postoperative period and define the further tactic of rehabilitation.

<https://esge.covr.be/cmdocumentmanagement/conferencemanager/documents/api/getdocument/5162/cmabstms/000065090/e4225d091f6e6bb069f82cedd1895b9a02dbb435c9f70c7161c623c0add595f2>

ES28-0454 - P147

E-Poster

Borderline early stage ovarian tumor staging by conventional laparoscopic single port: a technical approach

Julien Bakenga¹, Genestie catherine²

¹Clinique du Fief de Grimoire, Gynecologic Oncology, Poitiers, France

²Gustav Roussy, Pathology, Villejuif, France

Background

The objective of this study is to assess the feasibility of staging early borderline ovarian tumor by single port access standard treatment include complete surgical resection (cystectomy or oophorectomy) and surgical staging include infra colic omentectomy, peritoneal cytology and biopsies and for mutinous tumors , appendectomy

Methods

We present our first ten cases. The operative technique is fully described the instillation of the patients as we use conventional non curved instruments of classic laparoscopy. The operative time is evaluated We also compare one step to two step staging.

Results

All those ten cases have been fully treated with single port technique. The complete staging had been realised in reasonable time compared to conventional laparoscopy. No complication occurred.

Conclusions

Single port laparoscopic staging in early stage is feasible in reasonable operative time without complications.

<https://esge.covr.be/cmdocumentmanagement/conferencemanager/documents/api/getdocument/5103/cmabstms/000166290/380ffec05e21546d947ee4ee7f3e6a1fc28c9507b95b2ef8f77f5ec3b438d94d>

ES28-0312 - P148

E-Poster

Case report of two isthmoceles in a single patient managed by hysteroscopy

Maha Al-Khaduri¹, Shahila Sheikh²

¹College of Medicine and Health Sciences- Sultan Qaboos University, Obstetrics and Gynecology, Muscat, Sultanate of Oman

²Sultan Qaboos University Hospital, Obstetrics and Gynecology, Muscat, Sultanate of Oman

Background

Cesarean scar defect, also called isthmocele or niche, is a hypoechoic area within the myometrium of the lower uterine segment at the site of the uterine scar of a previous cesarean section. Cesarean section defects can be asymptomatic but in many cases, can lead to gynecological symptoms such as abnormal uterine bleeding, dysmenorrhea, dyspareunia, chronic pelvic pain and infertility. They may also be responsible for future obstetrical complications, such as ectopic pregnancy, uterine rupture and placental anomalies. Isthmocele may be managed by hysteroscopy or laparoscopy. Resectoscopic treatment can be considered effective in small size defects. The published literature describes procedures for repair of a single isthmocele. To our knowledge there has not been any previous report of two isthmoceles in the same patient that was managed by hysteroscopy.

Methods

We report a case of a patient with a history of two lower segment cesarean sections followed by 2 ectopic pregnancies. In her last cesarean surgery she had dense adhesions, plastered abdominal wall layers with bladder, bowel adhesions and atonic postpartum hemorrhage. She presented with secondary infertility and had 3 cycles of ovulation induction which were unsuccessful. An MRI pelvis diagnosed adenomyosis with myometrial defects at two sites in the lower uterine segment from the previous two cesarean sections. Hysteroscopic findings of 2 isthmoceles were identified, one at the internal os and another one just proximal to it. Tissue was resected using a bipolar loop at both isthmoceles to restore the lower uterine segment. An intrauterine foley was placed intraoperatively and left for 24 hours. The patient had an uneventful recovery.

Results

Successful resection of isthmoceles and restoration of lower uterine segment using a hysteroscopic approach.

Conclusions

In patients with multiple cesarean sections it is recommended to rule out multiple isthmoceles. Hysteroscopy can be a simple effective method for repair of more than one isthmoceles in the same patient.

<https://esge.covr.be/cmdocumentmanagement/conferencemanager/documents/api/getdocument/5252/cmabstms/000074870/bf1b5c817898d69a79264f6abcb8e1c2300c0f387cf11cd66c9466ac3411c255>

ES28-0313 - P149
E-Poster

Clinicopathological features of multiple primary neoplasms associated with gynecological malignancies

Yu Zhao¹, Yilun Chen², Qi Shen¹, Qiong Zhang¹, Yue Hu¹, Chih-Jen Tseng³

¹The Second Affiliated Hospital and Yuying Children's Hospital of Wenzhou Medical University, Department of Obstetrics and Gynaecology, Wenzhou, China

²Institute of Public Health- Chung Shan Medical University, Institute of Public Health, Taiwan, China

³Chung Shan Medical University Hospital, Department of Obstetrics and Gynecology, Taiwan, China

Background

Because of the improvement of medical technology and increasing long-term survivors for patients with many types of malignant disease, the problem of multiple primary neoplasms in the same host has increased. Population-based data on multiple primary neoplasms in gynecological malignancies are limited. The purpose of the study is to investigate the clinicopathological features of multiple primary neoplasms in gynecological malignancies and to provide a basis for the development of strategies for prevention and control of gynecological malignancies in the future.

Methods

A retrospective analysis was made of 1084 patients with gynecological malignancies treated in two medical centers during 2001 to 2015. R language (survival package) was used to calculate the overall survival rate of cancer patients and to assess the optimal cutoff time for multiple primary neoplasms.

Results

The total incidence of multiple primary neoplasms in gynecological malignancies was 5.7% (62/1084) in this study, of which 60 patients had double cancers, and two patients had triple cancers. In the 62 multiple primary neoplasms, 38 patients (62%) was metachronous carcinomas, 24 patients (38%) was synchronous carcinomas. Cervical cancer (17 patients, 44.7%) was the most frequent primary tumor type among the metachronous carcinomas and the most frequently observed tumor pairs were uterine corpus cancer-ovarian cancer (12 patients, 19.4%) . In metachronous multiple primary neoplasms, the median period between double cancers diagnosed was 41.6 months. The 3-year survival rate of these 62 multiple primary neoplasms was 80.6% (50/62), metachronous carcinomas was 79% (30/38) and synchronous carcinomas was 83% (20/24). 73.9 months could be the optimal cut-off diagnosis time for metachronous carcinoma patients who had longer survival time ($P<0.05$).

Conclusions

We conclude that gynecological malignancies are often associated with primary cancers elsewhere. A patient presenting with a gynecological malignancy should be thoroughly examined for second cancer, as should patients being followed-up carefully after the treatment for gynecological malignancies.

<https://esge.covr.be/cmdocumentmanagement/conferencemanager/documents/api/getdocument/5090/cmabstsms/000165230/8db41e396bf1308d7aaa971b07301e9abbfdd6d640f0122266ea206134f447e9>

ES28-0317 - P150
E-Poster

Hidden blood loss and its risk factors in laparoscopic radical hysterectomy for cervical cancer

Qiong Zhang¹, Yu Zhao¹, Yue Hu¹

¹The Second Affiliated Hospital and Yuying Children's Hospital of Wenzhou Medical University, Department of Obstetrics and Gynaecology, Wenzhou, China

Background

The aim of the present study was to investigate the amount of hidden blood loss (HBL) in laparoscopic radical hysterectomy (LRH) and to identify its risk factors to provide more comprehensive suggestions for clinical assessment.

Methods

Forty-eight patients who were treated with LRH were enrolled in this study. Their electronic medical data were collected to calculate the HBL and its risk factors were identified by multiple linear regression analysis.

Results

We observed a visible blood loss (VBL) of 191.15 ± 74.79 mL throughout the perioperative period. At the same time, the hidden blood loss was 152.53 ± 52.52 mL, which was slightly lower than the VBL and accounted for $45.34 \pm 11.49\%$ of the total blood loss (TBL). Multiple linear regression analysis suggested that patient age ($p=0.000$), operation time ($p=0.035$), hypertension ($p=0.024$) and pathological tumour type ($p=0.032$) were independent risk factors that contributed to HBL.

Conclusions

The amount of HBL was gravely neglected in LRH, which accounted for a large proportion of TBL. Additionally, age, hypertension, surgical time and pathological tumour type had the potential to increase HBL. When HBL is considered, therapeutic benefits may be gained in the prognosis of cervical cancer patients.

<https://esge.covr.be/cmdocumentmanagement/conferencemanager/documents/api/getdocument/5093/cmabstsms/000165260/2b4d09e15ad23f19e5ad235b4ee037cba76ae0453475443350fbdebc0475c3f6>

ES28-0319 - P151

E-Poster

Intracellular estrogen metabolism in endometrial cancer

Karlijn Cornel¹, Marlies Y Bongers²

¹Maastricht University Medical Center, Gynaecology & Obstetrics, Maastricht, The Netherlands

²Maxima Medical Center, Gynaecology & Obstetrics, Eindhoven, The Netherlands

Aim

The aim of this thesis was to investigate;

- The role of the local estrogen related enzymes in EC compared to postmenopausal controls
- The relation between the local estrogen metabolism in EC and patients prognosis
- The local estrogen metabolism and targeted treatment in EC

Background

There are two ways to classify endometrial cancer; by type (*type I* and *type II*) or by molecular profile (*POLE*, *p53* mutated, *microsatellite stable* and *non-specific molecular protein*).

In around 80% of cases, EC is related to increased unopposed estrogen exposure.

The estrogen metabolism can be divided in the 'systemic estrogen metabolism' influencing the 'local estrogen metabolism' by providing precursor steroids. A detailed overview of the complex intracrine estrogen metabolism in endometrial cancer is given in figure 1 chapter 1. The most important local reactions and their related enzymes are; 1) the conversion of estrogen sulfatase (E1S) into estrone (E1) by the enzyme steroid sulfatase (STS), whereas estrogen sulfotransferase (SULT1E1) catalyzes the opposite reaction (E1 à E1S); 2) the reductive reaction of E1 into 17 β -estradiol (E2) by the enzyme 17 β -hydroxysteroid dehydrogenase (HSD17) type 1, whereas the oxidative reaction E2 à E1 is catalyzed by the enzyme HSD17 type 2; and 3) conversion of androstenedione into E1 and testosterone into E2 by the enzyme aromatase (CYP19A1).

Research has shown an increased serum steroid level in endometrial cancer patients compared to postmenopausal controls. Furthermore, increased production of 17 β -estradiol is shown in ectopic endometriosis lesions compared to eutopic endometrium, with a specific decreased activity of the HSD17B2 enzyme. Those results suggest changes in the local estrogen metabolism in these endometrium related lesions

Materials / Patients

Chapter 1: Introduction

Chapter 2 describes a systematic review of the available literature on the most important local estrogen related enzymes (activity, protein levels, and mRNA levels of STS, SULT1E1, CYP19A1, HSD17B1 and HSD17B2) in relation to endometrial cancer.

Chapter 3 studies the local inter-conversions between estrone and 17 β -estradiol in endometrial cancer tissues compared to postmenopausal controls. Using a total of 53 EC tissues (29 grade 1, 18 grade 2 and 11 grade 3) and 16 normal postmenopausal controls were included.

In Chapter 4 the involvement of the intracrine STS, SULT1E1 and CYP19A1 enzymes in EC compared to postmenopausal controls was evaluated. By using tissue from 31 EC patients (21 grade 1 and 10 grade 2/3) and 19 postmenopausal controls were included. For SULT1E1 an enzymatic activity assay based on measurements of the product estrone 3-sulfate (E1S) with LC-MS/MS was developed.

Chapter 5 studied the relation of the local enzymes levels in EC and patients prognosis. Through measurements of the mRNA expression levels of HSD17B1, HSD17B2, STS, SULT1E1 and CYP19A1 in 175 ECs using cDNA microarray. Proteins were explored by immunohistochemistry.

Chapter 6 describes our exploration of the possibility of inhibiting HSD17B1 and impair the generation of 17 β -estradiol from estrone in EC using in vitro, in vivo and ex vivo models.

In chapter 7 molecular changes were studied between normal endometrium, atypical hyperplasia (a EC precursor lesion) and EC.

A retrospective study was conducted in patients diagnosed with endometrial hyperplasia. Promoter methylation of *APC*, *hMLH1*, *O6-MGMT*, *P14*, *P16*, *RASSF1*, *RUNX3* was analysed on pre-operative biopsies, and correlated to the final histological diagnosis, and related to the presence of *K-Ras* mutations. A total cohort of 98 cases was studied and differences in promoter methylation are observed for *hMLH1*, *O6-MGMT*, and *P16*.

Methods / Results

The systematically provided data showed a large discrepancy in results reported by studies due to 1) technical issues, sub-optimal study-design and patient cohort definition; 2) only recently it is possible to accurately access serum and tissue steroid levels by LC-MS and provide robust conclusions; 3) biological patient to patient variability account for a significant part of the contradictions described in various studies. (chapter 2)

A significant increased HSD17B1 enzyme activity, mRNA level and protein level was found in in grade 1 EC tissues which was even more prominent when including estrogen receptor (ER) α positive grade 1 ECs only, compared to the postmenopausal controls. mRNA levels for HSD17B4, 5, 7, 8 and 12 did not vary between all grades of EC and postmenopausal controls, whereas the mRNA level of HSD17B2 was increased in high-grade lesions compared to postmenopausal controls. Furthermore, three-dimensional ex vivo EC explant cultures demonstrated that HSD17B1 generates 17 β -estradiol out of estrone, which results in increased cell proliferation.

In conclusion HSD17B1 increases 17 β -estradiol exposure in grade 1 EC and therefore supporting tumor growth. This enzyme represents a potential therapeutic target (chapter 3).

Both the STS enzyme activity level and STS/SULT1E1 ratio for enzyme activity level were significantly decreased in EC grade 1 when compared to postmenopausal controls. No significant difference was found for SULT1E1 enzyme activity level. The protein expression (measured by immunohistochemical staining) showed no significant difference for STS and SULT1E1 when comparing EC with postmenopausal controls. There were no significant differences in STS, SULT1E1 and CYP19A1 mRNA levels between EC grade 1, EC grade 2/3 and postmenopausal controls. No significant difference in the calculated mRNA ratio STS/SULT1E1 was found between the three groups. No correlation could be found between enzyme activity, protein level and mRNA expression level for STS and SULT1E1. In conclusion, neither the sulfatase, nor the aromatase pathway seems to be altered in EC (chapter 4).

Patients with high intra-tumour mRNA expression levels of HSD17B1 had a poorer prognosis compared with those with low mRNA expression levels. Combining the mRNA expression of HSD17B1 and HSD17B2 in tumour tissues, patients with high expression of HSD17B1 and low levels of HSD17B2 had the poorest prognosis. Contrarily, women with high tumour mRNA expression levels of HSD17B2 and low of HSD17B1 had the best outcome. No differences in prognosis were seen for STS, SULT1E1, STS/SULT1E1 and CYP19A1 mRNA expression levels. At the protein level (analyzed by immunohistochemistry), HSD17B2, STS and SULT1E1 were highly expressed, whereas the protein expression of HSD17B1 was low and CYP19A1 protein expression was almost absent. In conclusion, HSD17B1 is a promising marker to predict EC prognosis (chapter 5)

Special developed EC cell lines which were derived from the well-differentiated endometrial adenocarcinoma Ishikawa cell line which expressed levels of HSD17B1 similar to human tissues were examined. In these cells, HPLC analysis showed blockage of HSD17B1 activity by a specific HSD17B1 inhibitor. In vitro, estrone administration elicited colony formation similar to 17 β -estradiol and this was impaired by HSD17B1 inhibition. In vivo, tumors grafted on the chicken chorioallantoic membrane (CAM) demonstrated that estrone upregulated the expression of the estrogen responsive cyclin A similar to 17 β -estradiol, which was impaired by HSD27B1 inhibition. Neither in vitro nor in vivo effects of

estrone were observed using HSD17B1-negative cells (negative control). Using a patient cohort of 52 primary ECs, the presence of HSD17B1 enzyme activity (ex vivo in tumor tissues, as measured by HPLC) was demonstrated, which was inhibited by over 90% in more than 45% of ECs using the HSD17B1 inhibitor. Since drug treatment is generally indicated for metastatic/recurrent and not primary tumor, the mRNA expression of the potential drug target, HSD17B1, was also demonstrated in metastatic lesions using a second cohort of 37 EC patients. In conclusion, HSD17B1 inhibition efficiently blocks the generation of 17 β -estradiol from estrone using various EC models (Chapter 6).

Promoter methylation of *hMLH1* and *O6-MGMT* gradually increases from normal endometrium to AH to EC; 27.3, 36.4% and 38.0% for *hMLH1* and 8.3%, 18.2% and 31.4% for *O6-MGMT*, respectively. *P16* promoter methylation is significantly different in AH (7.7%) compared to EC (38%). *K-Ras* mutations were observed in 12.1% of AH, and in 19.6% of EC cases. No association of *K-Ras* mutation with promoter methylation of any of the tested genes was found.

In conclusion *hMLH1* and *O6-MGMT* promoter methylation are frequently present in atypical endometrial hyperplasia, and thus considered to be early events in the carcinogenesis of EC, whereas *P16* promoter methylation was mainly present in EC and not in precursor lesions supporting a late event in the carcinogenesis of EC (Chapter 7).

Discussion

The results shown in this thesis should be validated in other well-defined patient and control cohorts;

- Performing the same or even more sensitive measurement techniques in relation to steroids and enzymes related to the estrogen metabolism is important to be able to compare studies on international bases and standardized laboratory techniques should be available for all researchers. As mentioned the introduction of LC-MS resulted in a much more sensitive assay than other frequently used TLC methods in the past.
- Improvement in the development of new techniques is necessary. For example measuring protein levels can be difficult because of extremely low expression levels, which we are not able to detect accurately at this moment due to the lack of sensitive antibodies.
- To improve clinical implementation easy to perform, quick and cost-effective techniques need to be developed for tumour characterisation. This will result in more individualized treatment options resulting in increased individual prognosis.
- Regarding the clinical introduction of the HSD17B1 inhibitor a well established mouse model, closely related to the human setting (intra-uterine tumour presentation in postmenopausal mice (ovariectomised)) is necessary before phase I/II trials in human can be performed.

Some of these questions will be (partly) answered by our own developed mouse model were mice developing intra-uterine well-differentiated endometrial cancer expressing the HSD17B1 enzyme.

International collaboration as performed in some of the studies in this thesis is necessary and will be continued, to unravel the endometrial cancer carcinogenesis. We are proud that the MUMC+ is part of the European (ENITEC) and global collaboration in this research-topic.

Conclusion

- Increased expression of HSD17B1 results in an increased local production of 17 β -estradiol in EC and is, in combination with low HSD17B2 expression, related with poorer prognosis in EC patients.
- STS, SULT1E1, CYP19A1 and HSD17B2 seems to be less important in the local generation of 17 β -estradiol in EC.
- Blocking HSD17B1 seems efficient in reducing the conversion of estrone into 17 β -estradiol in vitro, in vivo en ex vivo and therefore is an important therapeutic target for the treatment of preselected patients.
- *hMLH1* and *O6-MGMT* promoter methylation and *K-Ras* mutation seem to be early events in the carcinogenesis of EC. Whereas, *P16* promoter methylation seems to be a late event in the development of EC. This data supports the importance of epigenetic changes in de EC carcinogenesis

Impact to Patients' Health

The results of this thesis are interesting for research groups investigating the estrogen metabolism in endometrial carcinogenesis, treatment developers, clinicians and last but not least in the future patients suffering from endometrial cancer. When individualized tumour characterization will be feasible in clinical setting and interference in the estrogen metabolism resulting in decreased local estrogen levels becomes available, preventive measures and individualized adjuvant treatment can be developed to improve patients prognosis and quality of life.

ES28-0322 - P152

E-Poster

Asymptomatic cesarean scar viable gestation managed with ultrasound guided local potassium chloride and methotrexate followed by systemic methotrexate: a case report

Maha Al-Khaduri¹, Nihal Al Riyam², Shahila Sheikh²

¹College of Medicine and Health Sciences- Sultan Qaboos University, Obstetrics and Gynecology, Muscat, Sultanate of Oman

²Sultan Qaboos University Hospital, Obstetrics and Gynecology, Muscat, Sultanate of Oman

Background

Cesarean section rates are increasing with subsequent increase in complications related to the procedure. One such complication is caesarean scar ectopic pregnancy, with an incidence of 1 in 1,886 to 2,216 pregnancies. An ultrasound scan, Doppler examination and magnetic resonance imaging are all useful in early detection of asymptomatic cesarean scar pregnancy, thus enabling effective treatment and preservation of fertility. Management of scar ectopic can be challenging due to risk of significant bleeding and very high risk of hysterectomy and fertility loss. Synchronous usage of several treatment methods is an effective way to manage cesarean scar pregnancy. Local methotrexate therapy or potassium chloride (under ultrasound or hysteroscopy guidance) should be considered as it offers fertility preservation in asymptomatic pregnant patients.

Methods

We report a case of a patient presenting with secondary infertility and a history of one previous cesarean section with an incidental finding of a scar ectopic pregnancy at 5 weeks gestation just above the internal cervical os with a positive fetal cardiac activity diagnosed by transvaginal ultrasound and elevated B-Hcg levels. The patient did not miss a period and was seen in the infertility clinic for routine follow up. The patient was asymptomatic and hemodynamically stable. An MRI confirmed the diagnosis. Ultrasound guided intrasac injection of potassium chloride and methotrexate was performed in order to stop the cardiac activity in the foetus and the patient was followed by ultrasound confirming loss of cardiac activity and collapse of the sac. The serum B-Hcg remained elevated at one week post procedure with vascularity around the sac so a single dose of systemic methotrexate was administered. She was followed four and seven days later with finding of reduced serum B-Hcg and vascularity by Doppler ultrasound.

Results

Successful management of viable gestation scar ectopic using intrasac potassium chloride and methotrexate followed by single dose systemic methotrexate at one week post procedure.

Conclusions

Multimodality treatment for viable scar ectopic gestation can prevent significant hemorrhage and preserve patient's fertility.

ES28-0324 - P153

E-Poster

The long-term therapeutic efficacy of levonorgestrel-releasing intrauterine device in different histopathological diagnosis symptomatic for menorrhagia

Müge Keskin¹, Didem Cakmak¹, Aslı Yarıcı Gürsoy¹, Mine Kiseli¹, Gamze Sinem Çağlar¹

¹Ufuk University Faculty of Medicine, Obstetrics and Gynecology, Ankara, Turkey

Background

Menorrhagia is a common problem of reproductive age (1). Underlying pathologies causing menorrhagia are usually benign, yet accurate diagnosis is important for choosing the optimal treatment modality (2). There are many treatment options for menorrhagia including hormonal or non-hormonal medical therapies and surgical procedures (3). Levonorgestrel-releasing intrauterine device (LNG-IUD) (Mirena®, Bayer, İstanbul, Turkey) is a reversible hormonal contraceptive method with a proven efficacy in the management of menorrhagia (4). Different histopathological diagnosis may underlie menorrhagia symptom. In this study, the outcomes of LNG-IUD hormonal therapy for menorrhagia were evaluated in different histopathological diagnosis.

Methods

A retrospective data of patients diagnosed with menorrhagia (n=135) subsequently underwent LNG-IUD insertion at our gynecology and obstetrics department is reviewed. Basic demographic parameters, patient satisfaction rates and histopathological findings are reported.

Results

Mean (\pm sd) age of the patients was 42.86 \pm 6.9 years. Initial histopathologic diagnosis of the cases was as follows: proliferative phase endometrium in 37 (27.4%) patients, secretory phase endometrium in 26 (19.2%) patients, endometrial polyp in 19 (14%) cases, endometrial hyperplasia in 11 (8.1%) cases and endometritis in 5 (3.7%) patients. The remaining 37 cases (27.4%) had various different diagnoses such as myoma uteri (other than type 0, 1 and 2) and adenomyosis. LNG-IUD was applied as hormonal treatment in all cases. Endometrial sampling was repeated after 3 months in patients diagnosed with endometrial hyperplasia as follow-up. The follow-up of cases ranged from one year to 7 years after insertion. High patient satisfaction rates were recorded in all women after one year of insertion. All of the patients had improved bleeding patterns with amenorrhea or scanty menstrual periods, except one patient who underwent hysterectomy.

Conclusions

In patients with menorrhagia LNG-IUD is an effective treatment modality (5). Other than great improvement in patients' symptoms, tolerability, safety and long-term use of this therapy leads to high satisfaction rates. In addition, the results obtained from this study confirm the data that LNG-IUD has therapeutic efficacy in the treatment of endometrial hyperplasia and it also appears to be beneficial with low recurrence rates in patients with endometrial polyps (2).

<https://esge.covr.be/cmdocumentmanagement/conferencemanager/documents/api/getdocument/5004/cmabstms/000064210/e44bd2798193722082073d116be4818aed0cca68886402e9f49c19f5005844ed>

ES28-0331 - P154 E-Poster

Evaluation of effectiveness of endometrial sampling with pipelle endometrial biopsy compared to curettage and directed biopsy in pre- and postmenopausal women

Iolia Akaev^{1,2}, Emma Khoury³, Chit Cheng Yeoh⁴, Siavash Rahimi⁵, Francis Gardner⁶

¹University of Portsmouth, School of Pharmacy and Biomedical Sciences, Portsmouth, United Kingdom

²Portsmouth Hospitals NHS Trust- Queen Alexandra Hospital, Department of Histopathology, Portsmouth, United Kingdom

³University of Liverpool, School of Medicine, Liverpool, United Kingdom

⁴Portsmouth Hospitals NHS Trust- Queen Alexandra Hospital, Oncology Department, Portsmouth, United Kingdom

⁵Brighton and Sussex University Hospitals NHS Trust- Royal Sussex County Hospital, Department of Histopathology, Brighton, United Kingdom

⁶Portsmouth Hospitals NHS Trust- Queen Alexandra Hospital, Department of Obstetrics and Gynaecology, Portsmouth, United Kingdom

Background

Abnormal uterine bleeding should be investigated initially by ultrasound (USS) followed by hysteroscopy if the endometrium is abnormal on USS. It is recommended this should be performed in the outpatient setting unless there are contraindications. The endometrium is commonly sampled using a pipelle, which may provide insufficient material for histological examination. Patients are often subjected to further investigation, including a repeat biopsy, to rule out serious underlying causes.

The aim of the study was to evaluate the effectiveness of pipelle endometrial biopsy in pre- and postmenopausal women compared to curettage and MyoSure directed biopsy and to record the number of repeated biopsies required to establish a diagnosis.

Methods

A retrospective cohort study was performed evaluating endometrial biopsy samples from histological electronic records to confirm the nature of the sampling technique and number of procedures following pipelle sampling, either

reported sufficient for histological diagnosis or insufficient for histological diagnosis, in pre- and postmenopausal women.

Results

Premenopausal group (n=329): 11.9% of pipelle biopsies were reported as insufficient for diagnosis; 88.1% of patients had a single pipelle reported for a diagnosis, of these who had an initial pipelle 17.2% had a further curettage biopsy, 5.9% a directed biopsy, 17.2% another pipelle, 59.7% had no repeated procedures.

Postmenopausal group (n=129): 21.7% of pipelle biopsies were reported as insufficient for diagnosis; 78.3% of pipelle biopsies were sufficient for diagnosis, of those 9.9% had an initial pipelle followed by curettage, 19.8% by directed biopsy, 7.9% by pipelle, 62.4% had no repeated procedures.

3.8% and 21.4% of repeated curettage were insufficient in pre- and postmenopausal groups respectively. Directed biopsies always provided sufficient material for diagnosis.

Conclusions

Pipelle provided more insufficient biopsies in postmenopausal group. In both groups, a high number of repeated biopsies were required, which could have been avoided if directed biopsy had been used. Curettage is mainly used with general anaesthetic, but can be replaced by the MyoSure directed biopsy, which can be done in an ambulatory clinic avoiding general anaesthesia. This is more cost effective; the amount of biopsy tissue is superior and is reliably taken from the area of abnormality. Furthermore, polyps and other pathologies can also be resected with this device in a single procedure.

In premenopausal women with thickened endometrium, pipelle can be used without a hysteroscopic examination, but as we have demonstrated the number of repeated procedures is still high, despite the sufficiency of obtained material. Thus, use of a directed biopsy with hysteroscopy would provide a superior service to the patient, it would significantly shorten the treatment pathway for these patients and ultimately be more cost effective for the healthcare economy.

<https://esge.covr.be/cmdocumentmanagement/conferencemanager/documents/api/getdocument/5232/cmabstms/000164780/16b7c40afbc48bb57807f3c7c94df52ec2d34924b4641032352b8f9e67eca04f>

ES28-0330 - P155

E-Poster

Smooth muscle tumour of uncertain malignant potential (STUMP) - an unexpected finding in a 54 year old woman

Dorothea Saragli¹, Kostis Nikolopoulos², Manolis Nikolopoulos³, Mohamad Abdelwehab⁴, Pandelis Athanasias⁵

¹Clinical Fellow in Ambulatory Gynaecology, St Helier Hospital, London, United Kingdom

²Clinical Fellow in Ambulatory Gynaecology, St Helier Hospital, London, United Kingdom

³Clinical Fellow in Gynaecology Oncology, St Helier Hospital, London, United Kingdom

⁴Clinical Fellow in Fertility, St Helier Hospital, London, United Kingdom

⁵Consultant Obstetrician Gynaecologist-Lead for Ambulatory Gynaecology, St Helier Hospital, London, United Kingdom

Background

STUMP tumors are a very rare and a quite heterogenous entity. Due to limited data, there is no consensus regarding either the histological diagnosis or the appropriate management plan. Clinical suspicion is very difficult as the symptoms are similar to benign leiomyomas. Currently, there is no imaging method to positively diagnose STUMP preoperatively. The tumours are categorized between benign and malignant with usually less aggressive behavior than leiomyosarcomas, while they carry a small risk of delayed recurrence.

Methods

We report a case of a 54 year old woman with a known fibroid uterus, who underwent a total abdominal hysterectomy and bilateral salpingo-oophorectomy due to menorrhagia and pressure symptoms. Histology identified a STUMP.

Results

A 54 year old woman with known fibroids presented with heavy menstrual bleeding and urinary frequency. Preoperatively, a pelvic MRI showed endometrial thickness of 5 mm. Multiple fibroids were identified with the biggest, arising from the posterior uterine wall, measuring 10x8.4x6.4 cm. That fibroid showed central cystic degeneration with marked vascularity in the remaining tissue. Trace of free fluid was noted and no obvious lymphadenopathy. The post op histological report showed nuclei with mild to moderate atypia, 4-6mitosis per 10High Power Field(HPF) and no cellular necrosis, suggestive of a subtype of STUMP tumors. This is called atypical leiomyomas with low risk of recurrence. Immunohistochemistry showed cells negative for p53 but positive for p16 and Ki67. The patient made an uneventful recovery and was discharged home 3 days later.

Conclusions

Although STUMP tumors are quite uncommon, it could always be part of the differential diagnosis when treating women with fibroids if studies discovered certain imaging features. As a minimum requirement, fibroids should always be morcellated inside a bag when we take a laparoscopic approach. Future studies are needed to establish diagnostic criteria. Individualized plan according to the patient's age and fertility goals should be made. In view of the small but not negligible risk of recurrence, yearly follow up with clinical examination and imaging is the approach of our department. Advances in the field of molecular genetics and immunochemistry may provide us with further information in order to establish specific guidelines in the future.

<https://esge.covr.be/cmdocumentmanagement/conferencemanager/documents/api/getdocument/5234/cmabstms/000164830/b91ac5775141dfe82dbda5ff11648c289a030f691ed06131c7e48515886d95bf>

ES28-0334 - P156

E-Poster

A case-control study of the association between vaginal microbiota and vaginal lesions

Fangyue Zhou¹, Jingxin Ding¹

¹Obstetrics and Gynecology Hospital of Fudan University, Gynecology, Shanghai, China

Background

Recent studies have suggested potential role of the microbiome in cervical diseases. The correlation between microbiome and vaginal carcinogenesis, however, has not been explored. The purpose of this study was to assess the association between vaginal microbiota and vaginal lesions.

Methods

61 women afflicted by vaginal lesions with (n=27) or without (n=34) cervical lesions were enrolled in this cross-sectional case-control study with definite pathological diagnosis. Severity of cervical lesions and menopause status were both taken into consideration for matching patients. All of the 122 cases were human papillomavirus (HPV) positive. Their vaginal microbiota was determined using Illumina sequencing of the 16S rRNA gene amplified from DNA extracted from vaginal mucus samples.

Results

Lactobacillus iners was the dominant *Lactobacillus*, of all the 122 cases. The vaginal microbiota of women with vaginal lesions was characterized by higher abundance of *Atopobium*, *Gardnerella* and *Clostridium* and lower abundance of *Fingoldia* compared with that of women without vaginal lesions. Increased vaginal microbiome diversity was observed in women with vaginal intraepithelial neoplasia (VAIN) 2/3 and vaginal cancer, as well as a higher level of *Enterococcus* compared with VAIN1. Besides, the abundance of *Lactobacillus* decreased, while *Streptococcus*, *Prevotella*, and *Anaerococcus* increased in menopausal women with or without vaginal lesions. Premenopausal women with vaginal lesions interestingly showed higher microbiome diversity than menopausal ones.

Conclusions

Our findings suggest that in patients with HPV or cervicovaginal lesions, the most abundant *Lactobacillus* is *Lactobacillus iners*. The vaginal microbiota of women with vaginal lesions indicates increased level of *Atopobium*, *Gardnerella* and *Clostridium*. In VAIN2/3 or vaginal cancer, increased vaginal microbiome diversity was observed.

<https://esge.covr.be/cmdocumentmanagement/conferencemanager/documents/api/getdocument/5068/cmabstms/000164640/535d056deea259c268dfc4dc933d0567b12396c05d530230e12573c59d4ec880>

Latrogenic gastric injury in a routine diagnostic laparoscopy

Dorothea Saragli¹, Kostis Nikolopoulos¹, Manolis Nikolopoulos², Mohamad Abdelwehab³, Pandelis Athanasias⁴

¹*Clinical Fellow in Ambulatory Gynaecology, St Helier Hospital, London, United Kingdom*

²*Clinical Fellow in Gynaecology Oncology, St Helier Hospital, London, United Kingdom*

³*Clinical Fellow in Fertility, St Helier Hospital, London, United Kingdom*

⁴*Consultant Obstetrician Gynaecologist-Lead for Ambulatory Gynaecology, St Helier Hospital, London, United Kingdom*

Background

Laparoscopy has gained popularity in the past 20 years and is currently widely used in gynaecology. Overall is considered to be very safe with most common severe complications involving urological, vascular and gastrointestinal injuries (1-4/1000). Most of those injuries occur during the entry phase, either by the primary trochar or Veress needle. Gastric injuries are very rare with incidence of 1-2/100.000

Methods

We report the case of a 22 year old nulliparous woman, with normal BMI who underwent a diagnostic laparoscopy for severe dysmenorrhea and deep dyspareunia. Combined oral contraceptive pills and hormonal coil were not successful to treat her symptoms. Her past medical history included 2 laparoscopic ovarian cystectomies and a laparoscopic appendectomy. Pelvic MRI was unremarkable. As the symptoms were affecting the quality of life, decision was made to proceed with a diagnostic laparoscopy

Results

The patient was intubated with an endotracheal tube of 7mm with a length to lips of 22cm. Observations were normal. Veress needle was inserted at the base of the umbilicus, Palmer's test was performed but the intra-abdominal pressure was high (12 mmHg). Second attempt was made with similar findings, so open entry (Hasson) was performed. 10mm umbilical and 5mm left iliac fossa ports were inserted and a gastric perforation was strongly suspected. The stomach appeared very distended and a possible puncture site was identified. There was no active bleeding. All vital signs were normal. An oesophago-gastroduodenoscopy(OGD) was performed intraoperatively by the general surgeons and the injury was confirmed. The perforation was sutured laparoscopically due to bleeding. A nasogastric tube (NGT) was inserted. On questioning the anaesthetist stated that the intubation was difficult and initially the ET tube might have not been in the correct anatomical position. Post-operatively the NGT stayed in situ for 24hrs, proton pump inhibitors(PPI) were prescribed for 6 weeks and prophylactic antibiotics were also given. The patient made a quick recovery and was discharged home 2 days later.

Conclusions

Gastric distention during difficult intubation is associated with gastric injuries in laparoscopic surgery. Other risk factors for delayed gastric evacuation and consequent dilatation include obesity, diabetes and autoimmune diseases. Previous gastro-hepatic surgeries are also a major risk factor for gastric displacement. When risk factors are identified, an alternative entry point must be sought. Gastric distention should ideally be excluded prior to the start of the operation by palpation and the insertion of NGT is essential. When a gastric injury is suspected, the site of injury and surroundings organs should be examined thoroughly. The posterior gastric wall should also be examined and an OGD should be performed, so that through and through injuries are noted. General surgeons should be involved. Conservative or surgical treatment depends on the size and severity of bleeding

<https://esge.covr.be/cmdocumentmanagement/conferencemanager/documents/api/getdocument/5308/cmabstsms/0010164830/b392bd35ad7daa50702a390bcbc45068bba6493c6c915eb1d82531448c05c9eb>

Transumbilical morcellation while performing hysterectomy with single-port access

Elena Konstantinova¹, Boris Tsyvian¹, Samvel Vardnian¹

¹City Hospital №40, Gynaecological Department, Saint Petersburg, Russia

Background

To compare transumbilical and transcervical method of morcellation in patients with myoma uteri during single-port access hysterectomy.

Electromechanical morcellation in laparoscopic hysterectomy is a minimally invasive method to remove the uterine specimen from the abdominal cavity without the need for additional incisions on the anterior abdominal wall. The advantages of morcellation are reducing the severity of pain, shortening the period of hospital stay, low injury, cosmesis, improving the quality of life of patients. Despite of this use of morcellation can lead to negative consequences, such as: damage to large vessels, adjacent organs, deterioration of the prognosis in the malignant nature of the tumor lesion. Understanding and implementing safe laparoscopic morcellation techniques can reduce the incidence of these complications.

An improved technique morcellation when performing single-port laparoscopic hysterectomy allows for faster, more reliable and safer to perform the removal of the uterine specimen from the abdominal cavity, to reduce the risk of injury of adjacent organs and operating time.

Methods

The study was conducted on a cohort of 20 women who underwent single – port laparoscopic hysterectomy for myoma uteri at City hospital №40 (Saint Petersburg) between 2012 to 2018. In 12 cases, the specimen of the uterine body was extracted from the abdominal cavity by a typical transcervical method. In 8 cases, an improved method of morcellation - transumbilical-was used.

Results

In standard single-port supravaginal hysterectomy duration of morcellation through the cervical canal in an average of 15.17±1.95 min (95% CI: of 13.93-16.4 min). The average duration of new method of morcellation was 10.44±2.19 minutes (95% CI: 8.76-12.12 minutes) (p<0.001). In transcervical morcellation, the average duration of surgical intervention was 120.0±25.5 minutes (95% CI: 103.8-136.2 min) and in transumbilical surgery – only 89.4±18.4 minutes (95% CI:75.3-103.6 min), (p=0.007). There were no major complications in any case. All hystological results were benign leiomyoma.

Conclusions

FDA in The United States doesn't recommend the use of electromechanical morcellation in women with suspicion or confirmed presence of a malignant process. The Russian clinical guidelines for treatment of uterine fibroids don't have a restriction on the use of morcellation in laparoscopic hysterectomy. However, high oncological alertness remains during the preoperative investigation. All patients underwent pelvic MRI, endometrial biopsy and analysis for LDH before surgery. In doubtful cases, extraction packages are used or preference is given to laparotomy. The proposed technique of transumbilical morcellation allows to quickly, reliably, habitually and safely perform removal of the specimen from the abdominal cavity. This technology reduces the risk of injury to adjacent organs, the time of surgery and anaesthetic benefits, as well as the period of postoperative recovery of patients. The optimized method makes morcellation with single-port laparoscopic supravaginal hysterectomy simple, fast, safe and comfortable for the surgeon. There was no negative impact to patient's health.

<https://esge.covr.be/cmdocumentmanagement/conferencemanager/documents/api/getdocument/5140/cmabstsms/000084530/c7b2ce109af0f1a92b7622e561a2a92c868169bd631db227f2de3e6920512044>

ES28-0344 - P159

E-Poster

Laparoscopic female sterilization in ambulatory setting – evolution of care through the years

Sara Bernardes da Cunha¹, Matilde Martins¹, Cátia Rasteiro¹, Cristina Costa¹, Antonio Lanhoso¹, Paula Sarmento²

¹Centro Hospitalar de Entre Douro e Vouga, Obstetrics and gynecology, São Félix da Marinha - Gaia, Portugal

²Centro Hospitalar de Entre Douro e Vouga, Anesthesiology, São Félix da Marinha - Gaia, Portugal

Background

Analyze the evolution through the years of patient clinical status and satisfaction in laparoscopic tubal ligation (LTL) performed in ambulatory surgery (AS) unit.

Methods

A retrospective analysis of the information collected from the 24-hour phone call after gynecology surgery in our AS Unit from 2015 to 2018 was conducted. Women that underwent LTL were selected. Records included pain, hemorrhage, functional status (4 categories: "only hygiene", "some movement limitations", "none limitation" and "normal activity") and patient perceived adequacy of prescribed analgesia and given information. The patients were distributed in two groups- 1: procedures taking place between 2015-16; 2: procedures between 2017-18.

Results

A total of 555 procedures were performed. Pain after procedure was not different between groups. Fever after the procedure was more prevalent in group 1, than in group 2 ($U= 35546$, $p= 0,09$). Reported bleeding was more frequent in group 1, however was not different when classified in none, mild or moderate- ($X^2(2) = 5,92$ $p= 0,052$). There was no difference in the perceived suitability of medication provided ($X^2(1) = 0,826$ $p= 0,363$). Patients of group 2 considered that information was less adequate than patients of group 1 ($X^2(1)= 5,29$ $p= 0,021$).

Global self-evaluation of functional activity revealed smaller scores in group 2. There was an increase of cases with minimal functional status "only hygiene" 24 hours after the procedure and a decrease of patients with no limitation or normal physical activity.

Conclusions

Global satisfaction was high among both groups. Most patients considered prescribed analgesia and given information adequate.

This study identified differences in the occurrence of haemorrhage that was more common in group 1. Negative functional status outcomes were higher in group 2, yet no differences were found on the adequacy of pain medication between groups. Other factors not included in our analyses might explain the findings.

<https://esge.covr.be/cmdocumentmanagement/conferencemanager/documents/api/getdocument/5278/cmabstsms/0000164850/832c0197851cb791a5a70c425306fc6fddf481dd699ed17edefdea189d55ae65>

ES28-0348 - P160

E-Poster

The impact of surgical technique on pseudocapsule of uterine fibroids

Mine Kiseli¹, Gulsah Akgu², Asli Yarci Gursoy¹, Bercem Oguz¹, Melike Bahcecitapar³, Gamze Sinem Caglar¹

¹Ufuk University Faculty of Medicine, Department of Obstetrics and Gynecology, Ankara, Turkey

²Ufuk University Faculty of Medicine, Department of Pathology, Ankara, Turkey

³Hacettepe University, Department of Statistics, Ankara, Turkey

Background

The myoma pseudocapsule has been known to separate the myoma from surrounding myometrium. Recently, other than anatomical function, pseudocapsule has gained biological importance. Intracapsular excision of fibroids is recommended to better maintain the myometrial integrity (Tinelli A 2009). Therefore, surgical technique and surgical access (laparoscopy or laparotomy) in myomectomy can be a determining factor for pseudocapsule excision and healing process. In this study, myomectomy specimens excised by laparoscopy or laparotomy were re-examined to document pseudocapsule excision and thickness.

Methods

Among the myomectomy records operated between January 2018 and December 2018 (n=121), 34 women were randomly chosen for the study. The indications for myomectomy were menstrual disorders, pelvic pain, a large growing myoma or infertility. The operations were either by laparoscopy (n=14) or laparotomy (n=20). In cases with more than 3 fibroids or bigger than 8 cm in diameter laparotomy was preferred. The pathology specimens were re-evaluated by sectioning and measuring the pseudocapsula by a single pathologist.

Results

Mean age of the patients were 41 ± 5.9 years. The diameter of the excised myomas ranged between 3.5 and 15 cm. 17 cases (50%) had more than one fibroid. 14 (41.1%) women underwent laparoscopy and 20 (58.8%) women underwent laparotomy. Mean age of the patients in laparoscopy and laparotomy groups were $39,29 \pm 20$ and $42,90 \pm 23$ respectively ($p=0,082$). Single fibroids occurred in 10 (71%) of the laparoscopy patients while 13 (65%) had multiple myomas in the laparotomy group. Regarding the pseudocapsule of fibroids, re-examination of the fibroid specimens revealed thicker pseudocapsule in laparotomy group compared with laparoscopy group [$1,2$ mm (0,20-4,0) vs $0,75$ mm (0,20-2,0); $p=0.013$]. The postoperative healing and follow-up of all cases were uneventful.

Conclusions

Intracapsular myomectomy saving the fibroid pseudocapsule is suggested to be related with better healing after surgery and improved fertility outcomes (Tinelli A 2012). Laparotomy enables the surgeon for tactile sensation and removal of fibroids more extensively. Therefore, thicker pseudocapsule in laparotomy specimens seems to be related with the surgical technique itself. Even if there seems to be no difference between the two groups in healing process in this study, the low number of cases and the lack of fertility outcomes is a limitation. We infer that, the beneficial effect of laparoscopic surgery with intracapsular myomectomy technique needs to be evaluated for reproductive outcomes in future prospective studies.

<https://esge.covr.be/cmdocumentmanagement/conferencemanager/documents/api/getdocument/5160/cmabstsms/000064210/b7aef1c4780c8af22545a7ff5bdf5c9bfd0d925715cf04cc505abaa6218d4153>

ES28-0349 - P161

E-Poster

Relevance of care in the management of presumed benign ovarian tumours: retrospective observational series on 408 conservatively treated cysts, comparison of the evolution of practices

Anna Jung¹, Louise Reheis¹, Michel Hummel¹, Aline Host¹, Olivier Garbin¹

¹University Hospital, Bas-Rhin, Strasbourg, France

Background

The relevance of care is defined by the right act, for the right patient, at the right time. We were interested in the relevance of the management of presumed benign ovarian tumours before and after the publication of the CNGOF guidelines 2013 (French guidelines).

Methods

This is a retrospective observational study conducted at the University Hospital in Strasbourg France from 01/01/2013 to 31/12/2017, including all patients conservatively treated for a presumed benign ovarian cyst, divided into three groups, one for the year 2013 before the guidelines, one for 2014 to 2016 and one for 2017 after the guidelines are published. We were interested in the diagnostic approach (relevance of the prescribed imaging and the use of CA 125 dosage) on one hand and in the therapeutic approach with the relevance of the technique used and the relevance of the surgical indication on the other hand. The items studied were classified as relevant, irrelevant but justified, irrelevant. For these same items, we compared our practices in 2013 with those in 2017.

Results

Results. We included 408 cysts for 356 patients, the imaging performed was relevant in 47.2% of cases, irrelevant but justified in 33.8% and irrelevant in 19.1% with most cysts determined with unnecessary second-line imaging or large masses (>7cm) without second-line MRI. The CA 125 assay or its absence of assay was relevant in 82.9% of cases. The surgical technique was relevant in 88.9% of cases and not relevant justified in 10.8%. The surgical indication was relevant in 66.2% of cases, justified in 8.1% of cases, irrelevant justified in 21.1% and

irrelevant in 4.5% of cases with mostly small asymptomatic cysts. The anatomopathological analysis shows that in 77.6% of cases the initial diagnosis is confirmed. For dermoids, 91.8% correspond to the diagnosis made in imaging and 96.3% for endometriomas. We had 1 case of cancer, 2 cases of borderline tumor and 28 functional cysts (9.1%) not relevant.

Conclusions

To our knowledge, this is the first series in gynecology to evaluate the relevance of our practices. For imaging, two areas of improvement have been identified: dermoid cysts characterized on ultrasound, which still too often have an MRI and masses over 7 cm do not have enough. Regarding the dosage of CA 125, we have observed a clear improvement in practices since the last recommendations. The surgery indications are mainly relevant (95.5% of cases), with the residual question of whether it is really necessary to operate on asymptomatic pure liquid cysts, even large or progressive.

<https://esge.covr.be/cmdocumentmanagement/conferencemanager/documents/api/getdocument/4994/cmabstms/000166100/28652d3fdbc210c82d028f78dcc20f87bdf37aac503ce062928596fd8b1f09d>

ES28-0350 - P162
E-Poster

Is isthmocele a cause of infertility in patients with retroverted uteri?

Huseyin Kiyak¹, Berk Bulu²

¹*Kanuni Sultan Süleyman Teaching and Research Hospital, Obstetric and Gynecology, İstanbul, Turkey*

²*Istinye University- Liv Hospital, Obstetrics and Gynecology - IVF Center, İstanbul, Turkey*

Background

Cesarean delivery rates have increased dramatically worldwide. Risk of cesarean scar pregnancy, placenta accreta and uterine rupture are increased following cesarean deliveries. Perimenstrual spotting, pain and secondary infertility due to defective scar healing are some of the late complications of cesarean delivery.

An isthmocele is a myometrial defect observed on the cesarean incision site and its incidence is reported to range between 19-56%. The aim of this video was to present our technique for repairing an isthmocele in a retroverted uterus.

Methods

A 38 year old G1 P1 patient with a history of one cesarean delivery presented to the infertility clinic with inability to conceive for the past 3 years. She had undergone a cycle of in vitro fertilization treatment one year previously. The patient had a total antral follicle count of 5-6 and her AMH level was 0.8 ng/ml. On hysterosalpingography both Fallopian tubes appeared to be patent, however an isthmocele site was detected on the previous incision.

On laparoscopy the peritoneum of the bladder was dissected using an ultrasonic scalpel to determine the location of the isthmocele. The urinary bladder was densely adherent to the underlying myometrium and was dissected from the uterus using a lateral approach from both sides of the cervix. Following this the isthmocele defect was easily identifiable. We applied sutures on the upper and lower borders of the isthmocele defect to help in defining the areas which needed to be excised. The thick fibrotic tissue surrounding the scar defect was resected until healthy looking myometrial tissue was visible. The incision site was sutured in two layers. Additional sutures were placed aiming to reduce the tension in the previously placed sutures since retroverted uteri may be under increased risk of defective healing because of the tension caused by the weight of the uterine fundus.

Results

The patient was discharged from hospital 24 hours postoperatively without complications. The patient was offered IVF treatment due to decreased ovarian reserve and advanced maternal age. However the patient became pregnant spontaneously on the postoperative 8th month. She delivered a healthy baby at 39 gestational weeks by cesarean delivery.

Conclusions

Isthmoceles may be a cause of secondary infertility through various mechanisms. Menstrual blood accumulating within the isthmocele defect may provide a culture medium for ascending infections of the genital tract. The reflux of this fluid towards the endometrial cavity may have embryotoxic effects. Sperm transport from the cervix to the Fallopian tube may also be hampered due to the presence of this defect.

We believe the risk of isthmocele development is higher in retroverted uteri and placing additional sutures to relieve the tension caused by the weight of the fundus on the incision site may help in better healing of this area.

<https://esge.covr.be/cmdocumentmanagement/conferencemanager/documents/api/getdocument/5275/cmabstms/000143350/7e4d63780992807f590c93e1cf62780fea662a15fe61b176d6ff5db977008aaf>

ES28-0352 - P163 E-Poster

Preliminary objective evaluation of the FlexDex® needle holder: surgical performance and ergonomics

Francisco Margallo¹, Juan A. Sánchez-Margallo²

¹Minimally Invasive Surgery Center, Laparoscopy, Cáceres, Spain

²Minimally Invasive Surgery Center, Bioengineering and Health Technologies Unit, Cáceres, Spain

Background

With this study we seek to objectively evaluate the use of the new FlexDex® instrument during laparoscopic practice. For this purpose, surgical performance and surgeon's ergonomics were assessed during different tasks on a laparoscopic simulator, comparing them with the use of a conventional laparoscopic needle holder.

Methods

Three experienced laparoscopic surgeons (> 100 laparoscopic procedures) performed a peg transfer and a suturing task on a laparoscopic simulator. The peg transfer task consisted of transferring, using both hands, a surgical needle through a circuit's rings. The suturing tasks consisted of performing an intracorporeal suture on an organic tissue with a double and two single knots in opposite directions. Tasks were repeated five times and were carried out using the FlexDex® instrument and a conventional needle holder in a random fashion. Prior to the study, participants conducted a 15-minute training session with the new instrument. Execution time was recorded for each trial. In addition, flexion and radioulnar deviation of the wrist were recorded using an electrogoniometer (Biopac Systems, Inc.) attached to the surgeon's hand and forearm and the activation of the forearm muscles was also analyzed by means of a MYO armband (Thalmic Labs).

Results

Surgeons required more time to perform both the transfer task (183.8 ± 53.2 s vs 295.8 ± 55.7 s; $p < 0.05$) and the intracorporeal suture (69.0 ± 12.5 s. vs 73.2 ± 13.8 s; $p < 0.05$) using the novel laparoscopic needle holder. The use of the flexible instrument led to higher muscular activation of the extensor (18.978 ± 1.816 RMS vs 26.165 ± 4.085 RMS; $p < 0.01$) and flexor (12.373 ± 1.378 RMS vs 16.734 ± 3.043 RMS; $p < 0.01$) muscle groups of the forearm. Although ulnar deviation ($23.047 \pm 5.318^\circ$ vs $22.878 \pm 3.277^\circ$) and flexion ($12.030 \pm 3.740^\circ$ vs $10.730 \pm 5.316^\circ$) of the wrist were lower with the new instrument, no statistically significant differences were shown.

Conclusions

We believe that a longer training period is required with the FlexDex® instrument in order to achieve similar surgical performance as with conventional laparoscopic instruments. The preliminary results of this study show that the new instrument allows ergonomically more adequate postures for the surgeon during laparoscopic practice, although it is physically more demanding.

<https://esge.covr.be/cmdocumentmanagement/conferencemanager/documents/api/getdocument/5216/cmabstms/000048170/a52b6838511677b05bee917d9c00a831c61693938e192ebefb7ce5ab423871bb>

ES28-0357 - P164
E-Poster

Is Fitz-Hugh-Curtis syndrome a common laparoscopic finding in young women with pelvic inflammatory disease?

Sima Romina-Marina¹, Anca-Daniela Stanescu¹, Liana Ples²

¹UMF Carol Davila, Obstetrics-Gynecology, Bucharest, Romania

²UMF Carol Davila, Obstetrics and Gynecology, Bucharest, Romania

Background

Fitz-Hugh-Curtis syndrome (FHCS), represents a chronic manifestation of pelvic inflammatory disease characterized by perihepatitis or adhesions between the anterior surface of the liver and the abdominal wall. The real incidence is uncertain. The objective of our study was to evaluate if FHCS is a common finding among patients that underwent laparoscopy pelvic inflammatory disease (PID) or chronic pelvic pain.

Methods

We performed a descriptive retrospective cohort study in Bucur Maternity from Bucharest between 2014 and 2018 among patients who were admitted for PID. Patients age, symptoms, ultrasounds findings, treatment were recorded for each patient. Patients with endometriosis and prior surgical interventions were excluded from the study. The laparoscopy was the standard procedure for chronic pelvic disease.

Results

312 patients with PID were admitted in our department during the period of study. Fifty-eight patients underwent laparoscopic surgery for pelvic pain and constituted the study group. Among them 28% patients were registered with primary or secondary infertility prior to surgery. 78.6% patients presented different types of pelvic adhesions. 62% of the laparoscopies were performed for unilateral or bilateral sactosalpinx. There were registered 2.3% cases with severe abdominal adhesions in patients without endometriosis or other surgical risk factors. We performed adhesiolysis without other surgical interventions adnexa in 56% cases. FHCS was not a common finding in our study group. It represented 11.2% from all patients. The peculiarity is that the severity of pain was not correlated with FHCS. Adhesiolysis was performed in 56% cases with FHCS. The evolution was uneventful in all cases.

Conclusions

Laparoscopy is the standard method in order to diagnose and treat chronic PID. FHCS is a characteristic of PID and is not correlated with severity of symptoms.

<https://esge.covr.be/cmdocumentmanagement/conferencemanager/documents/api/getdocument/5123/cmabstsms/0000158720/03927f116e710c6e29ba7b633434746910696eaa4ef20cb031f72e6f5ded5726>

ES28-0359 - P165
E-Poster

Clinical complete response after radiochemotherapy due to FIGO IV stage gynecological cancers - response evaluation and replanning during course of radiation therapy

Mateusz Bilski¹, Andrzej Kukielka¹, Monika Bilaska², Bartek Barczyński², Krzysztof Patyra¹

¹Nu-med- Center of Oncology Diagnostics and Therapy, Radiation Therapy Department, Zamość, Poland

²Medical University of Lublin, 1st Chair and Department of Oncological Gynecology and Gynecology, Lublin, Poland

Background

FIGO (International Federation of Gynecology and Obstetrics) IV stage gynecological cancers have poor prognosis. We aim to present clinical complete response after radical radiochemotherapy due to FIGO IV stage gynecological cancers who were disqualified from surgical management. Radical radiotherapy/ radiochemotherapy in those patients is very hard to manage due to large volumes and high doses needed to achieve clinical complete response. Because of high risk of toxicities due to this type of treatment many patients undergo only palliative management. We suppose that evaluation of the clinical response during the course of radiation therapy may be a very helpful tool in replanning and shrinking the volume for final boost to the remnant tumour.

Methods

We performed a preliminary analysis of radiation therapy management and clinical response in 5 patients with FIGO IV stage gynecological cancers. 3 patients with cervical cancer, 1 patient with vaginal cancer and 1 patient with vulvar cancer. All of the patients had bladder and/or rectal infiltration. They were qualified to radical radiochemotherapy to the doses between 60-66 Gy with concurrent chemotherapy. All patients had MRI diagnostic response evaluation after 50-54Gy and 2 months after completing radio/ radiochemotherapy.

Results

All of the patients had near complete clinical response in MRI performed during treatment. MRI testing before the end of radiation therapy enabled us to shrink large primary volumes and boost remnant tumour to high doses of radiotherapy without increasing acute toxicity. All of the patients achieved complete clinical response in MRI performed 2 months after completing radio/ radiochemotherapy. The toxicity due to performed treatment was very low and resolved before second MRI diagnostic scan.

Conclusions

FIGO IV stage gynecological cancers, after good selection, might be treated in radical way to high doses of radiation therapy without serious toxicity. In those patients evaluation of response before the end of radiation therapy might be a key point. It enables to shrink the volume for final boost which might lead to clinical complete response and lower the potential toxicities due to smaller volumes of healthy tissue being irradiated.

<https://esge.covr.be/cmdocumentmanagement/conferencemanager/documents/api/getdocument/5070/cmabstsms/0000166160/fd952101757268cb88dd60f5bbf7c5ab2eb4d972b4460cfa2b94a73142d17e9b>

ES28-0360 - P166

E-Poster

The learning curve for laparoscopic hysterectomy-the experience of our clinic

Sima Romina-Marina¹, Iulia Margarit², Adelina Ivan³, Liana Ples¹

¹umf carol davila, Obstetrics-Gynecology, Bucharest, Romania

²St John Hospital- Bucur Maternity, Obstetrics-Gynecology, Bucharest, Romania

³St. John Hospital- Bucur Maternity, Obstetrics-Gynecology, Bucharest, Romania

Background

Hysterectomy represents the most common gynecological operation after caesarean section. The laparoscopic approach of uterine removal introduced since 1988 experience now a steady place due to the improvement of laparoscopic equipment and to the standardisation of the procedure. Learning curve is different from one department to another and it is related to technique, equipment and different uncommon factors. The purpose of our study was to evaluate the learning curve of laparoscopic hysterectomy in our department.

Methods

We reviewed and analyzed the medical records of patients who underwent laparoscopic hysterectomy for benign conditions at "Saint John Hospital" from 2017. We selected this period because it was the moment when a new medical team started to perform this procedure. We included in the study only the first 20 operations because later the operation time was similar. The team reached the plate period of the normal learning curve.

Results

A standard equipment was used for laparoscopic hysterectomy (atraumatic grasping forceps, bipolar clamp, laparoscopic scissors and irrigation and suction device). The first operation time for laparoscopic hysterectomy was 380 minutes. After 20 interventions the operation time decreased to 176-140 minutes. The reduction time was considerably reduced due to vagina suture improvement technique from about 40 minutes to 15 minutes. Overall the time improved with approximately 5.2% per intervention. The conversion rate to laparotomy was low (1.2%) because the cases were without previous cesarean sections, with small uterus and low body mass index.

Conclusions

In our study, the medical team that performed laparoscopic hysterectomy had a good learning curve. The operation time improved significantly. This operation can be safe for beginners surgeons if the cases are attentively selected.

<https://esge.covr.be/cmdocumentmanagement/conferencemanager/documents/api/getdocument/5124/cmabstms/00158720/325d13faff4d64c1dd074715e81babebc65ed627d8008f78beec7732e98ab054>

ES28-0367 - P167

E-Poster

Correlation between preoperative evaluation of deep infiltrating endometriosis and intraoperative findings using Enzian score and rASRM classification

Voicu Simedrea¹, Margan Roxana¹, Margan Madalin²

¹*EndoInstitute, Gynecology, Timisoara, Romania*

²*County Hospital, Gynecology, Timisoara, Romania*

Background

Deep infiltrating endometriosis (DIE) is a debilitating condition with an ill-defined set of symptoms, associated with significant delays in diagnosis and treatment, which severely impacts patients' quality of life and raises big healthcare costs.

Our purpose was to make a comparison of preoperative staging of DIE, by clinical exam, ultrasonography and magnetic resonance imaging (MRI) with intraoperative findings by means of the Enzian and rASRM score (The revised American Society for Reproductive Medicine

Methods

Between October 2017 and September 2018, a total of 103 women underwent surgery due to deeply infiltrating endometriosis, at Premier Hospital, Endo institute - Endometriosis competence center specialized in minimally invasive surgery, in Timișoara, Romania. Symptomatology was recorded preoperatively, as well as clinical exam, intravaginal ultrasonography, MRI, and they were later compared with intraoperative findings by means of the ENZIAN score and rASRM score. Laparoscopy was the main surgical approach

Results

A clear correlation was seen between grades of severity in the rASRM score and the Enzian classification. There was a strong correlation between clinical findings and ultrasonography, in relation with MRI results and intraoperative findings, especially for lesions in vagina, rectovaginal space, rectum, sigmoid colon and bladder, almost 90% for vagina/rectovaginal space and 85% for rectum/sigmoid colon. For uterosacral ligaments and intestine sensitivity and negative predictive values were lower, due to technical aspects, such as impossibility of evaluating the small intestine by ultrasonography.

Conclusions

In our study, ultrasonography and MRI-based Enzian score correlates well with the intraoperative findings, enabling a better multidisciplinary approach of the surgical procedure, involving endometriosis surgeon, visceral surgeon and urologist. As well, a correct preoperative evaluation of all deep endometriosis lesions is mandatory in order to correctly inform the patients about possible risks, complications, and surgical costs. Therefore, Enzian score represents an excellent communication tool between radiologists and gynaecologists and facilitates the whole process, from diagnosis to surgical treatment

ES28-0372 - P168

E-Poster

Need for fertility preservation in woman with endometriosis

Joanna Bubak-Dawidziuk^{1,2}

¹*Center for Biostructure Research Medical University of Warsaw, Department of Histology and Embryology, Warsaw, Poland*

²*Szpital im. Sw. Rodziny, Department of Gynecology and Gynecologic Oncology, Warsaw, Poland*

Background

To evaluate the impact of endometriosis for ovarian reserve via measurements of serum anti-Müllerian hormone (AMH), follicle stimulating hormone (FSH), estradiol and to indicate groups of patients where fertility preservation should be considered.

Methods

From August 2017 to July 2018 a prospective cohort study was performed. It included 50 patients below 35 years with confirmed endometriosis who were followed by laparoscopic surgery. AMH, FSH and Estradiol levels were assessed before and approximately one month after surgery. The stage of endometriosis was evaluated by rAFS and rEnzian classification. All patients filled in a questionnaire of medical history and previous treatment. Afterwards they underwent laparoscopic removal of all endometriotic lesions. Post operatively they were divided into groups using rAFS and rEnzian classification.

Results

The AMH level of operated patients was importantly reduced after surgery (from 2.95 ± 2.14 [mean \pm SD] at baseline to 1.05 ± 1.56 at follow-up). There was a statistically significant correlation between the rate of serum AMH decline and stage of endometriosis according to rAFS classification ($p=0,014$). The decline was about $0,31 \pm 0,8$ [mean \pm SD]; $0,08 \pm 0,64$; $1,68 \pm 1,44$; $1,38 \pm 1,9$ respectively in group I, II, III, IV. In addition, patients with bilateral ovarian endometriomas showed the highest decline of AMH levels compared with unilateral ovarian endometriosis (about $2,16 \pm 2,45$ in bilateral group; about $1,42 \pm 1,31$ in unilateral endometriosis). However, also patients who were not observed with cysts had a decreased level of AMH after surgery about $0,44 \pm 1,2$. FSH and Estradiol levels were not statistically significant.

Conclusions

The rate of serum AMH is significant indicator of ovarian reserve. It should be marked before all endometriosis surgeries as its level might be declined even in minimal and mild stages. Since it is reduced postoperatively all patients with endometriosis should be offered fertility preservation techniques.

<https://esge.covr.be/cmdocumentmanagement/conferencemanager/documents/api/getdocument/5039/cmabstsms/0000149390/82096bd5376db0047be5446a30e29d5e1e2b5de14cfc9154323bcc0eca4db33d>

ES28-0377 - P169

E-Poster

The preoperative diagnosis and surgical strategy for various severe endometriosis

Mari Kitade¹, Keisuke Murakami¹, Yukiko Okada¹, Shinichiro Ikuma¹, Rie Ozaki¹, Atsuo Itakura¹

¹*Juntendo University Faculty of Medicine, Obstetrics and Gynecology, Tokyo, Japan*

Background

Severe endometriosis may cause various pain as like dysmenorrhea and chronic pelvic pain, thereby significantly compromising women's quality of life. In this presentation, I would like to present a useful method of preoperative diagnosis and a strategy of laparoscopic surgery for women with severe endometriosis.

Methods

Deep infiltrating endometriosis (DIE): MRI jerry method developed in our department is useful for preoperative diagnosis of DIE. In the surgical technique, careful dissection is performed between the uterus and the rectum to enter

into the accurate layer of Douglas' Pouch. The severe adhesion in pelvic side wall areas is also dissected. When there are some infiltrating endometriotic nodules, we resect and remove it with scissors.

Colorectal endometriosis: Accurate preoperative diagnosis is necessary by using colon fiber or MRI jerry method to evaluate of the surgical indication. We usually perform careful dissection for complete Cul de Sac obliteration and anastomosis of rectum (low anterior resection).

Ureteral endometriosis: The hydronephrosis due to fibrotic stenosis of ureter are identified by CT, DIP, MRU. After insertion of ureteral stent, we usually dissected peri-ureteral adhesion and removed fibrous tissue of peri-ureteral deep endometriosis without anastomosis of ureter.

Bladder endometriosis: After imaging examination such as US, CT and cystoscopy, we performed the resection of bladder endometriosis under the cystoscopic monitoring. When the tumor was near the ureteral openings, we considered inserting ureteral stent preoperatively.

Results

Deep infiltrating endometriosis (DIE): 91 cases with DIE underwent laparoscopic surgery in our hospital and their visual analog scale (VAS) of menstrual pain significantly decreased (from 7.7 ± 2.6 to 3.1 ± 2.7) after surgery ($p < 0.01$).

Colorectal endometriosis: Laparoscopic surgery was performed in 12 cases, resulting in the improvement of postoperative symptoms in all the cases.

Ureteral endometriosis: Laparoscopic surgery has been performed for 4 cases, only one patient occurred postoperative recurrence, but it could be improved by ureteral stent therapy for only 3 months.

Bladder endometriosis: 6 cases underwent laparoscopic surgery in our hospital and the improvement of postoperative symptoms was observed in all the cases.

Conclusions

Laparoscopic surgery was found to be useful for women who suffered from various pain due to severe endometriosis. However, appropriate surgical indication and expert surgical skills are essentially, considering the difficulty of laparoscopic surgery for severe endometriosis.

ES28-0378 - P171 E-Poster

Total hysteroscopic removal of a submucosal uterine myoma with the use of cold knife

Antonios Gkoutzioulis¹, Angelos Daniilidis¹, Matina Dalla¹, Christiana Louka¹, Veronika Konstantinidou¹, Konstantinos Dinas¹

¹Hippokratio General Hospital Aristotle University, 2nd University Department of Obstetrics and Gynecology, Thessaloniki, Greece

Background

We demonstrate a technique for totally removing a 3 cm type 1 submucosal uterine myoma, with relative safety and minimal damage to the endometrial wall.

Methods

We report a case of a nuliparous 30 years old single woman with a history of menorrhagia. The ultrasonographic finding was a submucous fibroid measuring 3 cm. Initially a no touch diagnostic hysteroscopy was performed, which presented a type 1 fibroid, with 30% of it being intramural. Then a monopolar resectoscope was inserted and resection of the myoma was performed, up to the point when the endometrial lining was reached. Then gradually, with the use of the cold knife, the pseudocapsule of the myoma was recognized and gradually being detached from the uterine wall, until the whole of the fibroid was removed from the uterus.

Results

This technique involved the use of the resectoscope with a standard loop and the use of the hysteroscopic cold knife used only mechanically. After the initial resection of the fibroid, and the removal of the resected tissue, the loop is switched to the cold knife. For minimizing fluid absorption, the glycine solution was switched to normal saline during the use of the cold knife, since no electricity was used at that part of the procedure. Since the first menstruation after

the surgery, the patient did not report any abnormal bleeding and in a 3 year follow up did not present again any sign of menorrhagia.

Conclusions

This technique shows that the removal of medium/large submucosal fibroid type 1 can be safely removed in one step, by minimizing the use of electricity, thus reducing the risk of uterine perforation and thermal injury to adjacent organs.

<https://esge.covr.be/cmdocumentmanagement/conferencemanager/documents/api/getdocument/4914/cmabstsms/000044250/397fbb8b2fb45e2afdca39274fd366068855fc0e5a627d0dbe435461e31b02b>

ES28-0386 - P172

E-Poster

Isolated fallopian tube torsion: a rare case of acute abdomen in an adolescent female

Ioannis Tsimpanakos¹, Sandra Ampomah¹, Natalia Barbaneagra¹, Hemant Vakharia¹

¹Royal Free London - Barnet Hospital, Obstetrics & Gynaecology, London, United Kingdom

Background

Isolated fallopian tube torsion, that excludes the ovary, is a rare and challenging diagnosis. The clinical presentation can be non-specific and similar to acute abdominal emergencies, such as appendicitis. We herein report the case of a 12-year-old girl including discussion of the imaging and laparoscopic management.

Methods

Case report: A 12-year-old girl presented to the emergency department with an acute 4-hour history of sudden onset right iliac fossa pain, which was tender and rigid in palpation, suggesting acute peritonitis. However, other clinical observations were within normal limits on admission and she was afebrile. Biochemical and haematological investigations revealed only slight neutrophilia ($9.1 \times 10^9/L$) and the pregnancy test was negative.

Results

Pelvic ultrasonography was reported as showing a 6.5 x 5 x 6cm thin walled right adnexal cyst containing anechoic fluid with no evidence of internal haemorrhage or vascularity, which was suggestive of a simple right ovarian cyst. Because of the acuity and severity of symptoms, pelvic CT scan was performed and revealed the presence of an apparently thickened right fallopian tube with irregular thickening of the cyst wall, which was thought to be compatible with ovarian cyst torsion. The patient underwent an urgent laparoscopy that showed isolated torsion of the right fallopian tube with a distended and necrotic appearance. Both ovaries, uterus, the left fallopian tube and pouch of Douglas were normal. The affected tube was detorted, fluid was aspirated and sent for cytology and a right salpingectomy was performed with the use of bipolar diathermy (Ligasure). Histopathological examination of the right fallopian tube showed features of haemorrhagic infarction in keeping with torsion. The patient had an uneventful post-operative course and full recovery; upon discharge she was counselled regarding potential future fertility issues.

Conclusions

Isolated fallopian tube torsion is a rare cause of acute lower abdominal pain. Its diagnosis is usually delayed as there are no reliable radiological investigations and the clinical features are similar to surgical causes of acute abdomen. There should be a high index of suspicion so that urgent laparoscopy is performed for confirmation of the diagnosis and definitive management. Treatment is salpingectomy, as it often presents late with necrosis; however, an attempt to untwist the tube should be considered with the aim to regain fertility in women of reproductive age.

<https://esge.covr.be/cmdocumentmanagement/conferencemanager/documents/api/getdocument/5227/cmabstsms/000073390/e557ea374267aa6abc407d6b88c6a045150505594163bff56cb1b62cfbc6ca3c>

ES28-0387 - P173

E-Poster

Development of an outpatient hysteroscopy patient satisfaction survey

Ayesha Mahmud¹, Justin Clark²

¹*Walsall Manor Hospital, Obstetrics and Gynaecology, Birmingham, United Kingdom*

²*Birmingham Women's and Children's NHS foundation trust, Obstetrics and Gynaecology, Birmingham, United Kingdom*

Background

Outpatient hysteroscopy is the cornerstone of modern-day ambulatory gynaecological surgery. Hysteroscopy can help diagnose endometrial and structural cavity pathologies associated with abnormal uterine bleeding (AUB) and reproductive failure. As a safe, cost-effective, and well-tolerated procedure, the benefits of hysteroscopy are well recognized. However, currently, there is a need for an outpatient hysteroscopy tool that represents women's hysteroscopy journey, capturing the care, they receive. We report the development of a patient satisfaction survey developed as part of a service improvement project.

Methods

In collaboration with a multi-disciplinary team of hysteroscopy experts (British society of gynecological endoscopy), a pilot patient satisfaction survey was crafted based on current best practice guidance in outpatient hysteroscopy and existing hysteroscopy questionnaires. The pilot questionnaire was then tested across two hospital sites providing outpatient hysteroscopy services. Participants were asked to reflect on their experience of the care they received while completing the questionnaire, and asked to provide feedback on the questionnaire content. This helped provide an understanding of women's outpatient hysteroscopy journey and facilitated the modification of the pilot questionnaire into its final form.

Results

Thirty women participated in this quality improvement project across two hospital sites. Women provided feedback that informed successive revisions of the pilot questionnaire. Four key themes representing women's journey of outpatient hysteroscopy were crafted into a two-page questionnaire. These included aspects of care representing the continuum of their outpatient hysteroscopy journey (i.e. before, during and after) and their overall experience.

Conclusions

We developed a women-centred outpatient hysteroscopy patient satisfaction survey suitable for routine use in outpatient hysteroscopy. This survey will be rolled out nationally across the United Kingdom (U.K) as a useful resource for clinicians wanting to collect and report data on outpatient hysteroscopy practices both locally and nationally.

<https://esge.covr.be/cmdocumentmanagement/conferencemanager/documents/api/getdocument/5261/cmabstms/000092560/c137fd732967a83e60a65e860aad0b4ea149cdec9065fa68e44f5ad73675a756>

ES28-0406 - P175

E-Poster

A comparison of local outcomes following the management of deep infiltrating endometriosis requiring para-rectal space dissection with the national UK dataset

Adam Naskretski¹, Janet Berry¹, Alexandra Weaver¹, Katie-Ellen Candy¹, Nadine Di Donato¹, Denis Tsepov¹

¹*Queen Alexandra Hospital, Gynaecology, Portsmouth, United Kingdom*

Background

Our aim was to assess and evaluate the outcomes for patients requiring para-rectal space dissection as part of the surgical management of deep infiltrating endometriosis (DIE) between June 2017 and May 2018 at a UK BSGE accredited endometriosis centre and compare this to published national data.

Methods

We carried out a retrospective review of all patients with DIE requiring pararectal space dissection from June 2017 and May 2018. Patients were identified using our centre's British Society for Gynaecology Endoscopy (BSGE) database. The pre- and post-operative patient feedback were reviewed, and a Microsoft Excel spreadsheet was used to compare the data. This was evaluated against the published national data from BSGE gathered from 2009-2016.

We compared the baseline pre-operative median scores of the standardised BSGE pain and quality of life questionnaires to 6 and 12 months post-operative scores. We gave a numerical value from 0 to 4 to the subjective health scores and bowel symptoms. With 0 being none of the time and 4 being all of the time.

Results

Of 50 patients there was one intra-operative complication of a haemorrhage >500mls. There were no post-operative complications recorded.

The median EQUVAS health score improved from 50 pre-operatively, to 75 at 6 months and 80 at 12 months follow-up. Improved health scores were seen in 75% and 86% of respondents at 6 and 12 months respectively, with 22% worsened quality of life at 6 months, but only 11% at 12 months. Improvements were also seen in the median premenstrual pain score, from 7 to 6 and then further to 4 at 12 months. Menstrual pain improved from 9 to 6 at 12 months and non-cyclical pain halved from 6 to 3, as did dyspareunia from 5 to 2, and dyschezia from 3 to 1.

We showed no change to the bowel function and median scores for bowel frequency remained the same with urgency symptoms increasing slightly from 1 to 1.5.

These outcomes were comparable to the published national data.

While the median scores improved there was an important minority for whom the pain

Conclusions

In keeping with the published results from other centres, we have shown comparable improvements in our patient population following surgery for DIE, but with no improvement in the symptoms of bowel function. This allows us to use the national outcomes to aid pre-operative counselling of our patients undergoing surgery for severe endometriosis.

There is a small but important minority of patients who report worsened symptoms postoperatively whose outcomes are masked by using median scores. This possibility is important to include in preoperative counselling of patients considering major surgery for DIE.

<https://esge.covr.be/cmdocumentmanagement/conferencemanager/documents/api/getdocument/5163/cmabstms/000166200/c3f5ae7715547170e571b1de5784855fc3988eabc4319c37ed567082f4f31819>

ES28-0493 - P176
E-Poster

Gynecologic laparoscopic surgery for post-operative living kidney transplantation recipients

Yoshika Akizawa¹, Jun Kumakiri¹, Toshiyuki Kanno¹, Yu Horibe¹, Akira Nakabayashi¹, Tsutomu Tabata¹

¹Tokyo Women's Medical University, Department of Obstetrics and Gynecology, Tokyo, Japan

Background

With advances in medical practice, the number of living kidney transplantation cases has increased to 1,500 per year (2016) in Japan and the renal survival rate at 5 years after transplantation has also improved to more than 90%. On the other hand, reports of other surgical procedures for post-transplantation patients are rare. Herein, we report the practices, noteworthy perioperative cautions, and the innovations in our department.

Methods

Gynecologic laparoscopic surgery was carried out for eight patients with prior living renal transplantation in our department from April 2017 to April 2019.

Results

Laparoscopic surgery after living kidney transplantation was performed in 8 cases: 3 cases of multiple myomas, 3 cases of ovarian tumors, other cases of an atypical endometrial hyperplasia and an endometrial carcinoma. There were 3 cases of laparoscopic myomectomy and 2 cases of total laparoscopic hysterectomy, 3 cases were adnexectomy and an ovarian cystectomy. In all cases, the first approach was the parallel method for surgery, avoiding the renal graft. There was no significant prolongation of the bleeding operative time as compared to the same surgical

operation during the same period. Their postoperative courses were not eventful and they were discharged our hospital at 4-5 days after the surgery.

Conclusions

Minimally invasive laparoscopic surgery after living kidney transplantation is considered to be feasible, providing that a full understanding of the post-transplantation retroperitoneal anatomy has been obtained, based on devising an optimal approach to retroperitoneal dissection which is then carried out by skilled surgeons. In addition, with regard to perioperative management, individual treatments tailored to each case require cooperation with the transplantation team.

<https://esge.covr.be/cmdocumentmanagement/conferencemanager/documents/api/getdocument/5001/cmabstms/0000166390/6bdc1f69238507aeb44fe760b3daa33e8273ad47831200ce15b9111df87acb12>

ES28-0395 - P177

E-Poster

Perioperative surgical outcomes of laparoscopic surgery for endometriosis in obese patients: a comparative propensity score analysis

Diego Raimondo¹, Giulia Mattioli¹, Ivano Raimondo², Gilda Sicilia¹, Giulia Borghese¹, Renato Seracchioli¹

¹Unit of Gynecology and Human Reproduction Physiopathology,

Dipartimento di Scienze Mediche e Chirurgiche DIMEC- S. Orsola Hospital- University of Bologna, Bologna, Italy

²Gynecologic and Obstetric Unit Department of Medical- Surgical and Experimental Sciences- and School in Biomedical Sciences- University of Sassari, Sassari, Italy

Background

Obesity has always been considered a relative contraindication to laparoscopy, due to intrinsic challenges that have to be faced in the surgical treatment of an obese patient. Nevertheless, many studies have proved that laparoscopy has to be considered a valid choice for obese women affected by gynecological and non-gynecological disease, since it is associated with fewer complications if compared to the classical laparotomic approach. The purpose of the study is to compare feasibility and safety of laparoscopic approach for endometriosis surgical removal between obese and non-obese patients.

Methods

This is a retrospective study (Canadian Task Force Classification II-3) on a total of 1,230 consecutive women who underwent complete laparoscopic removal of macroscopic endometriotic lesions between January 2012 and November 2018 in our Tertiary Referral Center. Patients were divided according to the World Health Organization classification of obesity in obese (Body Mass Index (BMI) ≥ 30 kg/m²) and non-obese (BMI < 30 kg/m²).

Results

During the study period, we operated 91 obese patients (7.4% among the entire study population). At bivariate analyses, concerning baseline characteristics, significant differences between the two groups were found in terms of age (38.5 ± 7.6 years in obese vs 34.7 ± 6.1 in non-obese group, $P < .001$), history of previous surgery for endometriosis [47 (51.6%) vs 448 (39.3%), $P = .02$] and stage of endometriosis according to Revised American Society for Reproductive Medicine (r-ASRM) scoring system [stages 3 and 4: 78 (85.7%) vs 629 (55.2%), $P < .001$]. Furthermore, regarding perioperative surgical outcomes, we observed statistical differences between the two groups in terms of operative time (133.9 ± 64.4 minutes vs 123.4 ± 64.2 minutes, $P = .04$) and laparotomic conversion rate [6 (6.6%) vs 24 (2.1%), $P = .008$]; instead, rate of surgical complications within 1 month [7 (7.7%) vs 99 (8.7%), $P = .5$] and duration of hospital stay (4.3 ± 2 days vs 4.8 ± 4.6 days, $P = .9$), didn't differ between the two groups. At multivariate regression analyses, after adjustment for confounding factors, we noted in obese group a prolongation of 15.3 minutes of the operative time ($P = .01$) and an increase of 7.3% in open conversion rate ($P < .001$), but using the propensity score-weighted analyses, among investigated perioperative surgical outcomes only operative time was significant associated with obesity with an average treatment effect in obese patients of 20.4 minutes ($P = .009$).

Conclusions

Laparoscopic approach for endometriosis removal seems not to be negatively influenced by BMI in terms of safety and feasibility, except for operative time, which was observed slightly longer in obese patients.

<https://esge.covr.be/cmdocumentmanagement/conferencemanager/documents/api/getdocument/4968/cmabstms/000062110/34494b94e7c2edab7a7dcfceb8882fa41998d5f9e54c4e0f46ca1f2af602c60f>

ES28-0404 - P178

E-Poster

Ureteric reimplantation and nephrectomy due to deeply infiltrating endometriosis causing ureteric obstruction - a UK BSGE accredited endometriosis centre experience

Janet Berry¹, Alexandra Weaver¹, Lemke Solomon¹, Katie-Ellen Candy¹, Nadine Di Donato¹, Denis Tsepov¹

¹Queen Alexandra Hospital, Gynaecology, Portsmouth, United Kingdom

Background

To review the presentation, diagnosis and management of women with complex deep infiltrating endometriosis (die) requiring ureteric resection and reimplantation, or nephrectomy, secondary to ureteric obstruction by die.

Methods

A retrospective review of all patients with (die) requiring ureteric resection and re-implantation or nephrectomy. Patients were identified via computerised theatre records (theatreman) and cross-referenced against our centre's British society for gynaecology endoscopy endometriosis (BSGE) database. Non-endometriosis re-implantations were excluded. The search covered 2011 to April 2019.

Results

4 patients underwent resection and re-implantation of the ureter and one patient required a nephrectomy.

All cases were diagnosed with stage iii/iv endometriosis prior to being seen by our endometriosis clinic and were asymptomatic of ureteric involvement. In 4 cases the hydronephrosis was diagnosed on imaging (1 on uss, 3 on mri), and in 1 case at laparoscopy, confirmed on subsequent imaging (mri). All renal biochemistry was normal. 2 patients had a mag 3 renal scan, showing reduced renal function on the affected side, with one having marked atrophic changes. All cases were discussed in our endometriosis mdt and surgery was planned as joint cases with the urologists due to the high likelihood of ureteric re-implantation and potential nephrectomy. There were no intra-operative complications or conversions. 4/5 also had rectal involvement, with 2/3 needing a rectal shave and 1/5 segmental resection. Endometriosis was confirmed histologically in all cases. Follow up ranges from 4 months to 7 years. Pre- and post-operative standardised pain and quality of life questionnaires were given to the 4 patients eligible for the BSGE national database. 'Equvas' best imaginable health scores improved in 75%, by an average of 18.8, and there is a tendency to improvement in premenstrual, menstrual, non-cyclical and bladder pain alongside deep dyspareunia. Cyclical and non-cyclical dyschezia, low back pain, difficulty passing urine, bowel urgency and constipation showed worsened average scores. Hydronephrosis improved in all patients and there have been no recurrences of ureteric disease.

Conclusions

Endometriosis of the renal tract affects around 1% of women of childbearing age. Ureteric involvement may be asymptomatic and it is important to maintain a high index of suspicion for die causing ureteric obstruction, with imaging to look for evidence of hydroureter or hydronephrosis. Where diagnosis and management are delayed this can lead to persistent hydronephrosis and irreversible renal damage. Renal biochemistry may be normal, providing false reassurance, even when one kidney has become atrophic with markedly reduced function. Patients benefit from being managed within the endometriosis mdt as recommended by the BSGE. The BSGE database is designed to collect outcomes pertaining to rectovaginal endometriosis. It is important to ensure we also collect pre and post-operative outcome measures for women with urinary tract die as well as those with rectal disease within our units.

<https://esge.covr.be/cmdocumentmanagement/conferencemanager/documents/api/getdocument/5265/cmabstms/000070050/097dc8d3a5883187785b654b705a6f8f745820068cfb01488e4c21976a42acdb>

ES28-0444 - P179

E-Poster

Do endometriosis and myoma have common predisposing factors?

Mauricio Mieli¹, Ana Maria Grell², Gisele Mieli¹, Isabella Grubert¹, Isabela Iwaki¹, Mariana Dantas¹

¹Faculdade de Medicina da Universidade Municipal de Sao Caetano do Sul - Campus Sao Paulo, Ginecologia e Obstetricia, Sao Paulo, Brazil

²Faculdade de Medicina da Universidade de Sao Paulo, Ginecologia, Sao Paulo, Brazil

Background

Uterine fibroids and endometriosis are two very common conditions that can affect women. They may have similar symptoms, but they are very different pathologies. In both there is abnormal growth of tissues. Uterine fibroids are benign tumors that grow in the uterine walls and uterine cavity, whereas endometriosis is caused by misplaced tissue that is normally found in the uterus. When endometrial tissue, represented by glands and stroma, is found apart of the uterus and attached to adjacent organs, such as the large intestine, bladder, or other organs, ovaries, or fallopian tubes, endometriosis occurs.

Methods

A 34-year-old female patient was presented with a large subserous retroperitoneal myoma that started in the body of the uterus and reached the cervix. His MRI did not clarify whether this myoma infiltrated the myometrium. A laparoscopic myomectomy was performed and complete removal of myoma was possible due to subsequent fragmentation for withdrawal from the abdominal cavity.

Results

The fragments were sent to anatomopathological study. The result of microscopic analysis and histopathological conclusion was: benign mesenchymal tumor of smooth muscle cells. Presence of bundles of spindle cells in various directions. Undetected presence of mitotic or necrotic processes. Other findings include stroma and endometrial glands placed in the periphery of leiomyoma. There are no morphological signs of malignancy.

Conclusions

There are several theories as to why the endometrial tissue grows outside the uterus, in spite of having similar risk factors towards uterine myoma cases. Nevertheless, the exact causes are not clear. One of the possible reasons would be genetics; In addition, endometrial cells could relocate into the pelvic cavity in other ways, such as during cesarean section. It is important not to forget the hormonal dysfunctions, the presence of immune depression, occurrence of previous abortions, pelvic inflammatory diseases, among other possible reasons. The tissue affected by endometriosis outside the uterus cannot be completely removed in most cases, which can lead to internal bleeding, inflammatory processes at the surrounding areas and growth of scar tissue. Unlike uterine myoma, endometriosis can often occur in younger women, even in teenagers, after the menarche.

<https://esge.covr.be/cmdocumentmanagement/conferencemanager/documents/api/getdocument/5049/cmabstsms/000074180/15e274cb83948ddfd347ab534ca09146fffe25a485b4bd6b28f27895187c037>

ES28-0409 - P180

E-Poster

Increasing the rates of the laparoscopic route of hysterectomy - how much further can we go?

Juneida Khodabocus¹, Janet Berry¹, Amanda Katerere¹, Ngummanka Timi¹, Denis Tsepov¹

¹Queen Alexandra Hospital- Portsmouth- United Kingdom, Gynaecology, Portsmouth, United Kingdom

Background

A recent paper found a steadily increasing trend in the rate of the laparoscopic route of hysterectomy (lh) for benign disease. a local audit confirmed the same trend within our department over the last 4 years. We aimed to compare the indications, uterine size and operating times of the different hysterectomy routes used for benign cases in our unit and determine whether our lh rate can be increased further still.

Methods

Computerised theatre records search to identify all cases of hysterectomy in 2017. In depth review of hysterectomies done for benign cases (excluding caesarean hysterectomies, oncology cases, vaginal hysterectomies with anterior or posterior repair): indication, operating time and uterus dimensions at histology noted. Uterine volume calculated from dimensions on histology report. classification of hysterectomies as ah (total, subtotal and converted lh), lh or vh. Recording and analysing of data using excel.

Results

558 patients had a hysterectomy in 2017 with 249 performed for benign cases. Of the 247 cases reviewed, 75 were ah (14 subtotal, 3 converted lh), 140 were lh and 32 were vh the most common indications were menorrhagia (72/247), fibroids (54/247) and pelvic pain (68/247, out of which 46 was endometriosis).

For lh, pelvic pain (including endometriosis) was the most common indication compared to ah and vh where the most common indications were fibroid uterus and uterine prolapse respectively.

The uterine volumes varied according to route, with a median of 310 cm³ (mean 308cm³; range: 34 - 1848cm³) for lh, 480 cm³(mean 670cm³; range: 18 - 6358cm³) for ah and 232 cm³. (mean 236cm³;range: 57 - 465cm³) for vh. 62/72 (86.1%) intended ah had uterine volumes less than the largest successful lh specimen (1848cm³).

The median operating times were 150 min (mean 159 min; range 84 - 455 min) lh, 155 min (mean 166 min; range 86 - 404 min) for ah and 113 min (mean 120 min; range 55 - 193 min) in vh.

Conclusions

In 2017, 56.7% of our unit's benign hysterectomies were laparoscopic, commonly for pelvic pain, with ah second commonest at 30.4%, mainly for fibroids. Whilst the median uterine volume was bigger for ah (480cm³) than lh (310cm³), 86% (62/72) of intended ah had uterine volumes smaller than the largest successful lh. Theoretically, these cases were suitable for lh which would reduce hospital stay, improve recovery time, reduce blood loss and improve patient satisfaction and cost-effectiveness. The median operating times for lh and ah are similar (150 vs 155 min) and length of surgery should no longer be used as an argument against lh. With increasing laparoscopic training nationally, the rates of lh are expected to rise further, alongside the uterine size and complexity of surgery.

<https://esge.covr.be/cmdocumentmanagement/conferencemanager/documents/api/getdocument/5180/cmabstms/000158240/2bc9bc3914e6d3cf07b79b15b1123881dd8701cd2841e8eddb00cb8e056f4d3f>

ES28-0410 - P181
E-Poster

Acceptability of morcellator hysteroscopic polypectomy: relationship between pain and polyp size in pre and postmenopausal women - a retrospective descriptive study

Gloria Isabel Ruiz Barrajon¹, Victoria Quintero Morillo¹, Marina Picón Maroñas¹, Juan José Delgado Espeja², Juan Antonio Solano Calvo², Álvaro Zapico Goñ³

¹*Ginecología y Obstetricia- MIR 3, Hospital Príncipe de Asturias, Alcalá de Henares, Spain*

²*Ginecología y Obstetricia- Adjunto, Hospital Príncipe de Asturias, Alcalá de Henares, Spain*

³*Ginecología y Obstetricia- Jefe de Servicio, Hospital Príncipe de Asturias, Alcalá de Henares, Spain*

Background

The aim of this study is to assess the acceptability of hysteroscopic morcellator polypectomy, depending on the polyp size in pre and postmenopausal women.

Methods

Our daily routine is carried out with Bettocchi ® Hysteroscope (5 mm) with working channel (Karl Storz) and hysteroscopic morcellator Truclear SystemW ® (Smith & Nephew).

For our research we analyzed our hysteroscopic database, with more than 6000 records. We made a retrospective and systematic review of 343 morcellator hysteroscopic polypectomies, which were performed in an office setting with vaginoscopic approach and inhalation analgesia (a 50% equimolar mixture of nitrogen protoxide and oxygen). We compared pain in this patients, by a 1-10 visual analog scale (VAS). The absence of pain was numbered as 1 and the

worst imaginable pain by 10. Afterwards, we made two different groups, premenopausal (preM) and postmenopausal (postM) women.

We also evaluated the hysteroscopic time in the different groups of polyp sizes.

Results

There were 343 morcellation polypectomies from March of 2013 to March of 2019. We created three subdivisions based on the polyp size:

- First group was formed by 1-15 mm polyps, the main polyp size in our sample, which represented 56% of the total. The average pain measured with VAS was 4.56 in preM and 3.8 in postM.
- Second group was formed by polyps between 16 and 30 mm, 38% of the total. VAS in this group was 3.8 in preM group and 3.9 in postM.
- And the third one was composed of >31 mm polyps, which were only 6% of the total. The average pain was 2.71 in preM and 3.75 in postM.
- Average surgical time was also analyzed, showing a mean value of 11.5 minutes in the first group (1-15 mm polyps) and 17.5 minutes in the third one (>31 mm polyps).

Conclusions

Hysteroscopy is a well tolerated technique, which produces minimal pain when an optim analgesic method is used, as it happened in our sample. This can extend to both premenopausal and postmenopausal women.

Although the global average pain was slightly higher in postmenopausal women (3.81 in postM vs 3.69 in preM), the difference was not significative.

<https://esge.covr.be/cmdocumentmanagement/conferencemanager/documents/api/getdocument/5153/cmabstms/000166220/2c80d04fef72b40c3a80d1551b4065702c59736266ede76d6dc15f056a26f2df>

ES28-0423 - P182

E-Poster

Outcomes of extended day case laparoscopic hysterectomy (LHi) performed as part of an enhanced recovery pathway (ERP)

Gillian Coyle¹, Gemma Clemente², Charlotte Goumalatsou¹, Johnston Piers¹, Andrew Kent¹

¹Royal Surrey County Hospital, Gynaecology, Guildford, United Kingdom

²Josep Trueta University Hospital, Gynaecology, Girona, Spain

Background

Hysterectomy is a common gynaecological procedure carried out for various conditions including heavy menstrual bleeding and fibroids. LH has always been perceived as taking too long, requiring a high skill set and with little benefit in terms of hospital stay. Previous studies have suggested a higher complication rate compared to the abdominal and vaginal approaches.

We developed an ERP to address these issues so improving patient care and reduce the clinical and financial burden placed on the service and the patient. The key components are preoperative preparation, the surgical technique (LHi) and anaesthetic, postoperative care and follow up. LHi is carried out using the Harmonic and Valtchev Uterine Manipulator (VUM).

Objectives: to demonstrate the pre operative treatments and indications for women undergoing LHi. To outline surgical outcomes including length of surgery, intra operative and post operative complications.

Methods

614 women underwent LHi between 2004 and May 2019. Data were gathered prospectively for demographics, indication, previous surgery, parity and mode of delivery, procedure performed, intra- and post-operative complications and histology. For missing data (occurring when authors were absent for leave), notes were retrospectively analysed. Case notes from 6 women were missing in medical records and one set was missing the relevant documentation. Data were anonymised onto an encrypted database. Statistical analysis was carried out using SPSS.

Results

Data were analysed for the 607 women for whom we have data. Mean age was 47 years, with mean BMI of 27.4kg/m². The most common indication for surgery was abnormal uterine bleeding (47%). The mean operating time was 73 mins with 47% of patients having at least one additional procedure performed (most commonly excision of endometriosis, colpopexy, colposuspension and posterior repair). 91.4% of patients were discharged within 23hours. The most common post-operative complication was UTI, affecting 18%. Patient satisfaction scores were high.

Conclusions

LHi is a flexible technique with a low complication rate which is simple to learn and teach. As part of an ERP it can allow up to 90% of hysterectomies to be carried out laparoscopically with 91.4% being discharged within 23 hours, regardless of complexity.

<https://esge.covr.be/cmdocumentmanagement/conferencemanager/documents/api/getdocument/5108/cmabstsms/000148050/9c45f6c9a09df4da3a45e9f26fb6f3ad10ddc2445323f5e74dae0f7478cfba05>

ES28-0415 - P183

E-Poster

Is size the limit of minimal access surgery? A case series of laparoscopically assisted abdominal myomectomies (LAAM) - a single UK centre retrospective observational study

Alexander Lazaridis¹, Stewart Disu¹

¹Northwick Park Hospital, Gynaecology, London, United Kingdom

Background

Following recent advances in minimal access surgery over the last 30 years, laparoscopic myomectomy is considered the mainstay management option of symptomatic fibroids in the reproductive age.

Over the recent years, a modified advanced technique (LAAM) has become popular amongst patients for the management of very large or numerous symptomatic fibroids.

Methods

In our group, all patients received Misoprostol 400mcg PR and Tranexamic acid 1gram IV perioperatively. We utilized the modified Palmer's point entry to allow panoramic view of the bulky uterus and the modified Dillon's technique (20 IU of Pitressin in 200mls of NaCl 0.9%) to provide hemostasis and surgical plane formation for fibroid excision, which was facilitated with the Harmonic ACE[®]+7 Shears (Ethicon[®]).

We identified 10 women, that underwent treatment over the last 2 years (September 2016 to September 2018). The mean age was 34.8 years (range 24 to 46) and the mean BMI was 29 kg/m² (range 27 – 34 kg/m²). All patients had fertility aspirations.

Results

A total of 173 fibroids were removed, ranging from 4 to 40 fibroids per case. These fibroids were removed with a mini pfannenstiel laparotomy (4 - 6cm), with the aid of a small Alexis O wound retractor (Applied Medical) and cold knife bisection.

Average estimated blood loss was 1,2liters (range 500 to 2000mls). Out of ten patients, 6 patients required blood transfusion, with the majority receiving only one unit intra-operatively. Two patients developed ileus post-operatively, which resolved with conservative measures.

Average discharge was facilitated within 48 to 60 hours from the day of operation. No patient returned to theatres for re-intervention or was re-admitted.

During this time, one patient conceived spontaneously and was delivered by elective lower segment caesarean section at 39 weeks gestation.

Conclusions

The potential benefits of the LAAM approach are equivocal. On the one side, it avoids a midline laparotomy and confers the known benefits of laparoscopy (decreased infection rates, wound break-down, hospitalization and improved image quality and precise dissection).

A potential benefit of the LAAM is the avoidance of power morcellation for tissue extraction and the potential risks of dissemination of undiagnosed malignancy in the peritoneal cavity.

On the other side, the drawbacks include prolonged operative and anaesthetic times (mean average 180minutes) and potential increased blood loss.

As a consequence, the technique requires advanced laparoscopic skills and mastery in myomectomy, which therefore prevents this minimal access technique to be widely adopted for the management of significant fibroidal volume.

Nevertheless, since modern gynaecologists are practising in the era of patient choice, this technique should be included in the consultation of the patient with significant fibroidal volume and if appropriate a referral to a centre with expertise should be facilitated.

ES28-0418 - P184

E-Poster

Consecutive laparoscopic salpingectomies due to ectopic pregnancy after IVF in a patient with 46XX gonadal dysgenesis: a case report

Elitsa Valerieva¹, Nadya Magunska¹, Mariya Yunakova¹, Blagovest Bechev¹, Tanya Timeva¹, Mariyan Aleksandrov¹
¹Shterev Hospital, Gynecology, Sofia, Bulgaria

Background

46,XX gonadal dysgenesis (46,XX GD) is a primary ovarian defect leading to premature ovarian failure (POF) in otherwise normal 46,XX females due to development failure of the gonads and/or resistance to gonadotrophin stimulation. Patients usually present with primary hypergonadotropic amenorrhea, sexual infantilism without ambiguity and normal internal genitalia. The ovaries are replaced by a functionless, fibrous tissue, termed streak gonads. In such cases the only chance for conceiving is by in vitro fertilisation (IVF), using donor oocytes.

Methods

A 28-year-old woman referred to our clinic with presentation of primary infertility. Medical history showed primary amenorrhea and normal karyotype analysis. No history of pelvic inflammatory disease and/or previous operation was associated.

Results

Hormonal status measured LH 42.22 IU/l, FSH 76.14 IU/l, E2 35.70 pmol/l. Ultrasound examination revealed anteroposterior uterine diameter of 18.5 mm, endometrium thickness - 3 mm, hypoplastic ovaries and absent antral follicles. A diagnosis of 46,XX GD was assumed and a decision to continue treatment with donor oocyte IVF was made. Artificial stimulation of the endometrium with exogenous estrogen and progesterone was prescribed reaching endometrium thickness of 9 mm.

The patient underwent IVF with donor oocytes procedure. One fresh and two frozen embryo transfers under ultrasound control were performed, which resulted in 2 consecutive ectopic pregnancies, six months apart. Therefore, a laparoscopic salpingectomy was suggested as to proceed with further treatment procedures.

Conclusions

Patients with developmental anomalies, as gonadal dysgenesis, present a higher risk of an ectopic pregnancy, most probably due to alterations of the endometrial receptivity. Moreover, assisted reproductive techniques could be

discussed as an additional risk factor for the latter. Evidence from the presented case suggests that preventive bilateral salpingectomy could be hypothesized beneficial in such conditions, as to avoid ectopic pregnancies in otherwise complicated therapeutic cases.

<https://esge.covr.be/cmdocumentmanagement/conferencemanager/documents/api/getdocument/5217/cmabstsms/000165930/5d9a6de603c0561818f5fa9e99b7b6db5fb29df9125e821699acbadab40b5a61>

ES28-0419 - P185
E-Poster

Evaluation of TAP block application for post-operative analgesia in gynaecological robotic surgery

Alexander Lazaridis¹, Stewart Disu¹

¹Northwick Park Hospital, Gynaecology, London, United Kingdom

Background

Tranversus Abdominis Plane (TAP) blocks have recently become a very attractive alternative to the standard subcutaneous wound site local anaesthetic injections for immediate post-operative analgesia.

Methods

On this prospective observational pilot study we evaluated 10 cases over a period of 4 months, who had major operations (hysterectomy) with the DaVinci Xi robotic system.

After identifying the anatomical landmarks of the triangle of Petit, an injection of 40mls of 0.25% Bupivacaine with a blunted 16G needle was carried out.

The technique involved direct visualization of the needle's pathway until it reaches the level of the transversus abdominis muscle, 2 clicks are felt as the needle passes through the fascias of the external oblique and internal oblique muscles.

The DaVinci Xi offers a superior camera navigation ability and the surgeon can follow the needle pathway without any further adjustments. Moreover, since all ports are 8mm, camera can be accommodated in any of the original ports to aid quick visualization of the needle pathway with manual camera navigation by the assistant.

Results

The visual pain score results have revealed high satisfaction in the immediate post-operative time (6hours) and all patients only required simple analgesics for maintenance (Paracetamol 1gram QDS PO, Ibuprofen 400mg TDS PO). Thus avoiding heavy opioid analgesia and its negative post-operative consequences (nausea, vomiting, slow bowel movements, ileus, reduced post-operative mobilization and delay in urinary catheter removal).

Conclusions

We therefore advocate the use of TAP blocks in every minimal access gynaecological procedure, either laparoscopic or robotic, in agreement with the international literature.

ES28-0421 - P186
E-Poster

Fertility outcomes following surgery for rectovaginal endometriosis

Gillian Coyle¹, Charlotte Goumalatsou¹, Pat Haines¹, Andrew Kent¹

¹Royal Surrey County Hospital, Gynaecology, Guildford, United Kingdom

Background

Sub-fertility is known to be associated with endometriosis via multifactorial routes, with a prevalence of up to 50% in infertile women¹. These factors include reduced oocyte quality, structural issues with tubal and ovarian disease and

also biochemical factors. We aim to assess the fertility outcomes of patients undergoing surgery for Deep Infiltrating Endometriosis (DIE) and Rectovaginal (RV) disease.

This study stemmed from a large prospective study at the Royal Surrey County Hospital (RSCH) in Guildford, assessing quality of life data and patient outcomes following surgery for DIE which was published in 2016². This study evaluated patients undergoing combined surgery for RV endometriosis; this involved both pelvic clearance and fertility sparing surgery. It demonstrated significant improvement in QOL scores using the Endometriosis Health Profile (EHP 30). Pain scores in this cohort improved from 59.1 pre-operatively to 4.5 at 12 months post-operatively ($p < 0.01$). Further to this it demonstrated low complication rates, with 7.3% having a significant preoperative or post operative complication. 97.1% of cases were carried out laparoscopically. The fertility data obtained during this study warranted further evaluation.

Methods

Between May 2007 and May 2019, 147 patients underwent combined fertility-sparing surgery and all were given pre- and post-operative fertility questionnaires. These were completed at 2, 6 and 12 months and 5 years post operatively. Fertility outcome measures form part of this follow-up and to further evaluate fertility issues, women were sent a further postal questionnaire. Information obtained included time from surgery to conception, spontaneous versus assisted conception, number of pregnancies, miscarriage, ectopic pregnancy, gestation at delivery and mode of delivery. Patients undergoing assisted reproductive therapy were also asked for details regarding type of ART (IUI, IVF, ICSI), number of cycles, ovarian hyper stimulation syndrome, number of eggs harvested, use of donor gametes and complications from ART.

Data were collected onto an encrypted database and analysed using SPSS. Continuous data were normality tested and compared using paired and unpaired 2-tailed student's t test and categorical data using chi squared.

Results

As above

Conclusions

We will demonstrate the spontaneous pregnancy rates in women following combined surgery for RV endometriosis. Success rates of ART in this group will also be presented along with complication rates from spontaneous and assisted conception.

1. Meuleman, et al., 2009

2. Kent A, et al. 2016

<https://esge.covr.be/cmdocumentmanagement/conferencemanager/documents/api/getdocument/5112/cmabstsms/000148050/123da278a31f92453fe3df6e7f000c30e6889c1537f542801c39b7072942d46b>

ES28-0426 - P187

E-Poster

Postmenopausal bleeding – how effective is outpatient hysteroscopy at detecting and treating endometrial pathology?

Carina Johnstone-Ayliff¹, Wioletta Kapadia¹, Magdy Nawar¹

¹London North West University Healthcare NHS Trust, Obstetrics and Gynaecology, Greater London, United Kingdom

Background

Endometrial cancer predominantly affects postmenopausal women with more than 90% of cases presenting with vaginal bleeding. Investigation of postmenopausal bleeding (PMB) usually involves transvaginal ultrasound scan (TVUS) and hysteroscopy. Outpatient hysteroscopy services are rapidly expanding across the UK as it is a safe and cost-effective way of diagnosing and treating without the need for general anaesthetic (GA). Most units use a cut off of >4mm endometrial thickness (ET) on TVUS to proceed with hysteroscopy. Our objective was to assess the effectiveness of outpatient hysteroscopy in the investigation and treatment of PMB.

Methods

This retrospective study reviewed all outpatient hysteroscopies for PMB performed across two sites within the trust in the year from 1st August 2017 to 31st July 2018. Data were extracted from multiple electronic records systems (GCIS, ICE and EPRO).

Results

A total of 805 cases of PMB (mean age 59.5, s.d. 9.9 years) were referred for consideration of outpatient hysteroscopy. Referrals were made from gynaecology rapid access clinic, gynaecology outpatients or direct from primary care. 618 hysteroscopies were undertaken and, 566 (91.6%) diagnostic procedures were completed successfully. The most frequent reasons for abandoning the procedure were cervical stenosis and patient intolerance.

Of the successful diagnostic procedures, 14.7% of patients required booking for a further hysteroscopy under GA. Reasons included the need for further operative procedures such as polyp or fibroid resection, to obtain further biopsies and to gain better views of the endometrial cavity.

Most patients (95.4%) who underwent hysteroscopy had a TVUS prior to the procedure. 61 (10.8%) hysteroscopies were performed despite the ET being less than the 4mm threshold. Nevertheless, 12 of these 61 cases had endometrial polyps (19.7%). However, none of the sub-threshold cases had malignancy on histology.

Pathology requiring treatment was revealed in 217 (38.3%) of the 566 diagnostic hysteroscopies. 183 (32% of 566) cases showed endometrial polyps, with 108 (59.0%) of these resected or biopsied at the time. Histology showed 88.0% of these polyps were benign polyps, 3.7% hyperplasia (simple/complex/atypical) and 0.9% endometrial cancer (7.4% of cases missing data).

The other pathologies identified at hysteroscopy were submucosal fibroids requiring resection, endometrial hyperplasia and cancer. 22 cancers (3.9% of the 566 hysteroscopies), four cases of atypical complex hyperplasia, two cases of complex hyperplasia and two cases of simple hyperplasia were diagnosed at histology. In each of these cases the hysteroscopy had recorded abnormalities, either as suspicious, thickened, vascular or endometrial polyps.

Conclusions

In patients presenting with PMB, outpatient hysteroscopy in our trust is effective at both detecting and treating endometrial pathology. In more than one third of these patients there is pathology requiring treatment. Since patients with PMB often have co-morbidities, performing hysteroscopy without GA can be faster and safer, resulting in earlier diagnosis and treatment.

<https://esge.covr.be/cmdocumentmanagement/conferencemanager/documents/api/getdocument/5257/cmabstsms/0000145740/79a36d8f7fa09cd4589bc07cdd458caffb518664a7292eb506ce12958654d7d1>

ES28-0431 - P188

E-Poster

Laparoscopic versus laparoscopy assisted myomectomy for large fibroids

Islam Magalov¹, Nargiz Amiraslanova²

¹Azerbaijan Medical University, 1st Department of Obstetrics and Gynecology, Baku, Azerbaijan

²Azerbaijan Medical University, 2nd Department of Obstetrics and Gynecology, Baku, Azerbaijan

Background

Although there is no identification of really large fibroid for minimal invasive intervention, it is a serious challenge in preoperative decision making. We compared laparoscopic and laparoscopy assisted myomectomy for fibroids > 8 cm of diameter.

Methods

33 patients were included. I group – 22 patients who underwent laparoscopic myomectomy and II group – 10 patients whom myomectomy was performed with laparoscopic assistance. The medium size of the largest fibroid was 10,7cm (min -8 cm, max-20cm) in the Ist group and 10 cm (min 8 cm, max – 13 cm) in the IInd group. 12 patients in the Ist group and 4 patients in the IInd had only one fibroid. The others had 2 and more fibroids. Operative time, amount of blood loss and postoperative recovery were estimated.

Results

Laparoscopy assisted myomectomy lasted shorter than laparoscopic myomectomy – 110,3min vs 175,3 min. There was no significant difference in Hb level and postoperative recovery.

Conclusions

Laparoscopy assisted myomectomy occurred to be more preferable concerning the duration of surgery.

<https://esge.covr.be/cmdocumentmanagement/conferencemanager/documents/api/getdocument/5131/cmabstsms/000053050/a70bb160d980aa5b0c143ccb28faa4aa36ceb945eb9d972a4e73a3077a69fafa>

ES28-0432 - P189

E-Poster

Inexpensive innovation: the use of a plastic sims' speculum for colpotomy in MAS hysterectomy and instrument option appraisal - video demonstration

Nahid Gul¹, Siân Bullough²

¹Wirral University Teaching Hospital, MIS- Gynaecology, Gayton, United Kingdom

²Wirral University Teaching Hospital, Gynaecology, Wirral, United Kingdom

Background

Robotic Assisted Surgery (RAS), laparoscopic surgery, hysterectomy, colpotomy, sims' plastic speculum objective: To demonstrate innovative inexpensive surgical technique with better result and reproducibility. Design: In 2012 the UK hysterectomy rate was stated to be 42/100000. Our approach to performing such surgery has evolved over the years due to advancing technology. Less than 3% of hysterectomies performed at our unit, Wirral University teaching hospital, in the last 12 months were open. Over the last 12 months 18% were vaginal, 57% were laparoscopic and 20% were RAS. There are several crucial steps to ensuring a safe laparoscopic hysterectomy including maintaining good exposure at all times, identification of vasculature and ureters, bladder dissection and colpotomy..

Methods

Video demonstrated of surgical colpotomy technique with sims' speculum in laparoscopic and robotic assisted hysterectomy.

Outlined below are the steps we undertake to achieve colpotomy:

- Retroperitoneal dissection and ureters are identified
- Bladder is mobilised and reflected
- Uterosacral ligaments are identified and dissected
- Uterine arteries are skeletonised and diathermy with bipolar device
- Bladder pillars are divided to identify the anterior vaginal wall
- The lower blade of plastic sims' speculum is inserted into the vagina and the tip of blade angled into the anterior fornix to delineate the anterior vaginal wall from the cervix. Anterior colpotomy is performed with monopolar diathermy spatula/hook (cutting voltage 20)
- In the same orientation the blade is then moved posteriorly into the posterior fornix to identify the posterior vaginal wall from the cervix and colpotomy is completed.

- Once the colpotomy is completed the assistant removes the specimen, by grasping it with their fingers. A vulsellum can be used if required. The glove filled with sterile water is then placed in the vagina to ensure the pneumoperitoneum is maintained

Results

Successful completion of colpotomy in consecutive cases. The technique provides added advantage for dissection in difficult cases and large uterus.

Colpotomy was identified by Van Den Haak et al. as being significantly more complex laparoscopically than in open surgery. There is a huge array of devices available to aid laparoscopic colpotomy of varying efficacy and cost. We

believe we report the first innovative inexpensive technique "use of a plastic sims' speculum as the vaginal instrument to aid colpotomy" in a laparoscopic and robotic assisted total hysterectomy. Video demonstration.

Conclusions

We believe we report the first innovative inexpensive technique "use of a plastic sims' speculum as the vaginal instrument to aid colpotomy" in a laparoscopic and robotic assisted total hysterectomy. Video demonstration.

<https://esge.covr.be/cmdocumentmanagement/conferencemanager/documents/api/getdocument/5125/cmabstsms/000019900/0952526f7dc0816be3fe92286a76afa6cc48fb747c21d82e8d1a7ef889def0a7>

ES28-0435 - P190

E-Poster

Complications related to placement of suburethral retropubic tape: own experience

Islam Magalov¹, Arzu Poluxova¹, Rahshanda Aliyeva¹, Nargiz Naghiyeva¹

¹Azerbaijan Medical University, 1st Department of Obstetrics and Gynecology, Baku, Azerbaijan

Background

We have reviewed the data of patients operated for stress urinary incontinence (SUI) at our department within 2013-2018 in order to analyze the early and late negative consequences of surgery.

Methods

145 patients entered the study. All of them underwent an intervention including placement of suburethral retropubic tape (TVT – tension-free vaginal tape) and were divided in 4 groups : TVT as mono surgery – 48 patients, TVT and total laparoscopic hysterectomy (TLH) – 37 patients, TVT and total vaginal hysterectomy (TVH), TVT and laparoscopic sacropexy (LS). Pre- and postoperational examination consisted of physical evaluation, sonography, simple office urodynamic and cystoscopy (as appropriate).

Results

We defined as major complication the cases when it was necessary to remove the tape. Negative consequences which required tape removal were as follows: de novo urgency – 2 patients (TVT only group)(1,4%; 4,2%, respectively), exposition of tape to vagina -2 patients (all TVT+TLH group)(1,4%; 5,4%, respectively) and erosion of tape into the bladder – 1 patient (TVT+TLH group) (0, 7%; 2,7%, respectively). The tapes were removed after 3 -4 weeks in case of de novo urgency, after 3-6 months in case of its exposition to the vagina, and after 2,5 year in case of erosion to the bladder. In cases of de novo urgency and tape exposition vaginal part of the tape was removed vaginally and in case of erosion the whole tape was removed laparoscopically.

Conclusions

Despite being considered the gold standard in modern SUI treatment, these techniques are not free of complications. Somewhat its exposition and erosion in our experience was associated with the combination of TVT with TLH. This fact requires further detailed assessment to avoid such unwanted outcomes in future.

ES28-0437 - P191

E-Poster

Laparoscopic sacropexy with polypropylene meshes - our learning curve

Islam Magalov¹, Raxshanda Aliyeva¹, Arzu Poluxova¹, Nargiz Naghiyeva¹

¹Azerbaijan Medical University, 1st Department of Obstetrics and Gynecology, Baku, Azerbaijan

Background

Laparoscopic sacrocolopexy is considered the gold standard for the pelvic organ prolapses repair. However, necessity to dissect the area of promontory full of vascular and nervous pathways can lead to major complications and life-threatening hemorrhage. Besides, the possibility of long-term so-called minor complications like de novo bowel, urinary and sexual disfunctions because of nerves damage may lead to hesitations of surgeons at the time of prolapse

repair choose. The aim of our study is to show our way of “fast and safe” learning curve for laparoscopic sacrocolpopexy from first operations with use of takers, one mesh and long operating time (approximately 200 minutes) to standardized 90-minutes two mesh repair.

Methods

Our team has performed 104 laparoscopic sacropexies between 2012- 2018 for grade 3 and 4 apical and anterior compartment prolapses (POP-Q classification). From them -for 37 women was performed hysteropexy, for 52 - cervicosacropexy and for 15- culdopexy (10 for recurrent prolapses). Firstly, operation technique includes promontory dissection, opening the parietal peritoneum medially to the right ureter, the rectovaginal plane dissection, placement of one mesh posteriorly on the cervix and upper 1/3 part of vagina with irregular “intuitive” number of absorbable and non-absorbable sutures and fixation of mesh to promontory with takers

Results

Our first operations had long operation time (approximately 200 minutes) and relatively poor anatomical outcomes. Later, we start to use two meshes with fixation of the posterior mesh at the upper 2/3 of vagina without sutures on levator ani muscle and fixation of mesh in the upper 2/3 anterior compartment, standardize place and number of sutures at the anterior and posterior vaginal walls, cutting the anterior mesh, fixation of the posterior long mesh on promontory and stop to use takers at promontory, replacing them with non-absorbable 1 or 2 sutures. Consequently, after possible standardization of sacropexy, operation time have decreased to 90 minutes with better anatomical outcomes. No major complications occurred.

Conclusions

Laparoscopic sacropexy is an operation with protracted learning curve. Standardization of technique may reduce the operation time and lead to better anatomical and functional outcomes.

ES28-0439 - P192

E-Poster

Why are women not heard: literature review of delay in diagnosis in endometriosis across Europe

Luveon Tang¹, Asma Latifa Melhani¹

¹École des Hautes Études en Santé Publique, n/a, Paris, France

Background

The incidence of endometriosis is estimated to be from 2-10% within female population. A previous comparison study of endometriosis incidence and delay in diagnosis conducted in United Kingdom and United States in 1996 suggested a difference of almost 4 years between the UK and US, with the latter being worse in delays due to lack of access to universal healthcare. More recent studies of delays of diagnosis worldwide revealed that the length of time for individuals with endometriosis across Europe has not significantly improved. This literature review aims to bring together available data regarding duration for delay in diagnosis across several European countries with published data. We also looked at typical patient pathway in literature to identify potential reasons for delays.

Methods

Key search terms "endometriosis", "delay", "diagnosis", "patient pathway" were used in several search engines including "UK PubMed Central", "Science Direct" and "Ebsco". First 50 articles generated from each engine were listed and their abstract were reviewed. Only 35 related articles in total were found to be relevant and therefore used in this literature review. The median for delay in diagnosis of endometriosis of patient population from available European countries were used. The mean for delay in diagnosis were not used unless the median were not available, in which case the mean and median were not compared directly.

Results

Journal articles reporting delay in diagnosis in endometriosis was found for 5 European countries including United Kingdom, Norway, Austria, Germany, The Netherlands and 2 non-European countries (United States and Brazil). The range of length of period of diagnostic delay ranged from 5 to 10.4 years in Europe but was as high as 11.73 years in United States. The patient pathway from individuals' developing symptoms to seeking medical attention, physicians initiating investigations and formulating differential diagnosis, secondary referral to gynaecologists and individuals receiving treatment is comparable across the countries. However, there appears to be different cultural and socio-economic factors leading to delay in diagnosis of endometriosis across countries including access to universal healthcare and individuals' racial profile.

Conclusions

Diagnostic delay in endometriosis is unacceptably high compared to other chronic diseases (e.g. 9 months delay in diagnosis in rheumatoid arthritis). The range of length of period of diagnostic delay vary greatly across countries. It is important to understand the reasons of delay in relation to a typical patient's pathway of diagnosis and treatment and reflect on ways that the healthcare system can improve the service to individuals.

<https://esge.covr.be/cmdocumentmanagement/conferencemanager/documents/api/getdocument/5256/cmabstsms/000153130/48040a673f03f2725f4ec2f76496e0e6e649bff1eb38d00dcff8e14f2b829102>

ES28-0690 - P193

E-Poster

Myosure excision of placental site trophoblastic tumour: a case report

Annabel Grossmith¹, Wee Teck Lim¹

¹Lancashire Teaching Hospitals NHS Foundation Trust, Obstetrics & Gynaecology, Preston, United Kingdom

Background

Placental Site Trophoblastic Tumour (PSTT) is a rare variant of Gestational trophoblastic disease (GTD) which often presents late following the index pregnancy. Suction evacuation is the gold standard management of GTD, but PSTT is often diagnosed following alternative procedures given the unusual presentations. Myosure is a hysteroscopic tool used widely for the treatment of polyps and fibroids. There is minimal evidence to date on its use in resection of GTD under direct vision.

Methods

We present a case of a young patient presenting with intermittent vaginal bleeding 14 months after her last confirmed pregnancy - a term vaginal delivery. Ultrasound scan revealed a highly vascular hyperechoic structure within the myometrium. Myosure resection of the lesion under direct vision was undertaken, restoring the endometrial cavity to a normal appearance.

Results

PSTT was confirmed on histology and the patient was referred to the regional GTD centre where she underwent hysterectomy with conservation of the ovaries. No chemotherapy was required and she remains well with no signs of recurrence on urine hCG monitoring and follow-up imaging.

Conclusions

Myosure resection of retained products of conception under direct vision can be considered following unusual, particularly delayed presentations following the index pregnancy, or unusual ultrasound scan appearance. In this case, the outcome was optimal without the gold standard suction evacuation technique. Further research is needed in this area of hysteroscopic resection to determine whether Myosure resection is superior to suction evacuation.

<https://esge.covr.be/cmdocumentmanagement/conferencemanager/documents/api/getdocument/5254/cmabstsms/000166260/9eef3b3dc211e031ef7d64d5f6cc78612ab03ea95603f991b9210670d7bf9af8>

ES28-0443 - P194
E-Poster

Minimal access robotics in gynaecology: safe surgical procedure of pelvic clearance (total hysterectomy & BSO in Morbidly obese patient, BMI 79 with robotic assistance)

Nahid Gul¹, David Rowlands Cheshire²

¹Wirral university Teaching Hospital, MIS- Gynaecology, Gayton, United Kingdom

²Wirral university Teaching Hospital, Gynaecology, Wirral, United Kingdom

Background

Objective; to demonstrate with appropriate use of technology and team working, safe gynaecological surgery can be offered to patients in specialist settings

Design: surgical presentation from preparation, anaesthetic, positioning and surgical robotic procedure.

Methods

Method: 58 Year old referred from tertiary centre for robotic assisted hysterectomy with high suspicious endometrial pathology and persistent significant postmenopausal bleeding. After careful assessment. Anaesthetic review, informed consent, patient was listed for robotic assisted procedure. Multidisciplinary approach with team working, post operative HDU support, robotic assisted surgery was undertaken.

Results

Results; demonstration will high light the key points required for preparation, positioning, anaesthetic and robotic assisted surgical dissection. Pelvic clearance with hysterectomy, bilateral salpingo-oophorectomy, retroperitoneal dissection, ureterolysis, mobilisation of rectum due to previous endometriosis was undertaken . The procedure was uncomplicated. Patient was electively transferred to HDU for overnight observation and discharged home

Conclusions

Conclusion; minimal invasive surgery with robotic assistance allows surgeons to undertake procedures to benefit patients who might otherwise be denied of treatment due to significant risk of morbidity and mortality with other treatment modality .

<https://esge.covr.be/cmdocumentmanagement/conferencemanager/documents/api/getdocument/5126/cmabstsms/000019900/5ff7f1d2b35a6c7f44b715df3dc79788aa10a64163fae945dbe2077acaec5156>

ES28-0523 - P195
E-Poster

Utility of hysteroscopic findings for diagnosis of early endometrial cancer: reports of two cases

Nobuko Takashi^{1,2}, Jun Kumakiri¹, Toshiyuki Kanno¹, Yoshika Akizawa¹, Yuichi Sato², Tsutomu Tabata¹

¹Tokyo Womens Medical University, Obstetrics and Gynecology, Shinjuku, Japan

²Obstetrics & Gynecology Tatedebari Sato Hospital, Obstetrics and Gynecology, Takasaki, Japan

Background

Diagnosis of early endometrial cancer (EEC) is sometimes difficult via cytologic and histopathologic examination and images including an MRI.

Here, we report two cases with EEC which were difficult to diagnose by conventional examinations and were successfully diagnosed by hysteroscopic findings.

Methods

Two cases were retrospectively reviewed in the report.

Results

[Case 1] Fifty-five year old woman with a history of breast cancer was taken hormonal therapies for adjuvant. During follow-up, a 2-cm irregular mass was found in her uterine cavity by ultrasound. Although the endometrial cytologic

and histologic examination were negative, hysteroscopy revealed abnormal gray-white multiple polypoid lesions which were suspected EEC. Result of the endometrial biopsy conducted at the hysteroscopy revealed suspicious of atypical endometrial hyperplasia (AEH). The hysterectomy and bilateral salpingo-oophorectomy were performed, and postoperative pathological diagnosis was found endometrioid adenocarcinoma with grade 1 (stage 1A). [Case 2] 65-years-old postmenopausal woman complained several abnormal uterine bleeding during a year. Transvaginal ultrasonography found a 9-mm thickened endometrium and multiple uterine fibroids. AEH was suspected by the cytology and histologic examination.[Hysteroscopic finding] The hysteroscopy revealed multiple submucosal fibroids, and multiple papillary white small masses with superficial micro vessels. Because the masses were suspected the AEH or EEC, hysterectomy and bilateral salpingo-oophorectomy was performed. The pathological finding revealed an endometrioid adenocarcinoma with grade 1 with vascular invasion (stage 1 B), then postoperative adjuvant chemotherapy was performed.

Conclusions

Our cases show that the hysteroscopy is possibly useful for diagnosis of EEC in cases which are difficultly diagnosed by conventional examination including cytologic and histologic examinations.

<https://esge.covr.be/cmdocumentmanagement/conferencemanager/documents/api/getdocument/5085/cmabstms/000166270/02a6f9086373a1fbb27008093de81b69076e7a8f3e5cf19b9825eeb9fb9ad8ae>

ES28-0447 - P196

E-Poster

Coexistence of endometriosis and ovarian teratomas: a retrospective analysis of clinicopathological characteristics

Dimitrios Rafail Kalaitzopoulos¹, Eleftherios Pierre Samartzis², Markus Eberhard¹, Nicolas Samartzis¹

¹Hospital, Gynaecology, Schaffhausen, Switzerland

²University Hospital, Gynaecology, Zurich, Switzerland

Background

Endometriosis as well as teratomas are two diseases, which are typically found in women at reproductive age. Both pathologies share one special property: they are usually consisting of highly differentiated tissue in ectopic localisation. Teratomas are described as a result of an abnormal development of pluripotent stem cells. One similar hypothesis has been proposed for the pathogenesis of endometriosis. Noticeable is furthermore their affinity to the pelvic organs, respectively the ovaries. Only few studies have described the coexistence of endometriosis and teratomas. Therefore just little is known about further similarities.

Methods

The aim of this study is to describe the clinical and pathological characteristics of women, having surgical diagnosis of endometriosis and coexistence of histological confirmed teratomas. We therefore performed a retrospective research in our clinical database of the last 8 years to find all cases of women with endometriosis, which beside of it had a histopathological confirmed teratoma of the ovary. We totally found 22 cases and collected clinical data and intraoperative details.

Results

Women with endometriosis and teratoma of the ovary were all premenopausal by diagnosis with mean age of 31.2 (+/- 8.8) years. 40.9% (9/22) of cases are at rAFS score I, 31.8% (7/22) rAFS II, and 13.6% (3/22) rAFS III and 13.6% (3/22) rAFS IV. All of the patients had a benign histology of teratoma. One woman had a struma ovarii (monodermal teratoma). Two patients had simultaneously an endometrioma and teratoma in the same ovary. No gynaecological malignancy have been described. Most teratomas have been localized on the right ovary (54.4%, 12/22). 18.2% (4/22) of the teratomas were bilateral and 27.3% (6/22) only on the left side.

Conclusions

Our results indicate that women with coexistence of endometriosis and teratoma are mostly at rAFS score I or II and teratomas were found in the majority on the right ovary. Future studies could help identifying further similarities in this coexistence and maybe lead to new findings in the pathophysiology of endometriosis.

<https://esge.covr.be/cmdocumentmanagement/conferencemanager/documents/api/getdocument/5053/cmabstms/000166230/bc9095329d97d3c57d4c614a31fc982c1359579243a4dd74f7ff151ffc70a0dc>

ES28-0492 - P197
E-Poster

Efficacy of vasopressin during total laparoscopic hysterectomy for deep endometriosis

Hiroyuki Kobori¹, Noji Chisato¹, Noriko Yamamoto¹

¹Medical Topia Soka Hospital, Gynecology, Saitama, Japan

Background

Total laparoscopic hysterectomy for benign gynecological disease is associated with significant morbidity including blood loss. Pelvic endometriosis is often mentioned as one of the variables influencing surgical outcomes of total laparoscopic hysterectomy. The purpose of this study is to study the effects of reducing hemorrhage by injection of vasopressin combined with uterine artery ligation on total laparoscopic hysterectomy.

Methods

We performed a retrospective analysis of 27 patients who underwent total laparoscopic hysterectomy with deep endometriosis between March 2018 and April 2019. All patients were performed uterine artery ligation. 18 were treated without the use of any vasoconstrictive agent (group 1) and 9 were treated with intraoperative intra-myometrial injection of dilute vasopressin (20 IU/100 mL normal saline) (group 2). The main outcome measure was intra-operative estimated blood loss, procedure length and rates of complications.

Results

Overall, the mean EBL was 154.4 ± 195.7 mL in group 1 compared with 51.7 ± 25.6 mL in group 2, respectively ($p < .005$). Procedure length did not differ significantly between the 2 groups (104.4 ± 22.1 vs 107.0 ± 16.5 minutes). Vasopressin was not associated with serious cardiovascular adverse events.

Conclusions

Intraoperative intra-myometrial injection of vasopressin is effective of reducing hemorrhage in total laparoscopic hysterectomy with deep endometriosis.

ES28-0453 - P198
E-Poster

Nipple skin sparing mastectomy by conventional laparoscopic single port: about four cases

Julien Bakenga¹, Genestie Catherine²

¹Clinique du Fief de Grimoire, Gynecologic Oncology, Poitiers, France

²Institut Gustav Roussy, Pathology, Villejuif, France

Background

To assess the feasibility of laparoscopic single port technique in breast reconstructive surgery in BRCA1 mutation patients

Methods

Cases report of two patients with proven BRCA1 mutation. They underwent for nipple skin sparing mastectomy using laparoscopic single port intervention: all descriptive data, step by step technique is described - exposure-the positioning of the incision and trocars-difficulties are analyzed and criticized breast of 90B size have been operated

Results

Those two cases are fully analysed.

The most challenging points are fully discussed.

Patient is positioned in dorsal position, the arms are at 90°, the incision is made in the anterior axillary line.

The first steps done classically with cold scissors until all the outer quadrant of breast is free.

The Alexis is positioned and the Mini-Gelpoint system, insufflation at 8 mm Hg, dissection is done like in classical laparoscopy with cold non curved laparoscopic instruments.

The removal of the gland is easy.

At the end, an implant is put in the mastectomy cavity.
Operative time is mostly similar to conventional nipple skin sparing mastectomy

Conclusions

This innovative technique is feasible without compromising operative time, the quality of gland dissection and aesthetic result.

The use of laparoscopy in the breast surgery and the adjunction of single port is safe .

<https://esge.covr.be/cmdocumentmanagement/conferencemanager/documents/api/getdocument/5104/cmabstms/000166290/e7493304a23dc07922dc4f28a95610ca69d1be206d69fd0370b0a1751873bc6a>

ES28-0460 - P199

E-Poster

Spontaneous vaginal evisceration of the hail through fistulized elythrocele: a case report

Chris Minella¹, Blandine Simeu¹, Serge Rohr¹, Cherif Akladios¹, Lecointre Lise¹

¹University Hospital, Unit of Gynecology surgery, Strasbourg, France

Background

Most literature case studies of perineal evisceration are described mainly in postmenopausal women in the context of abdominal trauma or post-operative suture release. Spontaneous perineal evisceration in a context of genital prolapse is a rare but potentially serious condition and continues to remain challenging. Few cases of spontaneous perineal evisceration due to genital prolapse have only been reported in the literature.

Methods

We will describe here the case of a 90-year-old patient with a spontaneous vaginal evisceration of the small intestine in a known case of uterine prolapse. We performed an exploratory laparotomy, which identified an incarceration of the entire hail externalized through a vaginal perforation due to an old fistulized elythrocele. Extrication of the hail and a digestive resection was performed because of an intestinal ischemia. The follow-up was simple

Results

Cases of perineal evisceration have been described in the literature mainly in postmenopausal women in the context of abdominal trauma or post-operative suture release after hysterectomy or after sexual intercourse . For non-menopausal women, the reasons revoked in the literature are multiparity, deliveries with instrumental extraction or the consequences of violent sexual intercourse.

Vulvovaginal atrophy and menopausal status are the two main factors for perineal evisceration highlighted in literature. Indeed, the risk of evisceration with vaginal rupture is increased in postmenopausal patients due to thin, friable and less vascularized vaginal tissue. In presence of a prolapse, the risk of ulceration is added due to the loss of vaginal trophicity and especially since the vagina is in contact with an irritating foreign body, such as a pessary. This risk is all the more important when the pessary is neglected and the patient does not have regular gynaecological follow-up. In addition, perineal evisceration remains a rare but potentially serious complication if it is treated too late or if its treatment is neglected. It's a surgical emergency often performed by laparotomy requiring intestinal extrication and closure of the vaginal breach. A vaginal approach to limit complications associated with laparotomy was discussed by Matthews *et al* in 2014, but not there doesn't exist any clear recommendations.

Conclusions

By presenting this case, it seems important to us not to neglect the management of prolapse, especially in patients with marked vaginal atrophy. Therapeutic education concerning the use of the pessary combined with regular gynaecological follow-up seems relevant for these patients. In full knowledge of the facts, the place of the pessary in the event of disabling prolapse in a postmenopausal woman versus surgical treatment should be discussed on a case-by-case basis in order to limit the risk of vaginal rupture on ulcerated prolapse. This is all the more important when compliance seems difficult.

<https://esge.covr.be/cmdocumentmanagement/conferencemanager/documents/api/getdocument/5037/cmabstms/000151990/e103bbe0b013f5c47dbe310561431d830f2361d7974315a2784c4df39806caba>

The HYSTER study: the effect of intracervically administered terlipressin versus placebo on the number of gaseous emboli and fluid intravasation during hysteroscopic surgery

Paul Kesteren¹, Lucilla Overdijk², Bram Thie¹, Luuk Karskens², Bart Rademaker²

¹OLVG hospital Amsterdam, Gynaecology, Amsterdam, The Netherlands

²OLVG hospital, Anaesthesiology, Amsterdam, The Netherlands

Background

Terlipressin induced vasoconstriction is supposed to decrease intravasation and the appearance of venous gaseous emboli during hysteroscopic surgery. We therefore started a placebo controlled randomized controlled trial to investigate the effect of intracervically administered terlipressin on these parameters. The study protocol is published in: *Trials*. 2018 Feb 14;19(1):107. PMID: 29444699

Trial registration: Nederlands Trial Register (Dutch Trial Register), ID: NTR5577.

Methods

Forty-three patients (ASA 1 or 2) scheduled for transcervical resection of large, types 1-2 myoma or extensive endometrium resection were included. In a double-blind fashion patients were randomized 1:1 according to surgical treatment using either intracervically administered terlipressin or placebo. Transesophageal echocardiography was used to observe and record embolic events. Our primary end point was how terlipressin influences the severity of embolic events. Secondary endpoints included the effect of terlipressin on the amount of intravasation and on hemodynamic parameters.

Results

Preliminary results were as follows:

Variables	(N=43)	With terlipressin (21)	Without terlipressin (22)
Age(years)	44.7 ± 6,3	46,4 ± 5,2	43,1 ± 6,9
Length(m)	1,7 ± 0,1	1,7 ± 0,1	1,7 ± 0,1
Weight(kg)	74,8 ± 13,3	72,4 ± 12,1	77,2 ± 14,2
BMI	25,7 ± 4,0	25,32 ± 3,8	26,02 ± 4,3
Operation length (minutes)	39,6 ± 15,5	44,1 ± 17,7	35,1 ± 11,7
Intravasation in Liter	Count (N=43)	21	22
0,5	11	6	5
1,0	3	2	1
1,5	10	3	7
2,0	12	6	6
2,5	7	4	3

Abbreviations: BMI = body-mass index

Conclusions

Conclusions will be presented during the congress.

ES28-0474 - P201

E-Poster

Laparoscopic detorsion in a patient with delayed diagnosis of tuboovarian torsion rotated eight times with successful outcome

Suleyman Guven¹, Emine Seda Guvendag Guven¹

¹Faculty of Medicine- Karadeniz Technical University, Obstetrics and Gynecology, Trabzon, Turkey

Background

Ovarian torsion refers to the complete or partial rotation of the ovary on its ligamentous supports, often resulting in impedance of its blood supply. It is one of the most common gynecologic surgical emergencies. Even it is an acute condition, the diagnosis of this condition may rarely be delayed. In this case report, a case of delayed diagnosis of tuboovarian torsion rotated eight times was reported.

Methods

A 17 year old girl admitted to outpatient clinic with the complain of difficulty to walking for two mounts. She also occasionally complained cyclic pelvic pain. She admitted to different clinics for such complains and she was prescribed to use non-steroidal analgesics. Initial pelvic ultrasonographic evaluation revealed a single simple ovarian cyst 5 cm in diameter without clear assessment of ovarian blood flow. Following two months of such symptoms history, she was re-evaluated by gynecologist in an outpatient clinic. A single simple ovarian cyst 7 cm in diameter with thick wall, heterogenous appearance of the ovarian stroma, multiple small peripheral follicles, enlarged ovary with absent of Doppler flow within the ovary were noted during pelvic ultrasonograph. A serum human chorionic gonadotropin, hematocrit, white blood cell count and electrolyte panel was drawn. All tests were unremarkable. Emergency laparoscopy was done. Laparoscopic evaluation was revealed almost 200 cc blood in Douglas pouch, and necrotic appearance of twisted tube and ovary. Enlarged ovary and tube was rotated eight times (Figure 1). Laparoscopic ovarian detorsion, ovarian cystectomy and fixation ovary to fossa ovarica was carried out.

Results

During the operation clear bleeding from the stroma of ovary was noted. After two mounts of surgery the patient was in good health status with decreased number of antral follicles and normal blood flow in right ovary.

Conclusions

Laparoscopic tubo-ovarian detorsion and ovarian conservation, even in the case of a darkened, congested ovary is safe and good option also in case of delayed diagnosis.

<https://esge.covr.be/cmdocumentmanagement/conferencemanager/documents/api/getdocument/4983/cmabstsms/000166530/03003f3f6e43b042b89817ff8a0d5f161ead2ff9976dfb69a74026156227369e>

ES28-0475 - P202

E-Poster

Lower 1/3 vaginal agenesis with small vaginal fistula - a case report

Emine Seda Guvendag Guven¹, Suleyman Guven¹

¹Faculty of Medicine- Karadeniz Technical University, Obstetrics and Gynecology, Trabzon, Turkey

Background

Absence of the lower vagina occurs as a result of abnormal development of the sinovaginal bulbs and vaginal plate. This is a very rare condition. Most commonly, the ovaries, uterus, cervix, and upper vagina are normal, while the lower vagina is replaced by fibrous tissue. Case with lower vaginal agenesis and small vaginal fistula is very rare condition. In this case report, a case of lower 1/3 vaginal agenesis with small vaginal fistula in a regular menstruating woman was reported

Methods

A 29 years old woman admitted to outpatient clinic with the complain of dyspareunia and difficulty in vaginal intercourse. She had been married for three mounts. Her medical history was unremarkable and she had regular

menstruation since 13 years old. Vaginal examination revealed a small vaginal fistula (Figure 1) without normal vaginal appearance. Initial pelvic and perineal ultrasonographic evaluation revealed normal uterus, ovaries, cervix and upper vagina. MRI also confirmed the sonographic findings. A serum human chorionic gonadotropin, FSH, LH, E2 panel was drawn. All tests were unremarkable. Surgical correction was planned. The outer opening of vaginal fistula was catheterized with small urinary foley. Transvers incision and blunt vaginal dissection were made, the 2/3 upper vaginal segment was visualized, the distal portion of upper vaginal was sutured to introitus (Figure 2).

Results

Following completion of the operation, almost 7 cm vaginal segment was created. After one and half months of surgery the patient was in good health status without experiencing any pain during vaginal intercourse

Conclusions

Surgical vaginal correction of lower 1/3 vaginal agenesis with small vaginal fistula with the aid of urinary foley catheter is a safe and good surgical option.

<https://esge.covr.be/cmdocumentmanagement/conferencemanager/documents/api/getdocument/4986/cmabstsms/000166540/a4fb6eb3adaee922fbd7095ac812a3d8fc9144eac1a0ebcae23f2ea08f1e7f17>

ES28-0477 - P203

E-Poster

Deep infiltrating endometriosis: pain assessment after laparoscopic management postoperative pain in deep infiltrating endometriosis

Hale Göksever Çelik¹, Ercan Bastu², Ozguc Takmaz², Cenk Yasa³, Husnu Gorgen², Aruk Buyru²

¹Saglik Bilimleri University Istanbul Kanuni Sultan Suleyman Training and Research Hospital, Department of Obstetrics and Gynecology, İstanbul, Turkey

²Acibadem Mehmet Ali Aydinlar University, Department of Obstetrics and Gynecology, Istanbul, Turkey

³Istanbul University- Istanbul Medical Faculty, Department of Obstetrics and Gynecology, Istanbul, Turkey

Background

Deep infiltrating endometriosis (DIE), known as adenomyosis externa in the early nineties, describes the localization of endometrial glands and stroma outside the uterine cavity in fibromuscular tissue. Latter defining endometriotic lesions infiltrating more than 5 mm below the peritoneum called DIE. Surgical management of DIE has become a topic of increasing interest in gynecologic surgery. The aim of surgery is to excise all DIE lesions, especially nodules. Bowel nodules in particular can be treated with two surgical approaches: a radical approach, mainly based on colorectal segmental resection, and a conservative approach, by shaving and without opening the rectum or by extracting the nodule and the surrounding rectal wall using disc excision or full thickness.

Our aim was to investigate if there was an improvement in endometriosis-associated pelvic pain of women who had undergone laparoscopic treatment of DIE with extensive excision of nodules. Furthermore, we compared preoperative and postoperative pain scores of bowel nodule shaving and resection approaches when there was bowel involvement.

Methods

This is a retrospective evaluation of 65 patients who had a combined diagnosis of endometrioma and DIE. As the study was purely retrospective and non-interventional, it was not necessary to declare it to any Ethics Committee. Informed consent was obtained from all of the patients, allowing the use of their blinded clinical data for research purposes. The postoperative data were collected in a specific database and analyzed for postoperative pain outcomes by comparing preoperative symptoms using visual analogue scale (VAS) scores and the British Society of Gynecologic Endoscopy (BSGE) pelvic pain questionnaire.

Results

Sixty-five patients who met the criteria were included. The mean age of all patients was 35.0±6.3 (range, 22-50) years. The mean operative time was 121.3±50.2 (range, 60-270) minutes. Pre-op and post-op comparison of VAS scores for dysmenorrhea (8.57 vs. 2.91), dyspareunia (6.62 vs. 1.66), dyschezia (7.46 vs. 2.43), dysuria (5.67 vs. 1.34), chronic pelvic pain (4.11 vs. 1.22), and BSGE score (40.98 vs. 11.00) showed significantly reduced pain scores, respectively.

Conclusions

DIE is a form of endometriosis that usually requires surgical intervention because medical treatment is not effective. The surgical approach for DIE is challenging and should only be performed by surgeons who are experienced in performing such procedures. Laparoscopic management of DIE is a valid treatment option in terms of the reduction of postoperative pain and increasing quality of life according to pain score outcomes.

<https://esge.covr.be/cmdocumentmanagement/conferencemanager/documents/api/getdocument/5075/cmabstms/000046220/f76396dfe7eb11a2dd8b83110106d76e1f6e2db4f14f7ed9de11fd69aadee76f>

ES28-0487 - P204

E-Poster

Laparoscopic management of cornual ectopic pregnancy using encircling stitch - a study of 17 cases

*Niraj Yanamandra*¹

¹*Rainbow hospitals, Obstetrics & Gynaecology, Hyderabad, India*

Background

Cornual pregnancy accounts for 2–4% of ectopic pregnancies and is said to have a mortality rate in the range of 2.0–2.5%. The diagnosis and treatment are challenging and frequently constitute a medical emergency. Because of the abundant blood supply in the cornual region from both uterine and ovarian vessels, rupture occurring after 12 weeks of gestation often leads to severe haemorrhage and even death. Surgical management can be challenging in view of the risk of significant intra-operative bleeding. The technique of using encircling stitch at the base of ectopic pregnancy can reduce the risk of bleeding.

Methods

Laparoscopy was performed under general anaesthesia with 4-port technique including the umbilical port through which a 10 mm laparoscope was introduced. A polyglactin suture on a round bodied needle was used to encircle the ectopic pregnancy. Salpingotomy was performed using monopolar diathermy. Aqua-dissection was performed to remove the placental tissue while causing minimal tissue destruction. Products of conception were removed in one of the commercially available retrieving bags. Saline lavage was given and trocars withdrawn under vision after confirming haemostasis.

Results

Seventeen women over a period of 6 years were diagnosed with cornual ectopic pregnancy. The diagnosis was made between 8-12 weeks of gestation. All of them underwent laparoscopic salpingotomy using the technique described above. The operative time ranged between 75 + 10mins. The average blood loss was 55 ml. None of the patients needed blood transfusion and there were no intra or post-operative complications. All women were discharged within 24 hours.

Conclusions

Laparoscopic management of cornual ectopic pregnancy using encircling suture method is simple, safe, effective and nearly bloodless. It does offer all the other proven benefits of minimal invasive surgery including less analgesic need, quick return to work and minimal adhesive morbidity. This technique needs good intra-corporeal suturing skills.

<https://esge.covr.be/cmdocumentmanagement/conferencemanager/documents/api/getdocument/5277/cmabstms/000040170/f4a7da8b2d2606f9de87325f6a3b5898a59e9293b41bcc81d7b5220ed113c008>

ES28-0479 - P205

E-Poster

Uterovaginal anastomosis for cases of MRKH syndrome with rudimentary cavity

Hongxin Pan¹, Luo Guangnan¹

¹Luohu People's Hospital, Gynaecology, Shenzhen, China

Background

MRKH Syndrome with rudimentary cavity is a rare Mullerian anomaly. Surgical excision remains the classical treatment of the uterine horn with an endometrial cavity. The purpose of this study was to evaluate functional results of uterovaginal anastomosis done for cases of MRKH syndrome with functional rudimentary cavity.

Methods

Surgical procedures were done between May 2017 and December 2018 at the department of obstetrics and gynecology, the 3rd affiliated hospital of Shenzhen University. twelve patients who had diagnosed MRKH syndrome with rudimentary cavity were included. Combined laparoscopic Luohu vaginoplasty and anastomosing the uterine horn to the neovagina were performed. Follow-up was done by gynecological and MRI examination in a duration ranged from 6 to 18 months.

Results

The utero-vaginal anastomosis procedure was performed successfully in all cases. All patients had relief of the cyclic pain and had regular menstrual flow. two patients developed low vaginal stenosis without occlusion of the track.

Conclusions

Utero-vaginal anastomosis should be a promising conservative management option for MRKH syndrome with rudimentary cavity. Early diagnosis and surgery appear necessary to avoid the development of pelvic associated lesions.

<https://esge.covr.be/cmdocumentmanagement/conferencemanager/documents/api/getdocument/5158/cmabstms/0000149090/2040f6964a31795b6cb20cda3b9617b94c7f090d422c4b1080f1b4b77226f4df>

ES28-0481 - P206

E-Poster

Outpatient hysteroscopy with fingertip guidance, a new simple alternative to vaginoscopic approach

Tamer Said¹

¹Alexandria University, Obstetrics and Gynaecology, Alexandria, Egypt

Background

Outpatient hysteroscopy is one of the commonest procedure done in the tertiary hospital. Although the vaginoscopic approach is commonly used to enter the uterine cavity, a good percentage of patient document discomfort and pain during the procedure and can't tolerate the pain during the procedure. It is logic to try new methods to enter the uterus and to examine this method for effectiveness and discomfort.

Methods

This trial was done in the endoscopy unit in Alexandria university hospital and 250 women participated in this study. All of them were assigned to do office hysteroscopy. Informed consent was taken from all patients. Detailed history and vaginal ultrasonography was done for each case. Pregnancy test was done for all patients to exclude pregnancy. Half of cases (125 cases) were subjected to fingertip guided entry while the vaginoscopic approach was used in the rest of patients(125 cases).

Introduction of the office hysteroscopy inside the uterus with fingertip guidance using the index finger of the Lt hand to cover the tip of the hysteroscopy till it reaches the external os then navigation was done as usual inside the cervical canal and inside the uterine cavity.

Results

Descriptive analysis and clinical criteria of the study groups was done. The duration of the procedure, pain score and effectiveness of both approaches were compared. All adverse effects and complication were documented.

Conclusions

Outpatient hysteroscopy using the fingertip guidance is a safe, effective and tolerable choice for entry and has shorter time and less pain than vaginoscopic approach.

<https://esge.covr.be/cmdocumentmanagement/conferencemanager/documents/api/getdocument/5088/cmabstsms/000045340/1bef8e56080f759ac6220a9833a84d4b7e8acc49d1736259a0232cc37c35ba7c>

ES28-0495 - P208

E-Poster

Can we tame the bête noire? A review of urinary tract injuries in gynaecological laparoscopic surgery

*Karim Abdallah*¹

¹Sheffield Teaching Hospitals, Obstetrics and Gynaecology, Sheffield, United Kingdom

Background

The advantages of laparoscopic surgery over open surgery for benign gynaecological conditions have long been identified and proven in several studies. The argument that the incidence of urinary tract injuries increase with the laparoscopic approach was based on old studies. This review of literature aims to discuss and outline the incidence of urinary tract injuries during laparoscopic surgeries and means to avoid and reduce these types of common complications.

Methods

An online search including Cochrane library, Pubmed and Wiley's online library. We have also looked at the guidelines published by relevant Royal Colleges.

Results

Several studies have been identified discussing this major issue with laparoscopic surgery. studies and reviews that were published in English language had a reasonable number of patients were included.

Conclusions

Urinary tract injuries are the most common complications associated with laparoscopic gynaecological surgery. Appropriate knowledge of the anatomy combined with training and increased experience greatly reduce the risk.

ES28-0560 - P209

E-Poster

The impact of the blockade of DNA-methylation on the endometrium in the induced model of endometriosis in rats

*Yevdokymova Viktoriya*¹

¹Surgical, Gynecology, Odessa, Ukraine

Background

Endometriosis is the complex disease characterizing with the pathological and compensatory changes in the affected organs and tissues, with the general disorders in the female organism as the response to the local lesions with ectopic endometrium. This dishormonal, immunodependent and genetically predetermined disease takes the third place in the structure of gynecological morbidity and occurs in 8-15% females of fertile age. Accordingly to the data of recent researches the incidence of endometriosis is 17% for primary health care and 30% for patients requiring surgery.

Methods

There are widely used laboratory models when the new methods of the diagnosis and treatment are implementing to the medical practice. To assess the growth dynamics of endometrial ectopies in the conditions of the various activity of DNA methylation there was conducted the experimental study.

Results

The 80 Wistar line rats distributed into the referent groups: control group (n=20) with intact animals; I experimental animals (n=30) – animals with the artificially modelled endometriosis, II experimental animals (n=30) - animals with the modelled endometriosis and the blockade of DNA methylation with 5-aza-2-deoxycytidine (SigmaChemical Co., USA).

Conclusions

The duration of experiment was 3 weeks. For modelling endometriosis there was resected the uterine horn which was dissected along its sagittal axis, the flap was sutured to the parietal peritoneum with the endometrial surface. Before the surgery the rats received estrogen like folliculinum during 5 days. The statistical processing was conducted by the non-parametric methods, the software tools of Statistica 7.0 (StatSoft Inc., USA) were used.

<https://esge.covr.be/cmdocumentmanagement/conferencemanager/documents/api/getdocument/5288/cmabstsms/0000166500/22c99777b4aade4338940b4245c12fbd1186b523f42172b6a13cc9803d7362d6>

ES28-0510 - P210

E-Poster

Long-term assessment of serum anti-Müllerian hormone level after laparoscopic excision and suture for ovarian endometrioma

Jun Kumakiri¹, Yoshika Akizawa¹, Toshiyuki Kanno¹, Nobuko Takahashi¹, Tutomu Tabata¹

¹Tokyo Women's Medical University, Obstetrics and Gynecology, Tokyo, Japan

Background

Ovarian reserve after laparoscopic surgery for ovarian endometrioma is commonly known to be decreased, however, few studies concerning long-term assessment of serum anti-Müllerian hormone (AMH) levels after laparoscopic excision and suture have examined. We assessed ovarian reserve after the laparoscopic surgery in the long term by serial measure of the postoperative serum AMH level.

Methods

Fifty-six patients who underwent laparoscopic excision and suture from 2012 and 2016 were retrospectively analyzed. The AMH level was measured before surgery and at 3, 6, 12 and 24 months after surgery. Factors influenced on serum AMH level at 24 months after surgery were analyzed by multiple regression model.

Results

The mean serum AMH levels at 3, 6, 12 and 24 months after surgery were significantly decreased that the level before surgery (3.2 ± 3.1 , vs 1.9 ± 2.4 , 1.9 ± 2.2 , 1.9 ± 2.4 , and 1.8 ± 2.2 ng/mL, $p < 0.001$). In 30 patients with unilateral ovarian endometrioma, the serum AMH levels at these periods were 3.1 ± 2.8 , 2.7 ± 2.9 , 2.6 ± 2.7 , 2.7 ± 2.9 , and 2.5 ± 2.7 ng/mL, respectively. The AMH level at 24 months after surgery was significantly decreased than the level before surgery ($p=0.004$). In 26 patients with bilateral ovarian endometriomas, the serum AMH levels at these periods were 3.2 ± 3.4 , 1.0 ± 1.0 , 1.0 ± 0.9 , 0.9 ± 0.9 , and 1.0 ± 0.8 ng/mL, respectively. The AMH levels measured at all postoperative periods were significantly decreased than the level before surgery. Age, bilateral endometrioma, and preoperative serum AMH level were significant factors influenced on serum AMH at 24 months after surgery by multiple regression model.

Conclusions

Our data suggest that the decreased ovarian reserve after the laparoscopic surgery for ovarian endometrioma does not recover in the long term. In addition, the high risk of decreasing ovarian reserve in the long-term postoperative periods is considered in the laparoscopic surgery for older patients with bilateral ovarian endometrioma and low level of preoperative AMH level.

<https://esge.covr.be/cmdocumentmanagement/conferencemanager/documents/api/getdocument/5066/cmabstms/000073970/bcddf05f07cc1a6b09752f848dd7088671f33e54c8ccd9234c8f12e6f6062c95>

ES28-0502 - P211

E-Poster

Uterine isthmocele management: minimally invasive approach and its gynecological and obstetrical outcome - a prospective study

Bedayah Amro¹, Shaima Al Suwaidi¹, Zeinab Hakim¹, Maria Ramirez¹, Arnaud Wattiez¹

¹Latifa Hospital, Ob&Gyn, Dubai, United Arab Emirates

Background

Uterine Isthmocele is a growing entity in the field of minimally invasive gynecology surgeries especially in the last decades. This is mostly due to tremendous increase in cesarean section rate worldwide, and physician's awareness about Isthmocele diagnosis and possible clinical symptoms. Nowadays; symptomatic Isthmocele considered a challenge for physicians as there is no clear criteria yet for the best approach in term of selection and outcome whether gynecological or obstetrics. In our minimally invasive center we face quite significant no of such cases, for which we developed a systematic approach either by hysteroscopy (resection and coagulation) or laparoscopy (new overlap technique) management.

Objective: To study the appropriateness and effectiveness of each approach (laparoscopy (overlap technique) and hysteroscopy) in management of uterine isthmocele and its gynecological and obstetrical outcome

Methods

Design: A prospective study

Setting: In tertiary hospital -minimally invasive center-Latifa Hospital, Dubai, UAE

Patients: a series of 40 patients (till now, still recruiting going on) starting from 2018, with symptomatic uterine isthmocele, who attended our center and undergone either laparoscopic or hysteroscopic repair

Intervention: Laparoscopic (new overlap technique) or hysteroscopic repair according to selection criteria (i.e residual myometrial thickness, isthmocele characteristics, patient's complaints)

Main outcome measures: gynecological and obstetrical outcomes, increase in myometrial thickness at the site of cesarean section and correlation with histological analysis of the defect

Results

Study is still ongoing, preliminary results showed quite effectiveness of the hysteroscopic approach in resolution of the symptoms (esp. post menstrual spotting, chronic vaginal discharge and dysmenorrhea), laparoscopic approach with our new technique (overlap technique) showed quite effectiveness in restoring the anatomical thickness of uterine wall at the site of isthmocele. Fertility through IVF was improved tremendously after laparoscopic repair

Conclusions

In our opinion, criteria should be set in the management approach of isthmocele and should mainly depends on the patient presenting complaints. We believe that laparoscopic approach with our new technique in restoring the anatomical thickness of uterine wall is logically recommended for patient with infertility complaint. Hysteroscopy is an effective way for symptoms resolution though it doesn't correct the anatomical weakness of the wall so effect on obstetrics outcome is still questionable and awaiting final results of the study.

<https://esge.covr.be/cmdocumentmanagement/conferencemanager/documents/api/getdocument/5022/cmabstms/000144260/1dddf306e1a302074fd46b2235f070002ed02b06ad135c90260c38834da79c63>

Secondary abdominal pregnancy after primary laparoscopic salpingectomy for tubal pregnancy - a case report

Hui Fen Kao^{1,2}, Man-Jung Hung^{2,3}

¹Asia University, Department of Healthcare Administration, Taichung, Taiwan

²Asia University Hospital, Department of Obstetrics and Gynecology, Taichung, Taiwan

³Asia University, College of Medical and Health Science, Taichung, Taiwan

Background

Abdominal pregnancy indicated a pregnancy that has implanted in the peritoneal cavity and could occur 6 percent of maternal mortality rate due to the extra uterine implantations in omentum, vital organs, or large vessels, which leads to severe blood loss as invading vessels.^[1] The incidence was around 1.4 percent of ectopic pregnancies.^[2] The secondary abdominal pregnancy (SAP) refer to the extra uterine abdominal pregnancy beyond primary pregnancy status.^[3]

Methods

Case report

A 29-year-old primigravida woman has received primary laparoscopic radical right salpingectomy due to ruptured tubal pregnancy with abdominal internal bleeding.(Fig. 1) The pathologic appearance of the right fallopian tube revealed chorionic villi and the curettage endometrial tissue obtained decidua with Arias-Stella reaction. The decrease in serum β -human chorionic gonadotropin (hCG) between day 0(14167 mIU/ml) and day3(1106 mIU/ml) post-operation is 92.2 percent. After discharged, β -hCG increased to 6901 mIU/ml in day 17 postop at clinic. The clinic symptoms, signs and TVS showed no significant finding. The SAP was suspected and she received the single-dose protocol of methotrexate therapy (MTX) 82mg intramuscularly. The decrease in β -hCG between Day 4(3252 mIU/ml) and Day7(2085 mIU/ml) post-MTX is 35.89 percent. Unfortunately, she suffered acute upper abdominal pain as day 8 post-MTX. The secondary laparoscopy was performed, the purplish mass with bleeding was found at the dorsal part of great omentum near transverse colon during surgery, 3 cm in diameter(Fig. 2) and about 800 mL blood in the CDS. The lysis the mass from omentum was done carefully. Pathologic examination found chorionic villi in the removed tissue. β -hCG decreased to 399 mIU/ml in the second day and 198 mIU/ml in day 4 of secondary postop. After discharged, the follow-up serial β -hCG decreased to <0.6 mIU/ml in day 28 of secondary postop.

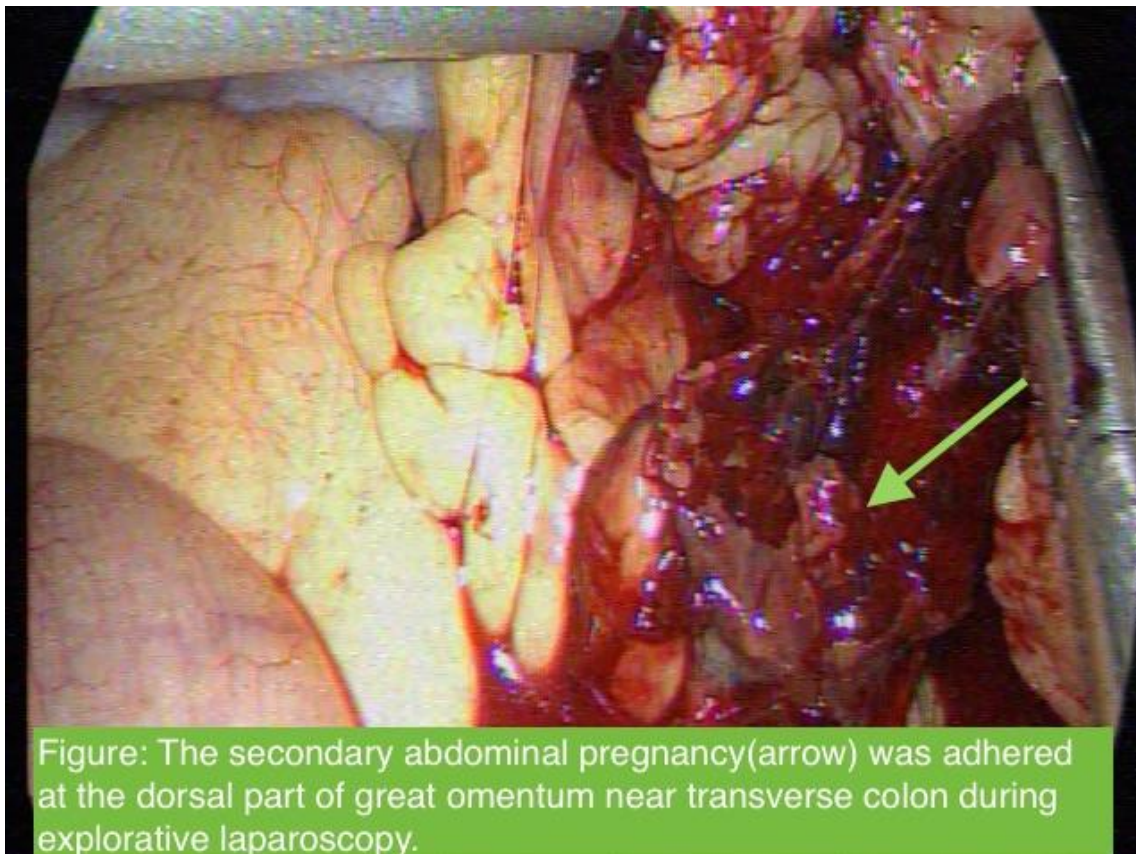


Figure: The secondary abdominal pregnancy(arrow) was adhered at the dorsal part of great omentum near transverse colon during explorative laparoscopy.

Results

Postoperative serial β -hCG levels were revealed stable or increased are risk of persistent trophoblast activities.^[4] The incidence of postoperative persistent ectopic pregnancy(PEP) was reported as 2.1% to 5.4%.^[5] It was difficult to distinguish the new lesion was iatrogenic spreading of the gestational tissue, but we could know the trophoblastic cells were in high activity.^[6]

Conclusions

SAP after primary laparoscopic treatment of tubal pregnancy is very low incidence, however the scenario could occur maternal morbidity and mortality. We present this case report hope to emphasize the awareness about follow-up serial serum β -hCG levels after ectopic operation closely until the level is negative.

<https://esge.covr.be/cmdocumentmanagement/conferencemanager/documents/api/getdocument/4965/cmabstms/000166620/b9d92de59c42f861250d2893947e5d7d50b78dddac74144ca8ff64d1a943d4ae>

ES28-0507 - P213 E-Poster

Case report and literature review of gas embolus during operative hysteroscopy: prevention, identification and management

Nicholas Dixon¹, Parijat Bhattacharjee¹

¹North West London University Hospitals, Obstetrics and Gynaecology, London, United Kingdom

Background

Symptomatic gas embolism during minimal access surgery is a rare and extremely dangerous event. We present a case report of a gas embolism during operative hysteroscopy. We also review the literature regarding recognition, risk reduction and management of gas embolism during operative hysteroscopy.

Methods

The case report is presented with reference to the patient notes as well as electronic results and imaging system at North West London University Hospitals Trust. Consent gained from patient for use of case. The literature search was carried out using key words related to case.

Results

Multiple studies have shown that gas emboli occur in 85-100% of operative hysteroscopic procedures. However incidence of morbidity and mortality secondary to gas embolus at time of hysteroscopy is around 1 in 5000 cases. We highlight how risk can be reduced by surgical technique, apparatus, safety practices in theatre, intraoperative monitoring of the patient as well as patient selection.

Conclusions

Gas emboli are an unavoidable phenomena in operative hysteroscopy. However reducing the fluid and gas intravasation, alongside other safety measures can reduce the strain placed on the pulmonary circulation and increase patient safety.

<https://esge.covr.be/cmdocumentmanagement/conferencemanager/documents/api/getdocument/5011/cmabstms/000166380/c705dcdcfcb9b9ff1889019680dc560ebff477f419f72a7a7245b51845d9e5c32>

ES28-0522 - P214 E-Poster

Balloon vaginoplasty: outcomes of 300 cases of neovaginal construction via mechanical tissue expansion

Ahmed Mohamed¹, Ali El Saman¹, Alshymaa H. Eleraky¹, Ahmed Abass¹, Tarek Farghaly¹, Essraa Badran¹

¹Assiut University- Egypt, Obstetrics and Gynecology, Assiut, Egypt

Background

Vaginal aplasia occurs in 1 in 5,000–10,000 female live births. Balloon vaginoplasty is a new and fast approach for construction of neovagina via mechanical tissue expansion. However, there was a rising concern about reproductive outcome of this technique. This work aimed to evaluate the impact of balloon vaginoplasty surgery on reproductive function.

Methods

Study population: Two major groups were identified:

Group A: cases with vaginal aplasia without functioning uterus. The main procedure was laparoscopic balloon vaginoplasty as described by (El Saman AM et, al.) We assessed the anatomical quality of the constructed neovagina and sexual function of identified cases. Group B: cases with isolated vaginal aplasia with functioning uterus, pull down or dual forces balloon vaginoplasty were performed. where the outcomes were related to menstrual, sexual and pregnancy outcomes.

Results

In group A, 277 cases were reported, all had a successful non complicated (apart of 2 burst balloon) procedure. The neovaginal depths were 8-11 cm as measured by specially designed vaginometer. Penetration score increased from 0-20/100 points to 80-90/100 points. Satisfactions scores penetration score increased from 10-30/100 points to 80-90/100 points.

In group B, 23 cases were identified, menstrual function were resumed and established in 19 cases after the first procedure and 4 cases after redo procedure secondary to vaginal stenosis. Five cases got married and all have regular satisfactory coital relation and two of them got 3 successful pregnancies

Conclusions

The results of this work showed that the balloon vaginoplasty has favorable anatomical, sexual and reproductive outcomes.

<https://esge.covr.be/cmdocumentmanagement/conferencemanager/documents/api/getdocument/4962/cmabstsms/000085090/eefe1fd38ab2881e220c2fd6b90a54957321e500df4a0e4de3491bc369991e96>

ES28-0515 - P215

E-Poster

A comparison between office hysteroscopy and OR hysteroscopy for RPOC removal

Nili Raz Kfir-EI^{1,2}

¹*Hillel Yaffe Medical Center, Department of Obstetrics and Gynecology, Hadera - Israel*

²*Technion, The Ruth and Bruce Rappaport Faculty of Medicine, Haifa, Israel*

Background

Abbreviations

OR operation room

RPOC-retained product of conception

CS -cesarean section

Objectives: To prove feasibility, efficacy and safety of office hysteroscopy removal of RPOC under 2cm.

Methods

We perform most RPOC removals over 2cm in the OR under general anesthesia using Johnson and Johnson 10mm gynecare hysteroscope, and most smaller ones in an office setting without anesthesia using the Storz 2.9 hysteroscope. We retrospectively compared the OR and office hysteroscopy routs for RPOC removal.

Results

Our pilot research included 15 patients in the office hysteroscopy RPOC removal group and 29 patients in the OR hysteroscopy removal of RPOC group. There was no statistical difference between the groups in gravidity, parity, abortions, previous cs, length of operation, median operating doctor experience.

There was no difference in complication rate between the 2 groups. Yet there were only 2 complications in this research – 2 patients in the office hysteroscopy group who suffered from anxiety just prior or in the beginning of the hysteroscopy thus needing to discontinue the procedure and were referred to OR treatment under anesthesia (the patients were 28,31 years old, RPOC size were 1,1.4 cm).

We found more patients with larger residua in the in the OR group compared with the Office group (an average size of 2.5 cm and 1.3cm respectively), due to the selection bias mentioned in the methods section. We found older patients in the OR group compared with the Office group (an average age of 33.5 and 28.8 years old respectively). The last 2 differences in size and age can be attributes to selection bias.

Average length of procedure in office hysteroscopy was 18.5 minutes compared to 23.8 minutes in the OR hysteroscopy, this trend for shorter procedure in office hysteroscopy did not achieve statistical significance, yet we believe it to be due to the small sample size.

Conclusions

This pilot study suggests office hysteroscopy in RPOC under 2cm is at least as good as OR hysteroscopy for larger RPOCs in terms of length of procedure and complication rate. We keep in mind that office hysteroscopy is known to be more cost effective.

The main disadvantage of our pilot is the small sample size, thus very small complication rate. We continue the study and plan to include more patients

<https://esge.covr.be/cmdocumentmanagement/conferencemanager/documents/api/getdocument/5050/cmabstms/0000166400/e9c4271bf44e1df12554a07436629b3f7fc0f931dca295ced806011c31143dc7>

ES28-0516 - P216

E-Poster

Predicting bowel resection amongst patients undergoing surgery for severe recto-vaginal endometriosis

Martin Hirsch¹, Alexandra Wojtaszewska², Arvind Vashisht¹, Alfred Cutner¹, Ertan Saridogan¹

¹University College London Hospitals, Gynaecology, London, United Kingdom

²University College London, School of Medicine, London, United Kingdom

Background

Severe endometriosis can take many forms including recto-vaginal disease. Techniques to excise recto-vaginal endometriosis include shaving, discoid bowel resection and segmental bowel resection. The operative length and morbidity is significantly increased with a bowel resection. There are limited pre-operative assessments that can accurately predict the requirement for the different surgical techniques required to excise all endometriosis. We aim to assess the association and accuracy of British Society of Gynaecological Endoscopy (BSGE) pain scores to predict bowel resection during surgery for recto-vaginal endometriosis.

Methods

Retrospective observational cohort study of consecutive patients undergoing bowel surgery for severe endometriosis at University College London Hospital. Data were collected from the BSGE online database excluding those patients not requiring bowel surgery. Univariate analyses were performed using Mann-Whitney U tests to assess relationship associations between bowel resection and pre-operative pain scores including: dysmenorrhoea; dyspareunia; and dyschezia during or outside periods.

Results

We included 100 consecutive women recruited between January 2016 and May 2018. Nine women (9%) underwent bowel resection during this period, 91 underwent a rectal shave. Cyclical dyschezia was the only pre-operative pain score associated with bowel resection ($p = 0.002$). A cut off score $> 7/10$ cyclical dyschezia, 9/55 (16%) required a bowel resection, and 0/45 patients with a pain score \leq seven required a bowel resection. With a cyclical dyschezia score $> seven$, the probability of requiring a bowel resection is 10.9%.

Conclusions

Cyclical dyschezia is the only pain score to be positively associated with bowel resection during surgery for severe endometriosis with bowel involvement. A cut off score above seven was highly sensitive but not specific for bowel resection. Cyclical dyschezia \leq seven performs well as a rule-out test for those proceeding with surgery for severe endometriosis. This aids counselling, consent and theatre scheduling. A multivariate analysis with additional pre-operative markers is required for greater accuracy.

ES28-0517 - P217

E-Poster

Laparoscopic management of ovarian torsion in early pregnancy: a case report

Mohamed Raslan¹, Pritesh Naik², Heba El Bassyony¹, Mohamed Elnamoury¹, Ayman Dawood³, Stefano Angioni⁴

¹Tanta University, Obstetrics and Gynecology, Tanta, Egypt

²Purnima Hospital, Gynecology, Mumbai, India

³Tanta University, Obstetrics and Gynecology, Tanta, Egypt

⁴University of Cagliari, Surgical Science, Cagliari, Italy

Background

Around 0.2% of pregnant women require abdominal surgery. The most common indications of laparoscopy in pregnancy are cholelithiasis complications, appendicitis, persistent ovarian cyst and adnexal torsion. Ovarian torsion in pregnant women is a relatively rare but serious complication may occurs if neglected

Objectives: To evaluate the efficacy and safety of early laparoscopic intervention in management of ovarian torsion in early pregnancy. Study design: Case report.

Methods

A 29-year-old primigravidain her first trimester (12 weeks) who had conceived spontaneously presented with severe and persistent lower abdominal pain. Pain was sharp stabbing and spreading diffusely across the lower abdomen. Patient had signs of an acute surgical condition. Ultrasound examination revealed a viable singleton intrauterine pregnancy of 12 week gestation and enlarged left ovary with left large hemorrhagic cyst measuring 12.8x10.8 cm. Doppler ultrasound revealed absent flow in ovarian vessels denoting ovarian torsion. Patient presented approximately 10 hours after onset of symptoms. Exploratory laparoscopy was performed in conjunction of intravenous tocolysis and subcutaneous progesterone injection. Uterine manipulations were restricted.

Results

The left ovary was found twisted once (laterally rotated) around its pedicle, black in color, with dark blood getting out on puncture. Laparoscopic de-torsion was done and left ovarian cystectomy were done. The duration of surgery was 96 minutes. The ovarian cyst was extracted via secondary port. Postoperative follow-up was uneventful. Ultrasound was done prior to discharge and patient was discharged after one day. Pregnancy continued successfully till 39+5 weeks with normal vaginal delivery of a healthy female infant.

Conclusions

Immediate exploratory laparoscopic management of ovarian torsion in early pregnancy is beneficial for treating ovarian torsion and preservation of the ovary. The procedure was found to be safe and not associated with any procedure related complications.

<https://esge.covr.be/cmdocumentmanagement/conferencemanager/documents/api/getdocument/5028/cmabstms/000166720/86cd7e7147f14938e6fec7aee8b87034f4cd73b93852481b941a3d73e8240d04>

Feasibility of robotic multisite-site hysterectomy with sentinel node mapping for treating early-stage endometrial cancer: a prospective pilot study

Fabio Barra¹, Franco Alessandr², Simona Iannini¹, Claudio Gustavino², Maria Grazia Centurion², Simone Ferrero¹

¹IRCCS Ospedale Policlinico San Martino- University of Genoa, Academic Unit of Obstetrics and Gynecology, Genoa, Italy

²IRCCS Ospedale Policlinico San Martino, Unit of Obstetrics and Gynecology, Genoa, Italy

Background

To evaluate the feasibility and safety of robotic multi-site hysterectomy with sentinel node mapping by intraoperative near-infrared fluorescence for treating patients affected by early-stage endometrial cancer that is expected to have a low risk of nodal involvement.

Methods

Patients with endometrial cancer at preoperative FIGO stage IA-IB were enrolled in this prospective pilot study. We excluded patients with extra-uterine disease or pre-operative evidence of pelvic or lombo-aortic nodal tumor involvement at pelvic ultrasound and magnetic resonance imaging (MRI). The surgical approach was conducted via the Vinci Xi Surgical System® (Intuitive Surgical Inc., Sunnyvale, CA, USA) by the same two operators. Prior to the placement of the manipulator, 4 mL of indocyanine green 0,5% infiltrated in the cervix at the 3 and 9 o'clock position, superficially (0.1 cm) and deep (1 cm) within the cervical stroma; thereafter, the peritoneal cavity was inspected and a pelvic washing was obtained. Initially, the abdominal cavity was entered, whereupon the round ligament as well as the peritoneum lateral to the infundibulo-pelvic ligament were divided for both uterine side. The sentinel lymph nodes were researched by intraoperative near infrared fluorescence Firefly™ system (Intuitive Surgical Inc., Sunnyvale, CA, USA) within approximately 20 min from the cervical injection. The various nodal regions (obturator, external iliac, presacral) of interest were accurately evaluated.

Results

Between April and December 2018, thirty-six patients undergoing robotic-assisted laparoscopic hysterectomy plus sentinel node mapping were included in the study. The median age of the patients was 57 years (range, 36-83 years) and the median body mass index was 23.7 kg/m² (range, 18.2-32.2 kg/m²). The median docking time, console time, and total operative time was 18 min (range, 9-36 min), 101 min (range, 71-149 min), and 123 min (range, 86-259 min), respectively. The median blood loss was 56 mL (range, 20-169 mL). Ultimately, the mapping procedure engendered at least one sentinel lymph node in 35 (97.2%) patients and was successful at bilateral mapping in 34 (88.9%) of the subjects. At definitive SLN histological evaluation, 6 women (16.7%) had pelvic-lymph-node metastases. The median time to discharge after the surgical robotic approach was 3 days (range, 2-9 days). Overall, no laparoscopic and 1 laparotomic conversions were required. One intraoperative (a bladder perforation, promptly sutured) and no post-operative complications occurred during the surgical procedures; no surgical complications were reported during sentinel node biopsy.

Conclusions

We demonstrated the feasibility at our institution of robotic multisite-site hysterectomy with sentinel node evaluation for treating patients affected by early-stage endometrial.

<https://esge.covr.be/cmdocumentmanagement/conferencemanager/documents/api/getdocument/5280/cmabstms/0000143980/0d9b86aa48aada652ffff3ab6da0f7a3229f2a29dfa963ebf3594f4754042951>

ES28-0529 - P221

E-Poster

Abdominal wall endometriosis: an 11-year retrospective observational cohort study

Jean Dubuisson¹, Sandra Marras², Nicola Pluchino¹

¹Geneva University Hospitals, Obstetrics and Gynecology, Geneva, Switzerland

²Geneva University Hospitals, Obstetrics and Gynecology, Geneva, Switzerland

Background

The objective of this study was to review patient characteristics, diagnostic methods, presence of concurrent pelvic endometriosis and type of surgery in patients with excised abdominal wall endometriosis (AWE).

Methods

Medical records from an 11-year period were searched to identify histologically confirmed AWE cases. Descriptive data were collected and analyzed. Two subgroups were differentiated: isolated AWE and pelvic endometriosis associated AWE.

Results

Thirty-five women with AWE were included. The most common symptom was cyclic abdominal or parietal pain (68.6%). 17.1 % had no symptom. Twenty-nine women (82.8%) had a history of gynecological or obstetrical surgery, most commonly cesarean section (CS). The mean interval between prior surgery and appearance of symptoms was 5.3 years. Six women (17.1%) had no prior surgery; all six presented with umbilical nodules, nulliparity and confirmed mild to severe pelvic endometriosis. Concurrent pelvic endometriosis was present in 34.3% of all women; 40% presented with isolated AWE while nine women (25.7%) had no pelvic exploration. Women with concurrent pelvic endometriosis had significantly lower parity, smaller nodule size and more umbilical location than those with isolated AWE ($p < .05$). A history of CS was more commonly found in women with isolated AWE. The overall recurrence rate was 11.4%, with a mean time follow-up of 5.2 years.

Conclusions

AWE is an infrequent condition associated with a long diagnostic and therapeutic delay. In patients with umbilical AWE and no surgical history, pelvic endometriosis is commonly associated and should be highly suspected.

<https://esge.covr.be/cmdocumentmanagement/conferencemanager/documents/api/getdocument/5151/cmabstms/000024320/9336edf3d459fa3ffd5227851da68b9b201aff88324bf34d381a3293cbbb5b6>

ES28-0531 - P222

E-Poster

Impact of the endometrioma surgery on fertility

Amal Mouzali¹, Mohamed Ziad Cheikh Al Ghanama¹, Smail Guerroum², Mokrane Medjtoh³, Nacima Djennane¹, Soumia Fedala¹

¹Medecine, CHU BEO, Algiers, Algeria

²Medecine, CHU Aïn Taya, Algiers, Algeria

³Medecine, CHU Naffissa Hamoudi, Algiers, Algeria

Aim

Our principal aim is to evaluate the impact of endometrioma cystectomy, on the ovarian reserve three and twelve months after surgery in infertile women by measuring : AFC,FSH and AMH

The second aims are:

- to calculate the pregnancy rate after surgery;
- to evaluate the pain by EVA before surgery and three and twelve months after ;
- to calculate the follicles' numbers retrieved on endometrioma cyst.

Background

Endometriosis is a common disease which can cause infertility, particularly in the case of endometrioma where two controversial options are proposed: surgery or AMP beside the absence of well-established recommendations.

Materials / Patients

In this study, 40 infertile patients with ovarian endometriomas whose diameter is greater than 04 cm aged between 21 and 40 years old with normal spermogram and tubal patency, were underwent laparoscopic surgery for cystectomy and treatment of endometriotic deep lesions if pain is associated or other pathologies non related to endometriosis disease like myomas, uterin's septa...

Surgeries were underwent by laparoscopy and one gynaecologist performed all surgery with patients consent.

Inclusion criteria are:

Age under 35 years old and AMH ≥ 1 ng/ml
Age 35 years old or over even if AMH < 1 ng/ml who refused AMP alternative
Endometrioma cyste ≥ 4 cm
Normal spermogram
Tubal patency at least unilateral

Exclusion criteria:
antecedent of two endometrioma cystectom

Methods / Results

This is a prospective and descriptive longitudinal study in a single centre at BAB El Oued state Hospital in Alegria between February 2014 and December 2018 that concern infertile women. The average age was: 31 ± 0.7 years old.

In This study, the endometrioma was isolated in 30% of cases, while 70% of endometriomas were associated with other pathologies of which 50% are deep endometriosis .

On cycle day 3 the following hormone levels were measured: serum levels of anti-Müllerian(AMH)

hormone, follicle-stimulating hormone(FSH), the number of antral follicles(AFC) was counted as well. The scanning was performed through 2D technology transvaginal ultrasound.

After cystectomy by laparoscopy, there was a significant increase of AFC 12 months after surgery (7.75 ± 0.58 follicles before surgery versus 8.48 ± 0.55 follicles after surgery, IC 95% [-3.16, -1.13], $p < 10^{-3}$).

The average of FSH doesn't increase, whereas the AMH decreases significantly in the postoperative period after three and twelve months (2.29 ± 0.26 ng/ml before versus 1.47 ± 0.23 ng/ml after three months ; 95% IC [0.50, 1.14], $p < 10^{-3}$ and 1.46 ± 0.20 ng/ twelve months after surgery ;95% [0.51, 1.14] , $p < 10^{-3}$).

But after stratification into three groups:

A first group where AMH is decreased after surgery in 50% of patients (2.55 ± 0.4 ng / ml preoperatively and 1.15 ± 0.21 ng / ml at 12 months postoperatively with $P < 10^{-3}$)

A second group where AMH is increased in 35% of patients at 12 months after surgery (2.69 ± 0.37 ng/ml preoperatively and increased at 12 months postoperatively 2.37 ± 0.37 ng/ml, $p = 0.13$)

A third group in 15% of patients where AMH is already decreased before surgery (0.50 ± 0.1 ng / ml preoperatively and 0.36 ± 0.2 ng / ml at 12 months postoperatively with $P = 0.31$)

Significant linkage is found between the decrease of AMH after surgery and the associated endometrioma with other surgical gestures. $P < 0.02$ caused by a probably ovarian devascularization.

The number of follicles removed from cysts are correlated to the AMH preoperatively but its absence postoperatively means that more the AMH is higher more are the follicles retrieved especially the primordial ones, in the other hand, the decrease of AMH postoperatively isn't correlated with follicles retrieved.

The surgery is efficient since 47.5% of our patients have obtained spontaneous pregnancy after 32 months of follow-up and 35% after one year despite low levels of AMH and there is one factor that may be incriminated in the non-occurrence of spontaneous pregnancy which is adenomyosis.

The decrease of pains (dysmenorrhoeas , dyspareunias) is significative after three and twelve months after surgery.

Discussion

Our study shows that the surgery of endometrioma is efficient since AFC increases in postoperatively, FSH doesn't increase nevertheless the AMH decreases in general. However, after stratification into three groups, we find a significant relation at the Khi 2 test between the decrease of AMH after surgery and the group where patients underwent endometrioma cystectomy and surgical treatment of other lesions notably deep endometriosis which represented 50% of cases like nodule ablation, shaving, uterolysis...

The AMH level after surgery isn't correlated with the number of follicles retrieved on cysts.

Based on our findings, the endometrioma cystectomy, which has been accused to be deleterious for many years, doesn't really damage the ovarian reserve by itself nevertheless the treatment of lesions particularly the deep endometriotic ones could devascularize ovaries.

In some cases, there was an increase in AMH average after 12 months from surgery, probably after ovarian recovery and revascularization.

In 50% there was a decrease in AMH average in cases where cystectomy is associated with other treatment especially deep endometriosis and 12 months weren't sufficient for ovarian revascularization and recovery.

We can also find a decrease of AMH before any surgery, that suggests the diminution of ovarian reserve is possible and can be created by the endometriosis environment.

Absence of correlation between the average of AMH after surgery and bilateral localisation of endometrioma is almost certain because of non-bilateral cystectomy .

In our protocol, in case of bilateral endometriomas, we decided to perform one unilateral total cystectomy and a partial one or just aspiration of the cyst in the opposite ovary.

The rate of spontaneous pregnancy is 47.5% until 32months follow-up and 35% after one year whereas 52.6 % were pregnant in the first 06 months after surgery and 73.7 % after 12 months, obviously the surgery has a good effect.

The majority of our patients have got pain associated with infertility also the surgery reduce pain in a significant way.

Conclusion

Endometrioma's surgery has been proved to be efficient without increase of FSH and an increase of AFC, nevertheless the decreased rate of AMH which can be increased in some cases in isolated endometrioma .The decrease in AMH level is not correlated with the number of follicles removed and despite this decrease, we get a pregnancy rate up to 47.5% and a reducing pain.

Impact to patients' health

Endometrioma cystectomy should be an alternative treatment of infertility on young patient instead of AMP if ever sperm is normal and tuba is patent, particularly if pain is associated .However, we should avert patients that AMH can be decreased in casep endometrioma isn't isolated but without reducing the spontaneous pregnancy rate.

<https://esge.covr.be/cmdocumentmanagement/conferencemanager/documents/api/getdocument/5159/cmabstms/000162180/18a2bfc3d18e8f7a7fcc3e68b01d18b9252f57bdf329b17a465cb7152545ad17>

ES28-0532 - P223
E-Poster

Robotic surgery vs laparoscopic surgery in patients with diagnosis of endometriosis: systematic review and meta-analysis

Stefano Restaino¹, Angelo Finelli², Liliana Mereu³, Silvia Pelligra¹, Giovanni Scambia¹, Francesco Fanfani¹

¹*Catholic University, Gynecologic Oncology, Rome, Italy*

²*University "G. d'Annunzio" of Chieti-Pescara, Department of Medicine and Aging Sciences, Chieti, Italy*

³*Santa Chiara Hospital, Obstetrics and Gynecological, Trento, Italy*

Background

To evaluate the safety and efficacy of robotic-assisted laparoscopy surgery (RAS) versus conventional laparoscopy surgery (LPS) in the treatment of endometriosis.

Methods

PubMed, Embase, Cochrane and Cinahl databases were searched from January 1995 to March 2019 to compare the RAS surgery with LPS surgery in the treatment of patients affected of endometriosis. According to meta-analysis criteria, 5 comparative studies were selected, including 1 randomized controlled trial and 4 retrospective studies. Outcome measures including length of operation, blood loss, operative complications, and the length of hospitalization. Only studies published in English were included in the meta-analysis. The outcomes of extracted data were estimated by the RevMan 5.3 software.

Results

Compared with RAS, LPS had lower operative time [risk ratio, 0.88; 95% confidence interval (CI), 0.61-1.15; $p < 0.00001$]. We found no significant differences in the conversion rates, blood loss, intra and post-operative complication and length of hospitalization.

Conclusions

More rigorous experimental studies are needed, that compare robotic-assisted surgery and laparoscopic surgery in patients affected by endometriosis. However, current data seem to encourage the use of minimally-invasive surgery to treat benign and malignant gynaecological diseases.

<https://esge.covr.be/cmdocumentmanagement/conferencemanager/documents/api/getdocument/4931/cmabstsms/000000310/e07d150200db8faee32cec5644e84279c7687836ba92445222f11ba58382d778>

ES28-0576 - P224
E-Poster

Cesarean scar viable gestation managed with ultrasound guided local potassium chloride and methotrexate injection, followed by systemic methotrexate and hysteroscopic resection

Maha Al-Khaduri¹, Nihal Al Riyam², Shahila Sheikh²

¹*College of Medicine and Health Sciences- Sultan Qaboos University, Obstetrics and Gynecology, Muscat, Sultanate of Oman*

²*Sultan Qaboos University Hospital, Obstetrics and Gynecology, Muscat, Sultanate of Oman*

Background

Cesarean section rates are increasing with subsequent increase in complications related to the procedure. One such complication is caesarean scar ectopic pregnancy, with an incidence of 1 in 1,886 to 2,216 pregnancies. An ultrasound scan, Doppler examination and magnetic resonance imaging are all useful in early detection of asymptomatic cesarean scar pregnancy, therefore enabling effective treatment and preservation of fertility. Management of scar ectopic can be challenging due to risk of significant bleeding and very high risk of hysterectomy and fertility loss. Synchronous usage of several treatment methods is an effective way to manage cesarean scar pregnancy. Local methotrexate therapy or potassium chloride (under ultrasound or hysteroscopy guidance) should be considered as it offers fertility preservation in asymptomatic pregnant patients. In addition hysteroscopic removal of cesarean scar pregnancy has been reported to be safe and effective in a small case series.

Methods

We report a case of a patient presenting with secondary infertility and a history of two previous cesarean sections with an incidental finding of a scar ectopic pregnancy, just above the internal cervical os, with positive fetal cardiac activity diagnosed by transvaginal ultrasound and elevated serum B-Hcg levels. The patient gave history that she did not miss a period and was seen in the infertility clinic for routine follow up. The patient was asymptomatic and hemodynamically stable. An MRI confirmed the diagnosis. Ultrasound guided intrasac injection of potassium chloride and methotrexate was performed in order to stop the cardiac activity in the foetus and the patient was followed by ultrasound confirming loss of cardiac activity and collapse of the sac. The serum B-Hcg remained elevated at one week post procedure with vascularity around the sac so a single dose of systemic methotrexate was administered. The patient was followed four and seven days later with finding of reduced serum B-Hcg and vascularity by Doppler ultrasound. She started to have fresh bleeding so hysteroscopic resection of scar pregnancy and suction curettage under ultrasound guidance were performed with blood loss less than 100ml. An intrauterine foley was placed for 24 hours with an indwelling bladder catheter and serum B-Hcg dropped drastically on the first postoperative day. She was discharged on the first postoperative day and followed weekly with transvaginal ultrasound and serum B-Hcg till it was negative.

Results

Successful management of viable gestation scar ectopic using intrasac injection of potassium chloride and methotrexate followed by systemic methotrexate and hysteroscopic resection of scar pregnancy with curettage.

Conclusions

Multimodality treatment for viable scar ectopic gestation can prevent significant hemorrhage and preserve patient's fertility with a rapid return to normal B-Hcg.

<https://esge.covr.be/cmdocumentmanagement/conferencemanager/documents/api/getdocument/5251/cmabstsms/000074870/6d20e395bca7f49d9a85853f7fb7ff4fb856513a459bbdc24cee894485941dfd>

ES28-0650 - P225

E-Poster

Case report of pregnancy after laparoscopic myomectomy due to infertility, followed by spontaneous hematoma and scar dehiscence: review of current myomectomy possibilities and its benefits

Jukna Povilas¹, Eglė Machtejevienė¹, Eimantas Švedas¹, Eglė Drejerienė¹

¹Lithuanian University of Health Sciences, Obstetrics and Gynecology, Kaunas, Lithuania

Background

Laparoscopic myomectomy becomes a new standard for the management of infertile patients with fibroids. However, the benefits of this approach remain controversial. The risk of uterine rupture and „near miss“ situation is increased.

Methods

A case of pregnancy after myomectomy is discussed. An electronic search of the published literature was conducted using the search terms "uterine rupture", "scar dehiscence", "myomectomy", "fibroids and pregnancy".

Results

The successful outcome of pregnancy after laparoscopic myomectomy complicated by uterine scar dissection on 25th week of gestation is reported. The pregnancy was prolonged and elective cesarean section at 36th weeks of gestation was performed.

Ultrasonographic and perioperative data are suggest multiple uterine wall transformations in the second and third trimester that may lead to scar dissidence and rupture. Laparoscopic myomectomy has advantages over laparotomy in the management of infertility but the possibility of uterine rupture in subsequent pregnancies should not be underestimated. Myometrium repair should be carefully assessed. Timing of the termination of pregnancy in the scarred uterus after myomectomy is discussed.

Conclusions

A pregnancy post myomectomy should be assessed with the utmost attention, due to rare but intricate uterine rupture complication. Every case needs an individual assessment, but 19 months after surgery is a safe interval to conceive. Consensus remains - if endometrial cavity was damaged a cesarean section should be performed and if possible - after 37 weeks of gestation. Recommendations for "personalised detailed pregnancy management plan after myomectomy" should be proposed.

<https://esge.covr.be/cmdocumentmanagement/conferencemanager/documents/api/getdocument/5246/cmabstms/000152500/5ae5207adbb9daa984c751db3ffa604c915d4c4873a9689be1e5ad0cc83edf59>

ES28-0541 - P226

E-Poster

Reproductive outcomes of complete bicorporeal uterus with a cervical septum (U3 B1 C1) following a novel surgical technique: case series

Recai Pabuçcu¹, Emre Göksan Pabuçcu¹, Tufan Arslanca¹, Aslı Yarcı Gürsoy¹, Mine Kiseli¹

¹Ufuk University Faculty of Medicine, Department of Obstetrics and Gynecology, Ankara, Turkey

Background

Mullerian duct anomalies (MDA) are congenital defects of the female genital system with an incidence ranging from 0.001 to 10%. A didelphys uterus is one of the least common amongst MDAs and also known as a "double uterus," with consisting of two uterine corn. A recent classification system defined this anomaly as U3 (bicorporeal uterus). In this case series, we aim to demonstrate a novel surgical technique for the correction of the endometrial and anatomic texture of the didelphys uterus and to reveal subsequent reproductive outcomes.

Methods

Medical records of the patients were reviewed from the reports. A brief explanation of the surgical method which appealed to patients is described below.

Results

A total of 3 patients admitted to our clinic with primary infertility. Initial follow-up using hysterosalpingogram (HSG) demonstrated a suspected didelphys uterus (U3 b) which MRI and/or transvaginal high-resolution sonography confirmed the findings. Vaginal examination revealed a single cervical ostium divided by a septum (C1 V0). We classified all three patients as U3b C1 V0 according to ESHRE/ESGE classification. In order to correct the uterine texture, hysteroscopy along with laparotomy was decided for all patients. A novel technique was the same for all patients; a speculum was inserted and a cervical septum was detected. A 5Fr office hysteroscopy was inserted into both uterine cavities to define anatomic landmarks and two hysteroscopes were inserted into both uterine cavities. By a scissor, the cervical septum was resected as much as possible but we were unable to resect the whole septum. Therefore, mini-laparotomy was performed and bilateral incisions were performed to the medial surfaces of bicorporeal uterine parts. Following identification of hysteroscopes that were inserted earlier, the upper region of the cervical septum was reached and resected from cephalad to caudal plane abdominally. Afterward, medial defects of both uterine corpuses were repaired using No: 1polydioxanon 910 absorbable suture in 3 layers. Finally, a single cavity was formed along with cervix and endometrium. A month after surgery, HSG was performed and a normal uterine cavity was identified in all three patients. Spontaneous conception was offered not until the 6th month of the surgery to all since there were no additional infertility factors. At the end of the 1st year of the surgery, all three patients conceived and all were delivered at term by C-section.

Conclusions

Management of complete bicorporeal uterus with a septate cervix (U3 b C1 V0) is challenging. Without intervention, reproductive outcomes are very poor. There is no consensus of the optimal management of such cases. We defined a novel surgical technique to correct the uterine texture and successfully delivered 3 cases by using this technique without any complication.

<https://esge.covr.be/cmdocumentmanagement/conferencemanager/documents/api/getdocument/5042/cmabstms/000164810/b085c05d57c47e66a2ca4cfb723d33670f1854bef47b6b281c3f24b96c40be98>

ES28-0543 - P227

E-Poster

Fertility preservation strategies for endometriosis: how to choose

Gloria Calagna¹, Luigi Della Corte², Luigi Giampaolino², Marianna Maranto³, Mariachiara De Angelis², Antonino Perino³

¹University of Palermo, Department of Obstetrics and Gynecology- "Villa Sofia Cervello" Hospital, Partinico, Italy

²School of Medicine- University of Naples Federico II,

Departments of Public Health and Neuroscience and Reproductive and Odontostomatological Sciences, Naples, Italy

³University of Palermo, Department of Obstetrics and Gynecology- "Villa Sofia Cervello" Hospital, Palermo, Italy

Background

Endometriosis is often associated with a compromised ovarian reserve, caused by several mechanisms involved in the progressive follicular depletion. The aim of this review is to summarize the current evidences on the fertility preservation techniques for patients with severe endometriosis, focusing on advantages and disadvantages.

Methods

All original papers, published until March 2019, reporting specific experiences data on fertility preservation (FP) strategies applied to endometriosis patients, were considered for the analysis. All reports related to experimental studies conducted on in vitro or animal models were excluded from the analysis. Available strategies include well-established techniques such as oocytes cryopreservation (OOC), embryos freezing and ovarian tissue cryopreservation (OTC), although the latter is still considered experimental.

Results

Four papers were included in the review: 2 case reports, 1 case series (2 cases), 1 prospective longitudinal analysis (only one case with criteria for inclusion in the review). Only 1 article described OOC approach and 3 articles described the OTC strategy. Four patients had a surgical history: 3 cases for endometriosis and 1 case for struma ovarii associated with endometrioma. In one case, OOC was performed though 3 cycles of ovarian stimulation and successive ovarian pick-up. Regarding OTC, 4 patients underwent orthotopic reimplantation: in 2 cases it was an orthotopic reimplantation of fresh ovarian cortex. In the case of patient with history of struma ovarii, the first orthotopic reimplantation failed and a second heterotopic transplantation on abdominal wall was performed. Positive outcomes were reported in only 3 patients: 1 case of pregnancy after in vitro fertilization; 1 case of normal ovarian tissue with a follicle at laparoscopic follow-up; 1 case of endocrine function and ovulation.

Conclusions

Many conditions are related to the high risk of premature ovarian failure and severe endometriosis is certainly a strong indication for fertility preservation. In single women, OOC could be offered: it requires ovarian stimulation, but not a partner. On the other hand, OTC has the main target of pre-pubertal girls and it can be performed at any time of the menstrual cycle without ovarian stimulation, although it requires two surgical procedures. Anyway, further studies are needed to evaluate the best option for endometriosis patients concerning risks, benefits and cost- effectiveness.

<https://esge.covr.be/cmdocumentmanagement/conferencemanager/documents/api/getdocument/5010/cmabstms/000142900/11d223b716fcb1fb1494f942958dcc1d50d1e6cc8b5047713e79c330440f038d>

ES28-0544 - P228

E-Poster

Complication rates for laparoscopic myomectomy and laparoscopic-assisted myomectomy: 3 years data from a North West London University Hospital

Nisreen Fahmy¹, Carina Johnstone-Ayliffe¹, Nicolas Galazis¹, Magdy Nawar¹

¹North West London University Healthcare, Northwick Park Hospital, London, United Kingdom

Background

To investigate outcomes and complication rates over 3 years of laparoscopic myomectomies and laparoscopic-assisted myomectomy done in a high volume centre in North West London.

Methods

Data were collected retrospectively for all patients who underwent laparoscopic myomectomy (LM), and laparoscopic-assisted myomectomy (LAM) between January 2016 and December 2018. Information on conversion rates, blood loss, length of hospital stay and post-operative complications were collected.

Results

A total of 71 patients were listed for LM, of which nine (12.6%) were converted to open intra-operatively. A further three patients underwent laparoscopic-assisted myomectomy (LAM) during the study period. Average length of hospital stay was two days for LM, three days for LAM and four days for those whose surgery was converted to open. Average estimated blood loss (EBL) was 360ml for LM, and 862ml for those converted to open. Six (9.6%) patients were treated for intra-abdominal infection, and two (3%) patients had urinary retention. One patient had postoperative ileus after conversion to an open procedure, and the two patients who were treated for UTI also had open procedures. None of the LAM patients experienced post-operative complications.

Conclusions

LM has long been considered a safe and effective management option for women with fibroid disease, conveying all the advantages associated with laparoscopic surgery, such as decreased blood loss and shorter hospital stay. However, our data suggests that LAM also provides an alternative to LM with low complication rates and may be considered an alternative for women with large fibroids who would otherwise undergo open surgery.

<https://esge.covr.be/cmdocumentmanagement/conferencemanager/documents/api/getdocument/5184/cmabstms/0000145740/b5f11402fe60217498a811f1052d14262f56ea6e4de93f245d5ddd2255520a9e>

ES28-0548 - P230

E-Poster

Experience of an emergent endometriosis unit

Nuria Lopez Diu¹, Margarita Gomez del Valle¹, Juan Acosta Díez², Ricard Peiró Muntadas³, Joan Manel Xiberta Pons⁴

¹Hospital General de Catalunya, Gynaecology - Endometriosis unit, Barcelona, Spain

²Hospital General de Catalunya, Gynaecology - Hysteroscopy unit, Barcelona, Spain

³Hospital General de Catalunya, Gynae-oncology Unit, Barcelona, Spain

⁴Hospital General de Catalunya, Gynaecology, Barcelona, Spain

Background

The aim of this study is to describe how the endometriosis unit at the Hospital General de Catalunya works. This unit is led by two gynaecologists, Dr. Margarita Gómez and Dr. Núria López, who perform check-ups, ultrasound diagnosis and endometriosis-related surgery. The unit collaborates with a multidisciplinary team composed of radiologists, colorectal surgeons and the pain unit.

Methods

Although endometriosis check-ups and surgery were performed previously, the unit was formally constituted in January 2018. That year a total of 72 visits were attended whereas from January to May 2019 alone 52 patients were taken care of. We performed a retrospective study about the patients, describing symptoms, previous medical treatment received and surgical interventions. We focused our analysis on which surgeries were carried out and whether they presented any complications.

Results

Out of the total number of patients treated, 73% suffered from dysmenorrhea. Other main symptoms were pelvic pain, in 35% of the cases and dyspareunia in 1%. Some women had secondary clinic associated to the main symptom, such as dyspareunia (23%), pelvic pain (10%) or dyschezia (6%).

After proper diagnoses, the cases were classified in five groups based on the severity of their disease. We found that 66% of them had unilateral or bilateral endometriomas, 24% had deep infiltrating endometriosis, 3% had an abdominal wall nodule, 2% had extrapelvic endometriosis and only a few of them had peritoneal lesions. No endometriosis was found in a marginal proportion of patients, so they were included in the chronic pelvic pain protocol.

Only 34% of the patients had received previous surgeries. 20 patients out of those had undergone cystectomy, whereas less than 10 had more complex surgeries such as hysterectomy or intestinal nodule resection. Most of the patients had received medical treatment. Combined contraceptive pills had been prescribed to a significant 66% of the patients. Other prescriptions had been dienogest, in 8% of the cases, progesterone pills in 16%, Mirena coil in 8%, and just 1,2% had had GnRH analogues.

The unit performed a total of 22 interventions during this period. Nearly half of them were cystectomies, 3 were annexectomies, 4 were radical hysterectomies and 4 were intestinal nodule surgeries. Some of these procedures were complemented with secondary surgeries like adhesiolysis. There was a patient with a vesical nodule which was extirpated with the urologic team. All these surgeries were carried out using laparoscopic methods. We had a total of 4 surgery complications, most of them in the urinary tract.

Conclusions

The creation of this endometriosis unit allowed the hospital to broaden and specialise the services offered to endometriosis patients by way of increasing awareness and collaboration with colleagues, which directed to use more patients than ever, as well as accumulating data for analysis and improvement of diagnosis and treatments.

<https://esge.covr.be/cmdocumentmanagement/conferencemanager/documents/api/getdocument/5148/cmabstsms/0000166680/d1a9622fa171a6af5b7acd17c1d6f6ad76c4cbec6ee708e25d873ce76b93e16c>

ES28-0549 - P231

E-Poster

Using raman spectroscopy to investigate endometriosis molecular structure

Taner Usta¹, Salih Yilmaz¹, Gozde Yilmaz², Aysen Oze¹, Sefa Celik², Sevim Akyuz³

¹Mehmet Ali Aydinlar University- Acibadem Altunizade Hospital, Gynecology and Obstetrics, Istanbul, Turkey

²Istanbul University- Faculty of Physics, Physics, Istanbul, Turkey

³Istanbul Culture University, Physics, Istanbul, Turkey

Background

Raman spectroscopy is a light scattering technique. It is based on the measurement of the inelastic scattered laser radiation by molecules. The laser light interacts with molecular vibrations in the system, resulting in the energy of the laser photons being shifted up or down. Endometriosis is a chronic disease which has to be diagnosed by histological examination. To determine the severity of the disease, the most commonly used, revised American Society of Reproductive Medicine (rASRM) classification can be used. In this study, Raman spectra of endometriosis tissues were taken and the changes in molecular level were examined comparatively and interpreted depending on the progress of the disease.

Methods

This study was based on spectroscopic examination of tissue samples taken from endometriotic cyst walls of 12 patients who were operated for endometriosis. After the cyst wall was removed from the abdomen, the cyst surface was cut from six different points and tissue samples were taken. Each sample was then placed in a separate tube and transported to a laboratory, in a container filled with liquid nitrogen to be measured with Raman spectroscopy. The 3 or 4 spectrum were recorded from different parts of the each tissue sample with Raman spectroscopy. The Principle Component Analysis (PCA) followed by Linear Discriminant Analysis (LDA), performed on Raman data.

Results

By following the evolution of the fluorescence intensity, samples were divided into 3 groups. The low fluorescent emission samples were in the first group, the middle fluorescent backgrounds were in the second group and the ones with high fluorescence were classified in the third group. All samples in the first group, ie samples with the lowest fluorescence background, had nodules, whereas, all samples in the third group (ie samples with the highest fluorescence background) were found to have no nodules. Three amino acids that are primarily responsible for the inherent fluorescence of proteins are tryptophan, tyrosine and phenylalanine. However, tryptophan is significantly more fluorescent than tyrosine and phenylalanine.

Conclusions

Raman spectral results are found to be mostly in consistent to surgeon scores. The patients with low rASRM scores, are grouped into 1 (group 1-weak endometriosis) by multivariate statistical analysis performed on Raman spectral

findings. The increase of pyrrole intermediates may show the possibility of cancer development in the long term follow-up of these patients. In our study, pathology result of only one patient was reported as borderline seromucinous cystadenoma. For this patient, the amount of pyrrole was found to be significantly higher than the other patients; the relative pyrrole density ratio is five times higher than the lowest patient. Raman spectroscopy coupled with the PCA-LDA statistical analysis showed great potential for a sensitive diagnostic alternative for identifying pathologic changes in endometriosis tissues.

<https://esge.covr.be/cmdocumentmanagement/conferencemanager/documents/api/getdocument/5292/cmabstsms/000121620/b1bb1a44b7954f1d74a93788baf8d069c08772d7dff1f7d8167523affacb41a5>

ES28-0559 - P234
E-Poster

Study of the relationship between the severity of preoperative anxiety and pain in office hysteroscopy

Igor Klyucharov¹, Ivan Kiassov², Kausar Yakhin³

¹Institute of Fundamental Medicine and Biology of Kazan Federal University, Department of Fundamentals of Clinical Medicine, Kazan, Russia

²Institute of Fundamental Medicine and Biology of Kazan Federal University, Department of Bioecology- Hygiene and Public Health, Kazan, Russia

³Kazan State Medical University, Department of Psychiatry, Kazan, Russia

Background

To study the relationship of preoperative anxiety with the intensity of pain during office hysteroscopy (OH).

Methods

The level of anxiety was studied in 138 patients before (OH) using State-Trait Anxiety Index (STAI), Sheehan Patient-Rated Anxiety Scale (SPRAS) and Yakhin – Mendelevich questionnaires. On the visual analogue scale (VAS), the level of pain of one's menses was assessed, after OH - the painful sensations at the diagnostic and operational stages. Statistical data processing was performed using IBM SPSS Statistics 22, Wilcoxon, Kruskal-Wallis criteria; Mann-Whitney, Kolmogorov-Smirnov and Spearman correlations.

Results

By STAI 79.1% of patients were in a state of moderate and high levels of situational anxiety, 81.9% of patients were in a state of moderate and high levels of personal anxiety, 16.4% had clinically significant anxiety. By SPRAS no patients rated anxiety as severe, 16,4% rated anxiety as moderate, 83,6% rated anxiety as light to absent. By Yakhin-Mendelevich test. The pre-disease character of neurotic disorders was within 10.4% - 20.9%, and the painful nature of neurotic disorders within 7.5% - 17.2%. A direct statistically significant correlation was observed between various anxiety states, the assessment of pain during menstruation and the level of pain during surgery.

Conclusions

It is necessary to rate the anxiety level and pain level during menstruation and during (OH). The level of anxiety, as assessed before hysteroscopy, is significant and it correlates with the level of pain during menstruation and surgery. The obtained data allow to predict the level of pain before (OH).

<https://esge.covr.be/cmdocumentmanagement/conferencemanager/documents/api/getdocument/5206/cmabstsms/000056160/0dae1cadd69b2545f479c2ec9fb5b2cd8ba349c1a207326219d7f22f4cb8d18b>

ES28-0562 - P235

E-Poster

The current status of diagnosis and treatment of female lower genital tract malformations in China

Lan Zhu¹, Na Chen¹

¹Peking Union Medical College Hospital, Department of Obstetrics and Gynecology, Beijing, China

Background

Female lower genital tract malformations are reproductive system defects caused by arrested or abnormal development of Müllerian duct (MD) and urogenital sinus in the embryonic period. Due to its rarity, the diagnosis and treatment of female lower genital malformations are still ambiguous. Also, except for WNT4 mutations that are thus far known to be causal for a clinically distinct subtype of Mayer-Rokitansky-Kuster-Hauser (MRKH) syndrome, the genetic etiology of disrupted MD development has not been reported clearly yet.

Methods

With the support of Chinese National funds, a national multi-centre network led by the Department of Obstetrics and Gynecology of Peking Union Medical College Hospital was established since April, 2012. 12 experienced tertiary medical centers are included in the network. Phenotype information and peripheral blood DNA sample of patients with malformations including MRKH, Herlyn-Werner-Wunderlich syndrome (HWWS), and vaginal atresia are recruited from these 12 centres using Bio-lims system.

Results

1. Chinese specialists proposed new clinical classification systems for HWWS and congenital vaginal atresia, which further prevent the ambiguous diagnoses or inappropriate treatments of these disorders. 2. We set up a series of new surgical techniques for correction of female lower genital tract malformations, including two laparoscopic peritoneal vaginoplasty techniques and vaginoplasty using tissue-engineered biomaterial graft. New minimally invasive and effective surgeries offer more options for clinical practice. 3. We promote the application of reservation of fertility surgery in patients with HWWS and congenital cervical dysplasia. 4. We have established a large multi-centre female lower genital tract malformation cohort, with complete phenotype information and peripheral blood DNA sample bank. Currently, 1555 sporadic patients, including 220 core families are included in our cohort. 5. Based on the cohort established, we performed exome sequencing on 442 MRKH patients, and analyzed the mutational burden of 19 candidate genes versus 952 control samples.

Conclusions

Our work promoted the diagnosis and treatment guidelines of female lower genital tract malformations in China. Also our work underlined the critical role of genes required for MD/WD development in the pathogenesis of MRKH syndrome.

ES28-0563 - P236

E-Poster

Evaluation of the cases of hysteroscopic myomectomy for type 2 myomas less than 4 cm in diameter

Suleyman Guven¹, Emine Seda Guvendag Guven², Hidayet SaP

¹Private Practice, Obstetrics and Gynecology, Trabzon, Turkey

²Karadeniz Technical University- Faculty of Medicine, Obstetrics and Gynecology, Trabzon, Turkey

Background

Determining the complications of the 1 step hysteroscopic myomectomy surgery of the single type 2 myomas that were less than 4 cm in diameter.

Methods

Records of 52 myomectomies were evaluated retrospectively In Karadeniz Technical University School of Medicine, Department of Obstetrics and Gynecology between 2016 and 2018 performed by single operator. Ten of the cases fulfilled the criteria included in the study.

Results

The mean age, gravida and parity were 40.87 ± 4.61 , 2.12 ± 1.25 and 1.5 ± 0.93 , respectively. The main symptom on admission was abnormal uterine bleeding in all cases. The median operation time was 22 minutes. One of ten patients

had hyponatremia and there was not any other complication after surgery. Pathologic analysis revealed myoma in all cases. No recurrent myoma cases were observed during two years of follow-up period.

Conclusions

Hysteroscopic myomectomy 1 step approach is a safe choice of treatment for type 2 myomas that are less than 4 cm.

<https://esge.covr.be/cmdocumentmanagement/conferencemanager/documents/api/getdocument/4984/cmabstms/000166530/ffba5ea86a50d97b5c3fe460b538341421eb144b02cc418eb2503824ccbf941a>

ES28-0565 - P237

E-Poster

Laparoscopic cystectomy for 20cm dermoid cyst: how we did it - tricks and tips!

Laura Beatty¹, Fiona Learmonth¹, Lorna Murray¹, Mohamed Allam¹

¹NHS Lanarkshire, Gynaecology, Glasgow, United Kingdom

Background

32 year old primiparous presented with 4 month history of bloating, abdominal distension and shortness of breath. On clinical examination, elevated BMI 38, large pelvic mass 34 week size filling abdomen and extending to left hypochondrium. Ultrasound scan confirmed the presence of a left sided dermoid cyst measuring 20 x 19 x 12cm.

Methods

Following clinical work up and review of published literature, decision to perform diagnostic laparoscopy and proceed for laparoscopic cystectomy of large dermoid cyst by an experienced laparoscopic surgeon.

Results

Uncomplicated procedure. Palmers point entry into abdomen, revealing large 34 week size dermoid cyst extending to left upper quadrant. Umbilical and lateral ports sited under vision. Dermoid cyst gently punctured with 12mm umbilical port and secured in place following inflation of port balloon. Cyst contents removed using irrigation and suction technique, draining 2 litre of sebaceous material. Following aspiration, cyst capsule secured using extra corporeal knot around capsule neck. 15mm endocatch sited and cyst capsule placed within intact. Specimen removed via 2cm extended sub umbilical incision. Nil spill of cyst contents throughout the procedure. Uncomplicated procedure and post operative recovery. Patient discharged home day 1 post operatively.

Conclusions

Following our initial experience of laparoscopic cystectomy for large dermoid cyst we intend to use this technique in future within our unit. With the knowledge gained from this experience and technique, however adapting to the use of warm saline irrigation to enhance aspiration technique. Our experience shows that laparoscopic cystectomy may be performed for large dermoid cysts, avoiding the need for major abdominal surgery, reducing both intra operative and post operative complications and allowing for enhanced recovery post operatively. Our technique allows for uncomplicated cystectomy to be performed for a large dermoid cyst with nil spill of cyst contents, eliminating the risk of chemical peritonitis.

<https://esge.covr.be/cmdocumentmanagement/conferencemanager/documents/api/getdocument/5168/cmabstms/000150510/7ed8ed0c2b00dce53c448fe2c52e397db71daa9a3aeb4911fdb6dea5d3eca8e7>

ES28-0570 - P238
E-Poster

Retrospective study of concordance between hysterosalpingography and hysteroscopy for uterine cavity evaluation for assessment of infertility in women

Emine Seda Guvendag Guven¹, Suleyman Guven², Hidayet Sal¹

¹*Faculty of Medicine- Karadeniz Technical University, Obstetrics and Gynecology, Trabzon, Turkey*

²*Private practice, Obstetrics and Gynecology, Trabzon, Turkey*

Background

The aim of the study was the accuracy of hysterosalpingography for evaluation of the uterine cavity

Methods

Records of 55 cases subjected to hysterosalpingography (HSG) and office hysteroscopy (HS) were evaluated retrospectively In Karadeniz Technical University School of Medicine, Department of Obstetrics and Gynecology between 2016 and 2018 performed by two operators. All couples had the history of primary infertility. Infertility work-up results including spermogram, hormonal evaluation and ovulation were all within normal limits. HSG and HS findings were compared with each other

Results

HSG results were normal (70.9%), endometrial polip (9.1%), minimal/moderate uterine septum (9.1%), submucous myoma (3.6%), arkuate uterus (5.5%) and T-shaped uterine cavity (1.8%). Hysteroscopy findings were normal (30.9%), endometrial polyp (25.5%), minimal/moderate uterine septum (30.9%), submucous myoma (3.6%), minimal uterine synesia (5.5%), isthmocele (1.8%) and T-shaped uterine cavity (1.8%). The concordance rates of HSG and hysteroscopy was 63.6%. The diagnosis of endometrial polyp, uterine septum, minimal uterine synesia and isthmocele was highly missed by HSG compared with hysteroscopy.

Conclusions

Hysteroscopy is the gold standard for uterine cavity evaluation and the diagnosis of endometrial polyp, uterine septum, minimal uterine synesia and isthmocele may be correctly done by HS compared with HSG.

<https://esge.covr.be/cmdocumentmanagement/conferencemanager/documents/api/getdocument/4985/cmabstsms/000166540/c4c5d8a5900bda430d4c515cfdc1c77b94f2113011cd1843d8f33933d655f0d1>

ES28-0572 - P239
E-Poster

Severe bleeding during the removal of the large myoma in the left parametrium tissue

Gediminas Mecejus¹, Eglė Baužytė¹

¹*Vilnius City Clinical Hospital, Gynecological, Vilnius, Lithuania*

Background

We present a case report of the removal of the large myoma of the uterus in the left parametrium tissue laparoscopically.

Methods

40 years old patient suffered from distention in the lower part of the abdomen, dysuria and difficulties in defecation. Gynecological and ultrasound examination showed a large myoma of 18 cm diameter in the lower part of pelvis. Uterus was dislocated to the right middle part of the abdomen. Decision – to remove the myoma laparoscopically with the uterus preservation.

Results

Laparoscopy was performed. We found the large myoma about 18 cm diameter. It occupied the whole small pelvis. Uterus body was raised from the pelvis and pushed to the right middle part of abdominal cavity. Incision was made just above the urine bladder and the myoma was dissected from parametrial tissue. Myoma was removed using the

traction. Coagulation of the parametrium tissue was performed. At the end of separation severe bleeding occur. Myoma was removed and pushed to the upper part of the abdominal cavity. Bleeding continued, but it was impossible to find the vessel. The round uterus ligament in the left side was cut off, the damaged vessel was found and coagulated. Bleeding stopped. Myoma was removed using morcellator, the myoma weight – 1400 g. Blood loss was 4000 ml, duration of the surgery – 360 minutes, the time of morcelation – 90 minutes.

Conclusions

The removal of the large myomas from parametrial tissues may cause severe bleeding due to additional vessels. The appropriate preparation and good surgery skills are required to achieve the success and to the perform surgery safely.

<https://esge.covr.be/cmdocumentmanagement/conferencemanager/documents/api/getdocument/5147/cmabstms/000073230/e1fe61f7957d68a5309b0ed4ecc13667926b74d1e53299fa4a14a64d8e81a95e>

ES28-0574 - P240

E-Poster

Transvaginal ultrasound features of intraligamental myomas

Marco Ambrosio¹, Ilaria Giaquinto¹, Luca Savelli¹, Diego Raimondo¹, Paolo Salucci¹, Renato Seracchioli¹

¹Sant'Orsola Hospital, University of Bologna- Gynaecology and Human Reproduction Physiopathology, Bologna, Italy

Background

The aim of this study is to describe the preoperative sonographic characteristics of intraligamental myomas (IM) using morphological uterus sonographic assessment (MUSA) group standardized terms and definitions.

Methods

This is a retrospective monocentric study. One hundred and twenty-five women with a pre-operative sonographic diagnosis of a myoma located close to the uterine isthmus or cervix from 2012 to 2019, who underwent laparoscopic myomectomy or hysterectomy, were included for study analyses. Nineteen women with a surgical confirmation of IM were included in group 1; the remaining population constituted the control group (n=106). The sonographic data were retrieved retrospectively from ultrasound reports and stored images, by one author. Sonographic features of our tumors were described according to MUSA nomenclatures. Clinical data were retrieved from patients' record.

Results

19 women with IM (group 1) and 106 women with low and lateral subserous or pedunculated myoma (control group) were identified. Median age was 46 ± 11.9 and 45.1 ± 9.1 ($p 0.386$) respectively. The presence of shadowing was detected in 12/19 (63%) women with IM, compared to 94/106 (89%) women in the control group ($p 0.004$). IM showed only internal shadows (12/12, 100%) compared to the control group (8/86, 9%). Heterogeneous echogenicity was detected in 17/19 (89%) of IM compared to 26/106 (25%) women in the control group ($p < 0.001$). IM were more vascularized mass related to low-lateral subserous or pedunculated myomas ($p 0.004$). Mean diameter of IM was 63 ± 22 mm. The position was low in the pelvis, close to the uterine isthmus or cervix in all cases. Transvaginal ultrasound demonstrated high specificity for the diagnosis of IM (0.93, CI 0,871-0.969).

Conclusions

On ultrasound, IM appear as solid tumor with heterogeneous echogenicity, oval shape and usually without shadowing or with internal shadows, adjacent to the uterine cervix or isthmus. Due to their position and their ultrasound features sonographers could be able to perform an accurate diagnosis of this specific type of myoma allowing to plan a correct surgery and avoid severe complications.

<https://esge.covr.be/cmdocumentmanagement/conferencemanager/documents/api/getdocument/5031/cmabstms/000166920/b73f5bcbf35a80fb11b292363bb49d0096185e703cf3ed280a2442ff922e0a>

ES28-0583 - P241

E-Poster

Open myomectomy - not that scary! A cohort study demonstrating the safety of open myomectomy for multi-fibroid uteri from a tertiary centre

Fusun Sirkeci¹, Isaac Manyonda²

¹Senior Registrar in Obstetrics and Gynaecology, Whipps Cross University Hospital- Barts Health NHS Trust, London, United Kingdom

²St George's NHS Foundation Trust- London, Obstetrics and Gynaecology, London, United Kingdom

Background

To demonstrate the safety and present the clinical outcomes following open myomectomy in women with symptomatic uterine fibroids who wish to retain their uterus.

Methods

Prospective hospital-based observational study conducted between October 2013 and April 2015. Our group performed 106 open myomectomy procedures including repeat surgery.

Results

Mean age for the patients was 40.5 years. 76% of the patients were of Afro-Caribbean ethnicity. Mean uterine size was 17.98 (SD 4.64) weeks size on examination, and scan assessed volume was 869.15 (SD86.48) cm³. Largest fibroid size was 627.465(816.1) cm³. 58.5% of all our cohort had more than 10 fibroids. About 17% of our cases had repeat myomectomy. The average blood loss during myomectomy procedures was 647.647 millilitres (mls) (SD: 495.5947). All of the cases had lower transverse suprapubic incision. 18.9% of all patients required a blood transfusion. Mean hospital stay was 4.8 days. We did not have any event requiring a hysterectomy.

Conclusions

In carefully selected and counselled patients under expertise care, the surgical risks for open myomectomy for large uteri are low. We feel that these observations support the concept of "fibroid centres" that are needed to care for the women with symptomatic uterine fibroids.

ES28-0588 - P242

E-Poster

Transvaginal scanning with a linear lateral array for the pre-operative assessment of rectovaginal endometriosis

Anthony Griffiths¹, Liz Bruen¹, Richard Penketh¹, Lutfi Shamsuddin¹, Angharad Jones¹, Caryl Thomas¹

¹University Hospital of Wales, Gynaecology, Cardiff, United Kingdom

Background

Rectovaginal endometriosis is a severe form of pelvic endometriosis in which pharmacological treatment is relatively ineffective. Laparoscopic surgical treatment is effective, but has the potential risks of bowel perforation and colostomy formation. Previously we have found transrectal USS to be highly accurate in assessing the depth and extent of disease. Using a transvaginal lateral array has the convenience of being less invasive to the patient, more familiar to gynaecologists and can be carried out in gynaecology outpatients.

Methods

Symptomatic patients with potentially extensive endometriosis were assessed with a high frequency lateral array probe via a vaginal approach. The extent of the disease was assessed and compared to a subsequent transrectal and surgical outcome. Positive and negative likelihood ratios were generated with confidence intervals.

Results

Provisional results confirm that transvaginal linear array is an accurate method to assess the extent and depth of disease involvement

Conclusions

The preoperative prediction of rectal wall endometriosis enables more accurate planning and allocation of operating theatre time that would be a sensible use of resources. It allows similar results with a greater patient satisfaction.

<https://esge.covr.be/cmdocumentmanagement/conferencemanager/documents/api/getdocument/5259/cmabstms/00166930/7698cba00b03c4b3e5a36803c6dc29f44519755fc6fdb4f4b6d279249d7843dd>

ES28-0589 - P243

E-Poster

Pelvic floor outcomes following uterus preserving treatments for uterine fibroids: an observational study

Fusun Sirkeci¹, Isaac Manyonda², Stergios Doumouchtsis³, Raj Das⁴

¹Senior Registrar in Obstetrics and Gynaecology, Whipps Cross University Hospital- Barts Health NHS Trust, London, United Kingdom

²St Georges NHS Foundation Trust, Obstetrics and Gynaecology, London, United Kingdom

³Epsom and St Helier's University Hospitals NHS Trust- London, Obstetrics and Gynaecology, London, United Kingdom

⁴St George's NHS Foundation Trust- London, Interventional Radiology, London, United Kingdom

Background

To assess the fibroid related symptoms, quality of life and associated pelvic floor functions (urinary, bowel and sexual) following UAE and open myomectomy using specific symptom related questionnaires on women with symptomatic uterine fibroids who wish to retain their uterus.

Methods

Prospective hospital-based observational study conducted between October 2013 and April 2015. Eligible premenopausal adult women with symptomatic uterine fibroids who underwent UAE or myomectomy (n=163) were asked to complete study questionnaires at baseline and then at 6 months and 12 months following their treatments. Fibroid related quality of life and pelvic floor function were assessed by using validated questionnaires namely UFS-QoL, KHQ, FSFI and ICIQ-B.

Results

Fibroid related QoL and pelvic floor functions improved by 6 months and reached a plateau at 12 months. The hospital stay (p: 0.0001) and complications were significantly less following UAE.

Conclusions

In comparison to myomectomy, UAE had similar symptomatic relief and improvement in the quality of life with fewer complications and shorter hospital stay.

ES28-0592 - P244

E-Poster

Vulvar lesion in perimenopausal woman: an atypical localization of endometriosis

Giorgia Monti¹, Francesco Martire², Chiara Barbanti¹, Gabriele Centini¹, Lucia Lazzeri¹, Errico Zupi¹

¹Obstetrics and Gynecology- University of Siena, Department of Molecular and Developmental Medicine, Siena, Italy

²Obstetrics and Gynaecological Unit- Univeristy of Rome "Tor Vergata", Department of Biomedicine and Prevention, Rome, Italy

Background

To describe a case of a vulvar lesion in a perimenopausal woman surgically approached.

Methods

A case report carried out in the "Santa Maria alle Scotte" University Hospital, Department of Molecular and Developmental Medicine, Obstetrics and Gynaecological Unit.

Results

Patient aged 46 years came to the gynaecological emergency department complaining the appearance of a right painful vulvar swelling during her menstrual period. The patient reported dysmenorrhoea 10/10 using the 10-point Visual Analogue Scale, heavy menstrual bleeding, previous unexplained infertility and a prior history of inguinal tuberculosis medically treated in 2015.

The gynaecological inspection was unremarkable except for a tense lesion of about 3.5 cm within the inferior portion of the right labia majora. It was extremely painful on palpation with a hard and elastic consistency. The overlying skin was reddened without warmth. At translabial ultrasonography a mass with ground glass echogenicity and regular margins, scarcely vascularized, measured in length 39 mm, in height 34 mm and in width 38 mm was detected. Uterus and ovaries appeared normal at the transvaginal ultrasound evaluation. The patient was given antibiotics and painkillers. After 6 days, the clinical and ultrasound features were unchanged and, with the consent of the patient, it was decided to perform a surgery in order to remove the lesion.

Under spinal anaesthesia, with patient in gynaecological position and a urethral Foley's catheter in situ, a longitudinal incision was made at the medial face of the minora right labia and the skin flaps were reflected. The lesion was exposed by blunt dissection on all sides and entirely excised, it was sent for histopathological examination. The resultant defect in the right vulvar region was repaired in two layers.

Cut section of the lesion showed uniloculated cyst with chocolate fluid content. The histological diagnosis refers to glandular endometriosis.

Postoperative recovery was fast and the day after surgery the patient was discharge.

Conclusions

Considering the extremely widespread localization of endometriotic disease, in the presence of typical findings such as dysmenorrhoea, infertility, ultrasound features, and in this case the appearance of painful lesion at the time of menstruation, even if it seems unlikely endometriosis should be suspected and take into account for a differential diagnosis.

<https://esge.covr.be/cmdocumentmanagement/conferencemanager/documents/api/getdocument/5269/cmabstsms/000166940/593a78b73c635b8229e42474d8e8c739a0d1385f34f17d97a2f57bcc7c5d9065>

ES28-0597 - P246

E-Poster

Case report: retroperitoneal teratoma

Florence Hanocq¹, Francois Closor², Nisolle Michelle²

¹University Department of Gynecology, University Gynecology Liege, Liège, Belgium

²University Department of Gynecology, Gynecology, Liège, Belgium

Background

Ovarian dermoid cysts are common and constitute 20% of ovarian tumors in adults. However, other localizations are described such as in the retroperitoneum, the pelvis, the mediastinum, in the cranium and in the sacrococcygeal space. The aim of this report is to describe a case of retroperitoneal cyst.

Methods

A 32 years old woman presented to gynecological emergency room for intense acute pelvic pain, irradiating towards the lumbar and lower right limb. She also complained of deep dyspareunia. The patient was afebrile and had no other symptoms. On gynecological examination, uterine mobilization was painful. A mass was palpated on the right hand side of the Douglas pouch. Endovaginal ultrasound demonstrated a heterogeneous mass of 71.5mm X 69mm presumably on the right adnexa.

Results

Laparoscopic surgery was decided and allowed the diagnosis of a right para-rectal retroperitoneal mass. Both adnexas were normal. After careful dissection of the retroperitoneal spaces and a right ureterolysis, a cystectomy was performed. Pathological analysis confirmed a mature teratoma.

Conclusions

Teratomas of the retroperitoneum are rare and can remain asymptomatic for a long time. They are generally treated with complete surgical resection as primary therapy. Pelvic and retroperitoneal surgeries can be complicated by ureteral, vascular, nerve wounds and cyst rupture (that may lead to chemical peritonitis). A careful differential diagnosis of the retroperitoneal mass and a good knowledge of retroperitoneal anatomy are mandatory before any surgery.

<https://esge.covr.be/cmdocumentmanagement/conferencemanager/documents/api/getdocument/5144/cmabstms/000166510/0c3d0c1de9a0e50ef48e8b66004b8b7094f91422212d5c28a23f9d1f9914a7bc>

ES28-0601 - P247

E-Poster

Single port access laparoscopy treatment of an embryonated ovarian pregnancy: a case report

Gianmarco Rossini¹, Roberto Angioli¹, Margherita Russo², Francesca Dessolis², Francesco Multinu³, Stefano Angion²

¹*Campus Bio Medico University of Rome, Obstetrics and Gynaecology, Rome, Italy*

²*University of Cagliari, Surgical Science, Cagliari, Italy*

³*European Institute of Oncology IRCSS, Gynecology, Milan, Italy*

Background

Ovarian pregnancy (OP) is an extremely rare form of ectopic pregnancy. Transvaginal pelvic ultrasound is the first method to assess an OP, but sometimes preoperative analysis is difficult and diagnostic laparoscopy is needed to confirm the diagnosis. Although OP can even be managed medically in many cases, minimally invasive surgery (MIS) is the gold standard for management. We present a case-report of an embryonated right OP successfully treated by single port access laparoscopy (SPAL).

Methods

We present case of 26-years-old woman second gravida primipara at 9 weeks of amenorrhea with a right OP treated by SPAL.

Results

The patient presented to the emergency department of our institution complaining of an increasing right lower abdominal pain. Her general condition was good and her vital signs were normal. She felt tenderness at abdominal examination. Transvaginal ultrasonography showed an ectopic gestational sac with yolk sac and embryonic pole with a crown rump length (CRL) of 9.3 mm with regular heart rate in the right adnexa and presence of anechoic free-fluid in the pouch of Douglas. Her preoperative hemoglobin was 14 mg/dl. SPAL was performed and evidenced the ectopic pregnancy in the right ovary. The patient underwent right salpingo-oophorectomy as the anatomy of the enlarged ovary was completely distorted by the presence of large vessels. The patient had an uneventful postoperative period and was discharged without complications two days after surgery with a human chorionic gonadotropin (hCG) of 3834 mIU/ml and hemoglobin of 12 mg/dl. Her blood hCG was followed in outpatient setting until it returned to normal range.

Conclusions

Although OP is a rare condition, it should be kept in mind as a rare possibility in women of reproductive age presenting with acute abdomen and lack of treatment may leads to poor prognosis. Preoperative diagnosis of OP is often challenging and often certain diagnosis can be made only intraoperatively. Surgery remains the gold standard in management of OP, especially MIS despite the progress in medical treatment. Our study showed that SPAL could be a valid alternative with a successful outcome to laparoscopic standard in treatment of OP. However, further studies are needed to confirm this conclusion.

<https://esge.covr.be/cmdocumentmanagement/conferencemanager/documents/api/getdocument/5201/cmabstms/000166760/66c6dd7380184ae15e9a268bc937c240b2647f5302e7bec01c9417974a6acca0>

Laparoscopic resection of diaphragmatic endometriosis: a case report

Panagiotis Sklavounos¹, Nikolaos Drandakis¹, Ioan-Iulian Iordache¹, Erich-Franz Solomayer¹

¹Saarland University Hospital- Homburg- Germany,

Department of Gynecology- Obstetrics and Reproductive Medicine, Homburg, Germany

Background

Endometriosis is common in approximately 10% of women during their child bearing age. The etiopathogenesis of this disease is not well understood. Diaphragmatic endometriosis is extremely rare. An estimated 0.6 to 1.5 percent of those who undergo surgery for endometriosis have this form and may cause upper abdominal pain on the right side, pain under the lower ribs, painful breathing, and sometimes nausea or vomiting.

Methods

We present a case of diaphragmatic endometriosis associated with pelvic endometriosis in a 22-year-old female patient with chronic pelvic pain and dysmenorrhea with a high score as also shoulder pain before and during the Menstruation. Pain was evaluated using a visual analogue scale (VAS). The woman reported mild moderate cyclic pelvic pain (VAS score = 6), and refractory severe right upper-abdominal and right shoulder pain (VAS score = 8). A magnetic resonance imaging (MRI) was performed to control the presence of endometriosis in the diaphragm, while the results showed normal upper abdominal organs, including liver, spleen, pancreas, kidneys, adrenal, as well as the lungs and no presence of endometriosis.

Results

Operative findings showed multiple diaphragmatic lesions as also multiple lesions in uterovesical Peritoneum, in left pelvic wall and in Pouch of Douglas . Diaphragmatic implants were distributed on the right side. There were 5 to 6 areas of superficial endometriosis in the anterior and center of the right hemi-diaphragm We performed a complete excision of the nodules, whereas only the half of the entire thickness of the diaphragm were involved. Thus the diaphragmatic lesions were removed completely without opening the pleural cavity and provoking a pneumothorax The postoperative evolution was satisfactory, and the patient left the hospital on the third postoperative day. No complications occurred. At 1 month and 3 and 6 months after surgery a pelvic examination was performed and a simple questionnaire was administered to determine her well-being and whether there were any complications. After 4 weeks and 16 weeks the young woman reported low cyclic pelvic pain (VAS score = 1), and no right upper-abdominal or right shoulder pain (VAS score = 0).

Conclusions

This case report underlines the importance of surgical expertise for the treatment of severe endometriosis. Diaphragmatic endometriosis should be included in the therapy concept of endometriosis. Laparoscopic resection of this form of endometriosis has been shown to be feasible and cost-effective; however, it should be managed in a referral center, by an expert laparoscopic gynecologist with knowledge of oncological surgical techniques, with the support of a trained anesthesiologist in order to avoid complications and to perform a safe but complete resection of the disease with optimal relief of symptoms..

<https://esge.covr.be/cmdocumentmanagement/conferencemanager/documents/api/getdocument/5294/cmabstsms/000015740/e9fa7f511a1efa20ff0f6f6ff4b741b367f87b11845df5f0a3bf7a6104a33796>

The prevalence of uterine septum among Omani women and reproductive outcome after hysteroscopic resection

Maha Al-Khaduri¹, Mohamed Al Siyabi¹, Al Farsi Yahya²

¹College of Medicine and Health Sciences- Sultan Qaboos University, Obstetrics and Gynecology, Muscat, Sultanate of Oman

²College of Medicine and Health Sciences- Sultan Qaboos University, Family Medicine and Public Health, Muscat, Sultanate of Oman

Background

Uterine septum is a Mullerian anomaly that affects 0.1-1.5% of the population and it has a significant association with miscarriage however there is little evidence to support that there is a connection with infertility. The gold standard for the investigation of the uterine septum is hysteroscopy. Among all Mullerian duct anomalies, the septate uterus is the only one that can be managed and corrected by hysteroscopic surgery. Many studies showed that hysteroscopic resection of uterine septum improved the pregnancy rate. Therefore, the main aim of this study is to estimate the prevalence of uterine septum and outcome after hysteroscopic resection, among Omani women with infertility and recurrent miscarriage.

Methods

This was a retrospective observational study. We included Omani females between the age of 15 and 50 years old who were attending the infertility clinic at a tertiary referral teaching hospital (SQUH) during the period of (1/1/2008-31/12/2018). The patients' data was collected from electronic records. The prevalence of septate uterus as well as the outcome after hysteroscopic resection like pregnancy rate, miscarriage rate and live birth rate were analyzed.

Results

Out of 3106 patients who visited the infertility clinic at SQUH over the ten-year period, and 1958 patients who had hysteroscopy, only 25 women were diagnosed with uterine septum and met the criteria of the study, with a prevalence of 0.8% and 1.2% respectively. The median age of patients was 36 ± 8 years. The most effective diagnosing method was hysteroscopy with a prevalence of 68%. Patients were diagnosed as primary infertility in 28%, secondary infertility 16%, or recurrent miscarriage 52%. The classification of the uterine septum was 40% (n=6) had a complete septum and 60% (n=19) as a partial septum. The associated gynecologic pathologies found were adenomyosis or endometriosis in 24% (n=6) and Polycystic ovarian syndrome in 40% (n=10). Fifty six percent of patients had a normal uterine cavity, 12% had intrauterine adhesions and 28% had residual septum on a second look hysteroscopy. The pregnancy rate after the septum incision was found to be 44% (40% conceived spontaneously) with a live birth rate of 72.8% and 27% first trimester miscarriage rate.

Conclusions

Hysteroscopy is the commonest method of diagnosis of uterine septum at our institution. Findings suggest that second look hysteroscopy should be routinely performed after resection. Hysteroscopic uterine septum resection improved the pregnancy and live birth rate.

<https://esge.covr.be/cmdocumentmanagement/conferencemanager/documents/api/getdocument/5239/cmabstms/000074870/a8470c0e8328a7d4375456763e7311659bb60aaf1bdaf039ef5b00c8561f0f1f>

ES28-0606 - P250
E-Poster

Advances in laparoscopic hysterectomy in Cardiff and Vale UHB - a 10 year review and comparison with English averages

Ceridwen Hayles¹

¹Registrar, University Hospital of Wales, Cardiff, United Kingdom

Background

Laparoscopic, and other minimally invasive methods, are considered the gold standard in hysterectomy for benign gynaecology. No formal process of collecting data on hysterectomy rates exists in Wales so it is not possible for units to assess how they compare to national averages. In England, this data is reported, so we wanted to see how rates in our health board in Wales compared to the English averages.

Methods

Data from the Theatreman operating system was analysed for a 10 year period to assess number of hysterectomies, route of access, conversion rates and procedure lengths. This was done for benign gynaecology and gynaecological oncology. Length of stay was obtained from the hospital portal. The benign and oncology data was compared to see where changes had been most significant and where lessons could be transferred within the unit. Our data was compared to English data, for the years where it had been published.

Results

The number of hysterectomies for benign gynaecological complaints has fallen year on year since 2008. The rate of laparoscopic and lap-assisted vaginal hysterectomies has risen, whilst the rate of open and vaginal cases has fallen. When compared to hysterectomies for gynaecological cancers, the rate of change is far slower and less significant. Conversion rates have not changed over the period analysed. Procedure lengths have increased for all approaches, except laparoscopic, where the average procedure length has fallen by 30 minutes. Open rates were lower than the average for English trusts, but laparoscopic rates were also lower. Length of stay is significantly lower for laparoscopic and vaginal approaches than for open approaches.

Conclusions

This health board in Wales is offering patients a service that is equivalent, if not better, than the national average for England. The decreasing number of hysterectomies performed highlights the shift towards alternative treatments for benign gynaecological conditions. The decreasing procedure length for laparoscopic approach compared to all other approaches likely represents increased technical competence and training in the laparoscopic approach whilst the complexity of cases has increased overall. Although the percentage of procedures performed with an open approach is lower than in England, there are still more hysterectomies being performed this way than laparoscopically. Lessons can be learned from the oncology team in the unit who have demonstrated a more significant change in practice over the same period of time. The health board is looking to introduce an MDT meeting to review all proposed open hysterectomies for benign conditions to assess whether this is the most appropriate approach, with the hope that an increasing number of patients will be offered minimally invasive surgery.

<https://esge.covr.be/cmdocumentmanagement/conferencemanager/documents/api/getdocument/5205/cmabstsms/0000166980/c4e7bb9592fadbbaed276430ce95b8238d802a252e51efc75a92d30092b0b38c>

ES28-0609 - P251
E-Poster

Effect of dual wavelengths laser system (DWLS) on ovarian endometrioma: an histopathological study

Elisabetta Corvetto¹, Luigi Napp², Felice Sorrentino², Maurizio Nicola D'Alterio¹, Daniela Fanni³, Stefano Angioni¹

¹University of Cagliari, Surgical science, Cagliari, Italy

²University of Foggia, Medical and Surgical Science, Foggia, Italy

³University of Cagliari, Division of Pathology, Cagliari, Italy

Background

Surgical management of ovarian endometriosis is still debated and controversial. The removal of the cystic capsule with the stripping technique (cystectomy) seems to be most recommended for the lowest recurrence rate, but has

harmful consequences on the ovarian reserve due to excision of healthy ovarian parenchyma. Some authors proposed plasma laser and CO₂ laser for the ablation of the cystic capsule instead of the stripping technique, in order to preserve healthy ovarian tissue. Nevertheless few data exist on thermal effect and possible ovarian damage. Moreover, no data are available on the risk of recurrence. The aim of the study was to evaluate the effect of dual wavelengths laser system (DWLS) on cystic capsule ablation by histologically analysing the depth of necrosis induced by vaporization and the thermal damage to the underlying healthy ovarian tissue

Methods

We analysed ovarian endometrioma tissues after diode laser ablation. DWLS, with flat fibres of 400 or 1000 micron (Biolitec® Leonardo®, wavelength of 980 nm and 1470 nm) was used using a set mode at 20 and 30 W, at a distance averaging 2 mm from the tip of the piece, and with an exposure time limited to 1 second on each site. Histopathological analysis of the depth of cyst wall ablated and the characteristics of the underlying ovarian tissue were performed after surgery.

Results

No complications occurred during surgery with good haemostasis control. Following histological analysis, the depth of necrosis induced by vaporization was medially 915 µm (range 600-1400 µm) depending on the power used. No endometriosis cells were found in the treated tissue and no thermal damages were found on the ovarian parenchyma below the necrotic tissue.

Conclusions

The DWLS ablation technique seems to be a good alternative to the stripping technique and other ablation techniques, as it produces an adequate depth of necrosis with a complete destruction of the endometriosis cyst wall and this could be associated with a more likely low risk of recurrence. In our results, it does not seem to cause a severe thermal damage to healthy ovarian tissue with a consequent higher probability of preservation of the ovarian reserve. The results in term of efficacy and pregnancy outcomes need further larger randomized studies

<https://esge.covr.be/cmdocumentmanagement/conferencemanager/documents/api/getdocument/5170/cmabstms/000166840/da16cc72afc4f4033575c01a6b34f1fde9decadd978a587eeaca40ba0295c984>

ES28-0616 - P252

E-Poster

Haemangioma of the uterine cervix, uterine body and fallopian tubes: a rare cause of menorrhagia

Nathalie Woodhead¹, Izzat Feras¹, Shatrughan Sah²

¹*University Hospital Coventry and Warwickshire, Obstetrics and Gynaecology, Coventry, United Kingdom*

²*University Hospital Coventry and Warwickshire, Histopathology, Coventry, United Kingdom*

Background

Haemangiomas are benign tumours of blood vessels. They are common in parts of the body but rare in the female genital tract. Only approximately 60 cases in the cervix, approximately 55 cases in the uterus and rare cases in the fallopian tubes have been reported. They can be asymptomatic or cause abdominal pain, excessive vaginal bleeding and pregnancy-associated complications.

We present a case of haemangioma of the cervix extending to uterine body and also involving both fallopian tubes causing menorrhagia refractory to medical management in a young patient. To the best of our knowledge haemangiomas involving cervix, uterus and fallopian tubes in the same patient has not been documented.

Methods

A 32 year old presented with a 3-4 year history of menorrhagia, dysmenorrhea and intermittent right iliac fossa pain. She had tried combined and progesterone only oral contraceptive pills. At presentation she had a Mirena® intrauterine system in situ and was also having monthly Depo-Provera® injections, despite this she had a light daily bleed which was impacting on her quality of life. She had 3 children all delivered by caesarean section, at her last caesarean almost 4 years prior, she had a tubal ligation. She had no past medical, surgical or family history of note. Clinical examination was unremarkable, cervix appeared normal and ultrasound pelvis was reported as normal. After extensive counselling on the risks she was listed for total laparoscopic hysterectomy with ovarian conservation. The surgery was uneventful with good post-operative recovery.

Results

Cut surface of the cervix revealed a spongy appearance with brownish-colour change involving deep stroma of both lips extending to the lower uterine segment and the uterine body. Sections from cervix, uterus and both fallopian tubes were highly vascular consisting of blood vessels of varying size and variable thickness lined by endothelial cells with oedematous stroma. Immunohistochemically the endothelial cells were positive with CD34 and CD31 but negative with ER and PR. A diagnosis of capillary haemangioma was made.

Conclusions

Haemangioma should be included in the differential diagnosis of patients with abnormal vaginal bleeding, particularly if reproductive age with symptoms unresponsive to medical management. If there is any clinical suspicion and in cases not responding to conservative treatment ultrasound using colour Doppler can be a useful screening test for uterine vascular malformation. A pelvic angiogram and CT may be needed to confirm the presence of a lesion. The best management of haemangiomas remains unclear. Approach needs to be individualised considering age and wish to preserve future fertility. Conservative approaches are described however surgery in the form of hysterectomy may need to be considered for cure, particularly in cases like ours where multiple sites are involved. Definitive diagnosis is often made as a histopathological finding after surgery.

<https://esge.covr.be/cmdocumentmanagement/conferencemanager/documents/api/getdocument/5179/cmabstsms/000153960/a6c44a8ea948129253b467ca9b588be1ab947d239932011c55f68f6eb610d7dd>

ES28-0618 - P253

E-Poster

Laparoscopic excision of a large vaginal wall leiomyoma

Theodoros Theodoridis¹, Panagiotis Pappas¹, Panagiotis Nikolakopoulos¹, Leonidas Zepiridis¹, Dimitra Aivazi¹, Grigoris Grimbizis¹

¹Aristotle University Thessaloniki, 1st Dept. Ob&Gyn, Thessaloniki, Greece

Background

To present a laparoscopic excision of a large vaginal wall leiomyoma

Methods

A 40 years old woman presented in the outpatient department complaining of dyspareunia and pelvic discomfort over the last two years. Bimanual examination revealed a firm, solid mass related to the left posterior vaginal wall. The mass was separate from the uterus and cervix. Transvaginal ultrasonography (TVS) and Magnetic Resonance Imaging (MRI) confirmed the above findings of a 5,8 cm fibroid. A vaginal wall leiomyoma was considered as the most likely diagnosis. Vaginal and minimal access surgical options were discussed in detail and the patient opted the laparoscopic approach. She was therefore consented accordingly.

Results

A laparoscopy was performed and the procedure was uneventful and morcellation was used to remove the surgical specimen. The patient was discharged the first postoperative day. The pathology report revealed leiomyoma without atypical cells or necrosis. This video presentation demonstrates in detail all the steps of the operation which are: laparoscopic identification of the vaginal leiomyoma, dissection of the peritoneum, removal of the leiomyoma, vaginal closure, morcellation of the fibroid, haemostasis and restoration of the anatomic relations in the pelvis.

Conclusions

Laparoscopic excision of vaginal wall leiomyoma is feasible, and safe. It can be a valid alternative method to the classic vaginal route of surgery.

<https://esge.covr.be/cmdocumentmanagement/conferencemanager/documents/api/getdocument/5111/cmabstsms/000044560/7cef4fbb0f64773b50df6df8a07b6228ec7ae96b4ab9d424d3634943cc878a16>

Successful hysteroscopic management of a heterotopic cervical pregnancy with novel 15Fr miniresectoscope

Maria Chiara De Angelis¹, Fernanda Cioffi¹, Luigi Della Corte¹, Fabrizia Santangelo¹, Attilio Di Spiezio Sardo², Giuseppe Bifulco¹

¹University of Naples "Federico II",

Department of Neuroscience- Reproductive Sciences and Dentistry- School of Medicine, Naples, Italy

²University of Naples "Federico II", Department of Public Health- University of Naples Federico II- Naples- Italy, Naples, Italy

Background

Heterotopic Cervical pregnancy (HCP) is a rare but life-threatening form of heterotopic pregnancy, defined as the simultaneous occurrence of intrauterine (IUP) and ectopic cervical pregnancy. Conservative methods have been suggested to treat HCP, focusing on the selective reduction of cervical pregnancies in order to maintain eutopic pregnancy.

We report a case of a HCP after in vitro fertilization (IVF) successfully treated with conservative hysteroscopic approach by means of novel 15FR miniresectoscope

Methods

A 31-year-old woman with primary infertility was referred to the Infertility Unit of Department of Obs&Gyn of University Federico II of Naples after two failed IVF. She was affected by essential hypertension and diabetes mellitus medically treated. The woman underwent controlled ovarian stimulation. After oocyte retrieval, 2 blastocysts were transferred into the uterine cavity.

The patient was referred to our care at 8 weeks of gestation with a diagnosis of HCP. She was clinically stable at the time of admission. Speculum examination showed a swollen cervix and no bleeding from the uterus.

Transvaginal ultrasonography revealed two gestational sacs: one was in the uterine corpus, and the other was located in the cervix, at 16 mm distance from the external os. A 6 weeks embryo with cardiac activity was visible in both gestational sac. (FIG. 1) Both ovaries appeared increased in volume, in agreement with the previous ovarian stimulation.

The benefits of selective reduction with an hysteroscopic approach and the potential risks for the fetus in the uterus were discussed and subsequently accepted by the patient.

In-patient hysteroscopy under loco-regional anaesthesia was performed using a 15Fr bipolar miniresectoscope (*Karl Storz, Tuttlingen, Germany*). This novel instruments allows an easy entrance by vaginoscopy into the uterine cavity without any cervical dilatation. Intrauterine pressure was controlled by a pump-machine set at low pressure (<50mmHg). The ectopic gestational sac, close to the internal cervical ostium was detected (FIG.2). A resection of the gestational sac (FIG 3) under ultrasonographic control was performed and a careful coagulation of vessels was carried out in the area of implantation.

Results

The specimen was sent for histological evaluation, which confirmed diagnosis of products of conception. An intra-operative and post-operative ultrasound revealed the presence of fetal cardiac activity for the IUP. Postoperative course was optimal without complications.

Patient was discharged 7 days after hysteroscopy in good condition with a normal intrauterine fetal development. Vaginal progestin therapy was recommended. Currently the patient is at 26 weeks of gestation and the pregnancy is carrying on without any complication

Conclusions

The therapeutic option chosen by our center to remove selectively the HCP by hysteroscopic surgery allowed to successfully treat the HCP without causing threat to the concomitant IUP and/or the patient's life. The 15Fr bipolar miniresectoscope combines the significant advantages of minimally invasive hysteroscopy surgery (i.e. avoiding blind cervical dilatation, easy entrance into the cervix) and traditional resectoscopic surgery

Determination of two guidance points in cervical channel progression using Campo Trophyscope®

Ahmet Berkiz Turp¹, İsmail Güler²

¹Assistant Prof, Obstetrics and Gynecology, Şanlıurfa, Turkey

²Gazi University School of Medicine, Obstetrics and Gynecology, Ankara, Turkey

Background

Office hysteroscopy can be performed in the office conditions without giving anesthesia to the patient. It is very important for the operator to do the training without feeling anxiety, and also provides training and comfort without fear. Our aim is to establish a safe and standardized methodology by identifying two guiding points as we move through the cervical canal after the discovery of the cervical canal.

Methods

Operator enters the vaginally, and examines for the external cervical os by making minimal movements. Operator guides the camera towards snow storm image. Operator uses lateral and posterior fornices and orientates and turns towards the snowstorm view in meantime, makes it easier to find external cervical os. External cervical os anatomy is different from pinkish color of vagina, and cervical mucus can be found with slight back and forth movements of camera. External cervical os may be in posterior or retroversion state. Camera is placed near posterior vaginal wall and camera is pulled back in slow motion to find external cervical os. After external cervical os is found, operator also controls cervical which is in magnified view. Multiparous woman, external cervical os entrance is wide and operator can enter cervical channel without fear. Nulliparous woman, camera is directed to cervical canal by encouraging operator to enter without fear. Cervical os and canal are a flexible structure. Operator informed the patient who is exposed to dilatation for first time, and patient is able to feel pain while advancing the camera. Most important guide points for camera are rugae of cervix within canal.

Main point is direction of cervical whitish rugae is like sperm passes towards uterine cavity after sexual intercourse. Rugae are first guidance methodology toward uterine cavity. A second guide point is a black hole in blind spot as camera advances. If no path is visible while camera is moving, camera is slightly retracted to see guidance points. These guidance points are indicated as a green color by slowing down the video image.

Results

Two guiding points are important to enter the cervical canal and proceed reliably here. 1. Rugae direction, 2. Black hole ahead. These two guiding points also ensures cervical canal progression, which is the most important part of the CAMPO TROPHYSCOPE.

Conclusions

Our aim is to disseminate the use of this instrument and to set up a standard training and guidance. When trainees learn how to use office hysteroscopy, more operative procedures such as resectoscope can be used easily. There is no standardized guidelines of these procedures. If trainees learn some tips and tricks during the courses, training period of the courses will also decrease. Since our philosophy is 'Primum non nocere', it is very important in all surgical experiences.

<https://esge.covr.be/cmdocumentmanagement/conferencemanager/documents/api/getdocument/5156/cmabstsms/000113640/163c6e7c4fdd4507320971251f0ef577d1f085cec2bc6f61b40080acca3378fa>

ES28-0620 - P256

E-Poster

Re-recurrence of isolated port site metastasis in a patient with endometrial cancer

Theodoros Theodoridis¹, Maria Lantzanaki¹, Dimitrios Tsolakidis¹, Leonidas Zepiridis¹, Sotiris Pitis¹, Grigoris Grimbizis¹

¹Aristotle University Thessaloniki, 1st Dept. Ob&Gyn, Thessaloniki, Greece

Background

The aim is to present a case of re-recurrence of port site metastasis after laparoscopic hysterectomy for stage II, grade 2 endometrial cancer

Methods

We report a case of a 70 year-old woman who presented with a diagnosis of grade 2 endometrioid endometrial cancer, after having a dilation and curettage for postmenopausal bleeding. She underwent laparoscopic hysterectomy with bilateral salpingo-oophorectomy and pelvic lymphadenectomy. The pathology confirmed stage II, grade 2 endometrioid endometrial carcinoma. She was treated with radiotherapy postoperatively.

Results

Five months after the surgery the patient presented with a painful mass at the left trocar site. A biopsy of the lesion revealed port site metastasis of endometrial cancer. A CT scan of thorax and abdomen did not reveal any other metastatic lesions. The gynecological oncology group opted a surgical removal of the lesion. The lesion was removed en block from the skin to the rectus abdominis. The peritoneum was opened and there was no evidence of metastatic spread. The surgical margins were free of disease.

Six months after the port site metastasis removal she presented with a new painful mass at the left inguinal region. The mass was removed in the same manner in clear surgical margins as well. Histological examination confirmed the recurrence of the initial port site metastasis. The gynecological oncology group advised her to have additional chemotherapy treatment

Conclusions

There is a growing interest of port-site metastasis due to the increasing use of laparoscopy in gynecologic oncology. According to literature, the incidence of port-site metastasis for early stage endometrial cancer is estimated at approximately 0,18-0,33%. The incidence is 1-2% for all gynecologic malignancies. The presence of a port-site metastasis is usually related to the setting of advanced disease with multiple metastases and poorer disease-specific prognosis. The presence of isolated port-site metastasis recurrence is a very rare complication of laparoscopic management of endometrial cancer.

<https://esge.covr.be/cmdocumentmanagement/conferencemanager/documents/api/getdocument/5113/cmabstsms/000044560/e2bd8cb744cd4af3e4c364e39dba387b53dc4d4a49d69222d2187886dd26a5ac>

ES28-0627 - P258

E-Poster

Hysteroscopic excision of a large retained placental polyp

Theodoros Theodoridis¹, Panagiotis Pappas¹, Leonidas Zepiridis¹, Dimitra Aivazi¹, Dimitrios Vavilis¹, Grigoris Grimbizis¹

¹Aristotle University Thessaloniki, 1st Dept. Ob&Gyn, Thessaloniki, Greece

Background

Presentation of a rare case of a large placental polyp, which was excised by hysteroscopy after intravenous treatment with methotrexate.

Methods

A 32-year- old woman (Gravida 1, Para 1) presented in the outpatient clinic of our department with severe recurrent menometrorrhagia during the last six months. Her medical and surgical history is unremarkable. 6 months ago she

had a miscarriage of a twin pregnancy at eight weeks of pregnancy and she underwent evacuation curettage. She underwent transvaginal ultrasound and MRI and a large mass with maximum diameter of 3,5 cm, was revealed in close anatomical relation to the right uterine horn. Rich vascularization of the tumor was also present.

Results

An initial diagnostic hysteroscopy revealed a pulsating tumor covering the right internal tubal ostium. The diagnosis is a placental polyp with many organized pulsating blood vessels. The patient then received four doses of intravenous methotrexate and then a second interventional hysteroscopy was performed 8 days later. The blood vessels were constricted and the tumor did not pulsate anymore. It was excised via the loop of a mini-resectoscope. The procedure was uneventful and the patient remains asymptomatic. The pathology report revealed a placental polyp. The video presentation demonstrates in detail the hysteroscopy before and after the medical therapy with methotrexate.

Conclusions

Placental polyp is a retained piece of placental tissue that persistently exists in the uterine cavity after abortion, miscarriage or parturition. In the attached video, hysteroscopic procedures before and after treatment with methotrexate are described thoroughly. Resectoscope is used for the excision of the polyp and the final result is excellent for the patient.

<https://esge.covr.be/cmdocumentmanagement/conferencemanager/documents/api/getdocument/5106/cmabstsms/000044560/fe4bef38c246d8212aa15b0c8b352050356b84f12c6bba61394afa826ced7bfd>

ES28-0633 - P259

E-Poster

Laparoscopic management of endometrial cancer: our initial experience

Theodoros Theodoridis¹, Stamatis Papadopoulos¹, Eleftherios Klonos¹, Dimitrios Tsolakidis¹, Leonidas Zepeiridis¹, Grigorios Grimbizis¹

¹Aristotle University of Thessaloniki, 1st Department of Obstetrics and Gynaecology "Papageorgiou" General Hospital, Thessaloniki, Greece

Background

Endometrial Cancer seems to be one of the most common gynecological cancer in Europe. The age pattern varies with the more frequent age range after 40 years, and mainly in postmenopausal women with an average age of 60 years. Despite being the most common gynecological cancer in many countries, there is evidence for many differences in the clinical management. In addition, if we take into account the fact that risk factors, such as obesity, hypertension, and diabetes often occur in Greek women, we could realize the importance of proper management and surgical treatment at the feasible and effective stages. The aim of our study was to assess the feasibility and safety of laparoscopic management of endometrial cancer patients.

Methods

12 patients with endometrial cancer underwent laparoscopy as diagnostic or therapeutic method of treatment. All the patients were operated in the 1st. Department of Obstetrics and Gynecology by the same surgeon. Before being operated, all the women were informed about the difficulties, which may occur during the laparoscopic approach and also for the possibility of a laparotomy, that should be carried out and all of them gave their consent.

Results

Twelve patients with endometrial cancer underwent total laparoscopic hysterectomy. In 6 patients the surgical procedure included pelvic lymphadenectomy (21, 15, 14, 20, 10, 19 lymph nodes were collected respectively). The operating time varied between 75-240 minutes and there were no intraoperative complications. There was none patient with positive resection margins and it has to be mentioned that the mean of estimated intraoperative blood loss was around 50 ml, which demonstrates the fact, that there was no need in any patient of conversion to mini laparotomy. All patients discharged from the hospital the second postoperative day in good condition

Conclusions

Laparoscopic management of endometrial cancer appears to be feasible, safe, and well-accepted method of treatment in selected cases.

<https://esge.covr.be/cmdocumentmanagement/conferencemanager/documents/api/getdocument/5109/cmabstms/000044560/3eefb752e1df9953fd3207968677b91668bb543076417dc56ab0c04b66ff2fa8>

ES28-0668 - P260

E-Poster

The role of outpatient hysteroscopy and the risk of significant endometrial pathology in premenopausal women

Carina Johnstone-Ayliff¹, Wioletta Kapadia¹, Magdy Nawar¹

¹London North West University Healthcare NHS Trust, Obstetrics and Gynaecology, London, United Kingdom

Background

Outpatient hysteroscopy is a safe and cost-effective way of diagnosing and treating abnormal uterine bleeding without the need for general anaesthetic.

Hysteroscopy is often performed in women who are 45 and under as an investigation and also as a treatment in the form of polypectomy and Mirena intrauterine system (IUS) insertion. It may also be used in the diagnostic work-up for considering transcervical resection of fibroids (TCRF). The aim of this study was to assess the success rates, the proportion of cases having simultaneous treatment and the endometrial pathology on histology in our unit.

Methods

This retrospective study reviewed all outpatient hysteroscopies for menstrual symptoms in premenopausal women aged 45 and under across two sites within the Trust in the year from 1st August 2017 to 31st July 2018. Data were extracted from multiple electronic records systems (GCIS, ICE and EPRO).

Results

Over the one-year period there were 312 cases of premenopausal women aged 45 and under with menstrual symptoms including menorrhagia, irregular bleeding, prolonged bleeding, intermenstrual bleeding and postcoital bleeding. The mean age was 37.8 years (s.d. 5.83 years). Referrals were made from gynaecology rapid access clinic, gynaecology outpatients or direct from primary care. 312 diagnostic procedures were attempted and 301 completed successfully, giving a failure rate of 3.5%.

Of the 301 diagnostic hysteroscopies performed, 48 patients (15.9%) required a further general anaesthetic (GA) procedure at a later date for resection of polyps or TCRF which could not be done at the time.

Of the diagnostic hysteroscopies performed, 99 (32.9%) involved treatment including polypectomy, Mirena IUS insertion or both. This included 41 patients (13.6%) who had a polypectomy, 54 (17.9%) patients had insertion of a Mirena IUS and 4 (1.3%) patients who had both.

Endometrial sampling by either directed (using grasping forceps under hysteroscopic vision) or pipelle biopsy was performed in 128 (41.0%) of the 301 diagnostic procedures. From the available histology reports, there were no cases of endometrial cancer, atypical hyperplasia or complex hyperplasia. There were only two cases of simple hyperplasia (0.66% of total cases performed, 1.1% of those either biopsied or who had polyps removed). All other histology was benign.

Conclusions

Outpatient hysteroscopy in symptomatic premenopausal women aged 45 and below was successfully completed in the majority of patients and showed non-malignant pathology in all cases.

<https://esge.covr.be/cmdocumentmanagement/conferencemanager/documents/api/getdocument/5260/cmabstms/000145740/31a338cf3a8540adb7579067499d7b68430a6e5bf5fc001d1ad8e1a710196e3e>

ES28-0634 - P261

E-Poster

Hysteroscopic diagnosis of a failing intrauterine pregnancy and treatment with the Myosure hysteroscopic morcellator

Minas Psychoulis¹, Pandelis Athanasias¹

¹Epsom and St Helier NHS Trust, Women's health, London, United Kingdom

Background

Pregnancy of unknown location (PUL) is defined as no sign of either intra- or extrauterine pregnancy or retained products of conception on transvaginal ultrasound, despite a positive pregnancy test.

A pregnancy site will not be visualised in 8–31% of early pregnancy scans. Hysteroscopy can be considered for diagnosis and treatment in some cases.

Methods

A case report of a 38-year-old patient with a pregnancy of unknown location that after a negative laparoscopy, two failed surgical evacuations (ERPC) and a failed medical management was treated successfully with the Myosure hysteroscopic morcellator.

Results

A 38 year old with two previous vaginal deliveries and a known fibroid uterus attended the early pregnancy unit with a history of vaginal spotting and mild abdominal pain and a positive pregnancy test.

A transvaginal scan was performed and reported as a pregnancy of unknown location.

B-HCG was 4,397 iu and progesterone was 13 nmol/l .

The patient was counselled for diagnostic laparoscopy as she was symptomatic and Evacuation of Retained Products of Conception if the laparoscopy was negative.

The diagnostic laparoscopy showed no significant pathology and the histology from the ERPC showed no evidence of products of conception.

Beta-HCG increased to 5,434 iu four days postoperatively and a repeat ERPC was offered under ultrasound guidance as no ectopic pregnancy was identified on pelvic ultrasound.

During the procedure products of conception were seen and histology confirmed that. Subsequent B-HCG levels were 2,127 iu, 2,853 iu and 4,430 iu in the next 7 days.

Repeat transvaginal scan identified a distorted endometrium from two submucous fibroids, the largest one on the posterior wall and the other one on the left lateral wall. Products of conception were between the two and measured as 40x24x28 mm. Misoprostol was offered to the patient to avoid repeat surgery but without effect.

After counselling, the patient was booked three weeks after her original presentation to the department for hysteroscopic resection of suspected retained products of conception using Myosure.

During the procedure an isthmus was identified between the two submucosal fibroids and the implanted pregnancy was on the large posterior fibroid. The retained products of conception and part of the fibroid were resected with Myosure.

Histology confirmed retained products of conception with no evidence of gestational trophoblastic disease and the subsequent B-HCG had fallen to 200 iu in a week. The patient was followed up with serial B-HCG and discharged once the level was below 20 iu.

Conclusions

Hysteroscopic Morcellation can be considered in selected cases for the removal of retained products of conception under direct vision. It is a safe procedure, can be performed in the office and improve patient satisfaction.

<https://esge.covr.be/cmdocumentmanagement/conferencemanager/documents/api/getdocument/5244/cmabstsms/000151950/1ce209c100df4807ab36a0a27bfc81c0b0ab28bb7c5b511ed3fa19a04284d31f>

ES28-0639 - P262

E-Poster

Laparoscopic management of cesarean scar defect (isthmocele)

Ana Ranc¹

¹*Slovenian, Department of Gynecology and Obstetrics- General Hospital Slovenj Gradec-, Slovenj Gradec, Slovenia*

Background

Cesarean scar defect or isthmocele or 'niche' has become a problem of modern society as the incidence of cesarean section (CS) rate is increasing worldwide. Complications, such as abnormal uterine bleeding, dysmenorrhea, obstetric complications in future pregnancies and subfertility are often the presenting sign of isthmocele. The prevalence of isthmocele at the site of cesarean delivery is estimated from 24% and 70%.

Surgical procedure should be considered in symptomatic women that are willing to preserve their fertility; hysteroscopic resection in isthmocele with residual myometrium (RM) ≥ 3 mm and laparoscopic resection in women with large isthmocele with RM ≤ 3 mm.

We present laparoscopic management of large isthmocele in 33 years old patient with 4 year lasting symptoms after second CS: intermenstrual spotting, dysmenorrhea, dyspareunia, chronic pelvic pain, vaginal discharge. Isthmocele was identified with transvaginal ultrasonography in sagittal and transversal plane with measures 13x16 x 32 mm and residual myometrium (RM) less than 1 mm. Oral contraceptive drugs were not successful in treatment of symptoms.

Methods

Surgical management was started with introduction of 5,5 mm hysteroscope for the evaluation and exact location of the isthmocele. After filling the bladder with blue dye solution laparoscopy was followed placing umbilical and suprapubic trocar and two side ports in the lower abdomen. Illumination by the hysteroscopic light allowed recognition of the thinnest point of the isthmocele and helped to prevent the bladder injury during adhesiolysis. Dissection of adhesions between bladder and the top of the 3 cm wide isthmocele was made by Thunderbeat device (Olympus). The isthmocele was then opened and completely excised using a cold scissor.

The well vascularized myometrium was sutured in two layers with three separate resorbable sutures (0 Novosyn) in each layer. The peritoneum was closed using running suture (third layer). Intrauterine hysteroscope was used to preserve the continuity of the cervical canal with the uterine cavity and as manipulator. At the end of surgery hysteroscopy was performed to visualize the repair of the cervical canal.

Results

At the end of surgery normal patency of cervix and complete correction of isthmocele was seen. The patient was discharged from the hospital after 2 days. We did not register any perioperative or early postoperative complications. One month after the operation the patient was free of previous symptoms.

Conclusions

Laparoscopic surgical management of isthmocele is a good method in treatment of large, symptomatic isthmoceles non responding to conservative treatment. Hysteroscopy is an excellent support method in almost all steps of laparoscopic surgery of isthmocele. The procedures should be planned and done by well trained team with experienced gynecologist and second assistance.

ES28-0645 - P263

E-Poster

Post partum perineal dysfunctions: a prospective analysis of risk factors

Konstantinos Martsidis¹, Carlotta Giuliani¹, Alessia Mereu¹, Maurizio Nicola D'Alterio¹, Michele Peiretti¹, Stefano Angioni¹

¹*University of Cagliari, Surgical Science, Cagliari, Italy*

Background

Many risk factors have been recognized to explain postpartum perineal dysfunctions such as multiparity, operative delivery, prolonged second stage of labor, epidural analgesia, perineal lacerations and fetal macrosomia. The perineal

damage is correlated to pregnancy and vaginal delivery due to direct mechanic trauma on muscles the elevator ani and anal sphincter, neurologic damage of pelvic floor nerves and connective-fascial lesion of the urogenital hiatus. During pregnancy there is an excessive pressure on the anterior perineum due to the weight of the gravid uterus and the direct pressure on the urogenital hiatus. During vaginal birth, all the muscular and ligamentous structures of the pelvic floor are exposed to intense pressure and traction forces in lateral and longitudinal directions. During impingement of the presenting part, the bladder is compressed between pubic bones and the fetal head with a consequent trauma that is directly correlated with the length of the expulsion phase. Health workers must be able to recognize, prevent and treat perineal dysfunctions during and after pregnancy. The aim of our study was to evaluate different maternal, neonatal and delivery-associated risk factors and analyze the pelvic floor alterations in the puerperium compared with the perineal function before birth.

Methods

106 primiparae women were enrolled, 4-5 months after delivery they underwent to an interview in order to evaluate urinary and anal incontinence, perineal pain, dyspareunia and a clinic examination of the functioning of the pelvic floor with pubococcygeus test (PC test). They also filled a questionnaire about the functioning of their pelvic floor during pregnancy. In order to obtain information about the risk factors there were considered: job, maternal age, gestational age, maternal weight before pregnancy, weight at term, maternal diseases, type of delivery (spontaneous, operative, caesarian section), episiotomy, grade of lacerations, Kristeller maneuver, type of induction (if any), length of labor, length of second stage of labor, head circumference, newborn's weight, epidural analgesia.

Results

Vaginal birth correlate with lower scores at PC test, urinary incontinence that is also associated with maternal age and weight, dyspareunia and perineal pain, especially in women who had operative delivery, episiotomy and/or lacerations. Epidural analgesia seems to be protective for postpartum dyspareunia (31,8% vs 44,2%). A significant correlation has been demonstrated between newborn head circumference and weight and perineal dysfunction after delivery probably due to longer labor and increased stretching of pelvic tissues.

Conclusions

Our data are in line with literature and underline that urinary symptoms tends to ameliorate after delivery demonstrating that pregnancy itself is a risk factor. Moreover, we discovered that in women with perineal dysfunction in postpartum the symptoms were worse than during pregnancy. If pregnancy is a risk factor for perineal dysfunctions, delivery is a worsening factor for a pre-existing situation or the appearing of new symptoms.

<https://esge.covr.be/cmdocumentmanagement/conferencemanager/documents/api/getdocument/5210/cmabstms/000166740/82d4f92dc220b507cc955f81dd1364bafcdc2bf9a39b34c0106d788b83964931>

ES28-0664 - P264

E-Poster

Laparoscopic surgical treatment of deep endometriosis – a 2 year experience

Matilde Martins¹, Sara Cunha¹, Maria Isabel Sá¹, José Carlos Silva¹, Cristina Costa¹, Mak Foo¹

¹Entre o Douro e Vouga Hospital Center, Gynecology and Obstetrics Department, Santa Maria da Feira, Portugal

Background

Deep infiltrating endometriosis is diagnosed in 20% of women with endometriosis. It is strongly associated with severe chronic pelvic pain, dyspareunia, and dysmenorrhea. Complete excision of endometriosis offers good long-term symptomatic relief, especially for those women with severe or debilitating symptoms.

The complication rate after laparoscopic surgery for deep endometriosis is estimated to be 3.4%, rising to 10–22% when colorectal resection is necessary. Postoperative intestinal and urinary fistulas have a deleterious impact on a women's quality of life, and are the most worrisome complications of deep endometriosis surgery.

The study aims to analyze our experience in the surgical treatment of deep endometriosis and to evaluate the complications after surgery for deeply infiltrating pelvic endometriosis.

Methods

A descriptive retrospective study including all surgical treatments in patients with deep endometriosis between March 2016 and October 2018 was conducted.

Parameters registered were: age, major symptoms, disease location, type of surgical treatment, operative complications, duration of surgery, estimated blood loss, need for conversion to laparotomy, duration of hospitalization and postoperative sequelae.

Results

During the studied period, a total of 12 women underwent laparoscopic surgical treatment for deeply infiltrating pelvic endometriosis in our service. Mean age and median parity were $43,08 \pm 4.88$ and 1, respectively.

The most frequent indication was disabling cyclic dyspareunia and chronic pelvic pain (66,7% of cases) followed by the presence of endometrioma (50% of cases).

The most common surgical procedures were adhesiolysis (91.7% of cases), hysterectomy (91.7%), nodule excision of the rectovaginal septum (83%) and the excision of ovarian endometriomas (50%). The mean operative time was 151 ± 37 minutes (ranging from 88 to 204 minutes). Laparoconversion was not necessary.

Intraoperative minor complications occurred in 2 women, namely bleeding managed laparoscopically. No major intraoperative complications occurred. Estimated blood loss was 278 ± 167 cc.

The average hospital stay was 3.58 ± 0.29 days (ranging from 3 to 5 days).

The overall rate of postoperative complications in our series was 25%: urinary incontinence (1 case), cystocele (1 case) and pelvic pain related to anal and rectal endometriotic implants that required reintervention.

Conclusions

Although our study has a considerable limitation (small sample), our findings showed that laparoscopic surgical treatment of pelvic endometriosis is safe and effective, with improvement of the patients quality of life, associated with a low rate of complications.

In order to achieve an acceptable complication rate, these patients should be managed by specialised multidisciplinary teams.

<https://esge.covr.be/cmdocumentmanagement/conferencemanager/documents/api/getdocument/5241/cmabstms/000167030/b1e390c8bb2351dc8cec249e70b52b0e91101693713044d849a68e0f85c1c885>

ES28-0657 - P265
E-Poster

The role of laparoscopy in the management of caesarean scar pregnancy

Jennifer Hoh¹, Gordon Narayansingh¹

¹Royal Victoria Infirmary, Gynaecology, Newcastle Upon Tyne, United Kingdom

Background

To highlight the role of laparoscopy in the management of caesarean scar pregnancy (CSP).

Methods

The patient's hospital notes were reviewed and the relevant investigation results accessed via the electronic record system.

Results

A 28-year-old G4P2 was referred to us from another hospital at 8 weeks gestation with suspected caesarean scar ectopic on ultrasound scan. She had one previous caesarean section at full dilatation for fetal distress. A repeat ultrasound scan and MRI were performed which showed similar findings. Her beta hcg was 20 498. After establishing the diagnosis, treatment options were discussed and the decision was to perform dilatation and evacuation of pregnancy under laparoscopic guidance. Laparoscopy was performed and pelvic side wall were opened to identify the uterine vessels. Bipolar diathermy to the uterine arteries was performed. Purse string suture was placed over the cervico-vaginal junction. Dilatation and evacuation was performed subsequently. There was minimal blood loss during the procedure of about 100mls. Transvaginal ultrasound scan was performed following the surgical evacuation, which

confirmed empty uterine cavity. The patient was discharged home the following day. Serial hcg levels were performed and the levels had fallen appropriately. The patient made uneventful recovery with no further intervention required.

Conclusions

Caesarean scar pregnancy is rare and the prevalence is approximately 1 in 2000 pregnancies. Transvaginal ultrasound should be the primary diagnostic modality and MRI can be used as second line investigation if the diagnosis is equivocal or if there is local expertise in MRI diagnosis of CSP. There is insufficient evidence to propose one specific intervention over another but the literatures supports surgical as the most effective approach. Our case has demonstrated that surgical evacuation under laparoscopic guidance is an acceptable method for management of early CSP with minimal blood loss and rapid recovery for the patient.

<https://esge.covr.be/cmdocumentmanagement/conferencemanager/documents/api/getdocument/5047/cmabstms/0000166520/0dfb91cc612248258296a1be261aaa09d0192ac89f88fc4d8a95939598c66ad4>

ES28-0658 - P266
E-Poster

Single port access laparoscopy (spal): is it the best treatment of concomitant diseases in different abdominal quadrant?

Gianmarco Dancona¹, Mohamed Raslan², Angelos Daniilidis³, Michele Peiretti¹, Maurizio Nicola D'Alterio¹, Stefano Angioni¹

¹University of Cagliari, Surgical Science, Cagliari, Italy

²University of Tanta, Obstetrics and Gynecology, Tanta, Egypt

³Aristotle University of Thessaloniki, Obstetrics and Gynecology- Hippokratia Hospital, Thessaloniki, Greece

Background

Single-port access laparoscopy (SPAL) technique is developing in the gynaecological field. This approach may increase the benefits of traditional minimally invasive surgery such as decreased blood loss and postoperative pain, faster recovery time, fewer complications, and better cosmetic results, without increasing costs. Nevertheless, few cases on SPAL ovarian surgery concomitant with the treatment of other diseases located in different abdominal locations have been reported.

Methods

Description of two cases of concomitant SPAL surgery in the Division of Gynecology and Obstetrics, University of Cagliari, Italy with X-cone (K. Storz, Tuttlingen, Germany).

Results

The first patients (28 years old, BMI 22) complained of pelvic pain related to an ovarian endometriosis of 5 cm in the left ovary and abdominal post prandial pain related to gallstones. She underwent single port laparoscopy for cholecystectomy and ovarian endometrioma excision. Surgery lasted 55 minutes, she was discharged after two days without any early or late complications. She had two pregnancy with two live vaginal deliveries of healthy children. The second patients (34 y, BMI 24) presented an ovarian dermoid cysts and chronic abdominal pain related to chronic appendicitis. She underwent SPAL for the removal of the cyst and appendectomy with Endo Gia stapler (Covidien). Surgery lasted 50 minutes and the patients was discharged on day three. Follow-up was uneventful and she reported the resolution of pre-surgical symptoms.

Conclusions

Single port laparoscopy seems the best approach when concomitant disease in different abdominal quadrants are present. In fact, this approach eliminates the problem of multiple and different site placement for accessory ports, typical of these procedures when performed simultaneously at conventional laparoscopy. It consents to reduce surgical risks related to the number of ports, it is a feasible and simple technique and has good cosmetic results with high patient satisfaction.

<https://esge.covr.be/cmdocumentmanagement/conferencemanager/documents/api/getdocument/5247/cmabstms/0000166750/b35bfaa1593548781e716e00372076c3931f2a57f370c5ec635e5e981416df6>

Innovative use of hysteroscopic morcellation in caesarean scar ectopic pregnancies and in persistent retained trophoblastic tissue

Aruna Ramineni¹, Achinta Dissanayake¹, Farhat Thaheem¹, Akobundu Nnochiri¹

¹BHR University Hospitals, Women and Children Division, Romford, United Kingdom

Background

Caesarean scar pregnancy is a rare form of ectopic pregnancy in which trophoblastic tissue implants into the defective myometrial scar resulting from a previous caesarean. The incidence may be on the rise due to increasing rates of Caesarean section as well as increased awareness and detection.

CSP can be classified as endogenous (type 1) and exogenous (type 2). In endogenous type growth occurs towards the cervical isthmus increasing the risk of bleeding following delivery. In the exogenous type pregnancy is deeply embedded in the scar growing towards the bladder hence increasing the risk of uterine rupture and haemorrhage. Management options include conservative, medical management Methotrexate, surgical management with hysteroscopic resection, uterine artery embolization, dilatation and curettage, laparoscopic or open resection and high intensity focused ultrasound (HIFU). Overall management can be challenging.

Methods

Retrospective case studies where hysteroscopic morcellation was used to treat patients with caesarean scar ectopics and retained products. A patient with a history of previous two Caesarean sections presented at 11 weeks of gestation with per vaginal bleeding following a failed pregnancy. Transvaginal sonography revealed a 11mm gestational sac with absent fetal pole embedded in to the caesarean scar. She agreed for surgical management with Myosure resection. At hysteroscopy retained products of conception were noted in the cervico uterine junction along with adjacent scar tissue. Resection of products of conception along with scar tissue was done using myosure. Bleeding was prevented by intravenous Tranexamic acid and balloon tamponade. She had an uneventful recovery. Histology confirmed products of conception.

In our second case, a patient in her 2nd pregnancy with a history of previous Caesarean section underwent surgical management for incomplete miscarriage but continued to experience persistent per vaginal bleeding 4 weeks post procedure. Sonography revealed persistent tissue. She underwent hysteroscopy and morcellation of the persistent trophoblastic tissue attached to the cervico isthmeal region. Complete resection was performed and recovery was uneventful. Histology confirmed trophoblastic tissue.

In our third case, a patient G7 P5 with BMI of 43 presented with bleeding and pain at 12 weeks gestation. Scan suggested a caesarean scar ectopic. BHCG `s was rising. Evacuation of scar ectopic was difficult due to patients BMI and uterus adherent to anterior abdominal wall. Laparoscopy was done to exclude uterine perforation and scar ectopic removed with morcellation by myosure device.

Results

All the women were treated with minimal blood loss and subsequent follow up revealed that the pregnancy tissue was successfully evacuated

Conclusions

Hysteroscopic morcellation of caesarean scar ectopic and persistent retained products is an innovative and safe procedure which is accepted well by the patients.

<https://esge.covr.be/cmdocumentmanagement/conferencemanager/documents/api/getdocument/5236/cmabstsms/000155840/cf0a10235b045e5e86af4b842f70df01cd570e69028301eff4df05d53e754b16>

Laparoscopic management of cesarean scar defect (isthmocele)

Ana Ranc¹, Branka Verdnik Golob¹

¹General Hospital Slovenj Gradec, Department of Gynecology and Obstetrics, Slovenj Gradec, Slovenia

Background

Cesarean scar defect or isthmocele or 'niche' has become a problem of modern society as the incidence of cesarean section (CS) rate is increasing worldwide. Complications, such as abnormal uterine bleeding, dysmenorrhea, obstetric complications in future pregnancies and subfertility are often the presenting sign of isthmocele. The prevalence of isthmocele at the site of cesarean delivery is estimated from 24% and 70%.

Surgical procedure should be considered in symptomatic women that are willing to preserve their fertility; hysteroscopic resection in isthmocele with residual myometrium (RM) ≥ 3 mm and laparoscopic resection in women with large isthmocele with RM ≤ 3 mm.

We present laparoscopic management of large isthmocele in 33 years old patient with 4 year lasting symptoms after second CS: intermenstrual spotting, dysmenorrhea, dyspareunia, chronic pelvic pain, vaginal discharge. Isthmocele was identified with transvaginal ultrasonography in sagittal and transversal plane with measures 13x16 x 32 mm and residual myometrium (RM) less than 1 mm. Oral contraceptive drugs were not successful in treatment of symptoms.

Methods

Surgical management was started with introduction of 5,5 mm hysteroscope for the evaluation and exact location of the isthmocele. After filling the bladder with blue dye solution laparoscopy was followed placing umbilical and suprapubic trocar and two side ports in the lower abdomen. Illumination by the hysteroscopic light allowed recognition of the thinnest point of the isthmocele and helped to prevent the bladder injury during adhesiolysis. Bladder Dissection of adhesiolysis between bladder and the top of the 3 cm wide isthmocele was made by Thunderbeat device (Olympus). The isthmocele was then opened and completely excised using a cold scissor.

The well vascularized myometrium was sutured in two layers with three separate resolvable sutures (0 Novosyn) in each layer. The peritoneum was closed using running suture (third layer). Intrauterine hysteroscope was used to preserve the continuity of the cervical canal with the uterine cavity and as manipulator. At the end of surgery hysteroscopy was performed to visualize the repair of the cervical canal.

Results

At the end of surgery normal patency of cervix and complete correction of isthmocele was seen. The patient was discharged from the hospital after 2 days. We did not register any perioperative or early postoperative complications. One month after the operation the patient was free of previous symptoms.

Conclusions

Laparoscopic surgical management of isthmocele is a good method in treatment of large, symptomatic isthmoceles non responding to conservative treatment. Hysteroscopy is an excellent support method in almost all steps of laparoscopic surgery of isthmocele. The procedures should be planned and done by well trained team with experienced gynecologist and second assistance.

ES28-0666 - P271

E-Poster

Mitotically active leiomyoma in pregnancy: a case report

Jennifer Hoh¹, Mei Kiang Liew², Jilly Goodfellow¹, Michelle Russell¹

¹*Royal Victoria Infirmary, Gynaecology, Newcastle Upon Tyne, United Kingdom*

²*Queen Elizabeth Hospital, Gynaecology, Newcastle, United Kingdom*

Background

To present a case of a rapidly growing cervical mass in a 32-year-old pregnant woman in which its histological diagnosis posed a challenge.

Methods

The patient's hospital notes were reviewed and the relevant investigation results accessed via the electronic record system.

Results

HM, a 32-year-old was referred to colposcopy clinic from maternity assessment unit at 14 weeks gestation following 4 episodes of vaginal bleeding and was found to have a mass on the anterior lip of the cervix. Her previous cervical smears were normal. On examination, there was a polypoidal mass arising from the anterior aspect of the cervix. As it did not appear sinister, a further follow up was arranged with the consultant in 6 weeks. At 24 weeks gestation, the mass had rapidly enlarged and is now protruding to the introitus. A punch biopsy was obtained. Histology showed bland spindle cell lesion. There was no convincing cytological atypia or excessive mitotic activity is seen. Ki67 proliferation index is difficult to interpret due to surface ulceration. Immunohistochemistry is supportive of smooth muscle tumour of uncertain origin. MRI scan was arranged and did not show any pelvic pathology and lymphadenopathy. At 28weeks gestation, the mass was protruding at least 4cm out of the introitus. Therefore, decision was made following MDT discussion for excision of the mass under spinal anaesthetic. Histology confirmed smooth muscle tumour of uncertain malignant potential (STUMP) but leiomyosarcoma could not be excluded. Therefore, the slides were sent to the histopathologists at UCLH and Royal National Orthopaedic Hospital in London for second opinion and the consensus was mitotically active leiomyoma affected by pregnancy. She had uneventful normal vaginal delivery at term. Follow up MRI scan in 6 months showed no recurrence.

Conclusions

Cervical leiomyoma accounts for 0.4% of all leiomyoma. Mitotically active leiomyoma is a tumour with high mitotic index and it differs from uterine smooth muscle tumour of unknown malignant potential (STUMP) due to lack of recurrences and metastasis outside the pelvis. In our case, surgical excision of the mass was decided after MDT discussion as we were aware of the possibility of preterm delivery. However, we were concerned that the mass had grown rapidly in a short period and the possible diagnosis of STUMP. Mitotically active leiomyoma is more common in women of reproductive age. Hormonal stimulation either exogenously or endogenously may be responsible for the morphological changes in some leiomyomas. This case highlights the importance of distinguishing between mitotically active leiomyoma and other variants such as STUMP to avoid unnecessary radical surgery.

<https://esge.covr.be/cmdocumentmanagement/conferencemanager/documents/api/getdocument/5079/cmabstsms/000166520/67a76331b698549c29ced666dc93a2edde79dd83a106a5cf22602b3bafc8b36e>

ES28-0669 - P272

E-Poster

Hysteroscopic diagnosis of uterine niche

David John Rowlands¹, Nahid Gul¹

¹*Wirral University Teaching Hospital, Gynaecology, Wirral, United Kingdom*

Background

Caesarean section rates continue to rise and long term complications are becoming increasingly recognised.

The possibility of there being an incompletely healed scar or niche has been recognised for at least a decade.

Uterine niches occur in a small percentage of women following caesarean section. As the rate of caesarean section in many countries has increased markedly and continues to increase, the number of women who have a niche and are affected by the niche has also risen markedly.

It is important that presence of the niche is considered a) in terms of symptoms; b) in terms of risk of perforation from invasive intrauterine devices or tests; c) in terms of risk of abnormal implantation on future pregnancy d) in terms of potential impairment of future fertility e) in terms of embryo transfer in IVF f) in terms of risk of failure in late pregnancy or labour .

We describe a hysteroscopic technique/observation for niche diagnosis.

Methods

Uterus and cervix examination with a 30 degree hysteroscope and saline.

Systematic examination and orientation with cystoscopic examination of the bladder takes advantage of the air bubble seen at 12 O'clock in the dome of the bladder.

We demonstrate a similar bubble used to identify the uterine niche in hysteroscopic examination of the uterus.

Results

We demonstrate the presence of the uterine niche with a bubble present in the niche seen at hysteroscopic examination.

Conclusions

Age old lessons and techniques from endoscopic examination of other structures can be applied to gynaecological surgery. Hysteroscopic diagnosis with the 'bubble sign' is simple and reproducible technique.

<https://esge.covr.be/cmdocumentmanagement/conferencemanager/documents/api/getdocument/4955/cmabstsms/000022970/4528f4fc4ba179f9837a04832be98cf2dfcb38c2c5a070b3572ccaddced7fabf>

ES28-0672 - P273

E-Poster

Outpatient hysterectomy for benign indications in Germany, is it time to begin?

Morva Tahmasbi Rad¹, Sven Becker¹

¹University of Frankfurt, Department of Gynecology and Obstetrics, Frankfurt, Germany

Background

Laparoscopic Hysterectomy (LH) is a safe procedure with low rates of complications and readmissions. Increasing evidence indicates that LH may be suitable for an outpatient setting but this may impair patient's satisfaction. In change from in-patient care to day case surgery factors impairing patients' satisfaction must be considered.

Methods

This is a nonrandomized, prospective pilot study of hysterectomies performed at university hospital center by 1 surgeon over 6 months. Patient preference and considerations has been asked with a questionnaire before the operation, 4 hours after and 2 week after the operations

Results

From the 24 registered patients with the age range 31 to 69 years old, 14 patients before the operation, 10 patients 4 hours after operation and 15 patients 2 weeks after operation considered it as a feasible intervention. Factors influenced the negative opinion about the discharge at the same day were previous different abdominal operations, fear from the pain after the operation, and complicated operations. The opinion of the surgeon after the operation about the operation and feasibility of the discharge individually was the most important factor for the patients to decide to be discharge at the same day.

Conclusions

Benefits of ambulatory hysterectomy include decreased costs of patients care and low infection rates. Patients' satisfaction is very important in change from in-patient care to day case surgery. The individual talks with the patients to understand the procedure before the operation and also after it, as well as recommendations for discharge will make the patients satisfied and make them consider the same day discharge comparing to in-patient care.

ES28-0674 - P275

E-Poster

Investigating the quality of evidence in the management of endometriosis

Martin Hirsch¹

¹Queen Mary University of London, Womens Health Research Unit, London, United Kingdom

Aim

I will evaluate the quality of information available to researchers, clinicians and patients on the management of endometriosis.

Background

The dissemination information from randomised controlled trials to clinical guidelines and then to patient information is dependent on the quality of research produced. There have been efforts made to improve the quality of data with excellent work from The World Endometriosis Research Foundation Endometriosis Phenome and Biobanking Harmonization Project (WERF EPHeC) setting standards for research design. There have been published tools for the standardisation of research design in several areas including clinical, covariate and surgical phenotype recording and specimen collection, processing and storage.

Trials continue to collect many outcomes and selectively report favourable or attractive outcomes that may be appealing to journals editors and readers, neglecting more widely recognised or valued clinical outcomes. This process of outcome reporting bias has not progressed with the advancing rigours which surround methodology. An improvement in outcome reporting standards can occur yet the endometriosis community has yet to determine the most important clinical outcomes amongst its stakeholders.

This problem makes comparison between and combination of results across studies difficult, if not impossible. As a result there can be difficulties in synthesising evidence to generate recommendations for clinical practice which is detrimental to the health of women with endometriosis.

Materials / Patients

We performed a series of systematic reviews to assess the impact of outcome reporting quality of the information available to endometriosis stakeholders: patients, clinicians, and researchers. We highlighted the sources of information key to each stake holder as follows:

1. Patients - online information
2. Clinicians - clinical guidelines
3. Researchers - randomised controlled trials

Methods / Results

We performed a three step evaluation:

1. Patients

We aimed to evaluate the credibility, quality, readability, and accuracy of online patient information concerning endometriosis.

We searched the five popular internet search engines: [1] aol.com; [2] ask.com; [3] bing.com; [4] google.com; and [5] yahoo.com. We developed a search strategy in consultation with patients with endometriosis, to identify relevant websites. We identified 750 websites, of which 54 were included. Over a third of websites did not attribute authorship and almost half the included websites did not report the sources of information or academic references. No websites provided information assessed as being written in plain English. A minority of

websites were assessed as high quality. A single website provided accurate information, evidentlycochrane.net. Available information was, in general, skewed towards the diagnosis of endometriosis. There were 16 credible websites, however the content limitations were infrequently discussed. No website scored highly across all four domains.

2. Clinicians

We wanted to assess whether outcome reporting variation had an effect on guideline formation. We evaluated the methodological quality of endometriosis guidelines, mapped their recommendations, and explored the relationships between recommendations and research evidence.

We include two international and five national guidelines. No guideline followed the standardised guideline development methods (AGREE-II). Guidelines performed poorly in the domains of stakeholder involvement and rigor of development and very poorly in the domains of applicability and editorial independence. The ESHRE guideline was objectively evaluated as the highest quality guideline (methodological quality score: 88/100). One hundred and fifty-two different recommendations were made, 10 (7%) recommendations were comparable across guidelines. There was substantial variation between the supporting evidence presented by individual guidelines for comparable recommendations. Forty-two (27%) recommendations were not supported by research evidence or cited expert opinion.

3. Researchers

We reviewed the outcomes and outcome measures reported in all randomised controlled trials (RCTs) of surgical interventions for endometriosis. We assessed the relationship of the outcome quality with methodological quality, year of publication, commercial funding, and journal impact factor.

We identified a total of 54 RCTs with 5427 participants reported 164 outcomes and 113 outcome measures. The three most reported primary outcomes were dysmenorrhea (10 outcome measures; 23 trials), dyspareunia (11 outcome measures; 21 trials), and pregnancy (3 outcome measures; 26 trials). The quality of outcome reporting was measured and the median score was 3 (interquartile range 4-2) and methodological quality 3 (interquartile range 5-2). Multivariate linear regression demonstrated a correlation between outcome reporting quality with methodological quality ($\beta=0.325$; $p=0.038$) and year of publication ($\beta=0.067$; $p=0.040$). No relationship was demonstrated between outcome reporting quality with journal impact factor ($Rho=0.190$; $p=0.212$) or commercial funding ($p=0.370$).

Discussion

1. Patients: there are no websites which provide high quality, accurate, and credible health information pertaining to endometriosis. Currently, websites contain limited amounts of information which are skewed towards the diagnosis of endometriosis. In the unlikely event that a website reports high quality, accurate, and credible health information, it is typically written in language that is challenging for a lay audience to comprehend.

2. Clinicians: there is significant variation in endometriosis guidelines. No guideline followed the standardised approach to guideline development advocated by AGREE-II guidelines. The involvement of women with endometriosis varied significantly. The consensus method for recommendation development was clearly described in only two guidelines. No guideline addressed endometriosis care in a low-resource setting. The funding-sources and conflicts of interest were poorly described with competing interests frequently not reported. A total of 152 separate recommendations exist across seven guidelines, only ten recommendations (7%) are comparable across guidelines. With differences in guideline development methods it is not surprising to find there was a paucity of comparable recommendations with wide intra-guideline variation in the supporting evidence.

3. Researchers: there was a lack of association between journal impact factor and outcome reporting quality. This finding may suggest that journal editors prioritise those studies with sound methodological quality or favourable results ahead of outcome reporting quality. Alternatively, this could be the result of outcome reporting bias. This could involve the selection of 'cherry picked' attractive results for submission without negative or inconclusive results. However, this is difficult to prove or negate without a set of core outcomes. The long term effect of outcome reporting variation is the restriction to produce meaningful conclusions. This limits the usefulness of research to inform clinical practice

These series of reviews have demonstrated that poor outcome reporting in clinical trials can lead to inconclusive and varied clinical guideline recommendations supported by minimal evidence. The knock on effect leads to a drip feeding of poorly generated clinical information being disseminated online to patients.

As clinicians, researchers and patients we must acknowledge that systematic reviews and meta-analyses are the highest quality research that can be used to implement evidenced based medicine, yet outcome reporting diversity restricts the combination of results for meta-analysis. This is of particular concern to health economists as two thirds of the annual health related disease costs for patients with endometriosis (€9579) are attributed to loss of productivity. Without harmonised outcomes the development of new, effective treatment modalities for women with endometriosis will not be achieved.

Conclusion

Variation in outcome reporting leads to multidirectional research that lacks comparability and threatens patient care. There is clear and evident need for the harmonisation of patient centered clinical outcomes through the development of a core outcome set in endometriosis.

The selection of pre-defined appropriate outcomes and outcome measures within endometriosis is necessary to limit bias and enhance patient centred care. The production and implementation of a core outcome set would help to address these concerns. A core outcome set is a collection of well-defined, discriminatory, and feasible outcomes that are the minimum measured endpoints to be reported by a trial or a systematic review. This does not restrict a trial or systematic review to the core outcome set however, it is envisaged that in most trials, the primary outcome would be selected from the core outcome set. The COMET Initiative was launched in January 2010. This aims to address the lack of standardised outcomes by aiding researchers with the prospective registration and development of core outcome sets.

Impact to Patients' Health

The work performed during my Thesis led a collaborative project with Cochrane Gynaecology and Fertility.

We developed a core outcome set to standardise outcome selection, collection, and reporting across future endometriosis research.

Healthcare professionals, researchers, and women with endometriosis collaborated in an open and transparent process using formal consensus development methods. A long list of potential core outcomes was developed by undertaking a comprehensive and systematic review of endometriosis trials. Potential core outcomes were entered into a modified Delphi method to identify consensus outcomes. These outcomes were entered into a modified Nominal Group Technique to identify the final core outcome set for endometriosis.

From the review of randomised controlled trials we generated a long list of 89 potential core outcomes were entered into a modified Delphi method. Three hundred and fifty-four participants, including 116 healthcare professionals, 32 researchers, and 206 women with endometriosis, representing 25 countries, participated in a two round Delphi survey. One hundred and sixteen participants (33%) withdrew from the survey. Eighteen consensus outcomes were entered into a modified nominal group technique. Eight healthcare professionals, six researchers, and 10 women with endometriosis, representing seven countries, added another 10 outcomes for consideration, and finally prioritised three core outcomes for trials evaluating treatments for pain and other symptoms associated with endometriosis (overall pain, improvement in the most troublesome symptom, and quality of life), eight core outcomes for trials evaluating treatments for infertility associated with endometriosis (viable pregnancy confirmed by ultrasound, pregnancy loss including ectopic pregnancy, miscarriage, and stillbirth, live birth, time to pregnancy leading to live birth, gestational age at delivery, birth weight, neonatal mortality, and major congenital abnormalities), and two core outcomes applicable to all trials (adverse events and patient satisfaction with treatment).

The biggest challenge will be embedding the core outcome set within future endometriosis research. This could make a significant contribution to advancing the usefulness of research to inform clinical practice, enhance the care women with endometriosis receive, and improve clinical outcomes.

ES28-0683 - P277

E-Poster

An evaluation of laparoscope handling: a view from a different angle.

Angharad Jones¹, Caryl Thomas¹, Anthony Griffiths¹

¹University Hospital of Wales, Obstetrics and Gynaecology, Cardiff, United Kingdom

Background

Traditionally routine minimally invasive gynaecological surgery in the UK is conducted using a zero degree laparoscope, with the 30 degree scope utilised by more sub-specialist laparoscopic surgeons. The control and quality of laparoscopic views is operator dependent, often the job of the most junior member of the team. We conducted a study to evaluate laparoscope handling by gynaecology trainees comparing the zero and 30 degree scope for time, accuracy and range of vision.

Methods

20 trainees at various stages of training completed tasks using a box trainer to navigate targets placed at different locations, depths and orientations. They were scored on time, error and range of vision. Error was recorded by assessment of maintaining the horizon, optimal distance from the target and a centred image.

Results

Trainees were more familiar with the zero degree laparoscope, achieving the allocated tasks in the fastest time and with the fewest errors compared to the 30 degree scope. When using the 30 degree scope trainees were able to achieve greater range of vision, but after longer spatial adaptation.

Conclusions

This study highlights the importance of increased familiarisation and acquisition of skills by gynaecology trainees with the 30 degree laparoscope to facilitate improved laparoscopic views and surgical efficiency during complex minimally invasive pelvic surgery.

ES28-0684 - P278 E-Poster

Outpatient hysteroscopic polypectomy using Resectr.

Angharad Jones¹, Caryl Thomas¹, Bruen Elizabeth¹, Richard Penketh¹

¹University Hospital of Wales, Obstetrics and Gynaecology, Cardiff, United Kingdom

Background

This video demonstrates effective outpatient hysteroscopic polypectomy using Resectr in a woman presenting with postmenopausal bleeding.

Methods

The history is of a 57 year old para 4 woman, who presented with postmenopausal bleeding. She underwent a transvaginal ultrasound, which suggested an endometrial polyp.

A diagnostic hysteroscopy via a vaginoscopy approach was performed using the Bettocchi 5mm hysteroscope. The hysteroscopic views showed a large polyp arising from the posterolateral wall of the uterus. Using saline irrigation, the single use Resectr was inserted through the operating channel and used to mechanically morcellate the polyp.

The Resectr is a non-powered, manual hand held tissue removal device consisting of a non-oscillating outer cannula and an internal rotating oscillating blade. Continuous outflow vacuum aspiration of irrigation fluid ensures good visualisation of the pathology with tissue being removed from the field of vision keeping the surgical field clean and clear.

The morcellated specimen was collected from the outflow channel in a tissue trap and sent for histopathology analysis, showing benign endometrial polyp.

Results

This case demonstrates the advantages of using Resectr. There is minimal requirement for cervical dilatation or local anaesthetic cervical block due to the thin 5 French outer diameter allowing use through a 5mm hysteroscope operating channel, rendering the procedure more comfortable for the patient. The saline irrigation distension media reduces the risk of complications from fluid overload. There is no use of high frequency current thus reducing the risk of uterine perforation.

The clear views of the operating field allow a shorter operating time, which can be performed in the outpatient setting. The simple handheld equipment reduces set up time with mechanical, efficient and visualised tissue extraction. This equipment facilitates a one-stop "see and treat" solution for women undergoing hysteroscopy with findings of endometrial polyps. It reduces the need for follow-up, repeat or more invasive procedures.

Conclusions

Outpatient hysteroscopic polypectomy using Resectr is a safe, practical, patient-friendly and cost-effective option for treatment of endometrial polyps.

<https://esge.covr.be/cmdocumentmanagement/conferencemanager/documents/api/getdocument/5291/cmabstsms/000092310/cc8978bf51bd1ad2bed894968589aa052ca399a15d025f480d8e615a1251195a>

ES28-0685 - P279

E-Poster

Laparoscopic excision of ovarian remnant causing chronic pelvic pain

Angharad Jones¹, Caryl Thomas¹, Richard Penketh¹

¹University Hospital of Wales, Obstetrics and Gynaecology, Cardiff, United Kingdom

Background

A 38-year-old G0 was diagnosed with endometriosis aged 17, subsequently undergoing 37 laparoscopies for pelvic pain. Total laparoscopic hysterectomy and bilateral salpingoophorectomy was performed aged 32, reported as technically difficult due to deep infiltrating endometriosis and dense adhesions. She continued to suffer with pelvic pain, having multiple admissions with subacute small bowel obstruction and becoming opiate dependent. A trial of progesterone and GnRH was unsuccessful due to side effects. In 2017 ultrasound showed a cystic structure in the right pelvis, suggesting ovarian remnant confirmed by FSH and oestradiol levels.

Methods

Laparoscopic adhesiolysis and excision of ovarian remnant was scheduled and Clomiphene 50mg prescribed 2 weeks preoperatively to stimulate the ovarian tissue, aiming to facilitate visual identification and excision. Intraoperative ultrasound demonstrated the desired effect of increased ovarian volume. On entry there were dense adhesions obliterating the pelvis. Methodical adhesiolysis was achieved with a mixture of blunt dissection and monopolar energy. The ovarian remnant was visualised in the right pelvis surrounded by thickened peritoneum. The ureter was identified, unexpectedly pulled medially by bowel adhesions. Ureterolysis was performed down to the ovarian remnant, which was dissected at its lateral border to allow the ureter to fall to a lateral place of safety. A finger in the vagina allowed further counter-traction of tissues and visualisation of the medial borders. The ovarian remnant was safely excised and placed in a retrieval bag, with the cystic elements aspirated to reduce the specimen volume, facilitating removal via the 5mm right iliac fossa port incision.

Results

The remnant ovarian tissue was excised in its entirety, with the pelvic anatomy restored and the bowel mobile at the end of the procedure. The patient was discharged within 24 hours postoperatively and has had significant improvement in symptoms on follow-up.

Conclusions

Consider remnant ovarian tissue in endometriosis patients who have had prior difficult hysterectomy and bilateral salpingoophorectomy who report continued pain. Clomiphene effectively enlarges remnant ovary to aid identification and facilitate complete excision. Before excising pathology, when presented with distorted anatomy it is important to identify and restore key anatomical structures to ensure the safest approach.

<https://esge.covr.be/cmdocumentmanagement/conferencemanager/documents/api/getdocument/5298/cmabstms/000092310/979aa94fa589b58f1d0f7d3e451abb017d02704126ef31301380ae8591600755>

ES28-0003 - P280

E-Poster

Endometrioma resections in infertility – where are we today?

Liselotte Mettler¹

¹University Hospitals Schleswig-Holstein- Campus Ki, Dept. OB/GYN, Kiel, Germany

Background

According to good medical surgical practice “endometriomas,” which occur frequently, were mostly surgically excised or opened and ablated. How do we proceed in infertility patients? Do we always enucleate endometriomas or try to get a patient pregnant without touching the endometrioma?

Methods

At the Department of Obstetrics and Gynecology, University Hospitals Schleswig Holstein, Kiel, we analyzed 550 patients with ovarian endometriotic cysts undergoing laparoscopic conservative excision or ablation according to ESGE, ESHRE and WES recommendations.

Results

The evaluations of questionnaires in our study with a final return rate of 52.5% left 289 patients in the follow-up study. Factors associated with recurrence of dysmenorrhea were younger age ($P < .01$), nulliparity ($P < .05$), and larger cyst size ($P < .05$). Previous laparoscopic surgery for ovarian endometrioma ($P < .05$) was the only significant risk factor for recurrence of pain that was found. One hundred ninety-seven patients were initially diagnosed with endometriomas at the time of surgery and of those 47 patients showed recurrent ovarian endometrioma (23.9%) in the follow-up period.

Patients with preoperative pain showed a significantly higher recurrence rate (log-rank test $P = .013$). Another statistically significant risk factor for endometrioma recurrence was preoperative dysmenorrhea (log-rank test $P = .013$). Other risk factors were larger cyst size (> 8 cm; rate of recurrence was 33.3% [5 of 15] vs 16.3% [15 of 92] in cyst size 5–8 cm and 16.8% [24 of 143] in cyst size < 5 cm), younger age at surgery (< 25 years: 6.4% [3 of 47] in the recurrence cohort vs 2.8% [8 of 289] in the follow-up cohort), and preoperative cyst rupture (rate of recurrence was 28.6% [2 of 7]).

The wish for postoperative pregnancy was found by 111 of 289 patients (38.4%). Combined surgical and hormonal treatment was given to 61 of 111 patients (55.0%), whereas surgery alone was performed in 50 of 111 patients (45.0%). Among these patients, the postoperative spontaneous pregnancy rate was 54.1% (60 of 111). A statistically significant difference ($P < .001$) between combined surgical and hormonal therapy and exclusive surgery was observed. If a patient has been pre-operated or has already a decreased ovarian reserve, has no pain and addresses our IVF Center with infertility of more than 2 years and an ovarian cyst of up to 5 cm, we follow strictly 5 key considerations: Symptoms, size of the cyst and accessibility of the ovary, past medical and surgical history, age and ovarian reserve and - last not least - the wish of the patient.

Conclusions

Patients with ovarian endometriomas and a desire for pregnancy seem to profit from additional postoperative medical treatment. If a patient desires IVF, has no pain, has an AMH in the normal or lower range definitely IVF-ICSI should be pursued and the endometrioma should be approached surgically later.

<https://esge.covr.be/cmdocumentmanagement/conferencemanager/documents/api/getdocument/4923/cmabstms/000013260/9831322473482759f5ff540ac283e67afc097f199dec9458ba68377cc8e107d4>

ES28-0441 - P281

E-Poster

Role of minimal access surgery for large fibroid uterus removal using principles of avascular planes in surgical dissection. A safe technique of retro peritoneal dissection

Nahid Gul¹

¹*Wirral University Teaching hospital, MIS- Gynaecology, Gayton, United Kingdom*

Background

Traditional surgical method of removing uterus with large fibroid mass is still undertaken with mid-line incision for safe dissection and decreasing blood loss. Large uterus with fibroid reaching above umbilicus are technically difficult with operative difficulties experienced by many surgeons. High conversion rates from laparoscopic route to open laparotomy have been reported for cases with large uterine mass. We present surgical procedure with video demonstration of case series of patients treated with minimal access surgery for large fibroid uterus.

Methods

Case series presentation with description of surgical planning and operative video presentation. Operative, perioperative and post operative outcomes are presented.

Results

We successfully completed all cases planned for minimal access surgery for large fibroid uterus using our method of surgical dissection in avascular planes and ligation of uterine arteries at the origin with minimal blood loss. There were no conversions, complications, return to theater in these cases series managed with our surgical strategy.

Conclusions

Minimal access surgery with appropriate training and advanced surgical skills can be used in most cases believed not to be suitable for minimal access surgery. Presentation and video demonstration will be a good opportunity to share our experience.

<https://esge.covr.be/cmdocumentmanagement/conferencemanager/documents/api/getdocument/5127/cmabstms/000019900/59f9a85ef2119a536816e215def9a8a50a6e0f8dd9cb99aaa8fc2b5bc131f57d>

Laparoscopic reconstruction of the cesarean section niche – a comparative report of three successive cases

Rastko Maglic¹, Branka Nikolic², Dejan Stojanovic³, Predrag Jokanovic⁴, Dragana Maglic⁵

¹Medical Faculty University of Belgrade- University Clinic Narodni front Belgrade, MIG Department, Belgrade, Serbia

²Medical Faculty University of Belgrade- University Clinic Narodni front Belgrade, Department of Conservative Gynecology, Belgrade, Serbia

³University Clinic Narodni front Belgrade, Department of Infertility, Belgrade, Serbia

⁴University Clinic Narodni front Belgrade, Department of Conservative Gynecology, Belgrade, Serbia

⁵Medical Faculty University of Belgrade- University Clinic Narodni front Belgrade, High Risk Pregnancy Ward, Belgrade, Serbia

Background

A symptomatic C - section niche (isthmocele) is a relatively rare complication of C -sections (apr. 1,9% of cases). Considering that a C - section is one of the most common surgical procedure in gynecology (20 to 30 % of deliveries in Serbia) it is still not such a rare complication.

In 2018/2019 three patients with C - section complications requested operative treatment for this disorder. They had one previous delivery by C - section. Two had secondary infertility problems and all three had a significant decrease in life quality. They had prolonged menstrual periods, with brown discharge, lasting up to day 15 of the cycle. Two had dyspareunia and one had strong pains after intercourse.

On Ultrasound exam the niche thickness in two of them was 3mm, and one had different thickness on the left side of the niche (5mm) and right side (2mm). The second patient had a previous attempt at hysteroscopic correction in 2017.

They had different anamnesis prior to establishing the correct diagnosis. The first patient spent 4 years, being diagnosed in Serbia, Bosnia and Germany before establishing the proper diagnosis. The second patient recognized her symptoms on an internet forum designed for patients – and went on to search for a doctor familiar with the topic. The third patient came because of strong pains during and after intercourse that deteriorated her life quality. This patient also had urinary discomfort as the bladder flap was elevated almost to the fundus of the uterus.

Methods

All three were prepared and operated by the same surgical team. All of them were operated laparoscopically. First the adhesions between the uterus and the bladder were removed, then the bladder flap was separated and developed. Inserting a uterine probe transvaginally exposed the niche. Then using a Ultracission device the niche was opened (resected). Finally the myometrium was reconstructed using 2.0 monofilament running suture in two layers. In two patients the bladder flap was repositioned, but in the third a third layer was reconstructed on the surface of the uterus, and the flap was not repositioned in order to prevent the urinary and dyspareunia complications she previously complained about. Average duration of the procedure was 2h.

Results

All three postoperatively had a checkup after their menstrual cycle. The thickness of the niche varied from 7 to 9 mm. Symptoms in all three of them have been completely resolved. So far only the first patient is preparing for an IVF pregnancy. The second patient is still planning when to get pregnant, and the third does not intend to.

Conclusions

It can be concluded that laparoscopic reconstruction of the C - section niche is a demanding but feasible technique, and is very beneficial to patients with symptoms.

ES28-0659 - P285
E-Poster

Robotic vs. laparoscopic real-time near-infrared imaging with indocyanine green for detection of occult endometriosis lesions: a case-control study

Luigi Carlo Turco¹, Diego Raimondo², Francesco Cosentino¹, Giovanni Scambia³, Renato Seracchioli², Giuseppe Vizzielli³

¹Fondazione di Ricerca e Cura Giovanni Paolo II- Università Cattolica del Sacro Cuore, Division of Gynecologic Oncology, Campobasso, Italy

²Gynecology and Human Reproduction Physiopathology, S.Orsola Malpighi Hospital- University of Bologna, Bologna, Italy

³Fondazione Policlinico Universitario "Agostino Gemelli" IRCCS- Università Cattolica del Sacro Cuore, Dipartimento Scienze della Salute della Donna- del Bambino e Sanità Pubblica, Roma, Italy

Background

Comparing perioperative results of robotic near-infrared radiation (NIR) imaging after intravenous injection of indocyanine green (ICG) (Cases) with a matched series of laparoscopic NIR-IGC (Controls) in symptomatic women with pelvic endometriosis.

Methods

A multicenter retrospective case-control study. From January 2016 to March 2018 the records of patients with endometriosis admitted to surgery at the Catholic University of Rome (controls) and at the University of Bologna (cases) were retrospectively analyzed. Robotic NIR-IGC (Cases) and Laparoscopic NIR-IGC (Controls) for endometriosis were performed. Surgical data of the procedures were collected.

Results

Twenty cases were matched as close as possible with 27 control subjects. The suspected lesions identified both with the white light (WL) and the NIR-IGC were 116 and 70 in the Controls (Laparoscopy) and Cases (Robot), respectively. Among them, 16/116 controls (13.8%) and 12/70 cases (17.1%) were identified only with NIR-IGC imaging and collected as occult lesions ($p=0.536$). The overall NIR-IGC lesion identification showed PPV of 97.8%, NPV of 82.3%, sensitivity of 82.0%, specificity of 97.9% for Control group and PPV of 100%, NPV of 97.1%, sensitivity of 97.1%, specificity of 100% for Cases, confirming that NIR-IGC imaging is a good diagnostic and screening test ($p=0.643$ and $p=0.791$, according to the Cohen kappa tests, respectively for laparoscopic and robotic group).

Conclusions

The few differences registered do not seem to be clinically relevant, thus making the two procedures comparable. Further prospective trials are needed to confirm our results.

<https://esge.covr.be/cmdocumentmanagement/conferencemanager/documents/api/getdocument/5150/cmabstms/000076020/fc42abb8e4c1446a3e42f286c1fbaac42ce69cdd19e3b16ef7718a3c28d0ee33>

ES28-0046 - P287
E-Poster

UCL1 promotes lymph nodes metastasis in SCNEC via reducing PROX1 ubiquitination

Zhang Yunqiang¹, Ding Jinxin¹, Zhang Xuyin¹, Hua Keqin¹, Chen Yisong¹

¹The Obstetrics and Gynecology Hospital- Fudan University, Gynecology, Shanghai, China

Background

Small cell neuroendocrine carcinoma of the cervix (SCNEC) of the cervix has a low incidence but poor prognosis. This study is to explore the differential gene expression in cervical small cell neuroendocrine carcinoma and try to screen potential therapeutic targets and study their biological functions and mechanisms.

Methods

Gene expression profiles were used to detect gene expression in 3 SCNEC patients, 3 cases with cervical adenocarcinoma and 3 cases with squamous cell carcinoma. 4 candidate genes were screened out and verified by

immunohistochemical (IHC) method in 16 cases of SCNEC, 30 cases of cervical squamous cell carcinoma and 30 cases of cervical adenocarcinoma. The clinical significance of one of the candidates (UCHL1) in SCNEC was analyzed by SPSS 22.0.

The biological functions of UCHL1 in SCNEC tumor was detected on a primary culture SCNEC cell line with siRNA interference and over-expression plasmid transfection technologies. Co-expression network analysis and immunoprecipitation technology were used to explore its mechanism

Results

UCHL1, PROX1, CRMP5 and TM4SF1 were identified as preliminary candidates. IHC results showed that the positive rates of UCHL1 and CRMP5 in SCNEC, squamous cell carcinoma and adenocarcinoma were significantly different (87.5% vs 10.0% vs 10.0%, $P = 0.000$; 43.8% vs 10.0% vs 6.7%, $P = 0.002$), while no significant difference for PROX1 and TM4SF1 ($P=0.609$, $P=0.830$). Clinical data showed that SCNEC patients with high expression of UCHL1 were associated with lymph node metastasis ($p=0.003$). In dead patients, UCHL1 high expression groups were likely to have shorter survival (median survival time was 8+1.50 vs 13+1.5 months, $P=0.055$).

In vivo, CCK8 and plate assembly assay showed that the proliferation of tumor cells in overexpression group was significantly lower than that in downregulation group ($P < 0.01$); flow cytometry showed that the proportion of G2/M phase cells in downregulation group was significantly increased ($P < 0.01$). Scratch and Transwell cell invasion tests indicated that the migration and invasion ability of tumor cells in overexpression group was significantly higher than that in downregulation group ($P < 0.01$); co-expression network suggested that PROX1 might interact with UCHL1, and immunoprecipitation and Western blot test verified that the ubiquitination level of PROX1 decreased significantly after overexpression of UCHL1 ($P < 0.01$).

Conclusions

UCHL1 is highly expressed in cervical small cell neuroendocrine tumors, which is associated with lymph node metastasis. It can promote cell migration and invasion via reducing PROX1 ubiquitination.

ES28-0030 - P288

E-Poster

Surgical treatment of early endometrial cancer: laparoscopy vs. laparotomy

Dimitrios Zouzoulas¹, George Pados¹, Dimitrios Tsolakidis¹, Alexis Papanikolaou¹, Stavroula Pervana², Thomas Zaraboukas³

¹Papageorgiou General Hospital, 1st Department of Obstetrics & Gynecology - AUTH, Thessaloniki, Greece

²Papageorgiou General Hospital, Anatomical Pathology Laboratory, Thessaloniki, Greece

³Interbalkan Medical Center, Anatomical Pathology Laboratory, Thessaloniki, Greece

Background

Endometrial cancer occurs mainly in menopause and usually (75%) it is diagnosed at FIGO Stage I. The surgical treatment of choice is total hysterectomy, bilateral salpingo-oophorectomy, peritoneal washing and systematic pelvic lymphadenectomy. The aim of this study is to compare laparoscopy with laparotomy for the surgical approach of early endometrial cancer.

Methods

We retrospectively reviewed the medical records of all patients that were treated for early endometrial cancer (January 2012 – December 2017), the clinicopathological characteristics and oncological results were described.

Results

Out of 177 cases of early endometrial cancer, 75 patients met the inclusion criteria. 19 (25%) were treated with laparoscopy (Group A) and 56 (75%) with laparotomy (Group B). The mean age of Group A was 59.8±12.8 and Group B 63.5±8.5, while most of the patients were FIGO Stage IA with grade 2 endometrioid carcinomas. Statistically significant difference was observed in BMI, Group A:27±2.3 & Group B:32.8±8, in surgery duration(min), Group A:200±15 & Group B:130±30, in hospital stay(days), Group A:1 & Group B:6±1, and in distant postoperative complication, Group A:1 & Group B:15. On the other hand, there was no statistically significant difference in the number of excised pelvic lymph nodes [Group A: (Right)12.1±5.5 / (Left)10.3±3.4, Group B: (Right)13.4±5.1 / (Left)11.8±4.7].

Conclusions

Laparoscopy is a safe and effective surgical approach for early endometrial cancer. It presents with shorter hospital stay, less postoperative complications, while the number of excised pelvic lymph nodes is similar to laparotomy. Possible limiting factors are high BMI, longer surgery duration and patients with severe comorbidities.

<https://esge.covr.be/cmdocumentmanagement/conferencemanager/documents/api/getdocument/4953/cmabstsms/000152190/9c76b0fd373ccc39628335cc9089fb4da497cdc59b24bb6ec8e100d7177433dd>

ES28-0034 - P289

E-Poster

Effectiveness of gabapentin and ramosetron combination for postoperative nausea and vomiting after laparoscopic hysterectomy

Min Hyung Jung¹

¹*Kyung Hee University Hospital, OB, Seoul, Korea- Republic Of*

Background

To evaluate the antiemetic effectiveness of gabapentin and ramosetron in women who underwent laparoscopic hysterectomy with benign uterine diseases. The patients received fentanyl-based patient-controlled analgesia after surgery.

Methods

The patients were divided into two groups. One group received 300 mg oral gabapentin before anesthesia, and the other group received a combination of 300 mg oral gabapentin and 0.3 mg intravenous ramosetron at the end of surgery.

Results

Postoperative nausea, vomiting, additional antiemetic drug use, pain, analgesic requirements and adverse effects were assessed. There were no significant differences in the incidence of nausea and vomiting events, use of additional antiemetics, use of analgesics, and postoperative pain scores. Within 2 days observation period after operation, the incidence of complete control of PONV and no additional antiemetics use was significantly higher in combination group.

Conclusions

The combination use of gabapentin and ramosetron is more effective method for preventing PONV after laparoscopic hysterectomy

ES28-0093 - P290

E-Poster

Benefits of office hysteroscopy in retain products of conception - uterine perforation in an operative hysteroscopy for a placental polyp: a case report

Isabel Blanco Herraes¹, Rayza Gabriela Gonzales Gamarra¹, Raquel Sanz Baro¹, Laura Pineda Dominguez¹, Isabel Ferreira Borrego¹, Carmen Alvarez Gil¹

¹*Fundacion Jimenez Diaz, Obstetrics and Gynecology, Madrid, Spain*

Background

We report a case of a 44 year-old woman, G4L2Ab1, with no relevant past medical history, which pregnancy was obtained by IVF (in vitro fertilization, egg donation). At 15 weeks of pregnancy she was diagnosed of a complex fetal malformation so and amniocentesis was performed. The patient decided to end the pregnancy at 18 weeks and oral Mifepristone followed by vaginal misoprostol was given to her producing complete fetal and placenta expulsion. The genetic study was negative.

After 13 days, the patient came back to emergency for abnormal bleeding and the scan showed a big endometrium of 35 mm with a Beta HCG de 105mUI/ml. Expectant management was decided with a new control 72 hours later and

the new doppler ultrasound showed a placental polyp of 30 mm. For this diagnosis a surgical hysteroscopy was performed 10 days later, with a resectoscope and during the hysteroscopy trying to remove part of the polyp with a surgical curette an uterine perforation took place, so the hysteroscopy was interrupted leaving the majority of the polyp inside.

The patient came for a control in five days with normal levels of prolactin and beta HCG < 2mIU/ml and the results of the previous hysteroscopy confirm a placental polyp with chronic myometritis so it was decided conservative management with antibiotics and hormonal therapy till a second time of hysteroscopy. An office hysteroscopy was performed in 45 days and the rest of the polyp was removed with bipolar energy and versapoint without complications or anesthesia. The histologic result confirm the same diagnosis previously established and control one month after surgery was normal.

Methods

Conclusions

The incidence of placental polyps is really low, but it is necessary to think about it in a patient with an abnormal bleeding after a delivery or late miscarriage., even is infrequent with an incidence of 0,25%

It is important to know that the final diagnosis is histologic.

About the treatment is clear there is a benefit for surgical treatment and it would be better to perform an office hysteroscopy or using a miniresectoscope to prevent mayor complications associated to resectoscope.

<https://esge.covr.be/cmdocumentmanagement/conferencemanager/documents/api/getdocument/5211/cmabstms/0000164800/8a5674d8fd19ae250c2d84a27d8e74129a31fa1afad010718cfc7dcd559cd051>

ES28-0533 - P291

E-Poster

Deep infiltrating endometriosis surrounding the left ureter in a pre-menopausal woman

Ahmet Tevfik Yoldemir¹

¹*Marmara University Hospital, Obstetrics and Gynecology, Istanbul, Turkey*

Background

Deep infiltrating endometriosis and possible adenomyosis might be cause of dyspareunia and abnormal uterine bleeding during midlife. We present a woman having deep infiltrating endometriosis surrounding the left ureter.

Methods

47 year old woman with abnormal uterine bleeding and dyspareunia was admitted. The patient's rectovaginal exam revealed tenderness at pouch of Douglas. Her ultrasound showed left endometrioma (5x5 cm) and possible adenomyosis. During the laparoscopy, the pouch of Douglas was obliterated. The left ovary had an endometrioma measuring 5 cm in diameter. It was densely attached to the pelvic side-wall. The right ureterolysis was done. Left ureterolysis was started at the level of the pelvic brim. There was extrinsic ureteral endometriosis starting at the level where the ovary adhered to the pelvic side-wall. The left ureter was constricted by endometriotic fibrosis. Right and left pararectal spaces were developed. Then rectovaginal space was opened. The endometriotic tissue was removed meticulously from the ureter. Total laparoscopic hysterectomy, left salpingoophorectomy, right salpingectomy were done. Urologist was invited and he placed ureteral stent through the left ureter for postoperative prevention of possible inflammatory process which could have occurred after extensive endometriosis excision.

Results

The ureteral stent was removed before discharge. The patient was discharged on postoperative day 2. Abdominal ultrasound a week later showed grade 1-2 hydronephrosis. IVP two weeks later showed both ureters with normal calibers and widths. One week later Tc-99m MAG-3 renal scintigraphy revealed normal perfusion and extraction functions. The final pathology confirmed adenomyosis and endometriosis over the left ureter

Conclusions

Ureteral endometriosis (UE) is infrequent accounting for less than 0.3 % of all types of endometriosis [Fertil Steril 1996; 66:920-4]. Due to the rare incidence and absence of specific symptoms of UE, the disease is overlooked and presents challenge in diagnosis and treatment. Preoperative diagnosis is important both for preventing risk of renal

dysfunction and managing surgical approach [Urol J 2014; 11:1806-12].

Patients with ureter involvement are asymptomatic in approximately 30% of cases and due to the non-specific symptoms and silent obstruction, they have the risk of progression to renal dysfunction if untreated [Diagn Interv Imaging 2015; 96:373-81].

On MRI, ureteric wall invasion is evaluated according to the contact circumference between the ureter and the endometriosis lesion: The lesion is classified extrinsic if the contact circumference is less than 180 degrees; intrinsic if the circumference is over 360 degrees [Diagn Interv Imaging 2015; 96:373-81].

In our case even though the endometriotic nodule with its extension as plaque formation was severely adherent to the ureter it was possible to excise the diseased tissue off of the ureter without the need for segmental ureterectomy and later re-anastomosis.

Perimenopausal woman with deep infiltrating endometriosis involving the ureter extrinsically benefit from laparoscopic endometriosis surgery.

<https://esge.covr.be/cmdocumentmanagement/conferencemanager/documents/api/getdocument/5149/cmabstms/0000113890/ddbfff1baab0fb89e9402533a81bdc74c275d06535dacc9f00bd93a2442c41010>

ES28-0163 - P294

E-Poster

The factors predicting lymph node metastasis in patients with borderline ovarian tumor

Menglei Zhang¹, Fangyue Zhou¹, Yuan He¹, Jingxin Ding¹, Keqin Hua¹

¹The Obstetrics and Gynecology Hospital of Fudan University, Gynecology, Shanghai, China

Background

This study was aimed to evaluate the risk factors of lymph node metastasis in patients with borderline ovarian tumor (BOT) who were operated on in a single institution and the necessity of routine lymphadenectomy for borderline ovarian tumor.

Methods

Two hundred forty-eight patients with borderline ovarian tumor who underwent lymphadenectomy in the Obstetrics and Gynecology Hospital of Fudan University, Shanghai, China between February 2001 and December 2018 were retrospectively studied. Patients' clinical manifestations, operation findings and pathological characteristics were compared between the patients who presented lymph node involvement and those who did not. Univariate and multivariate analyses were used to assess the risk factors for lymph node involvement in these patients.

Results

Of these 248 patients on whom lymphadenectomy was performed, 21 cases showed lymph node positive, whereas the remaining 227 patients did not. The tumor histology of 95.2% patients with positive lymph node is serous. The lymph node positive(LNP) group had higher proportion of nulliparous patients(42.9% vs 21.1%, $P=0.024$) and premenopausal patients(95.2% vs 71.8%, $P=0.018$) than the lymph node negative(LNN) group. The median preoperative serum CA125 was higher in the LNP group than the LNN group(529.3 ± 386.6 vs 159.9 ± 355.2 , $P<0.001$). The LNP group had larger tumor diameter than the LNN group(10.7 ± 5.9 vs 8.1 ± 5.6 , $P=0.046$). The 81% patients in the LNP group had bilateral tumor while 26.4% patients in the LNN group($P<0.0001$). The LNP group had higher incidence of macroscopic tumor on ovarian surface(66.7% vs 6.6%, $P<0.0001$) and macroscopic lesions(>1cm) in the pelvic or abdominal cavity than the LNN group(57.1% vs 5.3%, $P<0.0001$). Multivariate logistic regression models showed that risk factors for LNP were tumor diameter ≥ 10 cm($P=0.003$), macroscopic tumor on ovarian surface($P<0.001$), and macroscopic lesions(>1cm) in the pelvic or abdominal cavity($P=0.005$). The lymph node metastasis rate was very low in patients with tumor diameter<10cm(4.7%), or patients without macroscopic tumor on ovarian surface(3.2%) and macroscopic lesions(>1cm) in the pelvic or abdominal cavity(4%).

Conclusions

Tumor diameter ≥ 10 cm, macroscopic tumor on ovarian surface and macroscopic lesions(>1cm) in the pelvic or abdominal cavity were risk factors significantly affecting the lymph node metastasis of BOT by both univariate and multivariate analysis. Hence, patients without these risk factors may not need routine lymphadenectomy.

<https://esge.covr.be/cmdocumentmanagement/conferencemanager/documents/api/getdocument/4999/cmabstms/0000132230/2cb194f22c2ead1570a988e4dbd7e5cea9592091a89a8689858a8d96cc71ee86>

ES28-0168 - P295
E-Poster

A comparison of efficacy between postoperative medical treatment and expectant treatment in relieving dysmenorrhea after conservative laparoscopic surgery for deep-infiltrating endometriosis accompanied by dysmenorrhea

Zhu Qian¹, Liang Yan¹, Jian Zhang¹

¹International Peace Maternity and Child Health Hospital- School of Medicine- Sha, Obstetrics and Gynecology, Shanghai, China

Background

To compare the efficacy of postoperative adjuvant treatment [gonadotropin-releasing hormone agonist (GnRHa) and oral contraceptives pills (OCPs)] with expectant treatment in preventing recurrent of dysmenorrhea following conservative laparoscopic surgery for deep infiltrating endometriosis (DIE) with dysmenorrhea.

Methods

Patients who suffered from dysmenorrhea and received conservative laparoscopic surgery for DIE at the International Peace Maternity and Child Health Hospital between January 2012 and January 2016 were included. After conservative surgery for DIE, either postoperative adjuvant drug therapy (GnRHa or OCPs) was administered for 6 months or expectant treatment according to shared medical decision-making approach.

Results

147 women were found to be study eligible, 46 women were included in the GnRHa group, 42 women in the OCPs group and 45 women in the expectant group. Based on the GEE model. The postoperative dysmenorrhea scores of all 3 groups increased gradually (Wald χ^2 tested the effect of postoperative follow up month, $P=0.000$). However, Wald χ^2 tested the effect of postoperative treatments and showed that VAS scores for dysmenorrhea in the GnRHa and OCPs treatment groups were significantly lower than the expectant group, but there was no difference between the GnRHa and OCPs groups. During the 24 months after surgery, 25 (18.80%) patients experienced recurrent dysmenorrhea. Kaplan-Meier analysis and log-rank tested represented that the cumulative recurrence rate in expectant group (14/45) was higher than that in the hormonal groups (5/46 in the GnRHa group and 6/42 in the OCPs group) ($X^2=7.202$, $P=0.027$), but this was not statistically significant between two hormonal groups ($X^2=0.223$, $P=0.637$). A Cox proportional hazards model illustrated that concurrent adenomyoma, vaginal DIE and high preoperative dysmenorrhea VAS score were independent risk factors recurrent of dysmenorrhea, while postoperative medical treatment manifested positive protective effect.

Conclusions

Compared with expectant treatment, postoperative medical management was more effective in relieving dysmenorrheic symptoms and preventing recurrent of dysmenorrhea. This study provided guiding clinical evidence for the postoperative decision-making process for DIE.

ES28-0202 - P296
E-Poster

Laparoscopic removal of late-onset hematometra with dysmenorrhea and dyspareunia symptoms in a non-communicating uterine horn.

Sadiman Kiykac Altinbas¹, Omer Lutfi Tapisiz¹, Ozlem Moraloglu Tekin¹

¹University of Health Sciences- Etilik Zubeyde Hanim Women's Health Training & Research Hospital, Obstetrics and Gynecology, Ankara, Turkey

Background

We aimed to demonstrate the laparoscopic management of a rudimentary horn case and to emphasize the crucial steps which the surgeon should perform the surgery in a safe way.

Methods

Case Report

Results

A-36-year old patient, G2P2, was admitted to the hospital with a complaint of worsening lower abdominal pain occurring each menses during 8 months. Her external and internal genitalia including the cervix were normal except the-6-cm, accessory, cavitated left uterine mass suggestive of hematometra compressing the urinary bladder without any other genitourinary system pathology shown on the ultrasound examination. Diagnostic hysteroscopy revealed a single cervix without any vaginal malformations and a relative small uterine cavity with a right tubal ostium and the absence of the left tubal ostium. It was decided to remove the left uterine horn by laparoscopic route. The evaluation of the abdominal cavity revealed a-left non-communicating rudimentary horn tightly-resided on the lateral abdominal wall and two normal-looking ovaries and tubes.

In the first step, left salpingectomy was performed taking care of staying close to the tube. In the second step, the vesicouterine septum was divided to dissect the bladder from the cervix and the left uterine horn. In the third step, the broad ligament was fenestrated to lateralize the left ureter and to facilitate the transection of the utero-ovarian pedicle. The retroperitoneum was dissected and tract of the ureter was followed. Posterior peritoneum was also opened to become distant from the ureter and to recess place for the division of the horn by a monopolar hook. After the dissection and coagulation of the left uterine artery on the origin of the left hypogastric artery with the aim to minimize the bleeding while the excision of the uterine horn, the resection of the rudimentary horn was achieved using a monopolar hook. After the control of bleeding and lavage and drainage of the abdominal cavity, the operation was completed successfully. The patient was discharged on the first postoperative day and normal regular menstrual cycles without any pain and complaints during the 6 and 12 months after the surgery were noted.

Conclusions

Although laparoscopic excision of a rudimentary uterine horn seems to be an effective and feasible surgical approach in experienced hands, it should always be remembered that the anatomical landmarks and retroperitoneal space must be defined as the cleavage planes of the uterine horn and unicornuate uterus are not well-defined all the time. The ipsilateral ureter should be dissected as it lies adjacent to the vascular supply of the uterine horn and the ipsilateral uterine artery should carefully be coagulated. The ipsilateral fallopian tube should always be removed to avoid tubal pregnancy and cancerization.

<https://esge.covr.be/cmdocumentmanagement/conferencemanager/documents/api/getdocument/5248/cmabstms/000077000/3ca9149020460273456315eb1748cd668cb57fddb0812e6733987acb06ade322>

ES28-0213 - P297
E-Poster

Comparative cost-minimisation analysis between abdominal and laparoscopic hysterectomies in Greek public hospitals

Charalampos Dimitriadis¹, Elpida Pav², Kostas Athanasakis², Angelos Daniilidis³, Grigoris Grimbizis⁴

¹*Ippokrateio Hospital-Thessaloniki, Delivery Room Department Gynaecological Surgery Department, Thessaloniki, Greece*

²*National School of Public Health – ESDY, Dept. of Health Economics, Athens, Greece*

³*Ippokrateio Hospital- Thessaloniki, B' Obstetrics-Gynaecological Clinic, Thessaloniki, Greece*

⁴*Papageorgiou Hospital- Thessaloniki, A' Obstetric-Gynaecological Clinic, Thessaloniki, Greece*

Background

The present thesis studies the cost of hysterectomy; the most common surgical operation in gynaecology. Its aim is to provide with a comparative study on the operational costs between abdominal and laparoscopic hysterectomy so that the most financially viable approach for public hospitals can be determined.

Methods

The research approach taken in the thesis was twofold: first was the systematic generation of relevant bibliography in relation to the current usage, technical specifications, safety and cost of hysterectomy operations and secondly the collection, studying and analysis of data from two clinical data sets for both types of hysterectomy operations that took place in public hospitals. The data sets allowed for the costs involved on both operational approaches to be broken down in stages, in addition to providing their total operational costs.

Results

The comparative data analysis of the associated costs showed a considerable difference in the average costs involved between the two surgical procedures that were consistent throughout all their comprising stages. The average cost of the abdominal hysterectomy was found 15% more than the average cost of the laparoscopic hysterectomy.

Conclusions

Following the data analysis, our findings were compared to relevant findings provided by the international community. It could be concluded that further study is needed, not only on the financial aspects of hysterectomy but also in relation with its effectiveness. In addition, further study is needed on the current usage and pricing of hysterectomy operations. Both will help with public health policy targets being reached, *i.e.* the most operationally and cost-effective usage of medical resources while improving the health levels of the population.

<https://esge.covr.be/cmdocumentmanagement/conferencemanager/documents/api/getdocument/4932/cmabstms/000164480/08cbf766745fe6432e1418d80e7c299c273c2f02c014f2bdbce5769c4549b031>

ES28-0239 - P298 E-Poster

Minilaprotomy for a rare case of unicornuate uterus with noncommunicating horn with endometrioma with solitary kidney after failed laparoscopy

Mahmoud Abdelrasik¹, Amany Makroum¹, Maher Shams²

¹*Faculty of medicine, Obstetric Gynecology, Mansoura, Egypt*

²*Mansoura University Hospital, Obstetric Gynecology Department, Mansoura, Egypt*

Background

Mullerian duct anomalies result from abnormal formation, fusion or reabsorption of the Mullerian ducts during fetal life. A close embryologic relation exists between the development of the urinary and reproductive organs. Hence, renal tract defects are likely to be found in women with congenital uterine malformation. This report describes the technique of mini-laparotomy for the removal of a non-communicating rudimentary horn together with an associated endometrioma in a patient with absent one kidney.

Methods

The operation was done by minilaprotomy because there was two failed trails with laparoscopy

Results

Minilaprotomy may be suitable approach for dealing with complex uterine anomalies after failure of laparoscopy specially that associated with endometriosis and renal anomalies

Conclusions

Minilaprotomy is suitable surgical approach specially in complicated cases that associated with endometriosis and renal anomalies after failure of laparoscopic approach

<https://esge.covr.be/cmdocumentmanagement/conferencemanager/documents/api/getdocument/5052/cmabstms/000006460/23a4f104f86d5da6f25f4b5ed871fa41c810bc62e138ee457aeb0d08ba48bfa2>

Comparison of polypropylene and polyvinylidene fluoride mesh (Dynamesh) used in laparoscopic sacrohysteropexy

Kirsty Brown¹, Rebekah Wilson-Pearce², Zbigniew Tkacz¹

¹*NHS Tayside, Obstetrics and Gynaecology, Dundee, United Kingdom*

²*University of Dundee, School of Medicine, Dundee, United Kingdom*

Background

Laparoscopic uterine suspension with mesh has been considered the gold standard for uterine prolapse with reduced complication rates and recurrence. However, use of mesh is not risk free and the optimal material has yet to be established. We will compare the efficacy of both polypropylene (PP) and polyvinylidene fluoride mesh (Dynamesh) used in sacrohysteropexy. We aimed to evaluate the safety and efficacy of these two meshes. Robust literature has already been published for Dynamesh indicating superiority over the PP mesh. Our study aims to assess if the use of Dynamesh in our centre translates to better outcomes or not.

Methods

This is a single-centre retrospective analysis of outcomes of all patients undergoing laparoscopic uterine prolapse repair with the use of PP and Dynamesh. We compared 45 cases using PP and 45 cases using Dynamesh. Medical records were identified via the 'OPERA' electronic database. Medical notes were examined for data extraction regarding symptoms, operative morbidity and therapeutic outcomes. The POP-Q scoring system was employed to objectively assess pre- and postoperative pelvic organ prolapse (POP). Information was collated in an Excel spreadsheet for further analysis. Clear written information was provided and choice of mesh offered to all women.

Results

90 patients underwent laparoscopic sacrohysteropexy, 45 had Dynamesh and 45 had PP. 25% had concomitant vaginal or paravaginal repair of anterior/posterior wall across both groups. Parity ranged from 1 to 5. Median operating time was 100 min. Mean hospital stay 1.4 days (1-2). Intraoperative blood loss ranged from 0 to 400ml. There were no cases of mesh erosion, pelvic infection or haematoma in either group. 7% had recurrence of apical prolapse in the PP group, secondary to mesh elongation. All cases in the Dynamesh group have had objective improvement of the uterine prolapse at routine post operative review (POP Q Stage 0). 16% required subsequent surgery for anterior and/or posterior POP within the 6 year postoperative period across both groups. 13% reported de novo stress urinary incontinence across both groups. 1 case from the PP group required mesh removal due to mesh elongation and uterine prolapse recurrence.

Conclusions

Laparoscopic correction of uterine prolapse requires the use of mesh, for which there are different types available on the market. Any new material needs to undergo clinical scrutiny in order to evaluate the proposed benefits. Our case series verifies that Dynamesh is superior to PP, in terms of uterine prolapse recurrence and could be used in gynaecological surgery. Increased vigilance is required, as small numbers might underestimate the Dynamesh-related complications. Patient safety and clinical governance remain of paramount importance. Our results show promising evidence of the superiority of Dynamesh for the treatment of uterine prolapse.

<https://esge.covr.be/cmdocumentmanagement/conferencemanager/documents/api/getdocument/4993/cmabstms/000143570/1eb949f08517d990adc0688ac712617495b546f417ee5cf0f683af8ec698d7d5>

ES28-0284 - P300

E-Poster

Artificial intelligence and deep learning for computerized laparoscopic image understanding in gynaecology

Sabrina Madad Zadeh¹, Nicolas Bourdel¹, Tom Francois², Lilian Calve², Pauline Chauvet¹, Michel Canis¹, Adrien Bartoli²

¹Centre Hospitalier Universitaire Clermont-Ferrand, Department of Gynaecological Surgery, Clermont-Ferrand, France

²Université Clermont Auvergne, Endoscopy and Computer Vision, Clermont-Ferrand, France

Background

The digital camera has been brought to the operating room by laparoscopic surgery, offering surgeons the opportunity to receive support from image-guided surgery systems. Such systems require image understanding, the ability for the computer to understand what the laparoscope sees. Image understanding has recently progressed dramatically, owing to the emergence of artificial intelligence and especially deep learning techniques. The state of the art of deep learning in gynaecology only offers the image-based detection of anatomical structures without finding their exact localisation such a detection indeed reports the mere presence or absence of a structure. Having a precise image location for the anatomical structures would be more interesting. A possible solution to this problem is given by the concept of semantic segmentation, which allows the detection and pixel-level localisation of a structure in an image. The state of the art results are nowadays obtained by deep learning methods. However, deep learning methods involve an artificial neural network whose training requires a massive amount of annotated data. To date, such a dataset does not exist for gynaecology. In this work, we propose first to initiate such a dataset and second to train and evaluate the accuracy of a deep learning method for the automatic semantic segmentation of laparoscopic images in gynaecology.

Methods

We used the deep learning method called Mask R-CNN. Our dataset has 461 laparoscopic images which were manually annotated with three classes: uterus, ovaries and surgical tools. As opposed to simple localisation, labelling a dataset for segmentation is extremely time-consuming, because each pixel of the image must be labelled precisely. Mask R-CNN was trained on 83% of the dataset and evaluated on the remaining 17%.

Results

We performed an evaluation of the semantic segmentation task and of a detection task of uterus, ovaries and surgical tool. The segmentation accuracy is reported in terms of percentage of overlap between the segmented regions delivered by Mask R-CNN and the manually annotated ones. The percentages of overlap are of 84.5%, 29.6% and 54.5% for uterus, ovaries and surgical tool respectively. An automatic detection of these structures was then inferred from the semantic segmentation results which led to state of the art detection performance, except for the ovaries. The detection accuracy is the ratio of correct detections, where a correct detection is an overlap greater than 50% between the predicted and manually labelled segmentations. Specifically, the detection accuracy is 97%, 24% and 86% for uterus, ovaries and surgical tools respectively.

Conclusions

Our preliminary results are very promising, even with a yet restricted number of training images specific to gynaecological laparoscopy. More annotated images are necessary to further increase segmentation accuracy for the ovaries. The creation of a collaborative international surgical database seems essential.

<https://esge.covr.be/cmdocumentmanagement/conferencemanager/documents/api/getdocument/5191/cmabstsms/000165450/024c183ec3db3041392a00e80cea76ca71298a5fecdb09e0d937a134eba397e3>

ES28-0295 - P301

E-Poster

Resibufogenin inhibits ovarian clear cell carcinoma (OCCC) growth in vivo, and migration of OCCC cells in vitro, by down-regulating PI3K/AKT and actin cytoskeleton signalling pathways

Guan Nan Zhou¹, Jingxin Ding¹

¹Fudan University, Gynecology- the Obstetrics and Gynecology Hospital, Shanghai, China

Background

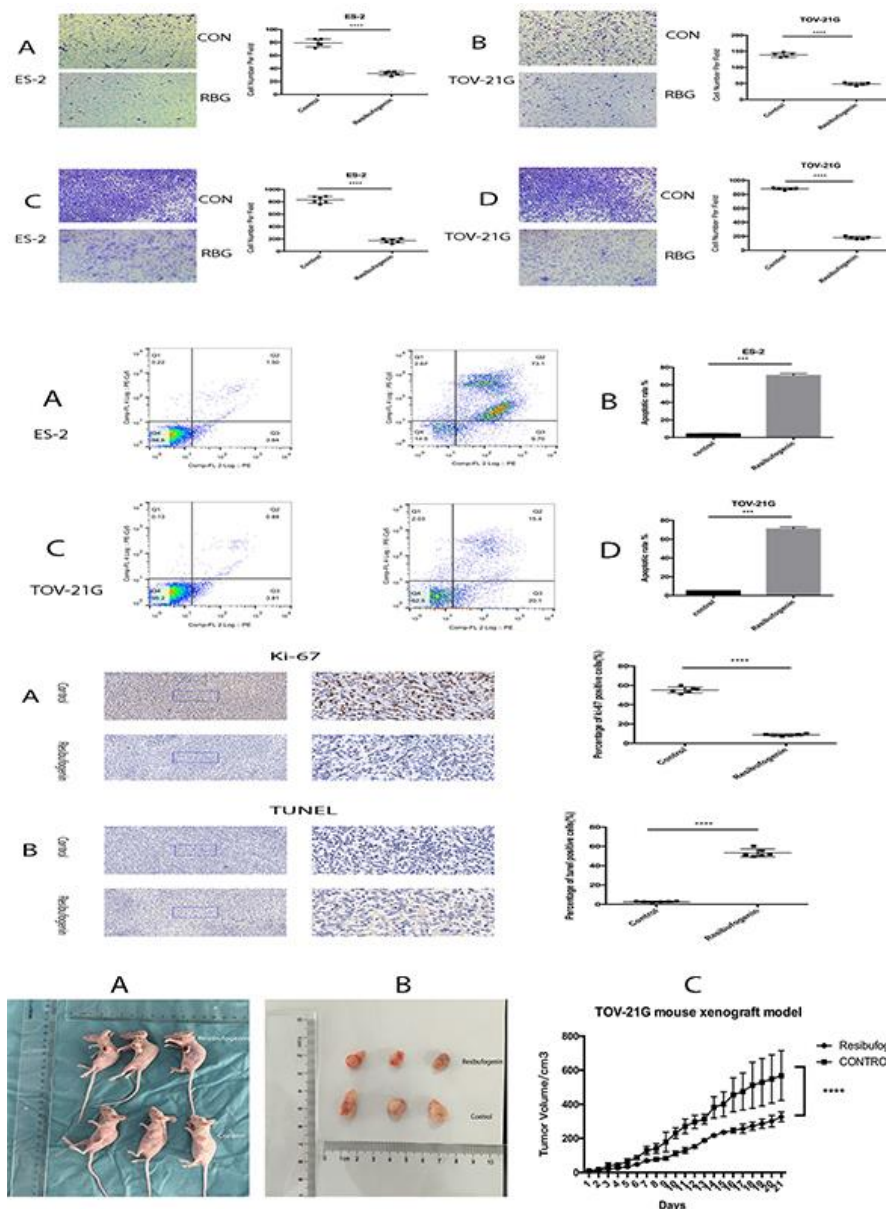
Ovarian clear cell carcinoma is a rare ovarian cancer which presents poor prognosis owing to its chemotherapeutic resistance. There is an urgent need to identify new therapeutic options for these patients.

Methods

Drug screening among 172 traditional Chinese medicines to find out the impact of resibufogenin on ovarian clear cell carcinoma. CCK-8 assay was used to detect cell viability. Transwell assay was used to examine cell migration and invasion. Flow cytometry assay was applied to evaluate cell apoptosis. Xenograft mouse models were constructed to clarify the treatment response in vivo. Then mRNA sequencing assay, qPCR assay, immunohistochemistry assay and western blotting assay were used to detect and verify the targeted pathways.

Results

Resibufogenin inhibited proliferation, migration, and invasion of OCCC cells, and induced apoptosis in them. Resibufogenin also suppressed the growth of xenograft tumors, which consequently showed lower Ki-67 and higher terminal deoxynucleotidyl transferase dUTP nick end labelling (TUNEL) expression.



We observed down-regulation of (a) PI3K and AKT in the PI3K/AKT signalling pathway, and (b) MDM2 and myosin in the actin cytoskeleton pathway upon resibufogenin treatment. Thus, resibufogenin inhibits growth and migration of OCCC cells in vitro and suppresses OCCC growth in vivo through the PI3K/AKT and actin cytoskeleton signaling pathways.

Conclusions

Resibufogenin inhibits growth and migration of OCCC cells in vitro and suppresses OCCC growth in vivo through the PI3K/AKT and actin cytoskeleton signaling pathways.

<https://esge.covr.be/cmdocumentmanagement/conferencemanager/documents/api/getdocument/5200/cmabstsms/000150920/f30374df6295bd97a0f798f46fb523527fbae1e2c9c4f71f5fc12bfa9c50c7bb>

ES28-0332 - P302

E-Poster

Intraoperative retrograde urography: a useful and easy to learn tool in the endometriosis surgeon's armamentarium

Jeffrey Ahmed¹, Amelia Thomson², Nava Sokolovsky², John Bidmead¹

¹King's College Hospital, King's College Endometriosis Centre, London, United Kingdom

²King's College Hospital, Department of Obstetrics & Gynaecology, London, United Kingdom

Background

For deep infiltrating endometriosis, advanced laparoscopic techniques used by endometriosis surgeons are often used to resect disease from tissues surrounding - or invading - the pelvic ureters. Most experienced endometriosis surgeons are familiar with these techniques and comfortable with retroperitoneal exploration of the pelvic ureters to examine for infiltrative disease. The suspicion of endometriosis affecting the extrapelvic portion of the ureters is less easily examined intraoperatively without opening the retroperitoneum along the great vessels, which is unfamiliar territory for most benign gynaecologic surgeons. We describe our approach to such cases.

Methods

Our institution's practice in such cases is to use intraoperative retrograde urography. For cases of endometriosis severely infiltrating the colorectal or urological tracts, we place as standard lubricated ureteric catheters (BBraun, Germany) cystoscopically using a rigid 30 degree cystoscope. A guidewire is rarely necessary. Under X-Ray image intensifier control, the gynaecologist then injects Urografin (or other suitable contrast material) and follows the outline of the ureters from the kidney pelvis through the entire length of the ureters bilaterally on the image intensifier screen. The course and outline of the ureters as well as stricturing caused by endometriotic disease can be easily seen throughout their length. The same process can be additionally utilised in many other settings: for example to exclude iatrogenic ureteric injury, or to exclude kinking of the ureters after suspensory procedures for genitourinary prolapse.

Results

The ability to use a simple tool which is frequently utilised in other surgical disciplines enhances the endometriosis surgeon's ability to exclude disease and detect iatrogenic injury. It is easily learned and handily reproducible by any skilled gynaecological endoscopic surgeon.

Conclusions

The endometriosis surgeon's armamentarium is greatly assisted by this simple tool: the intraoperative retrograde urogram. It represents the application of decades-old proven technology to permit a greater understanding of the surgical field and often prevents the need for invasive exploratory surgery around the great vessels, reducing operative time and lowering patient risk.

ES28-0341 - P303

E-Poster

Engineered bovine-milk-exosome-mediated delivery of resibufogenin and its enhanced suppression effect in

platinum-resistant ovarian cancer cells

Guan Nan Zhou¹, YuanYuan Gu¹, Menglei Zhang¹, Fangyue Zhou¹, Jingxin Ding¹

¹Fudan University, Gynecology- The Obstetrics and Gynecology Hospital, Shanghai, China

Background

Platinum-resistant ovarian carcinoma presents poor prognosis owing to its chemotherapeutic resistance. Numerous studies reported that exosomes are naturally occurring membrane particles that mediate intercellular communication by delivering molecular information between cells. Herein, we investigated whether bovine-milk-derived exosomes as carriers of resibufogenin (RBG) could inhibit platinum-resistant ovarian carcinoma and what is the specific mechanism.

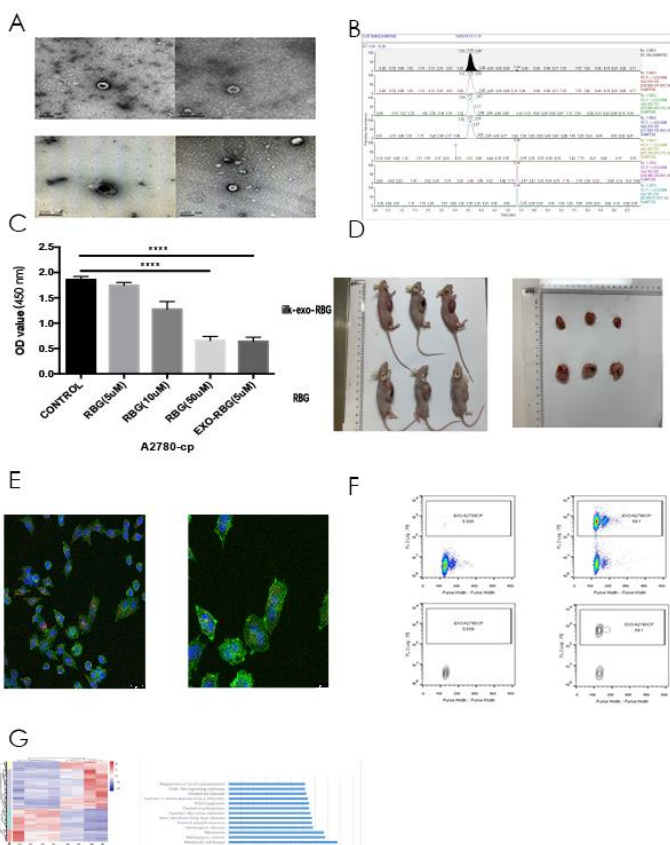
Methods

First, exosomes and exosome-encapsulated resibufogenin were isolated using differential centrifugation and were characterized by electron microscopy, nanoparticle tracking analysis and western blot. Then, the loading efficiency was measured by Ultra Performance Liquid Chromatography-tandem mass spectrometry (UPLC-MS) method. Then, the anti-cancer efficacy of exosome-mediated drug was assessed in vitro and in vivo. Meanwhile, the distribution of Milk-exosome-RBG in cells was inspected by confocal microscopy. High-throughput RNA sequencing was used to detect and verify the targeted pathways and GO analysis and western blot were applied to clarify the function.

Results

Bovine-milk-derived exosomes, which expressed CD63 and TSG101 and ranged from 35 to 201 nm, loaded resibufogenin with certain loading efficacy (A and B). Bovine-milk-derived exosomes delivered resibufogenin into platinum-resistant ovarian carcinoma (E,F), the dose-dependent process enhanced the cytotoxicity of resibufogenin (C). In vivo experiment demonstrated that intragastric administration of milk-exosome-RBG suppressed the growth of xenograft tumors (D), the effect of which was superior to that of intraperitoneal injection of resibufogenin and had lower ki-67 expression and higher tunel expression. The mRNA sequencing assay (G), qPCR assay, immunohistochemistry assay and western blotting assay showed that the PI3K/AKT and regulation of actin cytoskeleton signalling pathways accounted for the results above.

Sample/Method	Size by NTA (nm)	Loading Capacity (%)
milk-exosome	98±5.4	n/a
milk-exosome-resibufogenin	128±6.3	16.1%
empty milk-exosome loading	105±6.1	n/a



Conclusions

Bovine-milk-exosome may be used as effective carriers in delivering resibufogenin into platinum-resistant ovarian carcinoma via clathrin-independent endocytosis and macropinocytosis. Bovine-milk-exosome-RBG enhancing resibufogenin's cytotoxicity in vitro and in vivo through PI3K/AKT and regulation of actin cytoskeleton signalling pathway. This study supports the potential use of bovinemilk-exosome as a drug carrier for the treatment of platinum-resistant ovarian carcinoma.

<https://esge.covr.be/cmdocumentmanagement/conferencemanager/documents/api/getdocument/5080/cmabstms/00150920/ca18ec3e16413447d52b4e87d8a3cce1ac2f51c4e0738c0165f03162624cef08>

ES28-0365 - P307

E-Poster

Improved exploration of the abdominal cavity by laparoscopy: detection of an undescended ovary previously diagnosed to be congenitally absent

Lale Karakis¹, Huseyin Kiyak², Volkan Kasimogullari³, Eser Ozyurek³

¹Bahceci IVF Center, Obstetrics & Gynecology, Istanbul, Turkey

²Kanuni Sultan Suleyman Teaching and Research Hospital, Obstetrics and Gynecology, Istanbul, Turkey

³Bagcilar Teaching and Research Hospital, Obstetrics and Gynecology, Istanbul, Turkey

Background

Laparoscopy enables faster recovery, less postoperative pain and better cosmetic results due to smaller scar formation. One of the most important advantages of laparoscopy is that a more thorough exploration of the surgical area is possible.

We present a patient who had previously undergone laparotomy for left ovarian dermoid cyst excision and was diagnosed with right ovarian agenesis due to failure in visualizing the right ovary. The same patient underwent laparoscopy for recurrent left sided dermoid cyst and was found to have an undescended right ovary instead of ovarian agenesis. The aim of this video was to display how the superior laparoscopic exploration of the pelvic and abdominal cavity can be over exploration by laparotomy.

Methods

A 36 year old G3 P3 patient who presented to the gynecology department with left sided pelvic pain was found to have a 74x50x47mm pelvic mass resembling a dermoid cyst of the left ovary on transvaginal ultrasonography. She had undergone dermoid cyst excision of the left ovary through a pfannenstiel incision 6 years previously. She was also diagnosed with right sided ovarian agenesis as her right ovary could not be visualized during laparotomy. Laparoscopic excision of the dermoid cyst was planned.

Although the patient had completed her childbearing, an AMH test was run to evaluate her ovarian reserve, as she was thought to have only one ovary which was going to be operated on for a second time. Her AMH was 2.5 ng/ml, a level which was considered to be higher than expected.

Results

On laparoscopy a 6x7cm dermoid cyst was visualized on the left ovary. Although the patient had been previously diagnosed with right ovarian agenesis, on exploration, the right ovary was found to be situated high on the right pelvic sidewall in the paracecal area. An abdominal ultrasound was performed intraoperatively to seek for the presence of dermoid cysts on the right ovary. The left ovarian dermoid cyst was excised. The patient was discharged from hospital 24 hours postoperatively without any complications.

Conclusions

In cases in which a unilateral ovary cannot be visualized, the possibility of undescended ovary should be kept in mind before arriving at the diagnosis of ovarian agenesis. Undescended ovary is a rare finding and its prevalence is not known. A unicornuate uterus frequently accompanies an undescended ovary. The location of an undescended ovary may be detected with MRI following ovulation induction. Alternatively laparoscopic exploration can reveal the location of an undescended ovary.

<https://esge.covr.be/cmdocumentmanagement/conferencemanager/documents/api/getdocument/5276/cmabstms/00166140/9fd25104c9db359264efeb6a10044ffbb00e41ee29ba3e1f9ac670199a7dc07d>

ES28-0374 - P308

E-Poster

Trends in endometrial hyperplasia over the past decade – is it on the increase?

Christopher Skelly¹, Johanna Breen², Keith Johnston²

¹Obstetrics and Gynaecology, Craigavon Area Hospital, Craigavon, United Kingdom

²Antrim Area Hospital, Obstetrics and Gynaecology, Antrim, United Kingdom

Background

Atypical Hyperplasia carries a 30% risk of developing endometrial cancer over 20 years. Endometrial cancer has increased by 54% since the 1995. Overall hysterectomy rates are falling, and obesity increases. We reviewed 3 snapshot years over 10 years, in terms of hyperplasia numbers, management and surveillance.

Methods

Retrospective case note audit of 74 patients with histological diagnosis of endometrial hyperplasia with or without atypia for 2008, 2013 and 2018 in the Northern Health and Social Care Trust, Northern Ireland, as identified by the clinical coding department.

Results

- Endometrial Hyperplasia incidence in 2008 - 19 cases (23% atypical / 77% without atypia); 2013 - 24 cases (42% atypical /58% without atypia) and 2018 - 31 cases (29% atypical /71% without atypia).
- Mean BMI was 35, 39 and 36 in 2008, 2013 and 2018 respectively.
- Age range 33– 80 yrs. Mean age in 2008 - 59 years; 2013 - 56 years; 2018 - 53 years.
- 74% (n=17) of patients with atypical hyperplasia underwent a hysterectomy. 26% (n=6) had medical treatment with levonorgestrel IUS or oral progestogens and surveillance due to surgical unsuitability or patient choice.
- Hyperplasia without atypia was managed conservatively with progestogens and surveillance in 71% (n= 36) whilst 29% (n= 15) underwent hysterectomy with persistent, troublesome bleeding in the absence of progressive histology, being the main indication.
- Only 84% (n= 26) of 2018 cohort were followed up according to recommended 2016 Royal College of Obstetricians and Gynaecologists (RCOG) guidance.

Conclusions

Overall hyperplasia incidence is increasing. Unsurprisingly this cohort of women have an elevated BMI, however there was no significant upward trend over the last decade. Does the insidious decline in age demographic suggest that hyperplasia is occurring in younger women? Our review did not demonstrate a continuing increase in atypia, however there was a higher incidence in the 2013 group, who were also the most obese. Adherence to best practice surveillance in our hospitals was falling short.

<https://esge.covr.be/cmdocumentmanagement/conferencemanager/documents/api/getdocument/5196/cmabstms/0000155990/8880b8b24c116fdf07febe9bc5245ad6cc88474a98c4c70da03b5870cd7ac79c>

ES28-0430 - P310

E-Poster

A single satellite gynaecological center's 10 year outcome of 200 endometrial cancer cases

Christopher Skelly¹, Susan Wilson², Geoff McCracker²

¹Obstetrics and Gynaecology, Craigavon Area Hospital, Craigavon, United Kingdom

²Craigavon Area Hospital, Obstetrics and Gynaecology, Craigavon, United Kingdom

Background

To investigate the outcomes of 200 women with early stage (presumed stage 1 disease) endometrial cancer managed at a district general hospital over a 10 year period.

Methods

Retrospective audit of 200 patients with histologically confirmed endometrial cancer, within Southern Health and Social Care Trust in Northern Ireland, from 2009-2018. Information was collected from Northern Ireland Electronic Care Record and subsequently analysed on computerized database.

Results

Our cohort's BMI ranged from 22 - 63 preoperatively. 23% of BMIs were not recorded on the electronic care record. Of the BMIs available (n=154), 87.6% (n=135) classified as overweight or obese.

Age ranged from 34 to 83, mean 62.3 years. 74% (n= 148) presented with postmenopausal bleeding; 9% (n=18) presented with heavy menstrual bleeding, 5% (n=10) intermenstrual bleeding, 5% (n=10) pelvic pain; the remainder consisting of incidental finding on imaging, abnormal smear tests. In terms of surgical management 54% (n=108) women underwent total laparoscopic hysterectomy (TLH) with 100% bilateral salpingoophorectomy (BSO) rate, 28.5% (n=57) had abdominal hysterectomy with 100% BSO rate, 13.5% (n=27) vaginal hysterectomy (VH) with 48% having complete BSO, 3.5%(n=7) underwent laparoscopic assisted vaginal hysterectomy (LAVH) with 100% BSO rate, 0.5%(N=1) had transcervical resection of endometrium and mirena due to extreme obesity.

Overall complication rate was 5% (n=10) for abdominal hysterectomy with 7 wound infection/dehiscence, 1 ureteric injury, 2 post-op pyrexia. The Laparoscopic hysterectomy group had a 5% (n=10) complication rate, consisting of 3 bladder injuries, 1 bowel injury, 1 return to theatre, 1 port site infection, with a 3.6% conversion rate to open (n=4). Complication rate was 1% for vaginal hysterectomy and LAVH groups.

Median length of stay (inclusive of operative day) was 2 days for TLH and VH; 3 days for LAVH; 4 days for abdominal hysterectomy

Pre-operative histology compared with hysterectomy specimen matched in 78% (n=156) cases. 3% (n=6) were significantly upgraded from low to high grade.

Pre-operative radiological staging matched the hysterectomy specimen in 69%(n=138) of cases. 6% (n=12) were upstaged from stage 1, to stage 2 or 3.

Overall confirmed recurrence rate was 2.5%(n=5). None were detected through standard follow-up pathways.

Conclusions

This study supports the demographic correlation between high BMI and endometrial cancer. Despite the significant surgical challenges inherent to the obese patient, 71% of operations were carried out using a minimal access or natural orifice route. Complication rates were low and the shortest hospital stay was with laparoscopic and vaginal hysterectomy. Preoperative grading and staging was relatively accurate, with 9% patients being upstaged or upgraded. Confirmed recurrence rates are low, with a significant proportion of patients still in follow-up. Clinical follow-up is not useful in detecting recurrence in the majority of patients, which supports a self directed aftercare approach in the majority of early stage endometrial cancers.

<https://esge.covr.be/cmdocumentmanagement/conferencemanager/documents/api/getdocument/5199/cmabstms/000155990/8c11ad59e9d6ac369683ad0e0eb796aa815e60ea8f37283e38194c4fbd73c6b9>

ES28-0535 - P312

E-Poster

Quality of life after robotic-assisted laparoscopic hysterectomy in comparison to the conventional total laparoscopic hysterectomy

Mohamed El Essawy¹, Sarah Schneekloth¹, Nicolai Maass¹, Ibrahim Alkatout¹

¹*University Women's Clinic- Kiel, Gynaecology, Kiel, Germany*

Background

To evaluate the benefits of robotic surgery for hysterectomy for benign indication. The primary objective was to compare different outcomes, including intra- and post-operative complications, length of hospital stay, limitations of patients including; convalescence, sick leave and sexual intercourse, perioperative morbidity and postoperative pain,

satisfaction from the treatment, number of scars, positions of scars. Secondary objective was to analysis the learning curves by robotic Surgery.

Methods

All Women undergoing total laparoscopic hysterectomy for benign indications per RALH between 2013 and 2017 at the department of gynecology, University Hospitals, Kiel, Germany were eligible for analysis. Controls were patients that underwent TLH per CL. The postoperative parameters affecting the quality of life of patients were uniquely addressed through a postoperative questionnaire -interview. Patients received a detailed interview questionnaire addressing postoperative pain, limitations of basic hygiene, daily activity, and active participation on hobbies, sexual intercourse and number of sick leave days.

Results

Median total operating time was 145,00 min in the RALH, which was significantly longer, compared to 117,00 min for the TLH(P < 0,001). In the RALH were significant decreases in median operating time after the first 30 cases. Only nine percent (n=11) were not satisfied with the cosmetic results for abdominal incision, representing twenty percent (n=9) for RALH and slight more than two percent (n=2) for CL.

Only thirty three percent (n=28) did not have limitation with sexual intercourse after the operation. The two groups showed a similar time regarding being able to start with sexual intercourse after the operation with a median of 56,00 for CL and 49,00 days for RALH. Almost thirty percent (n=25) were afraid to start with intercourse after the operation, without any percentile different between the two groups.

Pain were recorded by 22,6% n=19 as a limitation for both groups. The RALH showed a slight advantage regarding pain during the sexual intercourse over the CL (15,2% n= 5 and 27,4% n=14). Detailed interview with patients showed that totally 5,9% (n=7) were unhappy about the scar representing 13,3% (n=6) in the RALH and 1,4% (n=1) and with position of the incisions were totally 1,7% (n=2) unhappy, which was only represented by 4,4%(n=2) in the RALH compared to none in the CL group.

Conclusions

The best possible route for hysterectomy and role of robotic assistance for execution of laparoscopic hysterectomy are to be decided by surgeon according to patient's characteristics and training of surgeon.

The RALH are showing similar advantages for patients and slightly marginal advantage regarding sexual functioning for RALH showing less pain. The rapid uptake of robotically assisted hysterectomy is encouraged through shorter learning curve compared to CL. Postoperative consulting of patients is in need of structural changes to encounter the patients fear and expectations regarding the sexual functioning.

<https://esge.covr.be/cmdocumentmanagement/conferencemanager/documents/api/getdocument/5297/cmabstsms/000035360/1fc3d2451ec53b42276f0873a8114294bf3e7810896b29fc9a24c06a852ca9b3>

ES28-0478 - P313

E-Poster

Single-port laparoscopic risk-reducing bilateral salpingo-oophorectomy (RRBSO) with multi-port laparoscopy RRBSO in women carrying BRCA mutations: a prospective comparative study

*Fabio Barra*¹, *Alessandri Franco*², *Marta Seca*¹, *Claudio Gustavino*², *Simone Ferrero*¹, *Maria Grazia Centurion*²

¹IRCCS Ospedale Policlinico San Martino- University of Genoa, Academic Unit of Obstetrics and Gynecology, Genoa, Italy

²IRCCS Ospedale Policlinico San Martino, Unit of Obstetrics and Gynecology, Genoa, Italy

Background

Risk-reducing bilateral salpingo-oophorectomy (RRBSO) has been shown to reduce the risk of ovarian cancer by over 80% in women with a BRCA 1 or BRCA 2 mutation. For this reason, the current National Comprehensive Cancer Network (NCCN) guidelines recommend performing RRBSO in these patients between the ages of 35 and 40 years after completion of childbearing. This study aims to compare the surgical and esthetic outcomes of single-port laparoscopic RRBSO with those of conventional multi-port laparoscopy RRBSO.

Methods

This was a prospective, case-control study enrolling women with confirmed genetic testing for BRCA 1 and BRCA 2 mutations who underwent laparoscopic RRBSO. Surgical procedures were performed between June 2017 to December 2018. Each woman was informed about the two types of surgeries and was alternatively assigned to undergo single-port laparoscopic RRBSO (n=35) or multi-port RRBSO (n=35).

Results

Patients had similar demographic characteristics in both groups. Of these, 46 (65.7%) were BRCA1 carriers, 24 (34.2%) were BRCA2 carriers. There were no significant differences in the estimated blood loss (12.3 ± 2.7 ml versus 11.8 ± 2.5 ml; $p=0.392$) and in the postoperative hospital stay (1.9 ± 0.7 days versus 2.0 ± 0.6 days, respectively; $p=0.083$) between the two surgical groups. Pain measured at visual analogue scale (VAS) immediately and at 6, 12 and 24 hours after surgery was lower in patients undergoing single-port RRBSO than in those undergoing multi-port RRBSO ($p=0.047$, $p=0.006$, $p=0.001$, respectively). After 1 and 4 weeks from the surgical procedure, the cosmetic satisfaction was significantly higher in patients undergoing single-port laparoscopic RRBSO ($p<0.001$). No women experienced major intraoperative morbidity in both study groups; one conversion to multi-port laparoscopy occurred in patients undergoing single-port laparoscopic RRBSO (2.8%); no conversion to laparotomy occurred in both study groups.

Conclusions

Laparoscopic single-port RRBSO allows a more rapid and easier specimen extraction, decreasing the risk of fragmentation as well as the need of enlarging the trocar site incision. Although it needs a specific learning curve, single-port RRBSO is technically feasible and characterized by comparable operative outcomes, lower postoperative pain and better esthetic outcomes than laparoscopic multi-port RRBSO.

<https://esge.covr.be/cmdocumentmanagement/conferencemanager/documents/api/getdocument/5279/cmabstms/0000143980/30f55a91f56dd20678d69a9e6e1b50b747ab055b08396d8623c821cf2b97cced>

ES28-0499 - P315

E-Poster

Association of p53 arg72pro polymorphism and endometriosis in a Greek population

Despoina Mavrogianni¹, Melina Markogiannaki¹, Konstantinos Ntzeros¹, Dimitra Dedousi¹, Dimitrios Loutradis¹, Athanasios Protopapas¹

¹University of Athens - School of Medicine, First Department of Obstetrics and Gynecology, Athens, Greece

Background

The p53 is a tumor suppressor gene which plays an important role in regulating the cell cycle, apoptosis and protecting the genome from DNA damage. Despite being the 'guardian of the genome' by preventing genome mutation, p53 gene also has a critical role in angiogenesis and embryonic development since it interacts with proteins which are involved in growth control, transcriptional regulation and inflammation. Polymorphisms have been identified as a potential risk factor for endometriosis. Recent research studies have shown that single nucleotide polymorphism (SNP) at codon 72 of the TP53 gene may increase the possibility of endometrial tissue growth outside the maternal cavity.

The aim of the present study was to investigate the possible correlation of the Arg72Pro polymorphism (rs1042522) and the occurrence of endometriosis in the Greek population.

Methods

DNA was extracted from 29 women with endometriosis (59 samples) and 100 control samples. Genotyping was performed by PCR amplification of the p53 Arg and Pro variants at codon 72. PCR results were visualized by using agarose gel electrophoresis.

Results

In the group of endometriosis the Arg72Pro polymorphism was detected in 4 of the 29 samples (13.7%) independently of the tissue examined. In 6 out of 29 samples a different genetic pattern between tissues of the same woman was detected (20.3%). In the control group the polymorphism was detected in 7 of the 100 samples (7%).

Conclusions

Our results show that women who carry the proline allele (Pro) have a statistically significantly higher risk of developing endometriosis than women carrying the Arginine (Arg) allele. These findings suggest that changes in the proline-rich region in the p53 gene where polymorphism is detected could alter the activity of p53 to regulate cell cycle and cell apoptosis. Additionally the presence of pro allele seems to have a protective influence in the appearance of endometriosis. An interesting finding is the presence of a different genetic pattern in different tissues of the same woman. Endometriosis is a disorder involving genetic and immunological factors and therefore polymorphisms may be involved in its appearance.

<https://esge.covr.be/cmdocumentmanagement/conferencemanager/documents/api/getdocument/5302/cmabstms/0000144720/5e8f89fd6792105f013e7409ef09fc5982eb6e70ba56bbe173e93692e2cf0936>

ES28-0500 - P316

E-Poster

Study of cart (cocaine- and amphetamine- regulated transcript) expression as a novel biomarker for endometriosis in Greek population

Despoina Mavrogianni¹, Christos Kagaras¹, Rami Raouasnte¹, Konstantinos Ntzeros¹, Dimitrios Loutradis¹, Athanasios Protopapas¹

¹University of athens- School of Medicine, First Department of Obstetrics and Gynecology, Athens, Greece

Background

Endometriosis is considered to be a chronic inflammatory disease affecting women of reproductive age. This common gynecological condition is characterized by ectopic endometriotic lesions. While the underlying pathophysiology of endometriosis remains unclear recent studies attempt to establish a genetic profile of the disease. Recent findings suggest that stress and abnormal function of the hypothalamic-pituitary-adrenal (HPA) axis may contribute to the development of the disorder. It seems that CART may interact with the HPA axis, and consequently be involved in the development and regulation of endometriosis.

The aim of the present study was to estimate the CART expression in women suffering from endometriosis, in a Greek population.

Methods

The study includes 32 women with endometriosis. The collected tissues were classified based on their histological profile into two groups, normal (control group) and endometriotic group. RNA was extracted from the tissues using NucleoSpin RNA kit. Single strand cDNA synthesis was performed with PrimeScript™ RT reagent Kit. The cDNA samples were subjected to qRT-PCR amplification. The specificity of the PCR product was evaluated by melting curve analysis and gel electrophoresis.

Results

Among the two groups, differences in expression were observed. More specifically in 11 (41%) of the women studied a significantly higher expression in the endometriotic group was detected when compared with the control group. CART expression of endometriotic tissue was 19.3 times higher than the normal.

Conclusions

In our study there was a positive correlation between CART mRNA expression and endometriosis. The results indicate that CART may be involved in the regulation and development of endometriosis, through a neuroendocrine pathway. Therefore CART among other genes could be included in the genetic profile of the disease.

<https://esge.covr.be/cmdocumentmanagement/conferencemanager/documents/api/getdocument/5303/cmabstms/0000144720/87b67dfda9cd11b35f93382ee96068c58cd0ff33054c4ae8bb28b6f9cd441482>

The use of Karman curettage following missed abortion can reduce the number of hysteroscopies – a prospective RCT

Nissim Arbib¹, Michal Ovadia¹, Nitzan Goren-Gepstein¹, Ron Schonman¹, Zvi Klein¹, Meir Pomeranz¹

¹Meir Medical Center- Kfar Saba- Israel, Department of Obstetrics and Gynaecology, Kfar Saba, Israel

Background

Spontaneous abortion may happen in 15% to 20% of known pregnancies, most occur in the first trimester. Spontaneous missed abortions can be treated either with medication or a surgical procedure. The surgical procedure performed is curettage, with complications in 1% of cases. Complications include increased bleeding, infection, uterine perforation and intra uterine adhesions, as well as anesthesia-related complications. If the patient's medical condition allows, medical treatment with Misoprostol can be a reasonable option. According to the literature, in 20% of cases drug therapy fails, and curettage or hysteroscopy are required. In this prospective randomized trial, we compared the efficacy of an ultrasound guided endometrial aspiration kit, e.g. Karman curettage, to treat Retained Product of Conception (RPOC), with expectant management. We wish to examine the success rate of Karman curettage in evacuation of Retained Product of Conception (RPOC) after recurred treatment failure with Misoprostol, in attempt to prevent invasive procedures for this purpose.

Methods

Forty woman, diagnosed with a missed abortion after recurred failed treatment with Misoprostol were randomly assigned to one of two groups. Women in the study group underwent suction endometrial curettage with Karman canula one week after receiving Misoprostol, immediately after an ultrasound (US) examination showing RPOC. Patients assigned to the control group did not receive any additional treatments in addition to Misoprostol. Patients in both groups were scheduled for an ambulatory operative hysteroscopy under anesthesia as per customary in our department. On the scheduled day all patients were examined with US. Patients with significant RPOC underwent hysteroscopy on the same day. Others were discharged.

Results

In the treatment group, hysteroscopy was necessary for only 2 patients compared to 10 women in the control group (p-value = 0.014). The treatment group experienced 6.05 days of bleeding, while those in the control group had only 1.41 days of bleeding (p-value = 0.006). The number of days off work in the treatment and control groups was 4 days and 0.76 days, respectively (p-value = 0.026).

Conclusions

Karman curettage can be an effective therapeutic approach to complete the abortion and can prevent the need for surgical intervention. This study offers a new treatment option for women with missed abortion that has not been described in literature thus far.

<https://esge.covr.be/cmdocumentmanagement/conferencemanager/documents/api/getdocument/5095/cmabstsms/000166480/a9bb49eee8b39e7ba0d2f908cc0d4cb008037596e57c9bf78d9b358a2d9d0760>

ES28-0551 - P319

E-Poster

Cervical sarcoma - a challenging disease

Ioan-Julian Iordache¹, Panagiotis Sklavounos¹, Romina Marina Sima², Adriana Mezey¹, Nikolaos Drandakis¹, Erich-Franz Solomayer¹

¹UKS - University of Saarland- University Hospital- Homburg- Saar- Germany.,

Department of Gynecology- Obstetrics and Reproductive Medicine-, Homburg, Germany

²Carol Davila University of Medicine and Pharmacy- Bucur Maternity- St. John Hospital,

Department of Obstetrics and Gynecology-, Bucharest, Romania

Background

Cervical sarcomas are very rare and heterogeneous gynecological tumors (rhabdomyosarcomas, leiomyosarcomas, liposarcomas, undifferentiated cervical sarcoma or malignant peripheral nerve sheath tumor-MPNST) and constitute less than 0,5 % of all malignancies of the cervix. We present our experience with a very challenging case of cervical sarcoma.

Methods

We report a rare and unusual case of a 40-year-old female who presented a history of abnormal bleeding and severe urinary retention. Gynecological examination and sonography revealed a 6 cm cervical mass, filling the vagina. The patient underwent a total laparoscopic hysterectomy (TLH) with bilateral salpingectomy (without morcellation). The histopathological diagnosis was undifferentiated uterine sarcoma with malignant peripheral nerve sheath tumor cells. Our patient received postoperatively adjuvant radiotherapy.

Results

After 3 months our patient was diagnosed with tumor recurrence and a new laparoscopy followed by chemotherapy were necessary. Despite all medical efforts, our patient died, 6 month after the surgery, due to metastasis.

Conclusions

Cervical sarcomas are very rare and aggressive tumors associated with poor prognosis, despite the proper therapy.

<https://esge.covr.be/cmdocumentmanagement/conferencemanager/documents/api/getdocument/5224/cmabstms/000165320/be36f44102f2654e44ca9e8fb9c87da77b028de622a397ad07c88a3b357b5af4>

ES28-0561 - P320

E-Poster

Quality of life and urogenital symptom outcomes in women undergoing total laparoscopic vs abdominal hysterectomy for benign conditions

Sabri Kurtay¹, Sadiman Kiykac Altinbas¹, Omer Lutfi Tapisiz¹, Fulya Kayikcioglu¹, Ozlem Moraloglu Tekin¹

¹University of Health Sciences- Etlik Zubeyde Hanim Women's Health Training & Research Hospital,

Obstetrics and Gynecology, Ankara, Turkey

Background

The aim of the study was to evaluate quality of life and urogenital symptoms in women undergoing total laparoscopic (TLH) vs abdominal (TAH) hysterectomy for benign conditions.

Methods

The study included 286 patients, 107 of whom underwent TLH and 179 of whom underwent TAH. Patients were evaluated with two validated questionnaires including Short Form-36 and Urogenital Distress Inventory-6 according to 3 periods as early (0-3 months), mid (4-12 months) and late (more than 12 months) postoperative periods. Patients; (1) with uterine size larger than 14 weeks of gestation, (2) with pelvic organ prolapse and/or urinary incontinence, (3) with a history of endometriosis and/or pelvic inflammatory disease, (4) who had intraoperative complications and underwent concomitant operation, were excluded.

Results

The patients, who underwent TLH, had better results when compared to TAH in terms of physical, social functions and pain scores in the early period (83.9 ± 10.2 vs 78.5 ± 9.9 , $p=0.018$; 86.7 ± 18.2 vs 75.9 ± 9.2 , $p<0.001$; 80.5 ± 27.4 vs 68.2 ± 31.1 , $p=0.027$, respectively). The patients, who underwent TLH, had better results than the patients who underwent TAH in terms of social functions in the mid and late periods (81.2 ± 23 vs 60.3 ± 21.6 , $p<0.001$; 84.3 ± 9.5 vs 68 ± 27.1 , $p=0.006$, respectively). No statistically significant difference was found between the two groups in terms of urinary incontinence after 12 months postoperatively.

Conclusions

TLH for benign uterine conditions improved quality of life in the early postoperative period. In the 12th month follow up, all parameters except for social functioning scale were comparable between the groups. No superiority was observed in terms of urinary function between the two hysterectomy types.

<https://esge.covr.be/cmdocumentmanagement/conferencemanager/documents/api/getdocument/5273/cmabstms/000077000/b639281a620a15f823acaeae9aa09450b7decfc298bcd8f3a44c13983b6c17>

ES28-0566 - P321

E-Poster

The role of transvaginal ultrasound in the detection of endometrial pathology in asymptomatic postmenopausal women with a thickened endometrium

Panagiotis Bakas¹, Dimitrios Mazis¹, Anastasios Potiris¹, Charalampos Karachalios¹, Eythymios Deligeoroglou¹
¹Aretaieio University Hospital, Obstetrics and Gynaecology, Athens, Greece

Background

To assess the risk of endometrial malignancy in asymptomatic postmenopausal women with an endometrial thickness of at least 5 mm, as evaluated by routine transvaginal ultrasonography.

Methods

A cohort of 103 asymptomatic postmenopausal patients from 43 to 77 years old presented between January 2015 and December 2016 at the Department of Obstetrics and Gynecology in Aretaieio University Hospital (Athens, Greece) for a routine gynecologic check-up. All had a transvaginal ultrasonic minimum endometrial thickness of 5 mm and underwent a subsequent hysteroscopic endometrial biopsy followed by dilatation and curettage.

Results

Endometrial cancer was diagnosed in 6 out of 103 women (5.8%) with a mean age of 69 years old. The youngest patient was 60 years old and the eldest was 75. The latter patient had a malignant mixed Müllerian tumor, while the five rest were diagnosed with an endometrioid endometrial adenocarcinoma (FIGO Grade 1 or 2).

Conclusions

Hysteroscopic assessment of the endometrial cavity in postmenopausal asymptomatic women with an ultrasonographically thickened endometrium could assist in the earliest possible detection of endometrial malignancies

<https://esge.covr.be/cmdocumentmanagement/conferencemanager/documents/api/getdocument/4927/cmabstms/000045910/fac003b076397431bcd48e16ea258b641c28bb3e05a22a76d5033bd5f5faec37>

Robotic assisted myomectomy: can ultrasound guidance help the surgeons?

Chiara Vacca¹, Francesca Vergine², Elisabetta Micelli¹, Maria Elena Rosa Obino¹, Francesca Papini¹, Vito Cela¹

¹*University of Pisa, Obstetrics and Gynecology, Pisa, Italy*

²*University of Pisa, Obstetrics and Gynecology, Pisa, Italy*

Background

Myomectomy is a difficult surgical procedure, especially when patients have multiple myomas. The purpose of surgery is the complete removal of all myomas, including the small ones to reduce the risk of relapses. We present our experience of women with multiple uterine myomas underwent laparoscopy-assisted robotic myomectomy using the ultrasound-guided da Vinci xi system.

Methods

Three female patients came to our attention complaining lower abdominal pressure and pain. A pelvic sonogram showed subserosal and intramural myomas of 1 to 9 cm diameter. All patients insisted on preserving the uterus and they were worried about cosmetic results due to the scar. We proposed myomectomy using the newly developed ultrasound-guided laparoscopy-assisted robotic system (da Vinci xi). Da Vinci xi system offers plug-and-play ultrasound system that allows quick and easy viewing during robot-assisted surgeries.

The procedures were effective to remove all uterine myomas, including the smallest ones. The myomas were removed according to the classic technique (hysterotomy with enucleation and subsequent suturing of the uterine breaches using Stratafix 2-0 and Polysorb 1-0).

Real-time intraoperative ultrasound helped us to: locate and identify fibroids, identify a mass inside the uterus, ensure no small fibroids are left after surgery and be less invasive during the surgical procedure.

Results

The duration of surgeries was about 2 hours, with an estimated blood loss of 200 mL. The patients had no post-op complications. The day after they were discharged. At the post-operative check after two months, the patients presented regular

uterine morphology and complete remission of symptoms. They were satisfied about cosmetic result.

Conclusions

Minimally invasive surgery, when possible, is the trend of the future. In our case it could be a new and valid technique for myomectomy. Robot-assisted laparoscopic myomectomy is a feasible technique for removal of deep intramural myomas unfavorably localized for traditional laparoscopy. Also the properties of the da Vinci robot seems to facilitate dissection and suturing during the surgical steps of myomectomy.

The advantages of using the ultrasound-guided robotic system compared to open myomectomy include a shorter length of hospital stay, less postoperative pain and analgesic use, faster return to normal activities, more rapid return of the bowel function, enhanced cosmetic results due to smaller skin incision size and above all the complete removal of all myomas, including the smallest ones, reducing the risk of relapses. Disadvantages of this technique include high costs of the robotic surgical system and equipment and the steep learning curve of this novel system.

<https://esge.covr.be/cmdocumentmanagement/conferencemanager/documents/api/getdocument/5167/cmabstms/000166880/350eab9e634bf058699676b46daf323d477024e12e55e02873e5d4f366312d92>

ES28-0596 - P326
E-Poster

Combination cervical and fundal local anaesthetic block technique for endometrial ablation in an outpatient hysteroscopy service

Gonzola Mezquita¹, Fevzi Shakir¹, Ozlem Turan¹

¹Royal Free Hospital, Obstetrics and Gynecology, London, United Kingdom

Background

Endometrial ablation is a minimally invasive procedure for treatment of heavy menstrual bleeding which can be performed under local anaesthesia. Paracervical and intracervical anaesthesia are the most commonly used methods of local anaesthesia, but combining the traditional cervical block with trans-hysteroscopic injections of local anaesthesia into the subendometrial myometrium of the fundus of the uterus could significantly reduce women's perception of pain during the procedure.

The aim of this study was to investigate the effectiveness of combining cervical block with intramyometrial block of the uterine fundus on women's perception of pain during Novasure Advanced® endometrial ablation.

Methods

The cervical block used is 4.4mls of 3% Citanest with Octapressin. Subsequently, a hysteroscopy was performed using a 4.2 mm hysteroscope, and an additional 5mls of local anaesthetic (combination of lignocaine and bupivacaine) was placed in the myometrium of the fundal wall through a Cook's injection needle under direct vision. 4 injections of 1.25mls of local anaesthetic was placed in between each tubal ostia at equal distances apart. The ablation was then performed and intraprocedure as well as post procedure pain scores were recorded as visual analogue scores (1-10).

Results

We present the results over the last year. Endometrial ablation was successfully completed in all women in the outpatient. The mean duration of the ablation procedure was 81.6 s. The mean pain scores during and immediately after the procedure were 3 and 1 respectively. All the patients were discharged home after the procedure within 20 minutes.

Conclusions

Endometrial ablation under local anaesthesia is a safe and feasible procedure that can be performed in an outpatient clinic. The combination of cervical and fundal block in addition to pre operative oral analgesia presented in this study could improve pain perception during and after the procedure.

<https://esge.covr.be/cmdocumentmanagement/conferencemanager/documents/api/getdocument/4975/cmabstms/000023290/93546b7ead1a585fac9a06aed37eb2f9c1eea5dd2442dcf80722b10b45f5e96a>

ES28-0612 - P328
E-Poster

A quality improvement project: patient satisfaction of the outpatient hysteroscopy (OPH) service at a UK regional hospital

William Farkas¹, Hannah Seagar¹, Emma Torbe¹

¹Great Western Hospitals NHS Foundation Trust, Obstetrics & Gynaecology, Swindon, United Kingdom

Background

Patient satisfaction of OPH is a recommended audit topic by the RCOG. Patient satisfaction of other local outpatient services e.g colposcopy, have previously been positively evaluated. The facilities and staff of both services overlap and therefore a similar assessment was undertaken. We aim to determine satisfaction of patients undergoing OPH, by obtaining quantitative and qualitative data.

Methods

All patients attending for an OPH at the Great Western Hospitals NHS Foundation Trust (GWH) during September 2018 were provided with a paper based patient satisfaction survey. This consisted of binary questions and free text comment box. Patients anonymously completed the questionnaires which were collected in a sealed box within the

department. At the end of the audit period the data was collated and analysed. A sample of women attending one clinic were invited to share their experience by participating in a structured interview with a junior doctor.

Results

37 questionnaires were returned. 5 patients were interviewed. 100% of patients were satisfied with their appointment. 31/37 (84%) received written patient information leaflet prior to their appointment thereby not meeting the standard of 100%. 27/37 (73%) of patients expected to see a consultant, whereas 16/37 (43%) saw either another doctor or a nurse. Multiple free text comments and compliments were recorded. At interview, 100% of women had a good experience. Themes from interviews included suggested improvements to the information leaflet to further manage patient expectations.

Conclusions

The OPH service at GWH is well received by patients. The positive feedback was shared with all members of the clinical team. Patient information provision and content have been reviewed and changes are in process. The aim is to further manage patients' expectations and experience. Patient satisfaction rates are high and comparable with other services. Interviews and free text comments highlight areas of good practice and opportunities for development.

<https://esge.covr.be/cmdocumentmanagement/conferencemanager/documents/api/getdocument/4991/cmabstsms/000165480/495bc7af4247274fcf258be9a13af5723803d011bb0351d0a6cca2ac607589e7>

ES28-0651 - P331

E-Poster

Anatomic distribution of endometriosis: a reappraisal based on series of 1101 patients

Stamatios Petousis¹, Alain Audebert², Chrysoula Margioulas-Siarkou¹, Konstantinos Ravanos¹, Nikolaos Prapas¹, Yannis Prapas¹

¹*Iakentro, Infertility Treatment Center, Thessaloniki, Greece*

²*Private Office, Rue de Turennes 45, Bordeaux, France*

Background

Main objective of the study was to reappraise the anatomic distribution of endometriosis lesions in cases with Superficial Implants (SI), Ovarian Endometrioma (OMA) and Deep Infiltrating Endometriosis (DIE).

Methods

A prospective observational study was operated between January 1989 to June 2009. A total of 1333 consecutive patients with a laparoscopic diagnosis of endometriosis, were extracted from our database. Due to missing data or repeated operations, 232 patients were excluded from the study. Finally, 1101 patients who met the selected criteria were included in the present analysis.. Primary outcome of study was the anatomic location of endometriotic lesions. Secondary outcomes were laterality of lesions as well as location of adhesions.

Results

Mean age of patients was 33.06 years (range 15-63 years) while the mean BMI was 21.5. The ovary was the most frequent site of endometriotic lesions (737 patients, 66.94%) followed by the utero-sacral ligaments (USL) (45.51%), the ovarian fossa (32.15%), the pouch of Douglas (29.52%) and the bladder (21.25%). Deep Infiltrating Endometriosis (DIE) was diagnosed in 159 patients (14.4%) with an increasing rate starting from the mid-nineties. The left side was predominant for all locations except for ovarian SI and fallopian tube, but for this latter location the number of cases was limited. 600 (54.4%) patients had adhesions with the adnexa being the most frequent site of location (47.4%).

Conclusions

Ovary was the main site of endometriotic lesions followed by the utero sacral ligaments. Left side was predominant for all locations except for ovarian SI and fallopian tube. The diagnosis of DIE has constantly being increased since mid-nineties. The large cohort of patients included in the study has strengthened previous reported data.

<https://esge.covr.be/cmdocumentmanagement/conferencemanager/documents/api/getdocument/5266/cmabstsms/000139520/6dfe2ad1c7732db20cd2c9afb9875ea0062a64918c2edb166fdc5726e583fe20>

Non-surgical management of interstitial pregnancies: feasibility and predictors of treatment failure

Alon Ben-David¹, Raanan Meyer¹, Aya Mohr-Sasson¹, Roy Mashiach¹

¹Chaim Sheba Medical Center- Tel-Hashomer, Department of Obstetrics & Gynecology, Ramat-Gan, Israel

Background

Interstitial pregnancy is a rare and potentially life-threatening medical condition. A range of surgical and non-surgical treatments for these pregnancies have been described in the literature but optimal management is still undetermined. Data on the outcome of conservative management and factors associated with its failure, as well as the outcome of subsequent pregnancies in relation to treatment modality are limited.

We aim to describe the management of interstitial pregnancies in a tertiary medical center, identify factors associated with treatment failure and report subsequent pregnancy outcome.

Methods

This is retrospective cohort study of all women who were admitted and treated for interstitial pregnancy in a single tertiary center between 2011-2019. Women were originally assigned to undergo expectant, medical or surgical treatment. The women's background and clinical data were compared according to initial treatment modality. Non-surgical (expectant and medical) management outcomes were analyzed to identify risk factors for treatment failure. Subsequent pregnancy outcomes were described separately.

Results

Thirty-seven cases of interstitial pregnancies were identified. There were high rates of pregnancies achieved by in-vitro fertilization (45.9%) and a history of ipsilateral salpingectomy (43.2%) among these patients. The non-surgical management success rate was 70.0%. A uterine rupture occurred during treatment in five (16.6%) cases. Gestational sac diameter significantly affected treatment failure ($P= .03$) and a diameter >20 mm was observed in all cases of failed non-surgical treatment. Data on future fertility was available for 21 (58.3%) women: 13 (61.9%) had a subsequent pregnancy, one of which was a recurrent interstitial pregnancy. The median inter-pregnancy interval was 8.1 months and all but three pregnancies reached third trimester and resulted in a live birth, with a total cesarean delivery rate of 61.5%. None of the subsequent pregnancies were complicated by uterine rupture and no serious adverse outcomes were noted in any of the subsequent intrauterine pregnancies that reached third trimester.

Conclusions

Successful non-surgical management of an interstitial pregnancy is feasible, although appropriate selection of cases is advised. A large gestational sac is a risk factor for treatment failure and should prompt surgical intervention. Subsequent pregnancies can generally be considered safe and with a favorable outcome.

We believe that the current work adds important information to the existing base of knowledge on the risk factors and management of IP and on the outcome of subsequent pregnancies. This can assist in guiding caregivers and patients on clinical decision-making.

<https://esge.covr.be/cmdocumentmanagement/conferencemanager/documents/api/getdocument/5027/cmabstsms/000077230/02251bba41d6eeb995a786c47784e9bb322a3901a6f737f78e5f31452a0b6975>

VIDEO POSTER (79)

ES28-0031 - VP001

Video Poster

Hysteroscopy for removal of retained products of conception in a patient with residual cervical pregnancy

Noam Smorgick¹, Adi Orenstein¹, Orna Levinsohn-Tavor¹, Ron Maymon¹, Zvi Vaknin¹

¹Assaf Harofe Medical Center- Affiliated with Sackler School of Medicine- Tel Aviv University- Israel, Division of Minimally Invasive Gynecology- Department of Obstetrics and Gynecology, Rishon Lezion, Israel

Background

Cervical pregnancy is a rare form of ectopic pregnancy. The surgical management of cervical pregnancy by curettage is often associated with heavy vaginal bleeding. In this report, we present a patient with residual cervical pregnancy who was successfully managed by operative hysteroscopy.

Methods

Hysteroscopic technique for removal of retained products of conception (RPOC) following curettage for cervical pregnancy.

Results

A 27 years old patient underwent curettage for a presumed 8 weeks early missed abortion. She has a history of 2 cesarean sections. During curettage, heavy bleeding was noted and the procedure was terminated. On follow up ultrasound scan, a residual trophoblastic mass measuring 41*36 mm located in the lower uterine segment was observed and the patient was scheduled for operative hysteroscopy for suspected RPOC. On hysteroscopy, a normal uterine cavity was observed, while the large and vascular RPOC mass was located in the cervical canal, consistent with residual cervical pregnancy. The RPOC mass was removed hysteroscopically by blunt dissection with the hysteroscopic loop without complications. Diluted intra-cervical vasopressin was used to control hemostasis and improve the hysteroscopic visualization. The post-operative hysteroscopy follow-up showed a normal uterine cavity and cervical canal.

Conclusions

Removal of RPOC following curettage for cervical pregnancy may be completed by hysteroscopy with favorable short- and long-term outcomes.

<https://player.vimeo.com/video/328423845?autoplay=1>

ES28-0024 - VP002

Video Poster

Laparoscopic treatment of obstetric peritonitis

Aleksei Golubenko¹, Victor Makeev¹, Sonya Kieva¹, Elena Medvedeva¹, Varvara Kirsanova¹, Ramilya Golubenko¹

¹Scientific and Clinical Multidisciplinary Medical Centre- Department of Gynecology- Oryol-Russia, Gynecology, Oryol, Russia

Background

A 26 years old post caesarian section due to premature detachment of normally placed placenta at 33-34 weeks. Had laparoscopy done on the 7th day post operation due to persistent symptoms of acute peritonitis. A diffuse fibrinopurulent peritonitis was revealed with complete suture failure of the uterus and abscess of the anterior abdominal wall

Methods

Laparoscopy

Total hysterectomy with fallopian tubes

Sanation

Drainage

Dissection and drainage of abscess

Results

Post operation no complications.

Conclusions

Effective method in case of peritonitis with abdominal wall abscess post caesarian section.

<https://player.vimeo.com/video/326380971?autoplay=1>

ES28-0007 - VP003

Video Poster

Radical treatment of endometriosis of the ovaries

Aleksei Golubenko¹, Umar Yakasai^{1,2}, Sonya Kieva¹, Victor Makeev¹, Varvara Kirsanova¹

¹Scientific and Clinical Multidisciplinary Medical Centre HKMLI, Gynaecology and Reproductive Technology, Oryol, Russia

Background

A 49 years old patient with bilateral ovarian endometriosis, uterine myoma and adenomyosis. complaints of dysmenorrhea, chronic lower abdominal pain dyspareunia

Methods

Laparoscopic total panhysterectomy

1 Laparoscopy, revision of small pelvis

2 Adhesiolysis and sanation of endometriomas

3 Coagulation and interseccion of infundibulo- pelvic and round ligaments

4 Mobilization of the bladder

5 Coagulation and dissection of the uterine vessels

6 Circular dissection of the vagina

7 Extraction of the uterus

8 Vaginal closure

Results

Post operation: no complications

Normal vaginal healing

Conclusions

Laparoscopy is a very effective method of treatment of widespread endometriosis of the ovaries

<https://player.vimeo.com/video/321958556?autoplay=1>

ES28-0012 - VP004

Video Poster

Hysteroscopic treatment of placenta increta

Aleksei Golubenko¹, Umar Yakasai¹, Sonya Kieva¹, Victor Makeev¹, Varvara Kirsanova¹

¹Scientific and Multidisciplinary Medical Research Center, Gynaecology and Reproductive Technology, Oryol, Russia

Background

A 30 years old patient who had planned caesarian section 4.5 months ago presented with 1/12 complaint of acyclic metrorrhagia. Ultra sound done revealed a suspicious placental tissue.

Methods

Hysteroresectoscopy
Placental resection
Ultrasonography
Monopolar resection loop

Results

1 Post operation no complications
2 Normal Healing

Conclusions

Hysteroscopy is an effective method of treatment of placenta increta.
Post operation histological report: Placenta Increta

<https://player.vimeo.com/video/322429117?autoplay=1>

ES28-0018 - VP005

Video Poster

Laparoscopic treatment of interstitial ectopic pregnancy following in vitro fertilization

Aleksei Golubenko¹, Umar Yakasai¹, Victor Makeev¹, Sonya Kieva¹, Ramilya Golubenko¹, Elena Medvedeva¹

¹Scientific Clinical and Multidisciplinary Medical Research Center Oryol, Gynaecology, Oryol, Russia

Background

Patient 42 years of age undergoing surgery laparoscopic bilateral salpingectomy due to hydrosalpinx. Under the IVF program, the embryo was transferred. According to ultrasonography revealed interstitial localization of the fetal egg in the left corner of the uterus.

Methods

Laparoscopy
Resection and suturing of the right uterine angle

Results

Post operation no complications
Discharged on contraceptives

Conclusions

Laparoscopic access is an effective method surgical treatment of interstitial ectopic pregnancy

<https://player.vimeo.com/video/325260151?autoplay=1>

ES28-0021 - VP006

Video Poster

Laparoscopic adenomyomectomy

Aleksei Golubenko¹, Umar Yakasai¹, Victor Makeev¹, Sonya Kieva¹, Ramilya Golubenko¹, Varvara Kirsanova¹

¹Scientific Clinical and Multidisciplinary Medical Research Center Oryol, Gynaecology, Oryol, Russia

Background

The patient is 30 years old with chronic pelvic pain syndrome, dysmenorrhea and dyspareunia for 3 years. Ultrasonography revealed a cystic form of adenomyosis.

Methods

Laparoscopy: adenomyomectomy

Monopolar resection adenomyoma, wound closure self-locking thread.

Concomitant resection of the bleeding stopped by bipolar coagulation.

Results

Post operation no complications

Conclusions

Laparoscopic access is an effective method of operation in cystic forms of adenomyosis

<https://player.vimeo.com/video/326297610?autoplay=1>

ES28-0019 - VP007

Video Poster

Isthmic pregnancy and rudimentary uterine horn: surgical treatment

Aleksei Golubenko¹, Umar Ykasai¹, Elena Medvedeva¹, Sonya Kieva¹, Victor Makeev¹, Varvara Kirsanova¹

¹Scientific Clinical and Multidisciplinary Medical Research Center Oryol, Gynaecology, Oryol, Russia

Background

The patient is 27 years old and has a history of primary infertility for 3 years. According to ultrasonography, interstitial pregnancy is revealed on the left. Laparoscopy was performed, uterus developmental anomaly was diagnosed intraoperatively: a single-horned uterus, a functioning rudimentary horn on the right and an interstitial tubal pregnancy on the right. Extirpation of a rudimentary uterine horn from the right fallopian tube was done

Methods

The operation was carried out from standard laparoscopic access, monopolar resection of the right uterine angle, uterine fistula closure with separate intracorporal sutures.

Results

The postoperative period was uneventful.

After discharge for 6 months, contraception is recommended.

Conclusions

Laparoscopic approach is an effective procedure for surgery in the interstitial form of ectopic pregnancy in combination with a functioning rudimentary uterine horn.

<https://player.vimeo.com/video/325617709?autoplay=1>

ES28-0020 - VP008

Video Poster

Pre-gravity preparation of the patient with cervico-vaginal fistula and CIN III

Aleksei Golubenko¹, Elena Medvedeva¹, Umar Yakasai¹, Sonya Kieva¹, Victor Makeev¹, Ramilya Golubenko¹

¹Scientific and Clinical Multidisciplinary Medical Research Center Oryol, Gynaecology, Oryol, Russia

Background

A 26-year-old patient who had an emergency caesarean section about the weakness of labor 2 years ago had a cervical vaginal fistula, severe cervical dysplasia revealed by colposcopy. during pregnancy, the patient had transvaginal cerclage due to isthmic-cervical insufficiency. In preparation for the next pregnancy and in order to treat severe cervical dysplasia, an operation was performed: laparoscopic cerclage. Conization of the cervix.

Methods

The operation was carried out from a standard laparoscopic approach, mercene tape 5 mm wide was used with 2 straight needles. the tape is applied at the level of the internal pharynx, the node is formed in the anterolateral space, peritonized

Results

The postoperative period was uneventful.

After discharge, contraception is recommended for 1 year, in terms of observation and examination after treatment of severe dysplasia. When the control PAP test and colposcopy after 6 months: no signs of relapse.

Conclusions

Laparoscopic cerclage is an effective procedure for surgery for insolvency of the cervix associated with anatomical causes.

The use of simultaneous treatment of severe cervical dysplasia with a method aimed at carrying a pregnancy is an effective pregravid method of preventing preterm birth.

<https://player.vimeo.com/video/325622793?autoplay=1>

ES28-0022 - VP009

Video Poster

Surgical treatment of a complicated form of rudimentary uterine horn

Aleksei Golubenko¹, Umar Yakasai¹, Victor Makeev¹, Sonya Kieva¹, Elena Medvedeva¹, Darya Kirsanova¹

¹Scientific and Clinical Multidisciplinary Medical Research Centre, Gynaecology, Oryol, Russia

Background

The patient is a 15 year old with complaints of dysmenorrhea, chronic pelvic pain since menarche at 2 years ago. Ultrasound examination revealed right ovarian cyst, aplasia of the right kidney, hematosalpinx on the right and abnormal uterus.

Methods

Ultrasonography
Laparoscopy
Extirpation of the rudimentary uterine horn
Resection of the right ovary
Salpingectomy
Adhesiolysis
Hysterectomy

Results

Post operation uneventful

Conclusions

Laparoscopic access is effective in such cases

<https://player.vimeo.com/video/325632022?autoplay=1>

ES28-0023 - VP010

Video Poster

Bilateral laparoscopic cystectomy of pregnancy 16-17 weeks

Aleksei Golubenko¹, Umar Yakasai¹, Victor Makeev¹, Elena Medvedeva¹, Sonya Kieva¹, Ramilya Golubenko¹

¹Scientific and Clinical Multidisciplinary Medical Center, Gynecology, Oryol, Russia

Background

At 16-17 weeks of pregnancy, tumours of both ovaries was revealed. Patient complained of pain in the lower abdomen

Methods

Ultrasonography

Laparoscopy

Results

Post operation no complications

Normal pregnancy

Conclusions

Laparoscopic cystectomy is effective and safe method of treatment in pregnancy

<https://player.vimeo.com/video/325655071?autoplay=1>

ES28-0025 - VP011

Video Poster

Surgical treatment of recurrent genital prolapse after laparoscopic pectovaginopexy

Aleksei Golubenko¹, Umar Yakasai¹, Sonya Kieva¹, Victor Makeev¹, Ramilya Golubenko¹, Elena Medvedeva¹

¹Scientific and Clinical Multidisciplinary Medical Center, Gynaecology, Oryol, Russia

Background

A 51 year old who laparoscopic pectovaginopexy a year ago noticed relapse of prolapse and urinary incontinence for 2 months. Ultrasonography revealed endometrial polyps

Methods

Laparovaginal pan hysterectomy

Anterior colporrhaphy

Transobscurator sling

Results

Post operation no complications

Conclusions

Methods are effective in treatment of cases like this

<https://player.vimeo.com/video/326379000?autoplay=1>

ES28-0027 - VP012

Video Poster

Installation and removal of laparoscopic cerclage

Aleksei Golubenko¹, Umar Yakasai¹, Sonya Kieva¹, Victor Makeev¹, Elena Medvedeva¹, Ramilya Golubenko¹

¹Scientific and Clinical Multipledisciplinary Medical Centre, gyne, Oryol, Russia

Background

A 36 years old with history of 2 miscarriages. Had laparoscopic cerclage inserted posteriorly

Methods

Stages of installation of tape:

Incision of vesico uterine fold

Dissection of bladder

Visualization of left uterine vessels

Dissection posterior sheet of wide utrine lagament

Dissection of the posterior leaf of wide uterine ligament

Passage of mersilen tape from the left to right

6 nodes

Peritonization

Stages of removal:

Adhesiolysis

Enterolysis

Identification of node of cerclage

Results

18 month post operation, patient complained of infertility and chronic pelvic pain.

Laparoscopy done revealed adhesions.

Adhesiolysis done and tape removed.

Conclusions

Installation and removal of laparoscopic cerclage is safe surgical technology

<https://player.vimeo.com/video/326394728?autoplay=1>

ES28-0026 - VP013

Video Poster

Laparoscopic treatment of postpartum hematoma

Aleksei Golubenko¹, Umar Yakasai², Victor Makeev¹, Sonya Kieva¹, Elena Medvedeva¹, Ramilya Golubenko¹

¹Scientific and Clinical Multidisciplinary Medical Research Centre, Gynaecology, Oryol, Russia

²Scientific and Clinical Multidisciplinary Medical Research Center, Gynaecology, Oryol, Russia

Background

A 28 year old patient had surgical hemostasis due to early postpartum haemorrhage (flashing of uterine vessels and imposition of compression sutures on the uterus). 5th day post op a laparoscopy was done due to intestinal paresis and hematoma of the small pelvis was revealed.

Methods

Stages of operation:

Laparoscopy

Adhesiolysis

Revision of the uterus

Sanation

Removal of suture
Drainage

Results

Post operation no complication

Conclusions

Laparoscopy is effective in treatment of postpartum hematoma

<https://player.vimeo.com/video/326401347?autoplay=1>

ES28-0076 - VP014

Video Poster

Left ovarian transposition of undescended ovary and unicornuate uterus

Charles Miller¹, Kirsten Sasaki¹

¹The Advanced Gynecologic Surgery Institute/ The Ad, Gynecology/Infertility, Naperville, USA

Background

To educate the minimally invasive gynecologist on the rare diagnosis of an undescended ovary and to demonstrate a laparoscopic technique for ovarian transposition to facilitate trans-vaginal oocyte monitoring and retrieval.

Methods

Laparoscopic ovarian transposition

Results

After the transposition, the left ovary is now visible on transvaginal ultrasound and accessible for transvaginal oocyte retrieval.

Conclusions

Laparoscopic ovarian transposition is a feasible, safe option to facilitate oocyte retrieval in cases of undescended ovaries.

<https://player.vimeo.com/video/333853581?autoplay=1>

ES28-0089 - VP017

Video Poster

Laparoscopic management of cervical myoma: a case report

Iveta Mikeltadze¹, Pille Soplepmann¹, Ülle Kadastik¹

¹Women's Clinic of Tartu University Hospital, Gynecology, Tartu, Estonia

Background

Uterine myomas are the most common gynecological disorder that occurs in 20-50% of reproductive age women. Most myomas arise from the uterine body. Cervical myomas are very rare and account for less than 5% of uterine myomas.

Surgical treatment of the cervical myoma is challenging due to its location, bad accessibility, non-optimal cervical mobility, increased risk of bleeding, adjacent organs and suturing difficulties.

Methods

The video illustrates a case of a 29 years old woman, who referred to our clinic due to abnormal uterine bleeding. Vaginal examination revealed cervical mass, that upon ultrasound scanning was suggested to be a 6,2x5,9x6,9

cm cervical myoma. Ultrasound findings were confirmed with MRT scan as well. For cervical myoma shrinkage the patient was administered with pre-operative gonadotropin-releasing hormone analogue (GnRHa) therapy. During therapy the volume of cervical myoma decreased from 130ml to 99 ml. After 3 injections of GnRHa patient was admitted to our department due to heavy uterine bleeding and it was decided to perform a laparoscopic myomectomy earlier than planned. During the laparoscopic surgery was accessed 6x5x6 cm cervical myoma originating from the posterior lip of cervix. Intramyometrially was injected adrenaline solution into the planned uterine incision site and myomectomy was performed. During myomectomy vagina was opened up. Removed cervical myoma was extracted from abdominal cavity through vagina and opening was closed. Blood loss during operation was minimal.

Results

The postoperative period elapsed without complications. Patient was discharged from the hospital in a good general condition on III postoperative day. The histology confirmed uterine leiomyoma diagnosis. 2 months after surgery patient came on follow up appointment and had no complaints. Ultrasound examination showed no uterine abnormalities.

Conclusions

Laparoscopic surgery is safe and effective method to remove cervical myomas.

<https://player.vimeo.com/video/334258980?autoplay=1>

ES28-0103 - VP018

Video Poster

Robotic modified radical trachelectomy and abdominal cerclage for cervical myoma

Ceana Nezhata¹, Pavan Ananth², Gerald Feuer³

¹Nezhat Medical Center, MIS, Atlanta, USA

²Nezhat Medical Center, Minimally Invasive Surgery, Atlanta, USA

³Northside Hospital, Gynecologic Oncology, Atlanta, USA

Background

Patient is a 28 year old nulligravida who underwent a prior robotic-assisted laparoscopic myomectomy for what was believed to be a symptomatic myomatous uterus. Final pathology, however, showed a smooth muscle tumor of uncertain malignant potential (STUMP). She was closely followed and was noted to have continued growth of the uterine tumor, with persistent symptoms. Despite extensive counselling, the patient adamantly refused hysterectomy and elected to undergo a second myomectomy due to her desire to preserve her fertility. Preoperative ultrasound showed a heterogenous, enlarged, uterus with multiple myomas.

Methods

Upon laparoscopic visualization of the pelvis, it was noted that the tumor had completely replaced the cervix. These findings were relayed to the family, who continued to decline hysterectomy. The decision was then made to proceed with a modified radical trachelectomy, in an effort to resect the tumor and preserve the uterine corpus. After successful completion of the surgery, it was apparent that the patient would not be a candidate for either labor or a vaginal delivery and would have significant risk of cervical insufficiency, so an abdominal cerclage was placed. To our knowledge, this is the first time such a case has ever been reported.

Results

The patient's postoperative course was uneventful and she was discharged home in good condition on postoperative day one. Estimated blood loss was less than 100 ml. The final pathology was benign leiomyoma.

Conclusions

The surgical management of cervical myomas can be very challenging, particularly in patients who are young and wish to retain their reproductive potential. These myomectomies are often done in an open fashion and are associated with excessive blood loss. Cases involving significant hemorrhage or severe distortion of the anatomy, leading to difficulty reconstructing the lower uterine segment and/or vagina, can prompt surgeons to perform an unplanned hysterectomy. In this case, the critical components of success included isolating and sacrificing the blood supply to the tumor early on during the procedure and identifying the need for a cerclage during the repair of the colpotomy.

Gynecologic oncologists routinely perform radical procedures for malignant pathologies and other advanced pelvic surgeons are able to perform this type of dissection. It is critical for them to recognize that this operation can be used for benign indications, as in the case described above.

<https://player.vimeo.com/video/334989332?autoplay=1>

ES28-0272 - VP019

Video Poster

Robotic hysteroscrapexy in 8 easy steps

Dimitrios Balafoutas¹, Achim Woeckel¹, Ralf Joukhadar¹

¹Würzburg University Hospital, Obstetrics & Gynecology, Würzburg, Germany

Background

Laparoscopic sacropexy is currently regarded as the gold standard procedure for the treatment of pelvic organ prolapse (POP). Uterine preserving techniques have shorter duration and less tissue injury. The robotic systems support the surgeon, thus facilitating shorter learning curves and higher feasibility along with lower rates of conversion to laparotomy.

Methods

We present an instructional video about the crucial steps of uterine preserving robotic sacropexy using the DaVinci Xi Surgical System. In this video, we describe the 8 main steps of the procedure along with tips and tricks to improve the surgical technique and to ensure patient safety. In our case a 59 yo patient with uterine prolapse POP-Q-Stage-III is presented.

Results

The outcome is the correction of the prolapse (POP-Q-Stage-0), short duration of the procedure (89 minutes), estimated blood loss of 25 ml and short hospital stay of 2 days.

Conclusions

When applying the right technique, robotic hysteroscrapexy is a reproducible, easy to perform and safe procedure to treat POP with good anatomical and functional results along with low blood loss and short hospital stay.

<https://player.vimeo.com/video/335237183?autoplay=1>

ES28-0438 - VP021

Video Poster

Vaginal morcellation technique

Kyung Hee Han¹, Dongho Kim¹

¹In-Ha Univ, Gynecology, InCheon, Korea- Republic Of

Background

For recent three decades, the increasing use of laparoscopy is an important feature in gynecologic surgery. A limit of laparoscopic approach is to remove the large surgical specimens. The introduction of electromechanical morcellation reduced the procedure time, but still morcellation is the most time-consuming part of the entire procedure in the cases of huge mass. Bigger sized morcellator is preferred to avoid prolongation of operation time, but accompanied additional skin incision which causes more post-operative pain and less cosmetic effect, does not correspond to the requirements of minimally invasive surgery. We carried out morcellation by the vaginal route using Semm's morcellation sets. We showed how to perform the vaginal morcellation in the cases of the myomectomy and subtotal hysterectomy.

Methods

After completion of main laparoscopic surgery, the guide rod of CURT is introduced into posterior fornix of the vagina and the fornix is perforated under laparoscopic vision as the same procedures as that in culdocentesis. 20mm of Semm's dilatation set is introduced into posterior fornix of the vagina and push up with clockwise rotation along with the guide rod under laparoscopic vision. The posterior fornix of the vaginal wall is easily dilated and perforated with 20 mm of Semm's dilatation set. Remove the dilatation set and 20mm Semm morcellator is advanced into the pelvic cavity for morcellation of the specimen. The surgical specimen is placed into pelvic cavity. Morcellation is performed using a 10mm claw forceps placed through morcellator. The assistant orients the specimen for the ovarian forceps in such a manner as to maintain the morcellator edge on the outer of the specimen

Results

VM through the PCDS using an electromechanical morcellator is a safe and feasible technique for surgical excision. The benefits of the procedure over AM are reduced immediate postoperative pain, shorter morcellation time and better cosmesis

Conclusions

VM through the PCDS using an electromechanical morcellator is a safe and feasible technique for surgical excision. The benefits of the procedure over AM are reduced immediate postoperative pain, shorter morcellation time and better cosmesis.

<https://player.vimeo.com/video/335303925?autoplay=1>

ES28-0154 - VP022

Video Poster

Novel method for accurate dissection in robotic surgery

Masaaki Andou¹, Shiori Yanai¹, Kiyoshi Kannno¹, Midori Okumura²

¹*Kurashiki Medical Center, Gynecology, Kurashiki-shi, Japan*

²*Shirakawa Clinic, Gynecology, Fukuyama-shi, Japan*

Background

To show how the double bipolar method allows for pinpoint accuracy of dissection in robotic surgery.

Methods

Prof Ichiro Uyama, a robotic gastrointestinal surgeon, pioneered the double bipolar method. From December 26th 2018 to April 22nd 2019, 21 patients underwent surgery where this technique was applied such as robotic modified radical hysterectomy and bilateral salpingo-oophorectomy with pelvic lymphadenectomy robotically on a clinical stage Ia case (grade 1-2 histology). Patients with clinical stage Ib (or grade 3 histology) also underwent laparoscopic extraperitoneal paraaortic lymphadenectomy. For the double bipolar method we use robotic Maryland forceps as the cutting device with a Valleylab TM FT10 energy platform (ForceTriad TM energy platform) at macromode 60W.

Results

Estimated blood loss was 201ml, operating time was 171mins. No patients who underwent these interventions suffered organ injury or required a blood transfusion. All patients featured in this video presentation gave their consent for their operative footage and patient data to be used for research and educational purposes.

Conclusions

This technique is useful for addressing and preventing issues commonly associated with the use of energy devices such as adjacent tissue injury. The pinpoint accuracy of this technique is important for bladder and ureteral dissection and exposure of vessels as the cuts are made in a very limited scope. The device works by a lightning strike mechanism, causing spark vaporization of the tissue, as a result there is minimal thermal spread to adjacent organs. The pinpoint accuracy of the bipolar method allows for safe and complete dissection.

<https://player.vimeo.com/video/335741724?autoplay=1>

ES28-0138 - VP023

Video Poster

Transvaginal single-port laparoscopic hysterectomy for large uterine

Yisong Chen¹, Xiaojuan Wang¹

¹The Obstetrics and Gynecology Hospital of Fudan University, Gynecology Department, Shanghai, China

Background

To demonstrate the transvaginal natural orifice transluminal endoscopic surgery (NOTES) hysterectomy for large uterine (the size of six months pregnancy) with combined transvaginal surgical and single-site surgical skills.

Methods

A 55-year-old woman (gravida 2 para 2) with a preoperative magnetic resonance imaging diagnosis of myoma associated necrosis (the uterine is as large as 6 months pregnancy) requested hysterectomy and bilateral adnexectomy. Transvaginal NOTES hysterectomy with combined transvaginal surgical and single-site surgical skills were performed.

Results

The operation took roughly 85 minutes and total blood loss was approximately 100ml. The patient recovered well and was discharged 2 days after surgery. The pathology revealed a necrotic myoma.

Conclusions

Combined with traditional transvaginal anterior/posterior colpotomy, single-site surgical skills allow the surgeon to accomplish hysterectomy for large uterine without abdominal incision and let patient recover rapidly.

<https://player.vimeo.com/video/336811545?autoplay=1>

ES28-0155 - VP024

Video Poster

Keywords for strategies for preventing recurrence in early invasive cervical cancer cases - completeness and isolation

Masaaki Andou¹, Shiori Yanai¹, Kiyoshi Kanno¹, Midori Okumura²

¹Kurashiki Medical Center, Gynecology, Kurashiki-shi, Japan

²Shirakawa clinic, Gynecology, Fukuyama-shi, Japan

Background

To present strategies for the regulation and enhancement of the safety and completeness of laparoscopic and robotic radical hysterectomy/radical trachelectomy (L-RH/RT +R-RH/RT= MI-RH/RT)for early invasive cervical cancer. We will present our techniques and skills as well as data on our long-term outcomes for MI-RH/RT patients.

Methods

170 early invasive cervical carcinoma stage IA1(LSVI+)-IB1 who underwent I MI-RH/RT between 2006-2015 were reviewed. Cases who underwent neo-adjuvant therapy were excluded from this study. We considered the keys to recurrence-free surgical intervention with regard to the techniques we apply in surgery in an attempt to regulate quality of dissection. Our keywords are completeness and isolation. Setting landmarks for dissection boundaries ensures completeness of dissection. For our type C radical hysterectomy/ trachelectomy, our goal is to remove the full length of the cardinal ligament.

To prevent the scattering of tumor cells isolation is important. We create a vaginal cuff as an initial stage of our procedure and don't use a uterine manipulator as there is the concern that this could stimulate any tumors in the vicinity. When extracting the specimen, we use a large protection bag. This bag prevents spillage of tumor cells in the abdominal cavity and prevents possible port site/ extraction site contamination.

Results

Of the patients included in this study, disease-free survival is 97.1% and the 5 year overall survival in 98.2%. All patients featured in this video presentation gave their consent for their operative footage and patient data to be used for research and educational purposes.

Conclusions

In our retrospective study, our minimally invasive approach for early-stage non-bulky cervical cancer is feasible and safe in terms of oncological outcomes. We found that focusing on standards for completeness and isolation were key factors in preventing recurrence.

<https://player.vimeo.com/video/335742457?autoplay=1>

ES28-0146 - VP026

Video Poster

Shaving of rectovaginal endometriosis

*Vasileios Minas*¹

¹Ashford & St. Peter's Hospital, Obstetrics & Gynaecology, Chertsey, United Kingdom

Background

A patient with severe painful pelvic symptoms and palpable recto-vaginal endometriosis which did not appear to involve the rectum muscularis in pre-operative investigations, elected to have laparoscopic excision of endometriosis.

Methods

The surgical steps of the procedure included the usual approach to rectovaginal endometriosis, starting with sigmoid adhesiolysis, ureterolysis to ensure the ureters were dissected safely away from the disease, adhesiolysis and mobilisation of the ovaries, suspension of uterus and ovaries to optimise access to pelvis, dissection of the pararectal spaces and shaving of the disease off the rectum, vagina and pelvic sidewalls with excision of the uterosacral ligaments.

Results

The procedure was completed laparoscopically with minimal blood loss. The patient's recovery was uneventful. Six months following surgery the majority of her painful symptoms had resolved.

Conclusions

A structured approach to the surgical excision of endometriosis using the principles of the SO-SURE acronym (survey and sigmoid mobilization, ovarian mobilization, temporary suspension of ovaries and uterus, ureterolysis, rectovaginal septum entry, entry into pararectal spaces and resection of all visible disease) provides safety and ensures complete excision of visible disease in patients undergoing laparoscopic surgery for endometriosis.

<https://player.vimeo.com/video/335662689?autoplay=1>

ES28-0210 - VP027

Video Poster

Laparoscopic ureteroneocystostomy - a minimally invasive repair technique for UV fistula

*Masaaki Andou*¹, *Shiori Yanai*¹, *Kiyoshi Kanno*¹, *Midori Okumura*²

¹Kurashiki Medical Center, Gynecology, Kurashiki-shi, Japan

²Shirakawa Clinic, Gynecology, Fukuyama-shi, Japan

Background

To present two cases of laparoscopic ureterovaginal fistula repair with uteroneocystostomy.

Methods

Case 1 suffered from fluid leakage two days after laparoscopic hysterectomy. Leakage of urine from the lower ureter was discovered on the CT scan. For repair, we performed laparoscopic ureteroneocystostomy with a psoas hitch to extend the length of the ureter. In this case, meticulous dissection was required to perform a complete surgery without impairing blood perfusion.

Case 2 was referred to us from another institute. She reported vaginal fluid leakage for four years, two weeks after undergoing abdominal hysterectomy. Six months after this original surgery, an urologist attempted to repair the fistula but failed due to excessive adhesion. This case was extremely challenging.

Results

No patients experienced stenosis or leaks and no other complications occurred and no blood transfusions were required. The fistulas were repaired without sequel. The patients were able to ambulate and take a normal diet the day after the surgery and could be discharged 4 days after surgery. All patients featured in this video presentation gave their consent for their operative footage and patient data to be used for research and educational purposes.

Conclusions

Although knowledge of reconstruction and laparoscopic skills such as intracorporeal suturing and ligation are difficult to master, this technique is valuable in its feasibility and patient friendliness.

<https://player.vimeo.com/video/335970597?autoplay=1>

ES28-0176 - VP028

Video Poster

Laser laparoscopy treatment of the uterine scar dehiscence (Isthmocele) with retroperitoneal anterior suspension of the uterus

Stavros Karampelas¹, Michelle Nisolle²

¹University of Liege-Hospital La Citadelle, Department of Gynaecology and Obstetrics, Tervuren, Belgium

²University of Liege, Gynecology and Obstetrics, Liege, Belgium

Background

The purpose of this study was to perform the best treatment for a patient with a dehiscence of the uterine scar (Isthmocele) with a residual myometrium of less than 1mm and a retroverted uterus.

The main symptoms were chronic pelvic pain and metrorrhagia.

The patient had a desire of pregnancy

Methods

The laser laparoscopic technic was chosen to treat this patient.

The vesico-uterine fold was detached in order to expose the uterine scar.

The next step was the introduction of a hysterometer into the uterine cavity and its placement to the isthmocele in order to expose the myometrial tissue that needed to be resected.

With the help of the laser the entire defected cavity of the uterine scar was resected up to the point where normal myometrium was visualised having thickness of about 10mm.

The myometrium was sutured in a superficial and a profound layer using monofilament absorbable suture.

Firstly the profound part of the myometrium was sutured using 0 size interrupted sutures.

The superficial myometrium was sutured using a 2-0 continuous suture.

The anterior suspension of the uterus was performed by passing a grasping forceps by the lateral trocars retroperitoneally up to the mid part of the round ligament. The round ligament was suspended to the point of the lateral abdominal wall and it was fixed to the aponeurosis using a polyfilament absorbable suture.

Results

The patient was discharged 20 hours after the operation.

Post operative pain was 5/10 the day of the operation.

No complications were reported

The patient was relieved from her symptoms of metrorrhagia and chronic pelvic pain one month after the operation.

The post operative myometrial thickness was minimal 9.3mm and maximal 10.3mm.

Conclusions

The laparoscopic approach for patients with myometrial thickness of less than 3mm is the treatment of choice in comparison to the hysteroscopic approach in order to avoid complications with the urinary bladder.

The technic is relatively easy to perform and the mean operative time is about one hour.

The post operative pain is low, the mean hospitalisation time is 24 hours and the probability of complications negligible.

Patients are relieved of their symptoms of metrorrhagia and chronic pelvic pain.

It is proven that the repair of an Isthmocele increases the pregnancy rate in patients with no other infertility factor.

The myometrial thickness increases post operatively which is important in patients with desire of pregnancy.

In case of retroversion to the uterus and Isthmocele, an anterior suspension of the uterus is recommended in order to decrease the tension of the sutures and improve the post operative results.

A pregnancy is allowed 3 months after the operation and an elective caesarean section is necessary since we do not have enough evidence for the moment to authorise a vaginal birth.

<https://player.vimeo.com/video/335951360?autoplay=1>

ES28-0180 - VP029

Video Poster

Learning TVT-O in 10 steps

Erika Mangano¹, Sandrine Campagne-Loiseau¹, Sandra Curinier¹, Michel Canis¹, Pauline Chauvet¹, Nicolas Bourdel¹

¹CHU Estaing, Gynecologic Surgery Department, Clermont-Ferrand, France

Background

Transvaginal Tension Free Vaginal Tape-Obturator (TVT-O) is an effective surgical treatment for stress urinary incontinence in women. This technique has been used for many years, but some complications still occur during and after this surgical procedure. These complications cause a high burden for patients, who frequently have to receive others invasive treatments subsequently. The main objective of this video is the standardization and accurate description of this surgical procedure adding some tips and tricks.

Methods

Step-by-step description of the technique through a video. Patients cannot be identified and they signed a written consent to use of video recording for research/scientific/teaching purpose. We considered video recording of TVT-O procedures in the same French tertiary care teaching hospital to build up the video.

Results

We identify more delicate steps of this surgical procedure in order to give advices for managing them successfully. Moreover we assess 10 rational steps in the procedure, which can help to standardize it: 1. patient's ergonomics, 2. anesthetic infiltration, 3. single vaginal incision, 4. creation of the pathway for device placement, 5. placement of the device, 6. check flat position of the tape, 7. obtain right tension of the mesh, 8. cut both lateral arms of the tape emerging from the skin, 9. urinary drainage to exclude stenosis, 10. suture vaginal mucosa and skin.

Conclusions

Together with an appropriate preoperative study, the standardization of this surgical procedure and the application of tips and tricks suggested could make this technique easier to learn for beginners and could help experienced surgeons in reducing, as much as possible, the most frequent complications too.

<https://player.vimeo.com/video/335978179?autoplay=1>

From chaos to order: restoring anatomy in frozen pelvis and segmental bowel resection for full thickness rectovaginal nodule

Konstantinos Kyriakopoulos¹, Shaheen Khazali¹, Phillip Bearn¹, Vasileios Minas¹, Matthew Errity¹

¹NHS, Centre for Endometriosis and Minimal Invasive Gynaecology, Chertsey, United Kingdom

Background

Frozen pelvis/deep infiltrating endometriosis is one of the most intimidating spectacles a gynaecologist can come across during a laparoscopy. In this video, we demonstrate our structured approach for excision of a full thickness rectovaginal nodule.

Methods

This is an edited video of a procedure performed at our unit in Chertsey, UK, CEMIG (Centre for Endometriosis and Minimal Invasive Gynaecology).

Results

We follow a structured approach which we call by the mnemonic “**SO SURE Resection**”. Depending on the case there may be an adjustment on the above order but in general the acronym itself is a well structured approach that facilitates the procedure.

The stages of the excision are as following:

1. **S**urvey of lower and upper abdomen and **S**igmoid mobilization
2. **O**varian mobilization (combination of sharp/blunt dissection)
4. a. **S**uspension of uterus using sutures
 - b. **S**uspension of ovaries
 1. **U**reterolysis
 2. **R**ectovaginal septum entry (disease is left on the uterus and normal tissue is entered in the rectovaginal space)
 3. **E**nter into pararectal space

Resection of the rectovaginal nodule/segmental bowel resection (care has been taken to lateralize the hypogastric nerve). At the end of the procedure we perform the Michellin test to ensure the integrity of rectal wall and check the safety of the anastomosis.

Conclusions

Following a structured approach ensures a safer and quicker procedure even in cases where endometriosis has entered the rectal lumen. It also provides a cleaner and more satisfying surgical field where all anatomical structures, including the hypogastric nerves) can be easily seen and preserved.

<https://player.vimeo.com/video/335972149?autoplay=1>

ES28-0183 - VP031

Video Poster

New method of lifting uterus in laparoscopic radical hysterectomy: two level lifting by ligation without uterine manipulator - based on the principle of no tumors

*Jie Chen*¹

¹*Fujian Provincial People's Hospital, Gynecology Department, Fuzhou, China*

Background

Recent studies have shown that the traditional laparoscopic had lower tumor-free and overall survival rates, higher recurrence rates and higher fatality rates than the open abdominal group. This is an important warning for laparoscopic radical hysterectomy. The use of uterine manipulator may violate the principle of tumor-free surgery.

Methods

1. We give up using uterine manipulator and switch to using surgical suture to ligate the isthmus of uterus. We can control the uterus by traction during the procedure. This method provides a good exposure of parametrial tissues and can successfully perform surgical dissection 2. Ligating the vagina to reduce cancer exposure to the pelvic cavity.

Results

After 30 cases of surgical operation, we could perform laparoscopic radical hysterectomy well with no-uterine manipulator procedure. The length of the vagina and the width of the parametrium were all up to standard.

Conclusions

This method reflects the tumor free surgical principle. Maybe these are the two key steps to safely perform laparoscopic radical hysterectomy.

<https://player.vimeo.com/video/349024057?autoplay=1>

ES28-0227 - VP033

Video Poster

Creation of peritoneal tunnel in robot assisted laparoscopic sacrohysteropexy (RALS)

*Hsin Mei Liu*¹, *Yichen Chuang*¹

¹*Far Eastern Memorial Hospital, Department of Obstetrics and Gynecology, New Taipei City, Taiwan*

Background

Sacrohysteropexy is a surgical procedure to correct uterine prolapse. It involves a resuspension of the prolapsed uterus by using a strip of synthetic mesh to lift the uterus and fix it in place. It preserves fertility and allows for normal sexual function by preserving vaginal length. Conversely, transvaginal mesh may complicated with persistent vaginal bleeding or discharge, pelvic or groin pain, or dyspareunia.

Laparoscopic sacrohysteropexy (LS) can be applied but the surgeon needs long term learning curve and advanced suture technique.

The da Vinci System is powered by robotic technology that allows the surgeon's hand movements to be translated into smaller, precise movements of tiny instruments inside the patient's body. Robot assisted laparoscopic sacrohysteropexy (RALS) is a novel and attractive technique for young women with pelvic organ prolapse. However, the surgical complication includes bleeding, peritonitis and mesh extrusion were rare but still concerned.

We develop the technique of creation of peritoneal tunnel to simplify the suture step, decrease the chance of mesh exposure, future mesh extrusion and adhesion possibility.

In this video, we compared the advantages of robotic approach in suture, intracorporeal tie and creation of peritoneal tunnel with laparoscopic approach.

Methods

We collected 3 female patients. Patient A was 35-year-old, para 3, uterine prolapse POP-Q system stage II. Patient B was 33 year-old, para 2, uterine prolapse POP-Q system stage III. Patient C was 53-year-old, para 3, uterine prolapse POP-Q system stage III. The choice of robotic or laparoscopic instrument is decided by their insurance reimbursement. They all wanted to preserve the uterus. Patient A and B received RALS while patient C received LS.

The surgical procedures included dissection of pre-sacral promontory area, anterior and posterior cervix and create a right peritoneal tunnel. Presacral vein was identified for avoiding massive bleeding. A polypropylene y-mesh was sutured attached to the anterior cervix, posterior cervix and passed through the peritoneal tunnel to the sacral promontory. The mesh was flattened and fixed by the tunnel. Peritoneal closure was performed smoothly without tension.

Results

The surgical console time was 240 min (patient A); 230 min (patient B) ; 210 min (patient C). Longer time for patient A and B were contributed to robot docking time. The blood loss were less than 100 cc. The post operation POP-Q system were both corrected to stage 0 after 5, 2 and 1 year follow up. No abdominal pain, mesh extrusion were found and they were satisfied for normal sexual intercourse.

Conclusions

It is safe and feasible to perform robot assisted laparoscopic sacrohysteropexy by creation of peritoneal tunnel.

<https://player.vimeo.com/video/336169166?autoplay=1>

ES28-0233 - VP034

Video Poster

laparoscopic simple ovarian fixation technique for the management of cases of ovarian torsion

Mohamed El Mahdy¹, Hoda Abdelsalam²

¹*Alexandria University- Faculty of Medicine, Obstetrics and Gynecology Departement, Alexandria, Egypt*

²*Ministry of Health, Obstetrics and Gynecology, Alexandria, Egypt*

Background

Ovarian torsion is one of the most dangerous acute and surgical conditions that can end with oophorectomy and affection of ovarian reserve. Simple and easy technique for management is required in order to save emergency cases especially for junior staff.

Methods

Case series of 5 cases of ovarian torsion. One case pregnant 7 weeks and 4 non gravid cases. All the cases presented with acute abdomen. Ovarian torsion was diagnosed by clinical examination, 2nd ultrasound criteria and affection of doppler sign with absent or low blood flow. Informed consent was taken from the patients before any intervention. Laparoscopic detorsin and fixation of the ovarian tip to the plicated ovarian ligament. Prophylactic fixation of the other ovary was followed. The patient consent for publishing is attached to this sector .

Results

Good postoperative stay in the hospital for 12 hours and no recurrence of the condition. The pregnant case is about 34 weeks now without any obstetrical complications. Follow up ultrasound shows good blood flow and normal doppler study.

Conclusions

Combined ovarian tip fixation to the plicated ovarian ligament can be considered a safe, easy, effective technique for management of cases of ovarian torsion.

<https://player.vimeo.com/video/336175424?autoplay=1>

ES28-0243 - VP036

Video Poster

Surgical management of repeated adnexal torsions : about a clinical case

Tamara De Rozario¹, Francois Stoll¹

¹Hôpitaux Civils de Colmar, Gynecology, Colmar, France

Background

The adnexal torsion is a surgical emergency in gynecology. It mainly concerns women presenting adnexal cysts during their period of genital activity. In case of repeated torsion, ovariopexy may be indicated to prevent the risk of recurrence. There are no recommendations for indications and surgical technique of ovariopexy.

Methods

We report the case of an 18-year-old patient with Mac Cune Albright syndrome. In her case, it only manifested by polycystic ovaries, recurrent ovarian cysts and three adnexal torsions (two on the right and one on the left). This video presents the last detorsion surgery as well as the bilateral ovariopexy performed a few weeks later. The surgical technic is detailed and its indication is discussed.

Results

Six months after procedure, the patient did not present a torsion recurrence.

Conclusions

Ovariopexy by laparoscopy seems to be a safe and effective procedure in selected patients.

<https://player.vimeo.com/video/336207123?autoplay=1>

ES28-0399 - VP037

Video Poster

High uterosacral ligament suspension with transvaginal natural orifice transluminal endoscopic surgery: presentation of 2 cases

Öğuzhan Yağdı¹, Gökay Özçeltik¹, Ahmet Özgür Yeniel¹, İsmail Mete İtil¹

¹Ege University School of Medicine, Department of Obstetrics and Gynecology, Izmir, Turkey

Background

The objective of this video is to present our technique of HUSLS via NOTES and to present the short-term outcomes and feasibility of the procedure.

Methods

2 patients with pelvic organ prolapse underwent NOTES high uterosacral ligament suspension. A 52-year-old woman (patient 1) and a 57-year-old woman with symptomatic anterior and apical prolapse admitted to our unit. The patient 1 had no previous gynecological surgeries. The examination of patient 1 revealed stage III anterior, stage III apical and stage II posterior prolapse. After discussing the available surgery options and obtaining informed consent, the patient underwent vaginal hysterectomy followed by NOTES bilateral salpingo-oophorectomy and HUSLS (according to the technique described below) and anterior colporrhaphy. The examination of patient 2 revealed stage III anterior, stage III apical and stage II posterior prolapse. The technique for NOTES HUSLS included the following steps: 1-placement of self-constructed NOTES port following vaginal hysterectomy, 2-identification of USLs and ureters on both sides, 3-suspension of the bowels to the anterior abdominal wall to improve exposure (optional), 4-ureterolysis on both sides, 5-insertion of one braided non-absorbable suture into the proximal USLs on both sides via NOTES 6-Removal of the NOTES port and insertion of two additional late absorbable sutures into the distal USLs on both sides transvaginally, 7-suturing and tying of the HUSLS sutures to the vaginal cuff, 8-closure of the vaginal cuff.

Results

Technique described was performed successfully to correct the prolapse. There were no peri-operative or post-operative complications and patients were discharged from the hospital on the second day following surgery. Post-

operative 1-month and 3-month examinations showed significant objective cure patients with high patient satisfaction in terms of quality of life and sexual function.

Conclusions

NOTES high uterosacral ligament suspension following vaginal hysterectomy appears to be a feasible, microinvasive and effective treatment option according to our short term results.

<https://player.vimeo.com/video/336447187?autoplay=1>

ES28-0400 - VP038

Video Poster

Tubal re-implantation following hysteroscopic tubal sterilization

Tina Ngan¹, Cornell Smith², John Thiel^{1,3}, Darrien Rattray³

¹Regina General Hospital, Obstetrics and Gynaecology, Regina, Canada

²Fraser Health Authority, Obstetrics and Gynaecology, Sudbury, Canada

³University of Saskatchewan, Obstetrics and Gynaecology, Regina, Canada

Background

In this video, we demonstrate a novel laparoscopic technique of tubal re-implantation following hysteroscopic tubal sterilization with micro-inserts.

Methods

First, laparoscopic bilateral cornuectomy and partial salpingectomy with removal of Essure™ coils were performed. Then, tubal cannulation with umbilical vein catheter and tubal re-implantation were demonstrated. Postoperative management included oral antibiotics, removal of stents under hysteroscopy and hysterosalpingography.

Results

The patient tolerated the procedure well; her recovery was uneventful.

Conclusions

This is the first reported case of tubal re-implantation following hysteroscopic tubal occlusion using the proposed method. The surgical steps and technical tips discussed are safe and may help patients with desire of pregnancy following Essure™ insertion who seek alternative options to assisted reproductive technology.

<https://player.vimeo.com/video/336586804?autoplay=1>

ES28-0459 - VP039

Video Poster

Laparoscopic uterine ventrosuspension procedure of apically descended uterus accomplished by using anterior mesh incorporated with bilateral round ligamentopexy: Kahyaoglu technique

Serkan Kahyaoglu¹, Yaprak Ustun¹

¹Ankara Dr. Zekai Tahir Burak Women's Health Application and Research Center- University of Health Sciences, Gynecology, Ankara, Turkey

Background

In this video presentation, we described a new surgical technique performed for correction of apical uterine prolapse in which we incorporated the lateral arms of the anteriorly anchored uterine polypropilene mesh to bilateral round ligaments combined with bilateral round ligamentopexy.

Methods

A 38-year-old G4P4A0 woman has attended to our gynecology unit with a complaint of prolapsed uterus. Upon vaginal examination, grade 3 apical uterine prolapse and grade 1 cystocele have been determined. According to the POP-Q classification the levels of uterovaginal landmarks have been detected as follows: Aa:-1 Ba:-1, Ap:-2, Bp:-3, C:-1, TVL:8. Due to the young age of the patient and lack of any other uterine pathology, we decided to perform a laparoscopic uterine ventrosuspension procedure combined with bilateral round ligamentopexy as a new and low risk uterine prolapse surgery method.

Results

During laparoscopic surgery, the peritoneal reflections just below the both round ligaments have been dissected for creating bladder flap. A 4x5 cm diamond shaped nonabsorbable mesh (Parietene™ Macroporous Mesh, Monofilament Polypropylene, Covidien™) has been anchored to the anterior part of the cervix and upper vagina by using 3/0 prolene nonabsorbable suture. Lateral arms of the centrally anchored mesh which were set as 2 cm in longevity have been incorporated to the round ligaments by using the same suture material. Postoperatively, a satisfying uterine suspension has been obtained and levels of uterovaginal landmarks have been detected as follows: Aa:-2 Ba:-3, Ap:-2, Bp:-3, C:-5,TVL:8 based on the POP-Q classification. Postoperative course of the patient was uneventful.

Conclusions

Unlike laparoscopic sacrohysteropexy, pectopexy and lateral fixation procedures; the surgical steps performed during this new surgical technique do not increase the risk of damage to neighbouring vessels, nerves or bones. Future studies comparing the efficacy, side effects, patient preferences and long term durability of this new surgical technique with previously described ones are needed.

<https://player.vimeo.com/video/337090396?autoplay=1>

ES28-0396 - VP040 Video Poster

Management of adnexal torsion in advanced pregnancy

Tina Ngan¹, Peter Thiel^{1,2}, Huse Kamencic^{1,2}

¹Regina General Hospital, Obstetrics and Gynaecology, Regina, Canada

²University of Saskatchewan, Obstetrics and Gynaecology, Regina, Canada

Background

The objective of this video is to review the risk factors, perioperative planning, and surgical management of adnexal torsion in advanced pregnancy.

Methods

A minimally invasive approach to the surgical management of adnexal torsion in advanced gestation is demonstrated. The procedure will be shown in a stepwise approach consisting of: identification of the anatomy, determination of accessory port placement, detorsion of the adenexa and finally removal of the specimen. Furthermore, general pearls to utilize and pitfalls to avoid in laparoscopic surgery during pregnancy are discussed.

Results

The patient tolerated the procedure well. She had an uneventful vaginal delivery at term. Pathology of the ovarian cyst was benign.

Conclusions

A minimally invasive approach to the management of adnexal torsion in advanced gestation can be safely accomplished through proper surgical planning, a stepwise approach and minimal manipulation of the gravid uterus.

<https://player.vimeo.com/video/336584671?autoplay=1>

ES28-0298 - VP044
Video Poster

Difficult pelvic lymphadenectomy in cytoreductive surgery for ovarian cancer

Li Li¹, Xiwa Zhao¹

¹The 4th hospital of Hebei Medical University, Gynaecology, Shijiazhuang, China

Background

Epithelial ovarian cancer is the common malignant tumor, with high mortality and poor prognosis. The recurrence is 75-80% in 2 years. The common reason of recurrence is chemotherapy-resistant. In general, every effort should be made during a primary cytoreduction procedure to achieve maximum cytoreduction of all abdominal, pelvic, and retroperitoneal disease since this offers superior survival outcomes. Those patients with tumor nodules outside the pelvis \leq 2cm should have bilateral pelvic and para-aortic lymph node dissection.

Methods

A case with enlarged and hard lymph node was studied in the research

Results

The ovarian cancer patient, age 56, was found by the supraclavicular adenopathy, supported by pathological biopsy. A laparoscopic exploration was done and ovarian cancer mass was found in right ovary. Pelvic lymph nodes enlarged and reconciled. The successful use of ultrasonic knife was important to separate adhesion to the vessels. The shaking to single page knife was quite useful to separate dense adhesion and quite safe.

Conclusions

The successful use of ultrasonic knife is significant to difficult pelvic lymphadenectomy

<https://player.vimeo.com/video/336522017?autoplay=1>

ES28-0361 - VP047
Video Poster

Robotic assisted neovagina sacropexy in a male to female transgender patient with pelvic organ prolapse after gender affirming surgery

Luigi Della Corte¹, Francesco Paolo Improda², Maria Chiara De Angelis¹, Marcello Granata¹, Pierluigi Giampaolino², Giuseppe Bifulco¹

¹University of Naples Federico II, Neuroscience- Reproductive Sciences and Dentistry, Naples, Italy

²University of Naples Federico II, Public Health, Naples, Italy

Background

The creation of a neovagina is the keystone of the treatment of male-to-female transgenders (MtF). Among potential complications of this surgical procedure, prolapse of the neovagina should be considered. In the cisgender patient, sacrocolpopexy is the gold standard surgery for the treatment of vaginal vault prolapse. However, the optimal surgical technique to treat prolapse of the neovagina in the MtF transgender patient has not been identified. The aim of this report was to describe the technique of robotic-assisted sacropexy of neovagina prolapse in a MtF transgender patient and to provide a detailed description of the procedure.

Methods

A 24-years-old MtF transgender patient with gender dysphoria underwent an intervention of complete removal of the penis and testicles and creation of a neovagina. However, she presented to our attention with a complete prolapse of the neovaginal cuff, one year after surgery. A robotic assisted laparoscopic neovagina sacropexy was performed using a Da Vinci Xi Robot.

Results

The patient had an excellent postoperative course. She was discharged home on postoperative day 2 without complications. The patient resumed vaginal intercourse three months after surgery. After two years of follow-up there were no long-term complications or recurrence of the prolapse.

Conclusions

Robotic-assisted neovagina sacropexy is a feasible and safe alternative to treat neovaginal prolapse in MtF transgender patients. It should be considered as a minimally invasive surgical alternative for the management of this uncommon complication of gender affirming surgery in MtF transgender patients.

<https://player.vimeo.com/video/336430562?autoplay=1>

ES28-0369 - VP049

Video Poster

Encountering and preserving the levator ani nerve during laparoscopic DIE surgery

*Chung-hsien Sun*¹

¹*Lucina Women & Children Hospital, Obs&Gyn, Kaohsiung City, Taiwan*

Background

There are many important somatic and autonomic nerves in the pelvic retroperitoneal space. DIE (deep infiltrating endometriosis) lesions frequently involve uterosacral ligament (USL) and then infiltrate to the retroperitoneal structures. Nerve-sparing DIE excision is our surgical goal. Most of us are familiar with the anatomy of hypogastric nerve, pelvic splanchnic nerve, pelvic plexus and sacral nerve roots. Levator ani nerve originates from S3 to S5, travels just superficial to the levator ani muscles to innervate these muscles. Levator ani nerve is rarely encountered or exposed during our routine laparoscopic DIE surgery. In this video, we will demonstrate a rare case with Rt posterior DIE lesions infiltrating almost the whole USL, involving the levator ani nerve.

Methods

Surgical videos were collected and edited.

Results

Hidden in the DIE fibrotic complex, it was difficult to directly identify the levator ani nerve. The indirect sign of the nerve entrapment is the levator ani muscle twitching during electrosurgery nearby the nerve. After careful stratification of the USL DIE complex, and careful dissection and exposure of the hypogastric nerve, pelvic splanchnic nerve, and sacral nerve roots, the right levator ani nerve originated from S3 can be identified, and preserved, while taking out all the fibrotic USL DIE lesions.

Conclusions

Although rare, levator ani nerve may be involved by DIE lesions. With the anatomical knowledge, it is possible to isolate and preserve the nerve during laparoscopic DIE surgery.

<https://player.vimeo.com/video/336431684?autoplay=1>

ES28-0381 - VP050

Video Poster

History of one DynaMesh - sequence of events in a short space of time

Zbigniew Tkacz¹

¹Medical School -Dundee University, Obstetrics and Gynaecology Dundee University, Dundee- Scotland, United Kingdom

Background

This video presents the case of subsequent surgeries in a short space of time and demonstrates unique features of the DynaMesh like: low tendency for adhesions, relatively easy detachment from the tissue and reattachment with no need to replace the mesh. It proves safety and universality of the DynaMesh with low tendency for inflammatory process and low risk for infection. Patient with apical prolapse underwent laparoscopic subtotal hysterectomy and pectopexy with DynaMesh. Histopathology results of the uterus revealed grade 1 endometrial carcinoma. Subsequent surgery a month later consisted of the laparoscopic detachment of the mesh from the cervix (central part of the mesh) and as recommended by the oncology MDT, removal of the cervix with BSO. Unfortunately, the mesh has not been covered with the peritoneum at the time of surgery hence another surgery a week later. Finally, after the next three months the patient underwent a fourth surgery with the reattachment of the mesh to the vaginal vault.

The outcome after the next six months since the last operation was excellent with apex at -7 and surprisingly no symptoms of erosion or dyspareunia. History of one DynaMesh - sequence of events in a short space of time.

Methods

Sequence of surgical procedures

Results

Results of the subsequent four surgeries

Conclusions

The DynaMesh has low tendency for adhesions, relatively easy detachment from the tissue and reattachment with no need to replace the mesh, low risk for infection and good mechanical features

<https://player.vimeo.com/video/336441587?autoplay=1>

ES28-0391 - VP051

Video Poster

History of one DynaMesh - sequence of events in a short space of time

Zbigniew Tkacz¹

¹Medical School -Dundee University, Obstetrics and Gynaecology, Dundee University, Dundee- Scotland, United Kingdom

Background

This video presents the case of subsequent surgeries in a short space of time and demonstrates unique features of the DynaMesh like: low tendency for adhesions, relatively easy detachment from the tissue and reattachment with no need to replace the mesh.

It proves safety and universality of the DynaMesh with low tendency for inflammatory process and low risk for infection.

Patient with apical prolapse underwent laparoscopic subtotal hysterectomy and pectopexy with DynaMesh. Histopathology results of the uterus revealed grade 1 endometrial carcinoma. Subsequent surgery a month later consisted of the laparoscopic detachment of the mesh from the cervix (central part of the mesh) and as recommended by the oncology MDT, removal of the cervix with BSO. Unfortunately, the mesh has not been covered with the peritoneum at the time of surgery hence another surgery a week later. Finally, after the next three months the patient underwent a fourth surgery with the reattachment of the mesh to the vaginal vault.

The outcome after the next six months since the last operation was excellent with apex at -7 and surprisingly no symptoms of erosion or dyspareunia.

Methods

This is one abstract video presentation and I would like to submit the identifiable patient

Results

As above this is a back side of the two page consent form and I cannot submit two pictures for technical reasons of ESGE

Conclusions

As in the already submitted abstract

<https://player.vimeo.com/video/336445029?autoplay=1>

ES28-0445 - VP052

Video Poster

Vaginal in-bag morcellation for ovarian fibroma

Kyung Hee Han¹, Dongho Kim¹

¹Inha University Hospital, Obstetrics and Gynecology, Incheon, Korea- Republic Of

Background

Our group already presented the feasibility of vaginal electromechanical morcellation through posterior-cul-de-sac. However, possible tumor spillage or tumor implantation induced from morcellation was a rising issue in laparoscopic surgery. Thus, endobag has been the alternative tool for power morcellation. In-bag morcellation was reported as safe technique during laparoscopic surgery. Thus, we executed in-bag morcellation with Semm set through posterior-cul-de-sac.

Methods

A video of woman aged 59 with right ovarian benign solid mass.

Results

After right salpingo-oophorectomy, the specimen was extracted using in-bag power morcellation through posterior cul-de-sac. Two surgical tips were important in our project. First, endobag including the specimen was tagged in port sites to prepare sufficient space for morcellation. Second, vaginal power morcellation was taken under camera vision to acquire safety. Vaginal bag was removed through posterior cul-de-sac and following suture was done. There was no significant mortality or morbidity problem after this surgery. The pathologic finding was ovarian fibroma.

Conclusions

Ovarian fibroma would also be indicated in vaginal in-bag morcellation.

<https://player.vimeo.com/video/336476225?autoplay=1>

ES28-0485 - VP053

Video Poster

Laparoscopic myomectomy in multiple large fibroids

*Niraj Yanamandra*¹

¹*Rainbow Hospitals Hyderabad, Obstetrics & Gynaecology, Hyderabad, India*

Background

Myomectomy is the preferred surgical treatment in reproductive-age women who desire to retain their fertility. The use of a laparoscopic approach for large myomas is still controversial, although there are several compelling reasons for its use. Laparoscopic removal of giant uterine myomas is rare and only a few cases have been published in the literature.

Methods

A 24 year old nulligravid woman presented with multiple uterine fibroids. MRI scan showed fundal and posterior wall fibroid measuring 16 x 10 cms and 11 x 8 cms respectively. There was another smaller one measuring 3x5 cms along the posterior wall which seemed to be pedunculated fibroid.

Laparoscopic myomectomy (LM) was performed using 4 ports. Myoma bed was sutured with self-retaining barbed and polyglactin sutures. The large specimen was retrieved by morcellation. It weighed 2.1 kgs.

A drain was kept in the pelvis for 24 hours. The patient was discharged home on second postoperative day.

Results

The multiple large fibroids were successfully removed laparoscopically. There were no intra-operative or post-operative complications. The patient did not need blood transfusion. She made a satisfactory recovery and was discharged home on second post-operative day. Further follow-up was uneventful.

Conclusions

This case confirms efficiency, reliability and safety of a minimally invasive surgical approach to removing multiple large myomas thus making it a reliable alternative to traditional abdominal myomectomy. In women with large fibroids such as the one in our study, a midline scar along with its morbidity could be avoided by this approach.

Laparoscopic removal of such large myomas has several challenges and should be performed after adequate patient counselling and in a set-up with appropriate surgical equipment and the necessary expertise in performing advanced laparoscopic procedures.

<https://player.vimeo.com/video/338651104?autoplay=1>

ES28-0511 - VP054

Video Poster

Laparoscopic treatment of subdiaphragmatic endometriosis implants

*Mara Mantovan*¹, *Burghard Abendstein*¹

¹*Landeskrankenhaus, Obstetricians and Gynecologists, Feldkirch, Austria*

Background

Endometriotic implants can be found on the subdiaphragmatic peritoneum causing respiratory chest/shoulder pain and shortness of breath. The gold standard of treatment is radical resection of all implants. This video demonstrates how to resect subdiaphragmatic endometriosis by laparoscopy.

Methods

Four trocars are placed: one subumbilical, one in the epigastric region and other two in the right and left hypogastric regions. We use bipolar scissors and plasmajet® for resection. Monopolar instruments are not recommended in order to avoid fasciculation of the diaphragm and the ensuing risk of perforation. For insufflation an autoregulative system (airseal®) is used which helps to maintain enough intraabdominal pressure even after opening the pleural cavity. The diaphragm is sutured with interrupted sutures.

Results

All endometriotic lesions are resected including a deep infiltrating nodule which is excised together with the underlying pleura. The postoperative course is uneventful, the patient goes home two days after surgery. A small pneumothorax resolves without drainage.

Conclusions

Laparoscopic resection of subdiaphragmatic endometriosis implants is feasible. A specific placement of the trocars is necessary and we advise to use an autoregulative insufflation system. In case of opening the diaphragmatic pleura careful suturing is mandatory. Drainage can be omitted.

<https://player.vimeo.com/video/338847928?autoplay=1>

ES28-0655 - VP056

Video Poster

Outpatients hysteroscopic removal of Chinese IUD. Description of a very minimal-invasive technique

Gaetano Perrini¹, Daniela Esposito¹, Pietro Simone Filitto¹, Nicoletta Biglia¹

¹"Ordine Mauriziano di Torino" Hospital, University of Turin- Department of Obstetrics and Gynaecology, Torino, Italy

Background

Hysteroscopic removal of an intrauterine device (IUD) is safe and effective, the choice for lost-IUD when manual removal with forceps is impossible due to strings rupture and/or embedded device. The most commonly used IUD in China is a flexible stainless steel ring (SSR), 1 inch in diameter (2.54 cm). Like most Chinese IUDs, SSR does not have an attached string, so the removal is more difficult than common used IUDs (supporting China's "one child" policy): cervical dilation and/or at least a mini-resectoscope are required because the SSR caliber is higher than the bite-opening of 5 french forceps or tenaculum. Our aim is to describe a very simple specifically developed technique applied to remove the Chinese SSR-IUD, keeping the procedure within the very minimally invasive approach of a completely-outpatients setting.

Methods

Women referred to our Outpatients Hysteroscopy Centre for IUD removal (8 in 2018), after comprehensive counselling and written informed consent, undergo "see & treat" office hysteroscopy, performed using a 4.7 mm continuous-flow operative office hysteroscope; vaginoscopic approach, saline as distension medium (inflow pressure 75-90 mmHg). Neither anesthesia nor analgesia are used. Description of technique is presented; procedure success and tolerance have been assessed.

Results

After checking uterine cavity and endometrium, once found the SSR, we introduce a 5 Fr grasping forcep holding a vicryl 0 suture (0.35 mm, without needle) through the operative channel of the hysteroscope. The other end of the suture is outside the patients, hold by the operator's assistant. Then, the suture is passed around the ring and caught again with the forcep. In this way, with a gentle traction, the SSR can be extracted. Mean age of treated patients is 42 ± 6 years; no previous ultrasounds, no relevant symptoms, mild anxiety. Mean pain values (Numerical Rating Scale 0-10) are 5.1 ± 1.9 (expected), 2.6 ± 2.1 (average), 4.1 ± 1.9 (maximum) and 0.7 ± 0.7 (discharge). Mean operative time is 8 ± 2 min; mean observation time before discharge is 35 ± 10 min.

Conclusions

Office hysteroscopy is a safe, successful and well-tolerated way to remove lost-IUD. In cases of obstacles due to IUD characteristics, especially their sizes, the mini-resectoscope appears to be the choice and, as a consequence, office hysteroscopes are claimed to be ineffective. Despite this general consideration, the described technique instead shows that the management of such tricky situations might anyway remain in a truly-outpatients setting. So we would like to point out the importance and advantage to (at least try to) treat women with the most minimally invasive approach.

<https://player.vimeo.com/video/339211524?autoplay=1>

Dermoid cyst causing peritoneo-cutaneous fistula

Sayed Elakhras¹, Mohamed Salama², Daa Ali³

¹*Omam Hospital, Minimally Invasive Surgery, Cairo, Egypt*

²*Faculty of Medicine- Ain Shams University, Obstetrics and Gynaecology, Cairo, Egypt*

³*Galaa Teaching Hospital, Obstetrics and Gynaecology, Cairo, Egypt*

Background

Dermoid cyst of the ovary is a bizarre tumor, usually benign, in the ovary that typically contains a diversity of tissues including hair, teeth, bone, thyroid, etc. A dermoid cyst develops from a totipotential germ cell (a primary oocyte) that is retained within the egg sac (ovary). Being totipotential, that cell can give rise to all orders of cells necessary to form mature tissues and often recognizable structures such as hair, bone and sebaceous (oily) material, neural tissue and teeth.

Dermoid cysts may occur at any age but the prime age of detection is in the childbearing years. The average age is 30. Up to 15% of women with ovarian teratomas have them in both ovaries. Dermoid cysts can range in size from a centimeter (less than a half inch) up to 45 cm (about 17 inches) in diameter. These cysts can cause the ovary to twist (torsion) and imperil its blood supply. The larger the dermoid cyst, the greater the risk of rupture with spillage of the greasy contents which can create problems with adhesions, pain etc. Although the large majority (about 98%) of these tumors are benign, the remaining fraction (about 2%) becomes cancerous (malignant).

A fistula is an abnormal connection between two hollow spaces (technically, two epithelialized surfaces), such as blood vessels, intestines, or other hollow organs. Fistulas are usually caused by injury or surgery, but they can also result from an infection or inflammation. Fistulas are generally a disease condition, but they may be surgically created for therapeutic reasons.

Methods

We present a rare case of a 22-year-old female patient, who presented to our clinic complaining of hypomenorrhea, severe dysmenorrhea and occasional inter-menstrual bleeding. She has a surgical history of cesarean section followed by laparotomy in 2016 for evaluation of a ruptured ovarian cyst.

Results

We decided to perform a diagnostic/therapeutic laparoscopy and hysteroscopy. During which, laparoscopic adhesiolysis of omental and intestinal adhesions, dissection of adhesions between both tubes and the anterior abdominal wall and cystectomy of 2 right dermoid cysts was done.

Operative findings:

- Enlarged ovaries
- Left haemorrhagic cyst
- 2 Right dermoid cysts
- Bilateral hydrosalpinx (resulting in Right salpingectomy)
- Fistula between the skin and right ovary

Conclusions

Dermoid cyst is not an uncommon finding in gynaecological practice. Although, it is known for its bizarre origin and structure, it can still present in an extraordinary way, as we report here, in this case.

Abnormal discharge from the abdominal wall necessitate meticulous examination and investigations to reveal the underlying pathologies.

Bizarre and unusual causes should be kept in mind, especially when the presentation and findings are not in context.

<https://player.vimeo.com/video/339137980?autoplay=1>

ES28-0607 - VP058

Video Poster

Diffuse pelvic adhesions due to previous infantile surgery in an infertile endometriosis patient

Sebile Guler Cekic¹, Burcu Yilmaz Hanege¹, Dogan Vatansever¹, Bulent Urman²

¹Koc University Hospital, Obstetrics and Gynecology, Istanbul, Turkey

²Koc Medical School, Obstetrics and Gynecology, Istanbul, Turkey

Background

Endometriosis is a disease that occurs in 6 to 10% of the general female population. About 25 to 50% of infertile women have endometriosis, and 30 to 50% of women with endometriosis are infertile. This video presents a 31 y/o infertile patient with a history of two unsuccessful IVF trials. Surgical history of midline infantile appendectomy and ovarian laparotomic cystectomy. Sonographic examination revealed a 80x70mm endometrioma on the left ovary and 24 mm anechoic cyst in the right ovary and hydrosalpinx on the right.

Methods

Laparoscopic endometrioma excision and salpingectomy was performed after extensive adhesiolysis. Port setup: palmar port for entrance to dissect broad adhesions, umbilical port for optic device after liberation of adhesions and additional three 5mm trocars over left and right lower quadrant. Energy source: Olympus PK, and Ethicon Harmonic Ace.

Results

Due to previous surgeries, virtually all of the intestinal tract and stomach and omentum were attached to the anterior abdominal wall by dense and loose adhesions. Before starting the real surgical intervention a thorough adhesiolysis was performed to provide adequate visualization of the normal anatomic planes. After exploration of the pelvic anatomy, laparoscopic left endometrioma aspiration, capsula excision and coagulation and bilateral salpingectomy were performed.

Conclusions

Laparoscopic observations revealing pelvic anatomy distortion can explain infertility in patients with deep infiltrating endometriosis. Major pelvic or peritubal adhesions that affect tubal patency and tuboovarian relationship could impair ovulation, inhibit ovum pickup, or impede ovum transport. There are certain reports that state uterine implantation is also affected in endometriosis patients by changes in endometrial receptivity. Therefore endometriosis surgery in infertile patients could help restore pelvic anatomy and enhance endometrial receptivity and oocyte pick up.

<https://player.vimeo.com/video/339171071?autoplay=1>

ES28-0615 - VP059

Video Poster

Laparoscopic removing of cervical cerclage with mesh erosion and repeated cerclage placement

Anton Fedorov¹, Alexander Popov², Elena Efremova², Svetlana Tuyrina², Victoria Vrockaya², Alexey Kova²

¹Moscow Regional Research Institute O/G, Endoscopy, Moscow, Russia

²Moscow Regional Research Institute O/G, Endoscopy, Moscow, Russia

Background

Preconceptional cervical cerclage is a very effective procedure for patients with repeated miscarriages and after cervix removing. Live birth rate after this surgery is 96-98%. Complication rate is 1.5%

Methods

For present time 137 laparoscopic cerclage surgery was done in our clinic. In this study we include patients with multiple pregnancies loss and failed vaginal cerclage, after cervix amputation and radical trachelectomy. Among 62 pregnancies only one preterm delivery at 27 weeks was detected. In this case after RAT IVF attempt twin pregnancy with reduction of embryo was ineffective.

Results

32 y. patient with previous cervix amputation was operated preconceptionally in our department. 4 month post op. She became pregnant spontaneously. Elective Cesarean delivery was done at 38 weeks. 1 year later during examination mesh erosion to the external os was detected.

Laparoscopy and cerclage removing was performed. We apply new mersilene graft 5 upper cesarean scar and previous cerclage at the same procedure.

Conclusions

No more mesh erosion was detected post op. During next cesarean section graft should be remove

<https://player.vimeo.com/video/340394707?autoplay=1>

ES28-0622 - VP060

Video Poster

Laparoscopic treatment of ovarian remnant syndrome

Engin Oral¹, Taner Usta², Salih Yilmaz², Aysel Ozkaynak²

¹Private Clinic, Gynecology and Obstetrics, Istanbul, Turkey

²Mehmet Ali Aydinlar University- Acibadem Altunizade Hospital, Gynecology and Obstetrics, Istanbul, Turkey

Background

Ovarian Remnant Syndrome (ORS) is a rare condition which defined as the presence of ovarian tissue in a patient who has had previous oophorectomy. Main symptoms are pelvic pain and pelvic mass or absence of the menopausal symptoms after oophorectomy. This rare condition is challenging the clinicians in its diagnosis and treatment. ORS is a histological diagnosis, made based upon pathologic confirmation of remnant ovarian tissue obtained at the time of surgical exploration. The definitive treatment of ORS is surgical excision of the remnant tissue. Pharmacologic treatment for patients who refuse surgery or are not candidates for surgical treatment consists of hormonal therapy to suppress ovarian function.

Methods

49 years old woman referred to our center with severe pain on the her left inguinal region. In her history, two times cystectomy one with laparoscopy and one with laparotomy, myomectomy with left salpingo-oophorectomy and finally a year ago hysterectomy with right salpingo-oophorectomy were performed. Pain on her left inguinal region was 9/10 according to Visual Analogue Scale (VAS). A serum Follicle Stimulating Hormone (FSH) level was in the premenopausal range. After insertion of the trocars the uterus and ovaries was not seen. Fibrous thickened tissue which was fixed to the left ureter was seen on the left iliac vessels. After dissection of the ureter the fibrous tissue was excised. Histopathological examination confirmed the ORS.

Results

The patient was discharged on the first day after surgery. The patient has been following for six months and no more pain on her left inguinal region. FSH level was in the postmenopausal range after the operation.

Conclusions

ORS is a rare condition which is challenging clinicians in its diagnosis. The definitive diagnosis is histological confirmation of remnant ovarian tissue obtained at the time of surgical exploration. The risk factors of the ORS were pelvic adhesions, anatomic variations, intra operative bleeding, poor surgical technique or endometriosis. The definitive treatment is surgical excision of the remnant tissue. Medical therapy can be a choice for patients who refuse surgery or are not candidates for surgical treatment.

<https://player.vimeo.com/video/339191374?autoplay=1>

ES28-0629 - VP061

Video Poster

Laparoscopic treatment of ureteral endometriosis involving hypogastric and uterine arteries

Nuria Barbany Freixa¹, Pere N Barri-Soldevila¹

¹Hospital Universitario Quiron-Dexeus, Ginecología y Obstetricia, Barcelona, Spain

Background

Endometriosis is a frequent disease affecting approximately 10% of patients at a fertile age. It is defined as the presence of endometrial glands and stroma outside the uterus. Ureteral endometriosis is much less common than ovarian or peritoneal endometriosis and is often asymptomatic. Imaging techniques may include a renal visualization in order to determine the presence of associated hydronephrosis. The treatment of ureteral endometriosis will be mainly surgical in order to prevent renal function loss. Depending on the severity and location of the endometriotic nodule we will consider whether performing a ureterolysis, a ureterectomy with ureteroureteral anastomosis, a ureteroneocystostomy or even a nephroureterectomy in cases with a complete renal function loss.

Methods

The video illustrates the case of a 43 year-old women with a previous history of two spontaneous vaginal deliveries, who consulted in our clinic for her gynaecological check-up. She presented to us with a recurrent left flank pain associated to dysmenorrhea and heavy menstrual bleeding. These symptoms were deteriorating for the last year. The physical examination revealed normality.

A transvaginal ultrasonography was performed showing a hypoechoic area next to the left adnexa which was compromising the ureter. The study was completed with the visualization of the left kidney revealing a left hydronephrosis. The MRI confirmed the previous imaging results and described an associated adenomyosis. , and, finally, the renogram showed a residual renal function of 10% in the left kidney. According to the urologists, and due to the decreased functionality of the kidney and recurrent pain, she was offered a laparoscopic surgery including nephroureterectomy.

Results

The patient was discharged on the 4th postoperative day. A transvaginal ultrasound performed two months after surgery revealed normality.

Conclusions

The management of deep infiltrating endometriosis requires a multidisciplinary unit including radiologists, gynaecological high skilled surgeons, urologists and colorectal surgeons in order to improve patient's quality of life.

<https://player.vimeo.com/video/339195973?autoplay=1>

ES28-0641 - VP062

Video Poster

Hysteroscopic polypectomy in an office setting, using a new hysteroscopic hand driven morcellation: Resectr® 5fr

Steffi van Wessel¹, Tjalina Hamerlynck², Steven Weyers², Celine Blank², Huib van Vliet³, Dick Schoot³

¹Ghent Universital Hospital, Gynaecology, Ghent, Belgium

²Ghent University Hospital, Women's Clinic, Ghent, Belgium

³Catharina Hospital, Gynaecology, Eindhoven, The Netherlands

Background

Nowadays, the hysteroscopic morcellator is a widely used technique for removal of intrauterine polyps. Various mechanical, motor-driven tissue removal systems are used in clinical setting. However, the development of devices continues and a new, mechanical hand driven device (Resectr®9fr. and 5fr.), which is recently launched, is effective in in-vitro and in-vivo setting, tested, and safe.

The video shows the hysteroscopic resection of a polyp, using a 5fr hand driven morcellator (Resectr® 5fr), in an office setting.

Methods

The hysteroscopic polypectomy is performed in an office setting using a 4.4mm 30° TROPHISCOPE® (Karl Storz) with a 5fr. working channel. The polyp is removed by a new type of hysteroscopic hand driven morcellator, Resectr® 5fr. (Boston Scientific). The blade has a window-opening at the end with cutting edges, which rotate six times during one hand squeeze. Through the window-opening tissue is aspirated by means of a vacuum source (Endomat® select, Karl Storz). The removed tissue is discharged through the device, collected in a pouch and made available for pathology analysis. Cervical preparation is not necessary.

Results

We present the case of an 81-year old woman with multiple endometrial polyps (< 1cm) suffering from abnormal uterine bleeding.

The polyps are removed using the hand driven hysteroscopic morcellator, Resectr 5fr, in an office setting. There were no complications and pathology analysis confirmed the diagnosis.

Conclusions

The Resectr® 5 fr is a new hysteroscopic hand driven morcellator used for the removal of smaller polyps in an office setting.

<https://player.vimeo.com/video/339206014?autoplay=1>

ES28-0656 - VP063

Video Poster

Laparoscopic myomectomy of a broad ligament fibroid with transvaginal tissue extraction

Caryl Thomas¹, Angharad Jones¹, Penketh Richard²

¹University Hospital of Wales- Cardiff, Obstetrics & Gynaecology, Cardiff, United Kingdom

²University Hospital of Wales, Obstetrics & Gynaecology, Cardiff, United Kingdom

Background

The objective of this video is to demonstrate the excision of a broad ligament fibroid and retrieval of tissue via a natural orifice of the posterior colpotomy. The aims are to display a safe technique of dissection, demonstrate the anatomy and also excision and retrieval of fibroid via the transvaginal route.

Methods

A 35 year old nulliparous female presents with a longstanding history of primary infertility. She had a laparoscopic excision of rectovaginal endometriosis in 2017 with resolution of symptoms. An ultrasound scan was performed which showed a 12x6cm fibroid which was thought to be a pedunculated or broad ligament fibroid. She was not eligible for funded IVF. The patient opted and consented for a laparoscopic myomectomy. An intraoperative live video was performed to record the findings and procedure which has been edited for this video.

Results

A laparoscopy confirmed a right sided broad ligament fibroid. The ureter was identified and tracked from the pelvic brim. Vasopressin was injected to reduce the operative blood loss. The fibroid was dissected from the broad ligament with monopolar diathermy. Following excision of fibroid, a posterior colpotomy was performed to retrieve the specimen. The colpotomy was subsequently closed vaginally. The patient made a good post operative recovery.

Conclusions

Ureteric visualisation is essential prior to excising broad ligament fibroids in order to minimise the risk of injury. Transvaginal tissue extraction is a safe alternative to a mini laparotomy which has the added benefit of improved cosmesis.

<https://player.vimeo.com/video/348789696?autoplay=1>

Hysteroscopic treatment of a complex case of Mullerian anomaly: complete septate uterus with cervical and complete longitudinal vaginal septum (U2bC1V1b ESHRE/ESGE Classification) and subserosal myoma

Antonella D'Apolito¹, Luigi Della Corte¹, Maria Chiara De Angelis¹, Alfonso Manzi¹, Antonia Testa¹, Giuseppe Bifulco²

¹University of Naples Federico II,

Department of Neuroscience- Reproductive Sciences and Dentistry- School of Medicine- University of Naples Federico II- Naples- Italy, Naples, Italy

²University of Naples Federico II,

Department of Public Health- School of Medicine- University of Naples Federico II- Naples- Italy, Naples, Italy

Background

To describe a successful hysteroscopic treatment of a complete septate uterus with cervical and complete longitudinal vaginal septum (U2bC1V1b ESHRE/ESGE Classification).

Methods

A 27-year-old patient referred to our Department of Obstetrics and Gynecology for leucorrhea, recurrent vaginal infections and dyspareunia. At bimanual pelvic examination a longitudinal vaginal septum up to the introitus was detected. 2D Pelvic ultrasound showed an intramural-subserosal myoma of the posterior wall (size:41x36 mm); the axial scan evinced a doubling of the endometrial profile.

3D Pelvic ultrasound showed a complete septate uterus with involvement of the uterine cervix

During an office hysteroscopy the suspicion was confirmed.

The patient was scheduled for an in-patient hysteroscopy and laparoscopic myomectomy.

Results

The longitudinal vaginal septum was removed by electro-surgical scalpel. Afterward the vaginal septum was refined with 5 Fr blunt scissors.

The cervical septum was removed with 5 Fr bipolar electrode. Operative hysteroscopy with 26 Fr resectoscope was performed until the visualization of both uterine tubal ostia. At the end of procedure an antiadhesive gel based autocross link hyaluronic acid was applied. Afterward the laparoscopic myomectomy was performed.

A single normal endometrial cavity with single cervix and vagina were obtained.

Dyspareunia has completely disappeared.

Conclusions

The hysteroscopic approach offers a unique opportunity to restore the physiological uterine function in order to improve the fertility outcomes. The hysteroscopic metroplasty under laparoscopic control remains the first choice only in cases where it is necessary to treat associated pelvic pathologies.

<https://player.vimeo.com/video/339219824?autoplay=1>

ES28-0675 - VP065

Video Poster

Total laparoscopic hysterectomy in gender dysphoria

Ebeid Elhami¹

¹National Health Service - UK, Women's Health - East Sussex, Truro, United Kingdom

Background

The term transgender describes a condition where an individual's gender identity differs from external sexual anatomy at the time of birth. Transgender hormone therapy and surgery are usually undertaken with the aim of making the external anatomical appearance more compatible with the gender identity. The patient should be aware of the risks and benefits of hormonal and surgical treatment. Any unrealistic expectations should be fully addressed before embarking onto those interventions. Here is a video presentation of case of gender dysphoria where a total laparoscopic hysterectomy is performed. The exposed pelvic organs to androgen hormone was well noticed during the surgical procedure using an ultrasonic dissecting shears

Conclusions

The term transgender describes a condition where an individual's gender identity differs from external sexual anatomy at the time of birth. Transgender hormone therapy and surgery are usually undertaken with the aim of making the external anatomical appearance more compatible with the gender identity. The patient should be aware of the risks and benefits of hormonal and surgical treatment. Any unrealistic expectations should be fully addressed before embarking onto those interventions. Here is a video presentation of case of Gender dysphoria where a total laparoscopic hysterectomy is performed. The exposed pelvic organs to androgen hormone was well noticed during the surgical procedure using an ultrasonic dissecting shears

<https://player.vimeo.com/video/339229443?autoplay=1>

ES28-0679 - VP066

Video Poster

Laparoscopic resection of left ovarian remnant

Charles Miller¹, Kirsten Sasaki¹

¹The Advanced Gynecologic Surgery Institute/ The Ad, Gynecology/Infertility, Naperville, USA

Background

Ovarian remnant syndrome is a rare condition. It often affects women with prior pelvic surgeries, especially those with a history of endometriosis. Our patient is a 38 yo G2P1 with a history of endometriosis and multiple pelvic surgeries, including a left oophorectomy for an infected ovary.

Methods

Laparoscopic excision of left ovarian remnant with severe lysis of adhesions after ultrasound diagnosis.

Results

Successful excision of left ovarian remnant. At her three week post-operative appointment, the patient's pelvic pain had resolved.

Conclusions

Ovarian remnant surgery is a rare condition that can often be diagnosed with a trans-vaginal ultrasound and can be treated laparoscopically by a skilled surgeon.

<https://player.vimeo.com/video/339603264?autoplay=1>

ES28-0689 - VP067

Video Poster

Exposure and surgical treatment of an ectopic pregnancy on the uterine scar

Stavros Karampelas¹, Frederic Chantraine¹, Michelle Nisolle¹

¹*University of Liège, Obstetrics and Gynecology, Liège, Belgium*

Background

Case report of a 39 year old patient with an ectopic pregnancy 7 weeks of gestational age on the uterine scar

Methods

The operation was performed using Laser laparoscopy. Prior to the exposition of the uterine scar the anatomy of the uterus appeared normal.

Detachment of the vesico-uterine fold and a careful partial detachment of the uterine scar using Bipolar and scissors was performed. A lateral opening of the uterine scar exposed the gestational sac and its content was emptied.

The entire uterine sac was resected using Laser laparoscopy.

A three step suture of the proximal with the distal part of the myometrium was performed using a monoclonal absorbable suture.

The overall bleeding of the operation was 100ml

Results

The patient was discharged from the hospital 20hours after surgery free of symptoms.

The residual myometrium at the site of the uterine scar after surgery was 7mm.

Conclusions

A one step laparoscopic procedure for the treatment of an ectopic pregnancy and the correction of the uterine scar is possible for a pregnancy of the first trimester with excellent post operative results.

<https://player.vimeo.com/video/341524497?autoplay=1>

ES28-0688 - VP068

Video Poster

Exposition of the lateral suspension mesh into the vagina-case report

Raxshanda Aliyeva¹, Islam Mahalov¹

¹*Azerbaijan Medical University, Gynecology, Baku, Azerbaijan*

Background

We report the case of 32 years old patient who had laparoscopic lateral suspension mesh placement in August 2018. Preop diagnosis was Histerocele grade. Also, important to note, that at the same surgery uterine tube was removed because of pyosalpinx.

4 months after surgery patient became to the department with the severe dyspareunia complaints.

At the vaginoscopy, we noticed mesh (2 sm) on the upper third of the anterior vaginal wall.

Methods

We performed total laparoscopic removal of the mesh. After careful bladder dissection, we made an incision at anterior vagina and removed fibrotic part together with the mesh. Vagina was sutured with interrupted absorbable sutures. Peritonization was performed.

After lateralization of the both ureters, we sutured and shortened sacrouterine ligament with non-absorbable suture.

Results

Patient had accident-free post recovery. At the 1 month follow-up, sutures from vagina were removed.

Conclusions

Some surgeons offer a lateral suspension prolapse surgery as a safe alternative to sacropexy with shorter learning curve. Indeed absence of necessity of the promontories dissection may seem attractive. But it should be borne in mind that all the complications associated with the meshes still work in this kind of surgery too.

It is also important to keep in mind, that suturing of the vagina should not be done with a non-absorbable thread. Besides, in cases of sacropexy it is not acceptable to suture vagina without suturing the cervix. At the end, all meshes, that are used in gynecology should be fixed as much as possible tension free.

<https://player.vimeo.com/video/339759920?autoplay=1>

ES28-0135 - VP069

Video Poster

En-bloc laparoscopic excision of the butterfly area for deep-infiltrating endometriosis

*Matthew Erritty*¹

¹*St Peter's Hospital, Centre for Endometriosis and Minimally Invasive Gynaecology, Chertsey, United Kingdom*

Background

This is a video demonstration of a technique for laparoscopic excision of deep infiltrating endometriosis.

In women with areas of widespread endometriosis it is possible to remove all areas of the disease in a single histological specimen which has the benefits of including microscopic skip lesions and allows for a smooth, fluid and continuous surgical process. The excised area includes both pelvic side walls, both uterosacral ligaments and a shave of the rectovaginal peritoneum. The final excised area resembles a butterfly shape hence its name.

Methods

The technique is reproducible and reliable and by maximising laparoscopic access and dissecting pelvic viscera, it reduces the risk of intraoperative visceral injury. After an initial pelvic survey, the ovaries are temporarily suspended to the anterior abdominal wall using 2-0 prolene sutures on a straight needle. A bilateral ureterolysis is performed which is extended as needed to include areas of disease on the pelvic side wall. With the aid of a rectal probe, the pararectal spaces on each side are opened to identify the serosal layer of the bowel. This incision is then extended caudally to the rectovaginal space and the rectum is dropped down and away from the margin of excision. The incisions of the side wall and pararectal spaces are then joined so that the uterosacral ligaments on both sides are included in the specimen. At the end of the procedure, a rectal integrity test is performed by occluding the rectum and then insufflating the rectum via the anus to examine for leaks. The ovarian suspension may be left in situ for 3 to 5 days to minimise the risk of trapped ovarian syndrome before then being removed in outpatients.

Results

The women undergoing this procedure are suitable for same day discharge and are then followed up by our specialist endometriosis nurse at 3 and 6 month intervals. Visual analogue pain scores are completed at each contact and an appointment with the gynaecologist arranged as needed.

Conclusions

This video demonstrates a reproducible and systematic approach for the excision of deep-infiltrating endometriosis that may be performed without the need for advanced surgical instruments.

<https://player.vimeo.com/video/335609957?autoplay=1>

ES28-0277 - VP070

Video Poster

Laparoscopic sacrocolpopexy for pelvic organ prolapse: surgical outcomes and follow up data

Dimitrios Zygouris¹, Nektarios Chalvatzas¹, Antonis Gkoutzioulis¹, Georgios Anastasiou², Andreas Kavallaris^{1,2}

¹*St Luke's Hospital, Department of Gynecologic Oncology and Minimally Invasive Gynecology, Thessaloniki, Greece*

²*Mother and Child Medical Centre, Department of Gynecologic Oncology and Minimally Invasive Gynecology, Nikosia, Cyprus*

Background

Aim of the study is to evaluate the safety, intra-operative and post-operative morbidity and long term outcomes of 90 patients treated laparoscopically to repair advanced (III-IV) genital prolapsed.

Methods

Between January 2011 and January 2019 90 women underwent laparoscopic sacrocolpopexy at St. Luke's Hospital in Thessaloniki, Greece and at Mother and Child Medical Centre in Nikosia, Cyprus. The patients with descensus uteri underwent total laparoscopic hysterectomy with BSO and then laparoscopic sacrocolpopexy using two different kinds of meshes. PRR for either cystocele or rectocele and PRS for both. All cases were completed laparoscopically. We analyzed patients' characteristics, surgical outcomes and success rate in follow up.

Results

Mean age was 59.5 years and body mass index 26.8 kg/m². The mean operative time of the laparoscopic sacrocolpopexy using PRR for cystocele (22 min), for rectocele (21 min) and using PRS for both (35 min). All the patients were reviewed at 1 moth, 3 months, 9 months and then every 6 months after the surgery for a period of 5 years. The follow-up was between 6 months and 6 years.

There were no major intraoperative or postoperative complications and we had no mesh exposure or erosion. The mean hospitalization stay was 2.1 days.

Conclusions

The laparoscopic sacrocolpopexy using dyna-mesh is an effective and safe technique to repair the pelvic organ prolapses. The long-term anatomical functional results are very satisfactory with no major complications and this should be a primary therapy option.

<https://player.vimeo.com/video/338896802?autoplay=1>

ES28-0310 - VP071

Video Poster

Robotic pectopexy for treating pelvic organ prolapse

Ralf Joukhadar¹, Achim Woeckel¹, Dimitrios Balafoutas¹

¹*Wuerzburg University Hospital, Obs & Gyn, Wuerzburg, Germany*

Background

Laparoscopic sacropexy is currently regarded as the gold standard procedure for the treatment of pelvic organ prolapse (POP). Yet it may be very challenging to perform in some clinical situations such as: in very obese patients, in case of extensive adhesions in the mid abdomen or in the presacral region, after prior surgeries or in cases of prior lumbar surgery along with lumbar pain. The pectopexy represents a good alternative for surgical treatment of POP in such cases.

Methods

We present an instructional video for the crucial steps to perform a robotic pectopexy easily and safely. In this video we describe the main steps of the procedure along with tips and tricks to improve the surgical technique and to ensure patient's safety.

Results

The results are presented by an example of a case report of a patient with a prolapse POP-Q-Stage-III. The anatomical outcome shows good correction of the prolapse (POP-Q-Stage-0), short duration of the procedure (132 minutes), estimated blood loss of 25 ml and a short hospital stay of 2 days.

Conclusions

When applying the right technique, robotic pectopexy is a reproducible, easy to perform and safe procedure to treat POP with good anatomical and functional results along with low blood loss and a short hospital stay.

<https://player.vimeo.com/video/336355475?autoplay=1>

ES28-0114 - VP073

Video Poster

Technique of ovarian orthotopical transplantation into a peritoneal pouch near the ovary beneath the fallopian tube

Esengül Türkyilmaz¹, Murat Sönmezer², Çağrı Gülümser³, Sinan Özkavukçu⁴

¹Ankara Bilkent City Hospital, Gynecology and Obstetrics, Ankara, Turkey

²Ankara University Faculty of Medicine, Gynecology and Obstetrics, Ankara, Turkey

³Zekai Tahir Burak Women Health Education and Research Hospital, Gynecology and Obstetrics, Ankara, Turkey

⁴Ankara University Faculty of Medicine, Histology and Embriology, Ankara, Turkey

Background

Thanks to the usage of effective chemotherapeutic agents, number of surviving patients with malignancy is increasing. However detrimental effects of these agents on the ovary may be a problem in terms of decreased fertility and premature menopause in later lives of those patients. To overcome this unwanted effect, ovarian tissue might be removed before cancer therapy and transplanted after therapy. Transplantation might be fulfilled heterotopically (outside the ovary) or orthotopically (inside/onto or near the ovary). In general we prefer orthotopical transplantation that is performed near ovary instead of inside/onto ovary. It is aimed to describe systematically our "orthotopical ovarian transplantation in a peritoneal pouch near the ovary beneath the fallopian tube" surgery technique in this paper and video presentation.

Methods

The surgical technique for the transplantation of ovarian tissue. Generally one-third up to two-thirds of the ovary is excised during the ovarian removal process. Then ovarian tissue is cryopreserved, in accordance with the vitrification technique, for the transplantation process that will be performed in the future. Transplantation procedure is planned at least 3 years after the end of oncologic therapy. The standard access route for the ovarian tissue transplantation procedure is laparoscopy. Initially all abdomen is inspected regarding any metastatic disease and biopsy is performed if necessary. Generally ovarian tissue is transplanted on the side with the patent tube. In our protocol, the standard method is orthotopically transplanting the ovarian tissue into a peritoneal pouch near the ovary beneath the fallopian tube. The peritoneum is incised without coagulation. After adequate peritoneal pouch is constituted, pieces of the ovarian tissue are located side by side with cortex side outward in the peritoneal pouch. We may transplant nearly 6-10 ovarian pieces at a time. After putting of them, the peritoneum above the ovarian pieces is sutured.

Results

Ovarian transplantation in a peritoneal pouch might be performed easily and safely by laparoscopy.

Conclusions

Spontaneous or in vitro fertilization pregnancies after transplantations are reported in the literature. Also distinct decrease on the follicle stimulating hormone (FSH) and increases on the antimullerian hormone (AMH) and the estradiol (E2) are indicated in many cases. In terms of the success that is defined as pregnancy rate and ovarian function recovery, there is no data between transplantation inside/onto ovary and transplantation into a peritoneal pouch near ovary in the literature. However we believe that transplantation into a peritoneal pouch near the ovary beneath the fallopian tube might be more successful according to transplantation inside/onto ovary because of better vascularization.

<https://player.vimeo.com/video/335203711?autoplay=1>

Hysteroscopic morcellation of retained products of conception

Mohamad Abdelwehab¹, Dorothea Saragli¹, Kostis Nikolopoulos¹, Pandelis Athanasias¹

¹*St Helier Hospital, Womens Health, London, United Kingdom*

Background

The aim of this case review was to assess the use of hysteroscopic morcellation in the outpatient setting, with regards to efficacy, patient safety and patient tolerability in the management of a case of retained products of conception where conventional treatment options had failed.

Methods

Targeted resection of calcified trophoblastic tissue using the Myosure reach morcellation technique was performed on a lady with retained products of conception 12 weeks post medical management of miscarriage using misoprostol after failed conservative and 1st line surgical treatment (dilatation and curettage)

- The procedure was performed in the outpatient setting, under ultrasound guidance and took approximately 15 minutes with a morcellation time of 6 minutes
- Oral analgesia 1 hour before the procedure was given
- Instillagel was applied intracervically
- 4.4ml of lignospan 2% was applied paracervically
- The cervix was dilated to Hegar 7
- Normal saline was used for distension and fluid balance was monitored
- Pain scores were measured using visual analogue score

Results

The procedure was very well tolerated by the patient with the following pain scores :

1. Pain during LA injection : 3/10
2. Pain during cervical dilatation : 3/10
3. Pain during morcellation : 1/10
4. Pain after the procedure : 0/10

- The fluid deficit was 840ml
- Histology confirmed calcified retained products of conception
- Ostia were visualized at end of procedure and normal uterine cavity shape restored

Conclusions

Hysteroscopic morcellation of retained tissue in refractory cases appears to be a safe and precise method of management.

The procedure is carried out in the outpatient setting thus avoiding general anaesthesia when compared to transcervical resection with the bipolar or monopolar resectoscope while also avoiding the associated complications of electrocautery and only resecting retained tissue thus preserving endometrial integrity.

The procedure is cost effective as it doesn't involve hospital stay and theatre utilization.

ES28-0440 - VP075
Video Poster

Laparoscopic drainage of tubo-ovarian abscess (TOA)

Mehmet Alp Matur¹, Gökay Özçeltik¹, Ahmet Özgür Yeniel¹, İsmail Mete İtil¹
¹Ege University, Gynecology and Obstetrics, Izmir, Turkey

Background

The objective of this video presentation is to show in selected cases laparoscopic drainage can be another option for tubo-ovarian abscess (toa)

Methods

47 years old patient who has IUD and type 2 diabetes in her past applied with severe inguinal pain. Bilateral sensibility in lower abdomen detected in examination. CT scan and usg matched with an abscess on right adnexal area. As initial treatment antibiotherapy was started and there was no clinical and biochemical result. Laparoscopic drainage was planned. We decided to get in to abdomen at palmer point with 5 mm trocar. Bowels were founded adhesive to abdomen anterior an lateral inside wall in largely area and there were also false membranes on bowels and omentum. Sigmoid colon was founded adhesive to left adnexa , anterior uterus was founded adhesive to bladder. There was also 2 abscesses; 1 from right 4-5 cm and 1 from left 7 cm. With verress needle we reached to abscesses, from 3 cm above symphysis pubis and punctured abscesses . Abdomen was washed after procedure. 2 drains were placed before operation finished .

Results

The procedure and postoperative recovery were uneventful. No minor or major complications occurred. We regression clinically and biochemically regression. Tuba and ovaries saved .

Conclusions

Treatment with antibiotics may be unsuccessful and failure to respond and necessitate surgical intervention or image-guided drainage of the toa. Some potential benefits of laparoscopy are such as quicker recovery, smaller incisions, less postoperative pain

<https://player.vimeo.com/video/336466437?autoplay=1>

ES28-0638 - VP076
Video Poster

Treatment of genital prolapse by a modified mini-laparoscopic lateral suspension

Dogan Vatansever¹, Burak Giray², Tuncer Kumcular³, Ozgur Oktem⁴, Senai Aksoy³, Bulent Urman⁴

¹Koc University School of Medicine, Department of Obstetrics and Gynaecology- Division of Gynaecologic Oncology-, Istanbul, Turkey

²Zeynep Kamil Women and Children's Health Training and Research Hospital,

Department of Obstetrics and Gynaecology- Division of Gynaecologic Oncology, Istanbul, Turkey

³VKF American Hospital, Department of Obstetrics and Gynaecology, Istanbul, Turkey

⁴Koc University School of Medicine, Department of Obstetrics and Gynaecology, Istanbul, Turkey

Background

Pelvic organ prolapse (POP) (also known as genital prolapse) is a common gynecologic problem affecting about half of the parous women and occurs primarily from the loss of pelvic floor support. We performed lateral suspension in patients with uterovaginal prolapse by mini and conventional laparoscopy by a modified technique. The goal of our manuscript is to describe the modified operative technique of laparoscopic lateral suspension with mesh in patients with POP.

Methods

Twenty-three patients with genital prolapse who underwent laparoscopic lateral suspension between 2016 and 2019 were included to the study. Lateral suspension was performed through one optical trans-umbilical 5-mm trocar, one 5-mm ancillary port on the right side, 3-mm mini-laparoscopic port on the right upper quadrant, and one 3-mm ancillary port on the left-lower quadrant. The umbilical incision and right lower 5 mm skin incisions were sutured with a 4/0 Monocryl, whereas 3-mm incisions were closed with a sterile strip. All operations were performed by the same surgeon.

Results

A total of 23 patients were included. The mean age was 57.87 ± 12.47 years, and the body-mass index was 26.54 ± 3.57 kg/m². The mean operating time was 128.7 ± 42.2 minutes. Of the 23 patients, 20 underwent laparoscopic hysterectomy and lateral colposuspension, and the remaining 3 underwent laparoscopic suspension without hysterectomy. None of the patients had peri-operative or post-operative complication. Conversion to laparotomy or transfusion were not required. The median hospital stay was 2 days (range, 1-5 days).

Conclusions

Laparoscopic lateral suspension using mesh effectively treats POP with low morbidity. The operation is feasible by using conventional port sites instead of two additional lateral abdominal incisions to fix the mesh. The long-term outcomes of this modified technique need to be further evaluated.

<https://player.vimeo.com/video/339203258?autoplay=1>

ES28-0546 - VP077

Video Poster

Laparoscopic excision of 10 dermoid cysts bilaterally in a case of ovarian torsion

Emre Volkan Kasimoğullari¹, Hakan Guraslan¹, Tolga Karacan¹, Eser Ozyurek¹, Evrim Ebru Kovalak¹, Berkay Yuksel¹

¹Health Sciences University Istanbul Bağcilar Research and Training Hospital, Obstetrics and Gynaecology Clinic, Istanbul, Turkey

Background

A 22 year old woman.

G1P1

Presented with lower abdominal pain.

+++ tenderness

Abdominal scan RO 8 cm dermoid cysts with no blood flow and LO 6 cm dermoid cysts.

Methods

Laparoscopy was performed. On the inspection of the cavity we noticed peritoneal fluid in the Douglas pouch and the change in colour of the right ovary. First we started to untwist the right ovary. Then coagulation of the cyst capsula was employed. Separating the capsula from cyst was carried out by bipolar energy and scissors. We paid attention to redefining plane of cleavage to reduce the risk of traumatic cystic rupture or spillage. Stripping the cyst from ovary was mostly performed by rolling technique. During the procedure both sharp and blind dissection were used. We removed 7 dermoid cysts from the right ovary. After finishing the cystectomy on the right side monopolar energy was applied to the capsula of the dermoid cysts in the left ovary. They were taken out of the cavity by using an endobag to minimize the risk of cyst spillage. We cleaned the pelvis with warm saline and finally a drain through a trocar was placed into the pelvic cavity.

Results

Recovery time was well and the patient was discharged on 2nd day after the surgery.

Conclusions

Surgery or detorsion should be the first line treatment if you have a suspicious diagnosis of ovarian torsion. Before diagnosis pelvic doppler ultrasonography can help find out the blood flow of that ovary.

<https://player.vimeo.com/video/338973458?autoplay=1>

ES28-0554 - VP078

Video Poster

Robotic excision of full- thickness diaphragmatic endometriosis

Elena Suarez-Salvador¹, Ritchie Delara², Magtibay Pau²

¹*Hospital Vall D'Hebron, Obstetrics and Gynaecology, Barcelona, Spain*

²*Mayo Clinic, Department of Gynecology, Phoenix, USA*

Background

Symptomatic diaphragmatic endometriosis is commonly associated with lesions that deeply invade the diaphragm and are more often located on its posterior aspect. Complete surgical excision offers higher rates of symptom improvement and resolution in patients with diaphragmatic endometriosis compared to ablative procedures.

Methods

This video presents a systematic robotic approach to excision of diaphragmatic endometriosis that highlights anatomical landmarks and technical considerations to complete the procedure safely and effectively.

Results

In the presence of symptomatic diaphragmatic endometriosis, the posterior aspect of the diaphragm should be explored. Resection of hepatic ligaments, use of a 30-degree endoscope and right lateral access can be helpful to visualize this anatomic area. Smaller superficial endometriotic lesions can also be encountered on the anterior diaphragm can represent sentinel lesions. Once the deep endometriosis involving the diaphragm is removed by full-thickness resection using electrosurgery, the pleural cavity and lung should be systematically inspected to rule out presence of additional endometriotic lesions. If the long axis of the diaphragmatic defect runs parallel to the posterior chest wall and can be closed tension-free, then mesh should not be necessary. Insertion of a red rubber catheter into the thorax along with use of negative-pressure suction at the end of the closure of the diaphragmatic defect may avoid the use of a postoperative chest tube.

Conclusions

The use of robotic assistance for resection of diaphragmatic endometriosis could make this procedure easier and safer to perform. In the presence of symptoms suggestive of diaphragmatic endometriosis, the posterior aspect of the diaphragm should be explored.

<https://player.vimeo.com/video/339038355?autoplay=1>

ES28-0624 - VP079

Video Poster

Laparoscopic management of deep infiltrative endometriosis with ureter dissection and low anterior resection anastomosis

Ulkar Heydarova¹, Dogan Vatansever¹, Alper Eraslan¹, Esra Bilir², Bulent Urman², Cagatay Taskiran²

¹*Koc University Hospital, Obstetrics and Gynecology, Istanbul, Turkey*

²*Koc Medical School, Obstetrics and Gynecology, Istanbul, Turkey*

Background

Prevalance of endometriosis among young women suffering from chronic pelvic pain that does not respond to medical treatment is 70%. There is no available robust data about the prevalence of deep infiltrating intestinal and urogenital endometriosis. In this video we present a deep infiltrating endometriosis case which includes the bowel and urinary tract. 25 y/o female suffering from severe pelvic pain and dysmenorrhea. History of two endometrioma excision by laparotomy and one laparoscopic endometrioma excision and sacrouterine nodule excision.

Methods

Laparoscopic deep infiltrating endometriosis surgery, low anterior bowel resection, ureter and nerve dissection and double J stent application on left ureter was performed. Port setup: umbilical port, and additional three 5mm trocars over left and right lower quadrant. Energy source: Olympus PK, and Ethicon Harmonic Ace.

Results

Endometrioma excision and removal of the sacrouterine and rectovaginal endometriotic nodules were performed successfully, after careful dissection of the retroperitoneal sidewall structures, ureters and nerve tracts. General surgery team was invited to the operation to perform low anterior resection concerning endometriotic bowel inclusion. Ureters and hypogastric nerve tracts were precisely dissected and visualized. Urology team applied double J stent to the left ureter. Surgery was concluded by total removal of all endometriotic nodules. No preop and postop complications. Final pathology: endometriosis

Conclusions

Laparoscopic surgery for deep infiltrating endometriosis is a technically challenging procedure which requires advanced surgical expertise. When an adequate surgical intervention is performed, a significant life quality boost is achieved in patients deeply suffering from severe pelvic pain.

<https://player.vimeo.com/video/339192330?autoplay=1>

ES28-0631 - VP080

Video Poster

Laparoscopic hysterectomy and bilateral ovarian fixation in deep infiltrating endometriosis

Burcu Yilmaz Hanege¹, Ulkar Heydarova¹, Dogan Vatanserver¹, Sebile Guler Cekic¹, Mustafa Serdar Yasartekin¹, Bulent Urman²

¹Koc University Hospital, Obstetrics and Gynecology, Istanbul, Turkey

²Koc Medical School, Obstetrics and Gynecology, Istanbul, Turkey

Background

Among young women suffering from chronic pelvic pain unresponsive to medical treatment the prevalency of endometriosis is approximately 70%. Some women could experience constant pain that interferes with their daily lives. Endometriosis patients could also experience dyspareunia, dysmenorrhea, dyschezia, dysuria and lower back pain. This video presents a 41 y/o female suffering from severe chronic pelvic pain. History of no previous pregnancy and no future fertility desire. MRI scan revealed bilateral endometrioma, rectouterine septations and endometriotic implants, bilateral hydrosalpinx and uterus myomatosis. Rectovaginal and sacrouterine endometriosis nodules could be palpated by bimanual pelvic examination.

Methods

Laparoscopic deep infiltrating endometriosis surgery (laparoscopic hysterectomy and bilateral salpingectomy) was performed. Port setup: umbilical port, and additional three 5mm trocars over left and right lower quadrant. Energy source: Olympus PK, and Maryland Ligasure.

Results

Due to severity of the disease, dense pelvic adhesions were explored upon entry to the abdominal cavity. All of the adhesions were liberated by careful dissection of the important retroperitoneal structures. Uterus, ovaries and bilateral fallopian tubes were all conglomerated by dense adhesions due to endometriotic implants. An approximately 3 cm lateral sidewall endometriotic nodule and 2cm rectovaginal nodule were excised. Total laparoscopic hysterectomy and bilateral salpingectomy were successfully performed. Both ovaries were then fixated to the psoas muscles on the right and left by vicryl sutures for precaution against risk of ovarian torsion. Pelvic anatomy was restored and all endometriotic lesions were precisely excised.

Conclusions

Laparoscopic deep infiltrating endometriosis surgery requires advanced surgical expertise. When performed proficiently, patients could relieve from pelvic pain that is a major setback for these patients' life quality.

<https://player.vimeo.com/video/339197404?autoplay=1>