

Paratesticular leiomyoma in an azoospermic patient and successful testicular sperm extraction (TESE) for intracytoplasmic sperm injection (ICSI) with an ongoing pregnancy

C. ORTEGA-HREPICH, E. VANDERLINDEN, C. BOURGAIN, P. DEVROEY, H. TOURNAYE

¹Center of Reproductive Medicine, Dutch Speaking, Brussels Free University, Brussels, Belgium.

²Department of Pathology, Dutch Speaking, Brussels Free University, Brussels, Belgium.

Correspondence at: Carolina Ortega, Center for Reproductive Medicine, Vrije Universiteit Brussel, Laarbeeklaan 101, 1090 Jette, Brussels, Belgium.

E-mail: Caroline.Ortega@uzbrussel.be

Abstract

Leiomyomata of the urinary and male genital tract are extremely rare. They have been reported throughout the genitourinary male tract and the most common localization is the renal capsule. However, leiomyomas of the epididymis, spermatic cord, tunica albuginea and testis have been reported.

We report diagnostic confirmation of a paratesticular leiomyoma in an azoospermic patient undergoing a testicular sperm extraction for intracytoplasmic sperm injection (TESE/ICSI) procedure.

Key words: Azoospermia, ICSI, Intracytoplasmic sperm injection, Paratesticular leiomyoma, TESE, testicular sperm extraction.

Introduction

Leiomyoma of the urinary and male genital tract is extremely rare. It is a benign soft tissue tumor that can arise from almost any site within the genitourinary tract containing smooth muscles. The most common localization is the renal capsule, followed by the bladder wall, epididymis, spermatic cord and tunica albuginea (Chiaramonte, 1988). Most of them are unilateral, nevertheless some cases of bilateral tumors have been described (Chiaramonte, 1988; Aus et al., 1991; Krichen Makni et al., 2005).

We report a case of a patient with primary infertility who had testicular sperm extraction (TESE) for intracytoplasmic sperm injection (ICSI) and in whom a paratesticular mass was discovered accidentally during the TESE procedure.

Case Report

A 31 years old man with a primary infertility of 7 years was referred to our center because of azoospermia. The medical history of the patient and

his wife showed no specific problems. Clinical examination revealed normally sized testes with a testicular volume of 15 ml as measured by a Prader orchidometer. Both epididymis and vasa deferentia, were present at both sides.

Six months before, the couple underwent a first unsuccessful TESE-ICSI treatment in another clinic. No paratesticular mass was reported and scrotal ultrasound was reported normal.

Routine laboratory examinations showed a serum follicle-stimulating hormone (FSH) of 11.8 IU/L, luteinizing hormone (LH) of 8.4IU/L and free testosterone of 56.6 ng/L. Sperm analysis showed azoospermia on several occasions.

The couple was planned for a combined TESE-ICSI trial. The wife of the patient had a regular menstrual cycle and the ovarian hyperstimulation was performed using a classical protocol with 0.25 mg/day of gonadotrophin releasing-hormone antagonist (Orgalutran®, Merck Sharpe & Dohme) and 150IU/day of recombinant gonadotrophins (Gonal-F®, Merck Serono). Ovulation triggering was done with 10000 IU of human chorionic

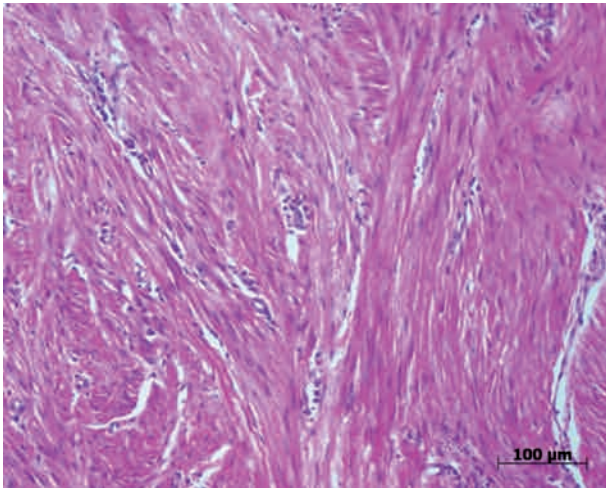


Fig. 1. — Paratesticular tumour composed of interlacing fascicles of spindled smooth muscles (hematoxylin-eosin, objective 20×).

gonadotrophin (Pregnyl®, Merck Sharpe & Dohme). Oocyte pick-up was performed under general anesthesia 36 hours later and 8 mature oocytes were retrieved.

The patient underwent a TESE on the same day of the oocyte retrieval.

During this surgery, an ovoid paratesticular mass was observed on the left testis, adjacent to the epididymis, measuring 2.5 × 2.5 × 2 cms. The mass was excised. Grossly it was firm and well circumscribed with a gray-white homogeneous surface.

Several testicular biopsies were taken to check the presence of spermatozoa and one of the biopsies was sending for pathological evaluation.

The microscopic examination of the paratesticular mass revealed a tumour composed of interlacing fascicles of spindled smooth muscles (Fig. 1). There was also focal inflammation with giant cells. The immunohistochemistry for smooth muscle actin (SMA) (Dako, clone 1A4, dilution 1/100) was positive. The final diagnosis of paratesticular leiomyoma was made. The analysis of the testicular biopsy showed a complete germ cell aplasia (Sertoli-cell-only syndrome). However, after multiple TESE, testicular spermatozoa were observed in the wet preparations which were used for ICSI. Based on morphology in the morning of day 3 after ICSI (van Royen E, 1999), 2 good quality embryos were transferred. The pregnancy test was positive and a single ongoing pregnancy was established.

Discussion

Testicular leiomyoma is a rare tumor of the testis (Chiaramonte, 1988; Destito et al., 1999). It is found most commonly in white males between the fourth

and sixth decades of their life with most presenting during the fifth decade (Aus et al., 1991; Leonhard et al., 1993).

Scrotal masses can be divided into intratesticular and extratesticular tumors. This differentiation is essential because of the high rate of malignancy in solid intratesticular lesions (90-95%) (Doherty et al., 1991; Krone et al., 1985; Yilmaz et al., 2002). The use of ultrasonography is extremely important to distinguish the two entities (O'Brien et al., 2008); it can differentiate between intra and extratesticular tumors in 95-100% of the cases (4) and avoid radical surgery. However, most of the patients have orchiectomy before a final diagnosis is established (McClellan et al., 1986).

Macroscopically, leiomyomas are greyish white masses with a rubbery consistency with whorled cut surface. Microscopically, they are characterized by intersecting smooth muscle bundles, which tend to be more prominent around the vessels and ducts. They may show myxoid characteristics and calcifications (Barton et al., 1999). Necrosis, nuclear atypia and mitotic activity are unusual (deLuise et al., 1976).

In 1996, Hertzberg et al. reported another feature of leiomyoma: multiple, narrow areas of shadowing not cast by calcifications, but corresponding to transition zones between the various tissue components of the mass and they suggested that it may help differentiate leiomyomas from other scrotal masses (Hertzberg et al., 1996).

The histogenesis concerning leiomyoma of the testis is not clear. Some authors support the theory of smooth muscle differentiation from myocytes in the wall of seminiferous tubules (Chiaramonte, 1988; Longchamp et al., 1998). Others authors proposed that they can arise from myoid cells or potentially their progenitors present in the vascular smooth muscle (González et al., 1999). Differentiation from totipotent teratomas has also been proposed (Chiaramonte, 1988).

The final diagnosis of the leiomyoma is made on its histopathologic examination based on a cellular proliferation of band spindle cells having a typical morphology with cigar-shaped nuclei and eosinophilic cytoplasm (O'Brien et al., 2008).

The use of monoclonal antibodies (clone I4A and HHF 35) reliably marks the product of α and γ isoactin genes, thus detecting neoplastic cells of the smooth muscle origin (Brittingham et al., 1997). Thereby, in 1999, González et al. detected smooth muscle specific actin in the neoplastic cells using actin specific monoclonal antibodies (González et al., 1999).

The differential diagnosis of leiomyomas includes leiomyosarcoma, fibromas, adenomatoid tumors,

cystadenomas, neurofibromatosis and specific inflammations (deLuise et al., 1976; Chiong et al., 2004).

In our patient with a paratesticular leiomyoma, there was a successful sperm retrieval and ICSI with an embryo transfer and ongoing pregnancy. There is little evidence that the presence of the tumor was of influence in the result of the TESE because of its paratesticular localization. The foreign body inflammation with giant cells can be attributed to the prior TESE procedure. In view of the pathologic findings and the extratesticular localization, further follow-up is not indicated for this mass.

References

- Aus G, Boiesen PT. Bilateral leiomyoma of the tunica albuginea. Case report. *Scand J Urol Nephrol*. 1991;25:79-80.
- Barton JH, Davis JC, Sesterhenn IA et al. Smooth muscle hyperplasia of the testicular adnexa clinically mimicking neoplasia. *Am J Surg Pathol*. 1999;23:903-9.
- Brittingham J, Liaw D, Liddel R et al. Comparative analysis of smooth muscle isoactin gene expression in normal and neoplastic tissues. *Pathobiology*. 1997;65:113-22.
- Chiaramonte RD. Leiomyoma of the tunica albuginea of the testis. *Urology*. 1988;3:344-5.
- Chiong E, Tan KB, Siew E et al. Uncommon benign intrascrotal tumors. *Ann Acad Med Singapore*. 2004;33:351-5.
- deLuise VP, Draper JW, Gray GF. Smooth muscle tumors of the testicular adnexa. *J Urol*. 1976;115:685-8.
- Destito A, Servello C, Pisanti F et al. Leiomyoma of the testis. *Scand J Urol Nephrol*. 1999;33:338-9.
- Doherty FJ. Ultrasound of the nonacute scrotum. *Semin Ultrasound CT MR*. 1991;12:131-56.
- González CM, Victor TA, Bourtsos E et al. Monoclonal antibody confirmation of a primary leiomyoma of the testis. *J Urol*. 1999;161:1908.
- Hertzberg BS, Kliwer MA, Hertzberg MA et al. Epididymal leiomyoma: sonographic features. *J Ultrasound Med*. 1996;15:797-9.
- Krichen Makni S, Mnif Hachicha L et al. Feminizing testicular syndrome with multiple hamartomas and bilateral paratesticular leiomyomas. *Rev Med Interne*. 2005;26:980-3.
- Krone KD, Carroll BA. Scrotal ultrasound. *Radiol Clin North Am*. 1985;23:121-39.
- Leonhard WC, Gooding GA. Sonography of epididymal leiomyoma. *Urology*. 1993;41:262-4.
- Longchamp E, Cariou G, Arborio M et al. The intratesticular leiomyoma: an unusual location. Report of a case. *Ann Pathol*. 1998;18:418-21.
- McClellan DS, Roscher A. Intrascrotal tumours in the older male. *Int Surg*. 1986;71:51-2.
- O'Brien J, Loftus B, Barret C et al. Leiomyoma of the testis: A rare testicular mass. *J Clin Ultrasound*. 2008;36:240-2.
- van Royen E, Mangelschots K, de Neubourg D, et al. Characterization of a top quality embryo, a step toward single-embryo transfer. *Hum Reprod*. 1999;14:2345-9.
- Yilmaz E, Bozdoan O, Atasoy P et al. Epididymal leiomyoma associated with leydig cell hyperplasia: a case report and immunohistochemical study. *Int Urol Nephrol*. 2002;34:215-8.