

Imaging in gynaecological disease: clinical and ultrasound characteristics of mucocele of the appendix. A pictorial essay

E. JANSEN¹, S. FRANSIS², S. AHMAD³, D. TIMMERMAN⁴, C. VAN HOLSBEKE^{1,4}

¹Department of Obstetrics and Gynaecology, ZOL Hospitals Campus St Jan, Genk, Belgium.

²Department of Pathology, ZOL Hospitals Campus St Jan, Genk, Belgium.

³Department of Pathology, University Hospitals KU Leuven, Leuven, Belgium.

⁴Department of Obstetrics and Gynaecology, University Hospitals KU Leuven, Leuven, Belgium.

Correspondence at: janseneleonora@gmail.com

Abstract

The aim of this pictorial essay is to describe the ultrasound characteristics of the mucocele of the appendix (MA) by transvaginal ultrasound. The databases of the pathology and gynaecology departments of two Belgian hospitals were retrospectively searched for all cases of MA. Only patients who received a preoperative transvaginal ultrasound scan by an experienced ultrasound examiner following the IOTA protocol were included. Ultrasound characteristics were described and pattern recognition was applied in order to find morphological characteristics typical for MA. Thirty-one cases were found of which five underwent a transvaginal ultrasound. In three out of these five cases a mucocele was described. All three masses had a similar morphology, i.e. a para-ovarian unilocular tubular mass with a color score of 1. A typical characteristic was the aspect of the cyst content, which resembled whipped cream. Although MA is seldom diagnosed by gynaecologists, transvaginal ultrasound is able to make an accurate diagnosis. MA is a para-ovarian, unilocular tubular mass that typically has a cyst content that resembles whipped cream.

Key words: Ultrasound, mucocele, appendix, pseudomyxoma peritonei, characteristics, transvaginal.

Introduction

A mucocele of the appendix (MA) is a rare benign condition of the appendix referring to any dilatation of the appendiceal lumen due to mucus accumulation (Malave et al., 2011). Because of its para-adnexal location, appendiceal mucoceles are sometimes misdiagnosed as adnexal masses and therefore referred for a transvaginal gynaecological ultrasound.

The aim of this study is to describe the gray-scale and color Doppler characteristics of the simple MA on transvaginal ultrasound in order to improve its correct preoperative diagnosis.

Epidemiology

Appendiceal mucocele is a cystic dilatation of the appendix due to accumulation of gelatinous mucoid

material in the lumen. It is a rare histological condition with a reported incidence of 0.2 to 0.3% (Woodruff et al., 1940). It is more common in women than in men, although some series report the opposite (Malave et al., 2011; Sasaki et al., 2003; Balci et al., 2009). According to Malave et al. (2011) the median age at diagnosis is between 54 and 64 years. Depending on the histological characteristics, two benign and two malignant subtypes are described (Woodruff et al., 1940). The benign neoplasms that represent the majority of the MA's are the simple mucocele of the appendix or retention cyst and the cystadenoma (63%). The malignant mucoceles are the mucoceles with epithelial hyperplasia and the cystadenocarcinoma. The mucocele can result from external occlusion and obstruction (e.g. endometriosis; carcinoid) or the mucus accumulation may be produced by a true mucinous neoplasm. Pseudomyxoma peritonei is a rare malignant

disease (incidence of 50/year in the United Kingdom), where the epithelial lining is ruptured and the mucus enters the abdominal cavity causing adhesions and scar tissue followed by obliteration of the abdominal cavity and intestinal obstruction. Pseudomyxoma can occur from a benign or a malignant MA, but is in itself a malignant disease with five-year survival rates ranged from 70 to 86 percent, while at 10 years, 60 and 68 percent of patients were still alive (Bryant et al., 2005).

Macroscopic appearance

The mucocele of the appendix is a distended, mucus-filled appendix. Macroscopically it may look like a glossy, rounded, protruding mass arising from the appendiceal orifice or just a bulging mass in the appendix. A vulcano-sign is also described on endoscopy (Hamilton and Stormont, 1989).

Microscopic appearance

The epithelium can be flat, atrophic and devoid of any atypical features in the simple mucocele, it can be hyperplastic with micropapillary configuration in the benign neoplasm or it can be frankly malignant with obviously malignant glands in malignant neoplasms.

Clinical symptoms

A quarter of the MA's are asymptomatic incidental findings during imaging or surgery (Malave et al., 2011; Kim et al., 1998; Kalu and Croucher, 2005). If symptomatic, patients present with chronic or acute pain in the right fossa, with or without a palpable mass (Degani et al., 2002; Khan et al., 2010; Zissin et al., 1999). Less often they present with gastrointestinal bleeding, gastrointestinal obstruction due to the mass effect or an acute abdomen due to rupture of the mucocele. Patients with a MA are often referred for surgery with the presumed diagnosis of acute appendicitis. The preoperative differential diagnosis with acute appendicitis could however be made by the absence of fever but remains difficult. Sepsis in a patient with a pseudomyxoma peritonei causes fever as well, but in this case the histology and the ultrasound morphology of the mass is completely different. Diagnostic tools like serum analysis are non-specific (e.g. anemia and increased sedimentation rate) but infectious parameters may suggest the presence of acute appendicitis instead of MA. Raised levels of the tumor markers CEA and CA 19.9 have been reported for malignant neoplastic mucoceles but not for the simple MA. Other differential diagnoses are leiomyoma, fibro-

ma, neuroma or lipoma of the appendix, mesenteric or duplication cyst, hydrosalpinx, lymphoma, intussusception, endometriosis and ovarian pathology. Several attempts have been made to describe MA's on ultrasound (Malave et al., 2011; Sasaki et al., 2003; Kim et al., 1998; Degani et al., 2002) and on computed tomography (CT) (Malave et al., 2011; Kim et al., 1998; Zissin et al., 1999). Findings include a dilated cystic structure in the right hemipelvis with a 'bottle, onion shell or banana-like' appearance. The structure may be filled with a homogenous hypoechoic to anechoic material and peripheral calcifications may be present (Malave et al., 2011; Degani et al., 2002). Mild peripheral contrast enhancement, after intravenous ultrasound contrast administration, is also found.

Prognosis

In general, the mucocele of the appendix is a benign condition that only requires surgery and no other treatment nor follow-up. Nevertheless one should take into account the potential to transform into a malignancy over time.

Another potential risk of the MA is that the mucinous fluid disseminates or the MA ruptures and gelatinous deposits spread throughout the peritoneal cavity resulting in pseudomyxoma peritonei. Pseudomyxoma peritonei is a highly malignant disease due to the obstructive nature of adhesions and liver metastasis. The treatment involves debulking surgery and intraperitoneal chemotherapy. Most pseudomyxomas peritonei originate from the appendix rather than from mucinous tumors of the ovary. According to Smeenk et al. (2008) pseudomyxoma peritonei has an incidence of 2 per million per year. Therefore, the surgical resection of the simple MA can be performed by a laparoscopic approach, but in case the risk of rupture and spilling during surgery seems to be too high, conversion to a laparotomy is indicated. In case of a malignant MA, a yearly follow up with physical examination, CT and tumor markers, CEA and CA 19.9 during the next 5 years is recommended.

Methods

The databases of the pathology and gynaecological ultrasound departments of two centres, Z.O.L. Genk, Belgium and University Hospitals Leuven, Belgium were searched retrospectively for all cases of MA between 2000 and 2011. Only patients who preoperatively had been scanned by CVH or DT were included. Both sonologists have special expertise in gynaecological ultrasound and are members of the IOTA (International Ovarian Tumor Analysis)

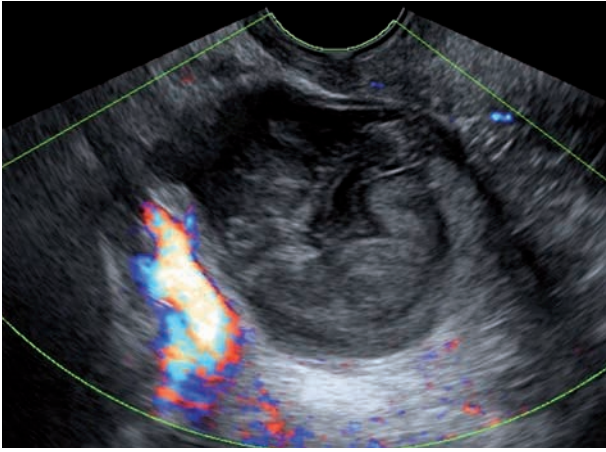


Fig. 1. — Diagnosis through ultrasonography on routine check-up. Colorscore 1 and Whipped cream characteristic.

group who participated in the IOTA studies. In the year 2000, the IOTA group published a consensus paper on which standardized terms and definitions should be used during the sonographic assessment of adnexal masses and how measurements should be taken. All included masses were described following the IOTA criteria. The IOTA protocol also required the ultrasound examiner to classify the mass as benign or malignant at the end of each scan and, whenever possible, to suggest a specific histological diagnosis.

Results

Database search retrieved 31 cases of MA of which five patients received a preoperative transvaginal ultrasound. One out of the five cases was excluded because this patient had - beside the MA, a concomitant stage IV ovarian cancer and the MA was not recognized as such during the ultrasound and therefore also not described in the report. A second case was excluded because only a peritoneal pseudocyst was visualised on ultrasound, but no other mass. In this patient, the diagnosis of a small MA was a coincidental finding during surgery. The remaining three patients were referred for a transvaginal ultrasound examination because ovarian pathology was suggested during previous examinations. One out of the three patients was asymptomatic and the diagnosis of MA was made during a routine gynaecological check-up (Fig. 1). In the second patient, an ovarian mass was visualised on CT scan, performed for vague gastro-intestinal complaints (Fig. 2) and the third patient was referred because of right fossa pain (Fig. 3). Demographic, clinical and sonographic characteristics are listed in Table I. All three masses presented with the same morphology i.e. a para-ovarian, unilocular, tubular masses with a

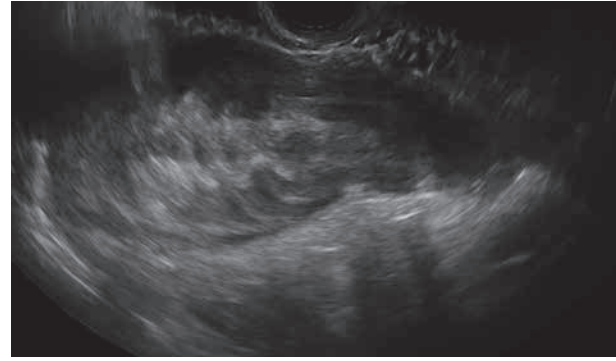


Fig. 2. — Diagnosis through ultrasonography after CT scan. Whipped cream characteristic.

color score of 1 (no flow visualised) (Table I). The median largest diameter was 72.6 mm (50-108 mm). A characteristic for MA that was found after pattern recognition was the aspect of the cyst content, which resembled whipped cream (Fig. 4). In all three cases the correct specific histologic preoperative diagnosis of MA was suggested by the sonologist. None of the masses was included in any of the IOTA studies since a mass that is presumed to be non-adnexal cannot be include

Discussion

The simple MA is a rare and benign condition of the appendix. The differential diagnosis that is made depends on the clinical presentation and the type of specialist that is taking care of the patient. The correct diagnosis is quite often only made after laparoscopy and in a substantial amount of cases a coincidental finding. Different sizes have been described depending on the amount of mucus that is accumulated in the MA. If visualised preoperatively on CT or ultrasound, it is often misinterpreted as an appendiceal malignancy or an adnexal mass. Because an MA presents as a para-adnexal mass, one should be aware of this type of pathology when performing a transvaginal gynecological ultrasound. It is imperative to diagnose this disease in time because of the risk of developing a pseudomyxoma peritonei. Where an intact mucocele is a benign process, peritoneal dissemination is considered lethal without the correct management. The correct preoperative diagnosis of a simple MA is rare made but is possible using the appropriate diagnostic tools. To the best of our knowledge there are no large series that report on the transvaginal ultrasound characteristics of MA.

We described three cases that received a transvaginal ultrasound and found similar morphology in all three cases, i.e. a para-ovarian, unilocular, tubular masses with a color score of 1 which is the same

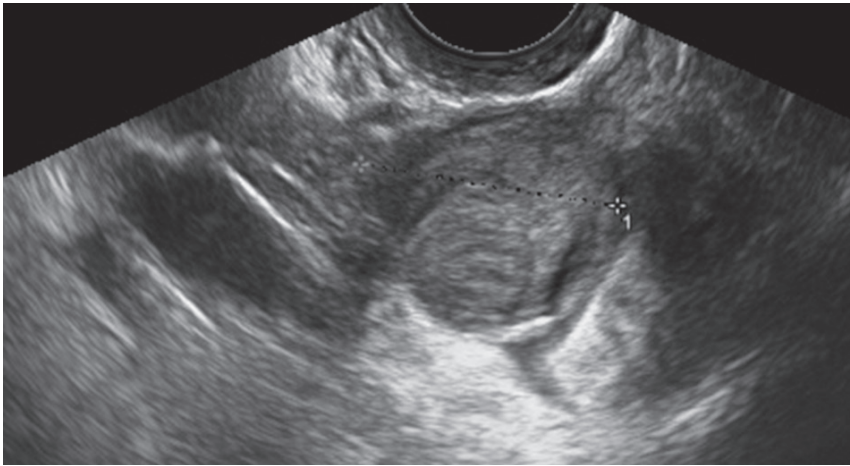


Fig. 4. — Whipped cream

Fig. 3. — Diagnosis through ultrasonography with clinical symptoms. Whipped cream characteristic.

Table I.		
Characteristic		total
Locularity	unilocular	3/3
Number of locules	< 5	3/3
Presence of papillarities	no	3/3
Largest diameter of lesion (mm)	Mean 72.6	**
Echogenicity of cyst content	mixed	3/3
Color- score	1	3/3
Suggestion	Benign and Appendiceal Mucocele	3/3

morphology as found in literature. The most typical characteristic we found is the whipped cream aspect of the cyst content.

We are aware of the small amount of cases, but explain this by the rarity of this pathology in gynaecology departments.

Conclusion

On transvaginal ultrasound the mucocele of the appendix is a unilocular, tubular, para-ovarian mass of medium size. We propose the “whipped cream” sign as a possible specific marker to suggest the presence of this rare, but clinically very important condition.

References

Balci O, Ozdelir S, Mahmoud AS. Appendiceal mucocele mimicking a cystic right adnexal mass. *Taiwan J Obstet Gynecol.* 2009;48:412-414.
 Bryant J, Clegg AJ, Sidhu MK et al. Systematic review of the Sugarbaker procedure for pseudomyxoma peritonei. *Br J Surg.* 2005;92:153-158.

Degani S, Shapiro I, Leibovitz Z et al. Sonographic appearance of appendiceal mucocele. *Ultrasound Obstet Gynecol.* 2002; 19:99-101.
 Hamilton DL, Stormont JM. The volcano sign of appendiceal mucocele. *Gastrointest Endosc.* 1989;35:453-456.
 Kalu E, Croucher C. Appendiceal mucocele: a rare differential diagnosis of a cystic right adnexal mass. *Arch Gynecol Obstet.* 2005;271:86-88.
 Khan MR, Ahmed R, Saleem T. Intricacies in the surgical management of appendiceal mucinous cystadenoma: a case report and review of the literature. *J Med Case Rep.* 2010; 4:129.
 Kim SH, Lim HK, Lee WJ et al. Mucocoele of the appendix: ultrasonographic and CT findings. *Abdom Imaging.* 1998; 23:292-296.
 Malave C, Wynn G, Nussbaum MS et al. Incidental diagnosis of appendiceal mucocele with vaginal ultrasonography and computed tomography. *Obstet Gynecol.* 2011;117:479-481.
 Sasaki K, Ishida H, Komatsuda T et al. Appendiceal mucocele: sonographic findings. *Abdom Imaging.* 2003;25:15-18.
 Smeenk RM, Van Velthuysen MLF, Verwaal VJ et al. Appendiceal neoplasms and pseudomyxoma peritonei: A population based study. *Eur J Surg Oncol.* 2008;34:196-201.
 Woodruff R, McDonald JR. Benign and malignant cystic tumors of the appendix. *Surg Gynecol Obstet.* 1940;71:750-755.
 Zissin R, Gayer G, Kots E et al. Imaging of mucocele of the appendix with emphasis on the CT findings: a report of 10 cases. *Clin Radiol.* 1999;54:826-832.