

Complete congenital foetal heart block: a case report

M. DEY, T. JOSE, A. SHRIVASTAVA, R.D. WADHWA, R. AGARWAL, V. NAIR

Department of Obstetrics and Gynaecology, Armed Forces Medical College, Pune, Maharashtra, India – 411040

Correspondence at: deym1@yahoo.com

Abstract:

Congenital heart block (CHB) is the most severe manifestation of neonatal lupus which can develop into a lethal atrioventricular (AV) block. Complete congenital foetal heart block related to maternal anti-Ro/SSA autoantibodies typically develops between 20 and 24 weeks of gestation. CHB with a structurally normal heart is frequently associated with maternal autoantibodies to Ro/SSA and La/SSB. We are presenting a case of foetal complete CHB with high maternal Ro/SSA and La/SSB titre with favourable outcome.

Key words: Congenital heart block, SLE, Ro/SSA, La/SSB, Dexamethasone.

Introduction

Isolated congenital heart block is defined as congenital heart block found in a structurally normal heart and when it is present with congenital heart disease known as complex congenital heart block. CHB with a structurally normal heart is frequently associated with maternal autoantibodies to Ro/SSA and La/SSB. Ro/SSA women have a 2% risk getting a child with CHB and the risk is about 20% among women who previously have had a child with CHB (Buyon et al., 2009). It is important to distinguish these two forms of CHB because they differ not only in their pathogenesis and in their rate of recurrence, but also in the prognoses of children affected. In fact, infants with CHB associated with severe structural heart disease have a poorer prognosis than infants with isolated CHB (Rosenthal, 2003) while the risk of recurrence is higher in mothers who have tested positive for anti-Ro/SSA antibodies. A mosaic of maternal, foetal, and possibly environmental factors might be involved in inducing CHB, but also the combination of such factors might be the way to induce the onset of CHB (Carolis et al., 2010).

Case report

A 23 years old G2P1L1 lady reported to our antenatal OPD at 24 weeks period of gestation (POG).

In her last pregnancy, she underwent an emergency caesarean section at term for breech presentation and delivered a healthy male baby weighing 2.7 Kg. She also mentioned preeclampsia developed at 36 week period of gestation for which she was monitored by daily blood pressure and biochemical and haematological parameters.

On examination, she was averagely built with a BMI of 24.8 Kg/m² without any pedal oedema and normotensive with normal vital parameters. On abdominal examination, uterine height corresponds with POG and foetal heart sound was 66/min on Doppler (Fig. 1).

Her antenatal biochemical and haematological parameters were within normal limits. TSH was 3.08 and DCT was negative. Immunological tests revealed serum ANA moderately positive and SS-A (Ro) antibodies and SS-B (La) antibodies strongly positive. Ultrasound examination revealed a single live intra uterine foetus with normal liquor at 24w2d POG with FHR of 56-60/min. Foetal echocardiography showed complete heart block with structurally normal heart. Maternal echocardiography was within normal limits. She was started on dexamethasone (4mg/day), iron and calcium supplements. She was followed up by weekly ultrasound to follow the FHR pattern and FHR was stable at 52-56 beats/ min with no features of hydrops.

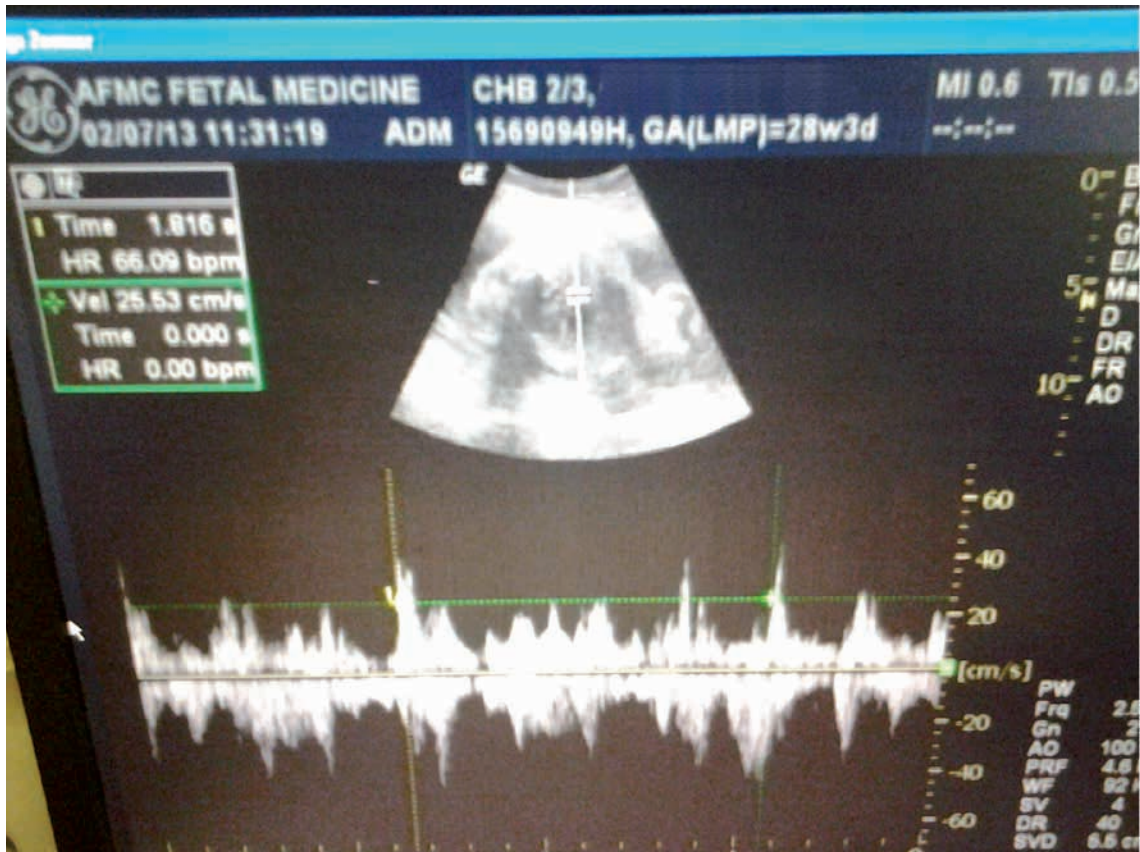


Fig 1. — Doppler showing foetal heart rate of 66/min

At 35w3d POG she underwent a caesarean section for preterm labour with post caesarean status and delivered a female baby weighing 2100 grams. The heart rate at birth was 60 beats/minute and APGAR score at 1 minute and 5 minutes was 7 and

9 respectively. Post delivery at NICU, the baby was stable at room air with heart rate of 60 beats/ min. ECG showed a heart beat of 54/ min and echocardiography did not reveal any structural abnormality (Fig. 2). The baby was discharged after one week

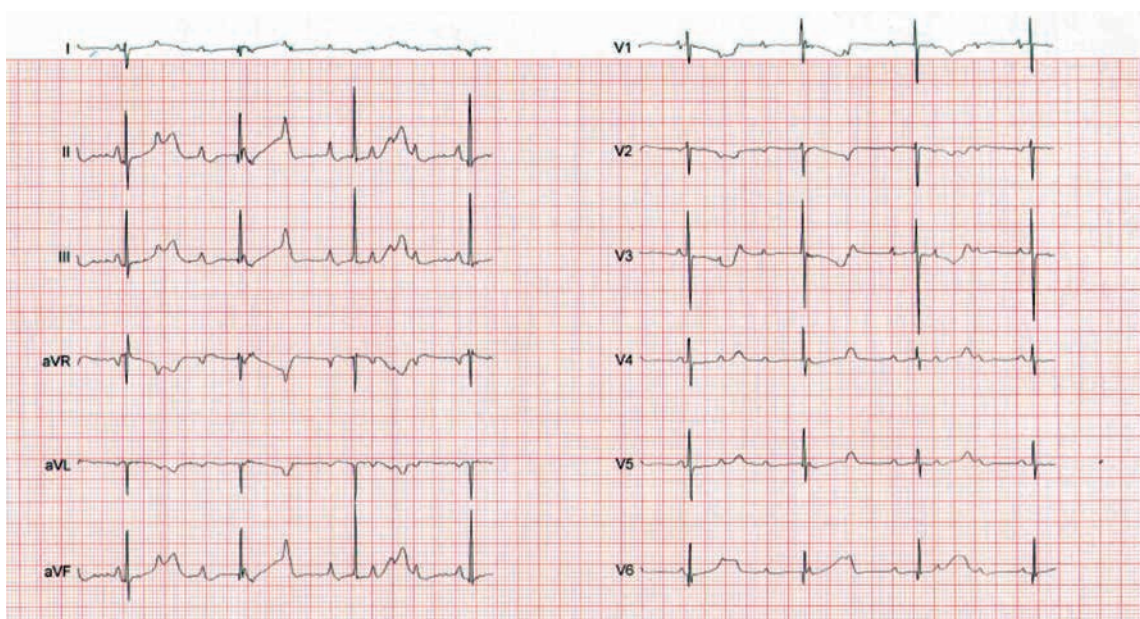


Fig 2. — Post delivery ECG showing heart rate of 54/ min

and carefully followed up on a weekly basis. Four months after delivery the baby did not require a pacemaker yet.

Discussion

CHB carries a significant mortality (20-30%, primarily foetal/ neonatal) and morbidity (67% require permanent pacing before adulthood) (Buyon et al., 1998). During pregnancy, the maternal autoantibodies cross the placenta and bind to cardiomyocytes, the atrioventricular (AV) conduction system is disrupted by inflammation with subsequent fibrosis and calcification leading to a complete AV block. A life-threatening cardiomyopathy (Nield et al., 2002) may be present in 10-15% cases. The most important risk factors for death in these patients are low birth weight, premature gestation, hydrops foetalis, endocardial fibroelastosis and diminished ventricular function. Patients who are diagnosed and treated in the neonatal period have a survival rate of 94% (Gupta et al., 2011).

Biomarkers such as prolongation of the foetal Doppler mechanical PR interval have not convincingly demonstrated utility in predicting advanced block (Friedman et al., 2008). Consistent with the fibrotic replacement of the atrioventricular node (AV) observed in autopsy studies from foetuses dying with CHB, reversal of a third degree block has never been achieved (Friedman et al., 2008). Current prophylactic and treatment strategies for CHB include maternal steroids, plasmapheresis, sympathomimetics, and *in utero* cardiac pacing (Buyon et al., 2009).

In most of the studies or case reports, the mother was treated with dexamethasone 4 mg daily after detection of foetal heart block and continued until the end of pregnancy. We also followed the same protocol with foetal echocardiography which showed a structurally normal heart. Although maternal tolerability of dexamethasone in our patient was excellent, dexamethasone may be associated with infection, osteoporosis, osteonecrosis, diabetes, hypertension, premature rupture of membranes, preterm labour and preeclampsia, foetal adrenal insufficiency, intrauterine growth restriction (IUGR), and oligohydramnions (Costedoat-Chalumeau et al., 2003). A review by Carolis et al. (2010) showed that steroid treatment to mother is beneficial in first and second degree heart block but once foetal third-degree block is detected, it is irreversible regardless of treatment.

Considering treatment with betamimetics, seven studies on nine foetuses treated with different betamimetics showed that in all of these babies there is no reversion to lesser degree of heart block. Four

babies needed the pacemaker implantation after birth (44%) and the overall one-year survival was 89%, with one neonatal death due to an immune-mediated liver fibrosis (Jaeggi et al., 2004).

Intravenous gamma globulin (IVIG) has been of benefit in a variety of immune-mediated and inflammatory diseases but treatment with intravenous immunoglobulin (PITCH study) showed to be ineffective as a prevention of CHB in pregnancies at risk of recurrence (Friedman et al., 2010).

Information on prenatal progression of the cardiac anomaly is important to plan perinatal management, as early pacemaker insertion may be required in some newborns. Temporary pacing can be achieved transcutaneously, transesophageally or transvenously.

A permanent pacemaker placement is needed in most children with congenital heart block. The medical care of congenital heart block is currently focused on identifying the optimal timing of pacemaker therapy to ensure a positive outcome (Puria et al., 2013). Our patient is still under follow up and may require a pacemaker in the near future.

In conclusion, patients who are at high risk of developing CHB, frequent surveillance at 16-20 weeks of gestation is required because steroids may improve the outcome of the foetus in first and second degree heart block. The delivery should be planned in a tertiary care centre where pacemaker placement facility is available, when needed.

References

- Buyon JP, Clancy RM, Friedman DM. Autoimmune associated congenital heart block: integration of clinical and research clues in the management of the maternal/foetal dyad at risk. *J Intern Med.* 2009;265:653-62.
- Buyon JP, Clancy RM, Friedman DM. Cardiac Manifestations of Neonatal Lupus Erythematosus: guidelines to management integrating integrating clues from the bench and bedside. *Nat Clin Pract Rheumatol.* 2009;5:139-48.
- Buyon JP, Hiebert R, Copel J et al. Autoimmune-associated congenital heart block: Mortality, morbidity, and recurrence rates obtained from a national neonatal lupus registry. *J Am Coll Cardiol.* 1998;31:1658-66.
- Carolis SD, Salvi S, Botta A et al. Which Intrauterine Treatment for Autoimmune Congenital Heart Block? *Open Autoimmunity Journal.* 2010;2:1-10.
- Costedoat-Chalumeau N, Amoura Z, Le Thi Hong D et al. Questions about dexamethasone use for the prevention of anti-SSA related congenital heart block. *Ann Rheum Dis.* 2003;62:1010-2.
- Friedman DM, Llanos C, Izmirly PM et al. Evaluation of fetuses in a study of intravenous immunoglobulin as preventive therapy for congenital heart block: Results of a multicenter, prospective, open-label clinical trial. *Arthritis Rheum.* 2010;62:1138-46.
- Friedman DM, Kim MY, Copel JA et al. Utility of Cardiac Monitoring in Fetuses at Risk for Congenital Heart Block.

- The PR interval and Dexamethasone evaluation (PRIDE) Prospective Study. *Circulation*. 2008;117:485-93.
- Gupta M, Hamilton R, Berul C et al. Pediatric congenital atrioventricular block. *Medscape*, Dec 6, 2011.
- Jaeggi ET, Fouron JC, Silverman ED et al. Transplacental fetal treatment improves the outcome of prenatally diagnosed complete atrioventricular block without structural heart disease. *Circulation*. 2004;110:1542-8.
- Nield LE, Silverman ED, Smallhorn JF et al. Endocardial fibroelastosis associated with maternal anti-Ro and anti-La antibodies in the absence of atrioventricular block. *Circulation*. 2002;40:796-802.
- Puria S, Pooni P, Mohan B et al. Pregnancy With SLE and Fetal Congenital Heart Block: A Case Report. *Cardiol Res*. 2013;4:126-8.
- Rosenthal E. Classification of congenital complete heart block: autoantibody-associated or isolated? *Lupus*. 2003;12:425-6.