

# Management of ovarian cysts and cancer in pregnancy

J. DE HAAN\*, M. VERHEECKE\*, F. AMANT

*KU Leuven – University of Leuven, Department of Oncology; University Hospitals Leuven, Department of Obstetrics and Gynaecology, Gynaecological Oncology, 3000 Leuven, Belgium.*

Correspondence at: Frederic.amant@uzleuven.be

\*Equally contributed

## Abstract

Adnexal masses during pregnancy are not uncommon. Ovarian cysts or masses during pregnancy should be accurately evaluated to identify the patients who need surgical interventions from those where a ‘wait-and-see’ strategy can be followed. Ultrasound and MRI are safe diagnostic tools to distinguish between benign and malignant lesions. Treatment options (surgical procedures) should be discussed for each patient individually. Both open surgery and laparoscopy can be performed considering the tumour diameter, gestational age and surgical expertise. A multidisciplinary approach is necessary in case of high suspicion of malignancy and preferably patients should be referred to centres with specialized experience.

**Key words:** Adnexal mass, pregnancy, diagnosis, management.

## Introduction

Since the introduction of routine obstetric ultrasound examination adnexal masses are diagnosed more frequently than before. The incidence of adnexal masses during pregnancy is estimated to be 0,2-2% depending on the stage of pregnancy. With a 1-6% malignancy rate, the vast majority of these masses are benign (Hoover and Jenkins, 2011; Leiserowitz, 2006; Runowicz and Brewer, 2014; Telischak et al., 2008).

Before the incorporation of ultrasound into clinical practice, adnexal masses during pregnancy were mainly diagnosed by physical examination when women presented with symptoms including abdominal/pelvic pains or a palpable mass. These masses were more likely to be surgically removed to resolve symptoms, avoid complications or because of the malignant potential. Since the finding of an adnexal mass during pregnancy now is mainly incidental, accurate diagnosis is important to identify those patients who are in need of surgery (Bernhard et al., 1999; Glanc et al., 2008; Leiserowitz, 2006).

The aim of this manuscript is to present an overview of the aetiology on different adnexal masses

during pregnancy, the different diagnostic options and treatment guidelines.

## Benign ovarian masses

In the premenopausal population adnexal masses found on examination are often incidentally, mostly benign and of little clinical significance. One has to make a distinction between an ovarian mass and a non-ovarian mass. Potential non-ovarian masses include pedunculated fibroids, hydrosalpinx or para-ovarian cysts. Fibroids appear as heterogeneous, solid masses whereas hydrosalpinx present more as a tubular shaped structure. A hydrosalpinx can be difficult to distinguish from a malignant neoplasm due to the presence of nodules and thick endosalpingeal folds. Para-ovarian cysts are a common incidental finding and do not have any clinical significance (Chiang and Levine, 2004; Glanc et al., 2008; Levine, 2014).

The most common ovarian masses in premenopausal women are functional cysts. Functional cysts, like a follicular cyst or corpus luteum, are hormonally influenced and can have different morphology on ultrasound. Follicular cysts have a

smooth, thin wall and are unilocular. The corpus luteum can have a variety of appearances ranging from a simple cyst to a complex cystic lesion with internal debris and thick walls (Parsons, 2001). A bleeding in a cyst results in a wide variety of ultrasound appearances depending on the timing and the amount of blood. All these cysts resolve by itself over a couple of weeks or even months (Chiang and Levine, 2004; Glanc et al., 2008; Hoffman, 2014; Patel et al., 2005).

Dermoid cysts are the most common non-functional ovarian masses in premenopausal women (Giuntoli et al., 2006; Hoover and Jenkins, 2011). When evaluating a dermoid cyst by ultrasound two of three characteristic features as mentioned in Table I have a 100% positive predictive value (Patel et al., 1998). The other common non-functional ovarian mass is an endometrioma. Endometriomas and dermoid cysts are benign tumours but can give symptoms due to rupture or torsion. Most of the epithelial neoplasms of the ovary are benign.

Cystadenomas count for 40-50% of all benign adnexal epithelial neoplasms, with the serous cystadenoma being the most common. They present as large (5-20 cm), thin-walled cysts. Serous cystadenomas are more common, are more often multi-

locular and are bilateral in 20%. Mucinous cystadenomas are bilateral in less than five percent. Cystadenomas are not hormonally sensitive and do not resolve after 16 weeks of pregnancy (Glanc et al., 2008; Hoffman, 2014). In Table I characteristics that distinguish the different masses by ultrasound are listed.

### Pregnancy-associated changes of ovarian masses

During pregnancy the same ovarian masses can be found as those diagnosed in the non-pregnant population. In addition, a number of pregnancy-associated masses may occur. When a pregnant patient presents with a symptomatic adnexal mass early in pregnancy, an ectopic pregnancy must always be ruled out since an undiagnosed ectopic pregnancy may have a potentially lethal outcome (Runowicz and Brewer, 2014). Other pregnancy-associated masses are benign and typically present as bilateral cysts, except for luteomas who present as unilocular solid masses (Leiserowitz, 2006; Hoover and Jenkins, 2011; Hoffman, 2014).

The most common pregnancy-associated ovarian masses are functional cysts like the corpus luteum of pregnancy and theca-lutein cysts. Most of these

**Table I.** — Benign adnexal masses discovered during early pregnancy sonography with their morphologic appearance on ultrasound. (Giuntoli et al., 2006; Glanc et al., 2008; Hoover et al., 2011; Leiserowitz, 2006; Parsons, 2001; Telischak et al., 2008; Whitecar et al., 1999).

Type of mass	Sonographic features
<b>1. Functional cyst</b>	
– <b>Corpus luteum</b>	– Widespread appearance; ‘Ring of fire’ with Doppler.
– <b>Follicular cyst</b>	– Mainly simple cyst < 10 cm, sometimes with debris.
– <b>Haemorrhagic cyst</b>	– Fine interdigitating lines (fishnet); solid compounds with concave outer lining. No flow with Doppler.
<b>2. Dermoid cyst</b>	– Rokitansky nodule; a hyperechoic nodule with acoustic shadowing in a background of low-level echoes. – ‘Tip of the iceberg’ phenomenon, where a highly echogenic cyst, contents of sebum and hair, causes posterior attenuation of sound. – ‘Dermoid mesh’, multiple interdigitating lines and dots which are seen when hair is floating in sebum.
<b>3. Serous cystadenoma</b>	– Large simple cyst > 5 cm. – Thin septations or papillary formations.
<b>4. Mucinous cystadenoma</b>	– > 5 cm in diameter. – Multiple septae. – Heterogenic aspect.
<b>5. Endometrioma</b>	– Round thick regular wall; diffuse homogenous low-level internal echoes (chocolate cyst). – Calcifications with acoustic shadowing.
<b>6. Leiomyomas</b>	– Not attached to the ovary. – Round regular wall. – When outgrowing the blood supply central necrosis may be seen.
<b>7. Paraovarian cyst</b>	– 1-2 cm simple cysts. – Not attached to the ovary.

cysts will resolve after the first 14-16 weeks of gestation but some, like the theca lutein cysts, can persist until after delivery. Masses still present after 16 weeks of gestation are predominantly non-functional (Chiang and Levine, 2004; Leiserowitz, 2006; Glanc et al., 2008; Hoffman, 2014).

Endometriomas can have a strongly changed appearance during pregnancy because of decidualized walls due to high levels of progesterone in pregnancy. A previous history of symptoms of endometriosis can be indicative. However, when the diagnosis remains uncertain further investigation is advised to rule out a malignant neoplasm (Glanc et al., 2008; Patel et al., 1999).

## Imaging

### Ultrasound

As stated above, most of the adnexal masses during pregnancy will be discovered as an incidental finding on routine obstetrical ultrasound. Ultrasound is the most common diagnostic tool to evaluate pelvic and abdominal pain during pregnancy since it is safe to use (Leiserowitz, 2006). Its high sensitivity and specificity to characterize the morphology of pelvic masses make it an ideal tool to use as a first choice diagnostic tool since morphology is the most important determinant in distinguishing benign masses from malignancies (Usui et al., 2000; Telischak et al., 2008; Hoover and Jenkins, 2011; Cohen-Herriou et al., 2013; Levine, 2014). The specific sonographic characteristics of the most

common benign adnexal masses in pregnancy are enlisted in Table I.

Different algorithms exist to differentiate between benign and malignant tumours or to stratify the risk of malignancy using elements such as tumour size, morphology and colour Doppler flow (Bernhard et al., 1999; Leiserowitz, 2006; Glanc et al., 2008; Telischak et al., 2008).

The IOTA (International Ovarian Tumor Analysis) studies are established to develop rules and models to characterize ovarian pathology and to demonstrate their utility in the hands of examiners with different levels of ultrasound expertise. The 'simple rules' can be used to classify 75% of all ovarian masses (Table II, Timmerman et al., 2010). Logistic Regression Model 1 and 2 (LR 1 and 2) were developed and externally validated to assess whether they work in different patient populations and in different clinical settings (phase 2 of the IOTA project). Both models also show high sensitivity and specificity in pre- and postmenopausal women however, there is no evidence of the usefulness in our specific patient population, e.g. pregnant women (Kaijser et al., 2014). Nevertheless, we do believe that these models are also useful during pregnancy.

### MRI

Magnetic resonance imaging (MRI) can be safely used during the second and third trimester of pregnancy, although the use of gadolinium-based contrast material should be avoided because fetal

**Table II.** — IOTA simple rules. Adjusted from Timmerman et al., 2010.

Ultrasonic features
<b>For predicting a malignant tumor (M features)</b>
M1 – Irregular solid tumor
M2 – Presence of ascites
M3 – At least four papillary structures
M4 – Irregular multilocular solid tumor with largest diameter $\geq$ 100 mm
M5 – Very strong blood flow (colour score 4)
<b>For predicting a benign tumor (B features)</b>
B1 – Unilocular
B2 – Presence of solid components, of which largest solid component has largest diameter $<$ 7 mm
B3 – Presence of acoustic shadows
B4 – Smooth multilocular tumor with largest diameter $<$ 100 mm
B5 – No blood flow (colour score 1)
Rule 1: If one or more M features are present in absence of B feature, mass is classified as malignant.
Rule 2: If one or more B features are present in absence of M feature, mass is classified as benign.
Rule 3: If both M features and B features are present, or if no B or M features are present, result is inconclusive and second stage test is recommended.

safety has not been established. MRI is particularly useful in making 3-dimensional images, distinguishing between different morphologic characteristics like bone of muscular tissue, e.g. leiomyomas, endometriomas and complex masses with solid compounds (Runowicz and Brewer, 2004; Leiserowitz, 2006; Telischak et al., 2008).

Although MRI can provide valuable diagnostic information beyond the ability of ultrasound, the use of MRI is only advised when ultrasound diagnosis is uncertain, masses are too big to fully assess by ultrasound or when there is a high probability of malignancy to evaluate possible extra-ovarian spread (Glanc et al., 2008; Hoover and Jenkins, 2011; Leiserowitz, 2006). It is also important to keep in mind that even though imaging by ultrasound and, in additional cases, by MRI have a high sensitivity and specificity pathologic examination only will reveal the true nature of the mass.

### **Tumour markers**

The reliability of tumour markers in the diagnosis and characterization of tumours during pregnancy is often debated. During pregnancy elevations of tumour markers are mostly associated with the normal physiologic changes of pregnancy and presence of obstetric complications (miscarriage, preeclampsia, HELLP) (Han et al., 2012). When an ovarian mass is diagnosed in pregnancy, CA-125 levels may help to distinguish between a benign or malign lesion and can be used to evaluate treatment (Giuntoli et al., 2006; Leiserowitz, 2006). However, decidua- and amnion cells also produce CA-125 resulting in higher CA-125 levels during pregnancy especially in the first and third trimester (respectively because of trophoblast invasion and detachment of the placenta). Tumour markers associated with germ cell tumours (e.g. AFP and b-hCG) and granulosa-cell tumours (Inhibine B and AMH) can also be elevated in normal pregnancy and can therefore only be used as follow-up (Leiserowitz, 2006).

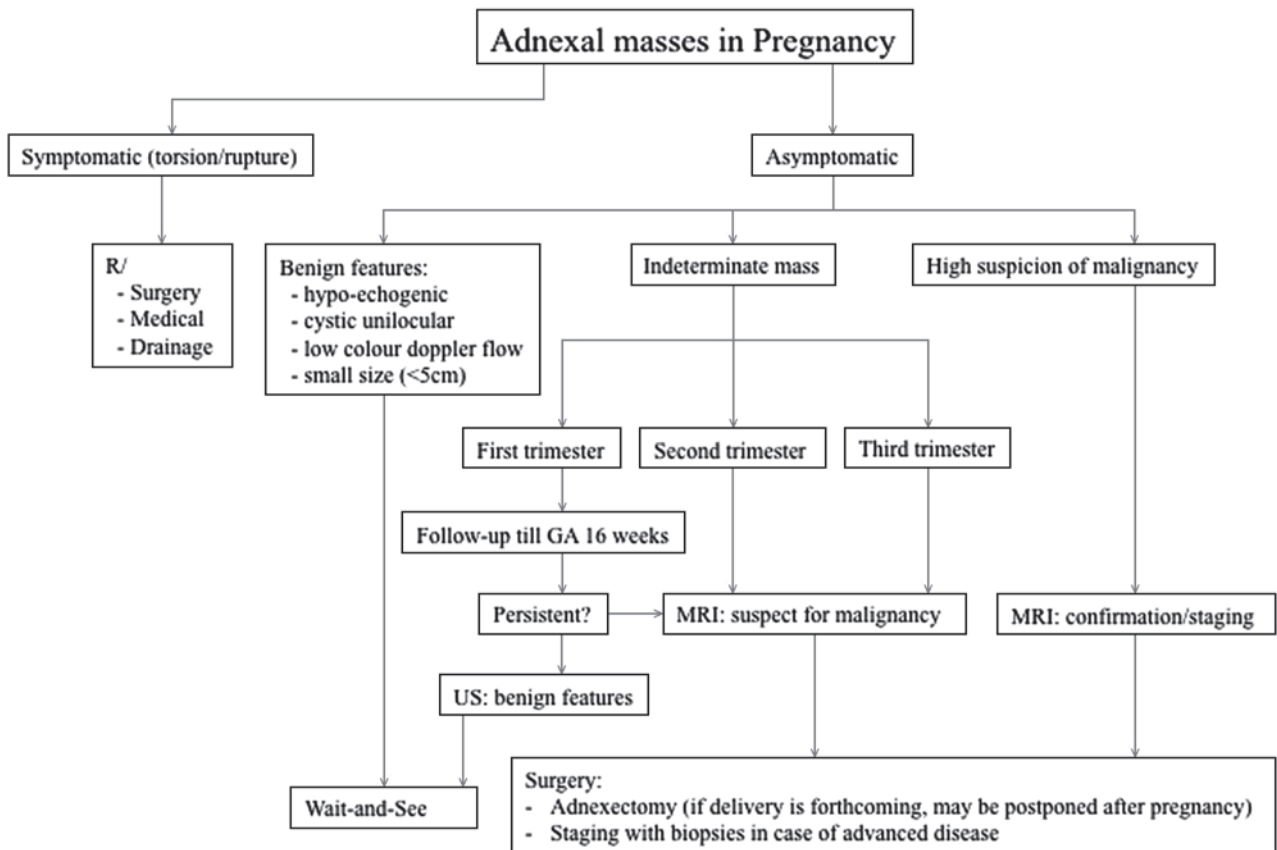
### **Surgery during pregnancy (open vs laparoscopy)**

An asymptomatic adnexal mass presenting as a simple cyst of five centimetre or smaller or a cyst with unequivocal benign features as stated above is very likely to resolve by itself and no further follow-up or treatment during pregnancy is necessary. Patients with asymptomatic cysts over five centimetres or with a less reassuring appearance must be reviewed after 16 weeks of pregnancy. If these cysts are persistent, further follow-up is advised to determine the need for surgical exploration

(Whitecar et al., 1999; Leiserowitz, 2006; Glanc et al., 2008). The clinician needs to make a careful decision when to operate since both too early (risk of miscarriage and loss of luteal function before the fourth month of pregnancy) and too late (complications as torsion, rupture or bleeding, progression in case of malignancy, premature labour) can affect the patient and fetus. Retrospective reviews assessing the outcome of adnexal masses following conservative management show higher fetal morbidity and mortality as well as the risk of spillage by spontaneous rupture. Para-ovarian lesions are likely to be benign and do not require intervention in pregnancy (Glanc et al., 2008). Figure 1 presents a flowchart to aid the decision-making for optimal management of an adnexal mass during pregnancy.

A midline laparotomy with minimal uterine manipulation is preferred in case of an open approach. Laparoscopy is safe and feasible when specific guidelines are followed. Laparoscopic management should be optimally scheduled between 16 and 20 weeks of gestation, based on the time allowed for spontaneous resolution, the optimized visualisation of the mass in contrast with the enlarged uterus, and the decreased ratio of premature labour (Amant et al., 2010; Hoover and Jenkins, 2011). Important to consider is the position of the patient to avoid hypovolemia, hypotension and hypoxemia by the slowly change to Trendelenburg allowing only mild inclination, and from 20 weeks of gestation onwards, using the left lateral tilt position. The preferred method for primary trocar insertion should be the open laparoscopy and supra-umbilical port placement to limit the possibility of uterine perforation by insertion of a Veress needle. The CO<sub>2</sub> pneumo-peritoneum and CO production during electrocoagulation do not seem to be detrimental to the fetus when a maximum pressure of 10-13 mmHg, an experienced surgeon and limited operation time is considered (Han et al., 2014; Ko et al., 2009). The fetus is surrounded by amniotic fluid that absorbs the electrical current. Next to these preventive measures in case of laparoscopic procedures during pregnancy, general guidelines for surgery during pregnancy need to be considered. Maternal and fetal heart monitoring, thrombosis and antibiotic prophylaxis, knowledge of the (side-) effects of the anaesthetic drugs and in selective cases the use of corticoids should be considered (Jackson et al., 2008; Amant et al., 2010).

Data on the use of tocolytic drugs are not available. Therefore it is recommended to use them in case of uterine manipulation, which is present during surgery for ovarian masses (Amant et al., 2014). Mathevet et al. (2003) reported on 48 cases treated with laparoscopy during first (n = 17),



*Fig. 1.* — Flow-chart: Management of adnexal masses in pregnancy.  
Abbreviations: US = Ultrasound; GA = Gestational Age; MRI = Magnetic Resonance Imaging.

second (n = 27) and third trimester (n = 4) for ovarian torsion, rupture of a cyst or the removal of persisting, suspicious or undetermined masses. The results show minimal risk for both the mother and fetus considering the possible technical problems and correct approach by the surgeon and specialized team.

### Early stage ovarian cancer (borderline and invasive)

The incidence of a malignant adnexal mass during pregnancy is reported between four and eight in 100000 pregnancies (Amant et al., 2010). Most frequently reported are the non-epithelial tumours (germ-cell and sex-cord) followed by ovarian tumours of low malignant potential (LMP, e.g. borderline tumours) and epithelial ovarian cancers (Morice et al., 2012). As stated above, diagnosis is usually made by routine prenatal ultrasound examination. The presence of ascites, peritoneal seeding or an omental cake indicates advanced disease. Of all malignant tumours of the ovary ten percent are metastases of other organs, mainly gastrointestinal or breast tumours. They are usually

solid and bilateral (Glanc et al., 2008). When the probability of malignancy is high or if there is a high risk of developing complications (rupture, torsion) surgery is indicated.

For early stage ovarian cancer, stage I and II according to the International Federation of Gynecology and Obstetrics (FIGO), standard surgical procedure consisting of hysterectomy, bilateral adnexectomy, omentectomy, cytology, biopsies and lymphadenectomy should be aimed for (Prat J and FIGO Committee on Gynecologic Oncology, 2014). For early stage disease, fertility- and pregnancy preserving treatment may be considered. In these selected cases surgery includes removal of the adnex and surgical staging (cytology, peritoneal biopsies, omentectomy and appendectomy in mucinous tumours). In unilateral borderline tumours, a laparoscopic procedure without spilling is possible. For invasive epithelial ovarian carcinoma, grade I and diagnosed at FIGO stage Ia, fertility- and pregnancy preserving management can also be performed (Prat J and FIGO Committee on Gynecologic Oncology, 2014). Restaging after delivery may be considered because of occult extra-ovarian disease, which may not be assessed adequately during



pregnancy (Amant et al., 2010; Morice et al., 2012). Non-epithelial tumours (germ-cell and sex-cord stromal tumours), which frequently present as bulky masses, are over 90% diagnosed at FIGO stage Ia and therefore are also treated by a resection and surgical staging (Mancari et al., 2014). For high-grade stage I and any stage II disease, standard adjuvant chemotherapy (carboplatin-paclitaxel) can be considered.

### Advanced stage ovarian cancer (borderline and invasive)

When there is a high probability of advanced stage ovarian cancer, further imaging besides ultrasound is required to evaluate the stage. As stated above, in pregnant women the use of MRI after the first trimester is considered safe and allows accurate evaluation of the mass and its possible spread. In case of higher stage disease in borderline tumours, adnexectomy/biopsy during pregnancy is aimed for, followed by completion of surgery after delivery. Since chemotherapy is not effective for borderline disease and given the indolent nature, an otherwise conservative approach during pregnancy is advised. Similar, the performance of complete cytoreductive surgery for advanced stage invasive (FIGO stage III) ovarian cancer is not possible during pregnancy. In most reported cases of advanced invasive disease, patients chose to terminate pregnancy when diagnosis has been made early in the first trimester of pregnancy (Mancari et al., 2014). When the patient wants to proceed the pregnancy, neoadjuvant chemotherapy (carboplatin and paclitaxel) until fetal maturity and complete cytoreductive surgery after delivery is recommended from midpregnancy onwards (Amant et al., 2014). However, experience is limited and the proposed approach still has an experimental character. A vaginal delivery is aimed for.

### Conclusion

Ovarian cysts or masses during pregnancy should be accurately evaluated to decide the most appropriate treatment option. Ultrasound and MRI are safe and allow distinguishing between benign and malignant lesions. A wait-and-see strategy is advised for an ovarian cyst with benign features. Masses with septa, solid components, papillae or nodules, or when persisting after 16 weeks of pregnancy should be further investigated. Treatment options including surgical procedures should be discussed for each patient individually. Both open surgery and laparoscopy can be performed considering the tumour diameter, gestational age and

surgical expertise. When advanced stage invasive ovarian cancer is diagnosed, termination of pregnancy may be considered in early pregnancy, otherwise chemotherapy can be administered during second and third trimester. When there is high suspicion of malignancy, a multidisciplinary approach is necessary, and preferably patients should be referred to centres with specialized experience.

### Acknowledgements

MV is a clinical researcher of the Research Fund Flanders (F.W.O.) FA is a senior clinical investigator of the Research Fund Flanders (F.W.O.).

### References

- Amant F, Brepoels L, Halaska MJ et al. Gynaecologic cancer complicating pregnancy: an overview. *Best Pract Res Clin Obstet Gynaecol.* 2010;24:61-79.
- Amant F, Halaska MJ, Fumagalli M et al. Gynecologic cancers in pregnancy: guidelines of a second international consensus meeting. *Int J Gynecol Cancer.* 2014;24:394-403.
- Bernhard LM, Klebba PK, Gray DL et al. Predictors of persistence of adnexal masses in pregnancy. *Obstet Gynecol.* 1999;93:585-9.
- Chiang G, Levine D. Imaging of adnexal masses in pregnancy. *J. Ultrasound Med.* 2004;23:805-19.
- Cohen-Herriou K, Semal-Michel S, Lucot JP et al. Management of ovarian cysts during pregnancy: Lille's experience and literature review. *Gynecol Obstet Fertil.* 2013;41:67-72.
- Giuntoli RL 2<sup>nd</sup>, Vang RS, Bristow RE. Evaluation and management of adnexal masses during pregnancy. *Clin Obstet Gynecol.* 2006;49:492-505.
- Glanc P, Salem S, Farine D. Adnexal masses in the pregnant patient: a diagnostic and management challenge. *Ultrasound Q.* 2008;24:225-40.
- Han SN, Lotgerink A, Gziri MM et al. Physiologic variations of serum tumor markers in gynaecological malignancies during pregnancy: a systematic review. *BMC Med.* 2012;10:86.
- Han SN, Verheecke M, Vandenbroucke T et al. Management of gynaecological cancers during pregnancy. *Curr Oncol Rep.* 2014;16:415.
- Hoffman MS. Differential diagnosis of the adnexal mass. In: Barbieir RL (Ed), *UpToDate* (Accessed on February 26<sup>th</sup>, 2015).
- Hoover K, Jenkins TR. Evaluation and management of adnexal mass in pregnancy. *Am J Obstet Gynecol.* 2011;205:97-102.
- Jackson H, Granger S, Price R et al. Diagnosis and laparoscopic treatment of surgical diseases during pregnancy: an evidence-based review. *Surg Endosc.* 2008;22:1917-27.
- Kaijser J, Sayasneh A, Van Hoorde K et al. Presurgical diagnosis of adnexal tumours using mathematical models and scoring systems: a systematic review and meta-analysis. *Hum Reprod Update.* 2014;20:449-62.
- Ko ML, Lai TH, Chen SC. Laparoscopic management of complicated adnexal masses in the first trimester of pregnancy. *Fertil Steril.* 2009;92:283-7.
- Leiserowitz G. Managing ovarian masses during pregnancy. *Obstet Gynecol Surv.* 2006;61:463-70.
- Levine D. Sonographic differentiation of benign versus malignant adnexal masses. In: Barbieir RL (Ed), *UpToDate* (Accessed on February 26<sup>th</sup>, 2015).
- Mancari R, Tomasi-Cont N, Sarno MA et al. Treatment options for pregnant women with ovarian tumors. *Int J Gynecol Cancer.* 2014;24:967-72.
- Mathevet P, Nessah K, Darget D et al. Laparoscopic management of adnexal masses in pregnancy; a case series. *Eur J Obstet Gynecol Reprod Biol.* 2003;108:217-22.

- Morice P, Uzan C, Gouy S et al. Gynaecological cancers in pregnancy. *Lancet*. 2012;379:558-69.
- Parsons AK. Imaging the human corpus luteum. *J. Ultrasound Med*. 2001;20:811-9.
- Patel MD, Feldstein VA, Chen DC et al. Endometriomas: diagnostic performance of US. *Radiology*. 1999;210:739-45.
- Patel MD, Feldstein VA, Filly RA. The likelihood ratio of sonographic findings for the diagnosis of hemorrhagic ovarian cysts. *J. Ultrasound Med*. 2005;24:607-14.
- Patel MD, Feldstein VA, Lipson SD et al. Cystic teratomas of the ovary: diagnostic value of sonography. *Am J Roentgenol*. 1998;171:1061-5.
- Prat J, FIGO Committee on Gynecologic Oncology. Staging classification for cancer of the ovary, fallopian tube, and peritoneum. *Int J Gynaecol Obstet*. 2014;124:1-5.
- Runowicz CD, Brewer M. Adnexal mass in pregnancy. In: Barbier RL (Ed), *UpToDate* (Accessed on February 26<sup>th</sup>, 2015).
- Telischak NA, Yeh BM, Joe BN et al. MRI of adnexal masses in pregnancy. *AJR AM J Roentgenol*. 2008;191:364-70.
- Timmerman D, Ameye L, Fischerova D et al. Simple ultrasound rules to distinguish between benign and malignant adnexal masses before surgery: prospective validation by IOTA group. *BMJ*. 2010;14:341
- Usui R, Minakami H, Kosuge S et al. A retrospective survey of clinical, pathologic, and prognostic features of adnexal masses operated on during pregnancy. *J Obstet Gynaecol Res*. 2000;26:89-93.
- Whitecar MP, Turner S, Higby MK. Adnexal masses in pregnancy: a review of 130 cases undergoing surgical management. *Am J Obstet Gynecol*. 1999;181:19-24.