

FACTS, VIEWS & VISION

Journal of the European Society for Gynaecological Endoscopy (ESGE)

inObGyn

Volume 14 – Number 3 – September 2022 – QUARTERLY

Supplement 1

OFFICIAL ABSTRACTS PUBLICATION

of the ESGE 31st Annual Congress

2nd – 5th October – Lisbon, Portugal

ESGE 31ST ANNUAL CONGRESS

2nd–5th October 2022 · Lisbon · Portugal

Excellence is a habit!
Gynaecological endoscopy at its best



www.esgecongress.eu

BEST SELECTED ABSTRACTS ORAL

ES31-0325 -

Best Selected Abstracts

Levonorgestrel releasing intrauterine device versus endometrial ablation in women with heavy menstrual bleeding: the follow-up of a multicentre randomized controlled trial

Arianne Derickx¹, Pleun Beelen¹, Peggy Geomini¹, Marlies Bongers¹

¹Máxima Medical Centre, Gynaecology, Eindhoven, The Netherlands

Background

Menorrhagia is a condition affecting a lot of premenopausal women in their daily life, physical activity, sexuality and often impairs the quality of life. Studies showed the levonorgestrel-releasing intrauterine system (LNG-IUS; Mirena) to be superior in treatment of heavy menstrual bleeding compared to oral medication. Studies comparing the LNG-IUS with Endometrial Ablation (EA) however were inconclusive for a long time. For this reason, in 2012 a multicentre randomized controlled trial was performed about the effectiveness of LNG-IUS versus EA in women with heavy menstrual bleeding. Long-term results between both treatment options however remain unknown. This long-term follow-up study aims to compare the effectiveness of both treatments after 10 years.

Methods

In the original RCT, 270 women with heavy menstrual bleeding from 26 hospitals and general practices in the Netherlands, were randomly allocated to receive either a LNG-IUS/Mirena (n=132) or EA/Novasure (n=138). All women that participated were contacted again, between 7 to 10 years after inclusion. Primary outcomes were blood loss and menstrual pattern (spotting, amenorrhea, dysmenorrhea), measured via the Pictorial Blood Loss Assessment Chart (PBAC). Secondary outcomes were patient satisfaction, reintervention rates, quality of life, and sexual function.

Results

84 women allocated to the LNG-IUS group completed the PBAC and 74 responded to the questionnaires, versus 88 and 89 respectively in the EA group. After an average of 7.5 years after inclusion, mean PBAC scores were zero in both treatment groups, and no differences were seen in menstrual patterns. A total of 53 women (72%) in the LNG-IUS group were satisfied with the treatment versus 74 women (85%) in the EA group, indicating a slightly significant difference in favour of EA (relative risk 0.84; 95% confidence interval 0.712-0.99). Compared with 53 women (54%) in the LNG-IUD group, 35 women (36%) in the EA group required a reintervention (relative risk 1.48; 95% confidence interval 1.08-2.05). A significant difference was seen in surgical reintervention rate in favour of EA (21 women, 22%), compared to LNG-IUS (43 women, 43%) (relative risk 2,01; 95% confidence interval 1.29-3.12). No differences were seen in quality of life and sexual function.

Conclusions

After long-term follow up, no differences are notable on menstrual patterns, quality of life and sexual function between the LNG-IUS and EA in women with heavy menstrual bleeding. However, women treated with an LNG-IUS have an increased risk of requiring additional treatment, and are slightly less satisfied compared to women treated with EA. The results of this follow-up study will help gynaecologists and patients to make a well-informed choice between on one hand the advantages of the less invasive and reversible character of the LNG-IUS, and on the other hand the advantages in patient satisfaction and reintervention rate of EA this study showed.

**ES31-0284 -
Best Selected Abstracts**

Mobile wireless gynecological endoscopy: hysteroscopy-laparoscopy-cystoscopy

Ioannis Chatzipapas¹, Nikolaos Kathopoulos¹, Athanasios Protopapas¹

¹Hellenic Society of Gynecological Endoscopy, Endoscopy, Athens, Greece

Background

Hysteroscopy, Laparoscopy and Cystoscopy (HyLaCy) have undergone significant advances in the field of gynecology over the past 50 years. Wireless signal transmission is the future of endoscopy regarding diagnostic and surgical treatment. Cable-free endoscopic equipment would be the ideal surgical instrument for every gynecologist.

Methods

We present a new HyLaCy setup using a modified action camera that joins to a c-mount adapter of 18-35mm and a portable led light source. The signal was wirelessly transmitted from the camera to a tablet computer using the corresponding mobile application. The new portable endoscopic viewing system cost is considerably lower than a typical endoscopic tower.

Results

Our team has used this setup in several diagnostics and operative procedures with excellent results. The image quality and resolution have been similar to a standard laparoscopic setup. Operations were completed without any intraoperative complications, and surgeons were satisfied with the visibility of the operative field. Surgeons also stated that they had no difficulty performing the operation with the new setup compared with the standard laparoscopic tower. The image quality obtained was comparable with the conventional laparoscopic setup. There were no postoperative complications, and patients were released from hospital the day after the operation.

Conclusions

This is the first report on the application of mobile technology used to facilitate HyLaCy operations. The new system favourable characteristics, such as wireless signal transmission, cost, flexibility, and size, support this as a feasible new technique for performing HyLaCy surgery.

**ES31-0248 -
Best Selected Abstracts**

Role of artificial neural networks in the sonographic diagnosis of uterine adenomyosis

Anna Chiara Aru¹, Diego Raimondo¹, Antonio Raffone¹, Lucia Lazzeri², Paolo Casadio¹, Renato Seracchioli¹

¹Sant'Orsola Hospital - University of Bologna, Gynecology and Human Reproduction Physiopathology, Bologna, Italy

²University of Siena, Department of Molecular & Developmental Medicine, Siena, Italy

Background

adenomyosis is a common benign gynaecological condition. Transvaginal ultrasound (TVUS) should be considered the primary imaging modality, since it is an accurate, low cost and easily accessible method. However, its diagnostic performance depends on the experience of the operator. Recently, deep learning (DL) based on artificial neural networks with representation learning has been adopted to help operators to untangle among differential diagnoses. The aim of this study is to first evaluate the performance of DL machine in the diagnosis of adenomyosis on uterine ultrasonographic images and compare it to diagnostic performance of intermediate ultrasound skilled trainees.

Methods

this is a prospective study performed in a tertiary referral academic centre for pelvic pain and endometriosis. TVUS was performed on consecutive eligible fertile-age patients giving consent to the study protocol who referred to our Unit between 1st and 30th April 2022. All ultrasounds were performed by an experienced sonographer, using the same ultrasound machine. Longitudinal scans of the uterine corpus were recorded in videoclips, and sequential ultrasound images were extracted by an automatic system. Adenomyosis was diagnosed only in presence of at least two ultrasonographic criteria according to the revised MUSA criteria. Thereafter, three intermediate ultrasound skilled trainees (>500 gynaecological ultrasound scans performed) blinded to clinical data were asked separately to make a diagnosis, only reviewing videoclips. Ultrasound images were used for the construction, validation, and testing of the DL system (Vgg13, Vgg19, ResNet 18 and ResNet 34). To reduce over-fitting, data augmentation and early stopping were applied. The primary outcome was to evaluate the accuracy in diagnosing adenomyosis of the DL model; secondarily, we compare several metrics (accuracy, sensibility, specificity) between DL model and subjective assessment of the trainee with the best performance.

Results

one-hundred patients were enrolled. The senior consultant made diagnosis of 45 uteruses with homogeneous myometrial echogenicity, 30 with multiple fibroids and 25 with adenomyosis. Ultrasonographic images per different type of uterus at TVUS (regular, fibromatosis, adenomyosis) were included in a random but balanced way in three sets: n=1645, n=1071, n=836 in the training set, n=481, n=336, n=252 in the validation set and n=495, n=359, n=336 in the testing set, respectively. Accuracy, sensitivity and specificity in diagnosing adenomyosis was 0.70, 0.72 and 0.69 for intermediate skilled trainees, and 0.51, 0.43 and 0.82 for DL model, respectively.

Conclusions

in this preliminary study DL model showed a lower accuracy but a higher specificity in diagnosing adenomyosis on ultrasonographic images compared to intermediate skilled trainees. More data are needed to confirm our findings and evaluate the role of DL in this setting.

**ES31-0093 -
Best Selected Abstracts**

Laparoscopic gynecological surgery under minimally invasive anesthesia: a prospective cohort study.

*Luigi Della Corte¹, Antonio Mercorio¹, Mario Palumbo¹, Paolo Serafino¹, Francesco Viciglione¹,
Pierluigi Giampaolino²*

¹*University of Naples Federico II, Department of Neuroscience- Reproductive Sciences and Dentistry, Naples, Italy*

²*University of Naples Federico II, Department of Public Health, Naples, Italy*

Background

In the minimally invasive era, laparoscopic gynaecological surgery is currently performed under general anaesthesia (GA), which although considered a safe technique, is accountable for different adverse effects and delayed recovery. Regional anaesthesia (RA) from an anaesthesiology perspective could be considered the “minimally invasive technique”. Aim of this study was to assess the feasibility and the perioperative outcomes of laparoscopic gynaecological surgery in regional anaesthesia from the point of view of the surgeon, anaesthesiologist and patient.

Methods

This was a prospective cohort study comprising sixty-six women planned to undergo gynaecologic laparoscopy surgery for benign pathology at University of Naples Federico II from January 2020 to April 2021. Women were assigned to either RA (Group A) or GA (Group B) based on patient's choice. The primary outcomes were the evaluation of postoperative pain, nausea and vomiting (PONV) and the antiemetic/analgesic intake. Postoperative surgical and anaesthesiologic variables were recorded.

Results

Duration of surgery were comparable between the two groups and no conversion to GA was required. Immediate postoperative pain was significantly lower in Group A [0 (0-0.8) vs 2 (1-5), $p<0.001$], also at 6 h [1.5 (0-2.8) vs 3 (1-5), $p=0.004$] with no statistically significant differences between the two groups at 24 h. A faster resumption of bowel motility ($p<0.001$) and patient's mobilization ($p<0.001$) were observed in the Group A. Early discharge and greater patient's satisfaction were recorded in patients who underwent RA. Intraoperatively pain score on a Likert scale during all the stages of laparoscopy in RA was assessed with a maximum score of 3 points.

Conclusions

RA showed to decrease the impact of surgical stress and to guarantee a quicker recovery without compromising surgical results. As well as different surgical approaches can be selected to treat different pathologies, RA technique could be a viable option for patients.

**ES31-0240 -
Best Selected Abstracts**

Trends of surgical routes for benign hysterectomy in morbidly and super morbidly obese patients in the United States

Giuseppe Cucinella¹, Andrea Mariani¹, Mansi Mathur², Yuki Liu², Yanli Li², Carrie Langstraat¹

¹Mayo Clinic, Department of Obstetrics and Gynecology, Rochester- MN, USA

²Intuitive Surgical Inc, Global Health Economics and Outcomes Research-, Sunnyvale- California, USA

Background

To analyse the surgical approach trends by obesity status among women undergoing hysterectomy for benign indications in the United States.

Methods

A retrospective analysis of adult (≥ 18 years) obese patients who underwent elective benign hysterectomy in the United States using Premier Healthcare Database* (representing ~25% of annual U.S. hospitals based on >10 million inpatient discharges and 93 million outpatient visits) between 2013 and 2020. Patients were identified using primary ICD9/10 for inpatient and CPT codes for outpatient settings. Patients with obstetric procedures, missing or extreme OR time & costs (<1st and > 99th percentile) were excluded. Proportions of patients who received open (OH), vaginal (VH), laparoscopic (LH) and robotic assisted (RH) hysterectomies were evaluated. The patients were stratified according to body mass index (BMI) and categorized as not obese or unknown; class I & II obesity (BMI 30-39.9 kg/m²); class III obesity (morbid obesity: 40-49.9 kg/m² and super morbid obesity: >50 kg/m²).

Results

Among 646,949 hysterectomies identified, 35% and 31% were LH and RH, respectively, followed by 21% OH and 13% VH. Seventeen percent of the patients undergoing hysterectomy had a BMI ≥ 30 kg/m²: 9.5% obese I&II, 6.5% morbidly obese and 1% super morbidly obese. The proportion of morbidly obese patients undergoing benign hysterectomy has steadily increased from 6% to 10% over the study period. Between 2013 and 2020, we observed an increase in minimally invasive hysterectomy while also observing a steady decrease in OH (Table 1). Specifically, we saw an increase in RH in patients with morbid obesity (32 vs. 40%) and super morbid obesity (39% vs. 44%) (Table1). We observed that robotic-assisted surgery becomes the surgical approach of choice with the increase in the patient BMI status: not obese or unknown (34%), obese I&II (38%), morbidly obese (40%), and super morbidly obese (44%). Approximately 70% of all benign hysterectomies in 2017 to 2019 were performed in the outpatient setting. RH represented 48% and 55% of outpatient hysterectomy in morbidly and super morbidly obese patients.

Table1: Trends of surgical routes in morbidly obese and super morbidly obese patients

	2013	2014	2015	2016	2017	2018	2019	2020
<i>Class III obesity: N (%)</i>								
	4771 (6%)	5167 (6%)	5813 (7%)	6387 (8%)	6892 (8%)	7290 (9%)	7941 (10%)	6304 (10%)
<i>Hospital Outpatient: N (%)</i>								
	1949 (41%)	2430 (47%)	3059 (53%)	3742 (59%)	4353 (63%)	5023 (69%)	5811 (73%)	4821 (77%)
<i>Morbid obesity: N (%)</i>								
Open	1310 (33%)	1412 (33%)	1563 (32%)	1569 (30%)	1559 (27%)	1412 (23%)	1266 (19%)	891 (17%)
Vaginal	316 (8%)	335 (8%)	405 (8%)	404 (8%)	433 (7%)	380 (6%)	422 (6%)	284 (5%)
Laparoscopic	1109 (28%)	1237 (29%)	1416 (29%)	1723 (32%)	1864 (32%)	2027 (34%)	2339 (35%)	1983 (38%)
Robotic	1264 (32%)	1335 (31%)	1468 (30%)	1607 (30%)	1925 (33%)	2212 (37%)	2625 (39%)	2080 (40%)
<i>Super morbid obesity: N (%)</i>								
Open	245 (32%)	311 (37%)	307 (32%)	310 (29%)	254 (23%)	249 (20%)	276 (21%)	197 (18%)
Vaginal	61 (8%)	42 (5%)	47 (5%)	71 (7%)	54 (5%)	71 (6%)	53 (4%)	60 (6%)
Laparoscopic	163 (21%)	180 (21%)	218 (23%)	297 (27%)	345 (31%)	375 (30%)	398 (31%)	342 (32%)
Robotic	303 (39%)	315 (37%)	389 (40%)	406 (37%)	458 (41%)	564 (45%)	562 (44%)	467 (44%)
<i>Perioperative 30 days cost: 2020 US\$</i>								
Median Cost	\$8,778	\$8,885	\$8,830	\$9,007	\$9,070	\$8,966	\$8,726	\$9,169

Conclusions

A minimally invasive surgery has become the preferred approach for patients in the US with Class III obesity who are undergoing hysterectomy for benign indications. During the time period studied rates of both RH and LH increased. Adoption of RH may have facilitated this widespread adoption, especially among patients with BMI \geq 50 kg/m². The RH may be responsible of the most recent outpatient setting increase without increasing the overall healthcare utilization costs.

**ES31-0345 -
Best Selected Abstracts**

Post-caesarean urinoma in a patient with previous excision of a vesicouterine endometriotic nodule

Margarida Cal¹, Natacha Sousa², João Sequeira Alves³, Sónia Barata³, Filipa Osório³

¹Hospital de Santa Maria- Centro Hospitalar Universitário Lisboa Norte, Obstetrics- Gynaecology and Reproductive Medicine, Lisboa, Portugal

²Hospital de Braga, Obstetrics and Gynaecology, Braga, Portugal

³Hospital da Luz Lisboa, Obstetrics and Gynaecology, Lisbon, Portugal

Background

We aimed to present a possible post-operative complication after a caesarean section in a patient with previous laparoscopic excision of an endometriotic vesicouterine nodule, and to demonstrate how it can be safely managed by minimally invasive surgery.

Methods

We present a stepwise demonstration of the laparoscopic surgery with narrated video footage.

Results

This video reports a case of a post-operative complication following a caesarean section performed in a patient with deep infiltrating endometriosis (DIE) and a previous laparoscopic surgery for excision of a vesicouterine endometriotic nodule. The patient presented to the emergency department ten days after the caesarean section, with complaints of abdominal distension and bloating. On examination, she presented with a distended abdomen with a positive fluid wave test. A CT scan with contrast was performed, which revealed a voluminous ascites and was suggestive of bladder wall rupture. Therefore, an exploratory laparoscopy was performed, and the bladder wall defect was identified and corrected.

Interventions: An exploratory laparoscopic surgery was performed and confirmed the presence of a voluminous urinoma with approximately 6.5 liters of urine within the pelvic and abdominal cavity. The key steps from the surgery were:

1. Aspiration of urine ascites and excision of multiple fibrinous adhesions.
2. Identification of the dehiscence of the posterior vesical wall, with an opening of approximately 5 centimetres in diameter.
3. Reconstruction of the vesicouterine space and closure of the vesical wall with a double-layered absorbable suture.
4. No post-operatively complications were reported, and vesical catheterization was removed after 15 days.

Conclusions

In this video, we demonstrate a possible complication following a caesarean section in a patient with a previous surgery for DIE with excision of a vesicouterine nodule and its management by a minimally invasive laparoscopic approach.

**ES31-0313 -
Best Selected Abstracts**

Safety and medium-term outcome of redo sacrocolpopexy: a matched-control study

Emma Bauters¹, Ann-Sophie Page¹, Laura Cattani¹, Susanne Housmans¹, André D'Hoore², Jan Deprest¹

¹*University Hospitals Leuven, Department of Obstetrics and Gynecology, Leuven, Belgium*

²*University Hospitals Leuven, Department of Abdominal Surgery, Leuven, Belgium*

Background

To assess whether a redo laparoscopic sacrocolpopexy (LSCP) has a higher complication rate and similar medium-term outcome when compared to a primary LSCP.

Methods

This is a single-centre matched-control study comparing 39 women who had a redo LSCP (cases) and 156 women who had a primary LSCP (controls) for symptomatic prolapse (Pelvic Organ Prolapse Quantification [POP-Q] system stage 2 or greater) between 1997 and 2020 at a tertiary centre, all part of a permanent audit study. Each case was matched with four controls, which were the closest primary cases on the operation list. The primary outcome was the occurrence of intraoperative and early (within three months after surgery) postoperative complications, which were graded according to Clavien & Dindo. Secondary outcomes included operative data (total surgery time, duration of adhesiolysis, estimated blood loss and conversion nature and rate), any complications beyond 3 months, Patients' Global Impression of Change (PGIC) score and POP-Q score both at the postoperative (6 weeks) and last available visit. Clinical assessment was done by an independent clinician, i.e., not involved in the surgery nor clinical management of the patient. This study was approved by the local ethics committee (B322202042753) and prospectively registered on Clinicaltrials.gov (NCT04378400).

Results

The intraoperative and early postoperative complication rates did not differ between groups (primary: 41.0% vs redo: 30.6%, $p=0.25$). The most frequent intraoperative complication was an operation time longer than 240 minutes (which was the 75th percentile in this cohort). Early complications were infectious and managed by antibiotics (Dindo II). Except for a higher need for intraoperative conversion in the redo group (primary: 0.6 vs redo: 7.7%, OR 12.9, 95% CI 1.3 to 127.8), there were no significant differences in terms of operative variables between cases and controls. Median follow-up time was 71.5 months (IQR: 42) in the primary LSCP group and 81 months (IQR: 54) in the redo LSCP group. Patients who underwent a redo LSCP were not more likely to develop a graft related complication (primary: 9.6% vs redo: 18.0%, $p=0.141$) nor to have a reintervention for a complication (primary: 12.8% vs redo: 5.8%, $p=0.161$) or prolapse (primary: 8.3% vs redo: 18.0%, $p=0.077$). Both subjective and objective outcomes did not differ significantly between groups.

Conclusions

In this cohort, redo LSCP is as safe as a primary LSCP and has comparable subjective and objective outcomes in the medium-term.

**ES31-0128 -
Best Selected Abstracts**

Long-term follow-up after laparoscopic cervicosacropexy or colposacropexy in a large teaching gynaecological centre

Sandra Coll Girona¹, Marta Vila¹, Ignacio Rodríguez¹, Rebeca Fernández¹, Pere Nolasca Barri¹

¹Department of Obstetrics- Gynecology and Assisted Reproduction- Hospital Universitari Dexeus- Barcelona- Spain in., Gynecology, Barcelona, Spain

Background

To describe our laparoscopic colposacropexy experience and to evaluate the risk factors associated with the recurrence of pelvic organ prolapse after surgery.

Methods

We retrospectively analysed 418 patients with symptomatic pelvic organ prolapse who underwent a laparoscopic colposacropexy at our centre from 2010 to 2020. We described demographic, clinical and surgical variables, and defined favorable or unfavourable outcomes; favourable was defined as complete anatomical correction and no symptoms after surgery.

Prolapses were assessed by Baden-Walker system (stage I-IV). All surgical procedures were performed by trained surgeons in laparoscopy by a standardized technique.

Continuous variables were described by means (SD), and categorical variables by percentages, t-test or chi square test were used for comparisons. Time to recurrence was analysed using survival cox regression. A p value <0.05 was considered as significant for all calculations.

Results

We included 418 patients; the mean age was 56.93 (10.32) y.o. and mean BMI was 24.79 (3.36) kg/m². Regarding obstetrics history, the mean parity rate was 2.14 (1.06), 97.6% had at least one vaginal delivery and 92 (22%) had a previous prolapse surgery. All cases were symptomatic, being vaginal vault the most common symptom (95.9%). In 124 (29.74%) cases levator ani avulsion was observed. Multiple compartments prolapse was diagnosed in 307 (73.44%) cases, being the apical compartment was the most affected (23.44%). The majority of patients (89.52%) had a type III or IV prolapse. Before surgery, 41.4% of patients performed assisted pelvic floor training. Regarding surgery, we performed a cervicosacropexy following subtotal hysterectomy in 336 (80.38%), we preserved the uterus in 13 (3.11%) cases and in 69 (16.5%) of cases we performed a colposacropexy. Median follow-up was 37 months; 40 (9.57%) recurred and 17 (4.06%) required re-intervention. Most recurrences occurred late, between the 2nd and 5th year of follow-up. In direct comparison, younger patients, those who presented levator ani avulsion and patients with cervicosacropexy with uterus preservation recurred more frequently. In cox regression analysis only levator ani avulsion was retained.

Conclusions

To the best of our knowledge, our series is one of the largest and with the longest follow-up. Recurrence rate was low, and comparable to other larger series. The only independent related factor to recurrence was the levator ani avulsion.

**ES31-0040 -
Best Selected Abstracts**

Redo laparoscopic sacrocolpopexy for pelvic organ prolapse recurrence: is it the right call?

Giuseppe Campagna¹, Giovanni Panico¹, Lorenzo Vacca¹, Sara Mastrovito¹, Alfredo Ercoli², Giovanni Scambia¹

¹Catholic University of Sacred Heart- Fondazione Policlinico Universitario Agostino Gemelli IRCCS, Department of women- children and public health sciences, Roma, Italy

²University of Messina- Policlinico G. Martino, PID Ginecologia Oncologica e Chirurgia Ginecologica Miniinvasiva, Messina, Italy

Background

As Laparoscopic Sacrocolpopexy (LSCP) has proven to be the gold-standard for treating Pelvic Organ Prolapse (POP), management of recurrence after its failure is a challenge with upcoming interest. Although LSCP has consolidated a crucial role in the treatment of de novo prolapse over the years, only few studies evaluated LSCP for recurrent POP after previous failed surgery in clinical settings and even less data has been published in literature regarding the reintervention with a second laparoscopic sacrocolpopexy (Redo LSCP). In patients with recurrence after surgical failure, repeat LSCP might represent a suitable surgical choice.

Methods

We present a retrospective observational study analysing safety, feasibility and outcomes of Redo LSCP.

Inclusion criteria were the following: patients with POP recurrence after a previous abdominal, laparoscopic, or robotic sacrocolpopexy surgery, who underwent a repeat LSCP.

The primary aim was to describe intraoperative findings and surgical choices taken during Redo LSCP explaining the crucial technical aspects and assess safety, feasibility, and efficacy of the procedure.

The secondary analysis included the comparison of patients who underwent a Redo LSCP to a cohort of consecutively operated patients who underwent LSCP for the treatment of a first-time diagnosed POP, responding to the same inclusion and exclusion criteria. Data of 20 patients with POP recurrence who underwent Redo sacrocolpopexy were recruited, as well as data from 80 patients undergoing LSCP as their first POP surgery.

Results

Mean 12-months follow-up demonstrated a statistically significant improvement of objective and subjective outcomes. No intra and postoperative complications were noted. Anatomical cure rate was 95%. Subjective cure rate was 100%, with a statistically significant POP symptoms resolution and improvement of voiding and storage symptoms.

Perioperative data and outcomes of Redo patients were compared to those of patients who underwent LSCP for a first-time diagnosed POP. The findings demonstrated that surgery did not differ from standard procedure in terms of intra/postoperative complications, hospital stay, blood loss, except for operative time.

Conclusions

Minimally invasive redo LSCP appears to be a safe and effective procedure in treating recurrent and symptomatic pelvic organ prolapse. Our series shows low recurrence rates, comparable to data from patients who underwent their primary surgery for POP.

**ES31-0066 -
Best Selected Abstracts**

Laparoscopic high uterosacral ligament suspension for vaginal apex suspension: a large single center experience.

Lorenzo Vacca¹, Giuseppe Campagna¹, Daniela Caramazza¹, Andrea Lombisani¹, Giovanni Panico¹, Giovanni Scambia²

¹Fondazione Policlinico Universitario A. Gemelli IRCCS, UOC Uroginecologia e Chirurgia Ricostruttiva del Pavimento Pelvico- Dipartimento di Scienze della Salute della Donna- del Bambino e di Sanità Pubblica, Roma, Italy

²Catholic University of Sacred Heart- Fondazione Policlinico Universitario Agostino Gemelli IRCCS, Department of women- children and public health sciences, Roma, Italy

Background

Laparoscopic high uterosacral ligament suspension (L-HUSLS) is an alternative surgical intervention for apical prolapse correction using native tissue derived from an abdominal transposition of the traditional vaginal technique.

Methods

This is a retrospective observational study including patients with apical POP (ICS) stage ≥ 2 alone who underwent L-HUSLS. The study was conducted at urogynecology referral centers of Fondazione Policlinico Universitario A. Gemelli IRCCS of Rome

Results

In the period from 2016 to 2018, 150 women underwent the surgical described technique: mostly were multiparous menopausal women with a median age and BMI of 64,5 (47-78) and 25,6 kg/m² (16.2-31.9) respectively. Only 10,7% of the included patients was already hysterectomized and 6,7% had already undergone a previous POP repair.

Preoperative apical and anterior POP Q stage was 3 in 53,3 % and 60,1% of cases respectively while posterior prolapse grade was <3 in all cases.

In case of non-hysterectomized patients without the need of uterus sparing procedure, a total hysterectomy was performed. Median operative time was 120 (60-270), with a minimal estimated blood loss. In 64% of women a concomitant anterior colporrhaphy was performed. We didn't register any intraoperative complications or early major post operative complication (≥ 3 according to Clavien-Dindo scale). No case of ureteral injury was observed. There were only 6 cases (4%) of urinary retention which all resolved spontaneously within 1 week. Median hospital stay was 2 days (1-4). There were 7 cases of the novo stress urinary incontinence (4,6%) and 4 (2,7%) patients with pelvic pain managed and resolved conservatively within 3 weeks with analgesic drug.

At a median follow up time of 24 months (12-48) there were 25 recurrences (16.7%): 13 (8,7%) involving only the anterior compartment, 5 (3,3%) the apical compartment and 2 (1,3 %) the posterior compartment. There were 5 (3.3%) multicompartamental recurrences including both anterior and apical descensus. POP recurrence grade was II in 20 (13.3 %) cases, and III in 5 (3.3 %) women.

There was a significant improvement of POP related symptoms including: frequency, nocturia, hesitancy, feeling of incomplete emptying, vaginal bulging, dyspareunia and stress urinary incontinence as also suggested by the PGI-I score <3 in 137 patients (91,3%) and by the statistical significative improvement of FSDS [34 (26-48) vs 16 (7-34); $p=0.000$] at the postoperative at 1-year FUP.

Conclusions

L-HUSLS suggest safety, feasibility and efficacy in the treatment of POP demonstrating with satisfying anatomical and functional outcomes.

**ES31-0191 -
Best Selected Abstracts**

Risk factors for adhesion-related readmission and abdominal reoperation after gynaecological surgery: a nationwide cohort study

Masja Toneman¹, Tjitske Groenveld¹, Pepijn Krielen¹, Harry van Goor¹, Pille Pargmae², Richard ten Broek¹

¹*Radboudumc, Surgery, Nijmegen, The Netherlands*

²*Radboudumc, Gynaecology, Nijmegen, The Netherlands*

Background

More than half of women in developed countries undergo surgery during their lifetime, putting them at risk for adhesion-related complications. Adhesion-related complications include small bowel obstruction, chronic (pelvic) pain, subfertility and complications associated with adhesiolysis during reoperation. The aim of this study is to predict the risk for adhesion-related readmission and reoperation after gynaecological surgery.

Methods

A Scottish nationwide retrospective cohort study was conducted including all women undergoing a gynaecological procedure as their initial abdominal or pelvic operation between June 1st 2009 and June 30th 2011, with a five year follow up. Prediction models for 2- and 5-year risk of adhesion-related readmission and reoperation were constructed and visualized using nomograms. To evaluate the reliability of the created prediction model, an internal cross-validation was performed using bootstrap methods.

Results

During the study period, 18452 women underwent their initial gynaecological surgery. 2719 (14.7%) of them were readmitted for reasons possibly or directly related to adhesions and 2679 (14.5%) of woman underwent a reoperation. Risk factors for a readmission directly or possibly related to adhesions were surgical approach (lower risk after laparoscopic surgery), lower age, malignancy as indication, intra-abdominal infection, previous radiotherapy, application of a mesh and concomitant inflammatory bowel disease (IBD). The risk of readmission was lower after fertility enhancing surgery. The prediction model for both readmissions and reoperations had a moderate predictive reliability of the model (c-statistics 0.611 and 0.647).

Conclusions

Risk factors for both adhesion-related readmission and abdominal reoperation were age, operation site, malignancy, fertility enhancing surgery, intra-abdominal infection, history of radiotherapy, mesh placement, and IBD. The constructed predictions models can guide the targeted use of adhesion prevention methods and the preoperative patient information and decision making.

**ES31-0081 -
Best Selected Abstracts**

Posterior Approach: a new approach for dealing uterine artery first, before the bladder dissection in TLH

Sakshi Srivastava¹, Nutan Jain², Shayari Jain², Vandana Jain²

¹MS Obstetrics and Gynecology from Rohilkhand Medical College and Hospital- Bareilly, Obs & Gynae, Jalandhar-, India

²Vardhman Trauma & Laparoscopy Centre Pvt. Ltd, Obs & Gynae, Muzaffarnagar, India

Background

To establish the safety of a new approach to uterine artery first, the posterior approach of bladder dissection (Newer approach) / versus lateral window approach (Conventional approach) in TLH.

Methods

Case-control study total of 673 patients with TLH spanning over 5 years, done at a tertiary referral centre from Jan 2017 to April 2022. Out of 673 patients, 330 patients underwent TLH by lateral window approach (Control) and 343 cases done by the new posterior approach. In the uterine artery first approach, the posterior leaf of the broad ligament is widely opened posteriorly till the mid of the uterus. We work from behind forwards and the uterine artery was skeletonized and transected first and then the bladder dissection started. This is based on two sound anatomic principles that the plane of uterine artery dissection is the same as bladder dissection. Secondly, the uterine artery holds the ureters to the uterus, so by first dissecting, coagulating, and cutting the uterine artery, the anterior mackenrod's ligaments are also cut which releases the ureters and they move laterally, and the plane of bladder dissection is reached effortlessly. Another observation is that bladder adherence is more pronounced at the level of the uterus and loosely attached at the level of the manipulator cup / cervical isthmus so in the new approach when we proceed with bladder dissection it looks as if the bladder is stretched over like a canopy and we work in the cotton candy plane below. Once the uterovesical space is fully opened exposing the manipulator cup then the uterovesical fold of the peritoneum is cut from above and TLH is completed.

Results

Control group had 330 cases with 134 patients with previous surgery while study group had 343 patients with 163 with previous surgeries. Patients were in age group (30yrs to 73yrs), BMI (16.61kg/m² to 58.11kg/m²), uterine weight (100gm to 3000gm). Previous LSCS were present in 160 patients, out of which 62 patients had 3 or more LSCS. As the total surgical time and blood loss depends on several variables a direct comparison of time and blood loss was not feasible, but the time of bladder dissection was much less. Two bladder injuries noted in lateral window approach, no injury noted in posterior approach, which could be attributed to ease of achieving the avascular plane of bladder dissection.

Conclusions

Contrary to a long-standing popular belief of bladder dissection first, we propose a new approach of uterine artery first posterior approach as an easy, safe, avascular dissection of the bladder in TLH.

**ES31-0530 -
Best Selected Abstracts**

Aggressive angiomyxoma in gynaecological patients: systematic review of the literature and proposal of an anatomico-surgical classification and therapeutic algorithm.

Andrea Rosati¹, Vito Andrea Capozzi², Alessandro Gioè¹, Emanuele Perrone¹, Giovanni Scambia¹, Salvatore Gueli Alletti³

¹Fondazione Policlinico Universitario A. Gemelli IRCCS, Woman-Child and Public Health Department, Rome, Italy

²University Hospital of Parma, Department of Medicine and Surgery, Parma, Italy

³Ospedale Buccheri La Ferla Fatebenefratelli, Department of Obstetrics and Gynecology, Palermo, Italy

Background

Aggressive angiomyxoma (AAM) is a rare locally infiltrative mesenchymal tumor arising primarily in the soft tissues of the vulvovaginal region, perineum and pelvis of adult women. The first choice is the surgical treatment; moreover, hormonal therapy is often used. The aim of this study was to report one of the largest series of AAM described in literature and to propose an anatomico-surgical classification useful to plan the therapeutic algorithm and surgical approach.

Methods

We performed a retrospective analysis of the clinical, surgical and histopathological characteristics of patients surgically treated for AAM at our institute, between March 2010 and July 2020. Local recurrence-free survival (LRFS) and the overall follow-up was calculated for each patient. We subdivided the AAM according to the anatomical position in type 1 (pelvic), type 2 (perineal) and type 3 (pelvic-perineal). We identified three ways of diffusion between these two regions: the trans-diaphragmatic pathway, through the urogenital diaphragm; the trans-levator ani pathway, through the levator ani muscle and the trans-obturator pathway, through the obturator canal.

Results

Nine patients were treated at our institution during the study period with a histological diagnosis of AAM. According to our anatomico-surgical classification four patients showed a type 1, four patients a type 3 and one patient a type 2 tumour. The most common surgical approach was the combined perineal/laparoscopic in 6 cases, while in three cases a purely laparoscopic or perineal approach were pursued. Regarding adjuvant treatment, two patients were treated with GnRh agonist and one with aromatase inhibitor after bilateral salpingo-oophorectomy. The median LRFS was 17.5 months (range: 6-36) and recurrence occurred in 4 patients. The median FUP time was 35 months (range: 26-129). 3 patients actually showed radiological sign of recurrent asymptomatic disease and 6 patients have no evidence of disease.

Conclusions

Our innovative anatomico-surgical classification provides a useful guide to plan the surgical approach to this rare disease.

**ES31-0395 -
Best Selected Abstracts**

Prevalence and risk factors of central sensitization in endometriosis patients using a validated inventory

Federica Renzulli¹, Diego Raimondo¹, Arianna Raspollini¹, Antonio Raffone¹, Paolo Casadio¹, Renato Seracchioli¹
¹Division of Gynaecology and Human Reproduction Physiopathology- IRCSS Azienda Ospedaliero-Universitaria di Bologna- Bologna- Italy,

Department of Medical and Surgical Sciences DIMEC- University of Bologna- Bologna- Italy, Bologna, Italy

Background

Central Sensitization (CS) is caused as an adaptive change of the central nervous system, triggered by different pathways, and clinically associated with several symptoms, including chronic pain. It has been demonstrated that also pain symptoms in women affected by endometriosis can be exacerbated by CS. With the present study we sought to assess: 1) CS prevalence in women with endometriosis; 2) any relation between CS occurrence and demographic and clinical factors in our cohort.

Methods

A single centre, prospective, observational study was carried out enrolling consecutive newly or re-referred patients with a clinical and/or instrumental diagnosis of endometriosis referring to our centre from January 2022 to April 2022. Before the visit, participants answered the *Central Sensitization Inventory* (CSI) questionnaire. This latter has been previously validated as a sensible tool for detecting CS in different conditions, including endometriosis. CSI part A evaluates the presence of 25 different symptoms correlated with CS. A CSI score ≥ 40 was used as a clinically significant score to identify the group of patients with high risk of CS. CSI part B investigates if patients has a previous diagnosis of one or more well established Central Sensitivity Syndromes (CSSs).

For each patient, bi-manual gynaecological examination and ultrasound evaluation were performed to detect endometriotic lesions' site (ovarian, deep endometriosis, combined), and several demographic and clinical data from medical history were collected. Pelvic pain symptoms associated to endometriosis were investigated using a 11-point numerical rating scale (NRS). Hormone therapy failure (HTF) was defined as persistence of at least one moderate-severe pain symptom (≥ 5 using NRS) after at minimum of 3 months of hormonal therapy.

Results

During the study period, 285 eligible women were included for the study analyses. CS was present in 118/285 (41.4%). At univariate analysis, infertility, moderate-to-severe pain symptoms (except dyschezia), altered bowel movements, HTF and most of CSSs were significantly associated to CS occurrence.

Multivariate analysis confirmed the significant association only between CS and moderate-to-severe chronic pelvic pain, HTF, migraine or tension-type headache, irritable bowel syndrome and anxiety or panic attacks.

Conclusions

Our study confirmed a higher prevalence of CS at CSI in women with endometriosis. Particularly in women with some CSSs and moderate-to-severe chronic pelvic pain, CSI questionnaire should be integrated in the clinical practice to assess the occurrence of CS to guide for additional treatments over conventional therapies.

**ES31-0034 -
Best Selected Abstracts**

Controlled ovarian stimulation with LNG-IUS *in situ* in women with atypical endometrial lesions, undergoing fertility-sparing treatment.

*Alessandra Gallo*¹, *Alessandro Conforti*², *Carlo Alviggi*², *Roberto Bartol*², *Virginia Foreste*², *Attilio Di Spiezio Sardo*¹

¹*University Federico II, Public Health, Naples, Italy*

²*University Federico II, Neuroscience- Reproductive Science and Odontostomatology, Naples, Italy*

Background

To demonstrate safety of ovarian stimulation with 52mg Levonorgestrel Intrauterine System (LNG-IUS) *in situ* in patients conservatively treated for atypical endometrial lesions

Methods

Prospective observational study: young women with atypical endometrial hyperplasia (AEH), or FIGO IA G1-G2 endometrial cancer (EC-G1, EC-G2), who underwent fertility-sparing treatment were enrolled. EC-G1 and EC-G2 were treated by three steps hysteroscopic technique, AEH by superficial endometrial resection. LNG-IUS was inserted after surgery. Hysteroscopic endometrial biopsies were performed at 3 and 6 months. If complete response (CR) was achieved, controlled ovarian stimulation with LNG-IUS *in situ* was started, oocytes retrieval performed, and mature oocytes cryopreserved. After removal of LNG-IUS, embryo transfer was performed.

Results

23 young women with AEH(n=17), EC-G1(n=3), or EC-G2 (n=3) were enrolled. CR was achieved in 14/16 (87.5%) of AEH, 2/2(100%) of EC-G1 and 2/3(66.7%) of EC-G2 at 3-month follow up and in 11/14(78.6%) of AEH, 2/2(100%) of EC-G1 and 2/2(100%) of EC-G2 at 6-month follow up. 10 patients underwent ovarian stimulation with LNG-IUS *in situ* (experimental group) and compared with 10 infertile patients undergoing ovarian stimulation in absence of LNG-IUS (control group). The mean number of oocytes retrieved, and mature oocytes was 8.10(± 2.77 SD) and 7.00(± 2.11 SD) in experimental group, compared with 6.30(± 3.3 SD) and 4.88(± 2.68 SD) in control group. There were no statistically significant differences in oocytes retrieved (p=0.19) and mature oocytes (p=0.05) between the two groups. Reproductive outcome (pregnancies and live birth rate) was also assessed. Pregnancy rate was 50%, live birth rate 37.5% and miscarriage rate 12.5%; 50% of patients experienced implantation failure.

Conclusions

Presence of LNG-IUS during ovarian stimulation has no negative effects on oocyte quality, balancing the effect of hyperestrogenism on patients with atypical endometrial lesions. The combined approach confirmed as a safe and effective fertility-sparing approach. Promising pregnancy outcomes can be expected.

**ES31-0071 -
Best Selected Abstracts**

Long-term cohort study on graft related complications after sacrocolpopexy with light versus heavier weight mesh.

Ann-Sophie Page¹, Laura Cattani¹, Stefaan Pacquée², Filip Claerhout³, Susanne Housmans¹, Jan Deprest¹

¹University Hospitals KU Leuven, Department Obstetrics & Gynecology- Pelvic Floor Unit, Leuven, Belgium

²Sydney Medical School Nepean- University of Sydney, Department Obstetrics & Gynecology, Sydney, Australia

³General Hospital Saint-Lucas, Department Obstetrics & Gynecology, Bruges, Belgium

Background

To investigate the long-term incidence and the characteristics of graft related complications (GRC), rate of reintervention for GRC and prolapse and subjective and anatomical outcomes following laparoscopic sacrocolpopexy (LSCP) with heavier weight (HW; over 44 g/m²) as compared to lighter weight (LW; 28 g/m²) polypropylene (PP)-mesh with resorbable poliglecaprone component.

Methods

Single centre study, comparing two consecutive prospective cohorts of women undergoing LSCP for symptomatic stage ≥ 2 cervical/vault prolapse, using either HW-PP mesh or LW-PP mesh at similar duration of follow-up. Primary outcome was the occurrence of GRC and their nature. Secondary outcomes included reinterventions for GRC or recurrent apical prolapse, subjective (Patient Global Impression of Change-score ≥ 4 (PGIC)) and anatomical outcome (C ≥ -1 cm).

Results

We identified 101 HW and 238 LW-implanted women who were audited at a similar follow-up period (HW:97 months (IQR:16 months) and LW:92.5 months (IQR:58 months)). GRC were more frequent in HW than LW-patients (22.8% (23/101) vs. 7.3% (13/178); HR=3.3; 95%-CI:1.6 to 7.1), more frequently symptomatic (HW: 16.8% (17/101) vs. LW:2.8% (5/178) ; HR=6.0; 95%-CI: 2.5 to 14.3) and lead more frequently to reintervention for GRC (HW:18.8% (19/101) vs LW:2.1%(5/238); HR=4.6; 95%-CI: 1.9 to 11.2). The vast majority of patients were better (PGIC ≥ 4) without difference between groups (HW: 71/84 (84.9%); LW: 154/178 (86.5%); HR=0.8; 95%-CI: 0.6 to 1.1), neither was there a difference in anatomical failure rate (HW: 1/60 (1.7%) vs LW:8/131 (6.1%); HR=0.2; 95% CI: 0.1 to 0.9, p = 0.13). Reoperations for recurrent vault prolapse were scarce (0.0% in HW compared to 0.4% in LW).

Conclusions

In these two consecutive cohorts compared at similar duration of follow-up, the number of GRC, symptomatic GRC and reinterventions for GRC were higher in patients operated with HW-mesh than when LW-mesh was used. There were no differences in subjective and objective outcomes nor in reoperation rates for prolapse.

**ES31-0228 -
Best Selected Abstracts**

Sonographic study of uterine biometry for the diagnosis of diffuse adenomyosis in a tertiary outpatient clinic

Matteo Giorgi¹, Diego Raimondo², Lucia Lazzeri¹, Bendetta Orsin², Ludovica Verrelli², Renato Seracchioli²

¹University of Siena- AOUS,

Department of Molecular and Developmental Medicine- Obstetrics and Gynecological Clinic, Siena, Italy

²Gynecology and Human Reproduction Physiopathology- IRCCS Azienda Ospedaliero-Universitaria di Bologna- Sant'Orsola Hospital, Department of Medical and Surgical Sciences, University of Bologna, Italy

Background

Transvaginal ultrasound (TVUS) can be considered the first-line imaging technique to diagnose adenomyosis. The aim of this prospective study is to systematically compare, in fertile-age women attending to a tertiary outpatient clinic, several uterine biometric parameters at TVUS between adenomyosis uteri and non-adenomyosis uteri and evaluate their potential role for the diagnosis of diffuse adenomyosis.

Methods

This prospective observational study was conducted between the 1st February 2022 and the 30th April 2022. Exclusion criteria were age less than 18 years, virgo, postmenopausal status, ongoing or recent pregnancy (less than 6 months), gynaecological malignancy, uterine malformations, previous surgery for adenomyosis or fibroids, focal myometrial lesions larger than 1 cm. Patients were divided in two groups according to the appearance of the uterus - adenomyotic and non-adenomyotic - at TVUS performed by expert operators. The two study groups were compared in terms of baseline and sonographic variables. First, we compared sonographic uterine biometric parameters (longitudinal (LD), anteroposterior (APD) and transverse (TD) diameters, volume, simple and complex diameter ratios) between the two study groups; secondarily diagnostic performance of their optimal cut-off values in diagnosing diffuse adenomyosis was evaluated.

Results

During study period, 56 eligible patients with a TVUS diagnosis of adenomyosis were included as adenomyosis uteri group. During the same period, a 1:1 ratio age and parity-matched group of eligible patients with non-adenomyosis uteri at TVUS was selected. Sonographic uterine diameters, volume simple and complex diameter ratios were all significantly different between the two groups, except for TD/(LD+APD). Optimal cut-off values of each biometric parameter demonstrated a low discriminative value for the diagnosis of adenomyosis. Of note, among all investigated parameters, the optimal cut-off values of APD and LD/APD showed the best sensitivity and specificity. In particular, APD diameter equal or superior to 39.5 mm (95% CI, 36.2-42.8) had sensitivity of 0.70 (95% CI, 0.57-0.80), specificity of 0.71 (95% CI, 0.59-0.82) and accuracy of 0.75 (95% CI, 0.66-0.84). LD/APD equal or inferior to 2.05 (95% CI, 1.96-2.13) showed sensitivity and specificity of 0.70 (95% CI, 0.57-0.80) each and accuracy of 0.72 (95% CI, 0.62-0.81).

Conclusions

Although several biometric uterine parameters at TVUS in fertile-aged women were statistically different between adenomyosis and non-adenomyosis uteri, their optimal cut-off values showed a low accuracy in diagnosing adenomyosis. Future larger studies are needed to confirm our data in different settings and conditions.

**ES31-0187 -
Best Selected Abstracts**

The multidisciplinary view on the uterine junctional zone; explaining discrepancies between MRI and ultrasound images on a microscopic level

Marissa Harmsen¹, Lisa Trommelen¹, Robert De Leeuw¹, Tina Tellum², Thierry Van den Bosch³, Judith Huirne¹

¹*Amsterdam UMC- location VUMC, Gynecology, Amsterdam, The Netherlands*

²*Oslo University Hospital, Gynecology, Oslo, Norway*

³*Universitaire Ziekenhuizen KU Leuven, Gynecology, Leuven, Belgium*

Background

The uterine junctional zone is the subendometrial area in the myometrium that contributes to peristalsis and aids in spermatozoa and blastocyst transport. Alterations in appearance of the junctional zone are associated with adenomyosis. Lack of uniform description of the physiological and pathological appearance and ill-defined boundaries of the junctional zone in both histology and imaging hamper understanding of the junctional zone's entity and limit its role in the diagnosis of adenomyosis. We aim to investigate the accordance on the definition of the junctional zone across different diagnostic approaches and examine how the imaging findings can be linked to histological findings in the context of adenomyosis diagnosis.

Methods

A comprehensive search was conducted using (MeSH) terms for the junctional zone and uterus in the PubMed, Google Scholar, and Web of Science databases up to September 27th, 2021, for articles describing the imaging appearance and histological structure of the junctional zone within the uterus. Relevant information was obtained from original articles and reviews written in English, irrespective of the date of publication and study design.

Results

The junctional zone is distinguished from the middle and outer myometrium by gradual changes in smooth muscle cells (SMC) density, extracellular space, connective tissue, water content, and vascularity. In studies using magnetic resonance imaging (MRI) or (2D/3D) transvaginal ultrasound (TVUS), the junctional zone has been visualized as a low-signal intensity band or hypoechoic halo, respectively. While the signal intensity from junctional zone to middle myometrium changes abruptly on MRI, the histopathological changes are gradual, and its border can be difficult to distinguish on TVUS. The thickness of the junctional zone on MRI was significantly larger than on TVUS. Thus, TVUS and MRI do not reflect exactly the same layer. Although a thickened junctional zone is often used to diagnose adenomyosis on MRI, the presence of adenomyosis can more accurately be described by interruptions of the junctional zone represented by direct features of adenomyosis, such as sub endometrial lines and buds on TVUS or bright foci on MRI.

Conclusions

Our review illustrates that the junctional zone is not a well-defined entity across and even within different diagnostic disciplines. A better awareness among clinicians is needed that findings on MRI cannot readily be extrapolated to ultrasound. Understanding of these findings is necessary to further investigate the potential relevance of the junctional zone as a functional unit in the uterus and the association between the visualization of direct features of adenomyosis in the junctional zone and clinical symptoms.

**ES31-0178 -
Best Selected Abstracts**

Prediction of adenomyosis diagnosis based on MRI

Connie Rees¹, Marloes van der Wiel¹, Joost Nederend², Aleida Huppelschoten¹, Huib van Vliet¹, Dick Schoot¹

¹*Catharina Hospital, Gynaecology and Obstetrics, Eindhoven, The Netherlands*

²*Catharina Hospital, Radiology, Eindhoven, The Netherlands*

Background

Adenomyosis is increasingly frequently suspected and diagnosed in women of fertile age and can cause debilitating symptoms. Non-invasive imaging-based diagnosis is still of variable accuracy, leading to diagnostic and therapeutic delay which can greatly influence patient quality of life. The diagnostic golden standard remains histopathological after hysterectomy.

Methods

Study Objective: Development of a prediction tool for histopathological adenomyosis diagnosis after hysterectomy based on MRI and clinical parameters.

This single-centre retrospective cohort study took place in the gynaecological department of Dutch regional referral hospital from 2007-2022. 296 women undergoing a hysterectomy for benign pathology with preoperative pelvic MRI were included.

MRI's were retrospectively re-assessed for all possible adenomyosis markers (junctional zone (JZ) parameters, high signal intensity foci (HSI foci), uterine size) in a blinded fashion by two researchers. Sensitivity, specificity, positive predictive value, negative predictive value, diagnostic accuracy and odds ratio (dOR) were calculated. Threshold values of continuous variables were investigated using Receiver Operator Characteristics (ROC) curves and Area Under the Curve (AUC). A multivariate regression model for histopathological adenomyosis diagnosis was developed based on selection of MRI and clinical variables from univariate analysis with $p > 0.10$ and factors determined to be of clinical importance.

Results

131 women (44.3%) had histopathological adenomyosis. In univariate analysis, patients had comparable age at hysterectomy, BMI and clinical symptoms, $p > 0.05$. Patients with adenomyosis had more often undergone a curettage (22.1% vs. 8.9%, $p = 0.002$), and had a higher mean JZ (9.35mm vs. 8.00mm, $p = 0.001$), maximal JZ (15.05mm vs. 12.45mm, $p = 0.002$), mean JZ to myometrium ratio (0.53 vs. 0.48 $p = 0.009$) and JZ differential (8.45mm vs. 6.75mm, $p = 0.009$). Presence of HSI foci on MRI was quasi-pathognomic for adenomyosis diagnosis (25.5% vs. 2.4%, $p < 0.001$).

A predictive model based on the parameters of: Age at MRI, History of Curettage, Dysmenorrhoea, Hypermenorrhoea, Mean JZ, JZ differential, JZ/Myometrium ratio, Presence of HSI Foci was created, with a good AUC of 0.761.

Conclusions

This is the first study to create a clinical diagnostic tool based on a combination of MRI and clinical parameters for adenomyosis diagnosis. As preoperative imaging-based diagnosis of adenomyosis remains challenging, this model, after sufficient external validation, could function to become a useful clinical-decision making tool in women with suspected adenomyosis.

BEST SELECTED ABSTRACTS VIDEO

ES31-0108 - Best Selected Videos

Posterior approach: a new approach for dealing uterine artery first, before the bladder dissection in TLH

Nutan Jain¹, Vandana Jain¹, *Shayari Jain*², Sakshi Srivastava³

¹Vardham Hospital, Director, Muzaffarnagar, India

²Vardham Hospital, Fellow, Muzaffarnagar, India

³Rohilkhand medical College and Hospital- Bareilly, Fellow, Bareilly, India

Background

To describe a new approach of TLH in which uterine artery is first skeletonized, coagulated and cut and then the bladder dissection done. We call it the uterine artery first, Posterior approach.

Methods

In this approach after dealing with adnexa, the broad ligament is opened widely, posteriorly till the mid of the manipulator cup. The uterine pedicle is dissected from behind forwards and cut and then as per the concept, that the plane of bladder dissection is the same as the uterine artery, we start getting into the utero vesicle plane. By cutting the uterine artery first, the anterior mackenrod's ligaments are also cut which frees the bladder and helps the ureters move laterally. By working in the correct plane, the bladder is mobilized in an avascular plane, till the other side uterine artery. Another observation is that bladder adherence is more pronounced at the level of uterus and loosely attached at level of manipulator cup / cervical isthmus so when we proceed with bladder dissection it looks as the bladder is stretched over like a canopy and we work in the cotton candy plane below.

Results

In the last five years out of 673 cases of TLH, 343 cases were done by the new, uterine artery first, posterior approach at a tertiary referral centre. 62 cases had previous 3 or more than 3 caesarean sections. Three cases had previous rupture uterus and bladder injuries. Surgical time spent in bladder dissection was less and bleeding was minimum even in the very densely adherent bladder. No bladder injury was noted in the new approach which could be attributed to the ease of bladder dissection.

Conclusions

We propose a new approach of uterine artery first as an easy, safe, avascular dissection of bladder in TLH, contrary to a long-standing popular belief of bladder dissection first.

<https://player.vimeo.com/video/709989167?autoplay=1>

**ES31-0126 -
Best Selected Videos**

Pelvic anatomy in laparoscopic surgery for pelvic organ prolapse: tips and tricks for a safe dissection

Marta Melo^{1,2,3}, Tânia Barros^{1,3}, Revaz Botchorishvili^{1,3}

¹Centre Hospitalier Universitaire Estaing de Clermont-Ferrand, Department of Gynaecological Surgery, Clermont-Ferrand, France

²Hospital Vila Franca de Xira, Department of Gynaecology and Obstetrics, Vila Franca de Xira, Portugal

³Centre International de Chirurgie Endoscopique, Centre International de Chirurgie Endoscopique, Clermont-Ferrand, France

Background

Laparoscopic surgery for pelvic organ prolapses is a complex procedure, requiring high skills and great knowledge of the anatomy, in order to avoid complications related to noble structures in proximity. This video aims to highlight the anatomical landmarks involved in the dissection during this procedure and give tips for a safe dissection.

Methods

We use videos to specify the anatomic structures we can encounter during dissection of the promontory, para-rectal space, recto-vaginal space, and vesico-vaginal space and give advice for acquiring better exposure and the right cleavage planes.

Results

Step-by-step overview of the surgical dissection involved in laparoscopic surgery for pelvic organ prolapse, specifying the most important anatomical landmarks and presenting tips to make the procedure safer.

Conclusions

Besides great surgical technical skills, a deep knowledge of the pelvic anatomy is key to perform such complex surgical procedure with safety, in order to preserve noble structures and avoid recurrence and complications.

<https://player.vimeo.com/video/710059428?autoplay=1>

**ES31-0271 -
Best Selected Videos**

Laparoscopic discoid excision using sutures for bowel closure

Nikolaos Kathopoulos¹, Dimitrios-Eythymios Vlachos¹, Konstantinos Kyriotis¹, Michael Diakosavvas¹, Ioannis Chatzipapas¹, Athanasios Protopapas¹

¹National and Kapodistrian University of Athens,

1st Department of Obstetrics and Gynecology- Alexandra Hospital, Athens, Greece

Background

Bowel endometriosis is a common pattern of deep endometriosis. Patients often complain of dyspareunia, dysmenorrhea, pain during defecation or lower-back pain. Surgical management of bowel deep endometriosis should be considered in patients with signs of bowel obstruction or those who remain unresponsive to medical treatment. Rectal shaving, disc excision and segmental bowel resection are the three techniques proposed for the surgical treatment of bowel endometriosis. Discoid excision is usually performed with the application of a transanal stapler. The aim of this video is to present the operative technique of laparoscopic discoid excision using sutures for bowel closure.

Methods

The video presents in detail the operative technique of discoid excision without the use of stapler. The operation begins with bilateral dissection of the ureters and development of the pararectal spaces. Special concern should be given to preserve the pelvic autonomous innervation consisting of the inferior hypogastric plexus and the hypogastric nerve. The detachment of the nodule from the bowel begins with deep shaving up to the muscularis interna. When deep shaving cannot establish complete excision of the nodule the surgeon proceeds to discoid excision. Bowel is closed then with two layers of interrupted Vicryl 3-0 sutures. The first and second suture are placed at the right and the left corner of the bowel defect and their threads are left 3-cm long to function as guide sutures. The third suture is placed in the middle of the incision and following sutures are placed to close the bowel defect. Subsequently a second layer of continuous 3-0 sutures is placed to secure a tight closure and avoid potential leakage.

Results

The advantage of the open technique described compared with the use of transanal stapler for discoid bowel excision is the ability to perform it when the pathology is located higher than 15cm from the anal verge or the diameter of the nodule is more than 30mm.

Conclusions

Although discoid excision for bowel endometriosis is usually performed with the use of transanal stapler the presented technique is useful in selected cases.

<https://player.vimeo.com/video/710508366?autoplay=1>

**ES31-0192 -
Best Selected Videos**

Laparoscopic extraperitoneal lateral repair with single suprapubic trocar

Michael Anapolski¹, Günter Noé¹

¹University Witten/Herdecke- Department of Obstetrics and Gynecology, Rheinland Klinikum Dormagen, Dormagen, Germany

Background

The number of patients with surgical correction of stress urinary incontinence applying vaginal tapes is continuously growing. In a case of relapse, such constellations may represent a serious challenge. Repeated surgery on predominantly elderly patients with significant comorbidity should combine high efficacy with as little tissue trauma as possible. We present a case of an 81-year-old female patient with a history of tension free transobturator tape, vaginal hysterectomy and cholecystectomy performed per laparotomy. The patient suffered also from type II diabetes, atrial fibrillation, arterial hypertension, hyperlipidemia and had a BMI of 34. The patient presented in our department with a lateral defect cystocele with mixed urinary incontinence, while stress incontinence II° was her leading complaint. After counselling about different treatment options, the patient wished a sustainable surgical therapy.

Methods

An extraperitoneal laparoscopic lateral repair was performed using a single instrument via the suprapubic incision. For the scheduled surgery, oral anticoagulation was replaced by low dose heparin injections.

Author(s) have received and archived patient consent for video and data recording/publication in advance of video recording of the procedure.

Results

The duration of the surgical procedure was 63 minutes. No wound drainage was required. No intra- or postoperative complications occurred. The patient could be discharged from our hospital on the 3rd postoperative day; the patient was continent and had no voiding difficulties. Almost four years after the procedure, no relapse of stress urinary incontinence occurred.

Conclusions

Extraperitoneal laparoscopic lateral repair is an elegant procedure for correction of lateral defect cystocele accompanied by stress urinary incontinence, suitable also for patients with a history of vaginal tape placement. Especially for elderly patients, use of a single trocar in the lower abdomen might reduce the tissue trauma.

<https://player.vimeo.com/video/710333051?autoplay=1>

**ES31-0014 -
Best Selected Videos**

Laparoscopic wedge resection of a caesarean scar ectopic pregnancy at nine weeks gestation

Melissa Workman¹, Sarah Smith¹, Darrien Rattray¹

¹University of Saskatchewan, College of Medicine- Obstetrics and Gynecology, Regina, Canada

Background

Caesarean scar ectopic pregnancies occur in 1 in 500 pregnancies with prior caesarean delivery and account for 4% of all ectopic pregnancies. Management is individualized and often requires a multi-modal approach. This case demonstrates a fertility-sparing approach to caesarean scar ectopic pregnancy in the context of multiple prior caesarean sections and advanced gestation.

Methods

A 40-year-old G6P3, with 3 prior caesarean sections, was diagnosed with a caesarean scar ectopic pregnancy at 9 weeks gestation and type 1 placenta percreta. She wished for fertility-sparing management which was planned to include pre-operative intragestational methotrexate and uterine artery embolization. Before this could be done, the patient experienced acute vaginal bleeding and she was taken urgently for surgical management. Operative approach included restoration of normal anatomy, a systematic approach to finding avascular planes for lysis of adhesions, and vascular control with intra-myometrial vasopressin and pre-emptive skeletonization of the uterine vessels.

Results

Laparoscopic wedge resection of the caesarean scar ectopic was successfully completed with the described method. There were no intraoperative or postoperative complications.

Conclusions

Although management of caesarean scar ectopic pregnancies requires an individualized approach, fertility-sparing laparoscopic wedge resection can be successfully and safely performed with a systematic surgical approach and judicious use of dilute intramyometrial vasopressin.

<https://player.vimeo.com/video/695516614?autoplay=1>

**ES31-0076 -
Best Selected Videos**

Laparoscopic ureteric reimplantation for severe endometriosis: when a kidney transplant surgeon joins the endometriosis multidisciplinary team

Benedetto Mondelli¹, Michael Adamczyk², Ben Lindsey³, Shaheen Khazali^{1,4}

¹CEMIG Centre for Endometriosis and Minimally Invasive Gynaecology at HCA The Lister Hospital, Gynaecology, London, United Kingdom

²CEMIG Centre for Endometriosis and Minimally Invasive Gynaecology at Ashford & St. Peter's Hospitals NHS Foundation Trust, Gynaecology, Chertsey, United Kingdom

³Royal Free Hospital, Renal transplant- Vascular surgery, London, United Kingdom

⁴Royal Holloway, University of London, London, United Kingdom

Background

A true multidisciplinary surgical team utilises the complementary skills of surgeons on the team to the benefit of the patient, leaving aside the arbitrary specialty boundaries. We present an MDT set up where a vascular and transplant surgeon who is very skilled in performing ureteric re-implantations through open approach joins forces with a laparoscopic endometriosis surgeon. The endometriosis surgeon (SK) performed the surgery with direct guidance from the transplant surgeon (BL) and completed a ureteric reimplantation laparoscopically at a tertiary referral endometriosis centre in the UK.

Methods

This 38-year-old woman presented to her local hospital with a large rectovaginal and uterosacral nodule causing severe hydronephrosis leading to a substantial kidney function loss. Left/right kidney function split (monitored with MAG3 scans) was 20/80% (only marginally recovering to 25/75% following GnRH analogues). Additionally, the patient was experiencing the typical symptoms of endometriosis, including very severe pelvic pain.

Results

In this video, we demonstrate our step-by-step approach for ureteric reimplantation. Following ureteric stent insertion, ureterolysis was attempted but the ureter could not be freed up and therefore a ureteroneocystostomy with psoas hitch was decided upon and performed. Cystogram at two weeks post operatively confirmed complete healing. Stent removal was attempted 4 weeks postoperatively but as resistance felt, removal was deferred for a further 3 weeks, suspecting entanglement of the stent in one of the sutures. The stent was successfully removed with ease 7 weeks after surgery.

Conclusions

The pain symptoms are dramatically improved and a repeat MAG3 scheduled for 6 months' following the procedure showed an improvement of the left kidney function from 19% to 28%.

<https://player.vimeo.com/video/709433147?autoplay=1>

**ES31-0421 -
Best Selected Videos**

Internal hernia after radical endometriosis excision of the pelvis

Patrick Bellelis¹, Victor Sergio Stockler Bruscin², Mariana Cunha Vieira¹, Mariana Corinti³

¹*University of Sao Paulo, Endometriosis Division, Sao Paulo, Brazil*

²*Santa Casa de Sao Paulo, General Surgery, Sao Paulo, Brazil*

³*Hospital Israelita Albert Einstein, Laparoscopic Division, Sao Paulo, Brazil*

Background

We describe a case of a 29 years-old woman referred to our centre complaining of severe dysmenorrhea, dyspareunia and chronic pelvic pain. The patient had no relevant past medical. The pre-operative investigation involved a transvaginal ultrasonography with bowel preparation and a magnetic resonance imaging that showed two infiltrative endometriotic nodules on the bladder, besides a complex impairment on the paracervix and posterior vaginal fornix, sigmoid, terminal ileum, appendix and cecum. She was submitted to a surgical procedure for radical eradication of the deep infiltrating endometriosis. She remained fasting on the 1st postoperative day, and, on the 2nd day, she already received a liquid diet. However, she evolved with significant abdominal distention. A CT of the abdomen was performed, which did not identify a fistula and was then submitted to a new laparoscopic approach with the hypothesis of ileal stenosis as a result of enterectomy.

Methods

At laparoscopy, an internal hernia was identified, with strangulation of small bowel loops, as a result of the epiploon flap performed to correct the defect in the left broad ligament.

Results

In this way, the epiploon flap was undone and any injuries to the other small bowel loops were checked. The patient had an excellent recovery and was discharged on the 3rd postoperative day of the second laparoscopic approach.

Conclusions

Although rare, do not forget to think about internal hernia and do not postpone the indication of laparoscopy for its correction.

<https://player.vimeo.com/video/714765392?autoplay=1>

**ES31-0159 -
Best Selected Videos**

Surgical correction of isthmocele by robotics and hysteroscopy

Priscilla Pessoa¹, Carolina Resende², Juliana Romano¹, Fernanda Dishchekenian¹, Débora Maranhão¹, Gabriela Guimarães¹

¹*Hospital Israelita Albert Einstein, Gynecology and Obstetrics, São Paulo, Brazil*

²*Hospital Israelita Albert Einstein- Hospital Moriah, Gynecology and Obstetrics, São Paulo, Brazil*

Background

To present a case of isthmocele repair containing placental remnants in a patient with late puerperal haemorrhage, using the robotic platform with hysteroscopy assistance

Methods

A 38-year-old patient without comorbidities presented with a late puerperal haemorrhage on the twentieth day after caesarean delivery, requiring hemotransfusion.

She was evaluated by the team 2 months after delivery, bringing diagnostic hysteroscopy that showed ismocele containing heterogeneous material inside.

For surgical treatment, robot-assisted laparoscopic video laparoscopy was indicated and complemented by hysteroscopy to correct the isthmocele.

In the surgical planning, we used a conventional laparoscopic portal was positioned in the right flank, and three robotic portals: one umbilical and two in right and left iliac fossae.

Results

The duration of surgery was two hours, with minimal blood loss and no complications. It was possible to perform metroplasty with excision of the material contained in the isthmocele and also to correct the defect with uterine suture in planes. The patient had a satisfactory postoperative clinical course and was discharged twenty-four hours after surgery. The pathological report of the material contained in the isthmocele showed endometrium without atypia.

Conclusions

Isthmocele can develop into ectopic pregnancy, uterine rupture, infertility, or abnormal uterine bleeding. Its treatment should be individualized. A robotic-assisted laparoscopic approach facilitates surgical access as well as tissue manipulation, since its forceps offer greater articulation and better access to difficult sites in the pelvis, compared to conventional laparoscopy.

This leads to greater intraoperative agility, ergonomics for the surgeon, and better postoperative outcomes.

Likewise, concomitant hysteroscopy allows a better diagnosis and acts as a guide for the correction of the defect, offering a view of the endometrial cavity during the laparoscopic surgical procedure.

<https://player.vimeo.com/video/710198131?autoplay=1>

**ES31-0194 -
Best Selected Videos**

Vaginal cerclage assisted laparoscopic hysteropexy technique: VCALH

Serdar Aydın¹, Sebile Güler Çekiç¹

¹Koc University, Obstetrics and Gynecology, Istanbul, Turkey

Background

Apical prolapse, alone or in combination with anterior/posterior vaginal wall prolapse, results from defects in the integrity of the uterosacral and cardinal ligaments. Sacrocolpopexy are accepted as the gold standard treatments for apical uterine prolapse. Reduced blood loss, fast patient recovery and fewer incisional morbidities are achieved by laparoscopic sacrocolpopexy (3). However laparoscopic sacrocolpopexy is a long and complicated procedure that requires specialized surgical skills, including precise dissection, suturing and the use of advanced laparoscopic equipment, or a robotic endoscopic unit to assist with suturing and dissection. Concomitant hysterectomy at the time of sacrocolpopexy, usually performed to facilitate access to the anterior and posterior vaginal walls, is associated with increased cost, morbidity, and operation time. Uterus-sparing hysteropexy reduces mesh exposure, operative time, blood loss and surgical cost with no differences in prolapse recurrence. Despite a better understanding of apical support and advancements in surgical techniques, there are still several problems associated with the peritonization of mesh and a non- physiological position of the uterus or vagina, including a relatively high recurrence rate, frequent mesh exposure and complications such as ileus and ureter damage. The aim of this video is describing the technical considerations for performing a new feasible and minimally invasive technique to correct apical and concurrent apical and anterior vaginal wall defects.

Methods

The presented operation is performed in two phases, consisting of an initial vaginal surgery followed by a laparoscopic approach.

Vaginal approach; 1. An anterior 2-cm long transverse incision to the anterior cervicovaginal junction and dissection of bladder. 2. Posterior colpotomy. 3. Insertion of mid-urethral sling tape into the cervix. 4. Free arms of tape are inserted into the peritoneum via posterior colpotomy.

Laparoscopic approach; 5. Two arms of tape is passed from the tunnel parallel and medial to a sacrouterine fold formed by a modified semicircular laparoscopic needle holder. 6. Fixation of both tape arms to the anterior longitudinal ligament.

Results

The tape can be inserted into the cervix in median 15 minutes and the laparoscopy procedure can be completed in 30 minutes. All operations performed laparoscopically. Hospitalisation duration was 1 day. No intraoperative or early postoperative complication occurred. No mesh erosion or long-term complications occurred. At a 1-year control, no cases of recurrence. The median postoperative point C was -9 cm.

Conclusions

This novel hysteropexy technique feasible and safe minimally invasive way to correct primarily apical or multicompartament defects with short operation time and satisfactory anatomical success.

<https://player.vimeo.com/video/710352539?autoplay=1>

**ES31-0267 -
Best Selected Videos**

Laparoscopic sacro-pecto-colpopexy for the management of apical prolapse. A novel technique with three attachment points with a single mesh

Jesus Molero^{1,2}, Ester Martínez Lamela^{1,3}, Marta Heras García^{1,4}, Yolanda Expósito Lucena⁵, Soledad Peco Adrover⁶

¹Hospital Ntra Sra del Rosario, Oncologic Gynaecology, Madrid, Spain

²TocoGyn Gynecological Clinic, Oncologic Gynaecology and Endoscopy Surgery, Alcalá de Henares, Spain

³Infanta Leonor University Hospital, Gynecology and Obstetrics, Madrid, Spain

⁴Santa Cristina University Hospital, Gynecology and Obstetrics, Madrid, Spain

⁵TocoGyn Gynecologic Clinic, Gynecology and Obstetrics, Alcalá de Henares, Spain

⁶Hospital Ntra Sra del Rosario, Gynecology and Obstetrics, Madrid, Spain

Background

Laparoscopic sacrocolpopexy has been demonstrated to be the gold standard of prolapse surgery in cases with apical defect. According to improve the results and avoid post-surgical failures, we recommend a novel technique with three attachment points (sacral and ileopectineal ligaments) with a single mesh. Less relapse risk (three attachment places better than one) and more physiological (mesh like a hammock).

Methods

In our Multidisciplinary Oncologic and Endoscopy Surgery Unit, in Rosario Hospital in Madrid, during last five years, from January 2017 to April 2022, we perform 147 reconstructive surgeries and 4 obliterative surgeries for pelvic floor dysfunction. The laparoscopic reconstructive surgeries were: 24 sacrocolpopexies, 3 sacrohysteropexies, 10 pectopexies, 16 sacro-pecto-colpopexies (SPcp) and 2 sacro-pecto-hysteropexies.

This video presents our technique for laparoscopic SPcp, step by step, in a 66yo-patient that presents a stage III apical vaginal prolapse. 1. Sacral promontory dissection, 2. Extending the peritoneal incision, 3. Anterior dissection (bladder down) of the vaginal vault, 4. Posterior dissection (rectum away), 5. Dissection of the levator ani muscle, both sides, 6. Ilipectineal ligament dissection on the pectineal line of the pubic bone, both sides, 7. Introducing the mesh (DynaMesh®-PRP visible, 17x15 cm), 8. Levator ani muscle mesh attachment, both sides 9. Posterior vaginal wall mesh attachment, 10 Mesh attachment of the bladder pillars and vaginal vault fascia (to avoid future cystocele), 11. Mesh suture to both ilipectineal ligaments by intracorporeal suture technique, using nonabsorbable sutures or novel procedure Ti-KNOT® DEVICE, 12. Sacral mesh attachment, and 13. Peritonealization.

Results

Perioperative results of laparoscopic SPcp are excellent. Mean age 58,38 years (range 45-58,3 years). Mean BMI 25,51 (SD 4). Prevalent symptoms: Bulge 62,5% and painful sexual intercourse 25%. 7 cases with previous gynaecological surgeries. Findings: POP-Q stage prior surgery: 13 cases in stage III (81.3%) and 3 cases in stage IV. We perform during surgery 5 total hysterectomies (31.3%) and 7 supracervical hysterectomies, in 12 cases with bilateral adnexectomy (75%) and 2 cases opportunist bilateral salpingectomy. In most cases Dynamesh PRP 17x15 cm mesh was implanted (87.5%). Mean operating time was 165.19 minutes (Range 130-210 minutes). Blood mean loss was 589.5 ml (SD 263.34 ml). No reported any perioperative nor postoperative complications. Mean hospital stay was 2.69 days (SD 0.47).

As we are following all our patients after laparoscopic sacro-pecto-colpopexy we can report on a significant improvement of anatomical outcome (mean 9.37/10 points) and quality of life (mean 9.63 / 10 points), at least in the short term follow up. Mean follow-up 22.7 months (range 0-54 months). No prolapse after surgery in 10 patients (62.5%) and in 6 patients POP-Q stage I (37.5%).

Conclusions

The laparoscopic sacro-pecto-colpopexy is an effective and safe technique to repair the apical prolapse with satisfactory anatomical and functional results.

<https://player.vimeo.com/video/710502817?autoplay=1>

**ES31-0316 -
Best Selected Videos**

Incidental damage of obturator nerve during laparoscopic pelvic lymphadenectomy in endometrial cancer: demonstration of a successful repairing procedure

Joana Oliveira¹, Cristina Celada-Castro², Kristina Agababayan³, Filipa Sousa¹, Juan Gilabert Aguilar⁴, Juan Gilabert-Estellés^{3,4}

¹Centro Hospitalar e Universitário de Coimbra, Gynaecology Department, Coimbra, Portugal

²Hospital Universitari de Vic, Department of Gynecology and Obstetrics, Barcelona, Spain

³Hospital General Universitario de Valencia, Endoscopy and Gynecologic Oncology Unit, Valencia, Spain

⁴European Gynecology Endoscopy School E.G.E.S., European Gynecology Endoscopy School E.G.E.S., Valencia, Spain

Background

In order to highlight the importance of intraoperative complications and their management, we demonstrate a video of an iatrogenic left obturator nerve lesion during a pelvic lymphadenectomy for endometrial cancer staging. The repair was promptly performed using an intracorporeal laparoscopic suture for an end-to-end tension-free nerve anastomosis.

Methods

Case description: A 70-year-old woman with a stage IB grade I endometrial adenocarcinoma was submitted to a surgical laparoscopic staging with total hysterectomy (TH), bilateral adnexectomy (BA), and bilateral pelvic and lombo-aortic lymphadenectomy. After an uneventful retroperitoneal lombo-aortic lymphadenectomy, the left paravesical space was dissected until the obturator fossae and a left pelvic lymphadenectomy followed, during which the left obturator nerve was accidentally transected with LigaSure™.

Results

A careful inspection revealed an almost complete transection (80%) of the nerve, with both proximal and distal cut ends identifiable and no fraying of the edges. The thickness of the non-sectioned nervous portion was less than 3 millimetres, but a tension-free reattachment of both edges seemed manageable. The edges were oriented towards each other, and a single stitch suture was placed using a 5-0 prolene, providing an epineural end-to-end coaptation. To reinforce the suture, a Fibrin sealant Tissucol® was applied. The contralateral pelvic lymphadenectomy was then performed, followed by TH and BA. The pieces were removed through the vagina using an endobag. The patient was discharged on the second postoperative day. During the follow-up, there were no signs of diminished adductor function, and neither there was any other detectable residual neuropathy or neurologic deficit involving the left thigh.

Conclusions

It is crucial to identify intraoperative complications and to develop abilities to manage them. This video proves that it is possible to repair a transected obturator nerve using laparoscopy, when performed by an experienced oncogynaecologist, with extremely good functional results.

<https://player.vimeo.com/video/710538948?autoplay=1>

ES31-0348 - Best Selected Videos

Surgical approach of an OHVIRA-like syndrome: a didactic video

Farida Akhoundova Sanoyan¹, Rosa Pinto Catarino¹, Jacques Birraux¹, Jean Dubuisson¹

¹Geneva University Hospitals and University of Geneva- Geneva- Switzerland,
Department of Pediatrics- Gynecology- and Obstetrics, Geneva, Switzerland

Background

Herlyn-Werner-Wunderlich (HWW) syndrome (also known as OHVIRA syndrome) is a rare congenital urogynaecological malformation, typically characterized by the triad of uterine didelphys, obstructed hemivagina, and ipsilateral renal agenesis. However, the multiple anatomical variations of this syndrome challenge the prompt diagnosis and the therapeutic approach. Surgical treatment may not always be clear until completing diagnostic with endoscopic exploration. We present a case of a laparoscopic hemi-hysterectomy in a young patient with an anatomical variant of HWW syndrome.

Methods

Our adolescent female patient, nuligest and virgin, with a history of left renal agenesis was addressed to the Gynaecology unit with complaints of chronic abdominal pain, worsened in the last weeks and mainly irradiated to the left iliac fossa. Physical examination showed a non-surgical but painful abdomen and normal external genital organs. Abdominal ultrasound and abdominopelvic MRI revealed a uterus didelphys and suspected a blind left hemivagina with 8 cm hematocolpos. The association with a left renal and ureteral agenesis was suggestive of an OHVIRA syndrome.

Given the worsening of the pelvic pain, an endoscopic exploration (vaginostomy followed by a laparoscopy to complete the diagnostic) under general anaesthesia was planned.

What was unusual is that vaginostomy didn't show either the hematocolpos, second hemivagina, or cervix, with no possibility then to drain it vaginally.

Exploratory laparoscopy revealed a uterus didelphys with a probably obstructed hemi-uterus on the left side as it was associated with a voluminous hematocervix and hematosalpinx. On the right side, normal hemi-uterus and adnexa with a permeable right tube. Peritoneal endometriosis was identified at multiple sites of the abdominal cavity. Left laparoscopic hemi-hysterectomy was decided intraoperatively after the patient's parents' consent.

Results

The video illustrates a hemi-hysterectomy as the surgical approach to one of the variants of HWW syndrome classified by Zhu L. 2015 as *cervicovaginal atresia without communicating uteri* (type 1.2.).

The procedure started as a standard hysterectomy, followed by a long adhesiolysis to progressively "enucleate" the dilated cervix from the surrounding peritoneum until the complete resection of the rudimentary left uterus and tube. Operative time was of 160 minutes, with 150 ccs of blood loss. Postoperative course was uneventful, and the patient went home on the sixth day after surgery.

Desogestrel-only pill was started to treat endometriosis and regular follow-up was established.

Conclusions

We highlight that HWW syndrome may be suspected in young patients with abdominal pain, a pelvic mass (suggestive of hematocolpos) and renal malformations. Early diagnosis and timely proper management of this syndrome are crucial as they would prevent urogynaecological complications such as endometriosis, infection, and infertility. Even if a conservative approach is recommended, some anatomical variants may require a hemi-hysterectomy. We believe our video may help surgeons to better identify the phenotypic presentation of OHVIRA syndrome and plan their surgical approach.

<https://player.vimeo.com/video/71055579?autoplay=1>

**ES31-0423 -
Best Selected Videos**

Intraoperative use of endovenous indocyanine green for real-time visualization of adnexal re-perfusion in case of adnexal torsion.

Michele Altieri¹, Ludovica Verrelli¹, Alessandro Arena¹, Paolo Casadio¹, Eugenia Degli Esposti¹, Renato Seracchioli¹

¹IRCCS AOUBO, Gynecology and human reproduction pathophysiology, bologna, Italy

Background

We describe two cases of women with adnexal torsion treated by laparoscopy: an 18-year-old woman with a torsion of the right adnexa and a 34-year-old woman with a torsion of the left adnexa. Both women were referred to our clinic for acute lower abdominal pain. At preoperative ultrasound examination, adnexal torsion was suspected, and laparoscopy surgery was performed.

Methods

An intravenous injection of 1.5 mL solution containing 3.75 mg dose of indocyanine green (ICG) for intraoperative fluorescence imaging was performed during surgery for adnexal torsion.

Results

We performed laparoscopic surgery in two cases of adnexal torsion. Detorsion of the adnexa in both cases was carefully performed and ICG was administered through a peripheral line to confirm the adnexal re-perfusion. A near-infrared camera head enabled vision of the colorant after latency of a few seconds. The adnexal re-perfusion was detected early near the salpinx and after few minutes around the ovary, through the ovarian hilus. The postoperative course was uneventful, and the patients were discharged after two days. Ultrasound performed at two months follow-up visit showed regular ovaries in both cases.

Conclusions

Adnexal torsion is a common gynaecological emergency and currently there are no specific tools for evaluating adnexal re-perfusion during surgery for adnexal torsion. To the best of our knowledge, this is the first reported use of endovenous ICG to evaluate adnexal re-perfusion. ICG fluorescence imaging can help the surgeon to objectively evaluate whether blood supply is present during surgery for adnexal torsion.

<https://player.vimeo.com/video/714770377?autoplay=1>

**ES31-0454 -
Best Selected Videos**

Laparoscopic management of the unsuspected complex non-ovarian pelvic masses

*Ester Martínez^{1,2}, Jesús Molero Vílchez^{2,3}, Judith Suarez Aguado⁴, Yolanda Expósito Lucena⁵,
Marta Heras Garcia^{2,6}*

¹*Infanta Leonor University Hospital, Obstetrics and Gynecology, Madrid, Spain*

²*Hospital Ntra Sra del Rosario, Oncologic Gynaecology, Madrid, Spain*

³*Toco-Gyn Gyneacologic Clinic, Oncologic Gynaecology, Alcalá de Henares, Spain*

⁴*Jiménez Ayala Institute, Pathology, Madrid, Spain*

⁵*Toco-Gyn Gyneacologic Clinic, Gynecology and Obstetrics, Alcalá de Henares, Spain*

⁶*Santa Cristina University Hospital, Gynecology and Obstetrics, Madrid, Spain*

Background

The aim of the study was to show the place of laparoscopy in the treatment of these lesions and to evaluate the technique of laparoscopic removal of adnexal masses.

Methods

Preoperative evaluation included history, clinical examination, sonographic images, and serum markers. Transvaginal ultrasound scanning was used as primary imaging modality. The study was complemented with magnetic resonance imaging (MRI) and, in some cases, computed tomography (CT). Intraoperative evaluation included cell washings and examination of the pelvis and upper abdomen.

We present in video format two cases of tumours whose diagnosis was not expected.

Results

The first case, 51-year-old woman presents ultrasound finding of cystic tumour of 66x49 mm with serohematic and heterogeneous content and increased vascularization in the Doppler study. Both ovaries were normal, and the mass was suggestive of tubal neoformative process. The level of CA-125 was 25 U/ml, CEA was 1,17 U/ml and that of CA 19–9 was 11.75 U/ml. MRI of the pelvis confirmed a right parauterine tumour with a thick capsule and solid papillary projections that restrict to diffusion. There was no associated lymphadenopathy or ascites. No disease spreading on CT. The mass depended on small intestine and was removed by a gastrointestinal anastomosis (GIA) stapler, and the protected extraction of the surgical specimens was in bag. Body mass index was 23.31 kg/m². Surgical time was 30 minutes. The mass measured 7 × 5 × 4.5 cm and the pathological analysis revealed a low grade (G1) mixed gastrointestinal stromal tumour (GIST). IHQ c-kit and DOG1 were positive. Ki67 was <5%.

The second case, 54-year-old woman with previous left adnexectomy and myomectomy by laparoscopy 20 years ago, presents ultrasound finding of heterogeneous solid tumour of 45x42 mm, without increased vascularization in the Doppler study. Right ovary was normal. The appearance was suggestive to represent an atypical pediculated uterine myoma. The level of CA-125 was 6.87 U/ml, CEA was 1.99 U/ml and that of CA 19–9 was 0.6 U/ml. MRI of the pelvis confirmed a solid tumour, that contacts with intestinal loops and suggestive of non-suspicious tumour with origin in the digestive tract. There was no associated lymphadenopathy or ascites. The mass has a retroperitoneal location with intense adhesions to the loops of the small intestine and appendix. After dissection and release of the intestinal loop, the tumour was removed with a GIA stapler. Body mass index was 23.05 kg/m². Surgical time was 65 minutes. The pathological analysis revealed a granulomatous reaction in relation to surgical material, without evidence of malignancy.

In both cases, discharge was in next day and no complications were reported.

Conclusions

Laparoscopy allows for a suitable management of complex non-ovarian pelvic masses.

<https://player.vimeo.com/video/715322978?autoplay=1>

**ES31-0495 -
Best Selected Videos**

Three-dimensional imaging reconstruction and laparoscopic robotic surgery: a winning combination for a complex case of multiple myomectomy

Antonio Mercorio¹, Simona Barbuto², Giuseppe D'Angelo¹, Mario Ascione¹, Pierluigi Giampaolino¹, Gaby Moawad³

¹*University of Naples Federico II, Ob/Gyn, Naples, Italy*

²*Medic Srl Moncalieri, Gynecology, Torino, Italy*

³*George Washington University, Ob/Gyn, Washington, USA*

Background

Minimally invasive surgery is the recommended approach to treat uterine leiomyomatosis, the most common benign neoplasia of the uterus, ensuring faster recovery, fewer postoperative adhesions and better cosmetic results compared to laparotomy; however, for complex cases with multiple fibroids a minimally invasive approach can be very challenging. Laparoscopic assisted robotic surgery thanks to the superior instrument articulation and three-dimensional images confers different advantages but presents as a main limit the loss of haptic feedback. Intuitive and accurate localization of myomas and the endometrium via three-dimensional (3-D) imaging reconstruction could be a valid intraoperative help for the surgeon.

Methods

A stepwise approach describing the incorporation of Hyper Accuracy 3D imaging technology into the preoperative and intraoperative surgical guidance of a patient with infertility and menorrhagia undergoing laparoscopic robotic surgery for multiple myomectomies.

Results

The preoperative and intraoperative use of three-dimensional reconstructed imaging via Hyper accuracy 3D during laparoscopic robotic myomectomy is presented.

Conclusions

The application of 3d imaging technology could overcome one of the main limits of robot assisted minimally invasive surgery, the lack of haptic feedback, enabling the surgeon to rapidly locate myomas and adapt accordingly the intraoperative plan in order to optimize the results. The combination of 3D imaging reconstruction and the use of robotic assistance in laparoscopy can overcome the disadvantages of traditional laparoscopy guaranteeing the patient to have a procedure effective as a classic open myomectomy while maintaining the advantages of a minimally invasive technique.

<https://player.vimeo.com/video/715639994?autoplay=1>

**ES31-0518 -
Best Selected Videos**

Laparoscopic release of sacral nerve root entrapment

Jon Einarsson¹

¹Brigham and Women's Hospital, ObGyn, Boston, USA

Background

The sacral nerve roots generally travel on the surface of the Piriformis muscle. However, in roughly third of cases, the sacral nerve roots travel within the Piriformis muscle. Most of those patients are asymptomatic, but this may occasionally cause entrapment of the corresponding sacral nerve roots, and this may lead to radiculopathy and intractable pain.

Methods

This video demonstrates important steps required for the safe release of the S2 sacral nerve root from the Piriformis muscle along with a few tips and tricks for exposure and management of sudden bleeding episodes.

Results

Surgical time was 90 minutes and there were no complications. Final results of surgery are pending since symptom resolution can take at least 6 months to manifest.

Conclusions

Laparoscopic release of the sacral nerve roots is feasible laparoscopically and may lead to symptom relief for patients with a longstanding history of debilitating pain.

<https://player.vimeo.com/video/715699492?autoplay=1>

**ES31-0525 -
Best Selected Videos**

Complete uterine septum, cervical duplicity and vaginal longitudinal septum: from diagnosis to total endoscopic treatment

Federica Pozzati¹, Luca Parodi¹, Maria Teresa Mirandola¹, Antonia Carla Testa¹, Giovanni Scambia¹, Ursula Catena¹

*¹Fondazione Policlinico Universitario Agostino Gemelli- IRCCS,
Dipartimento Scienze della Salute della Donna del Bambino e di Sanità Pubblica, Rome, Italy*

Background

To describe an accurate preoperative assessment and a totally minimally invasive ultrasound-guided hysteroscopic treatment of a complete uterine septum with cervical duplicity and a longitudinal complete vaginal septum (U2bC2V1 sec. ESHRE/ESGE classification). Patients affected by the malformation complain dyspareunia, infertility, and recurrent miscarriage. Surgical management can improve fertility and obstetrical outcomes.

Methods

We present a case of a patient with a complete uterine septum, double cervix and a longitudinal complete vaginal septum accurately diagnosed with bi and three-dimensional ultrasound and treated through transabdominal ultrasound guided hysteroscopy.

Results

A 30-year-old nulliparous patient came to our clinic because of infertility and a suspicion of uterine malformation. The two-dimensional ultrasound (2D) evaluation showed the presence of a complete uterine septum and a double cervix. The Mullerian congenital anomaly was confirmed at 3D ultrasound reconstruction. The gynaecological examination revealed the presence of a complete longitudinal non-obstructing septum dividing the vagina into two hemicavities. The treatment performed was totally minimally invasive. Vaginal septum incision was performed hysteroscopically. Complete incision of the uterine septa and communication between the two hemicavities was performed with a Collins loop under ultrasonographic guidance. Redundant endometrium was resected with a 90° loop electrode. One month after the procedure the hysteroscopic evaluation showed the presence of a normal uterine cavity and a unique vaginal canal confirming the success of the treatment.

Conclusions

The association of ultrasound and hysteroscopy represents the optimal combination to guarantee the most accurate diagnosis and the most effective treatment results.

Ultrasound guided hysteroscopic management of longitudinal complete vaginal and uterine septum with double cervix (U2bC2V1 sec. ESHRE/ESGE classification) is a safe and effective procedure that can be completely performed with hysteroscopic surgery thanks to the use of miniaturized instrument.

<https://player.vimeo.com/video/715714241?autoplay=1>

**ES31-0587 -
Best Selected Videos**

Hysteroscopic treatment of patients affected by Asherman's syndrome

Alfonso Manzi¹, Rossella D'Alisa², Maddalena Granata¹, Maria Chiara De Angelis³

¹University of Naples "Federico II",

Department of Neuroscience- Reproductive Sciences and Dentistry- School of Medicine, Naples, Italy

²University of Rome "Sapienza", Department of Maternal and Child Health and Urological Sciences, Rome, Italy

³University of Naples "Federico II", Department of Public Health- School of Medicine, Naples, Italy

Background

To describe hysteroscopic treatment of patients diagnosed with Asherman's Syndrome using miniaturized instruments.

Methods

Three patients were managed by hysteroscopy performed in operating room under general anaesthesia. Follow-up hysteroscopies at 1 months were performed in office setting. Case 1 is a 34-year-old woman with prior history of infertility and 2 ectopic pregnancies treated respectively with salpingectomy and uterine artery embolization. Case 2 is a 27-year-old woman with history of two spontaneous miscarriages, both followed by D&C. Case 3 is a 28-year-old woman with one previous spontaneous miscarriage also followed by D&C. Case 1 was treated using miniaturized mechanical instruments; case 2 with mechanical instruments and a 15 Fr bipolar resectoscope; patient 3 was treated using only miniaturized mechanical instruments. Synechiolysis was stopped when both tubal ostia are observed and an adequate uterine cavity for shape and volume was reached. At the end of all procedures an antiadhesive gel based on ialuronic acid was applied in order to prevent new intrauterine synechiae. At the 1-month follow up, only the patient 1 need a new synechiolysis performed in office setting using mechanical instruments; in this case, at the end of the procedure, a modified Word's catheter was inserted into the uterine cavity to prevent formation of new synechiae.

Results

All the surgical procedures were performed without any complication, and a healthy endometrium was observed for all three patients. No further synechiolysis was required after primary surgery for patients 2 and 3, while further adhesiolysis was needed for patient 1 after removal of Word's catheter.

Conclusions

Thanks to technical innovations, development of new techniques and anti-adhesion strategies, hysteroscopy has confirmed to be the gold standard technique for the treatment of Asherman's Syndrome.

<https://player.vimeo.com/video/717687401?autoplay=1>

**ES31-0623 -
Best Selected Videos**

Ten steps robotic intensive staging for early-stage ovarian cancer

Aniello Foresta¹, Riccardo Oliva¹, Camilla Certelli¹, Giovanni Scambia², Anna Fagotti², Valerio Gallotta²

¹Catholic University of the Sacred Heart, Department of Woman- Child and Public Health, Roma, Italy

²Fondazione Policlinico Universitario A. Gemelli- IRCCS, Department of Woman- Child and Public Health, Roma, Italy

Background

One-third of the patients with ovarian cancer (OC) is diagnosed with FIGO stage I-II, and their five-year survival is up to 90% [1,2]. Adequate treatment of early ovarian cancer (EOC) depends on the correct stage of the patient [3,4]. The feasibility and safety of minimally invasive surgery (MIS) for EOC is known and can be offered to selected patients [5]. No relevant differences between robotic and laparoscopic approaches for EOC staging are described in Literature [6].

Methods

We report the case of a 54 years-old patient diagnosed with an 81mm adnexal mass. DaVinci robotic system was used to perform surgery with four 8mm trocars along the transverse umbilical line, and 10mm trocar in Palmer's point. The instruments we used were ProGrasp Forceps, fenestrated bipolar, and monopolar curved scissors. Here we aim to standardize the robotic technique for EOC staging in ten steps.

Results

We have identified ten key steps to perform this procedure safely and effectively: Access to pelvic retroperitoneum; Identification of the ureter with development of pararectal and paravesical spaces; Closure of the uterine artery and section of ovarian pedicles and mobilization of adnexal mass with no-touch isolation technique; Development of rectovaginal and vesico-vaginal septum; Endobag extraction of surgical specimen; Access to lumbo-aortic retroperitoneum; Infiltration of the ovarian pedicle with indocyanine green then visualization and dissection of sentinel lymph node (LN); dissection of paracaval LN; dissection of inframesenteric LN; dissection of supramesenteric LN. Surgical time was 180 min and blood loss was 100cc without intraoperative complications. The patient was discharged on the 4th postoperative day without complications. Histology revealed a FIGO Stage IIA G3 serous endometrioid ovarian carcinoma.

Conclusions

Robotic staging of EOC in ten steps is a safe and feasible technique that must be performed by an experienced oncological surgeon in referral centres.

<https://player.vimeo.com/video/724593909?autoplay=1>

ABSTRACTS IN PLENARY SESSIONS

ES31-0399 - Endometriosis

Segmental resection for colorectal endometriosis with mini-laparotomy: to do or not to do?

Maciej Pliszkiwicz¹, Joanna Jacko¹, Marek Stańczyk², B. Paweł Siekierski¹

¹Medicover Hospital, Gynaecology, Warszawa, Poland

²Szpital Wolski, Oddział Chirurgii Ogólnej i Onkologicznej, Warszawa, Poland

Background

Colorectal surgery for bowel endometriosis is a growing necessity in everyday practice, therefore potential modifications of surgical techniques should be assessed, as they may yield positive results for both the patients and the healthcare system. We resolved to perform a comparison of two techniques of segmental resection for bowel endometriosis, in order to assess whether any of these techniques shows potential benefits over the other, and what would be their applicability in everyday surgical practice.

Methods

This study involved 94 patients with colorectal endometriosis, who underwent extensive endometriosis surgery that included a segmental resection of the sigmoid/rectum with mechanical reanastomosis. All procedures were conducted in laparoscopy, between January 2019 and May 2022, and involved 63 procedures with mini-laparotomy access, and 31 procedures with bowel resection using the method presented in this video. The assessed parameters included C-reactive protein, haemoglobin, and WBC levels at 48 and 96 hours postoperatively, as well as surgery duration, and hospital stay duration. The video shows an example of the technique applied, in an infertile patient with colorectal endometriosis, and an additional feature - a double pelvic kidney, notably interfering with surgery.

Results

There was no significant difference between study groups in terms of haemoglobin levels and WBC levels at 48 and 96 hours. However, we have noted significantly lower C-reactive protein levels at both 48 and 96 hours postoperatively, as well as significantly shorter surgery durations (median duration difference of 1 hour) and hospitalisation duration (median duration difference of 1 day).

Conclusions

Our results may indicate that a limited change in surgical technique, such as the one presented in this video, may yield substantially better results for both patients and healthcare providers, by improving patients' postoperative course and reducing costs related to excessive hospital stay duration.

<https://player.vimeo.com/video/712207694?autoplay=1>

**ES31-0457 -
Complications I Training**

Towards better informed consent in ambulatory hysteroscopy: a pivotal study of information source, anxiety and acceptability of modern office-based diagnostic and operative procedures

Maria Luigia Spinelli¹, Laura Scivoli², Fatoumata Bodiang-Stadlmayr³, Werner Stadlmayr³

¹*Geburt und Familie - Praxis Dr. med. Werner Stadlmayr, Center for Obstetrics and Gynecology, Aarau, Switzerland*

²*Geburt und Familie- Praxis Dr.med. Werner Stadlmayr, Center for Obstetrics and Gynecology, Aarau, Switzerland*

³*Geburt und Familie - Praxis Dr.med. Werner Stadlmayr, Center for Obstetrics and Gynecology, Aarau, Switzerland*

Background

Modern office diagnostic and operative hysteroscopy (OH) with vaginoscopic approach without anaesthesia has revolutionized the diagnostic and therapeutic work up of uterine pathologies with enormous advantage for the patients. However, potential patients' misconceptions may impair the informed consent process, and eventually the overall success of the therapeutic care. We aimed at a better understanding of patients' baseline knowledge and sources of information regarding OH, in order to improve pre-procedure counselling, provide reliable educational materials, and ultimately, optimize therapeutic outcomes.

Methods

A pivotal prospective cohort study was performed at our medical Centre. Patients who were offered OH as part of their diagnostic and therapeutic work-up were queried about expectations, knowledge, and sources of information regarding OH before pre-procedure counselling. Subjects' anxiety (modified State Trait Anxiety Inventory) and procedure acceptability (modified Patient Acceptability Scale) were assessed before and after counselling. Statistics were calculated using paired t and Mann Whitney tests.

Results

An international cohort of 42 patients, originally from 7 different Countries, completed the survey. 69.2% of them did research on OH before the visit. The most common sources of information were people including friends, family, and other doctors (42.1%), YouTube (29.7%), and medical websites (26.6%). Risks (95.4%), benefits (85.3%), and recovery issues (70.8%) were mostly investigated. Only 23.3% patients obtained reliable and current data about OH, while 74.5% received misleading/inadequate reports about varied issues such as instrumentation, setting, technique, pain, anaesthesia, risks, and postoperative recovery. 2.2% did not reach/understand enough information. A statistically significant difference was observed between the baseline and the pre-procedure anxiety score (37.16 SD 12.57 vs 33.77 SD 8.93; $p=.0165$) as well as the baseline and the pre-procedure acceptability score (3.81 SD 1.33 vs 1.23 SD 1.74; $p=.0029$).

Conclusions

This pivotal study identified a diffuse and varied misunderstanding of OH including significant misconceptions about the procedure as well as patients' preparation and risks. Pre-procedure counselling reduced anxiety and increased the acceptability of the procedure. Although worldwide spread, the concept of modern OH may remain misunderstood to the patients. Awareness of the gaps in patient knowledge and the sources of information may optimize preoperative counselling and ultimately improve the therapeutic care.

**ES31-0009 -
Urogynaecology**

Tension free laparoscopic colposuspension with intracorporeal sliding knot technique for stress urinary incontinence. Demonstration of technique and outcomes.

Abdalla Fayyad¹

¹*Yarmouk University School of Medicine, Obstetrics and Gynaecology, Irbid, Jordan*

Background

In the era of continued safety concerns about vaginal tapes for stress urinary incontinence, colposuspension has gained popularity over the last four years. Laparoscopic colposuspension (LC) has the same efficacy as open colposuspension, with the advantages of the laparoscopic approach. Complications of LC include post operative voiding dysfunction and new onset overactive bladder. We hypothesise that tying the LC sutures in a tension free fashion reduces the incidence of voiding dysfunction and overactive bladder post operatively. The technical challenge lies in controlling and maintaining the tension of the knots of LC. The aim of this study is to evaluate the feasibility and outcomes of tension free laparoscopic colposuspension (LC) using intracorporeal sliding knot technique for suture tying. The video will demonstrate a step-by-step approach of tension free LC with intracorporeal sliding knot technique.

Methods

45 consecutive women with a diagnosis of urodynamic stress incontinence who underwent tension free LC with intracorporeal sliding knot technique were prospectively evaluated. All patients had bladder neck hypermobility on clinical examination. The modified LC involved insertion of three sutures on either side, the first at the level of the upper half of the urethra, the second at the level of the bladder neck and the third suture was placed one centimetre cranial to the second suture. All sutures were passed twice through the vagina and then through the Cooper's ligaments bilaterally. All sutures were tied with intracorporeal sliding knot technique in a tension free fashion. All patients had a urethral catheter that was removed next morning. All women filled the King's Health questionnaire for urinary incontinence pre and post operatively, and the patient global impression of improvement for urinary incontinence post operatively. Patients were followed up at three months, one year and yearly. Cure of stress urinary incontinence was defined as "none" or "little" on the King's Health Questionnaire and PGII of "much better" or "very much better".

Results

No intra operative complications were recorded. All patients were discharged home the next day. There were no cases of voiding dysfunction post operatively. 38 women (84.4%) reported cure of their stress urinary incontinence as defined above. No patients developed bothersome posterior vaginal wall prolapse not needed intervention for new onset posterior vaginal wall prolapse post operatively. New onset urgency was reported in 5 women (11%), and one woman needed anticholinergic medications for the urgency.

Conclusions

In the era of continued safety concerns about vaginal tapes for stress urinary incontinence, tension free LC with intracorporeal sliding knot technique is feasible and has a comparable efficacy to traditional colposuspension. Our data suggests that this technique has a more favourable complications rate in terms of the incidence of postoperative voiding dysfunction and new onset posterior vaginal wall prolapse.

<https://player.vimeo.com/video/692187434?autoplay=1>

**ES31-0023 -
Hysteroscopy**

Comparative effectiveness of transvaginal versus hysteroscopic approach in patients with symptomatic caesarean scar defect

Wei Xia¹, Zhang Jian¹

¹International Peace Maternity and Child Health Hospital- School of Medicine- Shanghai Jiao Tong University, Gynecology, Shanghai, China

Background

Caesarean section (CS) is by far the commonest major operation worldwide and the associated complications also increased accordingly. This retrospective study was conducted to compare the efficacy between transvaginal repair and hysteroscopic resection in improving caesarean scar defect (CSD)-associated postmenstrual spotting.

Methods

In total, 346 patients were included in the study between June 2017 and June 2019. The propensity score matching (PSM) analysis was performed to adjust the baseline differences, 68 patients in the transvaginal group and 68 patients in the hysteroscopic group were analysed. Perioperative parameters including operation time, intraoperative blood loss, operative complications, hospitalization duration, hospitalization costs, pre- and postoperative anatomical indicators, postoperative spotting symptom were compared between the two groups.

Results

The improvement rate of postmenstrual spotting in the transvaginal group at the 3rd, 6th, 9th, and 12th months after surgery was 86%, 88%, 84%, and 85%, which was higher than 63%, 68%, 68%, and 70% in the hysteroscopic group, respectively (all $P < 0.05$). The median of the total days of spotting improved significantly at the 3rd month after surgery and did not change over time in each group within one year after surgery ($P > 0.05$). After surgery, the disappearance rate of the caesarean scar defect and the increase in the thickness of the residual myometrium in the transvaginal group were significantly higher than those in the hysteroscopic group ($P < 0.05$).

Conclusions

Compared to hysteroscopic resection, transvaginal repair is significantly better than hysteroscopic resection in improving postmenstrual spotting and the anatomical indicators of the lower uterus, but hysteroscopic resection has the advantages of shorter operation time, less significant intraoperative blood loss and complications, shorter hospitalization duration, and lower hospitalization costs.

**ES31-0570 -
Endometriosis I Reproductive Surgery**

The effect of age on the distribution and symptoms of endometriosis: a multicentre prospective national database study

Jonathan Lewin¹, Arvind Vashisht¹, Ertan Saridogan¹, Katy Vincent², Christian Becker², Martin Hirsch²

¹University College London Hospital, Gynaecology, London, United Kingdom

²John Radcliffe Hospital, Gynaecology, Oxford, United Kingdom

Background

Endometriosis is a leading cause of pelvic pain in adolescent patients. However, the natural history of the disease is not well understood. The aim of this study is to determine how endometriosis lesion distribution and symptoms vary with age amongst patients undergoing endometriosis surgery.

Methods

We analysed prospectively collected data from the British Society for Gynaecological Endoscopy (BSGE) database of all patients aged between 13- and 55-years undergoing surgery for severe endometriosis between 2012 and 2021 at 104 endometriosis centres. The relationship between age and lesion distribution was tested by chi-squared, ANOVA and logistic regression (adjusted for previous surgery), and between age and symptoms by Mann-Whitney-U and Spearman's correlation.

Results

We analysed data from 13932 operations. Mean age was 36.0 years (SD 7.5 years). Amongst these, 181 (1.3%) patients were adolescent (13-19) and 847 (6.1%) were young adults (20-24). Compared to older adults (>24 years), young adult patients were more likely to have superficial endometriosis (OR 1.619, 95%CI 1.368-1.926, $p<.001$), and less likely to have deep endometriosis of the bowel (OR 0.532 95%CI 0.458-0.620, $p<.001$), ovary (OR 0.400, 95%CI 0.343-0.466, $p<.001$), bladder (OR 0.605, 95%CI 0.411-0.858, $p<.006$), and pelvic sidewall or uterosacral ligament (USL) (OR 0.742, 95%CI 0.596-0.935, $p<.001$). Compared to older adults, adolescent patients were significantly less likely to have endometriosis of the bowel (OR 0.491 95% CI 0.361-0.675, $p<.001$), ovary (OR 0.440, 95%CI 0.317-0.601, $p<.001$), and pelvic sidewall/USL (OR 0.460, 95%CI 0.314-0.697, $p<.001$). Each additional year of age was associated with increased odds of having deep endometriosis of the bowel (aOR 1.031 per year, 95%CI 1.025-1.037, $p<.001$), ovary (aOR 1.031 per year, 95%CI 1.026-1.036, $p<.001$), and pelvic sidewall/USL (aOR 1.015 per year, 95%CI 1.007-1.023, $p<.001$), but decreased odds of having superficial endometriosis (aOR 0.968, 95%CI 0.963-0.973, $p<.001$). Total number of anatomical structures affected by deep endometriosis was higher among older adults than among young adults or adolescents (mean 5.868 vs 4.810 vs 4.558, $p<.001$). Compared to older adults, young adults had more severe scores for premenstrual pain (mean 6.816 vs 6.458, $p=.007$), menstrual pain (mean 8.491 vs 8.114, $p=.002$), dyspareunia (mean 5.927 vs 5.126, $p<.001$), and bladder pain (mean 2.858 vs 2.420, $p<.001$). Significant but small negative correlations were found between age and all symptoms except for non-cyclical pain, lower back pain, diarrhoea, and constipation.

Conclusions

This study provides evidence of disease progression in the natural history of endometriosis. Despite differences in lesion distribution, adolescent patients may have severe disease, and symptoms are comparable between younger and older patients. Adolescents and young people with endometriosis should be prioritised and treated along similar care pathways to adults.

ES31-0100 - Adhesions

Laparoscopic excision of a noncommunicating functional rudimentary horn: recognition and release of the ureter from solid adhesions

Olga Triantafyllidou¹, Dimitrios Mpalafoutas¹, Theodoros Kalampokas¹, Emmanouil Kalampokas¹, Panagiotis Christopoulos¹, Nikos Vlahos¹

¹Aretaieion University Hospital- Athens, 2nd Department of Obstetrics and Gynecology, Athens, Greece

Background

Hemi-uterus or class U4a, according to the ESHRE/ESGE classification of female genital tract congenital anomalies, with a rudimentary (functional) cavity characterized by the presence of a noncommunicating functional contralateral horn and is one of the various congenital abnormalities of the female genital tract caused by partial fusion of the müllerian ducts. We presented management of the patient with hemi-uterus and noncommunicating functional horn and severe endometriosis by laparoscopic excision of rudimentary horn, adhesiolysis and careful identification of the ureter.

Methods

26-year-old nulliparous woman admitted to the gynaecologic department with primary dysmenorrhea, chronic pelvic pain and dyspareunia. Two-dimensional transvaginal ultrasound and magnetic resonance (MRI) were performed and detected a hemi-uterus with a right rudimentary uterine hemicavity and solid mass close to the right ovary. The left tube and ovary were normal.

Results

The most important and difficult step in this surgery was freeing the ureter from the adhesions. The anatomy of the right side was altered. The primary step was the preparation of the extraperitoneal approach. The right round ligament was opened at the pelvic side wall but due to the solid adhesions and mass below the ovary it was difficult to identify the right ureter. The medial leaf of the broad ligament was dissected above the ureter. Then the ureter was released from the surrounding tissue, working directly on the adventitia of the ureter, and dissecting cautiously using the bipolar instrument. To dissect the farther part of the ureter, the forceps contralateral to the side of dissection strongly pulled the uterus at the round ligament so that the ureter can be seen in its length. Then the removal of the right rudimentary uterine horn was successfully performed.

Conclusions

Laparoscopic amputation of a noncommunicating functional rudimentary horn is considered the basic surgical treatment for women with hemi-uterus. A detailed diagnostic evaluation by ultrasound and MRI should be performed to avoid misdiagnoses of other anomalies with blind hemi cavity, which may be treated by hysteroscopy. These cases are often associated with severe endometriosis and extensive adhesions. The most important step in this procedure is freeing the ureter from the surrounding tissue before the removal of the rudimentary uterine horn. Careful release of the ureter along its entire length is a key prerequisite for avoiding injury to the ureter. Laparoscopic surgery with minimally invasive approach is an essential tool to treat these cases, achieving optimal results with low postsurgical pain and a short hospital stay.

<https://player.vimeo.com/video/709716986?autoplay=1>

**ES31-0614 -
Hysterectomy**

How to solve obstacles in initial cases of vaginal NOTES hysterectomy: Indonesia experience

Ferry Darmawan¹, Ichnandy Arief Rachman²

¹Indonesia Army Central Hospital Gatot Soebroto, Obstetrics & Gynecology, Jakarta, Indonesia

²KARMIG Center Indonesia Army Central Hospital Gatot Soebroto, Minimal Invasive Gynecology, Jakarta, Indonesia

Background

Natural Orifice Transluminal Endoscopic Surgery (NOTES) is one innovation in minimal access gynaecologic surgery. Vaginal NOTES hysterectomy is the simplest procedure that can be done through this approach. NOTES hysterectomy has better advantages that are aesthetics, less pain, and less length of hospital stay compared to conventional laparoscopic hysterectomy. This technique required new learning curve. In mastering NOTES total hysterectomy, there were some obstacles that need to be managed and evaluated. The aim of this presentation is to identify the obstacles and to evaluate how to start, manage and prevent problems for the initial case of NOTES total hysterectomy.

Methods

From 2017, our center, KARMIG Center was pioneered vaginal NOTES hysterectomy in Indonesia and has performed more than 100 cases of vaginal NOTES hysterectomy. KARMIG Center has also held NOTES training for our fellow. We did observational study from 100 initial procedures of NOTES hysterectomy.

Results

We found the mean operation time was 91.2 (65 – 125) minutes, blood loss was 110.5 (75 – 150) ml, VAS on day-1 post operation was 1.4 (1 - 3) with NSAIDs therapy, all patients were discharged from hospital one day after surgery. One complication case was bladder injury. One procedure was attributed with single incision laparoscopic surgery.

Conclusions

We observed the challenges to start vaginal NOTES hysterectomy were instrument and device limitation, case selection, technique, and skill obstacles intra operation. There are some tips and tricks for mastering vaginal NOTES hysterectomy based on Indonesia experience. NOTES total hysterectomy is feasible but need learning curve. Obstacles can be found in process of mastering NOTES total hysterectomy. Good case selection is essential to start NOTES total hysterectomy procedures. Avoid adhesion and adenomyosis case. The cases with no prior operation are good candidate for initial experience. The use of smart bipolar is also considered helpful and effective in NOTES total hysterectomy.

**ES31-0537 -
Robotic 1**

The new surgical robot Hugo™ RAS for total hysterectomy: a pilot study

*Luigi Pedone Anchorà¹, Giorgia Monterossi¹, Alessandro Gioè¹, Riccardo Oliva¹, Anna Fagotti¹,
Giovanni Scambia¹*

¹Fondazione Policlinico Universitario A. Gemelli IRCCS,

Department of Woman and Child Health and Public Health- Woman Health Area, Rome, Italy

Background

The robotic surgery industry is growing fast, and various companies are bringing their contribution to technological implementation. In this context, Medtronic introduced on the market one of the newest systems: Hugo™ RAS. The aim of this study was to investigate the performance, in terms of reliability and safety, of the new surgical robot Hugo™ RAS in a series of total hysterectomies.

Methods

This is a single-centre prospective study of a series of consecutive total hysterectomies performed with Hugo™ RAS.

All patients suitable to minimally invasive total hysterectomy +/- salpingo-oophorectomy were judged eligible for the study.

Exclusion criteria were preoperative diagnosis or clinical suspicion of gynaecological cancer.

In all cases, the "bridge" port placement and the "compact" docking configuration (where the ancillary port for the bed-side assistant is inserted on the Palmer's point) were adopted, and three robotics arms were used.

The total hysterectomy was performed step by step with uterine arteries ligation at the origin.

Surgical data and post-operative clinical data, including both early and late complications, were collected. Any malfunction or breakdown of the robotic system was collected.

Results

From March 2022, a total of 20 women were enrolled in the study and underwent total hysterectomy using Hugo™ RAS. Twelve of 20 patients (60.0%) underwent surgery due to uterine fibromatosis, 3 (15.0%) due to endometrial hyperplasia and 5 (25.0%) underwent prophylactic surgery due to BRCA-1 mutation.

Median age was 51 years, and median BMI was 24 kg/m². Eleven (55.0%) patients had previous abdominal surgery. The vast majority of patients (19, 95.0%) had an ASA score of 2, only 1 (5.0%) had an ASA score of 1.

Median uterine size at preoperative ultrasound was 77.5 mm (range: 62.9 mm – 12.5 mm).

Most patients (14, 70.0%) underwent concomitant bilateral salpingo-oophorectomy, while 5 (25.0%) underwent bilateral salpingectomy. One patient (5.0%), that had previous unilateral salpingo-oophorectomy, underwent concomitant unilateral salpingo-oophorectomy.

Among the entire series, in 1 case (5.0%) a fault occurred in a monopolar scissors. The problem took about 5 minutes to be solved without complications for the patient and without any need of surgical conversion.

Median docking time was 7.5 minutes (range: 3.5 minutes – 10 minutes). Median total operative time was 127 minutes (range: 98 minutes – 255 minutes).

The median estimated blood loss was 50 mL. No intraoperative complications were recorded.

The median time to discharge was 2 days (range: 2 days – 3 days).

During the follow up period, 1 patient (5.0%) experienced a grade 2 late complication. It was a urinary infection appeared on the seventh postoperative day and treated with oral antibiotics.

Conclusions

This is the first study exploring the use of the Hugo™ RAS in gynaecology. Hugo™ RAS seems to be safe and reliable. Further studies should confirm present data and investigate its use in other field of gynaecological surgery.

**ES31-0617 -
Robotic 2**

Ureteral endometriosis: a multidisciplinary approach to a silent disease

Alin Constantin¹, Henrik Zecha², Enikö Berkes¹

¹*Albertinen Hospital Hamburg, Obstetrics and Gynecology, Hamburg, Germany*

²*Albertinen Hospital Hamburg, Urology, Hamburg, Germany*

Background

Urinary tract endometriosis affects only the 0.3% to 6% of women affected by endometriosis, among which the most common localization is the bladder (84%-90%). The ureteral compression is rare but can lead to obstruction up to silent loss of renal function

Methods

Study objective: To demonstrate the safety and feasibility of laparoscopic robotic assisted approach to ureteral endometriosis and to highlight the importance of the multidisciplinary approach and the preoperative work-up.

Design: This is an educational video to explain the main steps of robotic assisted ureteroneocystostomy owing to endometriosis.

Setting: Tertiary care university hospital.

Case description:

A 43-year-old woman with a past history of endometriosis treated laparoscopically was referred to our clinic for grade II right hydronephrosis. Pelvic ultrasound demonstrated a 1,6-cm parametrial endometriotic nodule causing ureteral compression, diffuse adenomyosis and a 2,6cm endometrioma on the right ovary. Given that the patient had an absolute contraindication to hormonal therapy, we opted for robot-assisted laparoscopic complete resection of endometriosis. The procedure consisted in subtotal hysterectomy with bilateral salpingectomy excision of the right endometrioma, excision of the stenotic ureteral endometriosis nodule, right terminal partial ureterectomy and ureteroneocystostomy. Intrinsic ureteral endometriosis was confirmed by pathology. After 6 days, a cystography was accomplished to confirm anastomosis integrity, and the bladder catheter was removed. The patient was discharged on day 7 after a regular postoperative period. One month after the surgery, the patient refers wellbeing

Interventions: Preoperative insertion of JJ Stents. Laparoscopic robotic assisted subtotal hysterectomy, excision of the right endometrioma, excision of the stenotic ureteral endometriosis nodule, right terminal partial ureterectomy and ureteroneocystostomy.

Results

The procedure was uneventful, and the patient progressed to a full recovery. Operative times was 256 minutes. Estimated blood loss 120 mL. There were no intraoperative complications.

Conclusions

Clinicians should suspect ureteral endometriosis in premenopausal women with distal ureteral obstruction of uncertain cause. The main goals of the treatment should be preservation of renal function, relief of obstruction and prevention of recurrence. The multidisciplinary approach assures good clinical and surgical outcomes. The robotic approach in a complex procedure as surgical treatment of ureteral endometriosis is feasible and safe with good postoperative outcome. Further investigations with large comparative cohorts that include cost analysis are needed to fully assess the benefits achieved by robotic assistance.

<https://player.vimeo.com/video/722778466?autoplay=1>

**ES31-0083 -
Fibroids I Procedural**

Interobserver agreement of microvascular flow colour score and vascular index in fibroids and its correlation with 2D and 3D power Doppler outcomes: prospective cohort study.

Marissa Frijling¹, Barbara Stoelinga², Lynda Juffermans², Robert de Leeuw²,
Thierry van den Bosch³, Judith Huirne²

¹Amsterdam UMC- location Vrije Universiteit Amsterdam, Department of Obstetrics & Gynaecology,
De Boelelaan 1117- Amsterdam, The Netherlands

²Amsterdam UMC, Department of Obstetrics & Gynaecology, Amsterdam, The Netherlands

³UZ Leuven, thierry.vandenbosch@uzleuven.be, Leuven, Belgium

Background

Macro vascularity of fibroids can be quantified by two (2D) and three-dimensional (3D) power Doppler (PD) by a colour score (CS) or vascular index (VI), respectively. Micro vascularity may be of additional value to diagnose fibroids or to determine treatment options. Microvascular flow imaging (MVF) is able to display microvascular structures. Therefore, MVF may also be able to differentiate between fibroids with or without an avascular center. However, MVF and its quantification have not been compared yet with 2DPD or 3DPD. We evaluated the reproducibility and the correlation between MVF CS (1), 2DPD CS (2), MVF VI (3), and 3DPD VI(4).

Methods

Patients with one easily recognized fibroid of 1.5 to 10 cm were prospectively included. 2DPD and MVF CS were scored according to the Morphological Uterus Sonographic Assessment criteria. MVF VI was measured onsite and 3DPD VI offline. All images and measurements were performed by two experienced gynaecologists using a standardized protocol. The primary outcome was the intra- and interobserver agreement of MVF VI and MVF CS. Secondary outcomes were the correlation between MVF CS (1), MVF VI (2), 3DPD VI (3), and 2DPD CS (4) in the entire fibroid (I), the centre (II) and the capsule (III).

Results

In 30 consecutively included patients inter- and intra-observer correlations were good to excellent. Preliminary results vary between ICC 0.872 (95% CI 0,733-0,939) in 2DPD CS of the entire fibroid to ICC 0.996 (95% CI 0.990-0.998) in MVF VI of the entire fibroid. MVF VI (1) and MVF CS (2) correlated (very) strongly (preliminary results: total fibroid $r = 0.774$; centre $r = 0.869$; capsule $r = 0.722$; all $p < 0.05$). The correlation between MVF CS (1) or MVF VI (2) in all volumes, and 3DPD VI (3) in all volumes or 2DPD CS (4) in the centre, was overall strong. MVF CS (1) or MVF VI (2) in all volumes were overall moderate related to 2DPD CS (4) in the entire fibroid or the capsule. Preliminary results vary between MVF CS centre vs. 3DPD VI centre $r = 0.749$, $p < 0.05$: to MVF VI capsule vs. 2DPD CS capsule $r = 0.428$, $p > 0.05$).

Conclusions

MVF CS and MVF VI are reproducible. MVF CS and MVF VI were (very) strongly correlated, and these parameters were moderate to strongly correlated with 3D VI or 2DPD CS. MVF of the fibroids centre may be discriminating to assess the growth potential of fibroids and its responsiveness to therapy.

**ES31-0485 -
Reproductive Surgery**

Transvaginal uterine niche repair: minimal invasive approach and first results in infertility patients

Helena Van Kerrebroeck¹, Eleonora La Fera², Jean Christophe Schobbens¹, Ursula Catena², Giovanni Scambia², Rudi Campo³

¹Ziekenhuis Oost-Limburg- Genk- Belgium, Department of Gynecology- obstetrics and fertility, Genk, Belgium

²Fondazione Policlinico Universitario A. Gemelli- IRCCS,

Dipartimento Scienze Salute della Donna e del Bambino e di Sanità Pubblica, Rome, Italy

³Life Expert Center- Leuven- Belgium., Institute for Fertility & Embryology, Leuven, Belgium

Background

The uterine niche (isthmocele) is an iatrogenic defect of the uterine wall that can occur after caesarean section. It presents very heterogeneously in terms of degrees of severity and symptomatology. It can be asymptomatic or may be symptomatic with prolonged uterine bleeding, pelvic pain, and not least, secondary infertility (implantation failure, recurrent miscarriages). Although there are several repair techniques for the uterine niche according to severity and symptomatology, there are no guidelines or studies at present saying which technique is the best.

Methods

This is a prospective, monocentric, interventional study that started in August 2019 and is ongoing. All women included were symptomatic with a history of secondary infertility and/or recurrent miscarriages. All patients perform pelvic magnetic resonance (MRI), ultrasound, and diagnostic hysteroscopy preoperatively. Only women with a residual myometrial thickness (RMT) less than 3 mm are enrolled. The technique starts with the opening of the anterior fornix. By hysteroscopic transillumination, the lower uterine segment and in particular the edge of the defect is revealed. Excision of the thinned myometrial tissue and reconstruction of myometrial integrity is performed and finally, a hysteroscopy and ultrasound check-up are performed to evaluate the result during surgery. Patients were seen by contrast sonography after three months and follow-up was done until pregnancy and delivery.

Results

Between August 2019 and June 2022 twenty-five patients were enrolled. Twenty underwent already hysteroscopic control after 3 months. Of these, 17 (85%) had complete restoration of the uterine wall thickness evidenced by both hysteroscopy and ultrasonography. Three of them had a recurrent niche. Nine patients are at least 6 months after surgery and tried to conceive. Seven of them (78%) had a pregnancy with a favourable obstetric outcome.

In the end, surgical time was less than one hour with only one complication (hematoma), and all patients could go home the day after without any painkillers or discomfort.

Conclusions

Transvaginal isthmocele repair can offer a safe, rapid, and effective alternative to laparoscopic or laparotomic techniques.

Partial results of our study show that the transvaginal approach represents a valid minimal invasive option for patients with very thin RMT and desiring pregnancy. This technique appears to be less time-consuming, with short hospitalization, rapid recovery, and with a good result in re-establishing the myometrial integrity with the resolution of symptoms and favourable obstetric outcomes.

Predictive factors of sentinel lymph node failed mapping in endometrial carcinoma patients: a systematic review and meta-analysis

Giulia Rovero¹, Raffone Antonio², Raimondo Diego¹, Casadio Paolo¹, Mollo Antonio³, Seracchioli Renato¹

¹Division of Gynaecology and Human Reproduction Physiopathology- Department of Medical and Surgical Sciences DIMEC., IRCCS Azienda Ospedaliero-

Universitaria di Bologna. S. Orsola Hospital. University of Bologna- Via Massarenti 13- Bologna 40138- Italy, Bologna, Italy

²Gynecology and Obstetrics Unit- Department of Neuroscience- Reproductive Sciences and Dentistry- School of Medicine, University of Naples Federico II, Naples, Italy

³Gynecology and Obstetrics Unit- Department of Medicine- Surgery and Dentistry "Schola Medica Salernitana", University of Salerno- 84081 Baronissi- Italy, Baronissi, Italy

Background

In endometrial carcinoma (EC) patients, sentinel lymph node (SLN) bilateral mapping fails from 20% to 25% of cases, with several factors affecting likelihood of detection. The aim of this study is to assess predictive factors of SLN failed mapping in EC patients undergoing SLN biopsy.

Methods

A systematic review and a meta-analysis were performed searching all studies assessing predictive factors of SLN failed mapping in apparent uterine-confined EC patients undergoing SLN biopsy through the cervical injection of indocyanine green (ICG). The associations between SLN failed mapping and predictive factors of failure were assessed calculating the odds ratio (OR) with 95% confidence intervals (CI).

Results

Six studies with a total of 1,345 patients were included. Compared to patients with SLN bilateral successful mapping, patients with SLN failed mapping showed an OR of: 1.39 (p=0.41) for BMI>30 kg/m²; 1.72 (p=0.24) for menopausal status; 1.19 (p=0.74) for adenomyosis; 0.86 (p=0.55) for prior pelvic surgery; 2.38 (p=0.26) for prior cervical surgery; 0.96 (p=0.89) for prior caesarean section; 1.39 (p=0.70) for lysis of adhesions during surgery before SLN biopsy; 1.77 (p=0.02) for ICG dose<3mL; 1.28 (p=0.31) for deep myometrial invasion; 1.21 (p=0.42) for FIGO grade 3; 1.89 (p=0.01) for FIGO stages III-IV; 1.62 (p=0.07) for non-endometrioid histotype; 1.29 (p=0.25) for LVSI; 4.11 (p<0.0001) for enlarged lymph nodes; 1.71 (p=0.022) for lymph node involvement.

Table 1. Summary of pooled odds ratios with 95% confidence intervals assessing the associations between SLN failed mapping and predictive factors of failure

Predictive factor of failure	OR [CI 95%]	p-value
BMI>30 Kg/m ²	1.39 [0.63 – 3.07]	0.41
Menopausal status	1.72 [0.69 – 4.31]	0.24
Adenomyosis	1.19 [0.43 – 3.30]	0.74
Prior pelvic surgery	0.86 [0.52 – 1.43]	0.55
Prior cervical surgery	2.38 [0.53 – 10.77]	0.26
Prior caesarean section	0.96 [0.49 – 1.88]	0.89
Lysis of adhesions	1.39 [0.27 – 7.23]	0.70
ICG dose < 3mL	1.77 [1.11 – 2.83]	0.02
Deep myometrial invasion	1.28 [0.80 – 2.03]	0.31
FIGO grade 3	1.21 [0.76 – 1.92]	0.42
FIGO stages III-IV	1.89 [1.16 – 3.09]	0.01
Non-endometrioid histotype	1.62 [0.96 – 2.74]	0.07
LVSI	1.29 [0.84 – 1.99]	0.25
Enlarged lymph nodes	4.11 [2.30 – 7.35]	< 0.0001
Lymph node involvement	1.71 [1.08 – 2.72]	0.022

OR: odds ratio; **CI:** confidence intervals; **BMI:** body mass index; **ICG:** Indocyanine Green; **FIGO:** International Federation of Gynecology and Obstetrics; **LVSI:** lymphovascular space invasion

Conclusions

ICG dose<3mL, FIGO stage III-IV, enlarged lymph nodes and lymph node involvement are predictive factors of SLN failed mapping in EC patients.

**ES31-0624 -
Neuropelvelogy**

Preserving the nerves in the bowel endometriosis shaving, disc and segmental excision: technical, anatomical and fertility aspects

Helder Ferreira¹

¹Centro Hospitalar Universitário do Porto, Minimally Invasive Gynaecological Surgery, Porto, Portugal

Background

Endometriosis is a benign, estrogen-dependent disease that may affect the affected women's quality of life. It is characterized by ectopic localization of endometrial-like tissue on pelvic organs and, rarely, outside the abdominal cavity. The reported prevalence ranges from 6 to 10%, and medical treatment (combined oral contraceptives and progestins) is considered first-line therapy. In addition, surgical treatment is recommended for patients' poor responder to hormonal therapy, infertility (assisted reproduction may be an option), and evidence of organ damage (mainly bowel, bladder, and ureter). Bowel involvement is reported in up to 12% of patients, with the rectum being the most common site. In severe stages, bowel endometriosis can be as high as 37%. Bowel surgery is indicated in cases of evidence of significant stenosis, symptomatic lesions (chronic pelvic pain resistant to medical therapy, dyschezia, rectal bleeding, and progressive constipation up to bowel obstruction), or to improve fertility. Several procedures for bowel surgery (rectal shaving, discoid excision, and colorectal resection) could be considered according to size (longitudinal and transverse diameters), appearance (plane, convex, multifocal), and location (distance from the anal verge) of the nodule, and previous bowel surgery.

Methods

The excision technique depends on the longitudinal, anteroposterior and transverse diameters of bowel endometriotic nodules. The pelvic nerves from the autonomic and somatic networks are many times involved by endometriosis causing bowel dysfunction. In other cases, the nerve injury during the surgery may cause post-operatively severe impairment of the urinary/bladder, bowel and sexual functions.

Results

A total of 231 patients were considered eligible for analysis, with a median age of 34 years using the different techniques (shaving, discoid and segmental resection) to preserve the innervation and the pelvic organs' functions. The median operative time was 125 min, with an estimated blood loss of 80 mL and a median diameter of removed rectal nodule of 28 mm.

There was an improvement of all symptoms in the immediate postoperative follow-up. Among all patients with childbearing desire, the pregnancy rate found was 52.4% and was obtained by in vitro fertilization techniques in 28% of cases.

We had 7 cases of transitory bladder retention and 17 instances of transitory bowel constipation.

Conclusions

Laparoscopy, with its augmented imaging allowing the identification of smaller anatomical structures like the nerves, has been a significant step towards better surgical treatment of endometriosis patients. Following the neuropelviology knowledge and technical principles, we can approach our endometriosis bowel patients more safely and efficiently. Deep endometriosis excision contributes to a significant improvement of symptoms with an acceptable complications' rate.

**ES31-0565 -
Endometriosis**

Surgical management of bladder endometriosis: 12 years of experience from a reference center

Natacha Sousa¹, Margarida Caç, Sónia Barata³, Filipa Osório³, Inês Reis³

¹Hospital de Braga, Serviço Ginecologia e Obstetrícia, Braga, Portugal

²Centro Hospitalar Universitário Lisboa Norte, Gynecology and Obstetrics, Lisboa, Portugal

³Hospital da Luz Lisboa, Gynecology and Obstetrics, Lisboa, Portugal

Background

The aim of this study was to evaluate clinical presentation, imagiological evaluation, surgical techniques and outcomes in women who undergone laparoscopic surgery for bladder endometriosis.

Methods

A retrospective descriptive study was designed, including women with history of laparoscopic surgery for pelvic anterior compartment endometriosis at a reference endometriosis centre, between January 2011 and March 2022.

Results

From a total of 106 women included in the study, mean age was 35.3 ± 4.5 years-old, 25.4% were active smokers and 46.2% had a history of infertility. Regarding clinical presentation, symptoms were evaluated by Visual Analogue Scale and the frequency of reported levels ≥ 5 grade were, respectively, dysmenorrhea in 85.6%, pelvic chronic pain in 30.2%, dysuria in 32.1% and dyspareunia in 75.4% of the patients. Only 2 women referred haematuria. Most of the women (54,3%) didn't have elevated CA-125 levels at diagnosis. Twenty-seven patients had a previous history of endometriosis surgery, 9 of them due to bladder endometriosis. All the surgeries were performed by laparoscopic approach and most of the lesions were superficial, located in vesico-uterine fold (n=71, 66,9%), while the remaining lesions (n=35, 33.1%) were in the bladder wall (16,9% in the dome, 9.4% in the posterior wall and 6.6% involving the trigone). Regarding bladder wall lesions (n=35), a vesical nodule was identified in the ultrasound evaluation in 63% of the cases and in 94% of the pelvic Magnetic Resonance Imaging. Concerning surgical technique in these cases, a partial cystectomy was performed in 29 patients (82.8%) and shaving of the bladder wall in 6 cases (17.2%). In 35 of all the surgeries a complementary cystoscopy was performed to guide ureteral stent placement (including 93% of the cases where a partial cystectomy was performed). Additional procedures were performed in most surgeries: excision of a posterior pelvic compartment nodule in 87.0%, endometrioma removal in 49.1%, and ureter lesion excision in 14.1% of the cases. Considering short-term complications, the most common was cystitis (n=10, 9.4%), followed by urinary retention (n=2, 1.9%), pelvic hematoma (n=2, 1.9%), acute pyelonephritis (n=1, 0.9%) and vesicovaginal fistula with surgical repair in another case. Most common long-term adverse outcomes included renal dysfunction (n=4, 3.6%), urinary incontinence (n=4, 3.6%) and persistent dysuria (n=3, 2.8%). From the available records, 11 out of the 106 women had a surgical reintervention for endometriosis, none of them concerning bladder endometriosis recurrence, and 31 of women had at least one pregnancy after surgery, most of them by assisted reproduction techniques.

Conclusions

Bladder endometriosis is rare and due to the nonspecific clinical presentation, an early diagnosis is often difficult to achieve. Bladder endometriosis surgery seems to improve urinary symptoms, with a low rate of intra- and postoperative complications as well as a low rate of recurrence and long-term bladder capacity.

**ES31-0615 -
Adenomyosis**

Laparoscopic adenomyoma excision: undermining technique: a novel approach

Rajendra Sankpal¹

¹Medical Director- SAGE Hospit, Gynecological Endoscopy, Mumbai, India

Background

Adenomyomas have been seen with increasing frequency. Most of the time adenomyomas are incidental diagnosed during the course of laparoscopic myomectomy. The laparoscopic surgery for adenomyoma is technically challenging, time consuming. Resection of adenomyoma is difficult due to lack of demarkation between the normal myometrium and adenomyomatous tissue, fragile nature of the tissue and extension of adenomyomas within the endometrial cavity. Complete resection of adenomyoma is not possible. Laparoscopic suturing of the uterine defect is also challenging. Therefore, recurrence of the disease is well known. Therefore, laparoscopic excision of adenomyoma requires reevaluation and simplified reproducible technique.

Methods

We evaluated the “**Novel undermining Technique**” of Laparoscopic Resection of Focal adenomyoma in 104 patients. After injecting the vasopressin into the adenomyoma we utilised a circular incision on the focal adenomyoma with a cold scissors. In the beginning a large wedge of the adenomyoma tissue resected. This is followed by peripheral resection of adenomyomatous tissue underneath the margin of the uterine defect in order to make the edges pliable and more amenable for effective laparoscopic suturing in two layers. The amount of tissue to be resected depends upon the laparoscopic visual impression of the adenomyoma and correlation with the size depicted on preoperative sonography and MRI.

Results

With this technique the operative time and blood loss were minimised significantly even for larger adenomyomas. Significant reduction in symptomatology in 3 months to 4 years following surgery was noted in 80-86% of patients. 10% patient had recurrence of the adenomyomas in between 2-6 years.

Conclusions

With the Novel Undermining Technique Focal adenomyomas of less than 7 cm can be efficiently and safely removed laparoscopically with short operative time, minimal blood loss and with better approximation of the uterine defect. Larger adenomyomas more than 7 cm and diffuse adenomyosis are better managed with laparotomy

The applicability of neuronavigation-assisted laparoscopy on deep endometriosis recurrence treatment

Priscilla Pessoa¹, Fernanda Dishchekenian², Mariana Corinti³, Fernanda Asencio¹, Ricardo D'Amico⁴

¹Hospital Israelita Albert Einstein, Gynecology, Sao Paulo, Brazil

²Hospital Moriah- Hospital Israelita Albert Einstein, Gynecology, Sao Paulo, Brazil

³Hospital Israelita Albert Einstein, Gynaecology, Sao Paulo, Brazil

⁴Hospital Salvalus, Gynecology, Sao Paulo, Brazil

Background

To present neuronavigation as a tool for challenging laparoscopic endometriosis treatment.

Methods

A 44-year-old patient that complained of chronic pelvic pain and deep dyspareunia. Patient had already undergone deep endometriosis laparoscopic treatment and presented recurrence. Physical examination showed a painful left lateral vaginal wall nodule. MRI showed retractile tissue near the posterior vaginal wall infiltrating uterosacral ligament and paracervical region, measuring 2.4 cm and in intimate contact to the internal iliac nerve plexus. Due to these findings and the possibility of important anatomical distortion by the previous surgical approach neuronavigation-assisted laparoscopy was indicated.

Surgery started with electrodes neuronavigation placement. One electrode was placed at the external rectal sphincter muscle and another one at the internal anal sphincter muscle. The cavity inventory showed an extensive retrocervical lesion with local adhesion and retraction, blocked left ovarian fossa and left periurethral region compromising. In order to perform a safe excision of the retrocervical lesion surgery started by left ureterolysis.

Due to lesion proximity to the path of the hypogastric nerve neuronavigation electrodes was used as an accessory tool, which allows a more precise nerve path definition and a consequent safer procedure, by avoiding its lesion. The electrode is activated across the entire topography of the nerve to define its limits and ensure regions free of nerve pathway.

Results

Patient had satisfactory postoperative evolution, with an appropriate pain control and no bladder or bowel dysfunction. Pathology report confirmed endometriosis.

Conclusions

Endometriosis is a chronic disease that affects about 15% of women of reproductive age. Among the major morbidity symptoms are chronic pelvic pain, dyspareunia, infertility, urinary and bowel symptoms. Endometriosis patients commonly present deep involvement lesions, which explains the high intraoperative risk of noble structures in adverted injuries.

Neuronavigation appears as a tool to increase surgical approach safety, by reducing injury risks of sacral plexus, hypogastric nerve and, consequently, be able to decrease postoperative rates of overactive bladder and bowel emptying disorders.

<https://player.vimeo.com/video/710557903?autoplay=1>

**ES31-0594 -
Hysteroscopy I ESGE I GCH**

Step-by-step hysteroscopic treatment of complete uterine septum associated or not with cervical anomalies

Alfonso Manzi¹, Virginia Foreste², Simona Martone³, Brunella Zizolfi²

¹University of Naples "Federico II",

Department of Neuroscience- Reproductive Sciences and Dentistry- School of Medicine, Naples, Italy

²University of Naples "Federico II",

Department of Neurosciences- Reproductive Sciences and Dentistry- School of Medicine, Naples, Italy

³University of Siena, Department of Molecular and Developmental Medicine- Obstetrics and Gynecology, Siena, Italy

Background

To demonstrate hysteroscopic treatment of 3 different variations of incomplete müllerian duct fusion and reabsorption, using miniaturized instruments.

Methods

We present three patients with complete uterine septum and different cervical patterns who underwent metroplasty in operating room under general anaesthesia: Case 1 is a 33-year-old woman with history of primary infertility, complete uterine septum and normal cervix (Class U2bC0V0 according to ESHRE/ESGE classification, used to describe also next cases); Case 2 is a 34-year-old woman with infertility and abnormal vaginal bleeding, diagnosed with complete uterine, cervical septum and nonobstructive longitudinal vaginal septum (class U2bC1V1); Case 3 is a 28-year-old woman with infertility and dyspareunia, affected by complete uterine septum, double "normal" cervix and nonobstructive longitudinal vaginal septum (class U2bC2V1); all cases were treated using 15 fr resectoscope, with different technique depending on müllerian anomaly. At the end of all procedures, an anti-adhesion gel based on ialuronic acid to prevent post-surgical adhesions was applied.

Results

All surgical procedures were performed without any significant complication with complete resolution of the septa. No post-surgical adhesions formation was confirmed

Conclusions

Due to the technological innovations and improved surgical techniques, hysteroscopic metroplasty is an effective and safe procedure for the treatment of complete septate uterus with or without cervical abnormalities.

<https://player.vimeo.com/video/717702073?autoplay=1>

ES31-0131 - Fibroids

Myomectomy during pregnancy: a case report applying a “new” approach for uterine suture.

*Marco D'Indinosante¹, Anna Franca Cavaliere¹, Elisa Scatena¹, Alberto Matte², Giovanni Scambia³,
Federica Perelli²*

¹*Santo Stefano Hospital- Azienda USL Toscana Centro, Gynecology and Obstetric Department, Prato, Italy*

²*Santa Maria Annunziata Hospital- Azienda USL Toscana Centro, Gynecology and Obstetrics Department, Firenze, Italy*

³*Fondazione Policlinico Universitario A. Gemelli IRCCS,*

Department of Woman's and Child Health and Public Health Sciences- Gynecologic Oncology Unit, Roma, Italy

Background

The prevalence of uterine myomas during pregnancy varies from 0.3 to 15%. Uterine fibroids in pregnancy have been associated with increased risks of obstetric complications (spontaneous abortion, preterm delivery, preterm premature rupture of membranes) and caesarean delivery. Surgical treatment in pregnancy is a feasible option in selected patients affected by large mass/es. We report a case report about the application of a suturing technique (triple-flap method) during myomectomy in pregnancy, showing an excellent pregnancy outcome.

Methods

In October 2021, a 41-year-old Caucasian woman (BMI: 24) 3G2P at 11 weeks of GA was referred to our hospital for a large uterine mass. The ultrasound and the Magnetic-resonance-imaging (MRI) confirmed the presence of a voluminous intramural uterine mass more than 20 cm. As the mass was not known prior to pregnancy and was suspected to be growing rapidly, considering the couple's desire to hold the pregnancy, a laparotomic myomectomy was planned at 15 weeks of pregnancy.

Results

The uterine mass was removed without the use of electricity to respect the pregnancy but using an ultrasound device for greater haemostasis and speed of intervention. No opening of the uterine cavity was observed. Suturing of the uterus was performed using detached vicryl stitches following the triple flap technique that was first described in 2011 by Osada et al.

Estimated blood loss and operation time were 1000cc and 120 minutes, respectively. The only post-operative complication was anaemia, and the patient was transfused with 1 bag of blood after surgery. An ultrasonographic control of fetal outcome was carried out immediately after surgery which proved normal. Antibiotics (Ceftriaxone and metronidazole) and low molecular heparin were administered after the surgery. Hydroxyprogesterone Caproate (341mg/2mL im) was dispensed for 5 days to prevent a possible miscarriage. The patient was dismissed on the 5th postoperative day.

The patient was closely followed up and at 34 weeks of gestation a caesarean section was performed, after corticosteroid treatment to enhance fetal lung maturation, due to a partial amnio chorial detachment. The patient delivered a healthy male baby weighing 1960 gr and histological report revealed a uterine fibroma. The mother was discharged after 3 days and the child after 2 weeks without complication.

Conclusions

Surgical treatment of large uterine mass in pregnancy is a feasible option at tertiary level centres, in order to obtain histological report and reduce obstetrical risks. In this case, uterine reconstruction using the triple flap technique has been effective and has allowed the reconstruction of large surgical incision in the uterine wall.

FREE COMMUNICATIONS

ES31-0032 - Free Communication

Favourable surgical and obstetric outcomes in pre- and postconceptional laparoscopic abdominal cerclage: a large multicentre cohort study

Nour Abdulrahman¹, Nicole Burger¹, Jon Einarsson², Judith Huirne¹

¹*Amsterdam UMC- location Vrije Universiteit Amsterdam, Obstetrics and Gynaecology, Amsterdam, The Netherlands*

²*Brigham and Women's Hospital- Harvard Medical School, Obstetrics and Gynaecology, Boston, USA*

Background

To assess surgical and obstetric outcomes after pre- and postconceptional laparoscopic abdominal cerclage (LAC) placement, including subgroup analyses based on the indication for surgery.

Methods

A retrospective multicentre cohort study with consecutive inclusion of all eligible patients from 1997 onwards in the Dutch and from 2007 onwards in the Boston cohort was conducted. Eligible patients experienced at least one second- or third trimester fetal loss because of cervical incompetence and/or a short or absent cervix after cervical surgery. This includes (multiple) large loop excision of the transformation zone (LLETZ), conization or trachelectomy. Patients were divided into a pre- (surgery before pregnancy) and postconceptional (surgery during pregnancy) cohort and then into subgroups based on the indication for LAC: 1) prior failed vaginal cerclage 2) prior cervical surgery 3) other indication, such as patients in whom it is technically impossible to place a vaginal cerclage after cervical surgery but without a prior fetal loss, multiple prior dilation and curettage or multiple second or early third trimester fetal losses based on cervical incompetence. The primary outcome measure was delivery at ≥ 34 weeks of gestation. Secondary outcome measures comprised surgical and obstetric outcomes.

Results

A total of 273 patients were included; 250 patients underwent preconceptional and 23 patients underwent postconceptional placement until 12 weeks of gestation. Both pre- and postconceptional procedures showed excellent surgical outcomes, with six (2,4%) minor complications (uterine perforation) during preconceptional surgery. One conversion to laparotomy occurred during postconceptional placement because of hemorrhage and poor visualization in a patient with deep endometriosis and severe adhesions. Blood transfusions were not required. Pregnancy rate after preconceptional surgery was 74,1%. A total of 140 completed pregnancies were evaluated: 120 following preconceptional and 20 following postconceptional surgery. First trimester miscarriages occurred in 14,3%; 15,0% after preconceptional and 10% after postconceptional surgery. of all ongoing pregnancies 93,3% delivered at ≥ 34 weeks of gestation; 90,5% following preconceptional and 94,4% following postconceptional surgery. Delivery at > 34 weeks of gestation occurred in 86,4% (n=57) in the subgroup prior failed vaginal cerclage, 93,1% (n=27) in the subgroup prior cervical surgery and 100% (n=26) in the subgroup with another indication. Second trimester miscarriages occurred in four patients (2,9%), all in the subgroup prior failed vaginal cerclage of the preconceptional cohort. Fetal survival rate of all ongoing pregnancies was 96,7%; 96,1% following preconceptional and 100% following postconceptional surgery. Fetal survival rate was 93,8% in the subgroup prior failed vaginal cerclage, and 100% in the subgroup prior cervical surgery and other indication.

Conclusions

Pre- and postconceptional LAC placement is a safe procedure with favourable obstetric outcomes in patients with an increased risk of cervical incompetence. Subgroup analysis identifies patients with a prior failed vaginal cerclage with the greatest risk of cervical incompetence.

**ES31-0201 -
Free Communication**

A recurrent ovarian cystic teratoma presented with anti-NMDAR encephalitis: a rare case report

*Kalliopi Kordopati-Zilou¹, Anastasia Bagiasta¹, Alexandros Petrolekas¹, Olga Triantafyllidou¹,
Emmanouil Kalampokas¹, Nikolaos Vlahos¹*

*¹2nd Department of Obstetrics and Gynecology- Aretaieio University Hospital,
National and Kapodistrian University of Athens, Athens, Greece*

Background

Anti-N-methyl-D-aspartate receptor (NMDAR) encephalitis is a paraneoplastic limbic encephalitis first reported in 2007 by Dalmau et al. The prevalence of NMDAR encephalitis is estimated to be approximately 1 in 1.5 million people per year, and almost 80% of the total cases concern young women. Ovarian teratoma has been identified as a triggering factor in 58% of the affected women. This association has been thoroughly explored in the neurological literature, yet it remains almost unknown to the gynaecological community.

Methods

This case report concerns a 36-year-old female patient who attended a neurological emergency unit with fever, decreased consciousness, and a recent history of an acute psychotic episode. She was intubated and provided with intensive care unit (ICU) support because of hypoventilation and a Glasgow Coma Scale (GSC) score of 6/15. The diagnosis of NMDAR encephalitis was based on clinical suspicion and the detection of anti-NMDAR antibodies in the cerebrospinal fluid. First, she was treated with corticosteroids and a plasma exchange; however, there were poor outcomes. An abdominal MRI scan was carried out for further investigation, indicating bilateral adnexal masses. Consequently, she underwent laparoscopic surgery. Intraoperatively, a bilocular teratoma-like ovarian cyst 3.5 × 2 cm was identified on the right side and a multilocular serous cyst 7 × 5 × 3 cm on the left side, densely adherent to the ovary. The right bilocular mass was resected, and a right oophorectomy was executed. The procedure was uneventful, and the cysts were not ruptured. The histopathology report indicated mature cystic teratomas. Three months post-surgery, she presented with a relapse of psychiatric symptoms, and she was hospitalized again. Six months after surgery, a recurrent teratoma was identified by abdominal CT scan in the remaining right ovary. In the second laparoscopic surgery, a left oophorectomy was performed. During surgery, a recurrent teratoma-like ovarian cyst, 3.5 cm in size, was spotted in the right ovary.

Results

The recurrence rate of NMDAR encephalitis is reported to be approximately 12% and is higher in cases without ovarian teratomas. To the best of our knowledge, this is the second case report presenting a recurrence of both encephalitis and ovarian tumours.

Conclusions

Teratoma-associated anti-NMDAR encephalitis is a rare condition and is often overlooked by clinicians. Prompt diagnosis and proper management are associated with an improved prognosis. Young women with anti-NMDAR encephalitis-like symptoms should be immediately screened for ovarian tumours. Treatment should take place in a multidisciplinary setting that includes neurology and obstetrics/gynaecology departments.

**ES31-0263 -
Free Communication**

Step-by-step laparoscopic total hysterectomy in a patient with multiple C-sections

Akemi Koiti Nakamura¹, Carolina Fornaciari¹, Eduardo Zlotinik¹, Fernanda Asencio¹

¹Hospital Israelita Albert Einstein, Gynecology, Sao Paulo, Brazil

Background

The objective of this video is to show a step-by-step approach to a Laparoscopic Total Hysterectomy in a patient with multiple C-Sections and the increase in fibroid that it entails.

Methods

This is a case report illustrated with video. Patient was placed in semi gynaecological position, arms alongside the body and legs 80 grades abducted in adjustable leggings. Four laparoscopic portals were used. An umbilicus one for the camera, one in each iliac fossae and one suprapubic in the midline.

Results

Patient maintained abnormal uterine bleeding even after clinical treatment with hormonal contraceptives over a long period. Therefore, she was eligible for a laparoscopic total hysterectomy.

Conclusions

The patient had 4 prior C-sections which translated in an increase in fibrosis and difficulty in the dissection of the vesicocervical space. With a planned and methodical approach, we can use the uterine manipulation, anatomical landmarks and surgical technique presented to have a safe and effective surgery. In the end, the patient had a successful postoperative outcome and increase in quality of life.

<https://player.vimeo.com/video/710499480?autoplay=1>

**ES31-0607 -
Free Communication**

Laparoscopic management of large ovarian cysts

Ana Rita Alves¹, Diana Castanheira¹, Fabiane Neves¹, Jaime Vilaça², Isabel Duarte¹, António Santiago¹

¹Centro Hospitalar de Leiria, Obstetrics/Gynecology, Leiria, Portugal

²Luz Saúde, General Surgery, Porto, Portugal

Background

Large ovarian cysts, described in the literature as measuring more than 10 cm in their greatest diameter, represent a major challenge for laparoscopic surgery. Laparoscopy is currently the treatment of choice for most benign ovarian cysts, but the size of the cyst may be a limiting factor.

Methods

Description of two cases of large ovarian cysts successfully treated by laparoscopy using the ovarian cyst drainage technique followed by its immediate laparoscopic removal.

Results

Case 1: a 20-year-old female patient was admitted with abdominal pain and distension for 3 months. Pelvic ultrasonography and magnetic resonance imaging (MRI) revealed a right ovarian cyst measuring 24x19x6 cm. The cyst was filled with clear serous fluid. Considering the age, a laparoscopic cystectomy was performed successfully without any significant complication. The histopathology was suggestive of benign serous cystadenoma of the ovary. Case 2: 62-year-old postmenopausal woman was referred to our hospital by detection on a pelvic CT a bulky thin-walled mass measuring 177 mm at the level of the right adnexal region. In this context, the patient had no significant symptoms. Pelvic ultrasonography confirmed the existence of a thin smooth walled ovarian cyst with clear anechoic contents measuring around 21x14x12 cm. The laboratory tests were unremarkable, including the oncological markers β -hCG, AFP and CA-125. Preoperative magnetic resonance imaging (MRI) as the ultrasound scan findings were highly suggestive of a benign cyst. She underwent laparoscopic bilateral adnexectomy. In both situations, direct puncture of the cyst was performed with drainage and aspiration of its contents. The postoperative course was uneventful in both cases.

Conclusions

Large ovarian cysts are benign in most of the cases and histopathologically these cysts are either serous or mucinous. Although the laparoscopic approach of these cysts can be difficult due to the risk of cyst rupture and limited working space within the abdomen, constitutes a safe and viable technique.

**ES31-0075 -
Free Communication**

Laparoscopic partial vaginectomy and the use of ICG for the excision of a low rectovaginal nodule

Shaheen Khazal^{1,2}, *Benedetto Mondelli*¹, Michael Adamczyk³, Kyle Fleischer⁴

¹CEMIG Centre for Endometriosis and Minimally Invasive Gynaecology at HCA The Lister Hospital, Gynaecology, London, United Kingdom

²Royal Holloway, University of London, London, United Kingdom

³CEMIG Centre for Endometriosis and Minimally Invasive Gynaecology at Ashford & St. Peter's Hospitals NHS Foundation Trust, Gynaecology, Chertsey, United Kingdom

⁴St Richard's Hospital, Obstetrics and Gynaecology, Chichester, United Kingdom

Background

The use of Indocyanine Green (ICG) is well known in oncology where is used to identify sentinel lymph nodes using near-infrared light in endometrial, cervical and vulvar cancers. However, its application in benign gynaecology has not been widely adopted.

Methods

This video demonstrates the use of ICG to mark and delineate the margins of an ultra-low full thickness vaginal nodule with a lower limit reaching 3 cm from the vaginal introitus and aid its resection.

Results

We followed the structured approach "SO SURE" (Survey and sigmoid mobilization, Ovarian mobilization, Suspension of the uterus and ovaries, Ureterolysis, Rectovaginal-pararectal space entry, and Excision of the disease) for deep endometriosis surgery and achieved complete excision of a large 5 cm full thickness vaginal nodule invading the right parametria and involving the superficial layer of the rectum's muscularis. In the video are highlighted the benefits of using ICG to intraoperatively mark the large nodule avoiding excessive and unnecessary dissection.

Conclusions

In conclusion, the adoption of ICG in benign gynaecology should be further investigated. Other than marking the limit of an endometriotic nodule like here demonstrated, ICG can for example be utilised to check fallopian tubes patency, tissue perfusion following bowel resection and ureter identification among other applications.

<https://player.vimeo.com/video/709427288?autoplay=1>

**ES31-0269 -
Free Communication**

Outpatient one-step diagnosis and treatment of congenital mullerian anomalies

Simona Martone¹, Rossella D'Alisa², Virginia Foreste³, Brunella Zizolfi⁴

¹University of Siena, Molecular and Developmental Medicine- Obstetrics and Gynecology, Siena, Italy

²Policlinico Umberto I, Maternal and Child Health and Urological Sciences, Rome, Italy

³AOU Federico II, Department of Neuroscience- Reproductive Sciences and Dentistry, Napoli, Italy

⁴AOU Federico II, Department of Public Health, Napoli, Italy

Background

The aim of this study is to evaluate the feasibility of a novel outpatient approach requiring only one step for diagnosis and treatment of congenital Mullerian anomalies.

Methods

This is a single centre prospective cohort study conducted at University of Naples Federico II between July 2020 and April 2022. We included women (aged 18 to 40 years) with a suspected diagnosis of congenital Mullerian anomalies (Dysmorphic Uterus or Septate uterus) and meeting at least one of these criteria: history of long-standing unexplained infertility, recurrent implantation failure (RIF), and/or recurrent pregnancy loss (RPL). All patients underwent 3D sonography immediately before and after outpatient hysteroscopic metroplasty, using a "Voluson SWIFT" ultrasound system (GE Healthcare, Zipf, Austria) with 7.5 MHz probe. According to ESHRE/ESGE classification, the evaluation of dysmorphic uterus required the measurement of interstitial outline, isthmic diameter and their ratio, and lateral angle while the evaluation of a septate uterus required the measurement of interstitial line, depth of the septum and residual myometrial thickness. All surgical procedures were performed by one expert hysteroscopist, using 5 Fr scissors and/or bipolar electrode, or 16 Fr miniresectoscope. An anti-adhesion barrier gel has been applied after all procedures. Both the ultrasonographic examination and the operative hysteroscopy were performed in a single outpatient access, in order to reduce the number of hospital accesses and shorten the time for conceiving. For metroplasty, a residual fundal notch of 10 mm was considered safe.

Results

65 women with uterine malformations were enrolled, 45 with uterine septum and 20 with dysmorphic uteri (9 T-Shaped uteri, 8 Y-shaped uteri and 3 tubular uteri). One step approach has been possible in all cases. No intra or postoperative complication have been recorded. The procedure was well tolerated by all the patient, with a great degree of compliance. An improvement of the volume and the morphology of the uterine cavity has been observed after all metroplasties for dysmorphic uterus; moreover, no residual septum has been recorded after metroplasty for septate uterus, with depth of residual septum 1.2 ± 1 mm.

Conclusions

This novel one-step approach for Diagnosis and Treatment of Congenital Mullerian anomalies is safe and feasible in outpatient setting; it could be considered a powerful and useful tool to reduce the number of hospital accesses and shorten the time to conceive.

**ES31-0079 -
Free Communication**

The under-utilisation of laparoscopic myomectomy for the surgical management of uterine fibroids: a trust wide multicentre retrospective study

Natalie Cooper¹, Natasha Daniels¹, Zwelihle Magama¹, Mehrnoosh Aref-Adib¹, Jimi Odejinmi¹
¹Whipps Cross University Hospital, Obstetrics and Gynaecology, London, United Kingdom

Background

Laparoscopic myomectomy is the gold standard procedure for properly selected women who need surgery for fibroids, however, it is not equally available across the UK. We reviewed data from the largest NHS trust in England, to examine what proportion of open myomectomy procedures could have been done laparoscopically.

Methods

Retrospective review of myomectomies across Barts Health NHS trust from 2015 to 2019. We used previously published criteria to determine cases which could have been appropriate for laparoscopic myomectomy based upon the pre-operative ultrasound scan. We estimated potential cost savings using national tariff data.

Results

597 abdominal myomectomies were performed across four hospital sites. 139 (23.3%) cases were performed laparoscopically. Of the 330 open myomectomies with scan data, 143 could have been performed laparoscopically.

Across 4 hospital sites, the proportion of laparoscopic cases varied: site 1 = 4.3%, site 2= 55.5%, site 3 =19.0%, site 4 = 0%. By applying the scan criteria these proportions increase to 33.8%, 66.5%, 47% and 50% respectively.

Overall, 47.2% of women could have had laparoscopic myomectomy versus 23.3%, with a potential cost saving of £56,000.

Conclusions

There is potential to increase the proportion of laparoscopic myomectomies performed. We hypothesise that the current dearth of laparoscopic cases reflects the lack of advanced laparoscopic training opportunities. We are doing women a disservice by being unable to offer gold standard treatment to all women, no matter where they live.

**ES31-0290 -
Free Communication**

The effect of virtual reality on anxiety and pain in patients undergoing gynaecological surgery: a randomised controlled trial

Lynn Hoën¹, Bob Kreijveld¹, Ilse Bekkers², Eveline Mulder¹, Martine Wassen¹

¹Zuyderland Medical Centre, Gynecology, Heerlen, The Netherlands

²Maastricht University Medical Centre, Gynecology, Maastricht, The Netherlands

Background

A lack of postoperative acute pain management is associated with increased morbidity, longer recovery time, more opioid use, and subsequently increased health care costs. Therefore, alternative and additional methods to manage this postoperative acute pain are necessary to reduce opioid use and their adverse effects. Increasing evidence shows that virtual reality (VR) is a safe and effective option to reduce acute pain. This randomised controlled trial (RCT) aims to investigate the effect of VR on pain in the postoperative period after elective gynaecological surgery. Secondary objectives are preoperative anxiety, analgesic use, length of hospital stay and exploring experiences and satisfaction of VR use.

Methods

The study concerns a non-blinded single-centre RCT. This abstract shows the preliminary results of this RCT. Eligible patients, who will receive elective gynaecological surgery, were randomised to either the VR- group and receive additional VR during the pre- and postoperative period or the standard care-group. Exclusion criteria were chronic pain patients, history of prior opioid use, alcohol or drug abuse, known car sickness, epileptic insults in previous history, psychotically seizures in previous history, claustrophobic, blindness and history of mental illness.

A chi-square test was used to assess categorical variables. The independent sample t-test was used for continuous variables in case of normal distribution based on the skewness, kurtosis, and graphical representation of the continuous variables. For the mean-NRS scores for both pain and anxiety, median and interquartile range (IQR) were calculated since the data was not normally divided. For categorical variables, frequencies and percentages were calculated.

Results

48 participants were included in this preliminary analysis of the results of which 48% (n=23) received VR and 52% (n=25) received standard care.

Baseline characteristics were comparable for both study groups. Median and IQR for the mean NRS scores for pain on day 1 were 3.0 (1.8-5.0) in the VR group and 3.0 (2.0-4.0) in the standard group. VR did not lead to pain reduction ($p = 0.895$). Subsequently, there were no differences in analgesic use and length of hospital stay between both groups. Median and IQR for anxiety before and after intervention were respectively 4.0 (3.0-7.0) and 3.0 (2.0-4.0). In the VR group, anxiety was statistically significant decreased ($p < 0.001$). The majority of the participants thought it was a pleasant experience to use VR before and after surgery (respectively 82.6% and 69.6%).

Conclusions

This preliminary dataset shows that VR is not beneficial in reducing postoperative pain after elective gynaecological surgery. However, VR is beneficial in reducing preoperative anxiety. VR could therefore be of added value for patients that experience pre-operative anxiety. In the near future the VRAP-G RCT will provide an overview of the results of the complete data set.

**ES31-0516 -
Free Communication**

Use of indocyanine green dye for ureteric localisation in severe endometriosis cases

Athanasios Zikopoulos¹, Georgios Goumalatsos¹, Juneida Khodabocus¹, Charlotte Goumalatsou²

¹*Basingstoke and North Hampshire Hospital, Gynaecology, Basingstoke, United Kingdom*

²*University Hospitals Sussex NHS Foundation Trust, Gynaecology, Chichester, United Kingdom*

Background

The rate of ureteric injury has been reported to be as high as 21% in deep-infiltrating endometriosis. With 1% of endometriosis patients suffering from urinary-tract endometriosis, the estimated cumulative surgical complication rate is around 9%. Hence, the key preventative measure is ureteric identification. These include pre-operative regular or illuminated ureteric stenting and intra-operative ureteral mobilisation with ureterolysis. However, ureteric stenting is associated with complications especially if kept in-situ post-operatively; these include infection, encrustation, pain, discomfort, transient haematuria and post-operative fever. Conversely, the most common complication (<5%) of ureterolysis is ureteral injury, be it transection or by ischaemia from ureteral stripping or electrocautery.

Methods

A novel method that allows real-time identification of the ureter is intra-ureteric injection of indocyanine green dye (ICG) with visualisation under near-infrared light (NIR). The ICG is injected through a catheter inserted into the ureteric orifices via cystoscopy at the procedure start. The ICG binds to proteins on the urothelial layer, staining the inside lining of the ureter for up to 6 hours. Intra-operatively, the ureters become fluorescent under the NIR allowing easy identification hence resulting in lower risk of injury. This method of ureteric identification is relatively cheap and minimally time-consuming with low adverse event profile. The documented side effects are rare and range from nausea to anaphylactic shock. ICG is contraindicated in people with iodine sensitivity, renal failure, those undergoing dialysis as well as in pregnancy and breast-feeding.

Results

We present a series of cases of laparoscopic excision of endometriosis while using the ICG dye test. This imaging system enabled us to visualise the ureters whenever needed, enabling us to perform safe time-efficient surgery when extensive ureterolysis was required. The cases so far have sustained no complications. The post-operative recovery for all patients has been straightforward. In our experience, the use of ICG in such complex endometriosis cases was simple, safe, and effective.

Conclusions

ICG is increasingly used in various fields including ophthalmology for cataract, intra-operative angiography and laparoscopic general surgery including cholecystectomy, and colorectal resection for tumour localisation. This technique may well become the gold standard especially in complex cases of operative laparoscopy. In gynaecology, despite its huge potential in minimising ureteric injury, the use of ICG warrants a specific evaluation study to define its role while minimising side-effects.

**ES31-0053 -
Free Communication**

Hysteroscopic morcellation versus ultrasound guided electric vacuum aspiration for removal of retained products of conception: a multicentre randomised controlled trial.

Liselot Wagenaar¹, Tjalina Hamerlynck², Celine Radder³, Louisette Peters⁴, Benedictus Schoot^{1,2}, Huib van Vliet^{1,2}

¹*Catharina Hospital, Obstetry & Gynaecology, Eindhoven, The Netherlands*

²*Women's Clinic- Ghent University Hospital, Obstetrics & Gynaecology, Ghent, Belgium*

³*OLVG West, Obstetry & Gynaecology, Amsterdam, The Netherlands*

⁴*OLVG East, Obstetry & Gynaecology, Amsterdam, The Netherlands*

Background

To compare hysteroscopic morcellation (HM) with ultrasound guided electric vacuum aspiration (EVA) for removal of retained products of conception (RPOC) regarding the risk of postoperative intrauterine adhesions (IUA), complications and completeness of removal of the RPOC.

Methods

This trial was conducted in 3 teaching hospitals and 1 university hospital from April 2015 to date. 164 women diagnosed with RPOC on ultrasound ranging from 1 to 4 cm in diameter were included and randomised between HM and EVA. Women allocated to EVA underwent the procedure as soon as possible. In the HM group, a diagnostic hysteroscopy was planned at a minimum of 6 weeks after the end of pregnancy, followed by removal of the RPOC at least 2 weeks later. Postoperatively, a second-look hysteroscopy was scheduled after at least 1 menstruation or after a minimum of 4 weeks after RPOC removal. HM was performed with the TRUCLEAR 8.0 System or Elite plus (Medtronic, Minneapolis, MN, USA). EVA was performed using an 8 or 10 mm flexible, plastic Karman cannula.

Results

In our preliminary analysis, 70 women were treated in the HM and 75 in the EVA group. 19 patients did not undergo surgery due to spontaneous expulsion or outpatient hysteroscopic removal of the RPOC with forceps. The median operating time was similar between EVA and HM (5.82 min (2.96 – 10.00) vs 7.15 min (4.52 – 12.07), $p = .06$). No statistically significant differences were observed between HM and EVA for the occurrence of intra- and postoperative complications (5.71% vs 5.41% ($p = 1.0$) and 1.43% vs 1.33% ($p = 1.0$)) nor the completeness of removal of the RPOC (95% vs 86% ($p = .06$)). We will present the final results on IUA formation at the congress.

Conclusions

HM and EVA both show high rates of complete removal of RPOC with a similar complication rate.

A new surgical approach for fertility sparing management of diffuse endometrial G2 endometrioid adenocarcinoma: a step-by-step technique

Filippo Maria Capomacchia¹, Francesco Fanfani¹, Giovanni Scambia¹, Ursula Catena¹

¹Fondazione Policlinico Universitario Agostino Gemelli IRCCS,

Dipartimento per le Scienze della Salute della Donna del Bambino e di Sanità Pubblica, Rome, Italy

Background

4% of women diagnosed with EC are younger than 40 years old, and 70% of these women are nulliparous. These data highlight the importance of preserving fertility in these patients. It is demonstrated that hysteroscopic resection of focal well-differentiated (Grade 1) endometrioid adenocarcinoma, followed by progestins achieve a complete response rate of 95.3%. The hysteroscopic resection technique, the so called "three steps" technique, was first described by Mazzon et al. to treat focal Grade 1 (G1) EC without myometrial invasion.

Some years later, Giampaolino et al. described the hysteroscopic technique to treat diffuse atypical endometrial hyperplasia (AEH), consisting in superficial endometrial resection, preserving the basal layer of the endometrium.

Recently, fertility sparing treatment was proposed also in case of moderately differentiated endometrioid-(grading G2) tumours, with a relatively high remission rate.

Methods

We present a video of a new hysteroscopic approach, combining the use of a 15Fr bipolar miniresectoscope (Karl Storz, Tuttlingen, Germany) with a Tissue Removal Device (TRD) (Truclear Elite Mini, Medtronic) in case of fertility sparing treatment of diffuse G2 endometrioid adenocarcinoma.

Results

A 38 years-old patient affected by diffuse G2 endometrioid adenocarcinoma, who strongly wanted to preserve her fertility, was referred to our department. Magnetic resonance and computed tomography showed endometrial thickening confined to the uterus; neither pelvic or para-aortic lymph adenomegaly, nor ascites was observed. CA 125 was negative. After adequate counselling, patient underwent hysteroscopic procedure. Hysteroscopy showed a diffuse polypoid endometrial thickening occupying the whole uterine cavity, and also both tubal ostia areas. With the 15Fr miniresectoscope, resection of the main lesions including the underlying myometrium, was obtained. Afterward the TRD was used to remove the remaining pathological endometrium at the level of both tubal ostia areas, respecting the basal layer of the endometrium. At the end of the procedure the uterine cavity was completely free by pathological tissue and a levonorgestrel releasing intrauterine device (LNG-IUD) was positioned inside the uterus. Patient started also oral therapy with Megestrol Acetate 160mg daily, according to our internal protocol. Office hysteroscopic endometrial biopsy after 3 months showed a complete response.

Conclusions

Combined hysteroscopic resection with 15Fr bipolar miniresectoscope and TRD, in case of diffuse G2 endometrioid adenocarcinoma, followed by the administration of double progestin therapy with LNG-IUD and oral megestrol acetate, may be associated with higher complete response rate. Moreover, the use of TRD to complete the procedure reduces the use of electrosurgery and the subsequent risk of post-operative intrauterine adhesions. This could lead to better obstetrical outcomes in these patients. Further studies are needed to refine the indications and the surgical technique.

<https://player.vimeo.com/video/715722451?autoplay=1>

**ES31-0329 -
Free Communication**

Laparoscopic adenomyomectomy and double-flap reconstructive technique: description of the method.

Theodoros Theodoridis¹, Tilemachos Karalis¹, Christos Zymperdikas¹, Stamatis Papadopoulos¹, Athanasios Tolkos¹, Grigorios Grimbizis¹

¹Medical School- Aristotle University of Thessaloniki, 1st Department of Obstetrics and Gynecology, Thessaloniki, Greece

Background

Uterus-sparing resection procedures of adenomyomas are debated regarding their efficacy and rates of complications. In the current report we describe a laparoscopic adenomyomectomy and uterine reconstruction using the double-flap procedure.

Methods

Conventional laparoscopic method was used to explore the pelvic cavity. Uterus was incised vertically in order to expose the adenomyoma, which was excised from the surrounded tissue using laparoscopic scissors and monopolar electrical needle. The uterine reconstruction involved approximation of the serosa and myometrium of one side of the bisected uterus to the other side's myometrium, using interrupted 1-0 vicryl sutures. Next the second flap of the other side of the uterine wall was brought to cover the first flap, using again interrupted sutures (1-0 vicryl). Special care was paid in order to avoid any dead space. The adenomyoma was finally removed with a laparoscopic power morcellator, using a specimen retrieval bag in order to avoid tissue dissemination.

Results

The procedure resulted in optimal surgical result. 12 months after the operation the patient is asymptomatic with no ultrasonographic evidence of recurrence.

Conclusions

Laparoscopic adenomyomectomy using the double-flap method has good surgical results and a promising follow-up. It may represent the reconstructive method of choice in women with adenomyomas.

<https://player.vimeo.com/video/710468631?autoplay=1>

**ES31-0165 -
Free Communication**

Our experience with laparoscopic ethanol sclerotherapy in management of ovarian endometriomas: preliminary data of prospective study

Katarina Ivankova¹, Zuzana Marvanova¹, Jiri Hanacek¹, Jan Drahonovsky¹

¹Institute for Mother and Child Care, Endometriosis centre, Prague, Czech Republic

Background

We present a group of patients undergoing surgery for ovarian endometriomas in the largest endometriosis centre in the Czech Republic and our experience with ethanol sclerotherapy.

Methods

Evaluation of a group of 25 women (29 endometriomas) treated with sclerotherapy for ovarian endometriomas in Endometriosis Centre, Institute of Mother and Child Care, Prague between January 2021 and May 2022. All patients underwent transvaginal ultrasound examination prior to the surgery with no suspected malignancy according to IOTA simple rules.

Laparoscopy was performed in all cases - fenestration and aspiration followed by instillation of 95% ethanol via Foley catheter inside the cyst. A sample for histopathological examination was taken before alcohol instillation or at the end of the surgery with the same results.

We evaluated peroperative and postoperative complications, recurrence rate of endometriomas (6 to 12 months follow-up) and pregnancy rate with different sclerotherapy protocols.

Results

In 2021 we performed 148 surgeries on endometriomas, either as a part of complex surgery for deep infiltrating endometriosis or surgery for endometrioma alone. In 52% of those we performed cystectomy, 23,6% fenestration + coagulation, 19,6% sclerotherapy, 6% adnexectomy, 0,7% vaginal aspiration. Up to date, the mean age of the study group was 33,4 years (range 26 to 45 yrs), 42% of them were diagnosed with infertility, 14% were previously pregnant. 33,3% of patients had endometriomas alone, 66,6% had associated deep endometriosis either treated during the same procedure or left in situ depending on what was agreed with patient on consultation before surgery. 40% of the patients had 1 or 2 previous surgeries on the ovary on which sclerotherapy was performed. Mean diameter of the treated endometrioma was 72mm (range 35 to 160mm). Ethanol was left in situ in 32% of patients, in the rest of the patients was left for either 10 or 15 minutes and then aspirated. One case of postoperative abscess formation on the treated ovary with alcohol left in situ was observed. 2 patients got pregnant after sclerotherapy and both pregnancies were uneventful. In both of them alcohol was left in situ, and they were not treated for infertility. So far, we observed a recurrence rate of 13,7%, as the study is ongoing the data might differ at the end of the study.

Conclusions

To conclude, laparoscopic ethanol sclerotherapy is a promising minimally invasive procedure for treating endometriomas in women seeking pregnancy and those with previous surgeries for endometriomas. More data is needed to define indications and most effective protocol.

**ES31-0473 -
Free Communication**

Initiation of the 'See One Club': addressing problems in gynaecological surgical training since the Covid-19 pandemic

Ora Jesner¹, Dilip Visvanathan¹

¹Whipps Cross Hospital, Gynaecology, London, United Kingdom

Background

'See one, do one, teach one', the traditional model of surgical training has long been criticised and outdated due to concerns for patient safety. But how do gynaecology trainees acquire the required knowledge and skills when they do not have ample opportunities to 'see one'?

During the pandemic UK trainees in Obstetrics and Gynaecology felt the significant impact on their training particularly with a reduced exposure to elective operating. With significant reduction in gynaecology operating lists, there was growing concern amongst trainees on how they would achieve their required competencies. Increased uptake of webinar-based training in the pandemic was identified as an opportunity to provide trainees learning opportunities which cannot be found in textbooks or lectures.

Methods

The 'See One Club' was initiated, supported by Health Education England London, to optimise training opportunities by delivering bespoke webinar-based monthly teaching designed for the needs of the trainees. A programme was developed, incorporating a broad range of topics and experts were invited to teach using 'as-live' surgery. Trainees at all levels of experience were invited to attend virtually. The first club was launched in April 2021, initially to North Central and East London trainees. As the demand increased, it was extended across all London regions as well as London based trainees on the Medical Training Initiative (MTI) scheme. Feedback was collected after each session and the programme was adapted according to trainees' feedback and their educational needs.

Results

The sessions were delivered by experts in their fields, on a broad range of surgeries and procedures, narrating throughout their surgery. The interactive functions of webinar teaching gave ample opportunities for trainees to interact with the teaching and maximise learning. Up to 100 attendees in each session.

Feedback was collated from 333 attendees over 8 sessions and the sessions were rated on how helpful they were (1= not at all helpful, 5= extremely helpful). On average, this score was 4.6. Feedback was overwhelmingly positive and included comments such as:

'Love these sessions! So useful to hear experts talk through their approach.'

'At least there is some thought about gynae training.'

'It was helpful to watch an expert perform the surgery with the ability to ask any and all questions.'

'Continue to do expert talks like this one.'

Conclusions

There is no substitute for hands-on surgical training, however, video-based teaching lends itself to teaching anatomy and increase familiarity with surgical techniques and procedures, arguably much more than textbooks. This gives trainees greater knowledge and confidence to utilise the learning opportunities when they are in the operating theatre.

This programme addressed the reduced operative exposure by utilising the convenience and uptake of remote learning. The success of the 'See One Club' demonstrated a real demand for finding innovative ways of providing surgical training.

**ES31-0204 -
Free Communication**

To fight or to flee? A systematic review of ectopic pregnancy management and complications during the Covid-19 pandemic.

Amelie Morin¹, Michail Sideris², Sophie Platts¹, Tetyana Palamarchuk¹, Funlayo Odejinmi¹

¹Bart's Health NHS Trust, Obstetrics and Gynaecology, London, United Kingdom

²Barts and the London School of Medicine and Dentistry, Queen Mary University, London, United Kingdom

Background

During the COVID-19 pandemic, concerns regarding theoretical risks of surgery contributed to changes in clinical management to prevent contamination. We looked at the effect the pandemic had on the management of ectopic pregnancy. Our review compares published data on pre-COVID to COVID management of ectopic pregnancies and evaluates the differences where Early Pregnancy Unit (EPU) structures exist.

Methods

We performed a systematic review of the published evidence using a keyword strategy. The "Population Intervention Comparison and Outcome" (PICO) criteria were used to select studies. Three independent reviewers agreed on the data extracted after screening of the literature. The total population analysed included 3122 women. A meta-analysis of the included studies was completed using a random or fixed effect model depending on the heterogeneity (I^2). Our outcomes were the following: type of management of Ectopic Pregnancy (EP), incidence of ruptured EP and rate of complications. We compared units with and without EPU infrastructure.

Results

We included every study which recruited women diagnosed with ectopic pregnancy and compared the type of management during and prior the COVID-19 peak. Our literature search yielded 34 papers. 12 were included using the PRISMA guidelines. We observed no difference in the type of management (surgical versus non-surgical) [OR= 0.99 (0.63-1.55), $p=0.96$, $I^2=77%$] in the pre-Covid vs Covid cohorts overall but a reduction of surgical management in EPU structures. There was no difference in the ectopic rupture rate within the EPU branch [OR= 0.66 (0.33-1.31), $p=0.24$, $I^2=37%$]. In contrast, in non-EPU (NPEU) structures there was a clear increased risk of ruptured ectopic pregnancy [OR=2.86(1.84-4.46), $p<0.01$, $I^2=13%$] and complications [OR=1.69(1.23-2.31), $p=0.001$, $I^2=45%$].

Conclusions

The risk of ruptured ectopic and complications was significantly higher in the absence of EPU structures. This worldwide trend was not reflected in the UK, where EPU systems are widespread, suggesting that EPU structures contributed to prompt diagnosis and safe management. In the post-COVID era, healthcare systems have come to realise that pandemics might become the norm and thus the onus is to identify services that have worked seamlessly.

**ES31-0212 -
Free Communication**

**Are the music and prior analgesic medication effective in reducing pain during outpatient hysteroscopy?
A prospective randomized trial**

Alessandro Loddo¹, Gianmarco D'Ancona², Paola Abis³, Stefania Cornacchia³, Maria Luisa Fais³,
Stefano Angioni³

¹Clinica Ostetrica E Ginecologica Cagliari,

Azienda Ospedaliero Universitaria Di Cagliari. Dipartimento materno - Infantile, Cagliari, Italy

²Clinica Ostetrica E Ginecologica Cagliari- Azienda Ospedaliero Universitaria Di Cagliari - Italy.,
Dipartimento MATERNO - INFANTILE, Cagliari, Italy

³Clinica Ostetrica E Ginecologica Cagliari- Azienda Ospedaliero Universitaria Di Cagliari - Italy.,
Dipartimento Materno-Infantile, Cagliari, Italy

Background

Many methods have been described to reduce pain experience caused by office hysteroscopy which is reported as the most frequent cause for failure to complete the procedure. The aim of this study was to assess the efficacy of music and prior analgesic medication in reducing pain related to outpatient hysteroscopy.

Methods

This triple-arms randomized study was conducted in Hysteroscopic Unit of University Hospital in Cagliari from May 2021 to March 2022. A total of 264 patients scheduled for outpatient diagnostic or operative hysteroscopy were enrolled and randomly allocated to three groups according to complementary method used for pain relief: music group (n=88), oral premedication group (n=89) and control group (n=87). Oral premedication consisted of ibuprofen 200 mg + paracetamol 1000 mg administered 90 minutes before hysteroscopy whereas relaxing music was played during the procedure in the music group. Patients of control group didn't receive any pharmacological or non-pharmacological methods of relieving pain. Operative time and failure rate were also included in data collection. All procedures were performed by the same surgeon using a Bettocchi hysteroscope 5 mm in diameter and pain experience was evaluated during the test (T0) and 30 min after completion (T1) using VAS-score. A Kruskal-Wallis test was performed to compare the three groups and a p-value < 0.05 was considered statistically significant.

Results

All groups showed similar result with regard to duration and completion rate of procedure (p>0.05). We found no statistically significant differences in mean pain score between three groups during procedure as well as 30 min after completion (T0/p-value=0.35; T1/p-value=0.24), though the main pain score was always slightly higher in the control group. The VAS-score was also comparable between the three groups when we stratified for diagnostic and operative procedures (p=0.31 and p=0.43, respectively). Only nulliparous patients experienced significantly more pain during outpatient hysteroscopy compared to multiparous women (VAS score 6.32 ± 1.89 vs 4.33 ± 2.11 , respectively; p-value=0.032). No woman underwent intraoperative complications or experienced vagal reactions.

Conclusions

The severity of intra- and postoperative pain experienced associated to outpatient hysteroscopy is not influenced by prior administration of 200 mg ibuprofen + 1000 mg paracetamol or listening to music during the procedure.

**ES31-0286 -
Free Communication**

Laparoscopic removal of rudimentary horn

Theodoros Theodoridis¹, Christos Zymperdikas¹, Tilemachos Karalis¹, Dimitra Aivazi¹, Eleftherios Klonos¹, Grigoris Grimbizis¹

¹Medical School- Aristotle University of Thessaloniki, 1st Department of Obstetrics and Gynaecology, Thessaloniki, Greece

Background

Unicornuate uterus with rudimentary horn, a relatively rare hereditary malformation, results from the incomplete development of one of the Müllerian ducts during the 8th week of intrauterine development. Based on the new ESHRE/ESGE classification system of female genital tract congenital anomalies, unicornuate uterus with rudimentary is classified as Class IV congenital anomaly. This condition is related to several symptoms and gynaecological pathologies, such as chronic pelvic pain, dysmenorrhea and hematometra. It is also associated with obstetric implications and infertility. MRI might be a useful tool during the diagnostic procedure of the malformation. However, intraoperative diagnosis of the anomaly is common.

Surgical treatment by excising the rudimentary horn was until recently the gold standard for the treatment. However, the past few years, laparoscopic procedure was proposed as an equal alternative to laparotomy.

The aim of the present video is to point out the surgical steps of laparoscopic excision of right rudimentary horn from our patient's uterus.

Methods

A 4-port-laparoscopy (one 10 mm, two 5 mm and one 12 mm) was performed. The initial action was the careful division of the existing adhesions of the sigmoid colon. Afterward, the right round ligament was transected by using bipolar coagulation and scissors. An incision on the broad ligament of uterus up to the vesico-uterine pouch was performed. The right Fallopian tube and the right utero-ovarian ligament were ligated and cut. In the sequel, the rudimentary horn was detached from the uterus by using monopolar diathermy. The stitches to the myometrium were applied in two layers (the first layer was constituted by individual stitches, whereas the second layer was constituted by a continuous stitch). The detached rudimentary horn was removed from the abdomen with the use of a laparoscopic bag. Finally, the retroperitoneal space was sufficiently washed by warm saline and an extended control of haemostasis was performed.

Results

The recovery of the patient was uncomplicated. The patient was discharged 1 day post-operatively and the congenital malformation was histologically certified.

Conclusions

The procedure of laparoscopic excision of rudimentary horn was demonstrated in this video. Accurate surgical operations are of great importance in order to diminish all the unpleasant symptoms and to minimize the possibility of complications after the surgery.

<https://player.vimeo.com/video/710523990?autoplay=1>

**ES31-0593 -
Free Communication**

Ureteral resection and re-implantation due to parametrial endometriosis

Rita Valente¹, Luisa Cerqueira¹, Pedro Pinto¹, João Gomes¹, Ana Sofia Fernandes¹, Rui Pinto²

¹*Centro Hospitalar Universitário São João, Gynecology, Porto, Portugal*

²*Centro Hospitalar Universitário São João, Urology, Porto, Portugal*

Background

Exhibition of a laparoscopic surgery procedure in a patient with deep infiltrating endometriosis involving ureter, parametrium and uterine artery. We present nodule's resection and re-implantation of the right ureter

Methods

Review of the patient's medical records and laparoscopic surgery recording for describing the clinical case

Results

In this video we display a case of 37-year-old woman, gravida 3 (two vaginal deliveries and one spontaneous abortion) with a deep infiltrating endometriosis diagnosis and previous surgical intervention for intestinal lesion resection with anterior rectum resection 3 years ago.

At 2nd year of follow up she developed a persistent right lumbar pain. MRI was prescribed and showed a lesion with a maximum diameter of 23 mm involving the right parametrium, uterine isthmus, round and uterosacral right ligaments and also the right ureter, 5 cm before ureteral meatus. Because symptoms were refractory to medical therapy, the patient was evaluated with the collaboration of a urologist and conjoint surgery was planned.

During laparoscopic surgery, it was noticed that besides the right ureter, the homolateral uterine artery were also involved. After careful dissection of the referred anatomical structures, to allow complete lesion resection, both the right uterine artery and ureter were ligated, and the latter was re-implanted into the bladder.

There were no significant complications reported during the first month after the procedure.

Conclusions

This case highlights the importance of cautious surgical planning with adequate preoperative imaging and the availability of a multidisciplinary surgical team in the most complex endometriosis cases in order to avoid major complications.

<https://player.vimeo.com/video/715782524?autoplay=1>

**ES31-0437 -
Free Communication**

Sentinel node biopsy by retroperitoneal transvaginal natural orifice transluminal endoscopic surgery (vNOTES) in gynaecological malignancies: technique description and perioperative outcomes

Yannick Hurni¹, Clarisse Peter², Daniela Huber^{1,2}

¹Geneva University Hospitals, Department of Pediatrics- Gynecology and Obstetrics, Genève, Switzerland

²Valais Hospital, Department of Gynecology and Obstetrics, Sion, Switzerland

Background

Surgical staging with sentinel lymph node biopsy (SLNB) is an important tool to guide the management of early-stage endometrial and cervical cancers. This staging is generally performed by minimally invasive techniques such as conventional, single-site, or robotic laparoscopy. To further reduce the morbidity related to transabdominal surgeries, SLNB by total retroperitoneal transvaginal natural orifice transluminal endoscopic surgery (vNOTES) was recently introduced at our institution. In this video, we describe how to perform this surgical technique and we report our preliminary results.

Methods

Indocyanine green was injected into the cervix to identify sentinel lymph nodes (SLNs). Access to the pelvic retroperitoneal space was achieved through a paracervical incision in the lateral vaginal fornix, providing access to the obturator fossa. A GelPoint transvaginal access platform was used as a vNOTES port, and CO₂ was insufflated to expand the retroperitoneal space. SLNs were identified using fluorescence imaging, carefully resected, and removed transvaginally.

Results

Ten patients underwent SLNB by vNOTES at Valais Hospital (Sion, Switzerland) between October 2021 and May 2022. Indications to perform SLNB were endometrial cancer (6 cases), endometrial complex atypical hyperplasia (3 cases), and cervical cancer (1 case). The median operative time was 113 (81-211) minutes. The median estimated blood loss was 20 (20-400) mL. The overall bilateral detection rate was 100% (10/10). We completed all procedures without significant intraoperative complications, but 1 case required conversion to conventional laparoscopy. The median postoperative stay was 2 (2-4) days. We observed one case of postoperative deep vein thrombosis and an asymptomatic vaginal vault hematoma in one patient and a retroperitoneal hematoma requiring surgical drainage in another.

Conclusions

Our preliminary experience suggests that retroperitoneal vNOTES is a safe, feasible, and valuable technique to perform SLNB in gynecological malignancies.

<https://player.vimeo.com/video/715152505?autoplay=1>

**ES31-0168 -
Free Communication**

Ovarian tissue surrounding resected endometriomas: transforming the collateral ovarian damage to a potential source for oocyte preservation?

Rozemarijn de Koning¹, Mathijs Blikkendaal¹, Susana Chuva de Sousa Lopes², Lotte van der Meeren³, Frank Willem Jansen⁴, Eileen Lashley⁴

¹Endometriosis in Balance expertise centre, Gynaecology, The Hague, The Netherlands

²Leiden University Medical Centre, Department of Anatomy and Embryology, Leiden, The Netherlands

³Leiden University Medical Centre, Department of Pathology, Leiden, The Netherlands

⁴Leiden University Medical Centre, Department of Gynaecology and Obstetrics, Leiden, The Netherlands

Background

Ovarian endometriosis is associated with diminished ovarian reserve due to the disease itself as well as damage caused by excisional surgery, which may result in subfertility. The resected endometriomas are surrounded by ovarian tissue that contains follicles. However, data regarding density and maturation of these follicles are conflicting in previous publications. This study aims to quantify and characterise follicles and in particular (small) antral follicles in ovarian tissue surrounding resected endometriomas as these may serve as a potential oocyte source for *in vitro* maturation (IVM).

Methods

A retrospective cohort study was conducted at the Leiden University Medical Centre and the Endometriosis in Balance centre. Pathology slides of patients (≤ 50 years) that underwent uni-or bilateral endometrioma resection between 2011 and 2021 were analysed for the presence of follicles. To evaluate follicle maturation we used the follicular growth model as defined by Gougeon, with additional intermediate stages. Follicle density was determined by dividing the number of follicles by the ovarian tissue volume.

Results

In total, 1944 follicles in all stages of development were observed in ovarian tissue surrounding 96 endometriomas of 68 patients. A median density of 2.99 follicles (IQR 0.61-11.00) per mm^3 analysed ovarian tissue was found. Follicle density was negatively associated with age (-1.2 follicles/ mm^3 /year, $p=0.000$) and endometrioma size (-1.4 follicles/ mm^3 /cm, $p=0.037$). (Small) antral follicles were present in tissue surrounding 35 endometriomas (36.5%) derived from patients with a significantly lower median age compared to endometriomas where no (small) antral follicles were observed (30 versus 35 years, $p=0.003$). (Small) antral follicle density was 0.91 follicles/ mm^3 .

Conclusions

Our study demonstrates the presence of follicles in all stages of development surrounding resected endometriomas with a median follicle density of 2.99 follicles/ mm^3 . Data showed a decline in follicle density dependent on age and endometrioma size. In addition, we demonstrated the presence of (small) antral follicles in the tissue surrounding resected endometriomas, particularly in patients aged 30 or younger. We believe that these follicles may provide a potential oocyte source for IVM and represent an alternative fertility preservation option for ovarian endometriosis patients.

**ES31-0557 -
Free Communication**

Laparoscopic cystectomy: tricks and tips

Alvaro Bedoya-Ronga¹

¹*Birmingham City Hospital, O&G, Birmingham, United Kingdom*

Background

Ovarian cystectomy it's a common surgical procedure in benign gynaecology. Clear guidelines exist in the management of cysts in regards as to how and when to operate depending on menopausal status and malignancy concerns. This video relates to the laparoscopic surgical tricks and tips for benign cysts.

Methods

Video demonstration with educational comments.

Results

Educational content

Conclusions

- 1- Surgery in the left pelvic side wall starts with sigmoid mobilisation.
- 2- Assess and plan.
- 3- Use bag underneath the cyst to minimise the spillage of content. This is particularly important in Dermoid cysts to reduce the risk of chemical peritonitis.
- 4- Do a long superficial longitudinal incision parallel to the mesovarium, avoid breaching the cyst, consider if some ovarian tissue should be sacrificed.
- 5- Carefully dissect the ovarian tissue from the cyst, allow gas to help, use the assistant to stabilise the cyst, avoid using energy as much as reasonable possible.
- 6- If the cyst ruptures, avoid spillage by the using the suction irrigation system.
- 7- Pay attention to the ovarian surface. It is easy to overlook cyst capsule left adherent to it.
- 8- Check haemostasis, use diathermy sparsely.
- 9- Suture to achieve haemostasis and restore anatomy:
 1. Monofilament,
 2. Do a hangman knot, or similar, keep the tail on sight,
 3. Use a continuous suture,
 4. Use your assistant.
- 10- Remove the cyst in the bag, do a final check, and wash profusely

<https://player.vimeo.com/video/715756357?autoplay=1>

**ES31-0455 -
Free Communication**

Are ureterolysis for deep endometriosis really all the same? Anatomical classification proposal of ureterolysis: a single centre experience

Federica Campolo¹, Matteo Pavone¹, Alessandra De Cicco Nardone¹, Manuel Maria Ianieri¹, Giovanni Scambia¹
¹Fondazione Policlinico Universitario A. Gemelli- IRCCS, UOC Ginecologia Oncologica, Roma, Italy

Background

The parametrial infiltration by Deep Endometriosis (DE) may lead to the involvement of several structure as the ureter. The ureteral endometriosis (UE) has an incidence of 0.1% to 1%, and usually presents with nonspecific symptoms related to the ureters obstruction, requiring surgery. The type of surgery required includes either a conservative (ureterolysis) or radical treatment (ureteral resection with ureter-ureteral anastomosis, uretero-neocystostomy, nephrectomy) depending on the degree of ureters infiltration by DE. The incidence of intra and post-operative complications (ureteral injury, fistula or post-operative stenosis) after surgical treatment of ureteral endometriosis is extremely heterogeneous, ranging from 0% to 28,6%. No international consensus has been reached yet regarding the classification of urinary tract endometriosis, and the wide variability of surgical complications after ureterolysis, discloses the difficulty to compare all findings without a credible and reproducible classification of ureterolysis. The aim of our study is thus to propose a classification of ureterolysis based on the anatomic structure of the ureter and sustained by the difference of the procedures in terms of rates of complications.

Methods

During the study period 139 procedures of ureterolysis were included in the study. Patients were divided into three groups, according to the depth of ureterolysis required:

Type 1: excision of the tissue surrounding the ureteral presacral fascia.

Type 2: the presacral fascia is incised and partially removed.

Type 3: incision of the presacral fascia and the ureteral adventitia without the opening of the muscular layer.

Difference across the three types of ureterolysis in terms of incidence of ureteral fistula, intraoperative ureteral injury, post-operative onset of hydronephrosis were evaluated. Moreover, we compared the three types of procedures in terms of surgical and clinical outcomes.

Results

The rate of complications from ureterolysis was extremely low (2.9%) and complications especially arose in type 3 intervention (11.8% vs. 0% in type 1 and 8% in type 2; $p=0.008$). The incidence of ureteral fistula was reported in the 0.7% of cases while of urethral stenosis in 1.4% of cases of type 2 and only in one patient ureteral suture was needed, in type 3 ureterolysis. For what concerns pain symptoms at 3-months follow-up evaluation, there was a reduction after intervention, reaching a median score of 0.

Conclusions

Classification of ureterolysis based on the anatomic structure of the ureter is needed because the difference of the procedures based on the anatomical classification results in different complication rates, especially arose in type 3 intervention. This study represents a first observation to be further analysed and confirmed on larger scale and prospective longitudinal studies and it is the first that attempts to standardize the procedure of ureterolysis based on clear and reproducible anatomical landmarks, so that it will be possible to try to compare more reliable and reproducible results between the various authors.

**ES31-0157 -
Free Communication**

Uterine-artery embolization or myomectomy for uterine fibroids: the FEMME Study

Fusun Sirkeci¹, Mary A Lumsden², Jane Daniels³, Isaac Manyonda⁴, Jonathan Moss⁵, Anna Bell⁶

¹Consultant Gynaecologist, St Mary's Hospital- Manchester University NHS Foundation Trust, Manchester, United Kingdom

²University of Glasgow, Gynaecology, Glasgow, United Kingdom

³University of Nottingham, Nottingham Clinical Trials Unit, Nottingham, United Kingdom

⁴St George's- University of London, Gynaecology, London, United Kingdom

⁵University of Glasgow, Institute of Cardiovascular & Medical Sciences, Glasgow, United Kingdom

⁶St George's University Hospital, Radiology, London, United Kingdom

Background

Uterine fibroids are the most common benign tumours of the women of reproductive age and more women are seeking uterine preserving treatments. We have conducted a multi-centred randomised control trial to compare two most commonly utilised uterine preserving treatments namely myomectomy versus Uterine Artery Embolisation, as there was lack of long-term data comparing these two.

Methods

We have randomised 254 women were randomized, 127 to each treatment. Myomectomy was performed by any route but majority was open/ abdominal. We have collected data on fibroid-specific quality of life (UFS-QOL, range 0–100, higher is better QoL), menstrual blood loss (PBAC, >100 is heavy), pregnancy and complications.

Results

We obtained UFS-QOL scores for 206 women at 2 years: mean 84.6 (SD 21.5) in the myomectomy group, versus 80.0 (22.0) in the UAE group (mean adjusted difference 8.0, 95% CI 1.8–14.1; P=0.01), meaning higher improvement in QoL after myomectomy.

There were no differences in the bleeding scores, nor in the proportions of women reporting amenorrhoea or heavy bleeding. PBAC median scores decreased from 133 (IQR 63–275) to 32 (0–88) at 2 years in the UAE group and from 180 (100–383) to 41 (11–84) in the myomectomy group.

The number of surgical reintervention was higher after UAE.

Twelve women in the UAE group and 6 in the myomectomy group became pregnant over 4 years, with 7 and 5 live births, respectively (hazard ratio: 0.48, 95%CI 0.18–1.28). There was no evidence of any difference between the levels of biomarkers of ovarian reserve between the treatment groups.

Conclusions

Our multi-centre trial showed the superiority of myomectomy over UAE with respect to health-related quality of life. The overall incidence of perioperative and postoperative complications was similar in the two groups

**ES31-0479 -
Free Communication**

Utility of routine preoperative laboratory testing for patients undergoing minor gynaecologic surgical procedures: the impact on intra-operative and post-operative complications

Stefano Restaino¹, Anna Biasioli¹, Vincenzo Tarantino², Giovanni Esposito², Giulia Pellecchia¹, Ursula Catena³

¹*University-Hospital of Udine, Department of Maternal and Child Health-, Udine, Italy*

²*Univerisità Cattolica del Sacro Cuore, Division of Gynecologic Oncology, Roma, Italy*

³*Fondazione Policlinico Universitario Agostino Gemelli IRCCS, Division of Gynecologic Oncology, Roma, Italy*

Background

Minor surgery in gynaecology encompasses a broad range of minimally invasive procedures. These procedures are among the most common gynaecological surgical procedures and usually have a limited duration with a low risk of complications. The rate of complications reported in literature is between 0.95-4.5%.

The preoperative workup includes physical examination and many other lab-test performed to determine whether patients can safely undergo the intended surgical procedure, to identify high-risk patients and to treat any pathological condition before surgery. American Society of Anaesthesiologists (ASA) National Institute for Health and Care Excellence guidelines recommended against routine preoperative workup in the absence of clinical indications. Our goal was to investigate whether, in the absence of anamnestic risk factors, performing preoperative blood chemistry tests or not results in a different outcome in terms of intra- and postoperative complications and cost-effectiveness.

Methods

This was a retrospective, multicentric study involving all patients underwent minor gynaecological surgical procedures (diagnostic and operative hysteroscopy, dilation & curettage, conization, vulvar biopsy etc) under conscious sedation or general anaesthesia, at Fondazione Policlinico Universitario A. Gemelli IRCCS, CLASS Hysteroscopy Centre (Group A) between January 2020 and January 2021 and at Azienda Sanitaria Universitaria Friuli Centrale (ASUFC) Obstetrics and Gynaecology unit (Group B) between January 2017 to September 2021. The rate of preoperative laboratory testing before Day Surgery gynaecological procedures in low-risk patients was determined and factors associated with testing including patient characteristics and comorbidities were evaluated. Preoperative laboratory testing was defined as chemistry, haematology, coagulation, or liver function studies obtained within 30 days preoperatively. Institutional Review Board approval was obtained.

Results

1691 patients were available for analysis, of theme 1191 in Group A and 500 Group B. In first group the median age was 48 years (range 14-87) and median BMI was 25 kg/m² (range 15-53). In the second group the median age was 57 years (range 22-91) and median BMI was 26 kg/m² (range 15-61). The median operative time was 19 minutes (range 2-80) for Group A vs 24 minutes (range 1-80) for Group B (p=.0001). No differences in perioperative, post-operative outcomes and time of discharge were observed between the 2 arms. In details, we observed 14 (1.2%) and 7 (1.4%) post-operative complication in Group A and B respectively (p=0.70). In patients not admitted to routinely blood sample we observed a cost reduction about 400 euros for patients.

Conclusions

Routine blood tests may not be required in patients without risk factors admitted to minor gynaecological surgical procedures. In our samples we observed not statistically significant differences in term of post operative complications and hospital re-admission. In addition, this resulted in a considerable reduction in term of costs.

**ES31-0484 -
Free Communication**

Reproductive prognostic value of strict imaging criteria of the uterus

Eleonora La Fera¹, Helena Van Kerrebroeck², Stephan Gordts³, Ursula Catena¹, Giovanni Scambia¹, Rudi Campo³

¹Fondazione Policlinico Universitario Agostino Gemelli IRCCS,

Dipartimento Scienze Salute della Donna e del Bambino e di Sanità Pubblica, Rome, Italy

²Ziekenhuis Oost-Limburg- Genk- Belgium., Department of Gynecology- obstetrics and fertility., Genk, Belgium

³Life Expert Centre- Leuven- Belgium., Leuven Institute for Fertility & Embryology, Leuven., Belgium

Background

Until today no real consensus exists to define a normal uterus.

Normality should consider the 3 functional layers of the uterus as defined in magnetic resonance (MRI), the Endometrium, the Junctional Zone myometrium, and the outer myometrium. Also, the uterine morphology as defined by the ESGE / ESHRE classification on congenital anomalies and the CUME classification should be considered.

The Life Expert Centre (LEC) has a one-stop uterine diagnostic/therapeutic unit in which ultrasound, Hysteroscopy, and contract sonography are performed. The MRI results are integrated into the advice protocol and patient receives a protocol normal, subtle lesions or abnormal.

Does normality defined by the strict LEC criteria reflect a normal reproductive performance?

Methods

This is a prospective, monocentric single observer study. All women consulting with an infertility problem at the LEC received a 2-3 D Ultrasound (US), hysteroscopy (HSC), and contrast sonography by the same examiner. Those patients with normal findings and no obvious cause of infertility received a supplementary MRI. MRI exams were classified as normal when the inner myometrial layer was sharp aligned and did not measure more than 1/3rd of the total diameter.

The final observation was performed with an interval of a minimum of 2 years. The outcome was measured as the best reproductive result observed in those patients who received active treatment and no obvious embryonal factor or male infertility factor was present.

Results

Forty patients with normal US and Hysteroscopic findings and no further infertility factors were enrolled. After an observation interval of a minimum of 2 years, we recorded 28 (70%) deliveries, 6 (9,7%) miscarriages, and 6 (9,7%) women who did not get pregnant.

Of the 28 patients who delivered, all had a normal US, HSC, and MRI. The 6 patients with miscarriage and the 6 patients who did not get pregnant all had diffuse enlargement or total loss of junctional zone myometrium in MRI.

Conclusions

Our study shows that the strict criteria of normality defined by the Life Expert Centre correlate very well with successful reproductive outcomes.

Including MRI in the infertile patient to examine the Junctional zone myometrium seems important, especially for patients before entering an Assisted Reproductive Technology (ART) program.

It also highlights the need for a classification system that correlates abnormalities detected by MRI with those detected by ultrasound, hysteroscopy, and clinical symptoms. Minor abnormalities detected on hysteroscopy may subtend the presence of underlying myometrial pathology. Their rapid detection would mean rapid treatment with possible improvement in obstetric outcomes.

**ES31-0501 -
Free Communication**

Minimally invasive versus open pelvic exenteration in gynaecological malignancies: a propensity-matched survival analysis.

Nicolò Bizzari¹, Vito Chiantera², Matteo Loverro¹, Giulio Sozzi², Giovanni Scambia¹, Giuseppe Vizzielli⁴

¹Fondazione Policlinico Universitario A. Gemelli IRCCS,

UOC Ginecologia Oncologica- Dipartimento per la salute della Donna e del Bambino e della Salute Pubblica, Rome, Italy

²ARNAS "Civico – Di Cristina – Benfratelli",

Department of Health Promotion- Mother and Child Care- Internal Medicine and Medical Specialties PROMISE- University of Palermo- Palermo- Italy, Palermo, Italy

³University of Messina, 3.

Department of Human Pathology of Adult and Childhood "G. Barresi"- Unit of Gynecology and Obstetrics, Messina, Italy

⁴Udine University Hospital,

Department of Obstetrics- Gynecology- and Pediatrics- Obstetrics and Gynecology Unit, Udine, Italy

Background

The primary endpoint of the present study was to compare the disease-free survival (DFS) in patients undergoing open versus minimally invasive pelvic exenteration (PE). Secondary endpoints were comparison of cancer-specific survival (CSS) and peri-operative morbidity between these two groups. The primary endpoint of the present study was to compare the disease-free survival (DFS) in patients undergoing open versus minimally invasive pelvic exenteration (PE). Secondary endpoints were comparison of cancer-specific survival (CSS) and peri-operative morbidity between these two groups.

Methods

Multi-centre, retrospective, observational cohort study. Patients with central or lateral pelvic recurrence/persistence of gynaecological cancer, undergoing anterior or total PE by minimally invasive and open approach between 2010 and 2021 were included. Patients with positive para-aortic/inguinal lymph nodes and with distant metastasis were excluded. With a propensity match analysis patients undergoing minimally invasive PE were matched with a 1:2 ratio to patients undergoing open PE to equalized baseline characteristics.

Results

No significant difference in intra- and post-operative complications was evident between the two study groups (trend toward higher incidence of complications in open approach patients). Patients undergoing open PE received higher number of intra-operative transfusions ($p=0.013$). Median DFS was 17.0 months versus 17.0 months in open versus minimally invasive group, respectively ($p=0.632$). Median CSS was 30.0 months versus 26.0 months in open versus minimally invasive group, respectively ($p=0.800$). Positive surgical margins at final histology was the only significant factor influencing the risk of recurrence (HR 2.378, 95% CI 1.313-4.308) ($p=0.004$), while tumour diameter ≥ 50 mm at time of PE was the only significant factor influencing the risk of death (HR 1.833, 95% CI 1.080-3.111) ($p=0.025$).

Conclusions

No survival difference was evident when minimally invasive was compared to open PE in patients with gynaecological cancer. No difference in peri-operative complications, but higher intra-operative transfusion rate in open group, was evident. Involvement of surgical margins and tumour diameter at time of PE, represented the most important prognostic factors for DFS and CSS, respectively.

The role of tumour infiltration pattern within uterine topography in apparently early stage endometrial cancer

Andrea Rosati¹, Virginia Vargiu², Vito Capozzi³, Giulio Sozzi⁴, Giovanni Scambia¹, Francesco Fanfani¹

¹Fondazione Policlinico Universitario A. Gemelli- IRCCS- Roma- Italy.,

Woman- Child and Public Health Department, Rome, Italy

²Gemelli Molise SpA, Department of Gynecologic Oncology, Campobasso, Italy

³University of Parma, Department of Medicine and Surgery, Parma, Italy

⁴University of Palermo, Department of Gynecologic Oncology, Palermo, Italy

Background

The invasion site of the uterine cavity could affect the spreading pathways of endometrial cancer (EC). The objective of this study was to determine whether the invasion of the uterine fundus, corpus or isthmus was associated with higher-risk tumors and, whether these could be considered as independent risk-factors for lymph-node and adnexal-peritoneal metastasis.

Methods

Multicentre, retrospective study, including patients with apparent early-stage EC who underwent surgery between May-2015 and March-2021, in 4 Italian cancer-referral centres.

Study population was divided according to histologically proven tumour infiltration of the uterine corpus (Group-1), the uterine fundus (with or without the concomitant infiltration of the uterine corpus) (Group-2) and of the isthmus (with or without concomitant infiltration of the uterine corpus) (Group-3).

Results

Data of 844 women were retrieved. Four-hundred-thirty-seven patients belonged to Group-1, 311 to Group-2 and 48 to Group-3. Forty-eight patients were excluded for lack of histological data.

There were no differences in histology and grading-score between the three groups ($p = 0.304$ and $p = 0.153$ respectively). Higher rates of LVSI, deep myometrial invasion, and tumor ≥ 2 cm was found in Group-2 and 3 compared to Group-1 (LVSI: 23.8% vs 41.5% vs 35.4%, $p < 0.001$, myometrial invasion $\geq 50\%$: 25.4% vs 51.1% vs 47.9%, $p < 0.001$, T ≥ 2 cm: 68.0% vs 83.3% vs 89.6%, $p < 0.001$ in Group-1,2 and 3). A higher rate of cervical invasion was found in Group 3 (9.2% vs 10.9% vs 50.0%, $p < 0.001$).

Higher rate of lymph-node and adnexal-peritoneal metastasis were reported in Group 2 and 3 (LN metastasis: 12.1% vs 20.9% vs 29.2%, $p = 0.001$, adnexal-peritoneal metastasis: 2.1% vs 6.1% vs 6.3%, $p = 0.023$ respectively in Group 1,2 and 3).

At univariate analysis, fundus and isthmus infiltration showed an OR of 1.798 ($p = 0.003$) and 2.801 ($p = 0.003$) for the risk of lymph-node metastases versus corpus infiltration alone. However, they lost their statistical significance at multivariate analysis (fundus infiltration: OR 1.223, $p = 0.351$, isthmus infiltration: OR 1.763, $p = 0.143$).

In contrast, fundus infiltration was found to be a statistically relevant risk factor for adnexal-peritoneal metastases, along with histotype and LVSI (OR 6.403, $p < 0.001$ and 2.987, $p = 0.015$), both at uni and multivariate analyses (fundus infiltration OR 2.452, $p = 0.046$).

Stratifying the cases by risk classes, infiltration of the fundus and of the isthmus proved to be significant risk factors for belonging to high or advanced risk classes (OR 1.465, $p = 0.018$ and OR 1.856, $p = 0.049$ respectively)

Conclusions

Cancer involving the uterine fundus and isthmus were at greater risk to fall within high or advanced risk groups, reporting a higher rate of nodal and adnexal-peritoneal metastasis. However, tumour site infiltration was not found to be an independent risk factor for lymph-node metastasis, while infiltration of the uterine fundus resulted a statistically relevant risk factor for adnexal-peritoneal metastasis.

The influence of hormonal stimulation on uterine peristalsis in women with IVF/ICSI treatment compared to normal ovulating women measured by ultrasound speckle tracking.

Anna De Boer¹, Connie Rees¹, Brunella Zizolf², Nikos Christoforidis³, Huib van Vliet^{1,4}, Dick Schoot^{1,4}

¹*Catharina Hospital, Gynaecology and Obstetrics, Eindhoven, The Netherlands*

²*University of Naples "Federico II", Obstetrics and Gynaecology, Naples, Italy*

³*Embryolab Fertility Clinic, Obstetrics and Gynaecology, Thessaloniki, Greece*

⁴*Ghent University Hospital, Gynaecology and Obstetrics, Ghent, Belgium*

Background

It is shown that uterine peristalsis plays a role in procreation. Subjective visual inspection of uterine peristalsis is extensively researched throughout the menstrual cycle. Studies of uterine peristalsis in IVF/ICSI patients show higher frequency of uterine contractions during the periovulatory phase. Recently, a new automated quantitative method was validated to objectively analyse uterine strain using speckle tracking. Besides objective insight in frequency, also information on amplitude, direction and coordination of contractions is available. The effect of exogenous hormones on uterine contraction features has not objectively been studied using this tool before.

Methods

This multicentre prospective observational cohort study was performed between 2014 and 2022 in the Catharina Hospital in Eindhoven, the Netherlands, Embryolab Fertility Centre in Thessaloniki, Greece and University of Naples, Federico II in Naples, Italy. 23 women undergoing IVF/ICSI treatment were included regardless of the treatment cycle number and stimulation protocol. 30 healthy pre-menopausal women with spontaneous regular cycles served as controls. All included patients presented with sonographic normal uteri. Each participant underwent a 4-minute transvaginal ultrasound of the uterus in mid-sagittal plane. Ultrasound recordings in women undergoing IVF/ICSI on the day of follicle aspiration were compared with naturally ovulating controls on cycle day 9 – 14. The contraction features frequency, amplitude, direction and coordination were extracted from the ultrasound recordings with an automated quantitative method which objectively analyses uterine strain with speckle tracking.

Results

Patient characteristics of the IVF/ICSI patients and healthy volunteers showed no statistically significant differences. Both groups predominantly consisted of nulliparous women. In IVF/ICSI patients the contraction amplitude was significantly higher compared to controls (0.053 vs 0.040, $p < 0.001$). No statistically significant differences were found in contraction direction, frequency and coordination ($p > 0.05$). IVF/ICSI indications, treatment protocols and the number of produced follicles were not identified as confounders as they have no statistically significant influence on the characteristics of uterine contractions ($p > 0.05$).

Conclusions

Patients with normal uteri show similar uterine contraction frequency, direction and coordination during IVF/ICSI treatment and natural menstrual cycles. This suggests that a healthy uterus behaves similarly in IVF/ICSI treatment and during the natural cycle, regardless of hormonal stimulation. Thus, the presence of abnormal uterine peristalsis in IVF/ICSI patients most likely indicates the presence of underlying uterine pathology. A statistically significantly increased contraction amplitude parameter was reported in IVF/ICSI patients compared to normal ovulating women. The increased contraction amplitude in IVF/ICSI patients cannot yet be explained with current known information. If future studies can concretely correlate uterine peristalsis features, especially contraction amplitude, to successful pregnancy, this study will assist in answering the question as to whether embryo transfer is preferred during the natural or stimulated cycle.

**ES31-0189 -
Free Communication**

Laparoscopic management of pelvic organ prolapse with native tissue: a step-by-step technique

Konstantinos Kypriotis¹, Nikolaos Kathopoulos¹, Michael Diakosavvas¹, Ioannis Chatzipapas¹, Ioanna Lardou¹, Athanasios Protopapas¹

¹National and Kapodistrian University of Athens,

1st Department of Obstetrics and gynecology- Alexandra Hospital, Athens, Greece

Background

Pelvic organ prolapse is a frequent pathology owing to the midline or lateral defects of the pelvic fascia. Traditional vaginal surgery with or without the placement of a surgical mesh is the preferred method so far. Recently, laparoscopic native tissue repair of pelvic organ prolapse is gaining the attention of the pelvic surgeons. The scope of this video is to present a systematic approach of this technique highlighting the key steps ensuring a safe and effective operation

Methods

The operation begins with posterior colporrhaphy which is described in detail in the video. After the dissection of the rectovaginal space down to the level of the levator ani muscles, two layers of semilunar sutures are placed on the posterior vaginal wall, plicating the vaginal fascia. The second step of the operation is the anterior colporrhaphy. The vesicovaginal space is developed down to the level of the bladder trigone and a total of three interrupted sutures are placed to achieve vertical plication of the vesico-vaginal fascia. The third step is suspension of the vaginal stump from the uterosacral ligaments bilaterally by placing permanent Ethibond suture that suspends the corner of the vaginal cuff to the uterosacral ligaments on both sides. The last step is a Moschowitz procedure with placement of a circular purse-string suture, in one or two layers, that includes the rectosigmoid serosa and a final suture that incorporates the vaginal cuff. This way the pouch of Douglas is obliterated in an effort to prevent future prolapse

Results

The systematic presentation of the technique, with a step-by-step presentation, may contribute to make the operation reproducible by other surgeons.

Conclusions

Laparoscopic repair of pelvic organ prolapse appears to be a viable alternative to both laparoscopic procedures using surgical meshes and vaginal native tissue repairs.

<https://player.vimeo.com/video/710330466?autoplay=1>

**ES31-0255 -
Free Communication**

HUGO RAS system in urogynaecology: the first nerve sparing sacralcolpopexy for pelvic organ prolapse

*Giovanni Panico¹, Giuseppe Campagna¹, Daniela Caramazza¹, Sara Mastrovito¹, Alfredo Ercoli²,
Giovanni Scambia¹*

¹Fondazione Policlinico Universitario A. Gemelli IRCCS,

Dipartimento di Scienze della Salute della Donna- del Bambino e di Sanità Pubblica, Rome, Italy

²University of Messina, PID Ginecologia Oncologica e Chirurgia Ginecologica Miniinvasiva, Messina, Italy

Background

Minimally invasive sacral colpopexy is nowadays considered the gold standard for surgical treatment of pelvic organ prolapse (POP), combining high success rates to low risk of recurrence in comparison to other techniques. This is the first case of robotic sacral colpopexy (RSCP) performed with the innovative Hugo™ RAS robotic system. The aim of this article is to show the surgical steps of a nerve sparing RSCP performed with the new Hugo™ RAS robotic system (Medtronic), by also evaluating the feasibility, safety and efficacy of this procedure

Methods

A 50-year-old Caucasian woman with symptomatic pelvic organ prolapse-Q (POP-Q) Aa: 2, Ba: +3, C: +4, Bp: -2, Ap: -2, TVL:10 GH: 3,5 BP:3 underwent RSCP as well as a subtotal hysterectomy with bilateral salpingo-oophorectomy, using the new surgical robot Hugo™ RAS

Results

The procedure started by inserting a 12-mm optic port in umbilical position. Once pneumoperitoneum at 12 mmHg was reached, a 3D-HD 0° 10-mm scope (Storz) was inserted. Two additional standard 5-mm ports were placed under direct visualization in the right and left lower abdomen laterally to the inferior epigastric vessels, at 13 cm distance and 5 cm below the transumbilical plane. An additional 5-mm trocar was placed at palmer's point, for the first assistant use. Once all ports were placed, robotic docking was performed. The video shows the salient steps of the surgical procedure. Surgical procedure was carried out without intraoperative complications, operative time (OT) was 190 minutes, docking time was 9 minutes. No system errors or faults in the robotic arms were registered. At discharge, urogynaecological examination showed a complete resolution of the prolapse. To our knowledge, this is the first RSCP procedure performed with the new Hugo™ RAS robotic system.

Conclusions

RSCP using the Hugo™ RAS system seems to be a feasible and effective approach according to results in terms of operative time, cosmetic results, postoperative pain and length of hospitalisation. Large series are mandatory to better define its benefits, advantages, and costs.

<https://player.vimeo.com/video/710493703?autoplay=1>

**ES31-0334 -
Free Communication**

Neovagina creation in congenital vaginal agenesis: innovative mini-laparoscopic approach using indocyanine green fluorescence

Andreia Fontoura Oliveira¹, Helder Ferreira²

¹Centro Hospitalar do Médio Ave, Department of Gynecology and Obstetrics, Santo Tirso, Portugal

²Centro Materno Infantil do Norte - Centro Hospitalar Universitário do Porto, Department of Minimally Invasive Gynecology, Porto, Portugal

Background

Mayer–Rokitansky–Küster–Hauser syndrome (MRKHS) is a rare congenital syndrome with an estimated incidence of 1 per 4500–5000 females, resulting in the congenital absence of the upper part of the vagina. There is still no standardized treatment for vaginal agenesis: non-invasive treatment with progressive dilation is one option as well as surgical treatment either using grafts or through vaginal elongation. Surgical repair with a minimally invasive technique is a reasonable option for these patients, as it offers rapid results along with a fast post-operative recovery. Our aim is to describe a surgical technique for neovagina creation through vaginal elongation using a mini-laparoscopic approach with indocyanine green (ICG) fluorescence imaging, and its respective results.

Methods

Retrospective study including all cases of vaginal agenesis in the context of MRKHS surgically corrected in our centre since June 2019, through a mini-laparoscopic modified Vecchietti procedure with intraoperative application of ICG fluorescence, including the surgical technique, outcomes, and complications.

Results

Between June 2019 and April 2022, nine patients with MRKHS (mean age: 20 years; mean pre-operative vaginal length: 2 cm) were submitted to a vaginal agenesis surgical repair using a mini-laparoscopic and vaginal approach for placement of an external traction device that was daily adjusted until the creation of a neovagina (modified Vecchietti procedure). During the procedure, ICG fluorescence was applied to allow for better anatomic recognition and ureteric mapping. Surgery was completed with success in all patients, with removal of the traction device between the 5th and the 8th post-operative day, succeeded by daily usage of external vaginal dilators. This technique allowed for the creation of a neovagina in approximately one week; 6 weeks after surgery all patients had a 10,5-12cm length and epithelized neovagina. Regarding complications, one patient had isolated fever at the 9th post-operative day, that was controlled with empiric antibiotics.

Conclusions

This minimally invasive technique was able to create normal length neovaginas in one week, whose size was successfully kept after surgery, allowing for satisfactory sexual function, without major complications. Therefore, the mini-laparoscopic modified Vecchietti approach using ICG fluorescence appears to be a feasible and safe option in the treatment of vaginal agenesis, with rapid results and minor complications even in the setting of an anatomically distorted pelvis.

**ES31-0058 -
Free Communication**

Operative hysteroscopy versus ultrasound guided electric vacuum aspiration for removal of retained products of conception: a cohort study.

Tjalina Hamerlynck¹, Liselot Wagenaar², Celine Radder³, Louisette Peters⁴, Steven Weyers¹, Huib van Vliet²

¹*Ghent University Hospital, Women's Clinic, Ghent, Belgium*

²*Catharina Hospital, Obstetrics and Gynaecology, Eindhoven, The Netherlands*

³*OLVG West, Obstetrics and Gynaecology, Amsterdam, The Netherlands*

⁴*OLVG East, Obstetrics and Gynaecology, Amsterdam, The Netherlands*

Background

The most widely performed surgical procedure for removing retained product of conception (RPOC) is curettage. However, evidence suggests that hysteroscopic removal might have a lower risk of intrauterine adhesion (IUA) formation and more often results in complete evacuation than curettage. This study aimed to determine whether operative hysteroscopy for removal of RPOC has higher efficiency, a lower risk of complications, and a lower risk of IUA formation than electric vacuum aspiration (EVA).

Methods

This multicenter, prospective cohort study was conducted alongside an RCT in 3 teaching hospitals and 1 university hospital from April 2015 to date. Women diagnosed with RPOC on ultrasound ranging from 1 to 4 cm, who did not want to participate in the RCT due to a preference for a specific treatment option, were included. Women opting for EVA underwent the procedure as soon as possible. In the hysteroscopy group, a diagnostic hysteroscopy was planned at a minimum of 6 weeks after the end of pregnancy, followed by removal of the RPOC at least 2 weeks later. EVA was performed using an 8 or 10 mm flexible plastic Karman cannula. Operative hysteroscopy consisted of either HM (with the TRUCLEAR 8.0 System or Elite plus (Medtronic, Minneapolis, MN, USA) or the Intrauterine BIGATTI Shaver (Karl Storz GmbH, Tuttlingen, Germany) or loop resection (with an 8.5-mm bipolar resectoscope (Karl Storz GmbH, Tuttlingen, Germany)), according to surgeon's choice and system availability. Postoperatively, a second-look hysteroscopy was offered to all patients after at least 1 menstruation or after a minimum of 4 weeks after RPOC removal to check for IUA formation and completeness of removal.

Results

In our preliminary analysis, 125 women were treated in the hysteroscopy group and 28 in the EVA group. 26 patients did not undergo surgery due to spontaneous expulsion or outpatient hysteroscopic removal of the RPOC with a forceps. The median operating time was similar between EVA and hysteroscopy group (5.50 min vs 7.58 min, $p = .076$). No statistically significant differences were observed between the hysteroscopy group and EVA for the occurrence of intra- and postoperative complications (4.8% vs 3.6% and 0.8% vs 0%). The completeness of removal of the RPOC was significantly higher (92% vs 67%, $p = .012$) in the advantage of the hysteroscopy group. We will present the final results on IUA formation at the congress.

Conclusions

Our observational data show that RPOC are more often completely removed by hysteroscopy than by EVA with a similar complication rate for both groups.

**ES31-0208 -
Free Communication**

A modified technique for lateral suspension for POP (Pelvic Organ Prolapse): initial results

Mohamed Magdy¹, Mohamed Nabi², Hossam El-Mansy³

¹*Ministry of Health, Gynecology, Cairo, Egypt*

²*Cairo University, Gynecology, Cairo, Egypt*

³*Helwan University Hospitals, OBS/GYN department, Cairo, Egypt*

Background

Lateral suspension for POP become more accepted nowadays. The real difficulty is suturing the vault to the mesh. Here we present a modified technique where the mesh is fixed vaginally. This method should facilitate the procedure and shorten the operative time without decreasing the efficacy.

Methods

We performed this technique in 13 cases who underwent laparoscopic hysterectomy for 2nd and 3rd degree uterine descent. We had 12 control cases by the classic technique by the same operator.

After delivering the uterus, the vaginal cuff is not closed laparoscopically but closed vaginally. The mesh is fixed by Prolene 2-0 on seromuscular layer of the anterior and posterior vaginal walls. The mesh is then introduced inside the peritoneal cavity. Now the vault mucosa is closed over the mesh vaginally by Vicryl 2-0. When entering the abdomen laparoscopically, the mesh will be already fixed to the vault. You can pull the two arms and continue classically.

Both techniques were compared regarding time of closing the vagina and fixing the mesh and total operative time. Difficulty was assessed using VAS scale where 1 is the easiest and 9 the most difficult. follow up for 6 months postoperatively.

Results

Both groups were comparable regarding demographic data and indications of the operation.

The time of closing the vagina and fixing the mesh was shorter in the modified technique (12 ± 3 min vs 23 ± 6 min). The same was in the total operative time (77 ± 6 min vs 87 ± 10 min) . The new technique was much easier (VAS 4.2 vs 7.5)

There was no difference in the need for the post operative analgesia between both groups. postoperative period and the follow up period for 6 months were uneventful.

Conclusions

This modified technique for lateral suspension seems to be as effective as the original technique but much easier. We acknowledge that we need lager number of patient to confirm our result and we are actually working on that.

How to ban the climate crisis out of the OR: the first sustainable guideline

Kim van Nieuwenhuizen¹, Charlotte Michels², Frank Willem Jansen¹

¹Leiden University Medical Center, Gynaecology, Leiden, The Netherlands

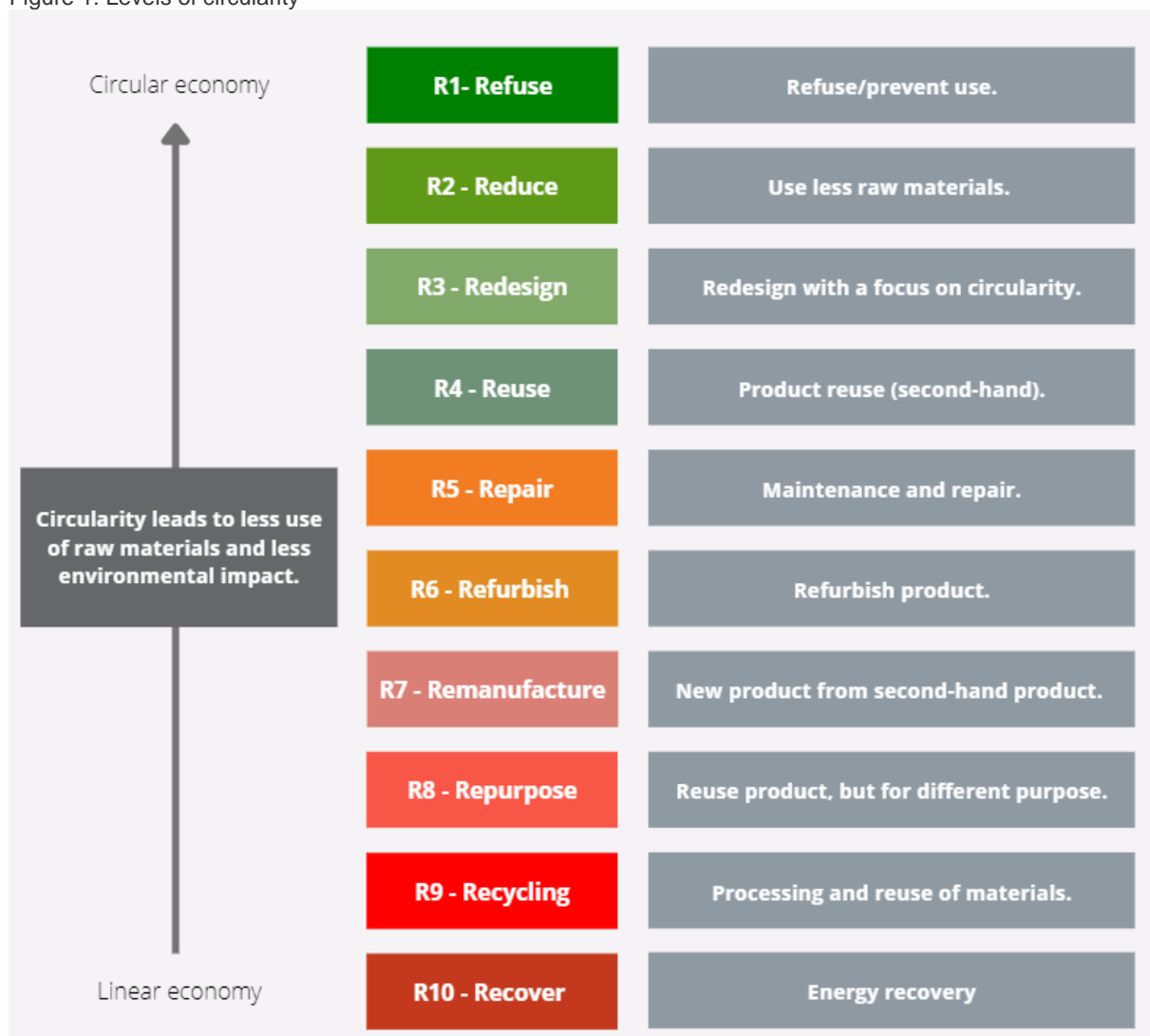
²Knowledge Institute of the Dutch Association of Medical Specialists,

Knowledge Institute of the Dutch Association of Medical Specialists, Utrecht, The Netherlands

Background

The healthcare sector produces 7-8% of our (inter)national CO₂-footprint. Whereas the OR accounts for only 6% of the hospital surface, 20-30% of hospital waste is produced at the OR, which is a result of the excessive use of disposables. The current climate crisis is a threat to the health of our ecosystems, and it indirectly menaces our own health, which obligates healthcare professionals to act. The best sustainable solutions are incorporated in the ladder of circularity (figure 1), where refusing is the best option, however surgery is still required. Awareness, scientific knowledge and governmental regulation can help to stop this crisis, but we as professionals will have to take the lead. With this mindset, we developed a guideline which comprises where to take action and includes tools to implement environmental sustainability in surgery.

Figure 1: Levels of circularity



Methods

A Dutch working group in which, among others, surgeons, gynaecologists, microbiologists, and anaesthesiologists have initiated the 'Guideline Sustainability in Clinical Guidelines'. This guideline consists of two parts. First, a literature search was conducted using PubMed, Embase, Web of Science, Cochrane and Emcare, regarding environmental sustainability in five topics: 'operating techniques', 'disposable versus reusable', 'OR cover materials', 'anaesthetics' and 'OR ventilation'. Life cycle assessments (LCAs) were included in the analysis to evaluate environmental impact. The GRADE method was used as a tool to rate the quality of evidence.

Second, tools are offered for each phase of guideline development for incorporating sustainability into guideline development.

Results

Preliminary results are shared. Five modules on OR related subjects were analysed and provided with our evidence-based considerations and recommendations. Next to that, we describe a step-by-step approach on how sustainability can be incorporated in (new) guideline development. For each phase, we provide insight into which actions can be taken by working group members and advisors of medical guideline development.

Conclusions

It is imperative that we as healthcare professionals take the lead to ban the climate crisis from the OR. With our new developed guideline, tools are given to start to reduce the CO₂ footprint of surgery. By selecting a low-impact operating technique ("straight-stick" laparoscopy versus robotics), using less disposables etc. reduction can be obtained. For example, literature shows robot-assisted laparoscopy is found to have a 1.5 times greater CO₂-footprint compared to laparoscopy and 3 times greater than laparotomy. Switching from disposable to reusable sharps containers leads to an 80% decrease in CO₂-footprint. Next to that, the use of reusable sterile surgical gowns produces 3 times lower GHG-emissions than using disposables. It is undeniable that we need to create sustainable and ensure high-quality healthcare, for ourselves, but also for the children of our children. This surgical guideline is the first evidence based, patient safe attempt to achieve this goal.

**ES31-0366 -
Free Communication**

Sacral neuromodulation in neurogenic diseases: 2 phase sacroneural implant surgery in a woman with tethered cord

Sebile Guler Cekic¹, Serdar Aydın²

¹Koc University Hospital, Obstetrics and Gynecology, Istanbul, Turkey

²Koç University Hospital, Division of Urogynecology, Istanbul, Turkey

Background

Sacral neuromodulation is a highly effective therapy. When used in urology for urinary incontinence, refractory urgency and frequency, and non- obstructive retention, it is employed after the failure of conservative measures and considered a surgical option. When used for fecal incontinence, however, it can be considered a first-line surgical treatment.

Methods

We will represent a 45-year-old woman with mixed urinary and anal incontinence due to incomplete spinal cord injury secondary to ependymoma and syringomyelia, who was diagnosed as having neurogenic bladder, bowel dysfunctions and pelvic floor muscle weakness. She had unsuccessful oral anticholinergic therapy as well as additional therapies like acupuncture. She was offered to have sacral neuromodulation surgery. Before the surgery she attended a multimodal pelvic rehabilitation program consisting of posterior tibial nerve stimulation, active pelvic floor muscle training accompanied by biofeedback and electrical stimulation of pelvic floor muscles. After an improvement with the posterior tibial nerve stimulation, she prepared for sacral neuromodulation surgery.

We applied 2 phase implant surgery. The first step which is called the temporary phase, was performed to see whether the leads were working which will be presented with x-ray pictures. In the second step a permanent battery was placed.

Results

Her recovery was remarkable. Anal incontinence resolved totally, urinary incontinence recovered %70 and her Female Sexual Function Index improved significantly.

Conclusions

To conclude this is a case who was frustrated and ceased all the treatments due to side effects or incompatibility for years, experienced the beneficial effects of a multimodal pelvic rehabilitation program and sacral neuromodulation surgery in whom neuromodulation became a cure. Proper patient selection and optimal lead placement are the key determinants of success of sacral neuromodulation.

<https://player.vimeo.com/video/710565925?autoplay=1>

Re-sacrocolpopexy in case of relapse after laparoscopic sacrocolpopexy: a surgical video

Evgenia Bousouni¹, Dimitri Sarlos¹

¹Kantonsspital Aarau, Frauenklinik, Aarau, Switzerland

Background

Laparoscopic sacrocolpopexy has been demonstrated to be the gold standard of prolapse surgery in cases with apical defect. According to our data, we have a result in a subjective cure rate of 95.3 % after laparoscopic sacrocolpopexy. Although recurrence can occur in up to 10% of cases and additional surgery is needed in about 5-6%. Recurrence of apex is very rare but recurrence of anterior compartment according to our data is about 6%. Isolated anterior compartment failure can occur especially if paravaginal defect has initially been present. A recurrence in anterior compartment is difficult to correct: an option is a vaginal anterior Mesh with high rates of dyspareunia and pain. In the last 1.5 years, we went in recurrences after laparoscopic sacrocolpopexy through re-sacrocolpopexy and the first results are very encouraging.

Methods

The Video demonstrates the case of a 50 year old patient undergoing laparoscopic re-sacrocolpopexy because of combined re-prolapse after primary laparoscopic sacrocolpopexy. The main problem is a recurrence of anterior compartment with paravaginal defect, the apex descends just a little. The old mesh will be left; trying to remove has risks without benefits. The preparation is anatomically more difficult, but the old mesh does not bother the placement of the new one. The anterior dissection is started by opening the vesico-vaginal space and separating the bladder from the vagina down to the level of the bladder trigone. Lateral dissection is performed by opening the paravaginal space and exposing the lateral edge of the vagina. The distal part of both ureters is dissected from the anterior parametrium to the bladder to avoid ureteral damage. The anterior mesh is then sutured to the distal vagina in the midline and laterally to the edge of the vagina. After the anterior preparation, we accomplish supracervical hysterectomy and then we perform the posterior dissection. The posterior mesh is sutured to the levator ani muscle or the posterior vagina and the cervix. Both meshes are fixed at the longitudinal ligament of the promontory to guarantee a tension free suspension. This can be challenging after sacrocolpopexy because of the anatomical restriction and scarring by previous mesh fixation to the longitudinal ligament of the promontory.

Results

The outcome of laparoscopic re-sacrocolpopexy in our patient group is excellent. We made in the last 1.5 years about seven cases of recurrence after laparoscopic sacrocolpopexy. As we are following all our patients after re-sacrocolpopexy, we have very good results at least in the short-term follow up.

Conclusions

Laparoscopic re-sacrocolpopexy seem to be feasible and safe and is an option to correct laparoscopically recurrences in order to avoid vaginal surgery after primary laparoscopic sacrocolpopexy. Prospective anatomical and functional evaluation and data analysis must be done to scientifically verify these promising initial results.

<https://player.vimeo.com/video/712533336?autoplay=1>

**ES31-0499 -
Free Communication**

Utility of rehabilitation treatment in perineal damage by delivery: 3D / 4D ultrasound study of the Levator ani muscle

Alessandro Serva¹, Annalisa Tiberi¹, Angela D'Alfonso¹, Erika Pelaccia¹, Matteo Bruno¹, Maurizio Guido¹
¹University of L'Aquila, Department of Gynecology and Obstetrics, L'Aquila, Italy

Background

The aims of the study were evaluating the existence of a statistically significant correlation between perineal lacerations (grade II, III and IV) and levator ani muscle damage (LAM). The macrotrauma or the microtrauma were identified to the 3D / 4D reconstruction with trans perineal ultrasound. The secondary aim was to demonstrate the effects of rehabilitation of the pelvic floor by comparing measures of muscle thickness at rest, with 3D perineal ultrasound before and after perineal rehabilitation therapy.

Methods

From January 2018 to April 2021 in the Pelvic Center of the Obstetrics and Gynecology Department of San Salvatore di L'Aquila hospital, 296 primiparous were enrolled in the study with perineal lacerations of II, III and IV degrees, after three months from vaginal delivery and Perineal Card score > 4. This is a card that lists various conditions that may occur before, during and after childbirth, each of which is associated with a score in relation to potential damage to the pelvic floor. 112 patients reported grade II lacerations; 88 grade III lacerations; nobody grade IV lacerations and 96 patients underwent episiotomy. Among the patients who were recommended for rehabilitation treatment (10 individual sessions of physiokinesis-therapy lasting 45 minutes twice a week), 96 were evaluated clinically and ultrasonographically at 3 months from the end.

Results

The analysis of the results obtained from this study did not reveal a statistically significant correlation between grade II lacerations, including episiotomy, and anatomical damage of the LAM. In contrast, a strong correlation with grade III lacerations has been demonstrated ($p=0.0148$). Furthermore, it emerged that the average thickness of the levator ani muscle before rehabilitation is 10.59mm, after rehabilitation 11.16mm. There was an increase in the thickness of the LAM after training in almost all the patients treated with an average increase of 0.57 mm.

Conclusions

The association between grade III perineal lesions and LAM damage reconfirms the role of high-grade lacerations in the etiopathogenesis of perineal anatomical damage and the possible re-evaluation of the protective role of the episiotomy towards laceration of a greater degree. Our data confirm the efficacy of pelvic floor rehabilitation as the main method of post-partum perineal recovery by increasing the average thickness of the LAM. The staff in charge has the task not only of treating the pathology, but also of offering these women useful tools for their perineal health.

**ES31-0468 -
Free Communication**

Vaginoscopic septotomy of a blind right vagina in adolescent with d'Herlyn-Werner-Wunderlich syndrome

Amal Mouzali¹, Mechri Nabila¹, Tayebi Youcef¹

¹Medecine, CHU Douera, Algiers, Algeria

Background

Herlyn-Werner-Wunderlich syndrome is a rare congenital anomaly of the urogenital tract. It is defined by the triad of a didelphys uterus, a blind hemivagina and ipsilateral renal agenesis. The diagnosis is usually made shortly after menarche.

Methods

We present a clinical case of a 14-year-old virgin girl, consulting for intense dysmenorrhea involving since her menarche (04 months before). Patient presented cyclical dysmenorrhea.

Clinical, ultrasound and MRI explorations revealed the presence of a uterovaginal malformation as well as a unilateral renal agenesis, classified according to ESHRE /ESGE U3b, C2, V2.

She had normal menses from the non-obstructed side, but her hemi-vaginal obstruction caused symptoms 10/10 from EVA.

The treatment was a vaginal septotomy with hysteroscopic edges resection in this adolescent virgin using an 18.5 Fr and bipolar energy.

Results

We performed a control vaginoscopy 05 months after the first one and the result was good with patency of right vagina therefore her problem is definitely resolved.

Conclusions

Vaginoscopic septotomy is the treatment of choice for blind vaginal anomaly.

<https://player.vimeo.com/video/715415916?autoplay=1>

ES31-0550 - Free Communication

Artificial intelligence for detection, recognition and 3D orientation estimation of surgical tools

Sara Paracchini¹, Madalena Tavares², Navid Rabbani³, Alessandro Buda¹, Adrien Bartoli³, Nicolas Bourdet⁴

¹*Ospedale Michele e Pietro Ferrero, Ginecologia Oncologica, Verduno, Italy*

²*Hospital Vila Franca de Xira, Gynecology and Obstetrics Service, Lisbon, Portugal*

³*ENCOV, Université Clermont Auvergne, Clermont-Ferrand, France*

⁴*CHU Estaing, Department of Gynecology, Clermont-Ferrand, France*

Background

Our project strives to bring artificial intelligence straight into laparoscopy, by training the computer to detect, recognise and estimate the 3D orientation of an instrument in the operative field. This may enhance the quality, safety and cost effectiveness of surgical procedures, help operating room workflow organisation and reduce complications related to dangerous instruments such as the morcellator.

The objective of this “ad interim” analysis is to define the most convenient method to guide the machine learning process on instrument detection, recognition and segmentation. We report results on three specific tasks.

Methods

The project was launched in December 2020 and is ongoing. A multidisciplinary team was established with an initial goal of designing and collecting a dataset towards training a specialised deep neural network model.

To achieve it, we built up a library of surgical anonymised videos and a comprehensive classification of devices, resulting in 12 instrument classes, each with variants, for instance “Energy instrument” -> “Bipolar” -> “Robi”. The instruments were also tagged as cylindrical and non-cylindrical according to their shaft.

The online image labelling software Supervise.ly was used to annotate the images with their classes, variants, masks and geometric primitives.

We have used Mask-RCNN, a neural network system adapted to object detection, which we specialised to detection, classification, and segmentation of the instruments. Technically, our implementation of Mask-RCNN uses the ResNet-50 backbone, a successful neural network architecture, pretrained on the large-scale Microsoft COCO-2017 dataset.

We used the standard mean average precision (mAP) metric to evaluate instrument detection.

Results

A total of 985 representative images, each taken from a different surgical sequence, were selected from the original dataset and split into two groups: the training dataset with 885 images and the test dataset with 100 images.

Three experiments were done:

- A 2-class experiment (cylindrical instrument vs absence of instrument) - mAP 66.9 %.,
- A 3-class experiment (cylindrical instruments vs non cylindrical instruments vs absence of instrument) - mAP 42%,
- A 12-class experiment (11 instrument classes vs absence of instrument) - mAP 39.2 %

In contrast to the expectations, the accuracies for 2nd and 3rd experiments are comparable. It shows a proper categorization of the tools can decrease the training complexity even for a hard task of 12-class tool detection but requires a larger pool of instances per instrument.

Conclusions

Standing on this preliminary data analysis, segmentation of surgical tools by classes gives more promising results than the simpler cylindrical and non-cylindrical classification.

This is encouraging for further improvement of the dataset.

**ES31-0098 -
Free Communication**

Initial experience of V-NOTES in gynaecology

*Estela Marquez Muñoz¹, Antoni Pessarrodona Isern², Ana Paula Velez Vintimilla¹, Jordi Cassado Garrida³,
Marta Hinarejos Companyo¹, Jordi Rodriguez Gonzalez³*

¹Gynecology and Obstetrics Resident, Gynecology and Obstetrics, Hospital Universitari Mutua De Terrassa, Spain

²Gynecology and Obstetrics Emerit Boss, Gynecology and Obstetrics, Hospital Universitari Mutua De Terrassa, Spain

³Gynecology and Obstetrics, Gynecology and Obstetrics, Hospital Universitari Mutua De Terrassa, Spain

Background

Evaluation of the introduction of Vaginal Natural Orifice Transluminal Endoscopic Surgery in the treatment of benign gynaecologic pathology.

Methods

Patients undergoing V-Notes gynaecologic procedures between January 2021 and March 2022. Patients with a history or suspicion of endometriosis, PID and rectal surgery were excluded.

Results

We have performed 50 interventions through V-Notes. We have divided the patients in to 2 groups, patients with myomatous uterus suffering metrorrhagia (32), patients with other pathologies, the miscellaneous group (18).

In the polymiomas uterus group, the mean age was 48 years and a BMI of 32.8, 6 patients had not had any vaginal delivery and 13 patients had a previous caesarean section.

The mean operative time was 73 (39-135) minutes, the mean of the uterine weight was 540 gr (122-2880).

There was one Dindo III complication, postoperative uterine artery bleeding that required reoperation and transfusion: and two Dindo I complications, a self-resolving cuff hematoma and a low urinary tract infection.

No other complications were observed at the 6-week follow-up.

There was only one conversion to mini Pfannestiel due to the impossibility to morcellate through vagina a 2880 gr uterus after the hysterectomy was performed.

In the Miscellaneous group, the mean age was 57 years and BMI of 27.

The mean operative time was 54 (22-105) minutes the mean weight of the uterus was 113 grams.

Conclusions

In a team with standard training in vaginal and laparoscopic surgery the introduction of V-Notes technique is quick and easy.

The V-Notes technique allows to operate through the vagina patients in which this access would be complex or impossible. It gives good access to the adnexa and abdominal cavity.

Moreover, the neumooperitoneum pressure is lower than in a laparoscopic abdominal surgery (6mmHg compared with 10-12 mmHg). This benefits the patients' suffering diseases that will not tolerate low cardiac preload, for example cardiopathy or high anesthetic risk.

Another advantages are that this surgical approach avoids all the complications of abdominal access, such as: trocar bleeding, postoperative pain, hernias, etc.

The postoperative period generally has minimal pain levels, which allows early discharge.

However, it exists a formal contraindication for patients affected by occluded pouch of Douglas secondary to endometriosis or PID.

**ES31-0030 -
Free Communication**

The new generation articulated laparoscopy in gynecology surgery

Aya Mohr-Sasson¹, Mason Hui¹, Asha B. Bhalwal¹, Alvaro I. Montealegre¹, Mateo G. Leon¹

*¹McGovern Medical School at The University of Texas Health Science Center,
Advanced Minimally Invasive Gynecologic Surgery, Houston, USA*

Background

To discuss the advantages and disadvantages of a novel articulated laparoscopic device compared to conventional laparoscopy and to demonstrate its benefits using a simulator model.

Methods

We present a novel articulated laparoscopic instrument and our experience with the implementation of this device using a laparoscopic simulator box. Interventions presented are the standardized Fundamental laparoscopic skill (FLS) peg transfer, tip positioning and laparoscopic suturing.

Results

Conventional laparoscopy requires high skills mainly due to challenging ergonomics and a two-dimensional vision. Robotic surgery flourished as it improves precision with wristed instruments making surgical movements more intuitive and easier to master. However, limitations of robotic surgery include the absence of haptic or tactile feedback and a higher cost. Additionally, availability may be a problem in certain settings. We present a novel hand-held articulated laparoscopic device that provides haptic feedback, short set up time, and lower cost while improving precision and dexterity with wristed instruments.

Conclusions

This novel articulated laparoscopic instrument may be an option to offer minimal invasive surgery with increased dexterity at a lower cost compared with robotic surgery. This option potentially combines the benefits of conventional laparoscopy and robotic surgery. Future research is needed to determine the learning curve and operative advantages of this device.

<https://player.vimeo.com/video/704645609?autoplay=1>

**ES31-0564 -
Free Communication**

Hysteroscopic, laparoscopic and robotic repair of isthmocele: a systematic review of current literature

Elias Tsakos¹, Ioanna Koutra², Emmanouil M. Xydias², Konstantina Papageorgiou², Alexandros Daponte³, Apostolos C. Ziogas²

¹*Embryoclinic, Department of Robotic Surgery, Thessaloniki, Greece*

²*University of Thessaly- School of Health Sciences, Department of Medicine, Larissa, Greece*

³*University of Thessaly- Larissa University Hospital, Department of Obstetrics and Gynecology, Larissa, Greece*

Background

Isthmoceles arising after caesarean delivery can lead to a plethora of symptoms such as abnormal uterine bleeding, pelvic pain, infertility, and risk of major complications during future pregnancy. The present review aims to assess the effectiveness and risks of the various minimally invasive surgical treatment options for symptomatic isthmoceles. In particular, the current review focuses on hysteroscopic, laparoscopic and robotic isthmocele repair, as well as the comparison between them.

Methods

The online databases PubMed/MEDLINE, Scopus, Web of Science were systematically searched for original articles on the different treatment options for isthmocele published between 2001 and 2022. Available studies were thoroughly evaluated in accordance with the PRISMA guidelines and with appropriate risk of bias assessment tools.

Results

From the initial pool of 441 studies, in the end 60 were about isthmocele treatment and from those, a final pool of minimally invasive surgical treatment options was formed. This pool contained 23 studies and 1812 patients for the hysteroscopic approach, 13 studies and 465 patients for the laparoscopic approach and 3 studies with 22 patients for the robotic approach, along with a few comparative studies with more than one method included. The choice of optimal approach was highly dependent on the individual case, mainly on clinical manifestations, ultrasonographic findings and family planning. Despite the lack of consensus, certain consistent trends indicated that minimally invasive techniques were favoured over more invasive ones, caused less complications and were overall more effective in myometrium repair. The hysteroscopic approach was the method of choice for most surgeons, due to shorter operating time, minimal blood loss and reduced hospitalization time, however, did come with increased risk of bladder injury and loss of uterine wall strength. Laparoscopic and robotic approaches were most frequently favoured in women that desired pregnancy as they facilitate effective repair and restoration of uterine anatomy with minimal scarring, with the latter remaining a less researched approach than the other two.

Conclusions

Isthmocele or caesarean scar defect is being recognized more and more as a possible cause of infertility and obstetric complications during future childbirths, as frequency of caesarean deliveries is on the rise. Surgical repair is key in the prevention of such unfavourable outcomes, with minimally invasive techniques such as hysteroscopic, laparoscopic and robotic approaches being the preferred options in most cases. There is no consensus on which of the three is superior or more suitable for specific cases, thus more research is required, on the robotic approach in particular.

**ES31-0057 -
Free Communication**

Never give up after 1 attempt in Grade 5 Asherman Syndrome

Esther Kuijper¹, Miriam Hanstede¹

¹Spaarne Gasthuis, Obstetrics and Gynaecology, Haarlem, The Netherlands

Background

Grade 5 Asherman Syndrome is often considered hopeless and therefore patients are denied treatment.

Methods

We present our video in which we demonstrate how to manage Grade 5 Asherman Syndrome by performing a transcervical adhesiolysis guided by fluoroscopy. After 1 attempt we failed to reach the uterine cavity and an MRI was performed showing functional endometrium higher up. This made us decide to try again with good result. Hysteroscopic, fluoroscopic and MRI images are shown, and methods of use are explained. After each procedure we left a copperless IUD and treated the patient with oestrogens (2 mg 2 times a day) for 6 weeks.

Results

After an initial failure to reach the uterine cavity, we managed to do so in a second attempt. We were able to reshape the cavity and an outpatient hysteroscopy 8 weeks after the successful procedure showed no recurrent adhesions. Our patient got pregnant spontaneously.

Conclusions

We advise to try at least 2 times to reshape the uterine cavity in Grade 5 Asherman Syndrome by using conventional hysteroscopic instruments and fluoroscopic guidance. MRI imaging could be helpful in locating any functional endometrium higher up.

<https://player.vimeo.com/video/708385666?autoplay=1>

**ES31-0338 -
Free Communication**

Transition of minitouch outpatient endometrial ablation to a community health service

Yatin Thakur¹, Amaju Ikomi¹, Vidya Thakur², Reetam Singh¹, Nanak Bhagat¹

¹*Basildon University Hospital, Department of Gynaecology, Basildon, United Kingdom*

²*Broomfield Hospital, Department of Gynaecology, Broomfield, United Kingdom*

Background

The first objective is to assess the feasibility of endometrial ablation in a community health service. The second objective is to evaluate the additional clinical value of new customised features of the Minitouch Endometrial ablation system.

Methods

We have performed office setting Minitouch ablations for heavy menstrual bleeding in our district general hospital since 2015. The outpatient team comprised a gynaecologist, a nurse, and a health care assistant (HCA). As cervical dilatation is not required for this 3.8mm diameter device, the procedure tray needs only a disposable speculum, vulsellum (if required), Pipelle catheter, and a cleaning preparation. Our standard heavy menstrual bleeding evaluation includes endometrial biopsy and transvaginal ultrasound scan and/or hysteroscopy. Since 2017, energy delivery customisation features (e.g., temporary pause, power adjustment) have been used when needed to further optimise patient comfort and satisfaction. As previously, patients were also instructed to take pre-procedure analgesia at home (typically paracetamol/codeine, diclofenac, ibuprofen, paracetamol). Entonox (inhaled nitrous oxide) was kept available as a rescue analgesic.

A retrospective observational cohort study of the safety outcomes of the 84 latest cases carried out between 2018 and 2022, using the customisation features of the ablation system was performed. Available data from procedure notes and routine follow up notes were analysed. Both sets were reviewed for intra and post-operative adverse events (if any).

Results

The procedure and the follow-up notes were available for all (n=84) patients. The patients received the Minitouch procedure without endometrial pre-treatment or menstrual cycle timing. Mean sounding length was 8.6cm (n=51, range 8.0-14.0cm) and mean cavity length was 5.5cm (n=57, range 4.0-9.0cm). No patients received local or general anaesthesia or sedation. The target energy dosage was set at 4800J for the main(fundus) treatment and 1200J for each extension treatment (for cavities > 4.0cm). The mean energy dose delivered was 5569J (n=81, range 3000-7200J). No cases were abandoned for patient not tolerating the procedure or for any other reason. The VAS pain scores (range 0–10) reduced immediately after the energy delivery. The mean pain score immediately post-ablation was 2.0 (n=52, range 0-7) and at discharge, it was 0.8 (n=60, range 0-6). No patient required a recovery room stay and all were discharged within 15 minutes of the procedure. Mirena was inserted in three patients after the ablation for contraception. There were no intra-operative or post-operative adverse events reported. Outcomes available for a limited number of patients were consistent with previously reported high success rates at our sites.

Conclusions

Office setting Minitouch ablation, using minimal resources, has proved to be a safe and well tolerated procedure in the community health service. Customisation features have enhanced patient comfort without affecting clinical outcomes.

**ES31-0482 -
Free Communication**

From a primary dysmenorrhea to a primary iatrogenic dyspareunia: when staplers are used to treat a vaginal septum

Enrico Tognazzo¹, Dubuisson Jean¹, Farida Akhoundova Sanoyan¹ (Switzerland)

¹Hopitaux Universitaires Genève, Gynécologie et Obstétrique, Genève, Switzerland

Background

A 14-year-old patient with a congenital genital malformation was firstly diagnosed by MRI as having an OHVIRA (Obstructed Hemi-Vagina and Ipsilateral Renal Anomaly) syndrome with a bicornuate uterus and left renal agenesis. A left hemato colpos was treated by section of the vaginal septum with a Endo-GIA stapler. She was secondarily referred when she was 21 years old for management of major dyspareunia related to staples. An MRI at this time described a complete septate uterus with two cervixes.

Methods

We performed a complementary resection of the vaginal septum and a vaginoscopy with staples removal with Betocchi hysteroscope.

Thank to images of a previous laparoscopy we could correct the diagnosis confirming that it was a case of septate uterus and not a bicornuate uterus. Clinical examination under general anaesthesia showed a single septate cervix.

With this information we could proceed to the direct section of the cervical septum and to the hysteroscopic section of the complete uterine septum, to ameliorate the obstetrical prognosis.

Results

The patient reported an important reduction in the intensity of dysmenorrhea and no more dyspareunia. She still does not have tried to conceive.

Conclusions

A precise diagnosis of the type of the genital malformation is necessary to correctly address the surgical management.

The diagnosis of complexes genital malformations can still be difficult relying only on imaging.

Automatic staplers are to avoid as surgical devices for the section or the resection of a vaginal septum.

<https://player.vimeo.com/video/715556630?autoplay=1>

**ES31-0535 -
Free Communication**

Tips and tricks in laparoscopic hysterectomy without uterine manipulator

Dimitrios Zygouris¹, Sofia Papadimitriou², Evgenia Stergiannakou¹, Andreas Kavallaris¹

¹St. Luke's hospital- Thessaloniki- Greece, Department of minimally invasive Gynecology-, Thessaloniki, Greece

²University Hospital of Ioannina- Ioannina- Greece., Department of Blood Transfusion-, Ioannina, Greece

Background

The objective of this retrospective study was to evaluate the feasibility and safety of Total Laparoscopic Hysterectomy (TLH) without manipulator or any vaginal tube. We describe our technique step by step and present our data on intra-operative and post-operative morbidity.

Methods

Between January 2011 and January 2021, we performed 1.142 Total Laparoscopic Hysterectomies, without using any kind of uterine manipulator in women with benign indications for hysterectomy. We analyzed retrospectively perioperative and postoperative outcomes. During the operation we used bipolar forceps and Laparoscopic Ligasure™ and vagina was Laparoscopically sutured with absorbable individual sutures. All operations were performed by the same surgical team.

Results

The average age was 52.1 years and BMI 27.1 kg/m², while the mean operative time was 78 min (43-168 min), the estimated blood loss was 59 mL (20-260 ml) and the mean uterine weight was 262 g (40-1580 g). There was no case of conversion to laparotomy. A blood transfusion was required for 16 patients (1.4 %), while there was one case of ureteral injury and three cases where the bladder was opened and fixed laparoscopically. The average hospital stay was 1.1 days, with only 40 patients staying for two or more days. In the long term, we had six cases (0.5 %) of vaginal vault dehiscence and one case of vaginal vault hematoma.

Conclusions

A TLH without the use of a uterine manipulator is a feasible and safe procedure. While it is perhaps a more demanding procedure for young doctors, when performed by well-trained and experienced laparoscopic surgeons, the procedure entails a short operative time and a low complications rate. As such, it should be the first step in the training of young doctors for performing laparoscopic radical hysterectomies.

**ES31-0181 -
Free Communication**

Total laparoscopic hysterectomy technique without using any kind of uterine manipulator

Irakli Todua¹, Tamriko Dzotsenidze², Tamar Giorgadze², Mariami Matcharashvili²

¹MD, Medical center "Innova", Tbilisi, Georgia

²Medical Center "Innova", Department of Operative Gynecology, Tbilisi, Georgia

Background

Hysterectomy remains one of the most frequently performed gynecological operation. There are a number of techniques of laparoscopic hysterectomy documented in the literature. The purpose of this video presentation is to demonstrate the safety and reliability of total laparoscopic hysterectomy technique without using any kind of uterine manipulator.

Methods

Surgical steps are as the follows:

1. Traction of the round ligament by assistant, followed by its coagulation and transection, dissection of anterior leaf of the broad ligament
2. Section of the posterior leaf of the broad ligament, coagulation, and transection of the infundibulo-pelvic ligament
3. Opening of the uterovesical fold and entering the retrovesical space anteriorly; transection of the uterosacral ligament posteriorly
4. Uterine vessels are coagulated and cut
5. Same steps are repeated on the opposite side, traction of the round ligament is performed by the surgeon himself
6. Vagina is plugged with a sterile tampon wrapped in a sterile glove
7. Circular colpotomy, close to the cervical edge, is performed
8. Extraction of the uterus from vagina
9. Closure of the vaginal vault

Results

Total laparoscopic hysterectomy can be performed without using uterine manipulator or vaginal tubes following the steps demonstrated. This technique showed the low frequency of the intra and postoperative complications, while the mean operative time was 37 min.

Conclusions

Demonstrated technique of THL seems to be a safe and useful surgical method as it promotes standardization of the hysterectomy without using an uterine manipulator and second assistant. Also we recommend it as a first step in the training of young doctors for performing laparoscopic radical hysterectomies.

<https://player.vimeo.com/video/710299228?autoplay=1>

Machine learning in minimal invasive gynecology: promises and pitfalls

Eleni Karatrasoglou^{1,2}, Adrien Bartol^{3,4}, Michel Canis^{5,6}, Nicolas Bourdel^{5,7}

¹University Hospital of Clermont-Ferrand, Department of Gynecologic Surgery, Clermont Ferrand, France

²National And Kapodistrian Univeristy of Athens, Department of Gynecology, Athens, Greece

³University of Clermont Auvergne, Computer Science, Clermont-Ferrand, France

⁴University Hospital of Clermont-Ferrand, Clinical Research And Innovation, Clermont-Ferrand, France

⁵University Hospital of Clermont-Ferrand, Department of Gynecologic Surgery, Clermont-Ferrand, France

⁶University of Clermont Auvergne, Department of Medicine, Athens, France

⁷University of Clermont Auvergne, Department of Medicine, Clermont-Ferrand, France

Background

Machine learning is a set of methods to construct predictive models from data. it is a branch of artificial intelligence based on the idea that systems can learn from data, identify patterns, and make decisions with minimal human intervention. in clinical medicine, the rise of machine learning based applications represents a new era, particularly in machine based surgical assistance. The creation of these applications occurs at the interplay between the surgeons and the scientists. The inability to conduct an efficient joint development may become a pitfall on the way.

Methods

Review of literature and clinical research

Results

Machine learning uses algorithms to train models with a wide range of possible inputs, known as covariates. amongst these models, The deep neural networks have recently achieved tremendous performance on previously unresolved problems and bears high promises. This owes to their flexibility to account for complex, nonlinear relationships between the model inputs and outputs. for instance, deep neural networks were recently used as predictive models for the length of stay after gynaecologic surgery, for surgical complications and the length of surgery and for the identification of childbirth delivery methods.

However, the creation of successful models includes pitfalls. We discuss four of these pitfalls and give suggestions to mitigate them. The first pitfall is the relevance of creating the model. It is mitigated by conducting a prior critical assessment of the clinical scenario in question and an evaluation of the related prognostic models already in use. The second pitfall is a poor design of the dataset used to create the model. This dataset can be too limited, biased or lacking variety. Physicians are very commonly unaware that bias is a problem in machine learning. not all physicians use unbiased data sources or continuously monitor bias. The consequences are the inability for the model to generalise and a limited reproducibility of the results by other groups. The third pitfall is to create an overly complex system. This is mitigated by carefully considering the extent of existing neural network architectures. The fourth pitfall is the lack of carefully designed success criteria. This is mitigated by reviewing how the achievement of the baseline models and of neural network models developed in related problems are quantified.

Eventually, we recall that the creation of neural network models involves the collaboration between physicians and data scientists. An early and clear communication between the two parties must be ensured to minimise the extent of misunderstanding.

Conclusions

Machine learning has the potential to create predictive models to assist surgery and improve the general clinical system. using such models in practice should not introduce any difficulty. However, machine learning must be used wisely, in close collaboration with the data scientists, introduced as early as possible in the process.

**ES31-0017 -
Free Communication**

Hand driven hysteroscopic tissue removal (ResectrTM 9fr) versus motor driven hysteroscopic tissue removal (TruclearTM) for the resection of endometrial polyps: a randomized controlled non-inferiority trial
Steffi van Wessel¹, Tjalina Hamerlynck², Huib van Vliet³, Dick Schoot³, Steven Weyers²

¹*Ghent Universital Hospital, Women's Clinic, Ghent, Belgium*

²*Ghent University Hospital, Women's Clinic, Ghent, Belgium*

³*Catharina Ziekenhuis, Obstetrics and Gynaecology, Eindhoven, The Netherlands*

Background

Three meta-analyses have been performed to compare the hysteroscopic tissue removal systems with electrosurgical resection for the removal of polyps and type 0 and 1 myomas. Subgroup analysis of data derived from randomized controlled trials revealed a significantly shorter operating time for hysteroscopic tissue removal systems (mean difference (MD) 4.5 minutes). Subgroup analysis per pathology however showed only a benefit for the removal of polyps (MD 7.8 minutes).

However, the development of devices continued and a new hand driven hysteroscopic tissue removal system, ResectrTM 9fr. (Minerva Surgical St Clara CA), was CE marked in 2016 and FDA approved in 2020. Its potential benefits are a simplified setup, because of the replacement of the electric powered control, and a larger working window.

The aim of this RCT was to compare the hand driven tissue removal system (ResectrTM 9fr.) with the motor driven tissue removal system (TruclearTM) for the removal of polyps in terms of procedure time, surgeon's convenience, safety, complications, conversion rate and completeness of removal.

Methods

Design: Randomized controlled non-inferiority trial.

Setting: Multicentre trial: Catharina Hospital (Eindhoven, the Netherlands) and Ghent University Hospital (Ghent, Belgium).

Patients: 140 women with endometrial polyps (≥ 8 - ≤ 20 mm) scheduled for hysteroscopic removal.

Interventions: Hysteroscopic polypectomy using a hand driven (ResectrTM 9fr.) or a motor driven tissue removal system (TruclearTM).

Results

Mean installation time was 10% shorter with the hand (H) compared to the motor (M) driven tissue removal system (estimated mean ratio H/M = 0.9; 97.5% Confidence interval (CI) 0.8 - 1.1). Mean resection time was 30% longer with the hand driven compared to the motor driven system (estimated mean ratio H/M = 1.3; 97.5% CI 0.9 - 1.9). Mean total procedure time was 10% longer with the hand driven compared to the motor driven tissue removal system (estimated mean ratio H/M = 1.1; 95% CI 0.91 - 1.298). The estimated odds (M/H) of a better surgeon's safety, practical and comfort score were, respectively, 4.5 (95% CI 0.9 - 22.1), 7.0 (95%CI 1.5 - 31.9), and 5.9 (95%CI 1.1 - 30.3). Conversion rates and incomplete resection rates were comparable in both groups (H versus M) (7.6% (4/66) versus 2.9% (2/68) and 6.1% (4/66) vs 3.0% (2/66), respectively). No intra- and postoperative complications were registered.

Conclusions

The hand driven tissue removal system was non-inferior to the motor driven tissue removal system for polyp resection in terms of mean installation and total procedure time. Results on resection time were inconclusive. Conversion and incomplete resection rates were within the range reported in the literature. Surgeon's reported rating for both devices was high, however, in favour of the motor driven tissue removal system. Patients were satisfied with both techniques.

**ES31-0114 -
Free Communication**

Vaginal natural orifice transluminal endoscopic surgery (vNOTES): a prospective multicentre study to evaluate feasibility and post-operative outcome

Francesca Massimello¹, Maria Lieta Interdonato², Paolo Mannella¹, Paolo Scollo³, Mario Giuseppe Meroni², Tommaso Simoncini¹

¹University of Pisa, Gynecology and Obstetrics, Pisa, Italy

²Grande Ospedale Metropolitano Niguarda, Gynecology and Obstetrics, Milan, Italy

³Ospedale Canizzo, Gynecology and Obstetrics, Catania, Italy

Background

Vaginal Natural Orifice Transluminal Endoscopic Surgery (vNOTES) represents an innovative mini-invasive technique to perform gynecological surgery. However, vNOTES indications, safety, potential advantages and long-term effects on sexual function are still debated. This study is aimed to evaluate the sexual function and overall satisfaction of patients subjected to gynaecological procedures through vNOTES. Another purpose of this study is to explore possible limitations of the application of vNOTES for gynaecological diseases in complex cases (large uterus, obesity, previous abdominal surgery).

Methods

This prospective multicentric observational study was conducted between March 2021 and May 2022. During the study period, we enrolled 60 women who underwent vNOTES surgery for gynaecological indications. All surgeries were performed by five surgeons in three Italian tertiary centres. Data were collected from patient files, during surgical procedures, and hospitalization. Patient's pain, satisfaction and sexual function were assessed using the VAS, PGI-I and FSFI questionnaires at 7 days, 60 days, and 6-months.

Results

During the study period, 50 (83.3%) patients underwent to vNOTES hysterectomy, meanwhile 10 (16.7%) have been subjected to vNOTES adnexal procedures. Average BMI was 24.8(6.4). Eight patients (13.3%) had a BMI \geq 30, of which 2 had severe obesity (BMI $>$ 45). Mean uterine weight was 290.7g. In 38% of hysterectomies involved large uterus, defined as uterus with a weight \geq 300g (range 300-1400g). During vNOTES hysterectomies, complication rate has been 8.3% and in five patients (8.3%) conversion to laparoscopy or vaginal surgery was needed. Obesity, large uteruses, previous C-sections, and abdominal surgery were not associated to a statistically significant increase of intra- and post- operative complications and conversion rate ($p>$ 0.05). No intraoperative complications and conversions occurred in patients who underwent to adnexal vNOTES surgery. Mean VAS score the day of surgery, the first day after surgery, at 7 days and 60 days were 2.9, 2.1, 1.7 and zero respectively. Mean PGI-I the day of surgery and the first day after surgery were 3.3 and 2.9 respectively. Mean FSFI at 6 months from surgery was 55.4.

Conclusions

vNOTES can be safely used to perform gynaecological procedures, even in complex cases as obesity, large uteruses, previous abdominal surgery. This approach is associated to low post-operative pain, high patients' satisfaction, without impacts on sexual function.

**ES31-0256 -
Free Communication**

Emergency surgical management on intracavity fibroid degeneration: a case series using a novel technique

Wioletta Kapadia¹, Elspeth Cumber², Aneeka Khan², Stewart Disu¹

¹London North West University Healthcare NHS Trust, Obstetrics and Gynaecology, London, United Kingdom

²London North West University Healthcare NHS Trust, Anaesthesia services, London, United Kingdom

Background

Leiomyomas are the most common benign tumours of the female genital tract. A submucosal fibroid may become pedunculated progressively, causing irritability and contractions of the uterus leading to cervical dilatation. A prolapsed pedunculated myoma into the vagina consequently becomes necrotic due to inadequate blood supply through the long pedicle which can also cause torsion of pedunculated myoma.

Methods

This video shows two emergency presentations of rather large solitary intracavity fibroids. Both presented out of hours to the Emergency Department in a busy Northwest London hospital with heavy vaginal bleeding and acute pelvic pain and with evidence of sepsis secondary to infarction and necrosis of the lesion. Both patients were in reproductive age, nulliparous. Intravenous antibiotics were administered for 24 hours to cover on-going sepsis prior to surgery on the CEPOD-list.

Results

A novel treatment approach was developed by the anaesthetic and surgical teams. This commenced with intravenous administration of 1 gram of tranexamic acid at an anaesthetic induction followed by modified dillons infiltration of intracervical pitressin 20iu in 200mls of normal saline in combination with injecting into the visible fibroid stalk at the level of the external os. Careful evaluation of the source and insertion of the intracavity fibroid was performed using a Bertocchi 2.9mm hysteroscope. Once achieved and assessed, a transcervical bipolar resection of the fundal insertion of the intracavity fibroid using a 4mm loop electrode was performed until traction of the peduculated fibroid released the lesion. The fundal base of the fibroid was resected completely. A similar approach was used for resection of the lower segment pendiculated fibroid. Finally Rectal misoprostol 1mg was used to stem bleeding.

Conclusions

Both cases were discharged within 24 hours of surgery. Histology confirmed necrotic leiomyomata without atypia, torted in one case. HVS in one case was positive for *Prevotella bivia*.

<https://player.vimeo.com/video/710492433?autoplay=1>

**ES31-0144 -
Free Communication**

Cost-effectiveness of intrauterine sonography-guided radiofrequency ablation (Sonata) compared with hysterectomy and myomectomy in women with uterine leiomyoma and heavy menstrual bleeding: an interim analysis.

Hoi Yau Chan¹, Tessel Cooijmans¹, Marlies Y. Bongers¹

¹Maxima Medical Center, Woman Mother Child Center, Veldhoven, The Netherlands

Background

To perform an economic evaluation comparing the cost-effectiveness of the Sonata system with laparoscopic hysterectomy (HT) and myomectomy (MT) from a societal perspective using a 6-month time horizon based on a multi-centre, prospective cohort.

Methods

Female patients aged 25 years old and above, presenting at outpatient clinic with complaints associated with intrauterine leiomyoma were eligible for recruitment. Treatment allocation was non-randomized and total follow-up of patients was 6 months (i.e., interim analysis). Primary outcome of this study was the Uterine Fibroid Symptom and Quality of Life questionnaire. Resource use was measured using the iMTA Medical Consumption Questionnaire and iMTA Productivity Cost Questionnaire. Missing values were handled using regression imputation based on predictive mean matching. Next, non-parametric bootstrapping was performed, and incremental cost-effectiveness ratios (ICERs) were calculated. Sensitivity analyses were conducted looking at baseline adjustments and assuming a healthcare perspective.

Results

In total, 131 patients were included of which 64 received Sonata (49%), 34 MT (26%), and 33 HT (25%). When comparing Sonata to MT, incremental costs were €-6,348 (€-9,550; €-3,282) and incremental QALYs were 0.010 (-0.027; 0.046) resulting in Sonata dominating MT. When comparing sonata to HT, incremental costs were €-6,921 (€-9,015; €-4,891) and incremental QALYs were -0.058 (95%CI: -0.078; -0.038). Lastly, when comparing HT to MT, incremental costs were €573 (€-2,851; € 3,789) and incremental QALYs 0.068 (0.031; 0.104) resulting in an ICER of €8,461 per QALY gained.

Conclusions

HT results in highest QALY gains but also highest costs. Compared to HT, Sonata has lower QALY gains and lower costs with a high probability of being cost-effective (note: willingness to accept a loss). MT results in similar QALYs compared to Sonata but at higher costs. MT is therefore the least cost-effective option. When willingness to pay thresholds are high (i.e., >€100.000 per QALY) HT is preferred over Sonata.

**ES31-0492 -
Free Communication**

Endometrial biopsy for accurate diagnosis of endometriosis

Taisiia Melnychuk¹, Carlos Lopez Gil², Elena Suarez Salvador³, Josep Castellvi⁴, Eva Colas Ortega², Antonio Gil Moreno³

¹Hospital de la Santa Creu i Sant Pau, Gynecology, Barcelona, Spain

²Vall d'Hebron Institute of Research, Biology, Barcelona, Spain

³Vall d'Hebron University Hospital, Gynecology, Barcelona, Spain

⁴Vall d'Hebron University Hospital, Pathology, Barcelona, Spain

Background

Endometriosis is underdiagnosed and under researched. Diagnostic delay causes negative impact in patients well-being, quality of life, fertility and has high economic and social costs. There is an increasing need in identification of diagnostic techniques to provide earlier diagnosis and decrease associated comorbidity. We analysed the accuracy of endometrial angiogenic biomarkers for detecting endometriosis. The aim of this study was to identify potential endometrial biomarkers for diagnosis of endometriosis, for predicting severity and analysing angiogenic activity in endometriosis recurrence as predicting factor.

Methods

In this case-control study, 33 women suffering from endometriosis with histological confirmation of the disease and 33 healthy controls without any gynaecological disease nor prior endometriosis history. Pipelle uterine biopsies from endometriosis patients were collected in the operating room prior to surgery, whereas, for healthy controls uterine aspirates were collected in the office of the clinician or at hysteroscopy as part of a gynaecological study of abnormal uterine bleeding. TaqMan real-time polymerase chain reaction was used to assess the expression of Endoglin, soluble fms-like tyrosine kinase-1 and placental growth factor.

Results

All assessed biomarkers were significantly lower in overall, ovarian and deep endometriosis. There were no differences between deep and ovarian endometriosis or among different subgroups: adenomyosis, deep-ovarian endometriosis and endometriosis with or without visceral affection. There were no differences between recurrence and no recurrence groups for overall and deep endometriosis. Soluble fms-like tyrosine kinase-1 levels were significantly lower in overall endometriosis with recurrence and in ovarian endometriosis with recurrence compared to no recurrence.

Conclusions

All studied biomarkers have demonstrated high accuracy for diagnosis of endometriosis. The angiogenic activity in pipelle uterine biopsy shows no correlation with the severity of the disease. Recurrence seems to be a more pro-angiogenic activity due to down-regulation of soluble fms-like tyrosine kinase-1 in overall and ovarian endometriosis. These results represent an approach toward the identification of potential diagnostic biomarkers for endometriosis, as well as possible therapeutic target and prognostic biomarkers of treatment monitoring and relapse predicting.

**ES31-0242 -
Free Communication**

Reduction in dysmenorrhea after the minitouch outpatient endometrial ablation procedure

Scott Chudnoff¹, Amy Brenner², Cidny Basinski³, Mark Akin⁴, Stephanie Reich⁵, Christina Sebestyen⁶

¹*Maimonides Health, OBGYN, Brooklyn, USA*

²*Amy Brenner- MD & Associates, Gynecology, Mason, USA*

³*CMB Research, Gynecology, Newburgh, USA*

⁴*AA ObGyn, Gynecology, Austin, USA*

⁵*CTOA Women's Health Texas, Gynecology, Austin, USA*

⁶*OBGYN North, Gynecology, Austin, USA*

Background

To review changes in dysmenorrhea pain scores of the subjects who underwent the Minitouch Procedure for the treatment of heavy menstrual bleeding.

Methods

A prospective, multicentre, single-arm, open label, pivotal clinical trial was conducted to evaluate safety and efficacy of Minitouch Outpatient Endometrial Procedure. The Trial was approved by the United States Food and Drug Administration (US FDA) and was conducted at 5 US physician's offices. Follow-up assessments were made at 24 hours, 2 weeks, 3-, 6-, and 12-months post-procedure.

114 premenopausal women with a history of heavy menstrual bleeding and a Pictorial Blood Loss Assessment (PBLAC) score >150. The demographics were as follows - mean \pm SD (range): age 41.6 ± 4.6 (30-50) years, parity 2.3 ± 1.1 (0-5), sounding depth 8.6 ± 1.1 (7.0-11.0) cm, uterine cavity length 5.2 ± 0.8 (4.0-7.0) cm, and endometrium thickness 9.5 ± 4.2 (3.0-23.4) mm.

Results

The data was collected from 100% (114/114) of the subjects in 100% of the follow-ups; there was 0% to follow-up.

Dysmenorrhea severity was recorded using a patient-reported numerical rating scale (NRS) pain score of 0-10 at screening, and at 3-, 6-, and 12-months post-procedure. The mean (range) dysmenorrhea scores reduced from 6.1 (0-10) at screening to 1.4 (0-8) at 3 months, to 0.9 (0-6) at 6 months and 0.8 (0-6) at 12 months post-procedure. 82% of the subjects at pre-procedure screening, and 4% of the subjects at the 12-month post-procedure, reported moderate to severe dysmenorrhea (score 4 to 10). The percentage reporting no pain (score 0) changed from 4% at screening to 67% at 12 months. 94% of the subjects reported reduction in their individual dysmenorrhea pain score, from an average 6.4 (1-10) at screening to 0.7 (0-6) at 12 months. 3% of the subjects with an individual average score 0.7 (0-2) reported no change.

Conclusions

The Minitouch Outpatient Endometrial Ablation Procedure resulted in significant reduction in dysmenorrhea pain scores of the subjects treated for heavy menstrual bleeding.

**ES31-0439 -
Free Communication**

The Gynaecological appendix

Sayed Elakhras¹, Vasilios Tanos², Hatem Farouk³, Mohamed Salama⁴

¹Omam Hospital, Dept. of Minimally Invasive Gynaecology, Cairo, Egypt

²Medical School of Nicosia University, Department of Obstetrics and Gynaecology, Nicosia, Cyprus

³Omam Hospital, Department of Research and Development, Cairo, Egypt

⁴Ain Shams University, Department of Obstetrics and Gynaecology, Cairo, Egypt

Background

Appendicitis is a relatively common condition encountered especially in younger populations, who are also encountered by the gynaecologists. Not uncommonly, a case may be suspected to be a complicated ovarian cyst, and turns out to be an acutely inflamed appendix, and the opposite is also not uncommon.

As minimally invasive surgeons, we have encountered many cases in which the appendix is a crucial part of the pelvic pathology presenting as a gynaecological problem. We have opted to call this finding "The gynaecological appendix"

Methods

We present a wide spectrum of cases where the appendix is deeply involved in the process of pelvic pathology, presenting to the minimally invasive surgeon dressed as a gynaecological problem.

Appendix may be incorporated in a tubo-ovarian mass, may initiate, or get inflamed secondary to a tubo-ovarian abscess. Appendix may also be affected by endometriosis or get kinked and obstructed by pelvic adhesions secondary to gynaecological pathology.

Finally, a poorly managed episode of appendicitis may end up in pelvic adhesions detrimental to the women's fertility.

Results

A wide array of cases where the appendicular pathology is an integral part of the complex pelvic pathology is presented.

The different etiologies, presentations and pathophysiologies are presented and discussed, along with the management approaches and post-operative responses.

Conclusions

The appendix is not far from the field of the minimally invasive gynaecological surgeon. Awareness of the different presentation, dissection techniques and management options should be familiar to the minimally invasive gynaecological surgeon to optimise management and outcomes in such cases.

**ES31-0506 -
Free Communication**

Short-term results of apical prolapse correction by unilateral pectineal suspension (UPS)

Michael Schreibmayer¹, Cosima Brucker¹, Dimitrios Bolovis¹, Wolfgang Hitz²

¹Nuremberg General Hospital / Paracelsus Medical University, Department of Gynecology and Obstetrics, Nuremberg, Germany

²Paracelsus Medical University- Salzburg- Austria, Department of Research and Innovation, Salzburg, Austria

Background

We have recently established unilateral pectineal suspension (UPS), a novel technique for apical and combined prolapse repair fulfilling a broad range of quality criteria for POP repair. UPS provides mesh-free midline anatomical suspension of the uterus using a single unilateral non-absorbable suture connecting the anterior cervix to the lateral part of the iliopectineal ligament. The purpose of this retrospective study was to analyse perioperative complication rate, short-term efficiency, and overall patient acceptance of the new UPS surgical concept.

Methods

Between November 2019 and January 1, 2022, 53 patients presenting with isolated or combined apical prolapse were scheduled for surgical treatment with UPS. All patients had failed conservative prolapse therapy. No previous POP surgery had been performed, and all patients presented without uterine pathology. Patients were offered the option of mesh-free apex correction combined with additional vaginal repair if needed and gave their informed consent. Outcome data were collected retrospectively from the patient files. All patients were examined during a routine follow-up visit 3-6 months after surgery to determine treatment success as defined by a composite endpoint.

Results

Mean patient age was 63.6 years (range 35-84 years). Mean BMI was 24.6 kg/m² (range 17.8-43.2 kg/m²). The patients stayed in the hospital 4 days on average (range 2-13 days). No drains were used. No conversions were observed. Estimated blood loss as shown by decrease in haemoglobin levels was 0.89 g/dl. Mean operating time for UPS alone was 44.08 min (range 20-74 min). Mean duration of UPS with additional procedures (anterior repair, posterior repair, supracervical hysterectomy, BURCH colposuspension) was 82.97 min (range 37-235 min). The longest operation time observed included extensive adhesiolysis and BURCH colposuspension. On follow-up examination after 3 to 6 months the composite endpoint was reached in 51 of 53 patients (96.2%). Patient satisfaction resembled the results of the composite endpoint.

Conclusions

UPS is a novel, minimal invasive, unilateral, mesh free suspension technique for isolated or combined apical POP correction in five defined steps. The procedure respects the physiological direction and angulation of the vaginal axis. Reliable apical fixation is accomplished in all POP stages, including stage 4 total prolapse. The uterus can be preserved unless uterine pathology warrants hysterectomy. UPS can be combined with additional procedures for the correction of POP and / or SUI during the same or a subsequent procedure. Initial retrospective analysis of the first 53 consecutive patients treated with UPS showed excellent perioperative results. The defined composite endpoint was reached in 96.2 % of patients with very high patient satisfaction.

**ES31-0601 -
Free Communication**

Hormone replacement therapy in women undergoing pelvic clearance for endometriosis: a case report and a national survey

Amer Saad¹, Subul Bazm²

¹University of Nottingham, Obstetrics and Gynaecology, Derby, United Kingdom

²University Hospitals of Derby and Burton NHS Foundation Trust, Obstetrics and Gynaecology, Derby, United Kingdom

Background

The optimal hormone replacement therapy (HRT) in young women who have undergone pelvic clearance for endometriosis remains controversial with insufficient evidence. The purpose of the case report was to highlight the potential risks associated oestrogen only HRT in this group of women. The purpose of the survey was to establish current UK practice and to raise awareness amongst all Gynaecologists and GPs regarding the main issues and risks associated with HRT in this group of women.

Methods

Case report

We present a case of recurrence of severe endometriosis associated with oestrogen-only HRT after hysterectomy and bilateral salpingo-oophorectomy (HystBSO) in a young woman with endometriosis.

National survey

A 21-item survey on the use of HRT after pelvic clearance in women with endometriosis was administered electronically using SurveyMonkey software. This was approved by British Menopause society and British Society of Gynaecological endomdscopy. It was sent to members of both societies as well as NHS Gynaecologists.

Results

Case report

A 45-year-old woman presented to our endometriosis centre with severe chronic pelvic pain while on high dose oestrogen only HRT for five years after HystBSO for endometriosis in a different hospital. MRI of the pelvis revealed multiple endometriomas around the cervical stump with severe left hydroureter and hydronephrosis with complete loss of renal cortex.

National survey

A total of 217 clinicians responded to the survey including Endometriosis specialists (21%), Gynaecological laparoscopic surgeons (24%), Menopause specialists (55%) (Gynaecologists (13%), GPs (33%) Nurses/trainees (9%). Overall, 63% offer combined HRT, 10% oestrogen only, 10% tibolone, and 15% varied HRT depending on endometriosis severity and completeness of excision. A total of 51% would give the progestogen component indefinitely, 22% for 3-6 months and 27% for varied durations. Most responders prescribe either oestrogen patches (37%) or gel (28%) with > 1% prescribing oral preparations. A total of 58% prescribe HRT immediately after surgery, 16% after six weeks, 10% after three months and 16% after varied durations. Most responders offer combined HRT to prevent recurrence of endometriosis (79%), development of new endometriosis (39%) or to prevent malignant transformation of residual endometriosis (42%). Sixty-three percent of responders prescribe combined HRT based on anecdotal evidence and personal experience. Overall, 54% responders indicated the lack of sufficient evidence and 66% lack of clear guidance for the use of HRT in this group of women.

Conclusions

The reported case clearly highlights the real risk of recurrence of potentially severe endometriosis when high dose oestrogen only HRT is used after incomplete excision of endometriosis. The survey highlights the wide variation in practice when using HRT in women with endometriosis. It was surprising to see that only ~70% of responders prescribe either combined HRT or Tibolone. In addition to raising awareness, the survey highlights the lack of evidence and the need for more research.

The association of disease extent using ENZIAN and rASRM classifications with pain symptoms in women with deep infiltrating endometriosis

Tjaša Ujc¹, Monika Sobočan², Leyla Al Mahdaw², Jure Knez²

¹University of Maribor, Faculty of Medicine, Maribor, Slovenia

²University Medical Centre Maribor, Department for Gynaecology, Maribor, Slovenia

Background

The ENZIAN classification of endometriosis was developed to complete the rASRM score and better classify deep pelvic endometriosis (DIE). Since this classification was specifically developed for DIE, it includes most common locations of DIE such as uterosacral ligaments (USL), vagina, RVS, the rectosigmoid and the bladder. Although it is more precise in describing the location of endometriosis, the reports of its accuracy in predicting the clinical symptoms of the disease are controversial. While studies have reported a correlation between ENZIAN classification with pelvic pain, dysmenorrhea and specific locations of endometriosis, others have failed to prove this diagnostic value. The aim of this study was to evaluate how specific endometriosis symptoms are associated with the ENZIAN score and rASRM classification.

Methods

A single-centre retrospective study included 101 women with DIE managed at a university-based tertiary care centre for endometriosis between 2009 and 2020. The demographic data and reported symptoms were collected from our computer system and the ENZIAN and rASRM classifications were applied retrospectively by carefully evaluating structured surgical reports after endometriosis surgery. The data were analysed using descriptive statistics.

Results

Median age at time of diagnosis was 32.0 years (min 21 – max 67). According to the rASRM classification, 20 women had minimal (stage I) disease (26%), 17 (22%) had mild disease, 28 (36%) had moderate disease and 12 (16%) had severe disease. Chronic pelvic pain was not associated with any of the domains of the ENZIAN classification ($p > .059$) or distant retroperitoneal location ($p > .794$), nor was it statistically significantly associated with the rASRM stage ($p > .519$). Dysmenorrhea was not associated with the ENZIAN classification ($p > .129$) or distant disease ($p > .123$) or the rASRM classification ($p > .305$). Only symptoms of dyschezia ($p < 0.001$) and rectal bleeding were significantly associated with the ENZIAN classification ($p < .001$), when there was endometriosis present in compartment »C« (rectum), but not with the rASRM classification ($p > .141$). Dyspareunia was not significantly associated with clinical findings of ENZIAN compartments ($p > .427$), distant disease ($p > .090$) or the rASRM disease classification ($p > .686$).

Conclusions

Our study suggests poor association of ENZIAN classification to clinical symptoms in DIE. Only symptoms of dyschezia and rectal bleeding could predict the presence of endometriosis in the rectum. Further prospective studies are needed to support these findings. If confirmed, further refinements to the classification of endometriosis are warranted.

**ES31-0174 -
Free Communication**

Determining the best method for the ultra-sonographic assessment of severity of adenomyosis: a pilot study

Lisa Trommelen¹, Robert De Leeuw¹, Thierry Van den Bosch², Judith Huirne¹

¹Amsterdam UMC- location VUMC, Gynecology, Amsterdam, The Netherlands

²Universitaire Ziekenhuizen KU Leuven, Gynecology, Leuven, Belgium

Background

To find the best method to express the severity of adenomyosis (AM) using 2- and 3-dimensional transvaginal sonography (2D- and 3D-TVS) in terms of interobserver agreement and correlation with dysmenorrhea (numeric rating scale (NRS)).

Methods

A prospective pilot study in a university clinic in 30 premenopausal women diagnosed with adenomyosis, without hormonal therapy. Diagnosis required at least 1 direct adenomyosis feature: myometrial line/bud, hyperechogenic island or cyst. Estimation of the affected myometrium (mild <25%, moderate 25-50%, severe >50%) was assessed in the recorded videos. Three independent observers evaluated 3D-TVS by 6 different methods for severity of AM: manual contouring of volume of AM using the 18° rotation step (10 different planes) in Virtual Organ Computer-Aided Analysis (VOCAL) and 10 sagittal planes in eXtended Imaging Virtual Organ Computer-Aided Analysis (XI VOCAL), estimating the affected myometrium and affected myometrial layer in multiplanar render (MPR) mode and counting the number of affected slices with set slice thickness in Multi-Slice View (MSV) or counting affected slices out of 10 or 20 transversal uterine slices in XI VOCAL. Intraclass correlation and Fleiss kappa were calculated, and the mean severity of AM outcomes were correlated with NRS.

Results

The first analysis in 5 patients showed that manual contouring was not feasible because of the diffuse character of AM. Counting affected slices in MSV had a poor intraobserver agreement, because the most lateral slices were not recognizable as uterine myometrium. In another 10 patients the 3 other methods were evaluated. The estimated severity category and affected layer using MPR showed poor interobserver agreement ($\kappa=0.49$, $p<.001$; $\kappa=0.24$, $p=0.036$ respectively) and only correlated with NRS in 2 out of 3 observers. Severity, expressed as number of affected slices in XI VOCAL, showed a good interobserver agreement (ICC 0.85; 95% CI 0.64-0.96 and 0.86; 95% CI 0.65-0.96, in 10 and 20 slices respectively). The means of the affected slices correlated significantly with NRS ($r=0.84$ and 0.87 ; $p=0.01$, in 10 and 20 slices respectively).

Conclusions

A semi-quantified method for grading the severity of adenomyosis using XI vocal of the transversal plane by counting the affected slices is feasible with good interobserver agreement and a very strong correlation with dysmenorrhea (NRS). Our results encourage to analyse more cases, to design future studies for optimization of this method and to assess its clinical relevance.

**ES31-0341 -
Free Communication**

An evaluation of the surgical extent of disease in planned joint gynaecological/colorectal cases for women with suspected endometriotic bowel involvement, based on pathology at MRI

Helene Hoyte¹, El Gizawy Zeiad¹, Timothy Bullen²

¹University Hospital North Midlands, Obstetrics and Gynaecology, Stoke-on-Trent, United Kingdom

²University Hospital North Midlands, Division of Surgery, Stoke-on-Trent, United Kingdom

Background

Bowel is the most common extra-gynaecological site of implant for endometriosis, affecting between 3.8-37% of women with the disease (Ferrero et al, 2011). MRI is highly specific and sensitive for diagnosis of deep endometriosis (DE), particularly at the rectosigmoid (Medeiros et al, 2014). However, by using the definition of deep endometriosis as $\geq 5\text{mm}$ below the peritoneal surface, this still excludes some patients with more superficial bowel pathology, for example adhesions/tethering only, who may still require multidisciplinary input at surgery.

This retrospective study aimed to establish:

- The proportion of patients who required either no colorectal input, or input for adhesiolysis, shaving, disc resection or segmental resection over three years at a UK endometriosis centre.
- To correlate pathology found at MRI with operative findings
- To use these results to establish whether any predictive pattern could be established to 'downgrade' patients to a non-joint waiting list, and thereby reduce pressures for the centre

Methods

Retrospective data for 100 cases who were planned for joint input on endometriosis theatre lists, after MDT, between 2018 and 2021 were obtained and analysed to correlate MRI findings, interval between MRI and operative date, operative input, and pathology extent at time of surgery.

Results

97 out of 100 patients had MRIs preoperatively, of which 95 reports were available. The prevalence of bowel involvement on MRI reports was as follows: 4% had nil definite bowel involvement, 33% had bowel tethering/adhesions, 20% had serosal involvement and 35% of patients had partial or full thickness bowel involvement. The mean interval between MRI and operative date was 56 weeks.

75% of all patients required colorectal input during their operations. Of these, 28% of patients had shaving, 9% had disc excision and 20% required segmental bowel resection, while 35% of patients had colorectal input for reasons such as extensive adhesiolysis, assistance with rectal mobilisation, or appendectomy.

Overall, 68% of patients with adhesions/tethering only on pre-operative MRI required colorectal input. Of these, 67% was to assist with adhesiolysis. However, 33% had deeper pathology, with 10% of these patients actually requiring segmental bowel resection for full thickness lesions.

32% of patients with either reported adhesions/tethering only, or reported serosal involvement on MRI, did not require joint input, with less pathology than expected.

Conclusions

MRI is well established for the diagnosis of DE. However, it may be more difficult to predict the extent of adhesions or more superficial forms of bowel endometriotic involvement, and therefore the need for joint input, in this small case series.

Surgical outcomes in the laparoscopic management of urinary tract deep infiltrating endometriosis

Luís Ferreira de Castro¹, Ana Andrade¹, Sofia Mesquita², Daniela Gonçalves¹, Rosa Macedo¹, Helder Ferreira¹

¹Centro Hospitalar Universitário do Porto, Gynecology, Porto, Portugal

²Centro Hospitalar Universitário do Porto, Urology, Porto, Portugal

Background

Our study aims to describe and evaluate the outcomes of laparoscopic surgical management of deep infiltrating urinary tract endometriosis (UTE).

Methods

We performed a retrospective review of patients who underwent laparoscopic operative treatment for UTE from 2014 to 2021 in our department. The inclusion criteria was the presence ureteral and/or bladder endometriosis. Patients' characteristics, pre- and postoperative symptoms, surgical procedures, and intra- and postoperative complications were analysed. Data were collected from the patients' electronic files. Statistical analysis was performed using SPSS 28.0 and a $p < 0.05$ was considered statistically significant.

Results

During the study period, 60 women surgically managed for UTE were included, of whom 33 (55%) for bladder endometriosis, 25 (41.2%) for ureteral endometriosis and 2 (3.3%) for ureteral and bladder endometriosis. At the time of surgery, the mean age and median body mass index were, respectively, 36.9 ± 5.5 years and 22.9 (5.61) kg/m^2 . Thirty-five (58.3%) women had a history of infertility and 40% had undergone previous surgical treatment for endometriosis. In the patients with bladder endometriosis, 22 (62.9%) were treated with partial cystectomy and 13 (37.1%) underwent shaving of the endometriotic nodule. Ureter operations were divided into 15 (55.6%) ureterolysis, 5 (18.5%) ureteroneocystostomy and 7 (25.9%) ureteroureterostomy. Hydronephrosis was present in 16 (59.3%) women with ureteral endometriosis and the left ureter was the most involved by the disease (63.0%). UTE was associated with other deep infiltrating endometriosis lesions in 49 (81.7%) cases, with a predominance of rectovaginal septum nodules.

The mean pre- and postoperative (12 months) dysmenorrhea and deep dyspareunia scores were, respectively, 7.4 ± 3.3 vs. 2.4 ± 2.8 ($p = 0.017$) and 5.7 ± 3.2 vs. 1.4 ± 2.2 ($p = 0.023$). Dysuria was present in 31 (51.2%) patients at the first medical evaluation and in 6 (10%) women in the postoperative period ($p = 0.024$).

We reported 8 (13.3%) intra- or postoperative complications: 1 promptly repaired iatrogenic laceration of the bladder wall, 2 inadvertent injuries of the ureter also repaired intraoperatively, 2 acute pyelonephritis, 1 bladder leakage during cystography 10 days after partial cystectomy and 2 ureteral fistulas after ureteroureterostomy, one of which required reintervention for urinoma drainage. All cases were operated by laparoscopy and 1 surgery was converted to laparotomy for the correction of an operative complication. Only one patient had a recurrence of UTE. This woman underwent partial bladder resection 26 months after a shaving operation of the bladder endometriosis.

Conclusions

UTE is a rare localization of ectopic endometrial implants, affecting 1-2% of women with endometriosis. Postoperative outcomes revealed a significant improvement in painful and urinary symptoms with low rates of severe complications or recurrence. The majority of our patients with UTE had multifocal deep infiltrating endometriosis. A multidisciplinary team is essential for a safe and effective management of this disease.

**ES31-0089 -
Free Communication**

Pre-operative mapping of deep infiltrating endometriosis (D.I.E) on MRI: are we using it efficiently? How do we compare to the national standards in accuracy?

Smitharaghavan Maniganahally Vijayaraghavan¹, Rahul Savant², Bilques Bilquies³, Samen Ray⁴, Aninda Saha⁵
¹14-, OBGYN, Thornaby, United Kingdom

²North tees and Hartlepool University Hospital, Obgyn, Stockton on Tees, United Kingdom

³North Tees and Hartlepool NHS trust, Obgyn, Stockton on tees, United Kingdom

⁴Northtees and Hartlepool NHS trust, Obgyn, Stockton, United Kingdom

⁵North tees and Hartlepool NHS Trust, Radiology, Stockton, United Kingdom

Background

D.I.E found in 1% of women with endometriosis, is defined as the occurrence of sub-peritoneal implants of endometriosis, and is commonly found in rectosigmoid, rectovaginal, Uterosacral, ureteral and bladder areas. It impacts QOL by causing dysmenorrhea, dyspareunia, Dyschezia, Chronic pelvic pain, and infertility.

Intense scarring, fixed retroversion of the uterus and obliteration of cul-de-sac from endometriosis may render laparoscopy inadequate to assess extent of the disease and treatment. (Marcal, Nothaft, Coelho and Choi, 2010). Accurate assessment of the extent of disease is important to plan the surgery to reduce complications. (Del Frate et al., 2006). The importance of counselling the patient to attain informed consent, postop recovery process and the implications there of cannot be overemphasised.

The role of MRI as a tool to diagnose and plan management has widened significantly. It has been found to be highly accurate to diagnose and map endometriosis, although operator dependent. (Lorusso et al., 2021). Positive MRI was identified when there was a thickening or irregular/regular nodules or cystic lesions in one or more of the following areas: (Marcal, Nothaft, Coelho and Choi, 2010)

1. Ovarian endometrioma (OMA)
2. Rectovaginal septum or rectosigmoid
3. Uterosacral ligaments
4. Torus uterinus
5. Obliteration of POD
6. Hyperintense/hypodintense nodules on T1 and T2 weighted images in POD/rectovaginal areas/torus uterinus/uterus/sacral ligaments/ureters

MRI is expensive and should be used judiciously. It is a highly specialised field and should be interpreted by personnel with specialist skills to report in the context of endometriosis.

We conduct a retrospective audit of comparing the findings on MRI with surgical findings as confirmed by pathology.

Objectives:

- Assess the judicious use of MRI in the context of endometriosis
- Analyse the accuracy rates of reporting in our unit and compare it to the best available standards in the literature.

Methods

Random selection of 25 patients who have had an MRI for suspected D.I.E over a period of 2 years.

- Positive MRI findings.
- The operative notes and pictures were reviewed to identify above positive findings of DIE on laparoscopy
- Histology to confirm endometriosis
- Literature search to identify studies on specificity and sensitivity of MRI use in endometriosis and compare it to our own findings.

Results

100% who had MRI had positive findings consistent with D.I.E on surgery

MRI had 96% specificity in identifying OMA and D.I.E -which is on par with national standards.

Sensitivity of MRI in identifying both D.I.E was 60%, while literature quotes ranging from 65% to 90% depending on structure involved – such as Uterosacral ligaments, rectovaginal septum or rectosigmoid and for OMA was 78%. (Literature up to 96%)

80% had positive histology for endometriosis.

Conclusions

The precious tool of MRI is being used judiciously at our Centre for endometriosis. The accuracy rates of reporting in terms of sensitivity and specificity are comparable to standards in literature,

Painful sexual intercourse, quality of life and sexual function in women with endometriosis: is it important to distinguish between deep and superficial dyspareunia?

*Arianna Raspollini*¹, *Simona Del Forno*², *Anna Andreotti*², *Emanuela Spagnolo*³, *Alicia Hernandez*³, *Renato Seracchioli*⁴

¹*Division of Gynecology and Human Reproduction Physiopathology- IRCCS Azienda Ospedaliero-Universitaria di Bologna- Bologna- Italy- Department of Medical and Surgical Sciences DIMEC- University of Bologna- Bologna- Italy, Gynecology and Obstetrics, Bologna, Italy*

²*Division of Gynecology and Human Reproduction Physiopathology- IRCCS Azienda Ospedaliero-Universitaria di Bologna- Bologna- Italy, Gynecology and Obstetrics, Bologna, Italy*

³*Department of Obstetrics and Gynecology- Hospital Universitario La Paz- Madrid, Gynecology and Obstetrics, Madrid, Spain*

⁴*Division of Gynecology and Human Reproduction Physiopathology- IRCCS Azienda Ospedaliero-Universitaria di Bologna- Bologna- Italy. Department of Medical and Surgical Sciences DIMEC- University of Bologna- Bologna- Italy, Gynecology and obstetrics, Bologna, Italy*

Background

evaluate the prevalence of deep and superficial dyspareunia in women with endometriosis in two referral centers for endometriosis (Bologna and Madrid) and to assess the impact of these symptoms on quality of life and sexual function. The secondary objective was to investigate the temporal relation between the onset of deep dyspareunia and superficial dyspareunia in women presenting both symptoms.

Methods

the study included 334 women of fertile age with clinical and sonographic diagnosis of endometriosis. Data about clinical history with particular focus on pain symptoms and dyspareunia (assessed with a Numerical Rating Scale NRS 0-10) were collected. Two scientifically validated questionnaires regarding sexual function (Female Sexual Function Index) and quality of life (International Quality of Life Assessment SF-36) were administered. If the women presented both deep and superficial dyspareunia, the temporal relation between these symptoms was investigated. Gynaecological examination and ultrasound were also performed.

Results

among the 334 study patients, 253 (75.7%) referred dyspareunia, of these: 21 (6.3%) superficial dyspareunia, 87 (26.0%) deep dyspareunia and 145 (43.4%) concomitant deep and superficial dyspareunia; 81 women (24.3%) did not refer dyspareunia. Women were divided into four groups (women presenting exclusively with superficial dyspareunia, women with exclusively deep dyspareunia, women with concomitant superficial and deep dyspareunia and women without dyspareunia). Severe dysmenorrhea (NRS 6-10) was more frequent in patients with dyspareunia (28.6% in superficial dyspareunia, 36.8% in deep dyspareunia, 37.2% in concomitant dyspareunia) than in patients without dyspareunia (14.8%). The median of pain severity was 8 in women with concomitant dyspareunia (range of values 6- 9), 5 in women with superficial dyspareunia (range of values 3-6), 4 in women with deep dyspareunia (range of values 3-6). Women with concomitant dyspareunia reported worse quality of life in all SF-36 items (physical function, body pain, general health, vitality, mental health, social function, and physical role) and worse sexual function than women with isolated dyspareunia or with no dyspareunia. Moreover, all women involved in the study show a reduced sexual desire; a greater deflection of sexual interest can be seen in patients with concomitant dyspareunia. Regarding the temporal correlation between the onset of deep and superficial dyspareunia the majority of women (56.6%) reported that deep dyspareunia developed first, while 41.4% that superficial dyspareunia develops first.

Conclusions

dyspareunia is frequent in women with endometriosis and the majority of women reports concomitant deep and superficial dyspareunia. Women with concomitant dyspareunia have worse quality of life and sexual function than women with isolated superficial or deep dyspareunia. We believe that is important to distinguish between deep and superficial dyspareunia in order to offer women adequate and eventually associated treatments, such as pelvic floor physiotherapy.

**ES31-0413 -
Free Communication**

A rare case of catamenial ascites

Shaun McGowan¹, Andrew Kent²

¹*Belfast City Hospital, Gynaecology, Belfast, United Kingdom*

²*Royal Surrey County Hospital, Gynaecology, Guildford, United Kingdom*

Background

This abstract was presented as a poster only (winning silver for best poster) at the British Society for Gynaecology Endoscopy Annual Scientific Meeting, 2022.

Endometriosis is a common condition affecting around 10% of reproductively aged women. It may be defined as the presence of endometrial-like tissue outside the endometrial cavity. Endometriosis will respond to hormonal stimuli and undergo cyclical bleeding. While pain is a common presenting symptom, we present a rare presentation of endometriosis- the presence of haemorrhagic ascites, this may recur or be exacerbated by menstruation- termed Catamenial Ascites. As part of this case report, we review the limited reported evidence on this presentation of endometriosis that readily mimics malignancy.

Methods

A 33-year-old nulliparous patient of African descent presented with abdominal pain, bloating, weight loss and menorrhagia. While a vague historian, she described cyclical abdominal pain and distension for 2 years with a possible diagnosis of endometriosis at laparoscopy in the past.

Clinical examination noted massive ascites and a pelvic mass.

Initial investigations revealed anaemia with a falling haemoglobin, raised inflammatory markers and a raised CA125 of 462.

A pelvic CT scan showed massive ascites, uterine enlargement? Fibroids and a left adnexal mass inseparable from the uterus but no peritoneal disease/lymph nodes. An initial diagnosis was made of a possible ovarian malignancy and referral to gynaecology- oncology.

A subsequent MRI showed haemorrhagic ascites, and an enlarged multi-fibroid uterus. Suspicious peritoneal nodularity was noted on the bladder and sigmoid colon however ovaries appeared normal. A revised diagnosis of severe endometriosis was made and referral to the endometriosis service.

The patient declined surgery and re-attended with cyclical episodes of the same pain and distension on a number of occasions requiring ascitic drainage. Conservative management with zoladex was commenced with some symptomatic relief. Due to ongoing symptoms and admissions the patient consented for laparoscopy.

Results

Laparoscopy confirmed exceptionally severe endometriosis and a multi-fibroid uterus with the patient awaiting definitive surgery in the form of a pelvic clearance.

Conclusions

Ascites secondary to endometriosis appears most prevalent in nulliparous patients of African descent. The condition often represents a diagnostic dilemma and may be easily mistaken for Ovarian malignancy due to the similar symptomatology and clinical findings². CA125 levels can also be markedly elevated in these cases. Gungor et al. found that malignancy was suspected in over 50% of cases at initial work up

This clinical presentation remains rare, being first described by Brews et al. in 1954 and since then, approximately 60 cases have been described. The exact pathogenesis of the ascites remains unknown.

Imaging and paracentesis may aid diagnosis. Diagnosis is confirmed by surgical assessment by laparoscopy in most cases.

Medical therapy may be used to reduce recurrence and ameliorate symptoms.

Images are available for this presentation.

**ES31-0149 -
Free Communication**

A case of chronic pelvic pain associated with migrated Filshie clips.

Irina Ramzan¹, Rowena Sharma¹

¹Aneurin Bevan University Health Board, Gynaecology, Newport, United Kingdom

Background

Bring awareness to risks associated with Filshie clip migration and consider review of national guidelines.

Methods

Case report, literature review.

Results

37-year-old underwent a diagnostic laparoscopy for chronic pelvic pain. She had a two-year history of non-cyclical right sided lower abdominal pain. Past medical history included sterilisation with Filshie clips nine years ago. Simple analgesics gave minimal improvement of her symptoms. Pelvic ultrasound demonstrated normal anatomy. Intraoperatively, both Filshie clips were found embedded into the peritoneum in the paravesical space bilaterally. Both fallopian tubes were obstructed post previous Filshie application. Pelvic and abdominal organs appeared normal. Peritoneum above Filshie clips was released with laparoscopic scissors and both clips were retrieved through the lateral ports. The patient recovered well after surgery and was followed up six-month post procedure. She reported a complete resolution of her symptoms.

Sterilisation with a Filshie clip is a common procedure in the United Kingdom. It has been introduced by the Mark Filshie in 1980s. It has low failure rate of 2-3:1000 procedures at 10 years and risk of major complications 1.9:1000. 2014 FSRH guideline on male and female sterilisation mentions slippage of Filshie clips as one of the reasons for failure of tubal occlusion. FSRH guideline and RCOG consent advice do not comment on the risks associated with a clip slippage.

There are cases reported in literature of Filshie clip migration resulting in clip expulsion through urethra and anus; pelvic abscess and groin sinus formation and chronic abdominal pain resolution post retrieval of migrated Filshie clip. According to Sokol et. al. 2000 Filshie clip migration is uncommon; Food and Drug Administration of the USA, 1996 reported incidence of Filshie clip migration 0.6 per 1,000 women. However Marcus Filshie in his review of experience with Filshie clips in 2002 reported 25% rate of clip migration.

UK national injury help is investigating potential Filshie clip litigations.

Conclusions

More studies are required to establish the true incidence of Filshie clip migration. The incidence of migration might be underestimated as some patient might be asymptomatic. In a small proportion of cases clip migration could result in development of chronic pelvic pain, which will require further investigations including a diagnostic laparoscopy. We feel that national consent advice should be updated and include Filshie clip migration and risks associated with it.

**ES31-0583 -
Free Communication**

Presurgical assessment and laparoscopic treatment of deep trigonal bladder endometriosis

Harald Krentel¹, Georgios Mavrogiannis¹, Katharina Otto¹

¹Bethesda Hospital, Gynecology- Obstetrics and Gynecological Oncology, Duisburg, Germany

Background

The successful laparoscopic resection of deep endometriosis infiltrating the bladder ground requires a detailed interdisciplinary presurgical assessment considering size, localization, and anatomical relation to vaginal, uterus and ureters.

Methods

Video-Presentation of the presurgical assessment and laparoscopic resection of deep endometriosis involving bladder ground, vagina, uterosacral ligaments, peritoneum, and right M. rectus abdominis in a 26-year-old patient.

Results

Complete laparoscopic resection of deep endometriosis without any complications, #Enzian P1 T+/+ A2 B2/1 FB F (M. rectus abdominis)

Conclusions

Detailed presurgical assessment allows the complete laparoscopic resection of complex deep endometriosis in a single surgery.

<https://player.vimeo.com/video/715778605?autoplay=1>

**ES31-0101 -
Free Communication**

Non-invasive ultrasound staging of endometriosis: can symptoms guide #Enzian compartments assessment?

Consuelo Russo¹, Francesco Giuseppe Martire¹, Aikaterini Selntigia¹, Terry Siciliano¹, Errico Zup², Caterina Exacoustos¹

¹University of Rome "Tor Vergata"- Rome- Italy.,

Department of Surgical Sciences- Obstetrics and Gynecological Clinic, Rome, Italy

²University of Siena- Italy,

Department of Molecular and Developmental Medicine- Obstetrics and Gynecological Clinic, Siena, Italy

Background

Following the established correlation between #Enzian classification and surgery, the aim of the study was to evaluate the potential link between a non-invasive ultrasound assessment and the #Enzian in patients with pelvic endometriosis, who never had previous surgery, and to correlate the involvement of the compartments to symptoms.

Methods

150 women with endometriotic ultrasound signs, with no previous surgery and not taking any hormonal therapy, were staged according to the #Enzian classification. Clinical symptoms were correlated to the different compartments of the #Enzian. Painful symptoms (dysmenorrhea, dyspareunia, dysuria, bowel symptoms) were evaluated using a visual analogue scale (VAS) and heavy menstrual uterine bleeding (HMB) was assessed subjectively. Statistical analysis compared all the compartments, as single or associated, with single symptom or association of them.

Results

Among the cohort, dysmenorrhea was the most prevalent symptoms affected 77% (115/150) of patients. Dyspareunia and HMB occurred in about 40% of women. The most frequent localization of endometriosis in patients with dysmenorrhea were #Enzian compartments: B left (78%), T left (52%) and O left (43%). Regarding the association of single symptom with single compartments we noticed statistical significances, as expected, associating HMB and adenomyosis (FA) ($p=0.02$), dysmenorrhea and B ($p=0.0001$), dyspareunia and A ($p=0.001$) and bowel symptoms and C ($p=0.002$), B ($p=0.007$) and T ($p=0.01$). Evaluating the correlation between single symptom and association of compartments involved, the most statistical significances were detected between dyspareunia and B+FA ($p=0.02$), dyspareunia and T+FA ($p=0.009$), dysmenorrhea and OI+BI ($p=0.02$), intestinal symptoms and O+B ($p=0.0001$) and O+C ($p=0.04$). Associating multiple symptoms with multiple compartments involved we detected statistical significances in correlating dysmenorrhea+dyspareunia with B+T ($p=0.04$), B+FA ($p=0.01$) and T+FA ($p=0.002$); dyspareunia+HMB and T+FA ($p=0.04$).

Conclusions

The #Enzian classification could be used by ultrasound as a non-invasive method to stage pelvic endometriosis. Specific symptoms could guide the diagnosis of the disease in specific compartments. The association of symptoms improve the detection rate of the ultrasound diagnosis and can guide the ultrasound staging to avoid unnecessary surgery and to monitor medical treatment.

**ES31-0350 -
Free Communication**

Complications after laparoscopic surgery for deep infiltrating endometriosis with rectal involvement and anterior rectal resection

Margarida Cal¹, Natacha Sousa², Inês Reis³, João Pedro Lopes³, César Resende⁴, Filipa Osório³

¹Hospital de Santa Maria- Centro Hospitalar Universitário Lisboa Norte, Obstetrics- Gynaecology and Reproductive Medicine, Lisbon, Portugal

²Hospital de Braga, Obstetrics and Gynaecology, Braga, Portugal

³Hospital da Luz Lisboa, Obstetrics and Gynaecology, Lisbon, Portugal

⁴Hospital da Luz Lisboa, General Surgery, Lisbon, Portugal

Background

We aimed to demonstrate a possible complication of rectal endometriosis surgery, the dehiscence of rectal anastomosis, and how it can be safely managed.

Methods

We present a stepwise demonstration of the laparoscopic surgery with narrated video footage.

Results

We report a case of rectal anastomosis dehiscence following a laparoscopic surgery for deep infiltrating endometriosis (DIE) with anterior rectal resection in a 26-year-old woman with no previous surgeries and no other medical conditions. She presented with a bulky endometriotic nodule which infiltrated the recto-sigmoid transition and the right lateral pelvic wall, with involvement of the sacral nerve roots. A laborious nerve-sparing dissection of the nodule was performed; however, due to the grade of rectal involvement and stenosis, an anterior resection of the rectum was performed, followed by mechanical circular stapler anastomosis. The anastomosis was tested during the surgery and there were no signs of leakage. On the post-operatively period, the patient developed complaints of abdominal distension, bloating and nausea; also, the inflammatory parameters peaked on the fifth day post-op. This setting led to a clinical suspicion of anastomosis dehiscence, which was confirmed by a CT scan; therefore, an exploratory laparoscopy was performed.

Interventions: Total laparoscopic approach of deep infiltrating endometriosis with severe rectal involvement, with key steps from two surgeries:

1. Excision of endometriosis nodule with sacral roots and rectal involvement, with anterior rectal resection and endoscopic mechanical anastomosis.
2. Exploratory laparoscopy, performed five days after the initial surgery, with identification of the anastomosis dehiscence and management of this complication with an ileostomy and placement of pelvic drains.

Conclusions

In this video, we demonstrate a possible complication of deep endometriosis surgery with anterior rectal resection – a dehiscence of the anastomosis – and its management by a minimally invasive laparoscopic approach.

<https://player.vimeo.com/video/710469132?autoplay=1>

**ES31-0517 -
Free Communication**

An integrated clinico-radiogenomic screening program for the identification of BRCA 1/2 carriers: a cost-effectiveness analysis (e-PROBE study)

Camilla Nero¹, Di Pilla Andrea¹, Ciccarone Francesca¹, Boldrini Luca¹, Alberghetti Benedetta¹, Specchia Maria Lucia¹

¹Fondazione Policlinico Gemelli, Dipartimento di Ginecologia Oncologica, Roma, Italy

Background

Germline pathogenetic variants of BRCA1-2 are associated with a cumulative risk for developing breast or ovarian cancer of 61-79% and 11-53%, respectively. Given the presence of effective cancer risk-reducing surgeries (RRS) for BRCA carriers, genetic testing should detect as many carriers as possible. Current indications to access BRCA testing are based on clinical/familial criteria but this approach seems to leave the majority of carriers unidentified. Data regarding the cost-effectiveness of a population-based screening are controversial. We developed an automated machine learning pipeline model with encouraging performances to identify BRCA status based on US images of healthy ovaries and evaluated the impact of its introduction as a screening tool in Italian population.

Methods

A cost-effective analysis comparing different models for the identification of BRCA1-2 carriers in the general population in Italy was conducted (current model named AS-IS; integrated clinic-radiogenomic model with published performances named TO-BE1.0 and integrated clinic-radiogenomic model with improved performances named TO-BE2.0). The direct costs for the healthcare system were considered using the rates currently in force in Italy.

Results

The identification rate of BRCA1-2PV carriers in the first generation before the onset of cancer is 14.6% in the AS-IS model, 56.4% in the TO-BE1.0 model and 82.9% in the TO-BE2.0. Given the rates of acceptance of RRS, the rate of BRCA-related cancers in the first generation drops by 23.7% and 38.7% in TO-BE1.0 and 2.0 respectively, compared to the AS-IS model. The rate of people aware of the mutation before cancer onset goes from 14.6% in AS-IS to 56.5% in TO-BE1.0 to 82.9% in TO-BE2.0 in the first generation. For the second generation, the identification rate of BRCA-carriers before the cancer onset is 96.7% in TO-BE1.0 model and 99.8% in TO-BE2.0. Finally, a reduction of 46.6% (TO-BE1.0) and 48.3% (TO-BE2.0) BRCA-related cancers is observed compared to AS-IS model. Considering a timeframe of 62 years (from 18 to 80 years) and a population perspective, the AS-IS model entails a cost for each individual of about 73.80 euros/Year/Person while the TO-BE1.0 and 2.0 ones of about 76.31 and 74.50 euros/Year/Person respectively. In the first cycle, the estimated incremental cost to increase BRCA1/2PV-HLYs by one year in the general population amounts to about 3,800 and 653 euros in the TO-BE1.0 and 2.0 respectively. Incremental costs per cycle drop to 1,480 and 341 euros for TO-BE1.0 and TO-BE2.0 models for each BRCA-HLYs-gained in general population, respectively.

Conclusions

The introduction of an effective radiogenomic screening tool (TO-BE2.0), has a massive effect after only one generation in detecting the estimated BRCA-carriers in the general population with low increasing of costs. The clinical impact is limited mainly due to the low acceptance rate of risk-reducing surgeries. It is highly likely that the increasing costs evaluated in the first two generations could drop significantly down if indirect cost are taken into consideration.

**ES31-0143 -
Free Communication**

T-shaped dysmorphic uterus: discrepancies between current 3D-ultrasound criteria and identification of the best 3D measurements

Giulia Monaco¹, Elvira Nocita¹, Sabrina Reppuccia², Aikaterini Selintigia¹, Brunella Zizolfi³, Caterina Exacoustos¹
¹University of Rome 'Tor Vergata', Department of Surgical Sciences Obstetrics and Gynecological Clinic, Rome, Italy

²University of Naples Federico II- Naples, Department of Neuroscience- Reproductive Sciences and Dentistry, Naples, Italy

³University of Naples Federico II, Department of Public Health, Naples, Italy

Background

the dysmorphic T-shaped uterus represents an ill-defined entity. Some criteria and classifications have been proposed to diagnose T-Shaped uterus based on ultrasound and hysteroscopy. The aim of the study is to review and compare current classifications for the diagnosis of T-Shaped Uterus by 3D ultrasound and to identify parameters to improve the accuracy of the diagnosis.

Methods

46 stored 3D transvaginal uterine volumes of women with a subjective diagnosis of T shaped uterus were evaluated offline. All the included uteri were considered T-Shaped by four ultrasonographers and had hysteroscopic diagnosis based on the presence of an increased distance between the tubal ostia, a narrow uterine cavity, or an abnormally elongated cervical canal. All the doubtful T-Shaped uteri or with fundal indentation (Y-shaped) were excluded. Uterine morphology assessment was performed on a coronal plane by measuring: fundal cavity width (Wf); corpus-isthmic level cavity width (Wi); uterine cavity length (L); lateral indentation angle (AI); lateral bulging (LB); T- angle (AT); length of the intracavitary line parallel to the interostial line at 10 mm from it (R10); length of the intracavitary line parallel to the interostial line at 20 mm from it (R20).

Results

among the cohort, the mean Wf was 34,98 (\pm 8,21) mm and the mean Wi was 6,50 (\pm 1,20) mm. Mean Wf/Wi ratio was 5,46 (\pm 1,09). In our population, all three CUME (Ludwin et al. 2020) criteria together (LB \geq 7 mm, AI \leq 130°, AT \leq 40°) have been identified only in 6 (13.0%) T-shaped uteri. 22 (47.8%) uteri respected two CUME criteria, in particular in 16 (34.8%) uteri there were LB \geq 7 mm and AI \leq 130°. Considering "the rule of 10" (Alonso Pacheco et al. 2021), R10 \leq 10 mm was found in 28 (60.9%) uteri. Combining the two classifications, only 8 (17.3%) uteri examined showed an association between R10 \leq 10 mm and two CUME criteria (LB \geq 7 mm, AI \leq 130°). Considering instead LB \geq 5 mm, 44 (95.6%) uteri examined presented this measurement. Increasing the measure of AI and using AI \leq 140° instead of AI \leq 130°, 40 (86.9%) uteri fulfilled this criterion. Combining these two new measurements, in 40 (86.9%) uteri there were LB \geq 5 mm and AI \leq 140°.

Conclusions

high discrepancies have been showed between current proposed classifications for the diagnosis of T-shaped uterus. Subjective evaluation by expert ultrasonographers is often more reliable and the presence of LB \geq 5 mm and AI \leq 140° could represent improved diagnostic criteria for the sonographic diagnosis of the T-shaped uterus.

**ES31-0039 -
Free Communication**

Urinary tract endometriosis: how to predict and prevent recurrence after primary surgical excision.

Tommaso Capezzuoli¹, Fabrizio Di Maida², Luca Lambertini², Massimiliano Fambrini¹, Andrea Minervini², Felice Petraglia¹

¹University of Florence- Florence- Italy,

Department of Experimental and Clinical Biomedical Sciences "Mario Serio"- University of Florence- Florence- Italy, Florence, Italy

²University of Florence- Florence- Italy, Department Experimental and Clinical Medicine- University of Florence- Unit of Oncologic Minimally-Invasive Urology and Andrology- Careggi Hospital- Florence- Italy, Florence, Italy

Background

Deep infiltrating endometriosis (DIE) is a chronic inflammatory disease with a high recurrence rate and repetitive surgery is very common. In particular, urinary tract endometriosis (UTE), occurs in 6-10% of cases, with bladder and ureteral involvement occurring in 70–85% and 9–23% of cases, respectively. Our aim was to explore clinical and surgical predictors of DIE relapse, relying on a large single institutional cohort of patients primarily treated with surgical excision for UTE.

Methods

This single centre, retrospective study analysed data from consecutive patients (n=105) affected by UTE and surgically treated. Surgical and clinical data were carefully gathered, specifically focusing also on age at the first surgery, postoperative hormonal treatment, as well as concomitant autoimmune diseases at the time of first surgery. All patients received a preoperative multidisciplinary evaluation with the gynaecologist, the urologist and the general surgeon. Uni- and multivariate logistic regression analysis to evaluate predictors of recurrence were fitted.

Results

Ureteral primary involvement was recorded in 46 (43.8%) cases, while bladder involvement occurred in 52 (49.5%) patients. Bilateral UTE was recorded in 7 (6.7%) patients. Overall, 53 (50.5%) patients received adjuvant hormonal therapy. At a median follow up of 71 (IQR 34-101) months, 30 (28.6%) patients experienced disease relapse, with 14 (13.3%) recurrences recorded at the level of the urinary tract. At multivariable analysis, age at first surgery <25 years (OR: 1.23; CI 95% 1.10–1.84; p=0.02) and concomitant autoimmune disease (OR: 1.45; CI 95% 1.24–2.17; p=0.02) were found as predictors of DIE recurrence, while adjuvant postsurgical therapy showed a protective role (OR: 0.83; CI 95% 0.53–0.98; p=0.01).

Conclusions

These results indicate that young age at first surgery and concomitant presence of autoimmune disease may be two factors independently influencing the development of DIE recurrence. On the contrary, postsurgical hormonal treatment showed a protective role, thus suggesting an important role of the medical therapy for a certain period of time in preventing repetitive surgery for recurrence.

**ES31-0166 -
Free Communication**

Clinical definition of a disorder caused by a symptomatic caesarean scar: a modified Delphi procedure

Saskia Klein Meuleman¹, Robert de Leeuw¹, Thierry van den Bosch², Ertan Saridogan³, Judith Huirne¹

¹*AmsterdamUMC - location VUmc, Gynaecology, Amsterdam, The Netherlands*

²*University Hospital K.U. Leuven, Obstetrics and Gynecology, Leuven, Belgium*

³*University College Hospital, Obstetrics and Gynaecology, London, United Kingdom*

Background

Uterine niches are frequently observed using transvaginal ultrasound after a Caesarean section (CS). A niche is associated with gynaecological symptoms but may also cause infertility and obstetric problems. However, more than 50% of all women with a niche are asymptomatic (1). A definition of the clinical condition of a disorder caused by a symptomatic uterine niche should help to identify women who may need therapy, assist future research projects and aid comparison of different studies. The aim of this study is to define the condition that should be considered as a CS scar disorder, using a modified Delphi procedure.

Methods

During a systematic literature search and focus group among five niche experts and women with a symptomatic niche, relevant items for the first questionnaire of the Delphi were discussed. Afterwards a modified Delphi procedure was carried out, in which 57 international experts in obstetrics and gynaecology were invited to participate. The experts were selected through their membership of European Niche Taskforce, Caesarean Scar Pregnancy Registry Team or International Society for Placenta Accreta Spectrum and a minimum of 30 niche evaluations a year, involvement in clinical research projects on niches or two articles published about caesarean scar related problems. Consensus was predefined as level of agreement of at least 70% for each item and a minimum of three Delphi rounds were planned.

Results

In total 31 international niche experts completed three questionnaires. Consensus was achieved on all features and symptoms associated with a symptomatic niche. It was agreed to call the condition a Caesarean Scar Disorder, defined as a uterine niche on imaging according to the definition of Jordans et al. UOG 2019 (2) in combination with at least one primary symptom or two secondary symptoms. Primary symptoms are spotting, pain during blood loss, technical problems with catheter during embryo transfer and secondary unexplained subfertility combined with intra-uterine fluid. Secondary symptoms are dyspareunia, secondary unexplained subfertility, secondary subfertility despite ART, abnormal vaginal discharge, discomfort during participation in leisure activities, chronic pelvic pain, avoiding sexual intercourse, odour associated with abnormal uterine blood loss and negative self-image.

Conclusions

A Caesarean scar disorder was defined during a modified Delphi procedure among 31 international experts as a uterine niche in combination with at least one primary or two secondary symptoms. This definition will be a solid base for future research, systematic reviews and the design of future guideline.

**ES31-0123 -
Free Communication**

The unmet need for psychological support for endometriosis related chronic pelvic pain: a review of current UK clinical practice

Sarah Wali¹, Tom Bainton¹, Glyn Towler², Robert Richardson¹, Amer Raza¹

¹*Chelsea and Westminster Hospital, Obstetrics and Gynaecology, London, United Kingdom*

²*Chelsea and Westminster Hospital, Anaesthetics, London, United Kingdom*

Background

Endometriosis is a debilitating condition, frequently associated with chronic pelvic pain (CPP) that should be approached using a bio-psycho-social model of care. The 2020 UK All Party Parliamentary Group (APPG) on endometriosis inquiry found that 81% women said pain has impacted their mental health negatively and 90% would have liked access to psychological support, which they were not offered.

Methods

We used an online questionnaire to evaluate the current clinical practice regarding provision of psychological therapies for endometriosis CPP, and gain expert opinion on how to improve the current pain management service at UK British Society of Gynaecological Endoscopy (BSGE) accredited endometriosis centres.

Results

26/86 (30%) named pain management specialists responded from 24/67 (36%) of BSGE endometriosis centres.

- 96% were anaesthetists 4% (1) were gynaecologists.
- 46% were aware of the APPG inquiry, 54% were not.
- 23% did not attend the multidisciplinary team (MDT) meeting (not aware or not invited). 77% attended always or when needed.
- 46% saw patients after multiple failed medical/surgical management, 27% after initiation of medical management or surgery, 19% after initial appointment in endometriosis clinic, 4% after discharge from endometriosis clinic, 4% from primary care prior to endometriosis clinic.
- 38% said patients did not have any psychological assessment prior to pain clinic referral.
- 77% offer psychological therapy (mostly in-house) as part of a pain management clinic. 23% did not, partly due to funding issues.

Conclusions

There is an unmet need for psychological therapies for endometriosis associated CPP. This is partly due to resource limitations, but not exclusively. Awareness and education of the psychological impact of disease as highlighted by the APPG findings, the identification of women who would benefit from bio-psycho-social therapies early in the patient journey and having true MDT management including pain specialists would have a positive impact on patient care.

**ES31-0250 -
Free Communication**

Fibroid delivered in vagina V-NOTES hysterectomy

Marta Hinarejos Company¹, Ana Paula Vélez Vintimilla¹, Estela Márquez Muñoz¹, Antoni Pessarrodona Isern¹, Jordi Cassadó Garriga¹, Jordi Rodríguez González¹

¹Hospital Universitari Mútua de Terrassa, Gynaecology and Obstetrics, Terrassa, Spain

Background

V – Notes (Vaginal Natural Orifice Endoscopic Surgery) hysterectomy technique can be a very useful approach to treat some difficult cases.

Methods

In this case we perform a V – Notes hysterectomy in a woman with a twelve-centimeter delivered fibroid, previous morcellations of the fibroid.

Results

A forty-seven-year-old patient was admitted to the hospital for menorrhagia. Ultrasonography showed a 17 X 12 X 12 cm uterus with a 12 X 11 X 9.8 cm transmural myoma. Haemoglobin was 5 grams/litter. Two red cell concentrates were transferred. Treatment with GnRh analogues was started. Hysterectomy was scheduled for three months later.

Two months later the patient complained of abdominal pain and slight menorrhagia.

On gynaecologic examination the myoma was found to have entered the vagina. On abdominal ultrasound the myoma was found to be in the vagina with a dilated cervix. Doppler showed intense vascularization.

Initially a torsion myomectomy was attempted but was unsuccessful due to the large size of the fibroid pedicle. We proceeded to the morcellation of the myoma until we visualized the anterior lip of the cervix, and then we could complete the myomectomy. The cervix was sutured to prevent blood drainage from the uterus during hysterectomy.

Then, we performed a V-Notes Hysterectomy in the standard way. Due to the large volume of the cervix, we used a sealing forceps to divide uterosacral ligaments and paracervix. The V-Notes hysterectomy was completed without any complications.

Conclusions

In conclusion, V – Notes hysterectomy allows to perform a vaginal route in those cases in which vaginal hysterectomy would have been more difficult.

<https://player.vimeo.com/video/710488126?autoplay=1>

**ES31-0474 -
Free Communication**

Normal uterine contractile activity in healthy women throughout the menstrual cycle: an exploration of reference values

Connie Rees¹, Anna de Boer¹, Brunella Zizolfi², Nikos Christoforidis³, Huib van Vliet¹, Dick Schoot¹

¹*Catharina Hospital, Gynaecology and Obstetrics, Eindhoven, The Netherlands*

²*University of Naples Federico II, School of Medicine, Naples, Italy*

³*Embryolab, Fertility Center, Thessaloniki, Greece*

Background

Uterine peristalsis is the rhythmic, wave-like motion of the subendometrial layer of the uterus. Various subjective methods using visual interpretation suggest that uterine peristalsis features are different in the various stages of the menstrual cycle, and they are thought to be important for fertility. However, no method has been developed which can assess all uterine contraction features simultaneously. Recently, a new automated quantitative method to measure uterine contractility was validated in IVF patients to analyse uterine peristalsis on transvaginal ultrasound recordings with speckle-tracking. With this method a new contraction feature – coordination – can be assessed alongside frequency, direction, amplitude.

Methods

Multi-centre observational prospective cohort study carried out in the outpatient gynaecology department of the Catharina Hospital in Eindhoven, the Netherlands, the University of Naples, Federico II, Naples, Italy and Embryolab Fertility centre in Thessaloniki, Greece. Patients were included from September 2014 up to January 2022. Primary outcomes were the contraction frequency (contractions/minute), amplitude, direction (Cervix-to-fundus, Fundus-to-cervix), and coordination.

70 women were included, criteria included: ≥ 18 years of age, premenopausal, a normal natural menstrual cycle. A normal cycle was defined as: regular (duration ± 28 days), no dysmenorrhea, no menometrorrhagia. Transvaginal ultrasounds were performed during the menstrual phase (M), late follicular (periovulatory) phase (LF), early luteal phase (EL, ovulation + 3 days) and/or late luteal phase (LL, ovulation + 7 days).

Results

Uterine contractility features were extracted from the gathered ultrasound recordings using a quantitative dedicated speckle tracking algorithm previously developed by our group. Each patient underwent a four-minute ultrasound of the uterus in mid-sagittal section. Patients had a mean age of 32 years, cycle duration of 27.8 days, and BMI of 23.0. The majority of uterine contraction features differed significantly between menstrual cycle phases. Contraction frequency was highest in the LF phase and lowest in the M and LL phases (1.55 vs. 1.28/min, $p=0.001$). A trend was found for contractions during the periovulatory and early luteal phases to travel mainly from cervix-to-fundus direction, whilst the menstrual phase showed contractions mainly from the fundus to cervix ($p>0.05$). No significant difference between phases was found for contraction amplitude. Contraction coordination (simultaneous contraction of the anterior and posterior walls in the same direction) was highest in the periovulatory phase ($p=0.002$). Our results are in line with previous published studies using subjective visual inspection.

Conclusions

We explored further implementation of a quantitative method of uterine peristalsis measurement. Our investigation of a novel contraction characteristic - coordination - opens up possibilities for research and a potential aetiological/treatment target. Further research using this method and suggested reference values will provide insight into contraction characteristics in abnormal uteri.

**ES31-0488 -
Free Communication**

The dark side of teratoma: ultrasound features of three different germ cells histotypes of ovarian masses referred as teratomas

Mariateresa Mirandola¹, Federica Pozzati¹, Silvia Zermano¹, Antonia Carla Testa¹, Anna Fagotti¹, Giovanni Scambia¹

¹IRCCS Fondazione Policlinico Universitario A. Gemelli- Università Cattolica del Sacro Cuore, Department of Woman and Child Health and Public Health, Rome, Italy

Background

Ovarian teratomas are the most common ovarian germ cell tumours, the majority are represented by mature cystic teratoma. Less common histotype are specialized monodermal teratoma, of which struma ovarii is the most frequent, and malignant lesions including mature teratomas with malignant transformation and immature teratomas. Ultrasound features of mature teratomas are well known but less common histotypes can present with a wide spectrum of imaging findings and this can lead to misdiagnosis. The objective of this video abstract is to describe the ultrasound features of three different germ cells histotypes referred to our center as suspicious for teratomas.

Methods

We describe three cases referred to our center for an adnexal mass diagnosed as suspicious of dermoid on ultrasound and surgically removed.

Results

Case 1: A 61-year-old woman, referred to our department for abdominal pain. Transvaginal ultrasound showed a left unilocular lesion, with mixed content, irregular margins, with no vascularization at colour Doppler. Final histology was positive for squamous carcinoma G2 on epidermoid cyst.

Case 2: A 37-year-old woman complained pelvic pain. Transvaginal ultrasound showed a right solid mass, with irregular margins, multiple internal cystic and solid areas, acoustic shadows and moderate vascularization at colour Doppler. Final histology was positive for low grade immature teratoma.

Case 3: A 31-year-old woman, pregnant at 14 weeks' gestation, with a rapidly growing pelvic mass was referred to our department. Transvaginal ultrasound examination showed a multilocular-solid cyst, with irregular margins, central solid component, and papillary projections, highly vascularized at colour Doppler. Final histology report was positive for struma ovarii.

Conclusions

The possibility of immature teratoma, monodermal teratoma and mature cystic teratoma with malignant degeneration needs to be taken in consideration when a dermoid cyst is suspected at ultrasound. The description of the ultrasound features of different germ cells histotypes can improve the differential diagnosis of rare ovarian tumours.

<https://player.vimeo.com/video/715581560?autoplay=1>

**ES31-0095 -
Free Communication**

Turning the difficult into easy: how does the application of an appropriate methodology enable the learning of laparoscopic suturing?

Eva Magret¹, Rocio Luna-Guibourg¹, Alba Farres¹, Natalia Teixeira¹, Cristina Soler-Moreno¹, Ramon Rovira¹
¹Hospital Sant Pau, Obstetrics and Gynecology, Barcelona, Spain

Background

To demonstrate that through the application of an appropriate learning methodology, it is possible to acquire the necessary skills to correctly complete a laparoscopic suture.

Methods

Prospective observational study involving 80 gynaecologists who participated in a one-day course in which the technique of suturing in laparoscopic surgery was demonstrated and practiced on a pelvic trainer. An evaluation was carried out at the beginning and end of the course, both theoretical and practical.

The time taken by the trainees to complete the suture was measured and the practical assessment was performed using the OSATS methodology which includes 3 types of assessments:

- A 15-item check-list of all the steps considered necessary to perform a laparoscopic suture with intracorporeal knot tying.
- A global assessment named GOALS that takes into consideration aspects such as respect for the tissue, time and movement, handling of instruments, use of the assistant, evolution of the intervention and knowledge of the specific procedure.
- An overall evaluation that assessed whether the student had passed or failed.

Four courses were held on consecutive days. Each course was attended by 20 students. Every 2 students had a pelvic-trainer to carry out the practice and a tutor was in charge of supervising the students every 2 pelvic-trainers.

Special emphasis was placed in two fundamental aspects:

- On the application of a learning methodology based on the division of a complex process into simpler steps. Thus, laparoscopic suturing was divided into 3 steps: needle orientation, passage of the needle through the tissue, and intra- and extracorporeal knotting. Each step was demonstrated independently through tutor-led and supervised training.
- On the role of feedback and the possibility of repeated practice, essential for the acquisition of the motor skills.

Results

Of the total of 80 students who participated in the course, 58 completed the pre- and post-course evaluation. The results were evaluated using the student's t-test for paired data. The mean improvement in the evaluation using:

- Checklist was 5.85 with a CI of 4.67 - 7.02 ($p < 0.001$).
- The GOALS assessment was 6.67 with a CI of 4.70 - 8.78 ($p < 0.001$).

Before the course, 12 students were considered to pass (20.69%) and after the course 52 passed (89.66%).

Conclusions

This study demonstrates that it is possible to acquire the necessary skills for laparoscopic suturing in a short time, considering indispensable aspects of motor skills learning, such as the feedback received by the trainee and the repetition of exercises.

**ES31-0560 -
Free Communication**

Endometriosis: training fit for the future

Harriet Nina Lamb¹, Gaiy Ahmad¹, Carl Parfit², Sarah Alvi³, Ros Ghaidan⁴

¹Northern Care Alliance, Obstetrics and Gynaecology, Greater Manchester, United Kingdom

²Royal Oldham Hospital, Obstetrics and Gynaecology, Greater Manchester, United Kingdom

³Manchester University, Medical Student, Manchester, United Kingdom

⁴Manchester University, Student, Manchester, United Kingdom

Background

Endometriosis is a chronic, debilitating condition that detrimentally affects quality of life and is associated with a huge health burden (estimated to cost the UK economy >£8.2 billion/year). A significant contributing factor to this is the universal average delay from onset of symptoms to diagnosis, which in the UK is 7.5 years.

In addition, qualitative research into experience of health care encounters has demonstrated that women experience clinicians in primary care to have insufficient knowledge of the condition and do not take their symptoms seriously. This can lead to a barrier for patients seeking healthcare.

Despite this, endometriosis is often overlooked in medical school curriculums. This needs to be urgently addressed, and good quality education must be provided to future doctors from the earliest stage. Not only should this include pathophysiology, diagnosis and treatment; but how to effectively communicate with women suffering from this condition.

Methods

Surveys were undertaken and information was gathered from 3rd and 4th year medical students. This was regarding how confident they felt speaking to patients about endometriosis, and what they felt was important regarding knowledge of endometriosis. Their views on how teaching should be delivered were also ascertained.

Results

Results demonstrated that almost all students felt a lack of confidence when speaking to patients about endometriosis.

The following themes emerged with regards to what the students wanted to learn:

1. How to take a history in a case of suspected endometriosis
2. How to discuss suspected diagnosis and investigations with a patient
3. How to discuss treatment options for patients with suspected endometriosis
4. How to explain deep infiltrative endometriosis to a patient
5. How fertility is affected by endometriosis.

The students expressed a wish for educational videos rather than face to face sessions, so that they could be accessed at any time and be revised as required. After the COVID-19 pandemic, education using digital platforms is much more commonly utilised and has been found to be effective.

Conclusions

With the information collected from medical students, we developed and produced a series of short educational films on the above topics. These take the form of simulated consultations and have been viewed and approved by expert patients. They can be used as part of classroom teaching or viewed by students for revision purposes. They can also be used for patient education, and to empower women as to what to expect from their healthcare encounters.

We would like to share examples of these short films as a template for this modern way of teaching medical students on this extremely important subject.

**ES31-0625 -
Free Communication**

Combined medical and hysteroscopic management of cesarean scar pregnancy

Noam Smorgick¹, Yair Shiber¹, Neta Eisenberg¹, Maya Naor¹, Zvi Vaknin¹

¹Shamir Medical Center- Tel Aviv University, Obstetrics and Gynecology, Rishon Lezion, Israel

Background

Caesarean scar pregnancy (CSP) is a rare type of ectopic pregnancy which may be managed by various medical and surgical options. We present a case series of patients managed by combined medical and hysteroscopic surgical approach.

Methods

Retrospective review of CSP-cases managed by combined methotrexate and hysteroscopy from January 2020 to August 2022. The interventions included administration of methotrexate (local and systemic intramuscular), with or without uterine artery embolization, followed by hysteroscopic removal of the residual pregnancy mass by use of bipolar resectoscope.

Results

The residual CSP mass was successfully removed in 7 out of 8 cases by hysteroscopy, while one patient required a robotic assisted resection and repair of the caesarean scar due to persistent CSP. Pre-operative uterine artery embolization was performed in 2 cases for the prevention of excessive bleeding. No intra- or post-operative complications occurred. The post-operative sono-hystero-graphy showed a residual myometrial thickness >4 mm in all cases.

Conclusions

Combined medical and hysteroscopic removal of viable CSP is safe and allows for fertility preservation.

**ES31-0163 -
Free Communication**

Bilateral endometrioma associated with posterior compartment endometriosis: a robotic resolution

Fernanda Dishchekenian¹, Akemi Nakamura², Juliana Romano², Priscilla Pessoa², Mariano Tamura¹, Gustavo Barison²

¹Hospital Moriah- Hospital Israelita Albert Einstein, Gynecology, Sao Paulo, Brazil

²Hospital Israelita Albert Einstein, Gynecology, Sao Paulo, Brazil

Background

To present the applicability of a robot-assisted laparoscopy in an extensive endometriosis of posterior compartment.

Methods

27-year-old patient that complained of pelvic pain associated with an abnormal vaginal bleeding. MRI showed uterine volume of 44 cc, ovarian cysts suggestive of endometrioma measuring 5 cm on the left and 1.3 cm on the right, associated with thickening of paracervical and retrocervical spaces with extension to the uterosacral ligaments.

Patient was eligible for robot- assisted laparoscopy for treatment of deep endometriosis. Patient was placed in semi gynaecological position, under general anaesthesia, with arms alongside the body and legs 80 grades abducted in adjustable leggings. Three robotic portals were positioned: one in the umbilical scar for the optics and two on the right and left iliac fossae. In addition, a conventional laparoscopic portal was positioned in the right flank.

It was performed a complete excision of posterior compartment endometriosis lesions, with proper bilateral ureterolysis and retroperitoneal development, including excision of a lesion in intimate contact with right hypogastric nerve and a left periureteral one. In addition, bilateral oophoroplasty under stripping technique for endometrioma excision was performed.

Results

Surgical duration was three hours, with minimal blood loss and no complications. Patient had satisfactory clinical evolution, discharged on the second postoperative day. Pathology report confirmed endometriosis nodules and endometrioma.

Conclusions

This report demonstrates the importance of the robotic approach on deep endometriosis surgery, especially in extensive inflammatory peritoneal disease. In such predictable complex cases, the applicability of the robotic platform with its precise and delicate movements and angulations allows safer and more ergonomic access to the pelvic posterior compartment, increasing safety in the dissection of retroperitoneal spaces and course of the surgery.

<https://player.vimeo.com/video/710227787?autoplay=1>

**ES31-0378 -
Free Communication**

Diagnosis and treatment of pelvic prolapse and anovesical incontinence through robotic hysteropexy
Izabella Dalbuquerque¹, Luisa Martins¹, Mira Zlotnik¹, Vanessa Alvarenga¹, Raphael Haddad¹, Renato Moretti¹
¹Hospital Israelita Albert Einstein, Gynecology, São Paulo, Brazil

Background

A 37-year-old patient with 2 vaginal deliveries with a 2-year complained of a wide vagina, low bladder sensation and urinary leakage on small efforts. On physical examination, an apical defect, stage 1 uterine prolapse, enterocele. On magnetic resonance imaging, multicompartamental perineal descent was observed associated with moderate anterior rectocele, with retention of residues and invagination of the intrarectal mucosa. Lastly, the urodynamic study showed SUI with PPV of 280mmhg. In this scenario, the purpose of this video was to demonstrate the steps of robot-assisted hysteropexy for treatment of Pelvic prolapse associated with anovesical and stress urinary incontinence.

Methods

Robot-assisted hysteropexy was performed. During surgery, a polypropylene mesh was used to repair the vaginal defect and to reconstruct the pericervical ring. The mesh was fixated to the cervical stroma using a 2.0 non-absorbable suture and fixed in the puborectal muscles and perineal body. The same type of suture was performed to fix the mesh from the posterior vaginal wall to the pericervical ring. A Mac Call culdoplasty reinforced the posterior correction. Finally, Tension-free fixation of the mesh to the anterior longitudinal ligament of the sacrum with prolene 2.0. The patient was discharged on the 1st postoperative day.

Results

We obtained efficient diagnosis and treatment. The patient did well in the postoperative period, with complete resolution of the condition.

Conclusions

Advanced uterovaginal prolapse can significantly affect women's quality of life and often requires surgical treatment. We report the case of a successful laparoscopic robotic-assisted pelvic organ prolapse correction treatment.

<https://player.vimeo.com/video/710575233?autoplay=1>

**ES31-0427 -
Free Communication**

Continued evidence of a novel hysteroscopic approach to reversible long-acting contraception and as alternative to sterilization

Thomas Hasskamp¹, Steven Weyers²

¹*Gynmuenster, outpatient clinic, Coesfeld, Germany*

²*UZ Gent- Belgium, Vrouwenkliniek, Gent, Belgium*

Background

To demonstrate continued experience and tolerability of a hysteroscopic insertion technique of a frameless, anchored intrauterine contraceptive device (ReLARC®) with a duration of action of 3 or 10 years.

Methods

Patients requesting contraception, or who encountered IUD (intra uterine device) problems, were evaluated by hysteroscopy and fitted with a ReLARC® intrauterine copper device. Ultrasound was performed before and immediately following insertion and at 4-8 weeks follow up to measure the position of the anchor. A fundus thickness of minimum 11 mm is required for a safe insertion. After 5 years, 104 randomized patients were contacted for further follow up by a telephone questionnaire to evaluate their satisfaction of the procedure and the method.

Results

From 2014 to 2021, 574 ReLARC® were inserted. Ultrasound evaluation at follow up confirmed correct positioning in 99%. Reinsertions were done in 6 cases (1%). 2 expulsions (0,3%) have been reported. No insertion problems occurred, even in patients with moderate to strong uterus arcuatus or septate (U2) following resection. There were no early removals due to side effects.

102 patients responded. 94% had an insertion with anaesthesia and reported pain for an average of 1.8 hours following insertion, 85 % said they were painfree the next morning. 6% patients without anaesthesia (vagoscopic approach) reported pain for an average of 1 hour following insertion and all of them were painfree the next morning. 91,2% of patients reported to be satisfied, (68,6% highly satisfied or 22,6% satisfied) with the method. Reasons for dissatisfaction included higher menstrual blood loss, pain and spotting in a minority of the patients.

Conclusions

In contrast to IUDs (intrauterine device), ReLARC® can be inserted in nearly all uterine cavities even U2 septate (ESHRE/ESGE classification of uterine anomalies). Following insertion, the anchor, which is the knot and thread will remain fixed at 5-8mm depth in the fundal myometrium.

If the knot has the same knot penetration depth at the follow up ultrasound control, there is 0.3 % risk of expulsion. ReLARC® can be inserted in an office setting using a 15 -19 Fr. hysteroscope.

Office hysteroscopy was performed in nearly all patients. Insertions without anaesthesia were limited but showed high tolerability and patient satisfaction. The 19 Fr. scope can be used without anaesthesia, tenaculum or speculum in office hysteroscopy.

**ES31-0422 -
Free Communication**

Laparoscopic suturing courses during the COVID era: can online course be an option?

Gabriele Centini¹, Susanna Maia², Nassir Habib³, Errico Zupir⁴, Rudi Campo⁵, Arnaud Wattiez⁶

¹*University of Siena, Molecular and developmental Medicine, San Rocco a Pilli, Italy*

²*Trofa Saúde Gaia, obstetrics and gynaecology, Vila Nova de Gaia, Portugal*

³*Francois Quesnay Hospital, Obstetrics and gynaecology, Paris, France*

⁴*University of Siena, Molecular and Developmental Medicine, Siena, Italy*

⁵*Life Expert Center, ObGyn, Leuven, Belgium*

⁶*Latifa Hospital - Dubai, Obstetrics and Gynaecology, Dubai, France*

Background

Laparoscopic abilities are improbable to be achieved exclusively in the operating theatre, therefore lab training has become mandatory to acquire specific psychomotor skills to be merged in a more complex procedures and training in laparoscopic suturing is probably the way of improving laparoscopic psychomotor skills. However, in the last 3 years laparoscopic training had a forced slowdown due to the COVID pandemic that blocked onsite course. The aim of the study is to assess the feasibility and effectiveness of online suturing course compared to the standard on-site one.

Methods

observational cohort study conducted between January 2018 and December 2021. The onsite courses were run in 3 days with a maximum of 20 participants training in pairs on a Szabo-Berci pelvic trainer, with a Storz Telepack, a 0-degree 10 mm scope as video-lighting source. While the online courses were held through a dedicated platform where a mentor can guide the trainees performing the exercises on a e-knot for one week 3 hours per day.

The participant's performance was evaluated through a pre- and post-course test. The participants were asked to perform 3 stitches across a vertical line while timed and precision and knotting were evaluated, with a score ranging from 0 to 12. The precision was assessed by awarding one point for each dot passed through with the stitch and the knot quality was assessed for locking and quality of the knot from 0 to 2 points.

Results

A total of 151 participants were enrolled in the study, amongst which 89 attended an online course (group A) and 62 an onsite (group B). Comparing the data within the group both courses showed a significant improvement in dot precision knot quality and total score ($p < 0.001$).

Comparing the data between the group, Group B resulted to perform better in precision in the pre-course test (4.0 ± 1.6 vs 3.0 ± 1.6 ; $p < 0.05$) that remained unchanged despite the improvement in both group in the post-course test (5.0 ± 1.0 vs 5.6 ± 0.6 , $p < 0.001$).

No difference in knot quality and total score was shown either in the pre or post test score.

Comparing, the mean improvement in total score the difference was higher in the onsite score but not statistically significant (4.7 ± 3.0 vs 4.1 ± 2.6 ; $p > 0.05$).

Conclusions

This study demonstrates that online suturing course as feasible and profitable for trainees and at the same time and resource sparing. The higher mean increases in total score for the onsite score prove that are probably more profitable for the participants and probably should be reserved for advanced training.

**ES31-0320 -
Free Communication**

Evaluation of radiofrequency endometrial ablation: a 17-year Canadian experience

Ethan Emslie¹, Kasey Berscheid¹, Justin Muir², Deanna Buitenhuis², Brad Sullivan², Darrien Rattray²

¹University of Saskatchewan, College of Medicine, Regina, Canada

²University of Saskatchewan, Department of Obstetrics and Gynecology, Regina, Canada

Background

Abnormal uterine bleeding is characterized by abnormalities in volume, frequency or duration of genital tract bleeding. Its most common clinical presentation is heavy menstrual bleeding (HMB), affecting up to 30% of reproductive aged women. Radiofrequency endometrial ablation (REA) is a uterine sparing procedure offering high patient satisfaction while minimizing recovery times and surgical risks. The purpose of the current study was to better elucidate REA durability by assessing failure rates as defined by need for post-ablation hysterectomy. Age at time of REA and duration from REA until hysterectomy were the primary focus. Exploring rates of REA failure based on age can help gynaecologists offer individualized patient counselling and more tailored management of HMB.

Methods

A retrospective cohort study was conducted at Regina General Hospital in Regina, Saskatchewan, Canada using patient data between April 1, 2002, and March 31, 2019. REA failure cases were identified using operative procedure codes and included patients who were 21 years of age or older, premenopausal, and had a history of HMB at the time of REA. A Kaplan-Meier survival curve was generated to evaluate the timing of hysterectomy in REA failure, stratified by age at index REA. Cox proportional hazard regression assessed the effect of age at index REA on time to post-ablation hysterectomy.

Results

The overall probability of post-ablation hysterectomy was 22.6%. The probabilities of post-ablation hysterectomy were 36.1% for women under 30 years old (n = 128), 28% for women 30-34.9 years old (n = 528), 29.6% for women 35-39.9 years old (n = 1152), and 17.6% for women over 40 years old (n = 2221). The 746 women who underwent post-ablation hysterectomy were subcategorized into two age categories to determine impact of risk factors: under 40 years old (n = 407) and 40 years old and above (n = 339). Tubal occlusion, Caesarean section, dysmenorrhea, chronic pelvic pain, and pain as the indication for hysterectomy ($p < 0.01$) were highest amongst women under 40 years old. Leiomyomas accounted for higher failure rates for women 40 years old and above ($p < 0.01$).

Conclusions

This study is one of the largest and longest in Canadian gynaecologic research, as highlighted by 18-years of data collection and 4029 total cases of REA. Results emphasize that post-ablation hysterectomy is more likely to occur in women under 40 years old. REA can be considered in women aged 30-39.9 years old provided an acceptance of a 70.4-72% success rate. Women under 40 years old with REA failure risk factors such as tubal occlusion, Caesarean section, dysmenorrhea, chronic pelvic pain, and pain as the indication for hysterectomy should be medically managed and consideration of REA should be delayed until 40 years old and above.

**ES31-0511 -
Free Communication**

This is what IVF Specialists don't see!

Mohamed Salama¹, Sayed Elakhras², Bassem Sobhy³, Vasilios Tanos⁴

¹Ain Shams University, Obstetrics and Gynaecology, Cairo, Egypt

²Omam hospital, Minimally Invasive Surgery, Cairo, Egypt

³Al Galaa Taeching hospital, Obstetrics and gynecology, Cairo, Egypt

⁴University of Nicosia Medical School., Obstetrics and gynecology, Nicosia, Cyprus

Background

In vitro fertilisation (IVF) and Assisted Reproductive Techniques (ART) have helped millions of couples achieve what once was deemed impossible to achieve, in terms of achieving pregnancy. Their techniques, protocols and interventions have witnessed many remarkable leaps over the past years.

However, there seems to be an evolving trend towards opting for easier, less risky, and apparently guaranteed ART rather than thoroughly investigating cases of delayed conception and offering them minimally invasive surgery (MIS) options if indicated.

In addition to the higher overall cost, and chances of failure of ART, there is also a potential for complications from ART procedure, especially for cases that have not been well-selected.

Methods

Through a series of cases, we present the potential drawbacks of rushing for ART options, in cases where MIS would have offered more radical and sustainable solutions.

Furthermore, we discuss complications that ensue inappropriately conducted cases of ART, that eventually seek help at the MIS clinics after along path of chronic pelvic pain and deterioration of their reproductive potentials.

Results

In our experience at a tertiary referral centre for minimally invasive surgery, we have encountered many cases submitted for ART, despite having undiagnosed/misdiagnosed endometriosis, myomata, including submucosal ones, hydro- and pyosalpinges, and other pelvic pathologies that should have warranted MIS intervention beforehand.

Furthermore, we discuss complications following ART interventions, such as pelvic inflammatory disease, dissemination of pelvic endometriosis, and pelvic adhesions.

Conclusions

ART is a very hopeful approach for patients with delayed conception. However, it is not without potential harms, especially if poorly conducted, or if the cases were not properly selected. MIS options remain a valuable and useful tool in the assessment and management of a large population of couples seeking fertility. MIS is also a rescue tool for management of complications when it gets out of hand after ART interventions.

BEST ePOSTER

ES31-0018 - P*001

Laparoscopic Gynecologic Surgery Under Regional Neuraxial Anaesthesia: the beginning of a new era?

Daniel Cacozza¹, Elisabetta Fumero², Eleonora Castellacci³, Lorenzo Forasassi⁴, Stefano Landi¹

¹Morragia Pelascini Hospital, Obstetrics and Gynecology, Gravedona ed Uniti CO, Italy

²Ciriè Hospital, Obstetrics and Gynecology, Ciriè TO, Italy

³Palagi Hospital, Day Surgery Multidisciplinary, Florence FI, Italy

⁴Donatello Clinic, Section of Anaesthesiology and Intensive Care, Florence FI, Italy

Background

At present, most laparoscopic interventions are performed under general anaesthesia literature we have few retrospective studies, with few cases, that show just minor laparoscopic procedures performed under regional anaesthesia.

Our study tried to assess the feasibility of almost all types of gynaecologic laparoscopies under regional neuraxial anaesthesia.

Methods

In this retrospective case series, we collected several cases of women undergoing different gynaecologic interventions such as adnexectomy, enucleation of ovarian cysts, multiple myomectomies, laparoscopic hysterectomies, laparoscopic complete excision of endometriosis and hysteroscopies using regional anaesthesia. All the surgeries were performed at the Donatello Clinic in Florence (Italy).

Results

A total of 33 patients undergoing surgery met inclusion criteria. Using RA we found: spontaneously breathing patients without the need of manipulations to the airway, no pulmonary complications, excellent muscle relaxation, fast postoperative bowel canalization, few postoperative pain, low postoperative narcotics use and low incidence of postoperative nausea and vomiting.

Conclusions

Almost all gynaecologic laparoscopies under regional anaesthesia seem to be feasible and safe in motivated patients, but further research is needed to confirm our encouraging data.

The length of uterine niche affects the severity of spotting symptoms: a morphological study based on thin-slice MRI

Wei Xia¹, Zhang Jian¹

¹International Peace Maternity and Child Health Hospital- School of Medicine- Shanghai Jiao Tong University, Gynecology, Shanghai, China

Background

To evaluate the morphological description of symptomatic niche by traditional parameters and radiomic feature parameters from thin-slice MRI. Use these two different methods to evaluate the niche with different degrees of spotting symptoms and the morphological differences of niche formed by one or two prior Caesarean sections (CSs).

Methods

Symptomatic women who were diagnosed with niche by thin-slice MRI in the International Peace Maternal and Child Health Hospital from June 2019 to June 2021 were included, and the clinical data and MRI image data were collected and analysed. Pearson correlation analysis and linear regression were used to evaluate the correlations between traditional parameters and radiomic feature parameters. Based on these two morphological assessment methods, the morphological differences of niches with severe (total bleeding days \geq 14 days) and mild spotting symptoms were compared by univariable and multivariable logistic analysis, and also the differences of niche formed by one or two prior Caesarean sections.

Results

Most shapes of the niches with spotting symptoms could be represented as an ellipsoid with width>length>depth, from which the volume was estimated based on traditional parameters (volume=0.520* length*width*depth). The results show good agreement with the volumes obtained by radiomics. ($R^2=0.756$, $P<0.001$, $y=1*x+0$). Niche length (adjusted OR 1.090, 95% CI 1.006-1.182) and minor axis (adjusted OR 1.208, 95% CI 1.094-1.333) were independent risk factors in patients with severe spotting symptoms. Comparing with one CS, spotting symptoms were more obvious after two CSs (8.76 ± 3.54 vs. 6.68 ± 3.90 days), and the niche length was longer (adjusted OR 1.304, 95% CI 1.190-1.429), surface area to volume ratio was smaller (adjusted OR 0.296, 95% CI 0.129-0.680).

Conclusions

The traditional and radiomic parameters, which are both based on thin-slice MRI, could provide complementary advantages to clinical application. The severity of spotting is related to the niche length diameter parameters and after two CSs, the length becomes longer, and the shape becomes more spherical. We recommend that obstetricians should pay attention to these results and try to repair niches during repeated CS, for reducing the occurrence of niche.

Implementation of endometrial ablation by Novasure with local anaesthesia in an office setting: our experience.

Charlotte Deltour¹, Jeroen R. Dijkstra²

¹University Hospital of Ghent, Gynaecology-Obstetrics, Ghent, Belgium

²Isala Zwolle, Gynaecology-Obstetrics, Zwolle, The Netherlands

Background

In the treatment of heavy menstrual bleeding, endometrial ablation is a minimally invasive procedure that could be performed under general, regional or local anesthesia. Performing procedures in an office setting - with local anesthesia - has been proven to be beneficial for patient wellbeing and to reduce costs, considering fewer anesthetic complications, shorter hospital stays, shorter recovery time and fewer used operation room resources (1). A systematic review by Reinders et al. showed that a combination of either intra- or paracervical anesthesia with intrauterine injections was more effective at reducing pain compared with intra- or paracervical anesthesia alone or no local anesthesia at all (1).

In our center, paracervical anesthesia and intrauterine injections for the fundal block are combined with premedication by oral painkillers. Our experience about the overall patient impression of the usage of local anesthesia in an office setting for endometrial ablation by Novasure (bipolar radiofrequency ablation) was evaluated.

Methods

Implementation of local anesthesia for Novasure - in the peripheral center of Isala, Zwolle, The Netherlands - started first of February 2021. Data was collected until 31st of January 2021. All procedures were performed by the same gynecologist, supported by two doctors assistants. Patients were presented a printed evaluation form immediately after undergoing the procedure. They were asked to fill in the form during the 15 minutes recovery time post procedure time in which they rested, drank something, filled in the form and could go home afterwards. The form consisted of 8 questions, with a 10 point Likert scale (1 being totally not agree, 10 being totally agree).

Results

In 11 months, 54 patients filled in the form, response rate 100%. A mean of 8.5 was given for "Sufficient information prior to the procedure" (distribution 3-10), 9.7 for "everything was clearly explained during the procedure" (7-10). Aftercare was scored a mean of 9.7 (7-10) and clarity of the follow-up 9.7 (7-10). In the case of pain, no side effects of the premedication, pain during and pain after the procedure were scored 9.6 (4-10), 1.7 (0-8) and 1.0 (8-4) respectively. A mean of 9.1 (1-10) women would recommend the Novasure under local anesthesia to a friend.

Conclusions

By our experience, the implementation of local anesthesia by a combination of paracervical and intrauterine injections in an office setting for endometrial ablation by Novasure was well received. Essentials are: sufficient information prior to the procedure (adequate counseling about expectations and manner of anesthesia, patient folder) and premedication.

Evaluation of LiNA SeaStar Retractor and Skin Hooks in the urogynaecology practice

*Hosam Elhalwagy*¹

¹*Consultant, Obstetrics and gynaecology, Hastings, United Kingdom*

Background

The LiNA SeaStar is a self-retaining retractor placed around the surgical incision to maximize tissue exposure. The Skin Hooks are inserted onto the retractor thus maintaining tension and retraction. As the procedure progresses, the Skin Hooks are moved to deeper layers of the fascia, revealing underlying tissue. This study was initiated to evaluate the use of this retractor in the urogynaecology surgery

Methods

Retrospective data was collected for 35 patients who underwent gynaecological surgery from September 2021 to May 2022 within the East Sussex Healthcare NHS Trust. The single use LiNA SeaStar retractor and Skin Hooks were utilised during all procedures. Data were collected from the patient information system. The abilities of SeaStar/Skin Hooks to retract soft tissue from the operative surface, to provide adequate exposure of the surgical site, increase the visibility of the surgical site, free the hands of the assistant and be repositioned during surgery were rated from a scale of 1-5 (1 = not at all satisfied, 5 = very satisfied).

Results

The LiNA Sea Star and Skin Hooks were utilised in 35 urogynaecology procedures: 14 vaginal hysterectomies with pelvic floor repair and sacrospinous fixation, 11 vaginal repairs with sacrospinous fixation, 5 autologous fascial sling procedures, 3 vaginal occlusion surgeries and 2 excisions of TVT mesh. 30 patients were placed in the lithotomy position, while 5 patients that underwent the autologous sling procedure were placed in the extended lithotomy position.

All procedures were performed with the single use LiNA SeaStar retraction system and Skin Hooks. The average number of Skin Hooks used per patient was 6 (minimum 4, maximum 8).

The SeaStar retractor and Skin Hooks were utilised successfully in all 35 patients, and no major concerns that hindered the procedure were reported. Two out of 35 patients had a minor skin laceration. The ability of the SeaStar system to retract tissue, the exposure of the operative field, the easiness of the retractor positioning, and overall satisfaction with the retractor were rated as very satisfying (5/5). The ability of the SeaStar to free the hands of the assistant was evaluated at 5/5.

Conclusions

The SeaStar retractor utilisation can save the use of an extra assistant during urogynaecology surgery. The retraction system offered good visibility and exposure of the operative field.

ES31-0125 - P*006

The SUPERIOR Randomized Controlled Trial of Transcervical Fibroid Ablation Compared to Myomectomy

Felix Neis¹, Bernhard Krämer¹, Sara Brucker¹

¹University of Tübingen, Gynecologie and Obstetrics, Tübingen, Germany

Background

To compare return to normal activity (RTNA) following transcervical fibroid ablation (TFA) with the Sonata® system and myomectomy for the treatment of symptomatic uterine fibroids.

Methods

In this prospective, randomized, controlled single center trial 132 women with symptomatic uterine fibroids are randomized to receive TFA or myomectomy in a 1:1 allocation. A sample of 120 subjects provides 93.5% power for primary analysis; an additional 6 patients/arm will account for a potential 10% loss to follow-up. Transcervical fibroid ablation or laparoscopic myomectomy ± hysteroscopic myomectomy is performed on up to 10 nonpedunculated fibroids per subject (fibroid diameters ≤ 8 cm). Patients will be followed through 12 months.

Results

The study is in progress and the status of the study will be presented. The primary endpoint is RTNA after treatment. Additional assessments include length of stay, the UFS-QOL and Overall Treatment Effect questionnaires, as well as patient satisfaction, safety, pregnancy occurrence and outcomes, and surgical reintervention rates.

Conclusions

The SUPERIOR randomized controlled trial is ongoing to compare the outcomes of TFA and myomectomy, including the duration of return to normal activity.

Association of ZEB1 expression with different forms of endometriosis.

Konstantinos Ntzeros¹, Despoina Mavrogianni¹, Nikolaos Kathopoulos¹, Nikolaos Mplontzos¹, Ntilay Soyhan¹, Athanasios Protopapas¹

¹National and Kapodistrian University of Athens,

1st Department of Obstetrics and gynecology- Alexandra Hospital, Athens, Greece

Background

Endometriosis is peculiar disease that may present with various histological types such as peritoneal implants, ovarian cysts and deeply infiltrating lesions. The gene expression profile of these different lesions has not, so far, been correlated with the particular characteristics of each type of disease, such as the ability of deep endometriotic cells to invade adjacent tissues.

Studies on gene expression of the transcription factor *ZEB1*, a crucial transcription factor of the epithelial-mesenchymal transition, have shown a modified expression in endometriotic lesions compared with the eutopic endometrium of women with endometriosis.

The aim of this study was to compare the expression levels of *ZEB1* between eutopic endometrium in patients with and without endometriosis, and between different types of endometriotic lesions derived from patients with and without deep infiltrative disease.

Methods

We have studied:

- 9 samples from women with endometriotic cysts without deep infiltrating endometriosis,
- 10 samples from women with deep infiltrating endometriosis who, in addition to the invasive endometriotic nodule, also developed endometriotic cysts.
- 8 samples of eutopic endometrium from women without endometriosis who underwent gynecological operation for benign lesions.

The technique applied to investigate *ZEB1* expression levels is Real-Time PCR. The results of the reaction were normalized by simultaneously investigating the expression of the house-keeping gene *G6PD*.

Results

Analysis of the samples, showed a tendency of higher expression of *ZEB1* in women with infiltrating endometriosis compared to women with endometriotic-only cysts without infiltrating endometriosis. The eutopic endometrium of women with endometriotic-only cysts showed under-expression of *ZEB1* in comparison with normal endometrium, while in women with infiltrating endometriosis no significant difference was observed. In the subgroup of women with infiltrating endometriosis, the endometriotic cyst walls, the infiltrating lesions and their paired eutopic endometrium showed similar expression levels. In the subgroup of women with endometriotic-only cysts, the cyst walls showed a tendency of *ZEB1* overexpression when compared to their paired eutopic endometrium.

Conclusions

It appears that different forms of endometriosis present with differences in *ZEB1* expression. Of particular interest is the different *ZEB1* expression profile between women with and without infiltrating endometriosis. Additionally, different *ZEB1* expression levels are found between endometriotic cysts of women with infiltrating endometriosis and women with endometriotic-only cysts. This suggests that similar endometriotic lesions could have a differential gene expression profile and therefore separate pathogenetic mechanisms for their development.

Incidence and risk factors for intraoperative and postoperative complications in the surgical treatment of vulvar cancer

Askin Kaya¹, Sophia-Marie Jäger¹, Marc-Philipp Radosa², Julia Sarah Maria Zimmermann¹, Erich-Franz Solomayer¹, Julia Caroline Radosa¹

¹Saarland University Hospital, Department of Gynecology- Obstetrics and Reproductive Medicine, Homburg- Saarland, Germany

²Klinikum Bremen Nord, Klinik für Gynäkologie und Geburtshilfe, Bremen, Germany

Background

The aim of this study was to determine the incidence of intraoperative and postoperative complications in the surgical treatment of vulvar cancer and to identify risk factors for such complications.

Methods

All patients who underwent surgery for vulvar cancer from 2010 to 2020 at the Department of Gynecology, Obstetrics and Reproductive Medicine, Saarland University Hospital were identified retrospectively using a prospectively compiled clinical database. Binary logistic regression analysis was performed to identify independent risk factors for intra- and postoperative complications. Complications were classified as intraoperative [organ injury (vessel), iatrogenic dermal laceration, blood transfusion, resuscitation, bleeding (defined as major intraoperative bleeding > 500 ml)] and postoperative complications according to a five-grade Classification system by Clavien and Dindo, which records all deviations from the normal postoperative course during a six-week period. Furthermore, postoperative complications were categorized as minor (CD I, II) and major (CD III, IV, V). A receiver operating characteristic (ROC) analysis was used to determine discrimination thresholds for quantitative risk factors.

Results

Out of 227 patients 218 patients were included in the final analysis. Overall, 5 (2.3 %) intraoperative and 49 (22.5 %) postoperative complications were detected. Multivariate analysis for intraoperative complications was not performable as there was only one significant risk factor in univariate analysis (primary lymphonodectomy). On multivariate analysis for postoperative complications, age [odds ratio (OR), 1.03; 95 % confidence interval (CI), 1.00 – 1.06; p = 0.02], number of removed lymph nodes in primary lymphonodectomy (OR, 1.07; 95 % CI, 1.00 – 1.14; p = 0.04) and tumor-free resection margin in mm (OR, 0.85; 95 % CI, 0.73 – 0.99; p = 0.03) were independent risk factors. ROC analysis revealed that number of removed lymph nodes in primary lymphonodectomy ≥ 5 and patients aged ≥ 48 years were more likely to develop postoperative complications. As for tumor free resection margins, a distance $\leq 2,25$ mm from the removed tumor was associated with postoperative complications.

Conclusions

In this analysis, the incidence was 2.3 % for intraoperative and 22.5 % for postoperative complications. Independent risk factors for postoperative complications were age, number of dissected lymph nodes in primary lymphonodectomy and tumor-free resection margins in mm. The factors identified might help to develop further strategies to reduce complications in the surgical therapy of vulvar cancer.

Impact of resident participation on surgical outcomes in laparoscopically assisted vaginal hysterectomy

Jang Eunbi¹, A Jin Lee¹, Kyeong A So¹, Sun Joo Lee¹, Tae Jin Kim¹, Seung-Hyuk Shim¹

¹Konkuk University School of Medicine, Department of Obstetrics and Gynecology, Seoul, Korea- Republic Of

Background

This study compared the surgical outcomes of patients with benign disease who underwent laparoscopic assisted vaginal hysterectomy (LAVH) to determine the association of surgical outcomes with resident participation in the gynecological field.

Methods

We performed a single center retrospective study of 683 patients diagnosed with gynecological benign disease from January 2010 to December 2015 who underwent the LAVH procedure. Clinicopathological characteristics and surgical outcomes were compared between the resident involvement group and attending physician alone group. The primary endpoint was 30-day postoperative morbidity.

Results

In total, 165 patients underwent LAVH with resident involvement and 518 patients underwent surgery without resident involvement. The mean age of the patients was 49 years and 48 years in the resident involvement group and attending alone groups, respectively. There was 30-day postoperative morbidity in 8 (3.5%) and 18 (4.8%) patients in the resident involvement group and attending alone group ($P=0.422$), respectively. Operative time was significantly different between the two groups, 131 minutes in resident involvement group and 101 minutes in attending alone groups ($P<0.001$). On multivariate analysis, Charlson comorbidity index > 2 (OR 8.0, 95% CI 2.7–24.0, $P<0.001$), operation time (OR: 1.018, 95% CI: 1.008–1.028; $P<0.001$) and EBL (OR: 1.002, 95% CI: 1.001–1.003; $P<0.001$) were significantly associated with 30-day morbidity, but resident involvement was not statistically significant.

Conclusions

The operation time was longer when the resident involvement in LAVH, but was no significant difference in morbidity at 30 days. Therefore, resident involvement in LAVH is a reasonable way to meet both resident training and patient safety.

Evolution in management of Ectopic Pregnancy (EP): a 20-year experience

Amelie Morin¹, Rishita Shah¹, Chloe Hall¹, Ora Jesner¹, Funlayo Odejinmi¹

¹Bart's Health NHS Trust, Obstetrics and Gynaecology, London, United Kingdom

Background

To observe the evolution of ectopic pregnancy management between 2000 and 2020 and how the gold standard approach to providing safe, high quality, minimally invasive and effective care to women with this condition has progressed along the years.

Methods

Retrospective study of 20 years of EP management in a London teaching hospital. We collected data and analysed variation along the years. 1296 cases were reviewed, analysing presenting symptoms, risk factors, ultrasound findings, blood loss and length of hospital stay. We reviewed the operative route and grade of the lead surgeon.

Results

The annual number of EP was stable. Common presenting symptoms were abdominal pain (80%) and vaginal bleeding (70%). 55% of women had one or more risk factors. An adnexal mass was identified on ultrasound in more 90% of women in the last 10 years. A striking switch to using laparoscopy was observed in 2003 and has become the gold standard surgical approach. Medical management was initiated in 2009. Interestingly, 3% of surgeries were performed by laparotomy in 2020 after 7 years of 100% laparoscopic management. The rate of procedures performed by trainees has stabilised between 60 and 80% since 2010.

Conclusions

The majority of EP are diagnosed on ultrasound. Surgical management is by laparoscopy and mostly by Registrars as lead surgeons. In 2020, laparotomy was used on 2 occasions: One can speculate whether some women delayed presentation due to fear of Covid contamination in hospital or could this be a consequence of the ever-increasing rate of pelvic surgery?

Minimally-invasive surgery versus open abdominal hysterectomy: a retrospective cohort study of 105 consecutive patients at a multi-site London university teaching hospital

Paula Fagan¹, Nick Tan¹, Carina Johnstone-Ayliffe¹

¹London North West University Healthcare NHS Trust, Department of Obstetrics & Gynaecology, London, United Kingdom

Background

Hysterectomies are one of the most commonly performed surgical procedures for the treatment of gynaecological cancers, pre-cancerous cervical or endometrial histological diagnoses, heavy menstrual bleeding, post-menopausal cysts, chronic pelvic pain and fibroids. There are various approaches to performing a hysterectomy including laparoscopic, open, vaginal and robot-assisted.

The efficacy of the laparoscopic or laparoscopic-assisted approach has previously been established. However, there is a potential for longer operating times compared with the open approach.

The aim of this study was to compare laparoscopic, robot-assisted and open surgery for total and subtotal hysterectomies in a multi-site London university teaching hospital over a one year period. Outcome measures evaluated include operative time, length of inpatient stay, surgical blood loss and Clavien-Dindo (C-D) complication rates.

Methods

This is a retrospective analysis of 105 consecutive hysterectomies performed over a one-year period from 1 February 2021 to 1 February 2022 at London North West University Healthcare NHS Trust. All patients who underwent surgery over the time period were identified via an electronic surgical booking system. Patient characteristics including age, menopausal status, indication for surgery and co-morbidities were collected from electronic patient records. Our primary outcome measure was operating time. Secondary outcomes included estimated blood loss, intra-operative and postoperative complications and length of hospital stay. Descriptive statistics were used for data analysis.

Results

A total of one hundred and five (n=105) hysterectomies were performed in our hospitals between 1st February 2021 and 1st February 2022. Of these, 68% were laparoscopic, 12% robot-assisted, and 20% were open. The open approach on average had the shortest duration of operating time of 117 minutes, compared with laparoscopic hysterectomy having an average duration of 169 minutes. The robot-assisted hysterectomies on average took 132 minutes. Complication rates were higher in the open approach cohort, having Clavien Dindo 1 complication rates in 30% and a C-D 2 complication rate of 20%. C-D 3 complications occurred in 4%. MIS had 23% C-D 1, and 2.9% C-D 2. The robot-assisted hysterectomy complication rate was lowest at a C-D 1 of 16.7%. Length of hospital stay was higher for women who had open surgery (mean 2.4 days). The average hospital stay for laparoscopic and robot-assisted hysterectomy was 1.5 and 1 day respectively. Average blood loss was lower in laparoscopic hysterectomies compared with open and robot-assisted hysterectomies.

Conclusions

This study demonstrates that the laparoscopic approach is associated with lower complication rates, reductions in hospital stay and less blood loss. The open approach had shorter duration of operating time overall. Given that benefits persist even in prolonged cases, a minimally-invasive approach should be offered to selected patients undergoing hysterectomy. Further evaluation is required to assess selection criteria for open vs laparoscopic or robot-assisted approaches to hysterectomy.

Clinical characteristics of women undergoing laparoscopic uterine niche repair

Monika Sobocan¹, Anamarija Jernejsek¹, Branka Zegura Andric¹

¹University Medical Centre Maribor, Division for Gynaecology and Perinatology, Maribor, Slovenia

Background

Cesarean sections are increasingly frequent obstetric interventions which can lead to the formation of isthmoceles. Literature also describes the myometrial defect which persists after cesarean section as a uterine niche. Prospective studies have shown, that isthmoceles can affect 50-60% of women after cesarean section and can cause symptoms such as dysmenorhea and abnormal uterine bleeding as well as secondary infertility. Isthmoceles are highly recognizable through transvaginal ultrasound and are characterized as myometrial thinning of at least 2 millimeters. Due to the important consequences of isthmoceles on fertility and quality of life through possible persistent symptoms of abnormal uterine bleeding management options for women during childbearing age are important. Herein we explore the characteristics of women which have undergone laparoscopic uterine niche repair at our institution.

Methods

This case study evaluated the characteristics of women which have undergone a laparoscopic isthmocele repair at the University Medical Centre Maribor, Slovenia between the years 2015 - 2019. Through a patient record analysis we have retrospectively analysed data of all women treated during the specified time period for uterine niche. We assessed the symptoms, pre-treatment diagnostics performed, the patient demographics and post-treatment outcomes of the patients. Statistical analysis was performed by using descriptive statistics.

Results

Between November 2015 to November 2019, 9 women were treated for isthmoceles at our institution by means of laparoscopic uterine niche repair. The average age of women treated for isthmocele was 32,8 years (minimum 27 years and maximum 38 years). An average time of 3,8 years had passed between the performance of a cesarean section and the subsequent isthmocele repair (minimum 1 year - maximum 11 years). Women initially presented in the majority of cases due to abnormal uterine bleeding (6/9 patients; 67%) or fertility related issues (secondary infertility or unsuccessful pregnancy (3/9 patients; 33%). Prior to treatment 33% of women (n=3) had had 2 cesarean section and the majority had only had one cesarean section (n=6, 67%). 44% of women had elective cesarean sections and 56% of them had emergency cesarean section. The mean myometrial thickness prior to isthmocele repair was 2,1 mm (minimum 1,4 - maximum 3 mm).

Conclusions

Laparoscopic isthmocele repair is a feasible management option for women with residual myometrium of 5 mm or less. Women trying to conceive unsuccessfully after a cesarean section or with symptoms of pain or abnormal uterine bleeding should be evaluated for the presence of a uterine niche. Counselling should be offered regarding surgical treatment. Attempts at conception after laparoscopic uterine niche repair should be postponed for at least 6 months after surgical management.

Robotic surgery for endometrial cancer: the experience of a Portuguese tertiary cancer center

Tânia Barros¹, Rita Torres², Luís Pinto², Adelaide Vitorino², Sónia Ferreira², Henrique Nabais²

¹*Centro Materno Infantil do Norte- Centro Hospitalar Universitário do Porto, Departamento da Mulher e da Medicina Reprodutiva, Porto, Portugal*

²*Centro Clínico Champalimaud, Unidade de Ginecologia, Lisboa, Portugal*

Background

Endometrial cancer is the most common gynecological cancer. Surgical management has greatly evolved in the past few years with the introduction of minimally invasive surgical approaches, like robotic surgery. This study aimed to report the experience of a Portuguese single institution with the application of robotic surgery (da Vinci Xi system®) in endometrial cancer.

Methods

A retrospective review of a Portuguese institution database of all patients who submitted robotic surgery for endometrial cancer between January 2019 and October 2021 was performed. Records were reviewed for demographic data and perioperative outcomes.

Results

During the period of study, 62 patients were submitted to robotic-assisted total hysterectomy with staging for endometrial cancer. The average age and body mass index of the patients was 66.92 years and 29.9 kg/m², respectively. Hypertension (36.1%) was the most frequent medical comorbidity among the study group. A mean preoperative CA125 level of 25.86±36.58U/mL.

Total hysterectomy and salpingo-oophorectomy were performed on all patients. One sentinel lymph node (SLN) was detected in 90.32% of the patients and bilaterally in 83.87%. Pelvic lymphadenectomy was performed in 45.2% of patients, and the mean number of harvested lymph nodes was 20 (range, 9–72). The rate of para-aortic lymphadenectomy was 22.6% and the mean number of lymph nodes was 16 (range, 8-51). Final pathologic analysis demonstrated that stage I and II disease comprised 79.03% (Ia 59.68%, Ib 19.35%) and 6.45% of patients, respectively. Stage III disease accounted for 14.52% of the patients. No patients with Stage IV disease were identified. The endometrioid type was the most frequent histology (74.19%). Six (9,68%) patients had serous carcinoma, 2 (3.23%) patients had clear cell type, 1 (1.61%) had carcinosarcoma and 7 had mixed carcinoma (11,29%).

Docking time averaged 5 minutes. The mean blood loss was 90mL. The mean hospital stay was 1.35±0.71 days. None of the patients had intraoperative complications. There were no peri-operative deaths. No conversion to laparotomy or laparoscopy was performed. Postoperative complications were reported in 1,6% of the patients.

Conclusions

In this study, robotic surgery (da Vinci Xi system®) appears safe and effective to use in endometrial cancer staging operations. Acceptable results can be expected, including reduced perioperative complications, lower conversion to laparotomy, reduced operative blood loss, and reduced hospitalization.

Endometriosis-related infertility: Does infertility correlate with the rASRM score and duration of endometriosis until surgical treatment? A long-term follow-up.

Tatjana Nobs¹, Dilara Akpinar¹, Sven Becker¹, Morva Tahmasbi Rad¹

¹University Hospital Frankfurt, Gynecology and Obstetrics, Frankfurt am Main, Germany

Background

Around 10% of women in the reproductive age are affected by endometriosis. Endometriosis development is influenced by inflammation and estrogen metabolism. The etiology and pathogenesis remain unclear. The mechanisms of endometriosis-related infertility have not fully been discovered. Endometriosis is detected in up to 30-50% of women who had diagnostic laparoscopy due to infertility.

Methods

A total of 102 women with endometriosis in the reproductive age have been included in the study. All of them got laparoscopic surgery between 2007 to 2017 on the grounds of fertility treatment or infertility diagnostics. The data was collected retrospectively and analyzed prospectively after a follow-up period of 36 to 197 months.

Results

The average time of infertility was 40 months. The longer the period of infertility, the longer it lasted until pregnancy ($p=0.007$). Every year without surgical treatment decreases the probability of becoming pregnant between 4.6-26% (95% CI of hazard ratio). Six months after laparoscopic treatment 38% of women with rASRM score 1, 13.3% with rASRM 2, 43.8% with rASRM 3 and 6.9% with rASRM 4 got pregnant. In the 42-month follow up rASRM 3 rated women showed the highest pregnancy rate (83.3%), followed by the rASRM 1 group (37.9%). Differences in the cumulated pregnancy rates were not significant.

Conclusions

The elapsed time until surgical treatment has a significant effect on the actual occurrence of pregnancy as well as the time until pregnancy. The intraoperative rASRM score does not correlate with the postoperative probability of pregnancy. Consequently, it is not possible to give a prognosis about the possibility of pregnancy regarding the intraoperatively determined rASRM score.

Myopericytoma of the broad ligament: a rare entity with a rare location

Paulina Costa¹, Ana Catarina Borges², Beatriz Palmeira¹, Maria Manuel Torrão¹, Rita Sousa¹

¹*Centro Hospitalar do Médio Ave, Gynecology and Obstetrics, Braga, Portugal*

²*Hospital de Braga, Gynecology and Obstetrics, Braga, Portugal*

Background

Myopericytoma is a rare mesenchymal soft-tissue tumor originating from the perivascular myoid cells. It may occur at any age, although most cases are seen in adults. It is usually a benign mass arising in the skin of extremities. Visceral organs and the central nervous system are rarely involved. We describe a case of myopericytoma in the broad ligament. To our knowledge, only a few cases of myopericytomas affecting the female genital tract are known to date.

Methods

Clinical medical record consultation and literature revision

Results

We present a case of a woman in her fifties, perimenopause, referred to our Gynaecology department due to the incidental finding of an adnexal mass during a routine transvaginal ultrasound. The ultrasound confirmed an adnexal atypical mass, that seemed to originate from the fallopian tube, with 58 x 19 mm in size. To better characterize the lesion, magnetic resonance imaging was performed, revealing a highly vascularized left broad ligament mass, of uncertain origin, that measured 51 x 31 x 56 mm, infiltrating the anterior/left uterine wall. The preoperative study was normal, and the neoplastic markers were negative. An exploratory laparoscopy was performed confirming a broad ligament mass with 4-5 cm in diameter and elastic consistency. We performed a laparoscopic excision of the lesion, and the extemporaneous examination characterized the mass as a mesenchymal tumor, without malignant criteria. Surgery underwent without complications and the post-operative course was uneventful. In the definitive pathological exam, macroscopically, it was a brown nodular mass, with 3.5 cm, smooth outer surface, and elastic consistency. Histological examination revealed a highly vascularized mass with areas of spindle cell proliferation with perivascular distribution. No cellular atypia, pleomorphism or necrosis were present. Immunohistochemical analysis was positive for smooth muscle action (SMA) in the perivascular cells and CD34-positive in the blood vessels endothelial cells. These findings were compatible with a myopericytoma. The patient is currently asymptomatic and will remain under surveillance.

Conclusions

This case, due to its rarity, raises awareness of an unusual diagnosis, suggesting that myopericytomas must be part of the differential diagnosis in the investigation of a female genital tract mass of unknown etiology. Histology and immunohistochemical analysis play an important role in its diagnosis.

Previously described cases alert for the possibility of local recurrence, highlighting the need for continued follow-up and the importance of complete surgical resection and margins evaluation.

Outcomes from the Outpatient Hysteroscopy Unit at London Northwest University Healthcare NHS Trust (2014 – 2021)

Wioletta Kapadia¹, Stewart Disu¹

¹London Northwest University Healthcare NHS Trust, Obstetrics and Gynaecology, London, United Kingdom

Background

Hysteroscopy is one of the most common procedures performed in gynaecology. The introduction of more advanced technology, including smaller diameter hysteroscopes in the early 90's and the Stefano Bettocchi's no-touch technique, made hysteroscopy less painful and invasive, leading to more hysteroscopies being performed in outpatient settings.

Methods

Data was collected retrospectively as a part of yearly audits from 2014, from computer systems including EPRO and ICE and from random patient notes.

Results

This presentation shows the development and growth of Outpatient Hysteroscopy (OPH) in our unit. OPH was introduced in 2014 with one OPH clinic taking place fortnightly. The number of patients referred has increased drastically since then, and we currently run more than 10 weekly OPH clinics. The primary source of referrals has also changed over this time, from only 13% of patients referred by their GP in 2016, up to 76% in 2021.

Our success rate has remained stable at around 80%, despite the increased number of referrals, but with a large reduction in the number of patients requiring hysteroscopy under GA (50% of those due to Cervical Stenosis). In addition, we have had a greatly increased detection rate of detection of malignant (5%) and premalignant (6%) cells.

Conclusions

We are continually working on improvement in our unit, with an increased importance on maintaining service despite a huge increase in demand, especially during the Covid pandemic. The number of staff with increased skill sets has grown and with the increase in demand the number of "see and treat" patients has increased since 2014, and we are working towards introducing a "one stop shop" to perform scan and hysteroscopy in a single patient visit.

vNotes technique in a case of very difficult abdominal access

Delia Yazdanian Masouleh¹, Sara Engels¹, Nathalie De Landtsheer¹, Evy Gillet¹, Georges Salem Wehbe¹, Stavros Karampelas¹

¹CHU Brugmann, Gynecology, Brussels, Belgium

Background

This is the case of a 78-year-old multiparous woman that was referred to our department for post-menopausal bleeding. The patient underwent pelvic ultrasound scan that showed a slightly thickened endometrium of 8 mm and hysteroscopic guided endometrial biopsies that showed a well differentiated low grade endometroid cancer. MRI stage was Ia. Total hysterectomy and bilateral salpingo-oophorectomy (BSO) was chosen as treatment. The patient presented several comorbidities including morbid obesity (BMI 40), and in her past history several abdominal surgeries complicated with severe abdominal wall eventration, including small and large intestines as well as part of the stomach.

Methods

Considering the really difficult abdominal approach the vaginal natural orifice transluminal endoscopic surgery (vNotes) technique was selected. This is an advanced minimally invasive gynecologic surgery technique, that requires 8 mmHg pneumoperitoneum and 0° to 20° Trendelenburg position. Instruments are placed through the vagina into the pelvic cavity, giving access to the uterus, fallopian tubes and ovaries without the need for abdominal skin incisions

Results

The vNotes total hysterectomy and BSO was performed in 30 minutes with minimal blood loss, little post-operative pain and fast recovery. The patient had no complications and was discharged from the hospital 24h post-operatively

Conclusions

The vNotes technique is a valid option for patients with severe comorbidities and difficult abdominal access.

MRI in Preoperative Staging in Patients with Endometrial Cancer: diagnostic value and error analysis in endometrial carcinoma

Mónica Calado Araújo¹, Rita Sequeira Campos¹

¹Hospital Pedro Hispano, Obstetrics and Gynaecology, Porto, Portugal

Background

Endometrial cancer (EC) is one of the most common gynaecological malignancies in developed countries. The aim of this study was to evaluate the diagnostic accuracy of magnetic resonance imaging (MRI) for detecting myometrial invasion (MI) and cervical invasion (CI) and pelvic lymph nodes metastasis (PLNM) in EC, factors that affect disease management and aid in surgical planning. The main causes of error in staging based on MRI results were also analysed.

Methods

Retrospective cross-sectional cohort study including patients diagnosed with EC from March 2021 to March 2022 at Hospital Pedro Hispano. The MRI examination was performed 8-140 days before surgery, and the imaging results were compared with histological findings. The sensitivity, specificity, accuracy, positive predictive value, negative predictive value, and κ coefficient were calculated. We used the Clopper-Pearson (exact) method to obtain 95% confidence intervals for each proportion estimate. Several factors were correlated with incorrect MRI diagnosis for MI, CI or PLNM such as mioma, cornual lesion, adenomyosis, tumour type, number of deliveries and tumour diameter. Mann-Whitney U-test or qui-squared tests were used to determine the statistical association.

Results

Our cohort included 21 women with EC. The sensitivity, specificity, diagnostic accuracy, positive predictive value and negative predictive value of MRI were 71,4%, 64,3%, 66,7%, 50% and 81,82%, respectively, for identifying MI; 50%, 100%, 80,9%, 100% and 76,47%, respectively, for identifying CI. For PLNM was not possible to calculate since lymphadenectomy was only performed when there was deep MI at extemporaneous examination. MI was incorrectly predicted in 6 patients (28,5%), and the main causes of error were cornual lesions ($p = 0.004$) and large tumour diameter ($p = 0.036$). By contrast, for CI there was no significant difference for the variables tested.

Conclusions

Preoperative knowledge of the depth of MI will facilitate the introduction of minimal invasive therapy for minimal disease. This study demonstrated high negative predictive value in identifying patients with deep MI and CI and high specificity in the diagnosis of CI, which not only reveals its great value in deciding the extent of surgery, but ultimately provides better optimization of the operating room planning.

Abstract: A Retrospective Review of Outcomes in Patients who Underwent Combined Laparoscopic Sacrocolpopexy and Ventral Mesh Rectopexy

Zbigniew Tkacz¹, Louise Haldane²

¹*University of Dundee Medical School, Obstetrics and Gynaecology, Dundee, United Kingdom*

²*University and Medical School in Dundee, Obstetrics and Gynaecology, Dundee, United Kingdom*

Background

NHS Tayside: Ninewells Hospital and Perth Royal Infirmary Aims The aims of this study were to determine outcomes in patients who underwent both Laparoscopic Sacrocolpopexy and Ventral Mesh Rectopexy in combined cases under Gynaecology and General Surgery in NHS Tayside.

Methods

Methodology Surgical lists from the past 8 years were analysed and 11 patients were found to have undergone the above combined procedures. Patients were then contacted via telephone and the ICIQ-VS questionnaire was used to determine patient outcomes following their surgery. The survey assesses 3 parameters: vaginal symptoms, psychosexual symptoms, and overall quality of life – the patients first had to rank the degree to which they were experiencing each symptom, and then the how much each bothered them. Vaginal Scores and Sexual Scores were then worked out using the ICIQ-VS formula.

Results

Results 11 patients underwent combined Laparoscopic Sacrocolpopexies and VMR in NHS Tayside from 2013-2021. 2 patients had sadly passed away from non-gynaecological causes and 3 patients did not answer their phones. Of the 6 that were able to fill out the questionnaire, 50% reported vaginal symptoms: dryness being the main symptom, followed by reduced sensation, vaginal laxity and descending bulge. The vaginal scores out of 53 for each patient were: 2, 2, 10, 0, 0, 0. 4/6 patients had active sex lives and were able to complete the Sexual Matters section. The Sexual Scores out of 58 for each patient were: 6, 8, 0, 0. The biggest complaint was mild recurrence of symptoms for 1/3rd of patients – but one patient suffered chronic infection of the mesh leading to long term antibiotic treatment. Another patient suffered chronic pain following her procedure, leading to suicidal ideation. However, most patients did not experience any complications during follow up in the Urogynaecology Clinic.

Conclusions

Conclusions This study aimed to assess patient outcomes following combined Laparoscopic Sacrocolpopexy and VMR. Analysis of patient Responses to the ICIQ-VS Questionnaire demonstrated a good post-op quality of life, with 84% reporting that their symptoms did not negatively impact their quality of life. Of the responses collated, 50% were still reporting ongoing vaginal symptoms, with dryness being the main symptom, followed by reduced sensation, vaginal laxity and descending bulge. On the Sexual Matters section of the questionnaire, 2/3rds of patients reporting having active sex lives, and of those, 50% said their sex life was affected by their prolapse symptoms. Thus, the combined approach produced good patient outcomes and most patients were now symptom free and satisfied with the results.

Vaginal cuff dehiscence after hysterectomy: about a clinical case

Fernanda Cristina Alves¹, Mariana Morais¹, Mário Moura¹, Ana Moreira¹, Osvaldo Moutinho¹

¹Centro Hospitalar de Trás-os-Montes e Alto Douro, Ginecologia/Obstetrícia, Vila Real, Portugal

Background

Vaginal cuff dehiscence is a rare, but potentially morbid complication of total hysterectomy (with an incidence ranging from 0.14-5%). Despite its rarity, it can occur as early as three days and as remotely as three years from the index surgery. The incidence of cuff dehiscence with evisceration is even lower (0.03-0.4%).

Methods

To describe a clinical case of vaginal cuff dehiscence with evisceration of small intestine loops after radical hysterectomy.

Results

We present a case of a 49-year-old woman diagnosed with a cervical squamous cell carcinoma (FIGO stage IA2) who underwent radical hysterectomy with pelvic lymphadenectomy. The postoperative period was uneventful, and the patient was discharged on the 6th postoperative day.

Six months after surgery, the patient presented to the emergency department with abdominal pain and vaginal foreign body sensation. The patient referred resumption of sexual activity since surgery only two days before the event. The gynecological examination revealed a complete vaginal cuff dehiscence with exteriorization of an intestinal loop to the vagina. The patient was rushed to the operating room and the dehiscence was corrected via abdominal route with a polyfilament vicryl single continuous layer suture. During the postoperative period, the patient started broad-spectrum antibiotic therapy and had no more gynaecological complications. Mentioning only the occurrence of thrombophlebitis in the upper limb which ended up prolonging the immediate post-surgery recovery period.

Conclusions

Major risk factors for vaginal cuff dehiscence are total robotic or laparoscopic hysterectomy, low body mass index (BMI) and cigarette smoking. The most common trigger for dehiscence among premenopausal individuals is coitus.

Besides, vaginal cuff dehiscence with evisceration constitutes a surgical emergency since bowel evisceration can lead to bowel necrosis and subsequent peritonitis and sepsis.

Although it is a rare event, it is important to be alert to its occurrence, even years after the index surgery.

Prevention of surgical site infection (SSI) in gynecology: a literature review and algorithm proposal.

Jessica Mauro¹, Alessandra Surace², Elisa Tripodi², Sara Paracchin², Chiara Borghi², Alessandro Buda²

¹University of Udine, Gynecology Oncology, Udine, Italy

²Ospedale Michele e Pietro Ferrero, Gynecology Oncology, Verduno, Italy

Background

Complications of the surgical site is a major unsolved health issue, with a negative impact on the patient outcomes and healthcare system. Furthermore, they are a burden on the national health care budget in their resulting cost. SSI represents the most frequent Hospital-Acquired Infections, constituting almost 20% of HAIs in Europe countries. To date there is a lack of data on this topic in gynaecologic surgery. Abdominal surgery carrying the highest risk and vaginal route the lowest. In addition, the SSI's risk increases in GynOnc surgery.

Methods

A review of the English literature was undertaken including publications between January 1965 and February 25, 2022, to identify papers that described how to prevent SSI following obstetric or gynaecological surgery.

Results

Overall, 118 publications were identified. Only studies describing preventive strategies for SSI were considered relevant (n = 27). A total of 8 studies were finally included and analysed in this review. The most common risk factors were identified and classified as shown in table 1.

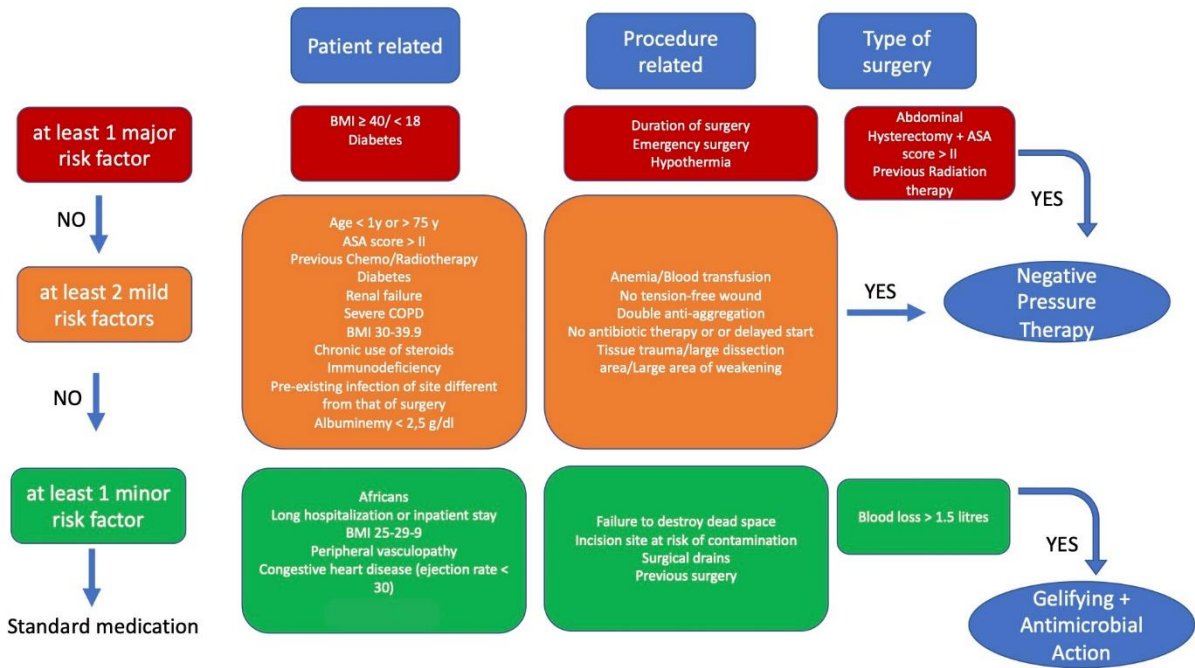
Table 1: SSI risk factors classification

PATIENT FACTORS	PRE-OPERATIVE FACTORS	INTRA-OPERATIVE FACTORS	POST-OPERATIVE FACTORS
Age	Skin preparation	Prolonged surgery	Haematoma
Obesity	Hair removal	Poor surgical technique	Blood transfusion
Diabetes Mellitus	Type I and II diabetes mellitus (glycemic control)	Surgical drains	Length of hospital stay
Place of residence - rural	American Society of Anesthesiology (ASA) score ≥ 3	Non-use of antimicrobial prophylaxis	
Smocking	Pre-hospital stay of ≥2		
Immunosuppression (e.g., steroid use, alcohol)			
Poor nutritional status			
Length of pre-operative stay			
Anemia			

Conclusions

The analysis of the available literature highlighted a paucity of content on active prevention in the post-operative period with few studies on gynecological surgery. Therefore, we propose an algorithm based on known and established risk factors (figure 1).

Figure 1: proposal of algorithm for prevention SSI



We propose an algorithm that considers not only the subjective characteristics of the patients, but also the features of the surgery they undergo. Based on the risk category, an appropriate advanced medication is proposed to try to reduce the rate of SSI. In presence of one major risk factor or two or more intermediate risk factors, a negative pressure wound therapy without reservoirs is proposed, that can produce a negative pressure of 80 mmHg on the surface of the wound. Whereas, if intermediate risk factors are less than two, or at least one minor risk factor, a medication including hydrocolloid technology and gelifying action with the antimicrobial activity is proposed. For all wounds with no particular risk factors, a standard dressing is maintained. Finally, by using a dedicate sheet, we also proposed to evaluate the efficiency of the medication used, regarding either the characteristics of the wound in post-surgical assessment, and the degree of comfort and satisfaction expressed by the patient.

Endometrial Hyperplasia: Audit of Diagnosis and Management

James Wylie¹, Donald Chandranath¹, Declan Quinn¹

¹Northern Health and Social Care Trust, Obstetrics and Gynaecology, Antrim, United Kingdom

Background

An audit of our Trust's diagnosis and management of Endometrial Hyperplasia prior to and during the COVID-19 pandemic with comparison against national guidance.

Methods

Our pathology team were able to identify all histopathologically confirmed cases of endometrial hyperplasia (both atypical and non-atypical) for the past 5 years (2017 - 2022). These patients' notes were reviewed, and their care was audited against the current national guidance from the Royal College of Obstetricians and Gynaecologists (RCOG). Two reviewers examined the medical notes and gathered the data against a pre-determined proforma. Data upon patient risk factors and management pathways was collated for comparison against guidance.

Results

Preliminary examination of the data has shown that most patients pre-COVID-19 pandemic were managed appropriately in line with the College guidance. From March 2020 onwards there was deviation from expected standards in review frequency and also noted delays in achieving definitive surgery where appropriate. Patient demographics are in line with known risk factors, in that those patients who were diagnosed with endometrial hyperplasia had higher BMIs, low parity and commonly were diabetic or had polycystic ovarian syndrome (PCOS).

Conclusions

COVID-19 has had a major impact upon the provision of care for patients with endometrial hyperplasia; both diagnosis and management have been delayed during the pandemic. Pre-pandemic we feel that these patients were well managed but during the unprecedented pressures some have faced delays in receiving optimal care. As a result, we hope to create a Trust guideline on the management of endometrial hyperplasia, for our clinicians, as well as a patient information leaflet to empower those individuals diagnosed with the condition.

Relationship between isthmocele and uterine closure in a hysteroscopic series: is it possible to modify uterine closure technique to avoid cesarean scar defect?

Antonio Claudio Cannizzaro¹, Gargano Graziella¹

¹Ospedale Buccheri La Ferla FBF Palermo, Ginecologia ed Ostetricia, Palermo, Italy

Background

The objective of this study is to demonstrate that the cross stitches technique determines a high risk of **isthmocele**. The usual technique during cesarean delivery is locked suture. In order to modify the cesarean hysterorrhaphy procedure used up to now and to stress that deep uterine scar defects are potentially the consequence of a suboptimal uterine closure technique.

Methods

This is a evaluation that examines the presence of isthmocele diagnosed hysteroscopy after transvaginal ultrasound (2D and 3D) and hydrosonography (gel foam) in patients who had a cesarean section. We performed about 1180 hysteroscopies and 271 of those showed isthmocele. 80% of patients had from 2 until 4 cesarean sections, 20% had only 1 cesarean. Hysteroscopy was performed from the tenth day of the menstrual cycle. We performed hysteroscopy with Bettocchi instrument and resectoscope for cases subjected to hysteroscopic correction

Results

The study envisaged a first phase from July 2019 / February 2021 in which the percentage of isthmocele was 26% and a second phase (March 2021/ February 2022 in which the percentage dropped to 19% (overall rate of 22,9%)

120 of isthmocele after cesarean delivery were performed in Buccheri La Ferla hospital (67%). Cesarean section in our hospital was all performed with double- or single-layer locked technique suturing. Patients' symptoms were spotting (61%), menstrual irregularity (14%), metrorrhagia (17%), infertility (8%). In all patients (700) of the first phase, cesarean section was performed with double- or single-layer locked technique suturing

In many patients of second phase undergoing cesarean section at the same hospital, a breccia suture was introduced with a continuous, introllecting double layer, with respect to the course of the muscle fibre of the lower uterine segment and at the ultrasound check at 30, 60, 90 days, the absence of isthmocele was confirmed almost totally

Conclusions

Caesarean deliveries are the most common abdominal surgery procedure globally and the optimal way to suture the hysterotomy remains a matter of debate. The surgical technique for uterine closure influences the healing of the Caesarean scar. It is possible that incomplete closure of the uterine wall due to the use of the single-layer, endometrial-saving closure technique or to the use of locking continuous sutures instead of interrupted sutures may result in more frequent and larger cesarean scar niches. We examined uterine caesarean scar remodelling by hysteroscopy in all our patients. Our results suggest that caesarean scar niches were present in 80% of the women who performed caesarean delivery. Our study showed that the locked technique used to do hysteroigraphy up to now will create definitely isthmocele.

On the order hand, the result of the continuous uncrossed double layer is significantly different

The interplay between renal failure, cardiac arrest, and pelvic organ prolapse: a case report

Diana Rodrigues-Martins¹, Ana Beatriz Almeida¹, Anabela Branco², Raquel Reis², Bercina Candoso², Rosa Zulmira¹

¹*Centro Hospitalar Universitário do Porto – Centro Materno Infantil do Norte CMIN, Women and Reproductive Medicine, Porto, Portugal*

²*Centro Hospitalar Universitário do Porto – Centro Materno Infantil do Norte CMIN, Urogynaecology Unit directed by Bercina Cardoso, Porto, Portugal*

Background

Pelvic organ prolapse (POP), the transvaginal descent of pelvic organs, can cause mild hydronephrosis but rarely leads to a deterioration in kidney function. We present a case of severe uterovaginal prolapse that caused bilateral ureteral obstruction and led to renal failure, hyperkalaemia, and cardiac arrest.

Methods

A case report of a patient managed at a tertiary centre.

Results

An 85-year-old female patient presented to emergency ward because of an altered state of consciousness. On her medical record there was five vaginal deliveries, hypertension, diabetes mellitus type 2, and a POP (quantification stage IV uterovaginal prolapse) which she previously refused to treat. Soon after the admission she developed a cardiac arrest requiring a temporary transcutaneous pacing. Results of laboratory analyses were as follows: creatinine 9.8 mg/d; potassium 7.2 mmol/L, glucose 211 mg/dL, pH of 6.9 and bicarbonate level of 7.2 mmol/L. While the use of beta blockers could have been a potential renal deterioration factor, data obtained from ultrasonography and the abdomen tomography revealed a bilateral hydronephrosis, leading to the hypothesis that the patient had post-renal renal failure, due to the compression by the prolapsed uterus. A single dialysis session was performed, and a pessary was then placed resulting in spontaneous diuresis, and improvement of kidney function (creatinine 1.5 mg/dL and potassium 4.2 mmol/L).

Two weeks later the patient was readmitted due to an episode of syncope. She had fever and a cardiac rate of 30-40 beats per minute. Her creatinine was 3.79 mg/dL and potassium 6.1 mmol/L. She also had leucocytosis and a C-reactive protein of 105 mg/L. The pessary had fallen of. The bradycardia was successfully corrected with isoprenaline, and she began endovenous antibiotics to a urinary tract infection with bacteraemia by *Escherichia Coli*. Since the patient agreed on surgical treatment, a vaginal hysterectomy was scheduled as soon as clinically possible. Surgery had no complications. At day one post-op her creatinine was 1.27 mg/dL.

Conclusions

Kidney failure due to uterine prolapse is rare, nonetheless, even in complex cases with various causative factors for kidney injury, the presence of severe POP should prompt the clinician to exclude this cause. Either pessary or surgical intervention have been shown to have a positive influence on the degree of hydronephrosis, however although the kidney function usually improves, a complete recovery is not always attained. Early recognition and treatment of this form of post-renal kidney failure is essential in order to prevent serious complications, as illustrated in this case.

Assessing the clinical impact of long-term use of GnRh analogues on women with benign gynaecological conditions during the COVID pandemic

Hoda Elmoniry¹, Medha Sule¹, Neeraja Kuruba¹

¹Norfolk and Norwich University Hospital, Obstetrics and Gynaecology, Norwich, United Kingdom

Background

During COVID pandemic, there was a temporary suspension of benign gynaecological surgeries and lack of theatre capacity in the United Kingdom; A result of which was prescribing GnRh analogues to women for prolonged periods outside of license use (6 months). This was to provide symptom control until the time of definitive surgery.

This service evaluation project was aimed to assess the clinical impact of long-term use of GnRh analogues (Zoladex) on women with benign gynaecological conditions during the COVID pandemic at the Norfolk and Norwich University Hospital, UK.

Methods

We collected retrospective observational data on all women who started Zoladex in the period between 2019 – 2020 and continued for more than 6 months. 41 patients received Zoladex for a duration that ranges between 7 months and 2.5 years. Data collected included patient demography, indication of use of GnRh analogues, number of doses, use of add back HRT and side effects. Data was collected from the Patient Administration System (PAS) database, pharmacy records, patient clinic letters, GP summary care records (NHS SPINE) and online patient notes

Results

41 patients had Zoladex for more than 6 months; 46% (19) of them had Zoladex for up to one year, 44% (18) for up to 2 years and 10% (4) for more than 2 years (total range of doses 7-31). The primary indication for use was chronic pelvic pain (46%), menorrhagia (27%), fibroid uterus awaiting surgery (17%) and Premenstrual Syndrome (PMS) (10%). 95% of patients (39) used add back HRT. 5 patients (12%) stopped HRT prematurely.

14 patients (34%) developed side effects from Zoladex; 3 patients (21%) reported these side effects during the first 6 months of use, 50% (7) between 6-12 months and 29% (4) after 12 months. 85% of patients (12) chose to continue with Zoladex use. 85% of patients (12) who developed side effects reported menopausal symptoms; 3 of them (25%) were not on HRT. One patient (7%) developed osteopenia confirmed on DEXA scan.

14% of patients (2) developed hypertension and were started on antihypertensive medications. One patient developed severe hypertension followed by chest pain and admission to the hospital with subsequent diagnosis of stable angina.

Conclusions

Our data shows that prolonged use of GnRh analogues is effective in providing ongoing symptom relief to patients with chronic pelvic pain, menorrhagia and PMS. 66% of our patients did not report side effects. Most patients with side effects (85%) chose to continue taking Zoladex after counselling.

Our data also suggests a rather surprising increase in the percentage of women who developed serious side effects including hypertension, chest pain and angina (14%). Thorough counselling regarding possible side effects and regular blood pressure monitoring in women receiving GnRh analogues could reduce the risk of developing such serious complications

Ambulatory laparoscopic gynaecological surgery: 2019-2021 experience

Marta Campos¹, Marta Xavier¹, Inês Filipe Gouveia¹, Andrea Quintas¹, Sandra Baptista¹

¹Centro Hospitalar de Vila Nova de Gaia/Espinho, Department of Obstetrics and Gynecology, Vila Nova de Gaia, Portugal

Background

Outpatient gynaecological surgery has been developing in the last two decades, and the technological advances have been fundamental. Laparoscopic surgery has several advantages when compared with laparotomy such as faster recovery, smaller scars, lower risk of infection, decreased adhesion formation and less costs. This way, ambulatory laparoscopic surgery allows to admit, treat and discharge the patient in the same day, in a cost-effective and patient friendly way. This work describes our centre's 3-year experience in ambulatory laparoscopic gynaecological surgery.

Methods

This is a retrospective observational study where we analysed all patients who underwent laparoscopic gynaecological surgery in our ambulatory centre between January 1st 2019 and December 31st 2021.

Results

In our study, 101 patients were included with a mean age of 37 years. 57 women had previous medical conditions, in which the most frequently presented were depression (n=13), asthma (n=9), thyroid disease and chronic venous insufficiency (n=5). Previous abdominal surgeries were present in 52 patients, with caesarean section (n=29), cholecystectomy and appendectomy (n=7) being the most prevalent ones. The mean Body Mass Index was 26.9. The ASA Physical Status Classification System was applied with 31 women classified as ASA I and 70 ASA II. A total of 114 procedures were performed (72.8% tubal ligation, 8.8% salpingo-oophorectomy, 7% diagnostic laparoscopy and chromopertubation, 3.5% ovarian drilling and 0.9% cystectomy). In 2019 and 2020 the only procedure performed was tubal ligation. Indications for surgery were definitive contraception (72.8%), infertility (14%), Polycystic Ovarian Syndrome (3.5%), surgical castration and unilocular cyst (2.6%), unilocular tumour with mixed echogenicity (1.8%), multilocular cyst, multilocular-solid cyst and solid tumour (0.9%). Adhesiolysis was performed in 4% of the laparoscopic surgeries, all in patients with history of previous abdominal surgery. The mean time in recovery room was 4 hours and 56 minutes. No women needed hospitalization after surgery. Histological findings of adnexal surgery revealed normal or benign lesions.

Conclusions

The laparoscopic gynaecological surgery performed in our unit seems to be a cost-effective and a safe procedure, with different indications including sterilization, adnexal surgery, and infertility investigations. We think that outpatient surgery will grow even more, with careful patient selection and multidisciplinary approach.

Hysterectomy after endometrial ablation

Neeraja Kuruba¹, Medha Sule¹, Srividya Sundararajan¹

¹Norfolk and Norwich University Hospital, Gynaecology, Norwich, United Kingdom

Background

Our objective was to analyse the characteristics of cohort of patients who required hysterectomy after endometrial ablation to resolve their persistent symptoms and study the histology of the uteri for any abnormalities in the presence of high factors for endometrial cancer.

Methods

We collected retrospective data over 6year period (Jan2015 - Dec2020) from case notes of patients who underwent hysterectomy after previous ablation. Demographic data including age, parity and BMI and data for the indication of ablation, preoperative medical history for and investigations including ultrasound and endometrial biopsy were collected. The operative findings and the interval time between ablation and hysterectomy, indication for hysterectomy (pain or bleeding or both), route, operative findings at hysterectomy and histology of the specimen were noted.

Results

Our study included 73 patients with a median age of 46years (range 30-56). Average parity was 1.7 and BMI 30.33 with a range of 19-48. One had PCOS and 3 had diabetes.

The main indication for endometrial ablation was menorrhagia in 77% (56), menorrhagia and pelvic pain in 23% (17). 72 women had endometrial biopsy prior to endometrial ablation showing benign histology. Ultrasound prior to ablation showed heterogenous myometrium with fibroid changes in 12, one/multiple small intramural fibroids in 26 and possible adenomyosis in 7. Check hysteroscopy at the end of procedure confirmed global ablation in 78%(57) and partial ablation with fundal or cornual sparing in 22%(16). Indication for subsequent hysterectomy was menorrhagia in 36, postmenopausal bleeding in 11 and significant pelvic pain in 26.

The interval between ablation and hysterectomy was an average of 25months (range 5 to 53 months). Most hysterectomies were performed by a minimally invasive route. 73% (53) had total laparoscopic hysterectomy, 19% (14) had vaginal hysterectomy and only 8% (6) had abdominal hysterectomy due to size of the uterus. All but one patient had benign diagnoses. One patient had CGIN. Some patients had multiple benign conditions including endometriosis, adenomyosis and leiomyoma. Most common was fibroids in 32. 10 of them had associated endometriosis and 29 adenomyosis.

Conclusions

Endometrial ablation is a minimally invasive surgical approach to menorrhagia with good success rates. However, in a small cohort of patients adequate symptom relief is not achieved. There is an association between failed endometrial ablation and history of pelvic pain. Review of pathology specimen showed an association with adenomyosis, leiomyomas and endometriosis. Incomplete ablation is also associated with failed ablation requiring subsequent hysterectomy. This information should be used to counsel patients preoperatively regarding failure of the procedure to achieve desired outcome requiring subsequent hysterectomy. It is reassuring to note that histology of the subsequent uteri has not showed any sinister pathology despite risk factors, but it is challenging to reassure patients in the setting of inability to assess endometrium post ablation due to scarred cavity.

Treatment of pelvic organ prolapse with Laparoscopic sacrocolpopexy. Technique description and long-term outcomes comparing polypropylene mesh with polyvinylidene fluoride mesh.

Dimitrios Zygouris¹, Sofia Papadimitriou², Evgenia Stergiannakou¹, Andreas Kavallaris¹

¹St. Luke's hospital- Thessaloniki- Greece, Department of minimally invasive Gynecology-, Thessaloniki, Greece

²University Hospital of Ioannina- Ioannina- Greece., Department of Blood Transfusion-, Ioannina, Greece

Background

Our aim was to evaluate the feasibility and safety of laparoscopic sacrocolpopexy (LSCP) and compare the long-term outcomes and complication rates of polypropylene (PP) and polyvinylidene fluoride (PVDF), following up within a minimum of 12 months.

Methods

This was a retrospective cohort study using patients who underwent LSCP for POP involving either PP or PVDF mesh between January 2011 and January 2020.

Results

Our study focused on 223 women who underwent LSCP with mesh between January 2011 and January 2020. All procedures were successfully completed laparoscopically, and patients' baseline characteristics were not statistically different in the two groups. Between January 2011 and December 2014, we performed 82 cases of LSC, mainly using PP mesh. Over the last 7 years, since January 2015, we have used PVDF mesh for POP in 141 cases.

Conclusions

LSCP using PVDF mesh was found to provide excellent anatomical and functional outcomes after a median follow-up duration of 45 months, compared with the PP group, which had a median follow-up duration of 54 months. Mesh infection and erosion rates in the PP group were significantly higher than those in the PVDF group. Additionally, rates of vaginal pain and discomfort were significantly lower in the PVDF group when compared with the PP group.

Ectopic pregnancy's surgically-treated: changes in 10 years

*Alexandra Santos¹, Carlota Carvalhos¹, Dora Antunes², Maria João Carvalho³, Cristina Frutuoso¹,
Fernanda Águas¹*

¹*Centro Hospitalar e Universitário de Coimbra, Serviço de Ginecologia, Coimbra, Portugal*

²*Centro Hospitalar e Universitário de Coimbra- Faculdade de Medicina da Universidade de Coimbra,
Serviço de Ginecologia, Coimbra, Portugal*

³*Centro Hospitalar e Universitário de Coimbra- Clínica Universitária de Ginecologia da Faculdade de Medicina da
Universidade de Coimbra, Serviço de Ginecologia, Coimbra, Portugal*

Background

Ectopic pregnancy is one of the most common causes of acute surgical abdomen in gynaecology. The aim of this study was to evaluate changes in presentation and surgical approach of ectopic pregnancies treated in the last 10 years, with a five-years' interval analysis.

Methods

A retrospective and comparative analysis of the surgically treated ectopic pregnancies in our department was made, including the following years: 2011 (group 1), 2016 (group 2) and 2021 (group 3). SPSS v28 ($p < 0.05$) was used for statistical analysis. The sample was anonymized, and epidemiological, clinical and pathological data was collected.

Results

Our sample included 78 women (2011: $n=24$; 2016: $n=29$; 2021: $n=25$), with only one case of non-tuber pregnancy (interstitial).

The most frequent age group was from 20-29 years in 2011 (62.5%) and 2016 (72.4%) and from 30-39 years in 2021 (48%). Considering groups 1, 2 and 3, respectively, there were no differences regarding previous pregnancies (50% vs 27.6% vs 40%), nulliparity (66.7% vs 44.8% vs 56%), previous abdominal surgery status (25% vs 24.1% vs 32%) and existence of risk factors for ectopic pregnancy (20.8% vs 31% vs 12%). There was history of infertility in 17.9% of the patients. Previous abdominal surgeries had no influence on the surgical approach, postoperative complications.

In 2016 and 2021, at admission, most women reported exclusively pain (41.4% vs 48%) with 37.9% and 12% being asymptomatic ($p < 0.001$). In 2011, every patient reported symptoms, most frequently, abdominal pain plus other symptoms. The median β -HCG was higher in 2016 (8391+-11532 mUI/mL) and was >5000 mUI/mL in 8.3% vs 44.8% vs 48% of the cases (2011 vs 2016 vs 2021, $p < 0.05$).

Surgery was the first approach in most women in all three years (62.5% vs 79.3% vs 68%, $p=ns$). The use of laparoscopy has been increasing (75% vs 93.1% vs 100%, $p < 0.05$), influencing the median hospital-stay (laparotomy: 3.13+-1.126 days vs laparoscopy: 2.5+-3.278 days, $p < 0.001$). Its length in 2011 was longer than in 2016 and 2021 (3+-1.251 vs 2.14+-0.915 and 2.64+-5.338 days, $p < 0.05$) and post-operative complications' frequency had decreased ($n=10/24$ vs $n=3/29$ vs $n=1/25$, respectively, $p < 0.001$).

Haemoglobin value at admission was lower in 2011 (11.588+-1.363, $p < 0.05$) when compared to 2016 or 2021 (14.879+-2,485 and 12.944+-0.205), with no difference regarding the need for blood transfusion between the groups.

Conclusions

Laparoscopy has been increasingly used as a first-line approach whenever surgical treatment is needed, with a decrease in the length of hospital-stay. The frequency of short-term post-operative complications has decreased throughout the years.

Clinical profile and risk factors were similar, although presentation at admission is being less severe namely regarding symptoms, β -HCG and haemoglobin levels, emphasizing an earlier access to hospital care.

Ultrasound utero-cervical angle to predict difficult embryo transfer

Alessia Romito¹, Giulia Galati¹, Giulia Mattei¹, Ilenia La Barbiera¹, Chiara Di Tucci¹, Ludovico Muzii¹

¹Sapienza University of Rome, Obstetrics and Gynecology, Roma, Italy

Background

Infertility affects up to 15% of couples worldwide. Although in vitro fertilization (IVF) success has slowly increased in the last decades, the delivery rate is about 20%. Embryotransfer (ET) is one cause of suboptimal results, and even if it is an apparently simple procedure, it is still not fully understood. It is estimated that a poor technique is responsible for up to 30% of the IVF failure. While ET should be performed by ultrasound guidance and aim to release the embryo at least 1 cm from the fundus, there are no known parameters that evaluate a difficult ET. This study aimed to identify the pre-and intra-operative parameters to predict rugged ET and establish its relationship with pregnancy rate (PR) in patients undergoing assisted reproductive technology (ART).

Methods

In this prospective study, patient candidates for ET following IVF/ intracytoplasmic sperm injection (ICSI) were recruited. The main characteristics of the patients were collected (age, body mass index, infertility cause, stimulation protocol). ET was performed with the use of transabdominal ultrasound guidance; different parameters were collected: the anatomical features (longitudinal, anteroposterior, and transverse uterus diameter), uterus version, grade of bladder distension, and utero-cervical angle (defined as the angle between two lines; the first line join the external and internal cervical orifice and the second line join the internal cervical orifice and uterine fundus). We divided patients into two groups based on the angle: low degree ($<45^\circ$) or high degree ($\geq 45^\circ$). ET was defined into two categories (easy or difficult) based on the need for additional manoeuvres. A pregnancy test was performed 15 days after the transfer.

Results

In total, we enrolled 52 women; the mean age was thirty-seven years old; above all, thirty-one (75%) had normal weight; forty-five (86%) had primary infertility, the majority with ovulatory dysfunction (44%). Difficult ET was described in 16 of 52 procedures (30%); only one was retroverted compared to the anteverted uterus (6% vs 43% $p: 0.006$). Easy ET was performed on 28 women (87%) versus four (40%) with low and high degrees, respectively. ($p < 0.001$). No difference was found between groups for other variables. The pregnancy rate was similar between groups.

Conclusions

Utero-cervical angle could be a promising marker of difficult ET, although the sample size is small to draw conclusion. More studies are necessary to confirm this result.

Introducing minimal invasive endoscopy in breast surgery: feasibility study of a Mammoscope

Anna Solomianik¹, Riek Siegfried², Bernhard Krämer¹, Selin Gürçan¹, Dominik Dannehl¹, Markus Hahn¹

¹University Clinic Tübingen, Department of Woman's Health, Tübingen, Germany

²Partomed research GbR, partomed research GbR, Villingendorf, Germany

Background

Operations on the mammary gland are of the most often preformed procedures in gynecology. In this field, both benign and malignant tissue extractions are nowadays still prominently conservatively performed. Recent studies indicate that de-escalation in this field using endoscopic techniques is possible and offers better cosmetic results especially for the small breasted. This study describes the development of a surgical endoscope exclusively designed for the breast. The Mammoscope is a single operator, handheld and resources-saving product. It is designed to enable endoscopic cavum formation using insufflation. This consequentially allowing tissue preparation and tumour extraction from the breast.

Methods

Between 01/2020 – 11/2021 the Mammoscope was examined and tested in a preclinical setting. The main tasks of this project were:

1. Development of suiting simulation models, 2. through the process of rapid prototyping and through close contact with the medical engineering optimization and revision of the instruments' prototypes.

Results

1. to achieve a suitable simulation model following points were brought into consideration –

a. The breast gland is special in its texture, varying in density and stiffness through the woman's life. A model needed to be found that reflects both evolved fatty tissue and young gland tissue. b. Models needed to be cost effective, replicable, and accessible. c. The model needed to show an anatomical correlation to the human body or at least enable the simulation of following aspects – insufflation and tissue integrity, consistency of warm tissue and ideally – circulation. The most suitable models were a. bovine and porcine muscles (tongue) b. freshly deceased young pig and final experiment on mother pig c. body donor.

2. The Mammoscope was tested in a simulated operating setting. Through the experiments, valuable knowledge has been gained regarding the optimal function of the Mammoscope. This knowledge directly translated in continuous improvements in the models. The Main changes in Models 1-2 were focused on ergonomics and handheld operating. The following model 3, by showing a better overall structure, switched the focus to the improvement of instrument capabilities and thermo-coagulation. Model 4 presents the final structure, allowing easy performance of all necessary operating steps.

The Mammoscope distanced itself from market products and the mentioned literature through its patented nose, suitable for the early creation of the cavum and through a specially designed optic. **Conclusions**

Through recurring successes in the simulated operating model, we could assume, that the Mammoscope allows the experimental surgeon the possibility of endoscopic surgery in the mammary gland. Clinical trials that ensure the safety of the endoscope in humans have to follow.

Management of pelvic inflammatory disease resulting in tubo-ovarian abscess

Amena Shelleh¹, Gedeon Lemma¹, Natalia Olejniczak¹, Mona Zanaty¹

¹Northern Care Alliance NHS Group, Obstetrics & Gynaecology, Oldham, United Kingdom

Background

Pelvic inflammatory disease (PID) results from an ascending infection and if left untreated, can lead to the formation of a tubo-ovarian abscess (TOA) which is associated with high morbidity and mortality. The diagnosis of TOA is heavily reliant on radiological findings and imaging is also very important in the management of TOA: this audit is to establish criteria to identify suitable patients for image-guided drainage by our local interventional radiology department rather than opting for surgical intervention.

Methods

Using a sample size of thirty patients who have a diagnosis of TOA based on ultrasound imaging as well as clinical and laboratory findings, medical notes and imaging were analysed. Statistical analysis was used to determine which imaging features were linked to positive outcomes with interventional radiology image-guided drainage of TOA, and which imaging features were better managed with surgical intervention.

Results

Results have shown better outcomes associated with interventional radiology image-guided drainage of TOA if the TOA is less than 5cm, whereas TOA size greater than 5cm are better managed with surgical intervention.

Conclusions

The findings of this audit have helped to establish criteria to identify suitable patients for image-guided drainage by our local interventional radiology department rather than surgical intervention, which is a less invasive method of management and is associated with reduced complications.

Evaluation of Assisted Reality Smart glasses Enabled Learning In Surgical Education

Shreya Kulkarni¹, Sule Medha¹, Neeraja Kuruba¹, Milind Kulkarni¹

¹Norfolk and Norwich University Hospital, Gynaecology, Norfolk, United Kingdom

Background

To evaluate trainee experience with the use of smart glasses in simulation training of laparoscopic ectopic pregnancy and laparoscopic suturing.

Methods

Simulation training was organised at Norfolk and Norwich university hospital, UK for a group of 10 trainees at different levels of training ranging from year 1 – 7 of gynaecology training. Smart glasses were used to remotely supervise the training of skills on animal model simulator for laparoscopic salpingectomy for ectopic and laparoscopic suturing on box trainer. Detailed feedback on each skill and overall satisfaction rates were obtained at the end of training day.

Results

Satisfaction scores were collected on a scale of 1-7 in the areas of psychomotor skills, communication, NOTTS, technical issues and feedback for laparoscopic salpingectomy and laparoscopic suturing skills stations. Feedback scores were also collected in the areas of Reduced Instructional Material Motivation Survey (RIMMS) and overall satisfaction. The mean score for psychomotor skills was 6.5 (1=completely disagree, 7=completely agree as a useful aid and easy to follow to perform the task); communication mean score was 6.6 (1= completely disagree, 7=completely agree useful in two-way communication); mean score for technical issues was 5.9 (1=completely disagree and 7=completely agree could hear and show the area of interest to trainer).

RIMMS mean scores were 6(1=completely disagree and 7=completely agree immersed in task while using smart glass system); 6.3 (1=completely disagree and 7=completely agree felt a feeling of trainer presence) and 6.3 (1=completely disagree and 7=completely agree enjoyed using smart glass system).

The overall mean satisfaction scores were 6.32 (1=not satisfied and 7=completely satisfied).

Conclusions

Surgical training is becoming increasingly difficult with reduction in training hours and is further negatively affected by COVID-19 Pandemic. Delivery of surgical training will need to move away from traditional models of face-to-face simulation training to more innovative methods of remote teaching. Trainees and trainers' confidence in transition from indirect to direct supervision is a key factor to achieve competence in surgical skills in real life. Smart glasses help in surgical training of the trainees by remotely supervising them and ensuring they are practising the skills on simulator correctly and achieving competence. Our feedback scores give a positive experience from all the level of trainees indicating that it would have a significant role in the future surgical training armamentarium

Comparison of general anaesthesia and combined spinal and epidural anaesthesia for gasless laparoscopic surgery in gynaecologic field

Jong Ha Hwang¹, Bo Wook Kim¹

¹International St. Mary's Hospital- Catholic Kwandong University College of Medicine, Obstetrics and Gynecology, Incheon, Korea- Republic Of

Background

Laparoscopic surgeries in gynaecologic field have been performed under general anaesthesia (GA) due to the respiratory changes caused by pneumoperitoneum and Trendelenburg position. Therefore, this study aimed to compare general anaesthesia and combined spinal and epidural anaesthesia (CSEA) for gasless laparoscopic surgery in gynaecologic field.

Methods

We matched patients with type of surgery who underwent gasless single port access (SPA) laparoscopic surgery under general anaesthesia and CSEA. The medical records of 90 patients between March 2018 and June 2020 were reviewed. Gasless laparoscopic surgery was performed in all patients with a SPA using a J-shaped retractor.

Results

No significant differences were observed for age, body mass index, parity, and previous abdominal surgery between GA and CSEA group. During operation under CSEA, six patients (20%) experienced nausea/vomiting. Hypotension (systolic blood pressure < 90 mmHg) was observed in five patients (16.7 %). Intravenous analgesics was administrated in four of the patients (13.3 %) who suffered from shoulder pain or abdominal discomfort. One patient developed bradycardia. The duration of hospital admission was shorter in the CSEA group than in the GA group (p value = 0.014). There was no difference between the groups in terms of surgery type, surgical specific finding, operation time, estimated blood loss, laparotomy conversion rate and use of additional trocar. No major complications such as urologic, bowel, or vessel injuries were found in both groups.

Conclusions

CSEA is a safe and feasible technique for application in non-obese patients undergoing gasless laparoscopic surgery in gynaecologic field.

The 10-year Recurrence Pattern of Mature Cystic Teratoma in Young Women

Sung Eun Kim¹, Park Chan-Hong¹, Lee Dong-Yun¹, Choi DooSeok¹

¹Samsung Medical Center, Obstetrics and Gynecology, Seoul, Korea- Republic Of

Background

Mature cystic teratoma (MCT) is the most common ovarian tumour. Although the treatment of MCT is surgery, recurrence may occur and there is no preventive method. In case of recurrence, ovarian damage caused by surgery cannot be avoided, so those who want to become pregnant should be careful. There are not many studies on MCT recurrence, and the follow-up period is different, and the age range varies from puberty to menopause, so it is not appropriate for counselling in young patients. Therefore, we conducted a study to predict the recurrence rate of MCT in young patients for long period.

Methods

This study was a retrospective cohort study with patients aged 10 to 29 years who underwent their first ovarian surgery between January 2000 and November 2018. These patients were diagnosed with MCT and without lesions suspected of recurrence on imaging within one year after surgery. Exclusion criteria was (1) no imaging test performed for more than 1 year after surgery, (2) presence of other benign pathology, and (3) presence of malignancy.

Patient's information was obtained through a medical chart review. Recurrence was defined as a case in which there was no lesion in the imaging for one year after surgery, and MCT was observed twice or more in the subsequent imaging test.

Results

A total of 442 patients were enrolled. Among them, 372 (84.2%) underwent laparoscopy and 70 (15.8%) underwent laparotomy. In the cystectomy group, recurrences were 44 instances and frequent when the tumour was large ($P = 0.0020$), when the tumour was bilateral ($P = 0.0013$), when CA19-9 level was high ($P = 0.0224$), when the patient was young at the time of surgery ($P = 0.0020$), or when laparotomy was performed ($P = 0.0010$). Seventeen cases of recurrences were reported during the follow-up period in the oophorectomy group. There were no statistically significant differences in baseline characteristics between patients with and without recurrence after oophorectomy.

The 10-year cumulative recurrence rate was 38.7% (95% CI: 25.3%–52.1%) in the cystectomy group and 38.2% (95% CI: 21.5%–54.8%) in the oophorectomy group (Figure 1).

Large tumour size (> 14 cm) (HR: 2.59; 95% CI: 1.11–6.08; $P = 0.03$) and bilateral tumour (HR: 2.65; 95% CI: 1.27–5.52; $P < 0.01$) were significant risk factor for recurrence.

Conclusions

The 10-year cumulative recurrence rate after surgery in young women with ovarian MCT was 38.7% in the cystectomy group and 38.2% in the oophorectomy group, and risk factors for recurrence after cystectomy were large tumour size and bilaterality.

A retrospective single-centre analysis of the 1000 gynaecologic robotic-assisted laparoscopic surgery cases

A Jin Lee¹, Eunbi Jang¹, Kyeong A So¹, Sun Joo Lee¹, Tae Jin Kim¹, Seung-Hyuk Shim¹

¹Konkuk University School of Medicine, Department of Obstetrics and Gynecology, Seoul, Korea- Republic Of

Background

This study reports the 1000 gynaecologic robotic surgery cases using Da Vinci Xi System, and includes cases of hysterectomy, adnexectomy, ovarian cystectomy, myomectomy.

Methods

This study evaluates patients undergoing robotic-assisted laparoscopic gynaecology surgeries (Da Vinci Xi Surgical System) done from December 2017 to February 2022. We retrospectively evaluated surgical outcome including estimated blood loss (EBL), operative time, postoperative complications.

Results

A total of 1000 patients with a variety of gynaecologic disease underwent robotic-assisted laparoscopic surgery, including 326 hysterectomies, 380 adnexectomies including ovarian cystectomies, 294 myomectomies. The median age was 45 years old (range: 18–72). The median EBL was 100ml (range: 80–220) and operation time (skin incision to skin closing) was 145 minutes. There were postoperative complications in 11 (3.5%), 4 (1.2%) and 6 (2.2%) patients in the hysterectomy group, adnexectomy group and myomectomy group, respectively. There were 13 cases only, conversion to laparotomy, and conversion to laparoscopy.

Conclusions

Robot-assisted laparoscopic surgery is an effective gynaecological surgical procedure with minimal bleeding and few postoperative complications. The outcome of many of these cases might help in choosing robotic surgery in gynaecological surgery.

Assessing the success of day-case hysterectomy and developing a standard procedure for implementation at a district general hospital

Kathryn Champion¹, Rozina Mughal¹, Iain Cameron¹

¹Queen Elizabeth Hospital, Obstetrics and Gynaecology, Gateshead- Newcastle upon Tyne, United Kingdom

Background

Day-case hysterectomies could lead to improved patient outcomes and are associated with quicker and more comfortable recovery, higher patient satisfaction and significant savings for hospital trusts. We sought to evaluate the safety and success of day-case hysterectomies performed at a district general hospital when compared to inpatient procedures and estimate how many patient stays could have been prevented.

Methods

This was a retrospective study, which examined 97 hysterectomies (only inclusive of total laparoscopic hysterectomy and laparoscopically assisted vaginal hysterectomy), performed between January 2019 and December 2020. We then created a guideline and patient literature which are to be used in the future as standard procedure for implementation within the trust.

Results

Of the 97 hysterectomies performed, 81 were inpatient procedures. 16 were day-case hysterectomies, 7 of which were planned, and 9 of which were unplanned. All planned day case procedures were discharged the same day. 1 woman (6.25%) was re-admitted on day 2 post-operatively due to abdominal pain, distension and shortness of breath for investigation for pulmonary embolism. 1 woman re-attended on day 15 and was found to have a UTI but was not admitted. When considering how many hospital stays could have been prevented, we used the criteria that we will use for patient selection in the future. This included BMI <40, ASA 1 or 2, and residing within 1 hour of the hospital so they could return if complications occurred. 53 (65.4%) patients out of the total of 81 inpatient hysterectomies fit our criteria and retrospectively could have been appropriate for day case hysterectomies. When an estimated unsuccessful same day discharge rate of 10% was applied, this potentially could have reduced overnight admissions by around 48 nights.

Conclusions

Same day discharge is a successful and safe option for patients of a specific criteria, undergoing total laparoscopic hysterectomy or laparoscopically assisted vaginal hysterectomy.

Safe surgical approach to ovarian neoplasms/ teratomas

Waldir Modotti¹, Rafaela Assmann¹, Larissa Marques¹, Camila Romero¹, Flavia Bueloni-Dias², Daniel Dias²

¹*IAM - Atendimento Médico Hospitalar, Gynecology, Assis, Brazil*

²*Universidade Estadual Paulista "Júlio de Mesquita Filho" - Unesp, Gynecology and Obstetrics, Botucatu, Brazil*

Background

To demonstrate the surgical technique for minimally invasive ovarian teratoma excision.

Methods

Laparoscopy is considered the gold standard for the treatment of ovarian neoplasms. It's less aggressive and allows the preservation of ovarian tissue when only resection of the cystic lesion is performed, separating it from the walls of the ovary. However, laparoscopic cystectomy carries a higher risk of accidental rupture of the cyst. In order to avoid complications resulting from rupture or leakage of the cyst content, the endobag is used to remove the teratoma from the abdominal cavity.

After performing the pneumoperitoneum by using a Veress needle at the Palmer point, the zero-degree optic is introduced through the 10 mm trocar inserted in the umbilical scar. Three accessory trocars are placed in the following locations: right iliac fossa, suprapubic region, and left iliac fossa.

With access to the abdominal cavity, the resection of the cystic lesion is performed, preserving the ovarian parenchyma. The cyst is placed in the endobag, which allows it to be removed from the abdominal cavity.

Results

Laparoscopic cystectomy for teratoma treatment performed safely, using an endobag to remove an ovarian teratoma without rupture or spillage.

Conclusions

Laparoscopic cystectomy is the gold standard for the management of ovarian neoplasms. The use of an endobag to remove the surgical specimen increases the safety of the method and avoids rupture and extravasation of the cyst content and, consequently, the complications subsequent to these accidents.

Hysteroscopic resection of FIGO stage 1a endometrial cancer; an alternative approach for medically unfit patients.

Charlie Cutler¹, Kyle Fleischer¹

¹St Richard's Hospital, Obstetrics and Gynaecology, Chichester, United Kingdom

Background

Endometrial cancer is the 6th most common malignant disease worldwide and the most common gynaecological malignancy in high-income countries. Current treatment of endometrial cancer involves surgery, radiotherapy, chemotherapy, or hormonal therapy, normally in combination to maximise chance of cure. Surgery remains the primary method of treatment and staging, usually a total abdominal hysterectomy and bilateral salpingo-oophorectomy (BSO) +/- sentinel lymph node biopsy, with lymphadenectomy reserved for patients deemed to be high risk. For medically inoperable patients, uterine brachytherapy, and external beam radiotherapy (EBRT) can achieve cure rates of over 70%. In patients unsuitable for brachytherapy or EBRT, high dose progestins may be used.

Methods

We present an alternative approach to a medically inoperable patient with FIGO stage 1a endometrial cancer; treatment of disease with hysteroscopic resection. The majority of preliminary studies investigating hysteroscopic management of endometrial cancer focuses on fertility preservation. In our patient, fertility was not a concern, but she was deemed an unsafe candidate for surgery. Our case is a 63-year-old obese woman with a background of severe chronic obstructive pulmonary disease on home oxygen therapy, hypertension, and obstructive sleep apnea. She underwent hysteroscopic resection and insertion of a Mirena coil for her stage 1a endometrial cancer.

Results

The patient was followed up with six-monthly, then yearly hysteroscopies and remained clear of disease four years following diagnosis. She reported minimal side effects from her treatments.

Conclusions

This case report demonstrates a potentially safe alternative management option in patients with FIGO stage 1a endometrial cancer that are medically unfit for major surgery.

ePOSTERS

ES31-0003 - P041

Impact of surgeon experience, patient age, and BMI on length of stay following Total Laparoscopic Hysterectomy– a review of 574 cases from a UK centre

Anjali Mehta¹, Susan Addley², Lotte Weenink², Victoria Cullimore², Subul Bazmi², Summi Abdul²

¹*The University of Nottingham, School of Medicine, Nottingham, United Kingdom*

²*University Hospitals of Derby and Burton NHS Trust, Department of Gynaecological-Oncology, Derby, United Kingdom*

Background

Evaluate the trend in post-operative length of stay following Total Laparoscopic Hysterectomy (TLH) over time and identify peri-operative factors significantly impacting this parameter.

Methods

This is a retrospective study design carried out at a tertiary gynaecological cancer centre in the UK. It looks at all patients who underwent TLH for endometrial cancer under the care of a single surgeon between 2008 and 2020. The surgeon who completed the most TLH procedures was selected, and his cohort of patients was retrospectively reviewed. Clinical and operative details were extracted from Lorenzo and ORMIS patient e-casenote systems. Data was collected on patient age, body mass index (BMI) and total in-patient length of stay (LOS) following TLH. Data is presented as means, percentages and univariate analysis performed to determine significance – setting $p < 0.05$.

Results

N = 574. Between 2008 and 2020, mean LOS following TLH decreased from 56 to 34 hours. Patients aged ≤ 50 on average stayed in hospital for a significantly $p = 0.001$ shorter time (33.8 hours) compared to those over 50 (46.1 hours). Patients with a BMI < 24.9 had a significantly $p = 0.025$ shorter LOS compared to those with a higher BMI (33.6 hours versus 44.7 hours)

Conclusions

Decrease in post-operative LOS following TLH over a 12-year period is likely a reflection of the learning curve associated with minimal access surgery – and the result of increasing operator experience. Whilst laparoscopic surgery is accepted as generally conferring shorter LOS in comparison with a traditional open approach across all patient populations, our data would suggest that women ≤ 50 years with normal BMI benefit most from adopting a laparoscopic route. This is an important point for patient counselling, theatre list and bed planning, and even patient selection in centres offering day case TLH.

The Diagnostic Value of Outpatient Flexible Sigmoidoscopy in Patients with Deep Infiltrating Endometriosis

Thomas Sewell¹, Melanie Orchard², Oliver O'Donovan³, Robert Longman²

¹*Bristol Royal infirmary, Obstetrics and Gynaecology, Bristol, United Kingdom*

²*Bristol Royal Infirmary, Colorectal Surgery, Bristol, United Kingdom*

³*Bristol Royal infirmary, Gynaecology, Bristol, United Kingdom*

Background

Endometriosis encompasses three main clinical variants which often overlap; superficial endometriosis, ovarian endometriosis (endometrioma) and deep infiltrating endometriosis (DE). DE may be defined as endometriosis where the lesions extend 5mm or more below the peritoneal surface. DE affects 10-20% of women with endometriosis and is a severe form of endometriosis which can significantly impact a patient's quality of life. 90% of DE is rectovaginal and when suspected, some clinicians have suggested the routine use of flexible sigmoidoscopy to identify the presence of intraluminal disease. To date, few studies have investigated the value of this. We aimed to assess the diagnostic value of outpatient flexible sigmoidoscopy prior to surgery for rectovaginal DE.

Methods

A retrospective observational study was performed from a consecutive cohort of patients referred for outpatient flexible sigmoidoscopy prior to planned surgery for rectovaginal DE. All patients were under the care of a specialist endometriosis multidisciplinary team and patients were identified from the team's endometriosis database. The inclusion criteria were all patients who underwent sigmoidoscopy prior to planned surgery for confirmed or suspected rectovaginal DE within a 10-year time period (January 2010 – January 2020). Data collection involved review of the case notes and internal hospital electronic medical records for all procedures performed over the study period. The primary outcome measure was the incidence of luminal disease. Secondary outcome measures were other pathology found during flexible sigmoidoscopy, technical feasibility and complications.

Results

102 consecutive cases were analysed with no cases confirming intraluminal disease. Non-specific evidence of endometriosis such as tight angulation of the bowel was found in 36.3%. The procedure was completed satisfactorily in 95 (93.1%) of women. There were no complications from the sigmoidoscopy procedures although 44.3% of patients reported moderate or significant discomfort. Following sigmoidoscopy 100 patients proceeded to surgery and the overall risk of direct bowel surgery was 11% with 4% requiring bowel resection.

Conclusions

Due to the low incidence of luminal endometriosis, performing sigmoidoscopy routinely is likely to be of limited benefit and does not aid patient counselling in the majority of cases.

We would recommend the selective use of sigmoidoscopy where colorectal neoplasia is considered or where endoscopic assessment is deemed appropriate for determining the location of suspected luminal endometriosis and subsequent resectional surgery planning.

Sigmoid Endometriosis Dressed up like Adenocarcinoma with Lymphatic Invasion

Ana Ribeiro¹, Hélder Ferreira²

¹*Centro Hospitalar do Baixo Vouga, Obstetrics and Gynecology, Aveiro, Portugal*

²*Centro Hospitalar Universitário do Porto, Minimally Invasive Gynecological Surgery Unit, Porto, Portugal*

Background

Intestinal endometriosis is found in 12% of women with endometriosis and is the most common extra-pelvic site. Although rectosigmoid is most common site contributing to 72% of intestinal endometriosis, the mucosal and lymph node involvement is rare and differential diagnosis from colon cancer may be difficult. Despite this, endometriosis causing intestinal obstruction is extremely rare with reported incidence between 0.1–0.7%.

Methods

A 40-year-old female who had a seven-day history of abdominal pain, fecaloid vomiting and absolute constipation presented to the emergency department. She had a distended, tense abdomen and her rectum examination revealed extrinsic compression in the anterior wall. Abdominal CT demonstrated stenosing segmental circumferential lesion in the sigmoid with 4 cm causing obstruction and marked dilation upstream of the sigmoid and the entire large bowel. Emergency laparotomy revealed a sigmoid tumour causing intestinal obstruction with no evidence of distant metastasis. Total colectomy with ileorectal anastomosis was performed. Histology presented a well-differentiated sigmoid colon adenocarcinoma with ganglionic metastasis in 4 of 50 lymph nodes examined. Six months later her CT revealed pelvic ascites and suspected peritoneal carcinomatosis. The ascitic fluid analysis didn't identify malignant cells and PET-FDG had no clear evidence of focal lesions suggesting metastasis. We decided a histological exam review and the final diagnosis came up: endometriosis with lymphatic involvement. Last pelvic MRI was stable and describes a frozen pelvis with concordant findings with deep pelvic endometriosis.

Results

Endometriosis is a challenging disease which is found in 6-10% of women in reproductive age. Bowels are the most common site of extra pelvic endometriosis affecting 3.8-37% of women with the disease. The most common sites are sigmoid colon and rectum followed by the ileum, appendix, and cecum. The symptoms of intestinal endometriosis vary according to the site of involvement, with most patients with intestinal endometriosis being asymptomatic. Rectosigmoid endometriosis can cause alterations in bowel habit and bleeding. Colonic endometriosis may manifest as an acute abdomen resulting from perforation and deeper lesions may present with bowel obstructions. Diagnosis of intestinal endometriosis is a challenge because of the non-specific clinical presentation and radiological appearance that can be confused with irritable bowel syndrome, inflammatory bowel disease, colitis, diverticular disease, or neoplasm. Laparoscopy with histological confirmation of endometriosis is the gold standard test for diagnosis of endometriosis.

Conclusions

Our case demonstrates the possible severity of the presentation of endometriosis, making it liable to be confused with a neoplasm. Our patient represents a case of symptomatic gastrointestinal endometriosis with mucosal involvement, without a previous history of pelvic endometriosis. Endometriosis causing large bowel obstruction is extremely rare and poses diagnostic challenge. In conclusion, endometriosis as a diagnosis should be considered in any young woman with symptoms from the lower gastrointestinal tract.

Validation of a laparoscopic myomectomy simulation model

Julie Vermeer¹, Deanna Buitenhuis¹, Erwin Karreman², Justin Mui¹, Tin Yan Tina Ngan¹, Darrien Rattray¹

¹*University of Saskatchewan, Obstetrics and Gynecology, Regina, Canada*

²*Saskatchewan Health Authority, Research Department, Regina, Canada*

Background

Simulation training is an integral part of medical education. It provides learners a low stakes opportunity to develop skills, receive feedback and debrief. The development and acquisition of surgical skills is well suited to simulation. This work initiates the validation of a laparoscopic myomectomy simulation model for Obstetrics and Gynaecology residents to improve their laparoscopic skills and learn the steps of a laparoscopic myomectomy.

Methods

A fibroid uterus model was created using beef roast, cow tongue, and pig fallopian tubes. Obstetrics and Gynaecology residents completed the simulation on three occasions: pre-intervention, with expert coaching and post-intervention. The pre-intervention simulation was recorded. Participants then watched a surgical video on how to complete a laparoscopic myomectomy and completed the simulation a second time with coaching from an experienced laparoscopic surgeon. One week later, they were recorded while completing the post-intervention simulation. Pre- and post-intervention participant videos were reviewed by two experienced laparoscopic surgeons using three assessment tools: 1) the Global Operative Assessment of Laparoscopic Skills tool 2) a validated scoring rubric for laparoscopic suturing, and 3) a novel scoring rubric to assess familiarity with the steps of laparoscopic myomectomy. Interrater reliability was assessed.

Results

Residents at all levels improved from pre- to post-intervention. The largest improvement across all levels was with the familiarity with steps of myomectomy. The average post-intervention score for junior residents was higher than the pre-intervention score for senior residents. Participants demonstrating the greatest improvement from pre- to post-intervention were residents who had performed <60 laparoscopic cases as the primary surgeon highlighting that this model allows less experienced residents to build foundational laparoscopic skills. Interrater reliability pre- and post-intervention was excellent.

Conclusions

Preliminary results are encouraging and support our intervention as valid simulation model for completing a laparoscopic myomectomy. The results reinforce the value of laparoscopic simulation training combined with expert coaching to elevate surgical skills amongst trainees.

The honey study: a randomized controlled trial comparing Medical Grade Honey versus fluconazole in the treatment of recurrent vulvovaginal candidiasis

Senna van Riel¹, Celine Lardenoije², Niels Cremers³, Martine Wassen¹

¹Zuyderland Medical Centre, Gynaecology and Obstetrics, Heerlen, The Netherlands

²Maastricht University Medical Centre, Gynaecology and Obstetrics, Maastricht, The Netherlands

³Triticum Exploitatie B.V., Research, Maastricht, The Netherlands

Background

Recurrent vulvovaginal candidiasis (RVVC) affects up to 9% of women worldwide. This amount is expected to increase due to lifestyle changes, increased fungal resistance and biofilm formation. Treatment options are limited and in 57% of the cases relapses occur within 12 months after starting fluconazole therapy, which is the current golden standard. The pathogenesis of RVVC is multifactorial and includes fungal biology, the vaginal microenvironment, and the immune system. Fluconazole is antimicrobial and thereby effective in inducing remission, but a long-term cure is hard to achieve and maintain. Medical grade honey (MGH) has antimicrobial, protective, anti-oxidative and immunomodulatory activity and may therefore be a good alternative treatment, especially in long-term remission. Previous studies with MGH did not show any clinical significant side-effects. MGH is therefore considered a safe medical product which has great potential as an alternative treatment for fluconazole in RVVC. This RCT aims to investigate the clinical cure rate and long-term efficacy of MGH compared to fluconazole in patients with RVVC.

Methods

A multi-centre randomized controlled trial (Zuyderland Medical Centre and Maastricht University Medical Centre+) comparing the efficacy of an MGH formulation (L-Mesitran) and fluconazole will be performed in 252 patients with RVVC. The primary objective is to investigate the mycological cure rate after one month via a vaginal culture. Secondary objectives are to investigate the clinical cure rate regarding symptoms. In addition, the prophylactic activity after six months maintenance therapy and the number of relapses within 12 months will be analysed for long-term efficacy. Moreover, information about side effects, discomfort, and quality of life will be collected with the use of questionnaires.

Results

We postulate that MGH in addition to its antifungal activity will modulate the vaginal microenvironment by its anti-inflammatory, antioxidative and immunomodulatory properties. It subsequently decreases symptoms and the number of relapses compared to fluconazole which has, according to current literature, strong antifungal activity, but is less effective in preventing relapses.

Conclusions

MGH has the potential to resolve candidiasis and decrease the number of relapses. Since there is no effective alternative treatment for fluconazole, this study may have a significant impact and improve the quality of life of women suffering from RVVC.

Using house-hold items to create low-cost simulation models for practicing laparoscopic skills

Ayesha Mahmud¹, Arzoo Amin²

¹*University Hospitals of North Midlands, Obstetrics & Gynaecology, Birmingham, United Kingdom*

²*East Surrey Hospital, Obstetrics & Gynaecology, London, United Kingdom*

Background

The emergence of the (COVID-19) pandemic has had an overwhelming impact on surgical training with cancelled operating lists and a shifting focus towards running essential services. Although, these changes have resulted in a trend towards eLearning and virtual platforms as never before, yet trainees find themselves at a loss. The lost opportunity for hands-on training threatens surgical-skill decay, placing trainees at a significant disadvantage compared to their predecessors.

Simulation training has shown to be effective in preventing decay and is recognized as a method for teaching novice learners' new technical skills. Minimal invasive surgery in gynaecology requires competence in key procedures such as laparoscopic hysterectomy. The core skills required to achieve such competence are psychomotor skills, visual-spatial skills, and cognitive skills. Homemade low-cost simulation models can be used to develop these skills.

Methods

We share our experience of using household items to create a variety of Easy Low-cost SIMulation (ELSIM) models for laparoscopic hysterectomy training. The models required common materials easily available at home, such as kitchen sponges, toilet roll cylinders, plastic pipes, modelling clay, fruits, and clothing items, etc. to simulate the vaginal vault, tissue dissection planes, and colpotomy models.

Results

In our experience household items not only allow for readily available practice exercises but also encourage creativity. Overall, the cost of our models is minimal, allowing for easy replication and a readily available substitute for commercially available more expensive models.

Conclusions

The COVID-19 pandemic has undoubtedly put trainees at risk of surgical-skill decay. However, using low-cost household models for surgical exercises focused on developing the psychomotor, visual-spatial, and cognitive skills central to surgical performance could help prevent surgical-skill decay.

laparoscopic repair of incarcerated diaphragmatic hernia during first trimester pregnancy.

Eleni Karatrasoglou¹, Aiki Tserkezoglou¹, Konstantinos Stamou², Vasiliki Chatzirafail¹

¹Euroclinic Hospital, Department of Gynecologic Surgery, Athens, Greece

²Mitera Hospital, Department of General Surgery, Athens, Greece

Background

we present the case of a female patient who suffered a bowel obstruction when the transverse colon became incarcerated in the diaphragmatic hernia. the patient was at the first trimester of pregnancy.

Methods

Case report

Results

A 34-year-old patient, at the second trimester of pregnancy arrived at the hospital complaining of abdominal pain and vomiting. The patient had a prior history of laparoscopic cholecystectomy, laparoscopic gastric banding, and removal but no history of known abdominal trauma. an obstetrical and abdominal ultrasound was performed with no specific finding. Due to the clinical deterioration of the patient an exploratory laparoscopy was decided. The abdominal cavity was surgically involved with laparoscopy and a diaphragmatic defect of 2cm was found, through which part of colon was herniated to the thorax. The part of bowel was gently removed of thorax and diaphragm was directly repaired without graft. No chest tube was placed. No resection and colon anastomosis were performed as the bowel had no signs of ischemia. Postoperative course was uneventful, and the patient was discharged 5 days after surgery. The woman is currently at the third trimester of pregnancy.

Conclusions

Herniation of abdominal contents through the diaphragm has been described for a variety of diaphragmatic defects and may be secondary to diaphragmatic injury, either traumatic or iatrogenic. It is rather uncommon the strangulation of colon and small bowel through a rent in diaphragm without any history of abdominal trauma. Clinical symptoms can be rather deceiving, especially in cases of pregnancy.

Real-time augmented reality in gynaecologic malignancies. on the verge of creating new software to automatically stage carcinomatosis. spotting cancer with a single look?

Eleni Karatrasoglou^{1,2}, Adrien Bartol³, Michel Canis¹, Nicolas Bourdel¹

¹University Hospital of Clermont-Ferrand, Department of Gynecologic Surgery, Clermont-Ferrand, France

²University of Athens, Department of Medical School, Athens, Greece

³University of Clermont-Auvergne, Department of Computer Science, Clermont-Ferrand, France

Background

We aim to create a real time augmented reality classification system for gynaecological malignancies, both in early and advanced disease. We focus on the creation of a software which can provide the endoscopic surgeon with an automatic detection of the localization and size of malignant lesions inside the abdominal cavity.

Methods

Clinical research. Annotation of frames/pictures of anonymous patients who underwent exploratory laparoscopy to diagnose the extensiveness of advanced gynaecologic malignancies.

Results

Augmented reality is a new approach in executing detailed surgical operations. During the preoperative phase most surgeons have a mental image of where the target lesion is and plan the route of exposure. Marking structures of interest on radiographic images that can be superimposed on live video camera images allow the surgeon to simultaneously visualize the surgical site as well as the overlaid graphic images, creating a so-called semi-immersive environment; this term is synonymous to augmented reality (ar).

During the last years we have accomplished real-time imaging in benign diseases of uterus (uterine myomas), so we have paved the way for further usage of this software to the field of oncology. It is widely known that the peri-operative management of primary and advanced gynaecologic cancer is strictly monitored by guidelines which are developed to provide recommendations for the optimal surgical result and therefore overall survival of patients.

Our goal is, always following the organizational guidelines, to develop a software which will automatically detect the malignant lesions on the surface organs of the peritoneal cavity. The augmented reality software will acknowledge in real-time the lesions according to their location in the abdomen, as well as their size. Ultimate goal is to predict which patients can undergo optimal surgery with a simple diagnostic laparoscopy and if so, detect and resect all visible malignant lesions greater than 0,5cm.

Conclusions

The next iteration of surgical advancement may be augmented reality (ar). This technology augments the surgeon's ability to view, understand and manipulate data about the patient in incredible ways. Further research needs to be done, but once we manage to introduce ar software in gynae-oncology surgeries, we will be on the leading edge of this exciting technology.

Ovarian dermoid cysts: factors influencing the surgical outcome

Lisa Marie Wilhelm¹, Tahmasbi Rad Morva¹, Bachmann Annette¹, Becker Sven¹, Gasimli Khayal¹

¹University Hospital, Gynecology & Obstetrics, Frankfurt am Main, Germany

Background

Dermoid cysts are rare and cause pathological findings in the ovary. Deep knowledge of the condition is necessary as dermoid cysts can be both benign and malign. Furthermore, recurrence of such an ovarian cyst must be avoided to prevent further damage of the ovarian tissue and several surgeries. Elective surgery can be performed when the cyst is diagnosed but does not show any symptoms. Emergency surgery is performed in case of ovarian torsion. The challenge is to remove the dermoid cyst as whole without rupturing.

Methods

335 cases of patients with dermoid cysts and surgery from 2012 to 2020 were reviewed retrospectively. Parameters taken into consideration were demographical, surgical and pathology results. The study was contributed to identify factors that might significantly impact the patients and surgical outcome.

Results

The median age of the cohort was 33 years, and the median BMI was 24,30 kg/m². Most surgeries were performed in 2015 with a total of 89 (26%). The surgical time was significantly increased in obese patients ($p < 0.05$) and in patients with a significant volume of the dermoid cyst ($p = 0.003$). Also, the hospital stay length was significantly longer in obese patients ($p = 0.03$). The surgical management (laparoscopic vs. Laparotomy) was chosen based on the size of the cyst, and when laparotomy was performed, and the hospital stay length increased significantly ($p = 0.001$).

Conclusions

Surgical management of dermoid cysts should be based on the size of the cyst and will impact the hospital stay length.

Outpatient hysteroscopic tissue removal system using in intrauterine pathology

Nafiye Yilmaz¹

¹Ankara Guven Hospital, Obstetrics and Gynecology, Ankara, Turkey

Background

Intrauterine pathology as endometrial polyp, leiomyoma uteri may cause abnormal uterine bleeding and also subfertility. Any intrauterine lesion in patients with risk factors should be removed and sent for pathologic examination. These intrauterine pathologies can be removed hysteroscopic management. also retained products of conception is amenable to hysteroscopic removal. Different hysteroscopic treatment modalities can be used for the treatment of these pathologies. Hysteroscopic loop-electrode resectoscopy provided a reliable method for removing intrauterine pathology but have some limitation: the distention media issues, risks of perforation, and visual field limitation created by resected tissue. Due to these limitation alternate treatment methods as hysteroscopic tissue removal systems have been developed. Minimizing procedure time mostly depends on maintaining tissue contact between the cutting window and the pathology in hysteroscopic tissue removal systems. And also, hysteroscopic tissue removal systems allow hysteroscopy procedures from the hospital to the office setting, smaller diameter hysteroscopes, less cervical dilation, less cervical trauma, easy cervical insertion, optimized visibility, controlled fluid deficit, shorter operation time, less or without anaesthesia, less cost, comfortable for the patients and doctors.

Methods

34-year-old patient with infertility was admitted to our clinic. Type 1 submucous myoma (2 cm) was detected in ultrasonographic examination and hysteroscopy was planned. Truclear 5mm with optic 0 degrees (Medtronic, tissue removal system®) as hysteroscopic tissue removal system was performed in hysteroscopic operation because of outpatient management during the covid 19 pandemic according to our clinical practice.

Results

We performed sedation anaesthesia; we use smaller diameter hysteroscopes and don't need cervical dilatation. operation time was 4 minutes, no more insertion and no bleeding.

Conclusions

Hysteroscopic tissue removal system is associated with a higher operative success rate and a shorter operative time among patients with endometrial pathology than is resectoscopy especially in outpatients' management. Also, hysteroscopic tissue removal system reduces bioaerosol exposure and clinical guidelines recommend using hysteroscopic tissue removal system in covid 19 pandemic.

Laparoscopic hysterectomy alone vs. laparoscopic hysterectomy plus sentinel node mapping in endometrial cancer: perioperative and long-term results from a multi-institutional study

Giorgio Bogani¹, Fabio Ghezzi², Jvan Casarin², Andrea Papadia³, Ludovico Muzii¹, Violante Di Donato¹

¹University La Sapienza, Department of Gynecological- Obstetrical and Urological Sciences, Rome, Italy

²University of Insubria, Gynecological Surgery, Varese, Italy

³University of Lugano, Gynecologic Oncology, Lugano, Swaziland

Background

Accumulating data supported the safety and effectiveness of sentinel node mapping (SNM) in endometrial cancer (EC) patients. Several retrospective studies compared outcomes after SNM and lymphadenectomy, suggesting that these two approaches are characterized by similar long-term oncologic results. However, no studies are evaluating outcomes of patients having SNM in comparison to patients who had no retroperitoneal staging. Here, we aim to compare outcomes after hysterectomy and hysterectomy plus SNM in EC patients.

Methods

This is a retrospective study, collecting data of EC patients treated between 01/01/2006 and 12/31/2016 in nine referral centres. A propensity-score matching was adopted to reduce the presence of confounding factors between groups. Kaplan-Meier and Cox hazard models were used to estimate 5-year outcomes.

Results

The study population included 398 (69.5%) and 174 (30.5%) patients having hysterectomy and hysterectomy plus SNM. As the results of the adoption of a propensity-score matched analysis, we selected two homogeneous cohorts of patients (150 having hysterectomy only vs. 150 having hysterectomy plus SNM). The execution of sentinel node mapping correlated with longer operative time, but it is not influencing the length of hospital stay and estimated blood loss. Two (1.3%) and one (0.7%) conversion occurred after hysterectomy and hysterectomy plus SNM, respectively ($p=1.00$). Overall severe complication rates were similar between groups (0.7% in the hysterectomy group vs. 1.3% in the hysterectomy plus SNM group; $p=0.561$). No lymphatic-specific complication occurred. Overall, 12.6% of patients having SNM were diagnosed with disease harbouring in their lymph nodes. Considering patients diagnosed with stage IIIC disease ($n=19$, 12.6%), we observed that macrometastasis, and isolated tumour cells were detected in 10 (6.6%), 3 (2%), and 6 (4%) patients, respectively. Four patients were diagnosed with stage IIIC2 (due to the detection of both pelvic and para-aortic nodal involvement). No patient was diagnosed with para-aortic nodal involvement only. Adjuvant therapy administration rate was similar between groups. Considering patients having SNM, 4% of patients received adjuvant therapy on the basis of nodal status only; all the other patients received adjuvant therapy on the basis of uterine risk factors. Five-year disease-free ($p=0.720$) and overall ($p=0.632$) survival was not influenced by the surgical approach. In comparison to hysterectomy alone, SNM did not improve disease-free survival in low- ($p=0.789$), intermediate- ($p=0.850$), and high-risk patients ($p=0.540$, log-rank test). Similarly, in comparison to hysterectomy alone, SNM did not improve overall survival in low- ($p=0.810$), intermediate- ($p=0.790$), and high-risk patients ($p=0.645$, log-rank test).

Conclusions

Laparoscopic hysterectomy (with or without SNM) is a safe and effective method for managing EC patients. Further evidence is warranted to confirm the role of SNM in the era of molecular/genomic profiling

What is the risk of malignancy of abdominal wall endometriosis?

Julie Alaert¹, Michelle Nisolle², Stavros Karampelas¹

¹*CHU Brugmann, Gynecology, Brussels, Belgium*

²*Université de Liège, Gynecology, Liège, Belgium*

Background

Endometriosis is considered to be a benign condition. However, it shares some characteristics with malignant tumours such as tissue invasion and damage. The main objective of this oral presentation is to describe the clinical characteristics of endometriosis-associated malignancy in abdominal wall and to analyse the different treatments offered to the patients and their outcome.

Methods

We performed a review of the literature about tumours arising from abdominal wall endometriosis.

Results

The probability of developing endometriosis in the abdominal surgical scar is 0.03% to 1%. Malignant-associated abdominal wall endometriosis is even more unusual and is likely to occur in 1% of these cases, especially in caesarean section scars. Abdominal wall endometriosis describes the involvement of ectopic endometrial tissue located retroperitoneally in the abdominal wall, including lesions secondary to a surgical incision and spontaneous lesions. Scar endometriosis is considered the most frequent of the abdominal wall and is defined as an iatrogenic effect. The main symptoms of malignant transformation of abdominal wall endometriosis include cyclic pelvic pain (73,8%) and a self-palpation of an abdominal mass (63.1%). The size of the mass varied between 2.5 and 22cm with a median diameter of 9 cm. Ultrasonography is useful for the diagnosis, as it is inexpensive, simple, non-invasive and easy to apply. The mean time interval from the first operation to the onset of malignant transformation of abdominal wall endometriosis is 17.8 years. Most common cancerous histological types of malignant endometriosis are mostly well or intermediately differentiated tumours of clear cell and endometrioid histological sub-types. Currently, because of its low prevalence, there is no unified treatment plan for malignant transformation of endometriosis. The most widely accepted treatment in the literature is a wide surgical resection of local lesions with adjuvant chemotherapy. The prognosis of endometriosis-associated malignancy in abdominal wall scars is very poor; the five-year survival rate is about 30%. High rates of relapse have been reported in the literature; therefore, some authors propose to have a strict follow-up every 3 months within 2 years post operatively.

Conclusions

Malignant transformation of extra pelvic endometriosis, especially abdominal wall scars, remains rare but is an aggressive disease that needs to be treated radically due to its rapid proliferation. No evidence-based guidelines have been established for diagnosis and treatment for this disease. Prevention of endometriosis implantation in any abdominal surgery, especially at time of caesarean section is important, as endometriosis-associated-malignant transformation in abdominal scar is mostly related to caesarean section scars.

Efficacy and feasibility of PuraStat® in laparoscopic gynaecological surgery: a case series

Philip Hall¹

¹St Andrew's War Memorial Hospital, Pelvic Medicine Centre, Brisbane, Australia

Background

Introduction: Bleeding following laparoscopic gynaecological surgery remains an ever-present potential complication. The aim of this study was to assess the efficacy and the feasibility of PuraStat®, a topical haemostatic device, made of self-assembling peptides in laparoscopic gynaecological surgery.

Methods

This is a prospective observational non-randomised, single operator case series. Eligible patients undergoing laparoscopic gynaecological surgery were enrolled. The primary endpoint was intraoperative efficacy in stopping remaining oozing at the resection site. Secondary endpoints were the volume of PuraStat used, Time to Haemostasis after PuraStat® application and the need for a secondary means to achieve haemostasis after PuraStat® application.

Results

Forty-six (46) consecutive patients were enrolled. The mean volume required to achieve haemostasis was 5.69 ml, the mean time to achieve haemostasis was 14.02 secs. Mean operative time overall was mins 70.65 mins and there was no need to employ a secondary haemostat. None of the patients experienced delayed post-operative bleeding and there were no post-operative complications in this group of 46 patients.

Conclusions

This case series demonstrates that PuraStat® can be easily used in laparoscopic gynaecological surgery and it is a safe and effective haemostatic agent. This the first study of PuraStat use in gynaecology world-wide and additional controlled studies would be useful to validate the results of this case series.

A clinical study assessing ZG16B/PAUF overexpression in high-grade ovarian serous adenocarcinoma

Victor Gaultier¹, Lise Lecointre¹, Cherif Akladios¹, Martin Demarch²

¹Département de Chirurgie gynécologique- Hopital Universitaire de Strasbourg- Strasbourg- France, Département de Chirurgie gynécologique- Hopital Universitaire de Strasbourg- Strasbourg- France, Strasbourg, France

²Institut de Cancérologie Strasbourg Europe ICANS, Oncology unit, Strasbourg, France

Background

A recent genomic analysis of human ovarian tumours identified the zymogen granule protein 16B (ZG16B) gene as encoding pancreatic adenocarcinoma positive regulatory factor (PAUF).

ZG16B expression at PAUF origin, a glycosylated protein initially described in human pancreatic cancer, is associated with aggressive tumour behaviour. By multiple mechanisms, PAUF promotes proliferation, migration, tumour invasion, has a pro-angiogenic and immunomodulatory action on the tumour microenvironment promoting tumour progression.

This study aims to assess the incidence of PAUF expression in high-grade ovarian serous adenocarcinoma, the most common histological subtype among epithelial ovarian tumours, and the impact of this possible overexpression on patient survival.

Methods

This retrospective study was conducted from January 17, 2004, to December 22, 2019. ZG16B was quantified by mRNA expression by RT-qPCR in high-grade ovarian serous adenocarcinoma samples frozen at -80° stored in the Biobank of the Paul Strauss Cancer Center, the University Hospital of Strasbourg France and the Strasbourg Cancer Institute (ICANS). These tumour samples are taken from initial diagnostic surgery such as exploratory laparoscopy carried out in patients mainly presenting with extensive ovarian cancer (FIGO stage III-IV).

Clinical data were collected concomitantly with biobank constitution and survival data were collected retrospectively on medical records.

Kaplan-Meier survival curves were plotted, the log-rank test used to compare survival.

Results

A total of 313 patients with ovarian cancer were included in this study. Of the evaluable patients, 26% had ZG16B overexpression.

Interestingly, patients with ZG16B overexpressing tumour experienced shorter progression-free survival (median PFS of 5.5 months (95% CI 2.3 and 11.9) versus 29 months (95% CI 15 and NA), respectively p = 0.002).

Conclusions

ZG16B overexpression seems to be associated with a worse outcome in high-grade ovarian serous adenocarcinoma and could represent a new therapeutic target. Recently, a new anti-PAUF/ZG16B antibody, PBP1510, was developed by PrestigeBiopharma (NCT05141149).

This study provides arguments in support of a future clinical trial to evaluate this antibody in patients with ovarian cancer.

Laparoscopic myomectomy for large cervical/broad ligament fibroids: case series

Hossam El-Mansy¹, Mohamed Magdy², Mohamed Nabil³

¹Helwan University Hospitals, OBS/GYN department, Cairo, Egypt

²Ministry of Health, Gynecology, Cairo, Egypt

³Cairo University Hospitals, Gynecology, Cairo, Egypt

Background

Myomectomy for large cervical/broad ligament fibroids represents a challenge to the Gynaecologists in general. Laparoscopic myomectomy is more challenging due to close proximity and possible pressure effect on urinary bladder and both ureters.

In this study we assessed the feasibility of laparoscopic myomectomy for cervical/broad ligament fibroids larger than 5 cm.

Methods

We reviewed our laparoscopic myomectomy database for cases of cervical/broad ligament fibroids larger than 5 cm.

In lithotomy position, the urologist performed cystoscopic insertion of bilateral external ureteric catheters followed by trocar placements by the gynaecologist.

Diluted Glypressin was injected in the plane between the myoma & the pseudocapsule. Monopolar hook was used to make an incision. Myoma screw was inserted in the myoma followed by traction and counter traction till removal of the myoma. Interrupted 3.0 vicryl sutures was used for hysterotomy. Myomas was extracted by cold morcellation.

All baseline and perioperative data were reviewed and reported case by case.

Results

From August 2018 to April 2022, out of 95 cases of laparoscopic myomectomy, 9 patients had cervical /broad ligament fibroids larger than 5 cm. The median myoma size was 5.7 (5-9 cm). The cervical myomas were 4: two anterior, one lateral and one posterior. The broad ligament fibroids were 5. No need for conversion in any case. Mean operative time was 82(\pm 12) minutes. Mean operative blood loss was 220(\pm 30) ml. Urethral and ureteric catheters were removed first day postoperative in all cases.

No major postoperative complications were reported. All specimens were found histologically benign.

Conclusions

Laparoscopic myomectomy seems to be a safe option in cases of large cervical/Broad ligament fibroids if done in suitable conditions.

The use of Simplified Interactive digital 3D models of endometriosis patients in preoperative consent clinic - EndoSketch® - A free and accessible service

Amr Amr Magdi Mohamed Moneib¹

¹*Cambridge University hospitals, Gybaecology, Cambridge, United Kingdom*

Background

A simplified interactive digital 3D model of patient pelvis will be digitally built by author on basis of imaging findings in endometriosis clinics to improve patient understanding in preoperative counselling and team orientation in surgery. While similar approaches were used with very expensive and sophisticated software. Minute details might not be very significant, and a more global but accurate simplified version is actually needed to help the untrained eyes of patients and junior members of the team. The aim is to provide a very advanced yet cheap version that provides benefits in communication and understanding with patients and team and improves the consent process empowering patients to make an informed choice. The EndoSketch® models can clearly and easily explain the affected organs and the surgical approach planned.

Methods

A free website <http://Endosketch.co.uk> and a mobile application EndoSketch® which will be rolled out on google play store were built with general 3D models representing different pictures of endometriosis. These models will be used as skeletons for modifiable 3D models to help the patients understand their findings in preoperative consenting clinics. A questionnaire will be used to assess patient satisfaction and understanding of findings and surgical plans after the use of the 3D model.

Results

This is a pilot study to assess the use of simplified interactive 3D modelling in preoperative consent clinics in an endometriosis centre. This will also serve as a prototype of an easy modifiable version of the app to facilitate a simplified demonstration of the organs affected.

Conclusions

This is a pilot study to assess the use of simplified interactive 3D modelling in preoperative consent clinics in an endometriosis centre. This will also serve as a prototype of an easy modifiable version of the app to facilitate a simplified demonstration of the organs affected.

Self-help strategies in women with endometriosis and chronic pelvic pain. Why a holistic approach is necessary and occasionally missed?

Amr Amr Magdi Mohamed Moneib¹

¹Cambridge University hospitals, Obstetrics and gynaecology, Cambridge, United Kingdom

Background

Objective: To demonstrate the practical use of self-help strategies in endometriosis and chronic pain conditions.

Methods

Discussion: Chronic pain conditions can be debilitating and affect the quality of life of many sufferers. Conditions like endometriosis, bladder pain syndrome, irritable bowel syndrome, fibromyalgia, and migraines can occur on their own but in many cases can present as multiple factors behind the pain. Diagnosis of these conditions is not easy and controversial. While a physical cause can eventually be found, sometimes even removing that either surgically or medically does not solve the problem. Recurrence can explain the late presentation of the same symptoms. Neuropathic pain can explain some of these situations. The psychological effect of having such debilitating conditions is usually ignored. Explaining the physiology of pain pathways and the interpretation by the brain is essential here. A Greek philosophy "Stoicism" teaches one's coming in terms with nature. That represents bases of Acceptance and commitment therapy that can be very essential in patients with chronic pain conditions. The importance of the teaching of self-help techniques like stretching, breathing exercises, and mindfulness is not addressed enough. Neuroplasticity is another feature of our brains of getting adapted to repeated situations. Brain training can be helpful to address the heightened volume of pain as result. Addressing patients' expectations honestly from the start is of paramount importance.

Results

A poster derived with mnemonic "less pain" summarizing pain control strategies is made available to patients to facilitate the education of these very helpful tools.

Conclusions

A poster derived with mnemonic "less pain" summarizing pain control strategies is made available to patients to facilitate the education of these very helpful tools.

An app is currently being developed to help patients with the LESSPAIN concept and self-help strategies.

VisualEndoMapping® A new way to describe endometriosis. Should we still use scores and grades?

Amr Amr Magdi Mohamed Moneib¹

¹Cambridge University hospitals, Gynaecology, Cambridge, United Kingdom

Background

Introduction: Many ways for describing endometriosis have been derived. Ranging from classifying endometriosis into superficial and deep, grade 1 to 4, mild to severe and finally scores that were derived by many societies. There is no consensus on one way to describe it. This inconsistency makes it difficult for both patients and doctors in describing the disease.

Methods

A computer software was designed by the author. This is available for free via the website Endosketch.co.uk and on Google app store with a simple interface where the user can click on different organs on a virtual model of pelvis to obtain different pictures of the disease.

Results

This is a prototype software. Further updates can be done to incorporate different findings. In future release a 3D model will be derived with a similar interface.

Conclusions

This is a prototype software. Further updates can be done to incorporate different findings. In future release a 3D model will be derived with a similar interface.

Virtuahyst© Virtual hysteroscopy to help counselling patients and improve training. A free website.

Amr Amr Magdi Mohamed Moneib¹, Mohamed Mabrouk¹

¹Cambridge University hospitals, Gynaecology, Cambridge, United Kingdom

Background

Hysteroscopy is a simple procedure that has become a common daily practice in modern gynaecology. Despite the simplicity, training is occasionally difficult and needs lots of practice which was not very accessible during covid 19 pandemic. Patients are getting more acquainted with what hysteroscopy is. However, there is not enough resources explaining the steps and the concept of Hysteroscopic surgery.

Methods

Endosketch.co.uk is a website that was developed to use 3d models in endometriosis surgery. A page on the website Virtuahyst is dedicated to hysteroscopy practice. A collection of 3d models of different Hysteroscopic findings to be used for counselling and education.

A questionnaire given to 20 women who attended OPH clinic and assess their satisfaction of having 3d models in explaining the procedure.

Another questionnaire of 20 junior doctors to assess if their concept of hysteroscopy has improved after the use of VirtuaHyst

Results

The results are still pending. However so far. Most are encouraging and proved 3D models are a good tool to explain the procedure.

Conclusions

EHealth is getting more important nowadays and facilitates the counselling process and the understanding of the condition.

Individualized 3D modelling of gynaecological disorders built with 3D pen. A cheap and easy option to improve preoperative counselling and education.

Amr Amr Magdi Mohamed Moneib¹

¹Cambridge University hospitals, Gynaecology, Cambridge, United Kingdom

Background

Preoperative counselling is essential for patient understanding and to ensure a proper informed consent. The use of technological advances is largely implemented in operating theatres but lots of work is still to be done in clinic settings. 3D pens are cheap and widely available products that can help build individualized pictures of gynaecological disorders and pathologies.

Methods

A proof-of-concept example was designed by the author using 3d pen which is easy to use and much cheaper than 3d printed alternatives. They also provide flexibility of adding specific pathologies depending on physical, ultrasound and MRI findings.

Results

Examples of the models used in counselling include endometriosis, multiple fibroids, and ovarian masses. A gallery of pictures of the models used will be presented in the poster.

Conclusions

The use of 3d models is a good way to help improve counselling and patient education. Having a physical 3d model helped women understand their pathologies to ensure an informed consenting process.

Long-term patient satisfaction and removal rate after Essure sterilization: a follow-up study

Rok Sumak¹, Tamara Serdinšek¹, Maja Rosič², Branka Žegura¹

¹University Medical Centre Maribor, Department of General Gynaecology and Gynaecologic Urology, Maribor, Slovenia

²Health Institution Rosič, Ptuj, Ptuj, Slovenia

Background

The objective of our study was to assess the rate and causes for Essure[®] micro-insert system removal and patients' long term satisfaction rate with the procedure.

Methods

All patients who underwent Essure[®] hysteroscopic sterilization at our tertiary centre between years 2007 and 2018 were included in this follow-up study. A questionnaire was sent to all patients per standard mail. Patients who did not respond to questionnaires per mail, were called by phone. The satisfaction with the Essure[®] sterilization, as well as any additional procedures after the insertion or insertion-related complications were analysed.

Results

From the year 2007 to 2018, we performed 427 Essure[®] hysteroscopic sterilizations and of these, 329 patients responded to the questionnaire (response rate 77%). Mean follow-up period was 84.2 ± 26.6 months. Ten patients (3%) had Essure[®] removal, two of them due to pain (0.6%). Patients were very satisfied with the procedure (9.5 on scale 0 – 10). Most patients (95.3%) would recommend the procedure to their friend.

Conclusions

Essure[®] hysteroscopic sterilization is a procedure with a very high satisfaction rate and a very low removal rate due to sterilization-related complications.

Operative hysteroscopy versus ultrasound guided electric vacuum aspiration for removal of retained products of conception: a cohort study.

Tjalina Hamerlynck¹, Liselot Wagenaar², Celine Radder³, Louisette Peters⁴, Steven Weyers¹, Huib van Vliet²

¹*Ghent University Hospital, Women's Clinic, Ghent, Belgium*

²*Catharina Hospital, Obstetrics and Gynaecology, Eindhoven, The Netherlands*

³*OLVG West, Obstetrics and Gynaecology, Amsterdam, The Netherlands*

⁴*OLVG East, Obstetrics and Gynaecology, Amsterdam, The Netherlands*

Background

The most widely performed surgical procedure for removing retained product of conception (RPOC) is curettage. However, evidence suggests that hysteroscopic removal might have a lower risk of intrauterine adhesion (IUA) formation and more often results in complete evacuation than curettage. This study aimed to determine whether operative hysteroscopy for removal of RPOC has higher efficiency, a lower risk of complications, and a lower risk of IUA formation than electric vacuum aspiration (EVA).

Methods

This multicentre, prospective cohort study was conducted alongside an RCT in 3 teaching hospitals and 1 university hospital from April 2015 to date. Women diagnosed with RPOC on ultrasound ranging from 1 to 4 cm, who did not want to participate in the RCT due to a preference for a specific treatment option, were included. Women opting for EVA underwent the procedure as soon as possible. In the hysteroscopy group, a diagnostic hysteroscopy was planned at a minimum of 6 weeks after the end of pregnancy, followed by removal of the RPOC at least 2 weeks later. EVA was performed using an 8- or 10-mm flexible plastic Karman cannula. Operative hysteroscopy consisted of either HM (with the TRUCLEAR 8.0 System or Elite plus (Medtronic, Minneapolis, MN, USA) or the Intrauterine BIGATTI Shaver (Karl Storz GmbH, Tuttlingen, Germany) or loop resection (with an 8.5-mm bipolar resectoscope (Karl Storz GmbH, Tuttlingen, Germany)), according to surgeon's choice and system availability. Postoperatively, a second-look hysteroscopy was offered to all patients after at least 1 menstruation or after a minimum of 4 weeks after RPOC removal to check for IUA formation and completeness of removal.

Results

In our preliminary analysis, 125 women were treated in the hysteroscopy group and 28 in the EVA group. 26 patients did not undergo surgery due to spontaneous expulsion or outpatient hysteroscopic removal of the RPOC with a forceps. The median operating time was similar between EVA and hysteroscopy group (5.50 min vs 7.58 min, $p = .076$). No statistically significant differences were observed between the hysteroscopy group and EVA for the occurrence of intra- and postoperative complications (4.8% vs 3.6% and 0.8% vs 0%). The completeness of removal of the RPOC was significantly higher (92% vs 67%, $p = .012$) in the advantage of the hysteroscopy group. We will present the final results on IUA formation at the congress.

Conclusions

Our observational data show that RPOC are more often completely removed by hysteroscopy than by EVA with a similar complication rate for both groups.

Total Laparoscopic Hysterectomy: intra and postoperative complications analysis

Angela Silva¹, Mak Foo Kok², Teresa Paula Teles²

¹*Centro Hospitalar do Médio Ave, Ginecologia e Obstetrícia, Vila Nova de Famalicão, Portugal*

²*Centro Hospitalar Entre Douro e Vouga, Ginecologia e Obstetrícia, Feira, Portugal*

Background

Report and analyse intraoperative and postoperative complications occurred in patients who underwent total laparoscopic hysterectomy (TLH).

Methods

A retrospective observational study of all total laparoscopic hysterectomy performed at Centro Hospitalar Entre Douro e Vouga, a secondary minimally invasive gynaecologic centre, between January and December 2021 (n = 63), was conducted. Medical records were reviewed for patient characteristics, intra and postoperative complications and length of hospital stay.

Results

Overall, 63 women underwent total laparoscopic hysterectomy at our institution during the studied year. Patient average age was 51.3 years, 44.4% (n = 28) were postmenopausal and 46.2% had previous abdominopelvic surgery.

The main surgical indications were: myomatous uterus (42.9%); endometrial hyperplasia (20.6%), abnormal uterine bleeding refractory to medical management (14.3%), adnexal pathology (7.9%), endometriosis (4.8%), adenomyosis (4.8%), cervical dysplasia (3.2%) and genetic syndrome – BRCA1 (1.6%).

TLH was performed with unilateral or bilateral adnexal surgery in 49.2% (n = 31) of the patients, with unilateral or bilateral salpingectomy in 42.9% (n = 27) and with bilateral adnexal preservation in 7.9% (n = 5).

The major and minor complication rates were 4.8% (n = 3) and 19.1% (n = 12), respectively. Major complications included one ureter lesion, one conversion to laparotomy due to multiple adhesions and one dehiscence of the vaginal cuff that underwent secondary closure by vaginal approach. Minor intraoperative complications included bleeding with no indication for blood transfusion in two patients (3.2%) and one patient (1.6%) with serosal sigmoid iatrogenic laceration, in whom suturing was immediately performed. Minor postoperative complications included 5 cases (7.9%) of vaginal cuff hematoma and 4 patients (6.4%) with infectious situations, namely 3 (4.8%) with lower urinary tract infections and one (1.6%) infection of the vaginal cuff.

No vesical lesion, no re-admission (less than 72 hours upon discharge) nor any intraoperative or immediate postoperative death occurred. Average hospital stay was 2.03 days.

Conclusions

Our study confirmed that laparoscopy represents a safe and effective surgical approach for total hysterectomy. Overall, TLH is associated with acceptable intraoperative and severe postoperative complications rates. Although complications occurred in approximately 24% patients who underwent TLH at our institution, major events were registered in less than 5% of the cases. Efforts to reduce intraoperative complications are vital to mitigate the likelihood of developing severe postoperative complications.

Minimally invasive anaesthesia for laparoscopic hysterectomy: a case series

Antonio Mercurio¹, Paolo Serafino¹, Mario Palumbo², Luigi Della Corte¹, Francesco Viciglione¹, Pierluigi Giampaolino¹

¹University of Naples Federico II, Ob/Gyn, Naples, Italy

²Universtiy of Naples Federico II, Ob/Gyn, Naples, Italy

Background

In the minimally invasive era, laparoscopic gynaecological surgery is currently performed under general anaesthesia (GA), although regional anaesthesia (RA) could be considered a valid alternative in some specific settings. Aim of this study was to assess the feasibility and the perioperative outcomes of laparoscopic hysterectomy in regional anaesthesia from the point of view of the surgeon, anaesthesiologist, and patient.

Methods

In this retrospective case series, we describe the outcome of laparoscopic hysterectomy under RA of 5 patients affected by benign gynaecological disease (atypical endometrial hyperplasia or myomas). A database search was performed to identify patients who underwent laparoscopic hysterectomy under RA from April 2020 and September 2021. The postoperative pain, nausea, and vomiting (PONV) and the antiemetic/analgesic intake were evaluated. Postoperative surgical and anaesthesiologic variables were recorded.

Results

Duration of surgery was 84 ± 4.18 and no conversion to GA was required. According to VAS score, postoperative pain during the whole observation time was less than 5. A faster resumption of bowel motility (≤ 9 hours) and patient's mobilization (≤ 4 hours) were observed as well as a low incidence of post-operative nausea and vomit. Early discharge and greater patient's satisfaction were recorded. Intraoperatively pain score on a Likert scale during all the stages of laparoscopy in RA was assessed with a maximum pain score registered of 2/5 at pneumoperitoneum.

Conclusions

RA showed to have a great impact on surgical stress and to guarantee a quicker recovery without compromising surgical results. RA technique could be a viable option for selected patients undergoing laparoscopic hysterectomy

Sacrocolpopexy for vaginal vault prolapse: 7-year experience from a Peripheric Centre

Joana Vasconcelos Raposo¹, Mariana Ormonde¹, Ana Lima¹, Filipa Osório², Laura Sampaio¹, Carlos Ponte¹

¹Hospital Divino Espírito Santo, Gynecology/obstetrics, Ponta Delgada, Portugal

²Hospital Da Luz, Gynecology, Lisboa, Portugal

Background

Pelvic organ prolapse (POP) is defined by herniation of the anterior or posterior vaginal wall, uterus, or vaginal apex into the vagina; descent may occur in one or more structures. It's a common, benign condition that can cause vaginal bulge and pressure, voiding, defecatory and sexual dysfunction, which may adversely affect women's quality of life.

According to the literature, the cause of apical prolapse is multifactorial, but vaginal parity and previous hysterectomy are the most commonly associated risk factors.

Apical vaginal support for post-hysterectomy vault prolapse can be provided by vaginal, abdominal, or laparoscopic routes. Sacrocolpopexy is associated with higher satisfaction rates and a lower re-operation rate compared with other surgical procedures.

The objective of this study was to investigate the gynecological and obstetric history of women submitted to Sacrocolpopexy for surgical correction of vault prolapse and the main complications associated with it.

Methods

Retrospective study that included all women who underwent Sacrocolpopexy since the procedure was started at the Hospital do Divino Espírito Santo in Ponta Delgada (HDES) in 2013 until 2020, when this type of non-urgent surgery was suspended due to the covid-19 pandemic. Data was obtained through clinical files and telephone contact. In this study, there was a significant association between a history of vaginal delivery and postoperative complications, considering the $p < 0.05$ ($p = 0.03$) using the chi-square test.

Results

We studied a group of 20 women who underwent sacrocolpopexy, with a mean age of 60.95 ± 9.65 years and 95,00% ($n=19$) of the patients who underwent the procedure had a grade IV Baden POP.

It was found that 95,00% ($n=19$) of them had previous vaginal deliveries, 15,00% ($n=3$) had 1 eutocic delivery (PE), 25,00% ($n=5$) 2 PE and 55,00% ($n=11$) 3 or more PE, the average PE being 3 ± 1.89 .

When evaluating the surgical gynaecological history, it was found that 70,00% ($n=14$) had undergone previous total abdominal hysterectomy and 30,00% ($n=6$) vaginal hysterectomy. Thirty-five percent ($n=7$) had some degree of associated urinary incontinence (UI), of which 10,00% ($n=2$) stress urinary incontinence, with a TVT-O being applied at the same surgical time in 15,00% ($n=3$) of the patients.

The procedure was effective in 61,90% ($n=13$) of the patients, 9,60% ($n=2$) reported UI complaints and 23,80% ($n=5$) reported some degree of prolapse, with only one patient needing another surgical correction for POP (posterior compartment).

Conclusions

Thus, it is concluded that although the study sample is small and we had a short follow-up, sacrocolpopexy constitutes a very satisfactory surgical treatment associated with high rates of success in the medium and long term, a fast recovery and low rates of morbidity, mortality, and recurrence.

In-vivo pressure build-up within the reproductive tract during hysterosalpingography: a pilot feasibility study.

Inez Roest^{1,2,3}, Amir Hajiyavand⁴, Velja Mijatovic³, Ben Willem Mol⁵, Carolien Koks¹, Karl Dearn⁴

¹*Máxima MC, Obstetrics and Gynaecology, Veldhoven/Eindhoven, The Netherlands*

²*Maastricht University, Grow research school for Oncology and Reproduction, Maastricht, The Netherlands*

³*Amsterdam UMC- Vrije Universiteit Amsterdam, Amsterdam Reproduction and Development, Amsterdam, The Netherlands*

⁴*University of Birmingham,*

Mechanical Innovation and Tribology Group- Department of Mechanical Engineering- School of Engineering, Birmingham, United Kingdom

⁵*University of Monash, Obstetrics and Gynaecology, Melbourne, Australia*

Background

Hysterosalpingographies (HSGs) are often performed to test tubal patency in subfertile women. Meta-analyses have shown that an HSG with oil-based contrast positively affects natural conception rates compared to water-based contrast (Wang, 2020). One of the hypotheses for the fertility-enhancing effect of tubal flushing is the dislodgement of mucus/cell debris within the Fallopian tubes. The infusion of contrast media may lead to a hydraulic pressure build-up proximal to the “debris plug”, dislodging the plug and improving cilia function. Currently, data on pressure build-up patterns during HSGs are lacking. The primary objective of this study was to determine the feasibility of recording the pressure build-up within the reproductive tract during an HSG. Secondary outcome measures were pain scores and the fluoroscopy images obtained during HSGs.

Methods

A prospective, single-centre study in 10 subfertile women. Written informed consent was obtained prior to the procedure. HSGs were performed according to local protocol with oral pain medication (paracetamol 1000mg and Naproxen 500mg). The oil-based contrast (Lipiodol Ultra Fluid, Guerbet) was aspirated into a disposable fluid dispensing syringe with an integral pressure transducer, capable of monitoring pressures from 0 to 35 bar (DiamondTOUCH™, Merit Medical). The contrast was infused into the uterus under fluoroscopic guidance. Pain scores were evaluated at three moments during the HSG on the Visual Analogue Scale (VAS, 0-10 cm, no pain-unbearable pain).

Results

Per second, 29 in-vivo pressure values were obtained. In all women there was a minimum *in-vivo* pressure of 0.3bar during the HSG. The maximum pressure was less than 1bar in 10% of the women, 1-2bar in 70%, and >2bar in 20%. The average total pressure was 0.72±0.25bar, the average maximum pressure was 1.71±0.58bar. In four women the HSG showed abnormal tubal patency (maximum pressure 1.6, 1.8, 1.8 and 2.3bar). In one of these four women intravasation of contrast was observed (maximum pressure 1.8bar), after which the procedure was directly halted. The highest maximum pressure (2.9bar) was reported during an HSG with bilateral patent Fallopian tubes, however, this woman reported the highest pain score (VAS 10). The amount of contrast used in this woman was the lowest among all (2.3mL Lipiodol). For all HSGs a pressure behaviour graph was created.

Conclusions

This study shows that recording the pressure build-up within the reproductive tract is feasible during HSG. We advise additional studies on the pressure build-up pattern in relation to pain scores and fertility outcomes to further investigate the hypothesis of dislodgement of mucus debris from the Fallopian tubes. Furthermore, studies on the characteristics of the different oil-based and water-based contrast media are required to define which contrast properties are related to effective dislodgement of debris from the Fallopian tube.

long-term results of transcervical, intrauterine ultrasound-guided radiofrequency ablation of uterine fibroids with the sonata system: a retrospective follow-up study

Tessel Cooijmans¹, Julia van der Meulen¹, Virrie van Zutven¹, Jaklien Leemans¹, Corine Verhoeven¹, Marlies Bongers¹

¹Máxima Medical Centre, Obstetrics and Gynaecology, Veldhoven, The Netherlands

Background

The Sonata system is a new minimally invasive, transcervical, uterine-sparing treatment option for fibroids with a mainly intramural location. The device combines intrauterine ultrasonography with radiofrequency ablation. Long-term follow-up data are still lacking. This study aimed to evaluate long-term outcomes of the Sonata system in terms of surgical reintervention and to identify factors predicting surgical reintervention. Moreover, patient satisfaction, fibroid size reduction and complication rate were evaluated.

Methods

We performed a retrospective single-centre cohort study of 53 women who underwent Sonata treatment between December 2011 and April 2019. Medical chart review was conducted to collect data on surgical reintervention, patient, fibroid, and surgery characteristics. In addition, women filled out a questionnaire containing questions about surgical reintervention and patient satisfaction.

Kaplan-Meier analysis was used to determine cumulative reintervention rates and median survival time. Univariate cox regression analyses were performed to identify factors predicting surgical reintervention.

Results

Median follow-up period was 36 months (interquartile range (*IQR*) 22-58). Twenty-four women (45.3%) underwent a surgical reintervention, of which the majority was a hysteroscopic myomectomy (45.8%). Surgical reintervention rates at one year and at two years follow-up were 22.6% and 39.0% respectively.

Eventually, 7 women (13.2%) underwent a hysterectomy after the Sonata treatment. None of the included factors significantly predicted surgical reintervention. Median fibroid diameter was 41 mm (*IQR* 29-50) before and 29 mm (*IQR* 20-40) after treatment ($p < 0.001$). Thirty-four women (69.4%) were satisfied with the treatment effect and 42 women (85.7%) would recommend the Sonata treatment to other women. No device-related complications occurred.

Conclusions

The Sonata system is a safe and minimally invasive treatment option for women suffering from (partly) intramural fibroids. The findings of this long-term follow-up study support counselling women for treatment with the Sonata system. More prospective studies with long-term follow-up are needed to investigate for which type and size of uterine fibroid the Sonata system is of most value.

Feasibility and learning curve of Vaginal Natural Orifice Transluminal Endoscopic Surgery (V-NOTES) hysterectomy

Liliana Mereu¹, Fabio Guardala¹, Martina Ferrara¹, Basilio Pecorino¹, Andrea Benedetto Di Stefano¹, Paolo Scollo²

¹*Ospedale Cannizzaro, Obstetrics and Gynecology, Catania, Italy*

²*Kore University- Ospedale Cannizzaro, Obstetrics and Gynecology, Catania, Italy*

Background

V-NOTES is an emerging new minimally invasive surgical approach that permits to avoid completely skin incisions

The aim of this study was to describe our experience with transvaginal natural orifice transluminal endoscopic surgery (vNOTES) hysterectomy and to evaluate the learning curve.

Methods

this is a cohort study on a retrospective analysis of first 40 vNOTES hysterectomy performed between February 2021 and February 2022 at Department of Obstetrics and Gynaecology of Cannizzaro Hospital in Catania Italy, by two senior surgery (PS e FG) and by a team with optimal skills in Laparoscopic and vaginal surgery.

Data on patients' characteristics, surgical findings and postoperative outcomes were prospectively collected in a computed database.

Primary outcome was surgical time. Secondary outcomes were intraoperative and postoperative complications, surgical outcomes, length of hospitalization and first 24 Hours postoperative pain

Results

All patients underwent hysterectomy for benign indications: 27 fibromatosis, 3 methorrhagia, 10 precancerosis. Concomitant procedures have been bilateral adnexectomy in 32 cases and bilateral salpingectomy in 8 cases.

The median age was 51 years (range, 42-64). Median BMI 30.2 (range 21-42.5). The Median operative time was 72 minutes (range, 40-110). Total operative time decreased after the first 10 cases to the following 10: from 63 minutes (range, 55-100 minutes) to 51 minutes (range 40-80) (<0.028).

The mean estimated blood loss was 20 mL (0-150). The median hospital stay was 2 days (1-3). There were no intraoperative adverse events and 1 postoperative grade 3 complication.

The median visual analogue scale score for pain assessment during the first 24 hours after surgery was 3 (range, 1-6).

Conclusions

vNOTES hysterectomy is a feasible and reproducible approach for benign indications with a short learning curve and low rate of perioperative complications.

The effect of myomectomy on reproductive outcomes in patients with uterine fibroids: a retrospective cohort study.

Emmy Don¹, Rik van Eekelen², Velja Mijatovic¹, Judith A.F. Huirne¹

¹Amsterdam UMC- location Vrije Universiteit Amsterdam- Amsterdam Reproduction and Development, Department of Obstetrics and Gynecology, Amsterdam, The Netherlands

²Amsterdam UMC- location Academic Medical Centre, Centre for Reproductive Medicine, Amsterdam, The Netherlands

Background

Even if asymptomatic, fibroids are associated with infertility, by distortion of the uterine cavity, causing impairment of endometrial receptivity or by changing myometrial functionality. The magnitude of this negative influence seems to be related to the number, size, and especially location of the fibroid within the myometrium. Myomectomy is often performed to treat related symptoms and in selected cases to increase the chance of ongoing pregnancy. However, compelling evidence for the effect of a myomectomy on reproductive outcomes is lacking.

Methods

This retrospective cohort study included patients who presented with uterine fibroids in a Dutch academic hospital between 2004 and 2018. A total of 311 patients were included in the analysis, of which 165 patients eventually received myomectomy and 146 patients remained on expectant management. Data was collected from the patient's medical file and questionnaires. Women were followed from fibroid evaluation or start of wishing to conceive to first live birth or end of study. For the main analysis, we used a Cox proportional hazards model with time-varying covariate for myomectomy including selected confounders for adjustments. In our sensitivity analyses, this was combined with an approach to account for confounders via a cloning/censoring/weighting that aims to emulate a randomized controlled trial.

Results

The most notable differences in baseline characteristics between the myomectomy and expectant management group were fibroid size (fibroid >7cm: myomectomy 48%; expectant management 15%), whether the fertility work-up was performed (myomectomy 56%, expectant management 76%) and whether the patient had fibroid related complaints (myomectomy 85%, expectant management 67%). The adjusted hazard ratio for the effect of myomectomy compared to expectant management on time to live birth was 1.26 (95% CI: 0.87-1.81). Sensitivity analyses yielded similar results, but secondary outcomes showed that women remaining on expectant management had more often received ART (63%) compared to women who eventually received myomectomy (39%). Consequently, the mode of conception was more often natural conception for women who eventually received myomectomy (67%), compared to women in the expectant management group (36%).

Conclusions

We did not find a negative effect in time to live birth rate after myomectomy compared to expectant management but did find less ART therapies in patients with fibroids and a wish to conceive, despite more, larger, and more symptomatic fibroids in the myomectomy group. This is noteworthy because patients have a recovery time after myomectomy. This suggests that any negative effect due to this waiting was balanced by a possible positive effect of myomectomy after recovery. Our results encourage the execution of a randomized controlled trial in women with large (symptomatic) fibroids not distorting the uterine cavity, and infertility or an actual desire to conceive.

Clinical experience with the senhance robotic system in gynaecology after the first 153 cases

Burghard Abendstein¹, Attila Rab¹, Michael Prugger¹, Manuel Magerle¹

¹Landeskrankenhaus Feldkirch, Gynecology and Obstetrics, Feldkirch, Austria

Background

the senhance robotic system differs in a few significant points compared to other established robotic systems. three of the main properties of the system are haptic feedback as well as freedom in the placement of the robotic arms. in gynaecologic surgery, especially for the treatment of endometriosis the evaluation of tissue qualities is important. the haptic feedback function turned out to be a helpful and save feature for that purpose. Several cases request surgery in the pelvic region as well as in the upper abdomen. due to the flexibility of the system instruments and optic can be connected to each robotic arm, thereby facilitating the access to all abdominal compartments with only little time loss. the system works with reusable instruments thereby reducing costs. we strive to evaluate these features and establish the robotic system for gynaecologic surgeries. our aim is to report on our experience as well as taking a glimpse at the future with the system after having performed 153 cases.

Methods

we performed 153 surgeries since 2020 in a trained and standardised team of 4 gynaecologists. we obtained informed consent from all patients. we started with simple adnexal surgeries to establish team routine and experience and were able to quickly move to larger gynaecologic surgeries including the resection of endometriosis and difficult hysterectomies. we are currently working on the establishment of the robot for cancer surgeries including sentinel node resections in endometrial carcinoma with the use of indocyanine green/fluorescence.

Results

during the entire period of 18 months, we performed 31 adnexal surgeries, 62 hysterectomies, 8 fibroid removals, 38 endometriosis resections and 4 sentinel lymph node dissection as well as 10 other surgeries. docking of instruments needs 7 minutes, time for actual surgery is comparable to standard laparoscopy. we met 2 major complications (1 bladder, 1 rectum). the senhance system proved to work stable without the need of special technical support.

Conclusions

currently the use of the senhance robotic system can aid in the performance of gynaecologic surgeries. we want to continue gaining more experience and to establish the routine use of the system for gynaecologic surgeries. the planned implementation of artificial intelligence and further technological improvements could potentially reduce risks and complications of gynaecologic surgeries while providing improved ergonomy for the surgeon during the procedure.

Cervical and rectal endometriosis in postmenopausal woman: a case report

Matea Berović¹, Jelena Pažur¹, Egon Kruezi¹, Ana Bašić¹, Ivan Brlečić¹, Neven Tučkar¹

¹University Hospital Centre Sestre milosrdnice, Gynaecology and Obstetrics, Zagreb, Croatia

Background

Cervical endometriosis is a benign condition, rather uncommon and usually an incidental or retrospective finding in histopathology reports. It can be completely asymptomatic or present with a diverse range of symptoms; from postcoital bleeding to life-threatening haemorrhage which results in hysterectomy. Although it is a rare disease, it co-exists considerably with premalignant and malignant gynaecological conditions. Our case distinguishes itself due to asymptomatic presentation despite the extension of the process to the intestine and presentation at postmenopausal age.

Methods

A 69-years nulliparous woman with no evidence of any previous gynaecologic disease in her medical history was underwent an ultrasonic examination. There was seen a suspicious intracavitary mass therefore she was referred for a hysteroscopy. Her last menstrual period was when she was 53 years old and since then she had not been bleeding. Since the dilatation of the cervical canal failed due to severe stenosis, magnetic resonance imaging (MRI) of the entire pelvis was performed. MRI described a heterogeneous intrauterine cavity mass, but also a suspect infiltration of the myometrium. Differential diagnosis was endometrial neoplastic process grade IA/IB. Moreover, deep pelvic endometriosis infiltrating cervix and muscular layer of rectosigmoid colon was suspected on MRI. Subsequent colonoscopy revealed no serious pathology, and the process in sigmoid colon was rather described as diverticulosis. Rectum did not implicate any pathology. Tumour marker tests (CA125, CEA, CA15-3, HE4, ROMA) were normal with the exception of elevated levels of CA19-9 (40,5 U/mL).

Results

Considering all tests previously done and suspicion of malignant disease, laparotomy was performed in collaboration with the surgical team due to suspected rectosigmoid involvement. Total abdominal hysterectomy and anterior rectal resection with T-T anastomosis was done. During the procedure, strong adhesions of the colon to the cervix and proximal part of the vagina was found. That part of the rectosigmoid colon was indurated with the 4 cm big mass. Histologic examination revealed glandular endometrial polyp, cervical endometriosis, and polypoid endometriosis of the rectum.

Conclusions

We present a case of the 69-years old nulliparous woman with severe cervical stenosis and no previous evidence of any gynaecological disease, who underwent a surgical procedure due to suspicion of uterine malignancy. Histologic examination revealed cervical endometriosis as well as rectal endometriosis without any symptoms.

Evaluation of OSNA method for rapid detection of lymph node metastases in women with endometrial cancer

*Eleonora La Fera*¹, *Alessandro Petrecca*¹, *Giorgia Monterossi*¹, *Stefano Restaino*², *Giovanni Scambia*¹, *Francesco Fanfani*¹

¹Fondazione Policlinico Universitario Agostino Gemelli IRCCS,
UOC Ginecologia Oncologica- Dipartimento per la salute della Donna e del Bambino e della Salute Pubblica,
Rome, Italy

²Azienda Sanitaria Universitaria Friuli Centrale Udine,
Unità di Ginecologia e ostetricia- Dipartimenti di Ostetricia- Ginecologia e Pediatria., Udine, Italy

Background

The objective of this study is to establish the clinical performance of the OSNA method for the detection of sentinel lymph node (SNL) metastases in women with early-stage endometrial cancer (EC) compared to standard Ultrastaging (US).

Methods

This is a prospective, multicentric, observational study, all women with early-stage EC underwent surgical staging with SNL identification. SNLs were serially sectioned at 2 mm slices thickness perpendicular to the longest axis of the node and the odd slices were submitted to ultra-staging, according to our institutional ultra-staging protocol, the even slices were submitted to the OSNA analysis.

Results

Three-hundred-and-sixteen patients were enrolled with 668 SNLs analysed. OSNA assay detected 22 (3,3%) positive SNLs of which 17 (2,5%) micro metastases, and 5 (0,7%) macro metastases, whereas pathological ultra-staging detected 24 (3,6%) positive SNLs of which 15 (2,2%) micro metastases and 9 (1,3%) of macro metastases. Using ultra-staging as a reference method the specificity of 98,4%, the diagnostic accuracy of 96,7% and the negative predictive value of 98,1% were attended. Discordant results were found in 22 SNLs (3,2%) corresponding to 20 patients (6,3%). We found 10 false-positive SNLs, all micro metastases, and 12 false-negative lymph nodes of which 9 micro metastases and 3 macro metastases.

Conclusions

Although only portions of a whole lymph node have been examined with OSNA analysis, it has proved to be highly specific with high diagnostic accuracy, a high negative predictive value, and moderate concordance with the standard US. Therefore, we believe that OSNA is a valid method for analysing lymph node metastases in patients with apparent early-stage EC.

A Case of an Incidental Finding of Polypoid Endometriosis

Liza Pui Chin Tay¹, Carmen Tong¹, Tse Yeun Tan²

¹*KK Women's and Children's Hospital, Department of Obstetrics and Gynaecology, Singapore, Singapore*

²*KK Women's and Children's Hospital, Department of Reproductive Medicine, Singapore, Singapore*

Background

Endometriosis is characterized by ectopic endometrial tissue in extrauterine sites, mainly manifesting as superficial or deeply infiltrating peritoneal lesions and endometriomas. It is a common condition that affects 10% of women of reproductive age globally (WHO, 2021). Polypoid endometriosis is a very rare variant of endometriosis that presents with symptoms differing from the common presentations of endometriosis. We report a rare case of polypoid endometriosis with the aim to educate gynaecologists and pathologists of such a variant.

Methods

We herein report a case of polypoid endometriosis in a premenopausal woman presenting with subfertility and dysmenorrhea. Hystero-salpingo-foam sonography revealed bilateral blocked fallopian tubes, endometriotic cyst and multiple endometrial polyps. She underwent a diagnostic laparoscopy which identified a friable yellow mass in the pouch of Douglas. Histology confirmed the mass to be polypoid endometriosis.

We also looked at other case reports of polypoid endometriosis reported worldwide to identify the common clinical, intra-operative and histopathological findings to allow for easier diagnosis.

Results

Polypoid endometriosis is a rare benign variant of endometriosis with histopathological features resembling an endometrial polyp. Endometriosis commonly presents as chronic pelvic pain, dysmenorrhea, dyspareunia, irregular menstrual cycles and infertility. On the contrary, polypoid endometriosis presents with mass effects of pelvic and vaginal polypoidal mass, large intestinal obstruction, abdominal pain, and per vaginal bleeding. It commonly manifests as a polypoidal mass and may mimic malignant neoplasms symptomatically, intra-operatively and histopathological resulting in extensive workup and surgical resections.

Conclusions

Although endometriosis is a common gynaecological condition, much lesser is known about polypoid endometriosis. Gynaecologists and pathologists should be aware about this rare benign variant so as to avoid extensive investigations and surgeries.

Postpartum Hemoperitoneum in Patient with History of Surgery for Endometriosis.

Zuzana Marvanova¹, Katarina Ivankova¹, Jan Drahonovsky¹

¹Institute for Mother and Child Care, Endometriosis Centre, Prague, Czech Republic

Background

To present a rare case of uterine vein rupture nine hours after uncomplicated vaginal delivery resulting in severe hemoperitoneum in patients with endometriosis. We report intraoperative findings and following procedures.

Methods

Case report

Results

A 26-year-old nulliparous woman was admitted to the hospital for labor induction. Patient underwent laparoscopic surgery for ovarian endometriosis two months prior to conceiving.

Mechanical induction with Foley catheter was used. Nine hours after delivery, the patient suddenly had severe abdominal pain and hypotension. Transabdominal ultrasound revealed haemoperitoneum. At laparotomy, we identified a complete rupture of broad ligament in the left uterine margin with uterine vein as a source of bleeding, foci of endometriosis described in cul-de-sac and on the left pelvic wall. We performed ligation of internal iliac arteries on both sides to control the blood loss. Bleeding was definitively controlled with single cross stitches and a fibrin sealant patch placed at the lesion. Total blood loss was 2500 ml.

The patient was discharged on the fifth postoperative day, fully recovered and her fertility was preserved.

Conclusions

Rupture of uterine vessels ranks among very rare complications in pregnant women or in postpartum period. However, this type of late postoperative complication will likely be more frequent as laparoscopic resection of deep infiltrating endometriosis become common method to reduce endometriosis-associated pain. Finally, it is necessary to be aware of those rare cases as they represent life-threatening situations which require urgent response and multidisciplinary cooperation.

Intrauterine Pregnancy with Maternal Collapse? Could it be scar ectopic

Zahra Azeem¹, Evangelia Bakal²

¹*University Hospital Birmingham, Obstetrics and Gynaecology, Birmingham, United Kingdom*

²*University Hospital Birmingham, Obstetrics & Gynaecology, Birmingham, United Kingdom*

Background

With the increase in the incidence of caesarean section, any subsequent risks of placenta previa, placenta accreta, and ectopic pregnancy have increased. Caesarean section scar pregnancy is the rarest form of ectopic pregnancy with incidence being 1 in 2000. Caesarean scar ectopic pregnancy poses a diagnostic and management challenge, and if not diagnosed and adequately treated in early pregnancy, it may lead to considerable maternal morbidity or mortality. With the increase in the incidence of caesarean section, any subsequent risks of placenta previa, placenta accreta, and ectopic pregnancy have increased.

Methods

Case Report: A 35-year-old woman was admitted in A&E department with collapse at 12 weeks of gestation. On initial assessment patient had marked tenderness in LIF and no signs of peritonism. A gynaecological USS was carried out and found an alive intrauterine fetus. The findings were confirmed from the dating scan performed at 11 weeks. FAST scan showed free fluid of 3 litters in the cavity. General surgeons were called in for review and a plan was made to shift her to theatre as a joint procedure to find the cause of bleeding. On laparoscopy an ectopic pregnancy was seen invading the left uterine artery. Patient ended up having a hysterectomy.

Results

Discussion: One of the types of ectopic pregnancy is caesarean scar ectopic pregnancy in which the pregnancy implants onto the scar in uterus. A uterine scar is deficient in decidua basalis or contains a faulty layer of fibrinoid degeneration. This ectopic pregnancy is not surrounded by decidualized endometrium; in fact, it implants into fibroid scar tissue and myometrium. This pregnancy is abnormal from the start and requires medical or surgical management to prevent further harm.

Conclusions

Early diagnosis of caesarean scar ectopic gestation using transabdominal and transvaginal ultrasound is of paramount importance to prevent morbidity and mortality. All the gynae assessment units need to have a diagnostic and management protocol and a high index of suspicion in patients presenting with abdominal pain and a previous scar.

The risk of uterine rupture after myomectomy: a systematic review and meta-analysis

Mez Aref-Adib¹, Wedisha Gankanda¹, Natasha Daniels¹, Zoe Thursz¹, Michail Sideris², Funlayo Odejinmi¹

¹*Whipps Cross University Hospital, Obstetrics and Gynaecology, London, United Kingdom*

²*Barts health NHS trust, Obstetrics and Gynaecology, London, United Kingdom*

Background

Fibroids are the most common uterine tumour. 30 percent of symptomatic women undergo myomectomy and future pregnancies can be complicated by uterine rupture, but the level of this risk remains debatable. We performed a systematic review to determine the pooled risk of uterine rupture (primary outcome) in pregnancy after open or laparoscopic myomectomy. We aimed to identify the impact of myomectomy on mode of delivery, fetal outcomes, intrauterine death, intrapartum still birth and excess blood loss (secondary outcomes).

Methods

We followed a prospective protocol according to PRISMA guidelines. We searched [MEDLINE, Dynamed, Cochrane Library] from inception to May 2021. We used fixed effects meta-analysis to calculate pooled risks with 95% confidence interval for uterine rupture. Heterogeneity was reported using I².

Results

Our search yielded 82 articles, of which 20 were included in the final meta-analysis, including 11978 women. The overall pooled risk of uterine rupture was 0.274[0.189-0.385, p=0.093, I²=30.9%]. Uterine rupture occurred from 10– 39.4 weeks gestation, with a median of 33.0 (range 29.0–35.25). The interval between myomectomy and pregnancy ranged from 1.5 to 96 months (median 19.00).

Conclusions

The risk of uterine rupture following myomectomy remains small (<1%). Due to other previous uterine surgery (e.g., Caesarean section), identifying the true risk of uterine rupture following myomectomy remains challenging. Given the importance of the topic, larger prospective observational studies and a national database may be beneficial to obtain robust evidence to counsel patients effectively.

Why and where are interventions performed in England for fibroids: a retrospective analysis of myomectomy for uterine fibroids in England (2018-2019)

Mez Aref-Adib¹, Funlayo Odejinmi¹, Rebecca Mallick², Sophie Strong³, Natalie Cooper¹, Anna Mcdougall⁴

¹Whipps Cross University Hospital- Barts Health NHS Trust, Obstetrics and Gynaecology, London, United Kingdom

²Princess Royal Hospital- Brighton and Sussex University Hospitals NHS Trust, Obstetrics and Gynaecology, Brighton, United Kingdom

³The Royal London- Barts Health NHS trust, Obstetrics and Gynaecology, London, United Kingdom

⁴North Middlesex University Hospital, Obstetrics and Gynaecology, London, United Kingdom

Background

Uterine fibroids are the most common tumour of the female genital tract. A quarter of women with fibroids are symptomatic of which a proportion will need to have an intervention. Due to a lack of high-quality patient information available and misconceptions regarding management options and outcomes, women frequently do not access appropriate treatment. In addition, there is controversy amongst clinicians as to which interventions to offer due to the lack of high-quality research data on outcomes for the management of uterine fibroids.

The aims of this study are to explore what interventions are available for fibroids in England and to assess whether equal access to these interventions exist in England's National Health Service. Determining these factors will empower women to make informed decisions regarding where to access care.

Methods

A retrospective analysis of Hospital Episode statistics data obtained from NHS Digital on all women who had an intervention for fibroids in 2018/19 was performed.

Results

There were 27,892 interventions for fibroids: 12,008 hysterectomies (43%), 1666 uterine artery embolisations (5.9%), 2970 myomectomies (805 laparoscopic and 2165 open). Nationally 10% of interventions were myomectomy. 40.5% of these were performed in London with the proportion of myomectomies in other regions ranging from 5-11%. Across England, 27% of myomectomies were performed laparoscopically and 73% open. Overall laparoscopic rates of surgery ranged from 20-34% with no statistical difference per region.

Conclusions

London is the region with the highest rate of laparoscopic myomectomy. The majority of myomectomies in the UK are still performed by an open approach. The number of myomectomies carried out by individual trusts varied widely and, in some hospitals, only open myomectomies were performed, suggesting a lack of access to laparoscopic intervention. Whilst this data set is limited by its lack of corresponding clinical details regarding presenting symptoms, details of surgeon experience or capability and the suitability of procedure for each woman, it is in our opinion a vital step in standardising fibroid care in England. We propose a national prospective database to investigate clinical details of and outcomes for women requiring interventions for uterine fibroids to facilitate evidence based, informed decision making.

Heavy menstrual bleeding – Are we choosing surgery judiciously?

Rahul Savant¹, Smitha Raghavan¹, Samendra Roy¹

¹University Hospital of North Tees, Obstetrics and Gynaecology, Stockton-on-Tees, United Kingdom

Background

Heavy menstrual bleeding (HMB) is the most common condition presenting to specialist gynae clinics. It constitutes high volume referrals and can have significant impact on the QOL of the patient. It is also a sign of malignancy in the reproductive organs of high-risk women. Appropriate assessment of cause of bleeding (especially ruling in/out malignancy) and management with least possible intervention constitute best medical practice in the management of women with AUB

Methods

Objectives:

To improve quality of management of women with HMB, through appropriate use of medical options and ensuring thorough counselling and informed consent if surgery is opted.

Materials and methods: Retrospective audit against NICE guidance- CG 44

Sample size	25 cases
Time period	February'18 – February '20
Case identification	Patients who have had Novasure ablation, Myomectomy, hysterectomy for HMB. Identified through Report Manager by date.

Results

Nice guidance 44 recommendation	Our performance
1.2.6- Carry out FBC in all patients with HMB	100% had FBC
1.2.7 – Coagulation if personal or family history of coagulation disorders or HMB since menarche	92% did not have Coagulation screen 8% who had – no clinical indication
1.3.4- Offer hysteroscopy if risk of endometrial pathology Persistent IMB, on tamoxifen or failed medical management	56% had hysteroscopy- all for either abnormal bleeding pattern or pre ablation or >45 years of age
1.3.11- Do biopsy only with hysteroscopy- do not do blind biopsy	79% had biopsy with hysteroscopy 21% had biopsy in context of myomectomy without hysteroscopy
1.3.12- offer US if suspected large fibroids/clinically difficult to assess	88% had US 69% of this had large or multiple fibroids 31% were normal 68% (17) had various medical options > 1year - 10 6-12 months - 2 <6 months 3 uncertain - 2 2/17 (12%) had all meds 8/17 (47%) had 2 or more types Only 24% had LNG-IUS (first medical management)
1.5.5- Try alternative pharmacological options (at least 6 months in primary care) not already tried or surgical management- ablation or hysterectomy	
1.5.6- consider hysteroscopic removal for endometrial polyps or fibroids	100%
1.2.10 - Do not undertake TSH unless indicated	76% had TSH- 12% of this had clinical indication 8% did not have either – 2 patients- one myomectomy, other hysterectomy
Hysteroscopy, biopsy before treatment in over 45	

Conclusions

Women with HMB were appropriately managed in our unit, as per the NICE guideline. Surgical option was chosen after exhausting medical options if possible.

Working above the level of umbilicus. Can robotic surgery be a surgeon's best ally?

Eleni Karatrasoglou¹, Vasiliki Chatzirafail¹, Aiki Tserkezoglou¹, Aristeidis Mpakas², Aikaterini Pavlaki³

¹Euroclinic Hospital, Department of Gynecologic Surgery, Athens, Greece

²Euroclinic Hospital, Department of Anaesthesiology, Athens, Greece

³Iaso Hospital, Department of Histopathology, Athens, Greece

Background

we describe different technical modifications with the technique of robotic surgery, specifically in cases of very large pathology of the uterocomple. all cases were performed by the same surgeon in our institution.

Methods

we include patients who underwent robotic-assisted laparoscopic myomectomy for multiple, bulky tumors and complex hysterectomies for the period from april 2000 to june 2020.

Results

For the majority of cases robotic surgery can provide the most effective, least invasive treatment for uterine fibroids, especially in cases of bulky and multiple leiomyomas and uteri with excessive uterine weight. Robotic approach has already proven its value and can also be preferred for cases with higher complexity. therefore, we are presenting the indicated robotic approach in the following cases: 1. myomatosis: multiple myomas and diffuse myomatosis, bulky fibroids which reach or exceed the level of umbilicus, highly vascularized myomas and leiomyomas in challenging locations and 2. Uteri exceeding 250gr. challenges and limits of robotic surgery remain the size and the number of myomas. However, the more experienced the robotic surgeon is, the more these limits are pushed, taking advantage of new techniques such as the use of haemostatic agents and the new software of perioperative imaging (augmented reality software).

Conclusions

Robotic surgery is feasible for managing very challenging cases of very large uteri which surpass the level of umbilicus. It is a safe procedure with acceptable longer operative time, hence the selection of suitable patients for the robotic approach should remain uncompromised issue.

Hysteroscopic resection of a uterine septum assisted by translumination technique

Gregor Olmes¹, Erich-Franz Solomayer¹, Romina-Marina Sima², Bashar Haj Hamoud¹

¹Saarland University, Department of Gynecology- Obstetrics and Reproductive Medicine-, Homburg/Saar, Germany

²“Carol Davila” University of Medicine and Pharmacy, Department of Obstetrics and Gynecology-, Bucharest, Romania

Background

Hysteroscopic resection is the standard technique for septate uterus. The translumination technique combines hysteroscopic diaphanoscopy within a laparoscopy. Translumination technique is described for surgical treatment of congenital uterine malformations and isthmoceles. In this case report we present a hysteroscopic resection of a uterine septum assisted by translumination technique.

Methods

A 28-years old nulligravida came for endoscopic treatment of a uterine septum. The patient had a Polycystic Ovary Syndrome. A hysteroscopic resection of the uterine septum combined with a laparoscopic drilling of the ovaries and a chromopertubation was scheduled.

Results

The surgery started with an operative hysteroscopy and confirmed a total septation of the uterus. Only the right part of uterus was visible. The ostium of the fallopian Tube was visible. The surgery was switched to a laparoscopy and showed no other uterine abnormalities. Pelvic endometriosis was identified (#Enzian P1) and resected. Ovary drilling was performed. Then translumination technique was used. Laparoscopic light was faded to identify the position of the hysteroscopic scope. Before resection of the uterine septum, only the right part of the uterus was translucent. Then stepwise resection of the uterine septum followed under laparoscopic monitoring. After complete resection of the uterine septum, the uterus showed a transparency on both sides. Then chromopertubation was performed and showed permeability on both Fallopian tubes. The postoperative haemoglobin level revealed Hb: 12,6 g/dl. The patient left the hospital two days after surgery in a good status.

Conclusions

Translumination technique facilitates hysteroscopic resection of septate uterus. It is a simple and practicable option for correct resection of uterine septum.

Recurrent struma ovarii – a case report of a diagnosis with a 2-year gap

Ana Varejão¹, Mafalda Laranjo², Gonçalo Miranda³, Rita Sequeira Campos¹

¹Hospital Pedro Hispano, Gynaecology and Obstetrics, Matosinhos, Portugal

²Hospital Pedro Hispano, Gynecology and Obstetrics, Matosinhos, Portugal

³Hospital Pedro Hispano, Pathology Department, Matosinhos, Portugal

Background

To present a case of recurrent benign struma ovarii. Struma ovarii is a rare monodermal teratoma predominantly composed of mature thyroid tissue (>50% of the overall tissue), most commonly between the ages of 40 and 60 years. It represents approximately 1% of ovarian tumours. Symptoms of struma ovarii are nonspecific, and they are usually asymptomatic and diagnosed incidentally. The definitive diagnosis is made by histological examination. Struma ovarii can be classified as benign or malignant, depending on the histological findings. Surgery is the main treatment option.

Methods

Short literature review and report of a case of recurrent struma ovarii with a 2-year gap.

Results

We present a case of a woman in her 40's who was referred to the Gynaecology Department for an incidental finding in CT scan of a complex ovarian mass, associated with symptoms of pelvic discomfort. Images showed a 10cm right pelvic mass with solid components suggesting ovarian teratoma. Tumour markers were negative. She underwent surgery (laparoscopic right adnexectomy) and histological examination showed an ovary totally transformed into a cystic mature teratoma, struma ovarii type. After surgery, thyroid function was normal. Two years later, she was again referred to a Gynaecological Department for findings of a complex multiloculated left ovarian mass of 5cm, with septa and multiple hypercogenic foci. Tumour markers were negative, and she was euthyroid. Left laparoscopic adnexectomy was performed. Histological examination of the left ovary showed total transformation into struma ovarii, without identifiable ovarian parenchyma and with no signs of malignancy.

Conclusions

Struma ovarii is an unusual tumour generally found incidentally on the surgical specimen of a teratoma. Women with struma ovarii usually present with pain and/or a pelvic mass. Clinical and biochemical features of hyperthyroidism are uncommon in women with struma ovarii, occurring in less than 5 to 8 percent of cases. Differential diagnoses include functional ovarian cyst, adnexal abscess, hydrosalpinx, endometrioma, ectopic pregnancy and ovarian tumours. Our case shows that despite its low risk of recurrence, recurrence of a benign struma ovarii is possible and should be included in the differential diagnosis.

Could the clinical factors and extent of symptoms affect the occurrence of pregnancy in infertile endometriosis patients after reproductive surgery?

Khayal Gasimli¹, Dilara Akpinar-Isici¹, Annette Bachmann¹, Sven Becker¹, Morva Tahmasbi Rad¹

¹*J. W. Goethe-University Frankfurt, Department of Gynecology and Obstetrics, Frankfurt, Germany*

Background

Endometriosis is a benign pelvic inflammatory disease that causes diverse chronic symptoms and infertility in reproductive-age women. Up to 47% of endometriosis patients (pts.) develop infertility and require multimodal management and long-term care. Our study aims to investigate the role of the extent of clinical symptoms and factors on occurrence of pregnancy after reproductive surgery.

Methods

A total of 102 consecutive infertile endometriosis pts. enrolled in this retrospective analysis. All patients underwent reproductive surgery. Correlation between clinical factors and pregnancy rate were analysed using the log rank test and the Kaplan- Meier method. Univariate and multivariate analyses were performed with the Cox regression model.

Results

Seventy-one pts. (69.6%) could achieve pregnancy in the course of their endometriosis treatment, while the remaining 31 pts. (30.4%) were not pregnant with or without ART after more than three years of the follow-up period. The median age of patients was 33,3 years (range: 21 - 46) and median the follow-up was 70 months (range: 36-197). The clinical factors such as age ($p=0.56$), BMI ($p=0.53$), dysmenorrhea ($p=0.32$), dyspareunia ($p=0.33$), chronic pelvic pain ($p=0.96$), concomitant diseases ($p=0.64$), localization of endometriosis ($p=0.58$) (except bowel), simultaneous uterine diseases (fibroids ($p=0.08$) (except submucosal, T0-2 according the FIGO classification), septum ($p=0.8$) and polyps ($p=0.28$) were not associated with occurrence of pregnancy. Its statistical correlations could be revealed with the duration of infertility ($p=0,02$), previous abdominal and pelvic surgeries ($p=0.03$), deep infiltrating endometriosis (DIE) ($p=0.004$), bowel endometriosis ($p=0.02$), the increasing number of localization of endometriosis lesions ($p=0.006$) and surgical intervention of ovaries ($p=0.02$), rASRM score ($p=0.0002$), pelvic adhesions ($p=0.001$), and complete endometriosis resection ($p=0.001$). Solely, complete endometriosis resection could influence the protective of the occurrence of pregnancy.

Conclusions

Complete endometriosis resection within the framework of reproductive surgery could have a protective effect on the occurrence of pregnancy in infertile women. Further prospective and multicentre research may allow validating these results

Anti-Müllerian Hormone (AMH) testing prior to endometrioma surgery in reproductive age women not seeking assisted fertility care: a survey of current UK clinical practice

Sarah Wali¹, Akanksha Garg¹, Kate Maclaran¹, Amer Raza¹, Robert Richardson¹

¹Chelsea and Westminster Hospital, Obstetrics and Gynaecology, London, United Kingdom

Background

There is evidence that endometriotic cystectomy, the gold standard for endometrioma surgery, is associated with a reduction in ovarian reserve. Anti-Müllerian Hormone (AMH) is a well-established marker of ovarian reserve. Current data regarding measuring serum AMH in women undergoing endometrioma surgery is limited.

Objective

To study current practice of serum AMH testing prior to endometrioma surgery in women who are not seeking assisted reproduction.

Methods

A cross-sectional study of current practice in the United Kingdom was conducted using an online survey consisting of 10 closed-ended questions.

Main outcome measure

The proportion of gynaecologists who have access to AMH testing, perform pre- and post-operative AMH testing in NHS and Private practice, and considerations of other risk factors.

Results

52/121 (43%) responses were received from consultants working at 39/67 (58%) BSGE endometriosis centres across the UK.

Preoperative counselling regarding the impact of endometrioma surgery on ovarian reserve:

- 79% routinely counsel
- 17% only counsel if family is not complete
- 4% do not counsel at all.

Preoperative AMH testing is considered:

- Desirable by 50% (of which 73% have NHS access)
- Mandatory by 21% (of which 91% have NHS access)
- Not evidenced/ not useful by 21% (of which 36% have NHS access)

There is an association between access to the test and its perceived importance or usefulness.

Routine testing is performed:

- Of those that have NHS access to AMH testing (35/52): 69% test preoperatively, 38% test postoperatively
- Of those that perform Private cystectomy (35/52): 54% both pre and postoperatively.

There is an association between access to the test and its routine use.

Conclusions

There is widespread pre and postoperative AMH testing in this patient group in NHS and Private practice. If there is access to the test, consultants are likely to consider it as mandatory or desirable ($p < .05$). Only 21% consultants view this test as not evidenced or useful. The use of AMH is strictly in the management of the infertile woman as levels in women without infertility do not correlate with fertility potential or the time to pregnancy. AMH should not be used to predict fertility or onset of menopause in women not diagnosed with infertility.

Feasibility of analysing robotic surgery using Intuitive Data Recorder (IDR).

Felix Neis¹, Sara Brucker¹, Christina Walter¹, Tjeerd Dijkstra¹, Bernhard Krämer¹

¹University of Tübingen, Gynecologie and Obstetrics, Tübingen, Germany

Background

The curriculum for approval as a daVinci surgeon requires training on the pelvitrainer and participation in online training courses. The skills learned will then have to be transferred to the operating room.

Methods

Collection of prospective surgical data using Intuitive Data Recorder (IDR) of robot-assisted total laparoscopic hysterectomies (rTLH) as part of the SOS trial. For analysis, the steps of rTLH were annotated and assigned to the respective surgical steps based on the recorded video.

Results

After a short learning/initiation phase, complete data sets of the surgeries could be recorded. It can be demonstrated in the analysis of the first 6 complete cases that rTLH is performed in a standardized manner. In experienced surgeons, the sequence of surgical steps and the time required for this is comparable. The frequency of camera movement, use of clutches and use of electrical energy for coagulation and cutting can be shown and compared for each surgical step.

Conclusions

Using IDR, surgeries of individual surgeons can be analysed and compared with those of other surgeons. Learning curves can be visually displayed

Can self-perception evaluation of heavy menstrual bleeding correspond to pictorial methods?

Sabrina Reppuccia¹, Consuelo Russo², Giulia Monaco², Serena Riccio², Giorgia Soreca², Caterina Exacoustos²

¹University of Naples Federico II,

Department of Neuroscience- Reproductive Sciences and Dentistry- School of Medicine, Naples- 80131, Italy

²University of Rome 'Tor Vergata', Department of Surgical Sciences- Obstetrics and Gynecological Unit, Rome, Italy

Background

The evaluation of heavy menstrual bleeding (HMB) is still a problem in primary care today because it's based on subjective evaluation on blood flow amount, that not always correspond to HMB, or on pictorial assessment which are not very used. The evaluation of HMB is also important to determine the impact of adenomyosis or uterine fibroids on quality of life. The aim of our study is to correlate menstrual pictograms to self-perception of menstrual blood loss (MBL), in order to evaluate if the only subjective evaluation is adequate to define HMB.

Methods

Premenopausal women, not on hormone therapy, who performed ultrasound scan (US) underwent an evaluation of MBL during menstrual period. All patient with self-perceived light, normal, heavy or very heavy menstrual periods were asked to complete two types of menstrual pictogram: PBAC (Pictorial blood loss assessment charts, Higham et al. 1990) and Magnay MP (Magnay menstrual pictogram, 2014). Menstrual bleeding is defined heavy if PBAC score is ≥ 150 and MP is ≥ 80 ml.

Results

100 consecutive patients who underwent US, met the inclusion criteria. The mean age was 32 years old. The mean PBAC score was 182 while the mean MP value was 173ml. About the self-perception, 65% of patients described menstrual bleeding as heavy, 35% as normal, nobody as light or very heavy.

Regarding PBAC score, 25% of patients have score < 100 , 55% of patients ≥ 150 , and 20% of patients > 300 .

Regarding MP, 35% of patients have MP < 80 ml, 65% of patients ≥ 80 ml, 50% of patients > 150 ml, finally 15% of patients have MP value > 300 ml.

All patients with PBAC score < 100 (25 patients) reported as normal their menstrual period. Only 15 patients with PBAC > 100 but < 150 referred HMB. With PBAC ≥ 150 , HMB is reported in 91% of patients.

About MP evaluation, the patients defined their menstrual bleeding as normal in 86% of cases with MP < 80 ml. If MP was ≥ 80 ml, the 92% of patients referred HMB. Considering MP > 150 ml, HMB is reported in 90% of cases.

Finally, all patients with PBAC and with MP > 300 defined their menstrual bleeding as heavy but not very heavy.

In patients less than 25 years old (25%), five patients referred normal menstrual period regarding PBAC ≥ 150 , whereas in patients ≥ 25 this discrepancy isn't seen.

There's 15% of discordance between the two pictorial systems in case of HMB.

Conclusions

Every method to assess MBL has limitations. Our results show that self-evaluation isn't the best method because it underestimates the intensity of the menstrual bleeding especially in young patients and in case of very HMB. Nevertheless, self-reported HMB are quite in accordance with pictorial system in 77% of cases.

Ovarian ectopic pregnancy; a diagnostic dilemma

Abhijeet Shah¹, Ahmed Mohamed Abdelmohsen², Charlotte Wyeth³, Catherine Bear³, Danielle Alexander⁴

¹*East Kent Hospitals NHS Trust, Gynaecology, Ashford, United Kingdom*

²*East Kent University Hospitals NHS Trust, Obstetrics & Gynaecology, Ashford, United Kingdom*

³*East Kent University Hospitals NHS Trust, Obstetrics & Gynaecology, Ashford, United Kingdom*

⁴*East Kent Hospitals NHS Trust, Obstetrics & Gynaecology, Ashford, United Kingdom*

Background

Primary ovarian pregnancies are one of the rarest types of extrauterine pregnancies, with an estimated incidence rate of approximately 1% to 6% of all diagnosed ectopic pregnancies. Sonography can be challenging in diagnosing ovarian ectopics.

Methods

A 28-year-old woman, P1, previous vaginal delivery presented with vaginal spotting and crampy abdominal pain for 2 days. Her last menstrual period was 5 weeks ago, and pregnancy test was positive. She had no medical or surgical history of note. Her BMI was 28 and no previous sexually transmitted infections, this was planned pregnancy and was taking 400 micro grams of folic acid.

Results

Initial HCG levels were 875 and two subsequent trans-vaginal scans suggested likely retained pregnancy tissues with the first scan an empty gestational sac of 24 mm. Medical management of miscarriage was offered and accepted. She was discharged to have pregnancy test in 10 days' time as the unit policy.

She presented 2 weeks later with persistent pregnancy test positive, and her HCG levels increased to 15000. TVS scan revealed a possible ovarian ectopic with foetal pole. There was no free fluid noted and no other adnexal masses. She was counselled for laparoscopy and possible partial oophorectomy +/- salpingectomy.

Laparoscopy confirmed right ovarian ectopic pregnancy and after removal of ovarian gestation, ovary started to bleed. Despite all haemostatic measures, bleeding did not stop and hence oophorectomy was performed. Patient made uneventful recovery and her HCG levels were below 2 after a week. Histology confirmed ovarian ectopic with chorionic villi.

Conclusions

Ectopic pregnancies are one of the leading causes of morbidity and mortality in a woman of reproductive age. Ultrasonography can be challenging in diagnosing ovarian ectopics and so does HCG levels. Laparoscopy should be considered as in this case for confirming diagnosis and surgical management.

Correlation of haemoglobin drop and the occurrence of intraoperative and postoperative complications in the context of gynaecological laparoscopic interventions

Askin Kaya¹, Marta-Anna Lazar-Danielczok¹, Marc-Philipp Radosa², Julia Sarah Maria Zimmermann¹, Erich-Franz Solomayer¹, Julia Caroline Radosa¹

¹Saarland University Hospital, Department of Gynecology- Obstetrics and Reproductive Medicine, Homburg- Saarland, Germany

²Klinikum Bremen Nord, Department of Gynecology and Obstetrics, Bremen, Germany

Background

The aim of this retrospective analysis was to investigate the correlation of haemoglobin drop (defined as the difference between the last preoperative and the first postoperative haemoglobin value in g/dl) with the occurrence of intra- and postoperative complications in gynaecological laparoscopic interventions and to identify risk factors for a haemoglobin drop > 2 g/dl and respectively for a transfusion of erythrocyte concentrates.

Methods

All patients who underwent laparoscopy at the Department of Gynaecology, Obstetrics and Reproductive Medicine at the Saarland University Hospital between 2013 and 2020 were retrospectively identified using a prospectively compiled clinical database. Binary logistic regression analysis was performed to identify independent risk factors for a haemoglobin drop > 2 g/dl and respectively for a transfusion of erythrocyte concentrates.

Results

Out of a total of 3968 patients, 3871 were included in the final analysis. Median haemoglobin drop was 1.1 g/dl (-4.2 - 13 g/dl). Significant correlation between haemoglobin drops and the occurrence of intra- and postoperative complications was shown ($p \leq 0.01$). On multivariate analysis, body mass index (OR 0.96, 95% CI 0.95 - 0.98, $p \leq 0.01$), operative time (OR 1.00, 95% CI 1.00 - 1.01, $p \leq 0.01$), postoperative length of stay (OR 1.04, 95% CI 1.00 - 1.07, $p = 0.04$), the degree of difficulty of the laparoscopic procedure according to Barakat ($p \leq 0.01$) and the occurrence of intraoperative (OR 2.03, 95% CI 1.35 - 3.04, $p \leq 0.01$) and postoperative complications (OR 1.39, 95% CI 1.00-1.94, $p=0.04$) were independent risk factors for a haemoglobin drop > 2 g/dl. Independent risk factor for an intraoperative transfusion of erythrocyte concentrates was operative time (OR 1.01, 95% CI 1.01 - 1.02, $p \leq 0.01$). As for a postoperative transfusion of erythrocyte concentrates, operative time (OR 1.01, 95% CI 1.00-1.01, $p \leq 0.01$), intraoperative transfusion (OR 6.44, 95% CI 1.81 - 22.92, $p \leq 0.01$) and the occurrence of intraoperative complications (OR 4.27, 95% CI 1.59 - 11.44, $p \leq 0.01$) were identified as independent risk factors.

Conclusions

Present data show that there is a significant correlation between haemoglobin drop and the occurrence of intraoperative and postoperative complications. With this retrospective study and the determination of independent risk factors a representative risk collective was identified. This might help to develop strategies to further reduce complications.

Infertility and Endometriosis: when should we perform the laparoscopic surgery and when can we expect the pregnancy, 10-year experience of a university centre

Morva Tahmasbi Rad¹, Dilara Akpınar², Khayal Gasimli², Annette Bachmann², Sven Becker²

¹University of Frankfurt, Department of Gynecology and Obstetrics, Frankfurt, Germany

²University of Frankfurt, Department of Gynecology and Obstetrics, Frankfurt am Main, Germany

Background

Endometriosis has been considered as the main cause in 25-50% of women with infertility. Laparoscopy is an important intervention in these group of patients. The aim of our study was to evaluate the effect of laparoscopy on the time from operation to pregnancy and to examine the best time to perform such operations.

Methods

The data of 695 patients who have had laparoscopic intervention with the diagnosis of endometriosis during 2007 until 2017 in the university hospital of Frankfurt-Germany have been collected retrospectively and the number of 102 patients with infertility have been followed up for median of 70 months (range: 36-197). The data has been analysed with BiAS 11.10.

The cumulative pregnancy rate in several groups have been compared with Log Rank test and the Kaplan Meier methods. In all variables also the predictive influence of time until the pregnancy has been investigated using univariable and multivariable cox regression. The p-value less than 0.05 has been defined as statistically significant.

Results

The highest pregnancy rate was reached on the 7th month after the operation (7.8%). In rASRM stage 3, the highest postoperative pregnancy rate was 5-6 months after the operation (n=4, 25%) while in rASRM stage 4 was 5 to 8 months (13.8%). The mean (\pm SD) time until the pregnancy was 10.8 ± 9.4 and the median was 8 months.

The cumulative pregnancy rate increased in first to second year more than 10% (cumulative pregnancy rate 61.8%, n=63). From the 38th postoperative month, the cumulative rate of pregnancy was stable by 69.6%, no other pregnancies. The mean time of the infertility was 40 months. The longer was the time of the infertility the longer was the time from the operation until the pregnancy p=0.007). With each year of infertility (without any therapy) the chance of pregnancy will be reduced from 4.6 to 26 % (95%CI of the Hazard ratio).

Conclusions

Performing the laparoscopic therapeutic intervention as soon as possible in case of fertility has the statistically significant effect on the time from the operation until the pregnancy. The highest peak of cumulative pregnancy rate will be achieved in the first 2 years after the operation. After 38th month the cumulative pregnancy rate will be stable.

Patient satisfaction outcomes following laparoscopic excision of endometriosis in a private set up in the United Kingdom

Ahmed Mohamed Abdelmohsen¹, Abhijeet Shah¹, Catherine Bear¹, Gaurab Gurung¹, Robyn Patrick²

¹East Kent University Hospitals NHS Trust, Obstetrics & Gynaecology, Ashford, United Kingdom

²Maidstone & Tunbridge Wells NHS Trust, Obstetrics & Gynaecology, Tunbridge Wells, United Kingdom

Background

Patient's satisfaction after a laparoscopic surgery can be subjective due to varying pain thresholds and expectations following the surgery. Pain scores and quality of life index are important in determining outcomes and a long follow up is essential to understand the sustainability of successful surgery.

Methods

During a 24-month period from February 2017 until January 2019, 50 consecutive women with suspected endometriosis +/- endometrioma, who were complaining of pelvic pain, underwent laparoscopic excision surgery.

A laparoscopy was performed by the same surgeon and exclusion criteria included sub-fertility patients, pathology other than endometriosis and involved 3 port laparoscopy. Excision was performed with scissors diathermy or HARMONIC ACE®+7 Shears. Hemostasis was achieved at the end of procedure and no complications were noted. There was no readmission of patients following the surgery. Five women were removed from the follow up as they were found to have deep infiltrating endometriosis and referred to the BSGE endometriosis centre. Forty-five women were followed at 2 months and 12 months after the surgery. Out of 45 women, 25 women opted for Mirena IUS at the time of surgery. Twenty women opted for progesterone pills such as Cerelle and five opted for combined oral contraceptive pills.

Visual analogue scores for pelvic pain were completed pre- and postoperative at 2 and 12 months. Patient satisfaction was scored from 1 to 10. A score of 1–4 was considered "dissatisfied," 5–8 was "satisfied," and 9-10 was "very satisfied." Scores were compared pre-operatively and at 2 months and 12 months.

Results

The demographic details of the patients include the mean age of the women was 24 years (range 18-40). 5/45 (11.3%) patients had deep seated infiltrating endometriosis or revised AFS stage IV disease and did not have rectal shaving or recto-sigmoid dissection of endometriosis due to the private Hospital policies. BMI ranged from 16-42 with average of 28. There was no previous laparotomy in the group.

30/45 women (66.67%) had excision with Harmonic ACE and rest with scissor diathermy.

The mean score for dysmenorrhoea, dyspareunia and non-cyclical pain had reduced at 12 months to 25/45 (55.55%) at subsequent follow up. Patient satisfaction score: At 12 months, 38 women (84.4%) were satisfied (scores of 5–8) or very satisfied (scores of 9 or 10) with the treatment and 7 patients (15.5%) were dissatisfied (score < 5).

Conclusions

This was a simple population cohort study with pain score and satisfaction scores which was easier and quicker to undertake at the follow up appointments. Endometriosis excision surgery does need longer follow up and it is prudent to see them after 12 months of initial surgery to quantify successful outcomes in regard to patient satisfaction.

Early non-invasive ultrasound diagnosis of endometriosis in young patients <25 years old: follow up of the disease and symptoms

Elvira Nocita¹, Consuelo Russo¹, Serena Riccio¹, Giorgia Soreca¹, Francesco Giuseppe Martire¹, Caterina Exacoustos¹

¹University of Rome "Tor Vergata", Department of Surgical Sciences Obstetrics and Gynecological Clinic, Rome, Italy

Background

the aim of the study is to assess in young patients < 25 years old, with non-invasive ultrasound (US) diagnosis of endometriosis, the evolution of the disease and symptoms during a follow up period more than one year.

Methods

patients <25 years old from our Gynaecological Ultrasound Unit with ultrasound diagnosis of endometriosis and a follow up period more than one year were included in this study. All patients showed at least an US features of endometriosis. Medical history, symptoms and kind of therapy were collected as usual before each follow up ultrasound examination. At US scan accurate evaluation and measurements of the endometriotic lesions and adenomyotic ultrasound signs were recorded. Amount of menstrual bleeding and painful symptoms (dysmenorrhea, dyspareunia, dyschezia, dysuria, bowel symptoms) were evaluated using a visual analogue scale (VAS).

Results

62 patients met our inclusion criteria having a follow up period of 21.4 months (range 12-50 months). All patients took hormonal therapy, due to their symptoms and the presence of disease, during follow up period. 32.2% were on continuous progestin, 25.8% on continuous estroprogestin, 22.6% previously on continuous progestin and then on continuous estroprogestin. 74.2% (46/62) of patients reported an improvement of pelvic pain. In fact, patients reported average VAS 8.9 at first visit and subsequently VAS 4.9 during follow up. Dysmenorrhea improved in 87% (54/62) of cases. Concerning dyspareunia, dyschezia and dysuria there were improvements, although in a smaller percentage respectively 29% (18/62), 19.3% (12/62) and only 2/62 patients for dysuria. At US examination, ovarian endometrioma was found in 24/62 (38.7%) reported cases and among these, 75% (18/24) had a decrease of volume more than 36.1%. Utero-sacral ligament (USL) fibrotic thickening was detected in 71% (44/62) of cases and only 4 patients had rectal DIE. During follow up 40.9% (18/44) of patients showed a reduction of USL lesions size, 22/44 cases (50%) remained unchanged, while in 4/44 cases increased. Rectal deep infiltrating endometriosis (DIE) remained unchanged. Mild grade of adenomyosis was detected in 41.9% (26/62) of patients and despite adenomyotic foci shrank in 69.2% (18/26), a total disappearance was observed only in 2/62 cases.

Conclusions

early non-invasive ultrasound diagnosis of endometriosis in young patients could prevent the progression of the disease by starting an adequate hormonal treatment, could improve painful symptoms, reduce endometrioma size and USL fibrotic thickening. Rectal DIE, some USL fibrotic thickening and adenomyosis don't get worse. Further and longer follow up period are needed to confirm the role of early diagnosis and early treatment in these young patients.

Hysteroscopic findings in patients with breast cancer and treatment with tamoxifen: a retrospective descriptive study.

María Rodríguez-Marín Giménez¹, Angela María García¹, María Teresa Buergo¹, Rocío García¹, Leticia Delgado¹, Alvaro Zapico¹

¹Hospital Universitario Príncipe de Asturias, Ginecología y Obstetricia, Madrid, Spain

Background

The purpose of this study was to describe hysteroscopic findings in breast cancer patients receiving antihormonal treatment with tamoxifen as adjuvant therapy.

Methods

A list of all hysteroscopies performed in the Gynaecology Department from January 2019 to May 2022 was obtained. Medical records of all patients included in the list were reviewed and those women with previous diagnosis of breast cancer who were under tamoxifen treatment were included in the study. Data on age, pre- or post-menopausal status, hysteroscopy indication, hysteroscopic findings and results of pathological anatomy were extracted and analysed.

Results

A total of 96 patients were studied; mean age was 55.6 ± 8.8 years (range: 31-80). Of them, 74 (77.1%) were postmenopausal woman. Up to 7 (7.3%) patients were asymptomatic, in one patient hysteroscopy was performed following a suspected biopsy, and the indication in the remaining were ultrasound alterations in 62 (64.6%), and bleeding in 26 (27.1%). In the hysteroscopies performed, up to 49 (51.0%) patients had no significant findings, 38 (39.6%) had polyps, 2 (2.08%) had malignancy-suspected lesions, 2 (2.08%) had cysts, and 5 (5.2%) other findings. Polypectomy and myomectomy were carried out by using morcellation in 17 (42.5 %), scissors in 10 (25.0 %) and bipolar electrosurgical system in 7 (17.5 %). Biopsy was performed in 2 (5%) and no procedure in 4 (10%). The 2 malignancy-suspected lesions were removed by morcellation and biopsy respectively.

Pathological anatomy showed: 3 (3.1%) endometrial adenocarcinomas (the two hysteroscopy diagnosed and one polyp), 11 (11.5%) atrophic endometrium, 10 (10.4%) simple hyperplasia, 49 (51.0%) endometrial polyps and 23 (24.0%) others findings.

Conclusions

In our series of patients with previous breast cancer that followed treatment with tamoxifen, hysteroscopy showed 49% rate of endometrial pathology, with 3.1% of patients having an adenocarcinoma. These results confirm the need of yearly clinical and ultrasounds follow-up for patients under tamoxifen treatment. Hysteroscopy showed to be an efficient method for identification of suspected lesions.

Cell type-specific anti-adhesion properties of peritoneal cell treatment with plasma-activated media (PAM)

Myriam Holl¹, Marie-Lena Rasch¹, Sara Brucker¹, Martin Weiss¹

¹Eberhard Karls University Tübingen, Department of Women's Health, Tübingen, Germany

Background

Postoperative intraabdominal adhesions in laparoscopic surgery as a result of increased cellular proliferation and secretion of extracellular matrix proteins are responsible for severe clinical disorders. Prevention using barrier materials has failed to demonstrate clear clinical benefit yet. Antiproliferative and cell function modulating effects of physical plasma on biological tissues have been widely described. The administration of plasma-activated media (PAM) to specifically modulate cell proliferation and protein biosynthesis is a promising therapeutic strategy for the prevention of pathological cellular responses associated with chronic inflammatory and pro-adhesive diseases.

Methods

Patient-specific primary mesothelial cells and fibroblasts were cultured in 2D cell culture systems after isolation from intraoperative peritoneal wash cytologies and peritoneal biopsies. Primary mesothelial cells and fibroblasts were dose-dependently PAM-treated and analysed by molecular biology methods and Raman imaging.

Results

Dose-dependent treatment of primary peritoneal cells with PAM identified a cell type-specific therapeutic dose-window, characterized by selective inhibition of proliferation and viability of pro-adhesive peritoneal fibroblasts. In addition, the expression and secretion of pro-adhesive cytokines and the extracellular pro-adhesive matrix proteins collagen and fibronectin were significantly reduced within this dose-window. The cause of the anti-adhesive cell effects was identified as impairment of the cytoplasmic membrane and the consecutive intracellular increase of reactive plasma species followed by DNA hypermethylation, transient induction of DNA double-strand breaks, cell cycle arrest, and p53-associated apoptosis. In contrast, the cellular viability and the potential of mesothelial cells for proliferation and epithelial wound closure were preserved in this dose-window.

Conclusions

Treatment with PAM results in pro-therapeutic and anti-adhesive cell responses in 2D cell culture systems, characterized by cell type-specific inhibition of proliferation and protein biosynthesis. Routine intraoperative application of PAM in laparoscopic surgery may allow the prevention of adhesion-related clinical disorders.

Novel approach to diagnostic and operative hysteroscopy training. Hands-on training with one-to-one tutor in live patients.

Olga Triantafyllidou¹, Emmanouil Kalampokas¹, Theodoros Kalampokas¹, Dimitrios Mpalaftoutas¹, Grigorios Karampas¹, Nikos Vlahos¹

¹Aretaieion University Hospital- Athens, 2nd Department of Obstetrics and Gynecology, Athens, Greece

Background

Hysteroscopy is a very common tool providing the gynaecologist the ability to diagnose and treat a variety of intrauterine disorders. Hysteroscopy has become the standard of care for many of these pathologies. However, numerous obstacles exist for learning the principles and technical skills necessary for minimally invasive operations. Hands-on training in live patients faces ethical, legal, and economic obstacles but is still the best model of surgical education. Even nowadays, there are not many opportunities for young but even for experienced doctors to be trained properly in real operating conditions. The second problem is that an appropriate course should include a wide range of surgical techniques for treatment of almost all possible intrauterine pathologies, using wide range of instruments and hysteroscopes for proper training of the colleagues. Thirdly, no validated curriculum specific in hysteroscopy exists. The aim of this presentation is to share our experience in training seminars in diagnostic and operative hysteroscopy by 2nd Department of Obstetrics and Gynecology of "Aretaieion" University Hospital, Athens, Greece.

Methods

The 2nd Department of Obstetrics and Gynecology of "Aretaieion" University Hospital, Athens, Greece in collaboration with a university and a private hospital organizes for 6 consecutive times the hysteroscopic course in diagnostic and operative hysteroscopy. Every course includes 2 days of training and consists of a short theoretical part, video presentation and hands-on model training using a diagnostic hysteroscope and resectoscope. During the second day only 10-15 trainees are transferred to an operative room and perform with the guidance of experienced gynaecologists the whole range of surgical procedures (endometrial polyps, uterine septum, endometrial adhesions, simple diagnostic hysteroscopy for infertility, submucosal myomas). The total number of patients is not less than 20-22 cases in 3 operating rooms with live re-broadcasting of the operations in the amphitheatre where the other participants of the seminar are located. That way we provide the opportunity to every trainee to operate 1 or 2 patients with one-to-one tutor. Our team is responsible for sufficient number of patients as well as for a wide range of endometrial abnormalities.

Results

Although complications with both diagnostic and operative hysteroscopy are rare, they can often be prevented with thorough preoperative evaluation and appropriate intraoperative decision making of the instructor together with the trainee.

Conclusions

Our hysteroscopy courses with hands-on training in live patients provides participants with the opportunity of surgical experience under the close guidance of the tutor. The primary goal of our course is to prepare an inexperienced gynaecologist to be able to perform simple hysteroscopic procedures. We strongly believe that with appropriate training and education, every gynaecologist can safely incorporate hysteroscopy into their surgical practice.

Robotic-assisted vs conventional laparoscopy in deep infiltrating endometriosis surgery: a retrospective study of perioperative outcomes

Ana Perestelo¹, Anna Ruano¹, Laura Mañalich¹, Francesc Vallribera², Sonia Monreal¹, Antonio Gil-Moreno¹

¹Hospital Vall d'Hebron, Gynecology, Barcelona, Spain

²Hospital Vall d'Hebron, Colon and Rectal Surgery, Barcelona, Spain

Background

To compare perioperative outcomes (operative time, estimated blood loss, intra and postoperative complications and length of hospital stay) in robotic-assisted laparoscopic surgery (RAS) and conventional laparoscopy (LPS) in patients undergoing surgery for deep infiltrating endometriosis (DIE).

Methods

Observational retrospective cohort study including all surgical patients affected by DIE in Vall d'Hebron Hospital in Barcelona from January 2019 to April 2022. Patients underwent RAS or LPS according on the availability of the robotic room. All the procedures were performed by the same surgical team including gynecologists, colorectal surgeons and urologists.

Results

A total of 93 patients were included, 34 patients underwent RAS and 59 underwent LPS. The two groups were comparable regarding preoperative characteristics and surgical procedures, with no statistical differences observed. The mean age in the RAS group was 38,9+/-6,1 vs 40,1+/-6,18 in the LPS group ($p=0,99$). The mean body mass index in the RAS group was 24,8+/-4,6 vs 25,5+/-4,9 in the LPS group ($p=0,76$). Non-fertility preservation surgery with hysterectomy was performed in 22 (64,7%) patients in the RAS group vs 36 (61,0%) in the LPS group ($p=0,72$). Intestinal surgery (including shaving, segmental or discoid resection) was performed in 21 (61,8%) patients in the RAS group vs in 36 (61,0%) in the LPS group ($p=0,94$), while the rate of intestinal resection was slightly higher (without significance) in the LPS group: 12 (35,3%) in the RAS group vs 28 (47,5%) in the LPS group (OR 0,60, 95CI: 0,26-1,42; $p=0,25$). Urological procedures (including ureterolysis, bladder surgery and ureteral reimplantation) were performed in 10 (29,4%) patients in the RAS group and in 19 (32,2%) patients in the LPS group ($p=0,78$). No conversion to laparotomic surgery was needed.

No statistically significant differences were found in perioperative outcomes after adjusting by potential confounding variables. Operative time was 236+/-85 min in the RAS group vs 262+/-102 min in the LPS group ($p=0,21$), and in the subgroup analysis for intestinal resection surgery was 308+/-73min in the RAS group vs 329+/-99min in the LPS group ($p=0,514$). Estimated blood loss was 200+/-151 ml in RAS group vs 295+/-309 ml in LPS group ($p=0,10$). Hospital stay was 4,0+/-5,7 days in RAS group vs 3,6+/-2,4 days in LPS group ($p=0,52$). There was 1 (2,9%) intraoperative complication in RAS group (bladder lesion), and 2 (3,3%) in the LPS group (bleeding >2L, sigmoid lesion) ($p=0,71$). Major postoperative complications that required re-intervention were reported in 3 (8,8%) patients in RAS group (2 colorectal anastomosis leakages, 1 vesico-vaginal fistula) and in 6 (10,2%) patients in LPS group (1 colorectal anastomosis leakage, 2 bleedings of the colorectal anastomosis, 1 vesical suture leakage and 1 rectovaginal fistula) ($p=0,96$).

Conclusions

RAS provides similar perioperative outcomes compared with LPS in DIE surgery, and it can be considered a valid alternative.

Review of total laparoscopic hysterectomies (TLHs) at the Aneurin Bevan University Health Board (ABUHB) during Covid-19 pandemic.

Irina Ramzan¹, Anita Nargund¹

¹Aneurin Bevan University Health Board, Gynaecology, Newport, United Kingdom

Background

Assessment of the impact of Covid-19 pandemic on the delivery of TLHs at the ABUHB

Methods

Retrospective study between 1st of April 2020 and 22nd of August 2021 including TLHs only. Data was extracted from the clinical workstation and patients were followed up to six months postoperatively.

Results

ABUHB is a healthcare provider in Wales and delivers gynaecology services to 250,479 female population. Benign surgery and surgery for stage IA endometrial cancer is provided by the ABUHB gynaecology department. There was a 40% reduction in the number of hysterectomies during Covid-19 pandemic at the ABUHB. However, we were doing 10% more TLHs.

43 TLHs were performed during the time of our study, majority of the case were endometrial pathology and menorrhagia/fibroid uterus, 17 and 11 patients respectively. 6 patients required surgery for chronic pelvic pain, 2 patients required TLH for ovarian cyst and premenstrual syndrome. The other group were patient with BRCA gene mutation and uterine prolapse. Maximum uterine size was 12 weeks; 29 cases had a normal size uterus. 6 patients had a body mass index (BMI) more than 40, 5 patients had BMI of 35 to 39. The shortest surgery time was 55 min and the longest 228 min. All procedures were joint procedures by a consultant and a training grade doctor. Visiport was a preferred abdominal entry in 27 cases and Hasson's in 8 patients. There were no complications with the abdominal entry, but one patient required Visiport entry after a failed Hasson. Thunderbeat energy device was used for dissection in 20 cases and Ligasure in 8 cases, followed by Harmonics. In 33 cases, surgeon used a monopolar hook for colpotomy. There were three conversions to laparotomy: first case due to extensive endometriosis, second case due to difficulty in airway ventilation and third patient due to difficulty with colpotomy at laparoscopy. Vaginal vault was closed intracorporeally in 32 cases; Stratafix suture and vicryl 1.0 suture used in 26 cases and 6 cases respectively. 11 patients had vault closure with vicryl 1.0 vaginally. 31 patients required a one-day admission only. One patient developed pulmonary embolism postoperatively and one patient had a vaginal haematoma managed conservatively.

Conclusions

Covid-19 had a significant impact on provision of gynaecological surgery worldwide including our department. Training continued to be provided to junior doctors but at the reduced volume. Our study demonstrated a safe delivery of laparoscopic hysterectomies and increase in the uptake of laparoscopic procedures during Covid pandemic. There was a 7% conversion rate and 2.3% rate of major postoperative complication. There were no complications associated with Stratafix vaginal vault closure. We continue to review our services in the downward Covid-19 trend.

Robotic Assisted Laparoscopic Myomectomy, Clinical evaluation and associated clinical condition - a cohort study at Emory Saint Joseph's Hospital of Atlanta.

*Magdi Hanafi*¹

¹Emory University, Gynecology, Atlanta, USA

Background

A Retrospective analysis of consecutive Robotic Laparoscopic Myomectomy (RLM) cases performed by the single surgeon (author) between January 1st 2016 and June 30th 2018

To evaluate the effects of the myomata characteristics (Location in the uterus, number, size and weight of the tumours), associated pathology (Pelvic endometriosis, adenomyosis, pelvic and abdominal adhesions) on the operative procedure parameters (Operating time, estimated blood loss and length of hospital stay), post operative pain level, days of taking pain medications, weeks to return to work, pregnancy rate.

Methods

Data were collected from EMR. Data were reviewed and analysed, approved by Sterling Institutional Review Board Atlanta, Georgia, USA (IRB ID: 6470).

Patient age, demographics, BMI, leiomyomata characteristics (number, size weight of each case fibroids), operative time, estimated blood loss, duration of hospital stay, post-operative pain level, associated pelvic conditions such as endometriosis, adenomyosis, PCOS, pelvic adhesions. Post-operative clinical outcomes surveyed by administering questionnaires to the patients.

Results

174 RLM cases were included and reviewed. Cases included uterine myomas up to 10, heaviest weight 846 gr largest myoma up 15.0 cm diameter. Two patients (1.14%) underwent conversion to laparotomy. OT 146 minutes and Mean Estimated Blood Loss (EBL) in RLM was 109ml (<150 ml). The mean aggregate weight of leiomyomata removed in RLM cases was 72.6 grams. Estimated Hospital Stay was 1.2days. No intraoperative or perioperative complications were noted and post operative skin wound infection 2 cases

OT and EBL for larger fibroid tumour ≥ 6 cm is significantly greater than small fibroid tumour ≤ 5 .

OT and EBL for RLM cases with > 3 fibroid tumour is significantly greater than cases with 1-3 fibroids

Correlation EBL in RLM cases with intramural (104 ml) and subserous fibroid 50 ml is 10.6% variation

LHS 19.8% variation 1.4 days in subserous and 1.1 days in intramural fibroid

LHS in RLM cases with >3 fibroids statistically significant in comparison with RLM cases with 1-3 fibroid

Associated condition endometriosis, adenomyosis, pelvic adhesions and their effects throughout the RLM procedure did not have significant impact on OT, EBL or LHS

RLM cases had significantly smaller number weeks return to work (3.9weeks), lesser number days until first bowel movement (1.5 days) fewer number of weeks resuming sexual activity (6.3 weeks). Post operative clinical outcome on a 3-year follow-up survey showed pregnancy rate 48.3% (62 cases among the RLM were trying to get pregnant and 30 Patients successfully delivered at the time of data collection ending 11/ 30 2021)

Conclusions

Size, numbers, location of the tumours i uterine wall Subserous Vs intramural have significant impact on EBL, LHS, OT, number weeks return to work, number of days have first bowel movement.

Post operative pregnancy rate (infertile cases 48,3%) within three years.

Other associated conditions had no significant effects in the variables studied

Laparoscopic management of huge benign ovarian cysts: case series

Tamer Said¹

¹*Alexandria University, Obstetrics and Gynaecology, Alexandria, Egypt*

Background

The benign ovarian cysts are one of the most common indications of laparoscopic surgery. The usual technique is to do the benign ovarian cysts to do aspiration of the cyst then do stripping of the cyst wall from the ovarian tissue. This technique could take a long time if the cyst is large or huge,

Methods

In this cases series we recruited 8 cases of huge ovarian cysts. All of them were completely examined and all necessary investigations were done. When the cases were fully investigated, we do ultrasound guided cyst aspiration of the cyst using the 5 mm trocar. After the size of the cyst become appropriately small retraction of the trocar and insertion of the co2 to do pneumoperitoneum. Then, insertion of the primary trocar through the umbilicus. The small opening was done in site of secondary trocar site and exteriorization of the cyst and ovary outside the abdominal cavity and perform the stripping technique leaving a small part of the cyst to be completed by the laparoscopy in standard technique.

Results

The time for cystectomy was cut short by using the new technique. None of our cases needed laparotomy. No soiling of the peritoneal cavity occurred in any of our series. No complication in any of our cases. The technique was used in different types of cysts included dermoid, cystadenoma and chocolate cyst.

Conclusions

Exteriorization of the cyst wall to be excised outside the abdominal cavity is effective and safe and led to saving in the time of the surgery without complications

SYNAPPH study: Uterine synechiae prevalence after post-partum hemorrhage

Audrey Astruc¹, Philippe Descamps¹, Pierre Emmanuel Bouet¹, Constance Rio¹, Guillaume Legendre¹

¹chu Angers, Gynecology Department, Angers, France

Background

Uterine synechiae is a major cause of secondary infertility. Its origin is mostly post traumatic after an endometrial aggression. Hysteroscopy is the gold standard for its diagnostic. Post-partum hemorrhage (PPH) management follows a step-by-step algorithm where we first perform a uterine revision followed by a bimanual massage, we use oxytocin molecule then prostaglandins like sulprostone and if bleeding continues more invasive techniques may be needed (intra uterine tamponade balloon, uterine arterial embolization, and surgical techniques). Although surgical techniques have shown to create intra uterine synechiae, uterine synechiae after delivery has not been studied.

Our aim was to determine uterine synechiae prevalence after PPH.

Methods

We conducted a single centre prospective study in Angers University Hospital from January to December 2021. Women who presented a PPH (blood loss of 500cc or more) were proposed a diagnostic hysteroscopy eight weeks after delivery. Women with a history of uterine surgery (curettage, surgical hysteroscopy...) were excluded. An ethic committee authorization was obtained. Our primary objective was to determine the prevalence of uterine synechiae, and our secondary objective was to find an association between synechiae, and techniques used for PPH management, and symptoms.

Results

83 women were enrolled in our study. Women were mostly nulliparous with a vaginal delivery and a mean blood loss of 974cc. Only 7% have required the use of intra uterine tamponade balloon, 4% the need of a uterine arterial embolization and none required a surgical treatment.

We found a uterine synechiae prevalence of 24%, eight weeks after delivery; mostly type I according to the ESGE classification. 3 women (15%) had an intra uterine tamponade balloon in the synechia group vs 3 (5%) women in the non-synechiae group, but it was not significative (OR 3,52 (0,652-19,098) p= 0,123). The need of a second uterine revision (OR 5 (1,501 ;16,6652) p=0,009) and bimanual massage (OR 3,5 (1,121-10,090) p=0,020) were found to be independent risk factors in multivariate analysis.

Conclusions

It is the first study to our knowledge to evaluate the risk of uterine synechiae for PPH that do not require surgical treatment. We found an important number of synechiae, and these results need to be confirmed by a controlled study. Maybe should a diagnostic hysteroscopy be proposed to every woman presenting a post-partum hemorrhage when a second uterine revision is realized?

Effectiveness of augmented reality simulation training using objective metrics in gynaecological laparoscopy

Zacharoula Koukoulis^{1,2}, Rahul Gore¹, Kamran Safdar Rao¹, Tint- Tint Wai¹, Karen Coombe¹, Barry Whitlow^{1,2}

¹East Suffolk and North Essex NHS Foundation Trust, Obstetrics and Gynaecology, Colchester, United Kingdom

²ICENI Center, Obstetrics and Gynaecology, Colchester, United Kingdom

Background

Our objective is to evaluate the effectiveness of hands-on augmented reality simulation training in improving laparoscopic skills for gynaecological procedures, using objective metrics.

Methods

Delegates participated in our advanced course for gynaecological laparoscopy in the ICENI Center, in November 2021, and underwent 2 days of intensive augmented reality simulation training for several gynaecological procedures using augmented reality simulation technology and training boxes developed by Inovus Medical.

Data were collected using the Inovus software programme and included mean completion time, distance travelled, time on screen, ambidexterity, and acceleration. The mean completion time (in minutes) corresponds to the total time it took to complete a given procedure. Distance travelled (in meters) shows the total distance travelled during a procedure. It is an expression of economy of movement, and it is more desirable to see a lower total distance travelled, where no movement is wasted. Time on screen (in %) represents the amount of time that the instruments remain in view inside of the simulator, as a percentage of the mean completion time for the given task- scores close to 100% are desirable. Ambidexterity (in %) was calculated as the percentage of non-dominant (left) hand usage during the procedure- scores close to 50% are desirable. Acceleration (in meters per sec per sec) is intended to reflect undesired jerky movements- low scores are desirable.

We compared metrics obtained while delegates performed one laparoscopic task at the start of the course, and metrics obtained while they performed the same task after 2 days, at the end of the course.

The Wilcoxon signed-ranks test (non-parametric) was used for the comparison.

Results

8 delegates participated in the course and were included in the study. All worked in the UK, with the majority being year 5-6 in the UK training programme.

The mean scores for completion time went from 5.7 to 4.3 min ($p=0.043$), for distance travelled from 97.7 to 61.1 meters ($p= 0.028$), for acceleration from 0.20 to 0.17 meters per sec per sec ($p=0.042$), for time on screen from 92.5% to 93.2% ($p=0.116$) and for ambidexterity from 50.1% to 50.2% ($p=0.674$).

Overall, statistically significant differences/ improvement was noted for the mean completion time, for the distance travelled and for acceleration. Time on screen and ambidexterity of the delegates were not found to be significantly different between the two attempts - of note, the latter values were high from the first attempt.

Conclusions

We demonstrated objectively that hands-on augmented reality simulation training improves the skills needed for gynaecological procedures including the reduction of undesired jerky movements. We conclude that a consistent simulation training programme using augmented reality and objective metrics preceding surgical training in theatre would increase patients' safety, trainees' competence and confidence and trainers' willingness to teach.

An Intrauterine Cavity Morcellator: A Novel Approach to High Volume Uterus Morcellation. EX-VIVO Study

Yair Daykan¹, Ron Schonman¹, Rina Tamir Yaniv¹, Yael Yagur¹, Zvi Klein¹, Meir Pomeranz¹

¹Meir Medical Center, Obstetrics and Gynecology, Kfar Saba, Israel

Background

To evaluate the safety and efficacy of the Heracure Device for intra-uterine morcellation after vaginal or laparoscopic hysterectomy.

Methods

Design: A single-arm, prospective-observational non-randomized study.

Setting: A university-affiliated Medical Center.

Patients: In ten post-hysterectomy uteri the novel intrauterine morcellation technique was performed (Ex-VIVO).

Interventions: Ex-vivo intrauterine morcellation.

Results

Ten uteri were examined in this trial. No major complications occurred during the procedure. All ten (10) uteri were successfully reduced in size (size reduction range was between 9% to 54%). The average resection time using the Heracure Device was 4.3 minutes (range: 1min – 10min). Mean uterus weight reduction was 21%, with a mean circumference reduction of 25%. The use of a protective cover, made of flexible cut-resistance material wrapped around the uterus, was successfully demonstrated. No leakage was observed from the outer surface of the uterus/serosa after the saline injection post-procedure examination.

Conclusions

In this novel experiment, we verified the efficacy and safety of the Heracure device for vaginal intra-uterine morcellation. This technique enables rapid and easy removal of the uterus through the vaginal orifice.

Application value of CDO1 and CELF4 genes combined with ultrasonography for endometrial cancer in postmenopausal women

Lei LI¹

¹National Clinical Research Center for Obstetric & Gynecologic Diseases- Peking Union Medical College Hospital, Department of Obstetrics and Gynecology, Beijing, China

Background

Women with postmenopausal bleeding (PMB) and endometrial thickness can also be signs of endometrial cancer (EC). The ACOG recommends that women with abnormal bleeding could be evaluated for EC if they are older than 45 years. Patients' pain and repeated hysteroscopy often cause fear in women, especially women with PMB. The Pap test, minimally invasive, was used for methylation test has a promising application prospect in EC diagnosis.

Methods

Following the GCP guidance, the subjects were recruited in Peking Union Medical College Hospital in China. 363 women over 40 years old who underwent endometrial biopsy including women with post- or pre- postmenopausal bleeding in the hysteroscopic room were enrolled. If the biopsy result is positive, follow-up treatment shall be carried out. The biopsy or surgical pathology were as the final pathology. The methylation tests were determined by CisEndo methylation (CDO1 and CELF4) real-time system (CISPOLY Co., China) using cervical exfoliated cells samples in the study. Positive results were defined in $\Delta Ct-CDO1 \leq 8.4$ or $\Delta Ct-CELF4 \leq 8.8$. The data of clinical syndrome and tests including endometrial thickness (ET) ≥ 5 mm for post-MW and ≥ 11 mm for pre-MW, CA125 test, BMI measure, and methylation test were collected.

Results

In 143 postmenopausal women of 363 participants, the sensitivity and specificity were TVS at 81.2% and 39.6%, CDO1 methylation (+) at 75.0% and 94.3%, CELF4 methylation (+) at 78.6% and 95.4%, and the CDO1 / CELF4 methylation (+) at 87.5% and 90.8%, respectively. The positive rate of different tests was 49% at endometrial thickness, 47.6% at BMI ≥ 25 at 47.6%, CDO1 & CELF4 at 39.9%, and CA125 at 21.0%. The positive rate of different tests for EC was CDO1 & CELF4 (87.5%), BMI ≥ 25 , CA125 (39.3%), and endometrial thickness (23.2%), respectively. The combination of TVS (+) or double methylation genes (CDO1 or CELF4) (+) were 100.0% sensitivity and 59.8% specificity. The combination of TVS (+) and double methylation genes (CDO1 or CELF4) (+) were 64.3% sensitivity and 95.6% specificity.

Conclusions

The methylation test of cervix cytological samples may be a new method for women with PMB. The combination TVS and double methylation (CDO1 / CELF4) genes could be the potential minimally invasive tests for EC diagnosis.

Quantitative Ultrasound Measurement of Uterine Contractions in Adenomyosis versus Normal Uteri - the WAVES Study

Connie Rees¹, Anna de Boer¹, Brunella Zizolfi², Nikos Christoforidis³, Huib van Vliet¹, Dick Schoot¹

¹*Catharina Hospital, Gynaecology and Obstetrics, Eindhoven, The Netherlands*

²*University of Naples Federico II, Public Health - School of Medicine, Naples, Italy*

³*Embryolab Fertility Center, Fertility, Thessaloniki, Greece*

Background

During the menstrual cycle, the natural contraction pattern of the uterus in response to changes in oestradiol and progesterone. Abnormal uteri (for instance due to adenomyosis) potentially react differently to these stimuli, which may be a cause of associated clinical symptoms such as hypermenorrhoea, dysmenorrhoea, and infertility. This has never before been quantified objectively in women with abnormal uteri however, due to the absence of a suitable measurement tool.

Methods

Study Objectives: Measurement and analysis of uterine contractions by quantitative 2D transvaginal ultrasound (TVUS) measurements in women with abnormal uteri due to adenomyosis versus women with normal uteri.

This multi-centre prospective observational cohort study took place in the outpatient gynaecology department of participating centres. 29 women with sonographic suspicion of adenomyosis with a natural menstrual cycle, were compared to 70 women with normal uteri and regular menstrual cycles. Patients were included from September 2014 up to January 2022.

Each patient underwent a four-minute 2D TVUS of the uterus in mid-sagittal section. Uterine motion analysis was implemented by a novel dedicated speckle tracking algorithm; with frequency, amplitude, coordination, and velocity-related features extracted from the derived signals to characterise the uterine contractions. Measurements were carried out at different points of the menstrual cycle (menstrual phase, early follicular, periovulatory and early and late luteal phases).

Results

Results differed most significantly between groups in the periovulatory phase, with women with adenomyosis showing lower frequency (1.44 vs. 1.79 contractions/minute, $p=0.025$), higher amplitude (0.09 vs. 0.04, $p=0.000$) and lower velocity of uterine contractions (0.62 vs. 0.83, $p=0.0008$). In the menstrual phase, women with adenomyosis showed a trend toward higher contraction frequency (1.37 vs. 1.33 contractions/minute, $p=0.592$), amplitude (0.05 vs. 0.04, $p=0.259$) and velocity (0.72 vs. 0.67, $p=0.456$). Across all phases, women with adenomyosis showed a trend towards reduced contraction coordination (0.23-0.34 vs. 0.15-0.26). This being statistically significant in the late luteal phase ($p=0.018$).

Conclusions

Our results confirm differences in uterine movement in abnormal versus healthy uteri. This could add to the aetiological understanding of clinical symptoms of these conditions (i.e., dysmenorrhoea or infertility). The notable difference between groups regarding coordination identifies this feature as potential prognostic or therapeutic markers. Further research in women with (other) benign uterine disorders will hopefully lead to a better understanding of the clinical implications of abnormal uterine contractility in this population.

A 5-years' experience of Total laparoscopic hysterectomy without uterine manipulator. Single institution retrospective study of 882 cases.

Tamriko Dzotsenidze¹, Irakli Todua², Tamar Giorgadze², Mariami Matcharashvili²

¹MD, Medical Center "Innova", Tbilisi, Georgia

²Medical Center "Innova", Department of Operative Gynecology, Tbilisi, Georgia

Background

The aim of the retrospective study was to investigate the feasibility and safety of the total laparoscopic hysterectomy without uterine manipulator.

Methods

This is the retrospective study of cases of total laparoscopic hysterectomy without uterine manipulator, performed in one institution between January 2016 and March 2022 in women with benign indications for hysterectomy. The patients' medical records were used as the database for the study, surgical procedure details, intra and postoperative complications were evaluated.

Results

882 cases of TLH from January 2016 to March 2022. Mean age of patients was 52,8 years (range, 29 – 88 years), approximately half of the patients were postmenopausal. BMI ranged between 23.4 kg/m² and 44, 3 kg/m². The mean operative time was 37 minutes (range, 25-110 minutes). The estimated blood loss was 59.6 ml (range, 20-200 ml), the median uterine weight was 273,3 g.(45-780g), the average length of stay in hospital was 58 hours (range 47-71 hours). Total cases of complications were 28 (3.2%). Intraoperatively there was 5 cases of laparoconversion (0.6%), due to large uterine size, ureteral stent placement 3 cases (0,3%). Laparoscopic revision was performed in 5 cases (0,6%) because of pelvic haematomas. Urinary tract infection - 6 cases (0,7 %), haemotransfusion was performed in 7 cases (0.8%), including 3 cases of preoperative haemotransfusion due to severe anaemia. We reported 2 cases of vaginal vault dehiscence in postoperative period, managed through vaginal approach. More than medium positive correlation was estimated between uterine weight and intraoperative blood loss volume. (Pearson Correlation =0,564, P<0.001).

Conclusions

The study shows that THL without uterine manipulator is the feasible and safe procedure due to its low complication rates, short operative time and hospital stay.

Hysteroscopic treatment of uterine septum and obstetrics results

*Clementina Pilar De Antonio¹, Marta Miguez Medina¹, Eva Vila Escude¹, Montserrat Cubo Abert¹,
Anna Ruano López¹, Antonio Gil-Moreno²*

¹Hospital Vall d'Hebron, Gynaecological endoscopy, Barcelona, Spain

²Hospital Vall d'Hebron, Gynecology department, Barcelona, Spain

Background

Determine if hysteroscopic resection of uterine septum in women of childbearing age with a septate uterus and incomplete reproductive desire improves the live birth rate, as well as to evaluate the safety of this procedure.

Methods

Retrospective descriptive study that includes 29 patients with septate uterus treated hysteroscopically from 2018 to 2021 at the Vall d'Hebron Hospital in Barcelona. The main results studied were the pregnancy success rate after surgical treatment as well as analysing the obstetric and perinatal results. To compare results obtained using three different surgical techniques (scissor resection vs versapoint system vs Collins loop resector).

Results

29 patients were treated hysteroscopically of the uterine septum between 2018 and 2021. 9 of them using scissors, 3 using versapoint system and 16 using a Collins loop. After the operation, only 21 patients wished pregnancy, obtaining a pregnancy rate of 66.66% (n=14), of which 64.28% (n=9) were spontaneous and 35.71% (n= 5) through assisted reproductive techniques. Of the 14 initial pregnancies, 3 abortions occurred in the first trimester (21.42%), 3 are currently pregnant and 8 pregnancies (57.14%) were prolonged beyond 35 weeks of gestation, where 7 live births were obtained. An intrapartum uterine rupture was observed, which led to perinatal death of the newborn.

Conclusions

Hysteroscopic surgical treatment of the septate uterus in women of childbearing age with incomplete gestational desire is a common clinical practice to try to improve fertility in these patients. However, there is currently no conclusive evidence to support that hysteroscopic resection in women with this pathology improves the live birth success rate. Quality randomized clinical trials are needed to be able to decide which is the best clinical practice in this pathology.

Hormonal replacement therapy (HRT) and office hysteroscopy: a single centre experience.

Ángela María García De La Chica¹, María Rodríguez-Marín¹, Teresa Buergo¹, Rocío García¹, Leticia Delgado¹, Álvaro Zapico¹

¹Hospital Universitario Príncipe de Asturias, Gynecology and Obstetrics, Alcalá de Henares. Madrid, Spain

Background

To evaluate endometrial pathology via office hysteroscopy among patients using hormonal replacement therapy (HRT) in our centre.

Methods

A database was made including all women receiving HRT from December 2010 to May 2022 in our hospital that were referred to office hysteroscopy due to clinical or ultrasound suspicion of endometrial pathology. Different items such as age, hysteroscopy indication, hysteroscopic findings, and results of anatomical pathology were analysed.

Results

20 postmenopausal patients were included in a retrospective study; mean age was 51.60 ± 8.82 years old (range: 37-72 years old). The mean age of the menopause was 44.53 ± 9.576 years old (range: 24-61 years old). Among them, the most prevalent indication of the hysteroscopy was abnormal vaginal bleeding in 10 patients (50%) patients, in 5 patients (25%) the hysteroscopy was performed due to ultrasound abnormalities, 3 patients (15%) were asymptomatic and, in 2 patients (10%) hysteroscopy was performed due to an alteration in an endometrial biopsy.

Hysteroscopic findings vary from 7 patients (35%) had endometrial polyps, 5 (25%) patients without any important hysteroscopic result, 4 patients (20%) had an atrophic endometrium, 3 (15%) had a functional endometrium and 1 patient had a submucosal leiomyoma. The most used analgesic method among our study was the use of nitrous oxide (12 patients).

Histological findings were: 6 patients (30%) had an endometrial polyp, 1 patient (5%) had an endocervical polyp, 8 patients (40%) did not have a representative biopsy, 1 patient (5%) had a simple endometrial hyperplasia, 1 patient (5%) had a proliferative endometrium, and 3 patients (15%) showed an atrophic endometrium.

Conclusions

In our retrospective study, among 6683 patients that were referred to hysteroscopy along these years, only 20 patients were into HRT. In this group, despite of the suspicion of endometrial pathology, none of them showed a malignant endometrial condition.

Birth Register for Deep Endometriosis - a prospective multicenter study

Peter Oppelt¹, Katrin Oberfichtner¹, Philip Trautner¹, Imre Szilagyi¹, Simon-Hermann Enzelsberger¹

¹Kepler University Hospital, Gynecology- Obstetrics and gyn. Endocrinology, Linz, Austria

Background

The last years provided us with various discoveries about the influence of endometriosis on complications during pregnancy. By contrast, only very few studies have focused on the impact of endometriosis on delivery. In particular, the outcome of deliveries from patients with deep endometriosis – both operated on and unoperated – has not been sufficiently investigated. For this reason, the initiative to create a world-wide birth register for deep endometriosis has emerged. The main purpose is to gather information about birth injuries, delivery mode and fetal outcome.

Methods

Data is entered in an electronic database. The data entry mask is accessible on a protected area of the register homepage. To obtain a center-specific access link and access code, online registration as participating center is necessary. The study was approved by the institutional ethics committee of the Johannes Kepler University and registered in the German Clinical Trials Register (ID: DRKS00016768).

Results

So far, 175 cases have been entered into the registry, of which 153 are available for analysis after taking into account all of the drop-out criteria. The mode of delivery is distributed as follows: vaginal spontaneous delivery 39.9 % (n=61), vacuum extraction 7.2 % (n=11), forceps 2.6 % (n=4), primary caesarean section 28.1 % (n=43) and secondary caesarean section 22.2 % (n=34). Thus, caesarean section was performed in 50.3 %. 10.5 % of children (n=16) were born prematurely (before 37+0 pregnancy week).

Conclusions

A high rate of caesarean section in women with deep endometriosis is observed. A detailed first interim analysis will provide further information to better inform affected women in the future.

If you are interested in participating: endo-birth.kepleruniklinikum.at

A Rare Case of an Isolated Fallopian Tube Torsion

*Maria Papageorgiou¹, Theodoros Kalampokas¹, Stavroula Morfiri¹, Olga Triantafyllidou¹,
Emmanouil Kalampokas¹, Nikolaos Vlahos¹*

*¹2nd Department of Obstetrics and Gynecology- Aretaieio University Hospital,
National and Kapodistrian University of Athens, Athens, Greece*

Background

Isolated fallopian tube torsion (IFTT) is a rare cause of acute pelvic pain. IFTT is the rotation of the tube around its longitudinal axis, while the ovary and its blood flow remain unaffected. Bland-Sutton first described IFTT in 1890. The estimated prevalence is 1 in 1.5 million women. The most common aetiology includes anatomic abnormalities, such as hydrosalpinx and paraovarian cysts, although a normal tube might also be affected. Early diagnosis and treatment are crucial in order to maintain the patient's fertility. However, many pathologic conditions can mimic similar symptoms, making diagnosis problematic.

Methods

This case report concerns a 39-year-old nulliparous female patient without a past medical history. The patient presented to the emergency room due to a 4-day history of right lower abdominal pain. The physical examination revealed abdominal tenderness with defense. Her total blood count was within normal limits. Transvaginal ultrasound demonstrated an allantoic mass of about 55 × 15 mm in contact with a 46 × 42 mm hypoechoic cyst adjacent to the right ovary, while the Doppler blood flow was normal. An immediate laparoscopy was performed, which revealed a triple torsion of the right fallopian tube around the infundibulopelvic ligament. The fallopian tube appeared dilated and necrotic. A right salpingectomy was performed. The patient was discharged the day after.

Results

IFTT remains a tricky diagnosis because its symptoms are non-specific and extremely common. The differential diagnosis includes a wide range of other emergency causes for abdominal pain, such as ovarian torsion, appendicitis, pelvic inflammatory disease, ectopic pregnancy, and renal colic. Preoperative ultrasound with colour Doppler remains a useful diagnostic tool. Laparoscopy is the gold standard for both diagnosis and treatment.

Conclusions

IFTT is an extremely rare condition. Increasing awareness regarding this serious complication should be the main goal among clinicians, and IFTT should always be suspected in women with acute lower abdominal pain, regardless of age.

Endometriosis Associated Ovarian Cancer (EAOC)-could we prevent it?

Amelie Morin¹, Mehrnoosh Aref-Adib¹, Funlayo Odejinmi¹

¹Bart's Health NHS Trust, Obstetrics and Gynaecology, London, United Kingdom

Background

Endometriosis is a known risk factor for endometrial cancer and was first described as such in 1925 by Sampson. EAOC is believed to arise from ovarian endometriomas and occurs in 0.5 to 1% of cases. The molecular mechanisms of carcinogenesis and the transformation timeframe remain poorly understood. A literature review by Murakami et al identified 79 cases. Most women were diagnosed in their 40s and had normal CA 125. The average time from endometrioma to cancer diagnosis was 36 months. Most cases were detected at an early stage (FIGO stage 1) and most tumour developed during the first 10 years of an endometrial cyst being seen.

Methods

A 38-year-old nulliparous female patient presented with abdominal pain and bloating. An ultrasound scan showed a 6 cm left dermoid cyst. Her CA 125 was 43. She was referred to the local NHS hospital for surgery. At laparoscopy significant endometriosis was seen. The left ovary was enlarged and adherent to the bowel, pouch of Douglas and uterus.

Results

An ovarian cystectomy was performed, and the histology revealed a stage 1 endometrioid cancer.

Conclusions

EAOC is rare but can affect pre or postmenopausal women and any endometrial cyst. There is no current biological markers, imaging criteria or diagnostic tools to identify women at risk of developing EAOC. Women diagnosed with endometriosis should be considered at risk and extra attention given to their symptoms. Guidance for surveillance and management may need to be updated to incorporate this risk and help to prevent conversion into malignancy.

Laparoscopic Removal of interstitial portion of tube: Novel method for management of Interstitial Ectopic pregnancy

Smita J¹, Siraj Shahul Hameed Mohamed², Bernard Chern²

¹Associate consultant, minimally invasive surgery- Kk women's and Children's Hospital, Singapore, Singapore

²KK Women's and Children's hospital, Minimally Invasive surgery, Singapore, Singapore

Background

Laparoscopic salpingectomy including interstitial fallopian tube without myomectomy/ cornuostomy may be a new frontier in management of interstitial pregnancy. In addition, this method reduces the thermal injury of myometrium. This in turn reduces the morbidity associated with the conventional wedge resection, such as blood loss, and potential risks of uterine rupture in future pregnancy.

We present a case of a 36-year-old lady with 8.5 weeks of amenorrhea diagnosed with an interstitial pregnancy and uterine fibroid. She underwent laparoscopic salpingectomy including the interstitial part of fallopian tube with products of conception without myomectomy and cornuostomy. Intra-operative blood loss was minimal. She was well up post-operatively and weekly serum beta human chorionic gonadotropin (serum β -hCG), down-trended optimally in the third week of surgery.

Keywords: interstitial pregnancy; Laparoscopic salpingectomy

Methods

A 36-year-old lady, gravida 4 para 1, presented with 8.5 weeks of amenorrhea with history of left iliac fossa pain, associated with per vaginal spotting. She had one no other medical or surgical history of note. Vitals were stable at presentation with blood pressure of 120/76 mm Hg and heart rate of 78 min. Abdomen was normal, soft, non-tender. with no signs of acute abdomen. Vaginal examination revealed minimal amount of stale blood, cervical os was closed. Ultrasound imaging revealed a cystic mass measuring 3.4 × 2.5 × 2.0cm at left cornu region, with surrounding peripheral vascularity, small uterine fibroids, and largest measuring 3.7 cm left lateral wall of uterus. Minimal free fluid in pelvis was noted. Serum human chorionic gonadotrophin (beta-hCG) at presentation was 27,600 IU/mL. Couple was counselled regarding options of management for interstitial pregnancy. Diagnostic hysteroscopy and laparoscopy were done, and the intra-operative findings showed a 4 cm subserosal fibroid at the left cornu region, overlying the non-ruptured interstitial pregnancy. Bilateral fallopian tubes and ovaries appeared normal. Laparoscopic salpingectomy including removal of interstitial fallopian tube was done without myomectomy and cornuostomy. There was minimal blood loss and thermal injury to the myometrium.

Results

Patient recovered well and was discharged on postoperative day 2. Subsequent outpatient monitoring revealed optimal reduction of beta-hCG in third week after surgery Her urine pregnancy test subsequently was negative. Patient remained well and stable. Her histopathology revealed product of conception in left fallopian tube.

Conclusions

Interstitial pregnancy is a rare but potentially life-threatening gynaecological condition. Late diagnosis leads to cornual rupture which can be life threatening with significant haemorrhage, hypovolemia, shock, or death. In general, the available data are inconclusive and conflicting in guiding appropriate counselling of patient with regards to treatment modality, impact on future pregnancy, mode of delivery in future pregnancy and future recurrences. Laparoscopic salpingectomy with complete removal of the interstitial part may be a new frontier in management of interstitial pregnancy.

Patient controlled Analgesia after laparoscopic myomectomy: is it necessary?

Amelie Morin¹, Natasha Liou¹, Michail Sideris², Zwehile Magama¹, Roopa Majumdar¹, Funlayo Odejinmi¹

¹Bart's Health NHS Trust, Obstetrics and Gynaecology, London, United Kingdom

²Barts and the London School of medicine and dentistry, Queen Mary University, London, United Kingdom

Background

To compare post-operative patient-controlled analgesia (PCA) to oral (PO) opioid use following laparoscopic myomectomy. The primary outcome measure was morphine milligram equivalent (MME) dose, and the secondary outcome assessed the impact of opioid use on patient recovery.

Methods

Prospective cohort study of consecutive laparoscopic myomectomies in a university hospital. Patients were given either PCA or PO analgesia in addition to routine pain relief. MME use was measured in the first 24 hours, and pain scores were recorded at predefined time points using a visual analogue scale: recovery, 6 hours post-op, discharge, and day 14.

Results

14 patients were recruited with 7 patients in each group. Both groups were of similar age, ethnicity, fitness, and body mass index. The PCA group had on average more fibroids removed (4 fibroids vs 2 fibroids, $P=0.90$). All operations were of similar duration and blood loss. The PCA group required significantly more MME (54 mg vs 23 mg, $P=0.03$) and had higher pain score at 6 hours post-op (6 vs 2, $P=0.09$). Pain scores were similarly reported at subsequent time points. Both groups mobilised by 12 hours and the PO group patients were discharged earlier (24 hours vs 48 hours, $P=0.09$). All patients reported "Good" satisfaction at 14 days.

Conclusions

Minimally invasive surgery has led to speedier recovery and post-operative pain management should facilitate this. By using multi-modal oral analgesic protocols, patients may require less opioid analgesia, report lower pain scores, and have shorter hospital stays.

Office Operative Hysteroscopy Using the Lina Operascope Lasso and Biopsy Forceps

Nancy Hafner¹, Nadine Hammoud¹

¹*Fairfax Gynaecology Group, Gynaecology, Fairfax, USA*

Background

Advances in endoscopic technology have facilitated the development of innovative and ergonomic hysteroscopes with instruments that can be used in an office set up. Outpatient operative hysteroscopy is now a frequent procedure that allows patients to be diagnosed and treated during the same appointment.

Methods

Retrospective data was collected from hospital records from 148 patients who underwent office hysteroscopy, including 31 patients with polypectomy and 27 patients with targeted endometrial biopsy. All procedures were performed in a private gynaecology practice in Fairfax, Virginia.

Office hysteroscopy was performed with the LiNA Operascope, a single use hysteroscope with an operative channel. Polypectomies were performed with the LiNA Operascope Lasso (16 mm), a 5 Fr mechanical instrument with a basket at the distal end. Targeted biopsies were obtained with the LiNA Operascope Biopsy Forceps (5 Fr).

Results

In 2021, 148 hysteroscopies were performed in an office setting under local anaesthesia with paracervical block. The mean age of the patients was 53 years. 53% of the patients were menopausal. The main indications for hysteroscopy included abnormal uterine bleeding, postmenopausal bleeding, abnormal findings during diagnostic imaging as well as endometrial polyps.

In 31 patients' polypectomies were performed with the LiNA Operascope Lasso. In 29/31 patients the polypectomies were successfully completed (average polyp size 1,1 cm, ranging from 0,5 – 2 cm). In one patient the endometrial polyp was only partially removed due to large polyp size (2,5 cm). One patient did not tolerate the hysteroscopy procedure. In all successful polypectomy cases sufficient tissue samples for pathology assessment were obtained.

27 patients underwent endometrial biopsies with the LiNA Operascope Biopsy Forceps. In 26/27 cases the procedure was completed successfully and sufficient tissue samples for pathology assessment were obtained. None of the patients who underwent endometrial biopsies with the LiNA Operascope Biopsy Forceps experienced any interruption due to pain or loss of tolerability during the procedure.

Conclusions

The LiNA Operascope Lasso and Biopsy Forceps are suitable instruments for hysteroscopic polypectomies and targeted endometrial biopsies in the office setting.

Robotic-assisted laparoscopic partial cystectomy for urologic deep infiltrating endometriosis

Maria Teresa Murcia¹, Sonia Monreal¹, Eva Vila¹, David Lorente², Laura Mañalich¹, Antonio Gil-Moreno¹

¹*Hospital Vall d'Hebron, Gynecology, Barcelona, Spain*

²*Hospital Vall d'Hebron, Urology, Barcelona, Spain*

Background

Endometriosis is a chronic inflammatory disease that affects approximately 10 - 15% of women of childbearing age. Urological involvement is seen in 1.2-3.9% of women with endometriosis. The bladder is the most common location of urinary tract endometriosis (84-90%). Ureter involvement is commonly extrinsic, ureter compression is rare but can lead to obstruction up to silent loss of renal function. Minimally invasive surgery provides significant advantages, with lower rates of surgical complications such as surgical trauma, infection, postoperative pain and hospital stay. The objective is to demonstrate the safety and feasibility of robotic-assisted laparoscopic approach to urinary tract endometriosis.

Methods

We present a stepwise approach to robotic-assisted laparoscopic urinary tract endometriosis management, demonstrating its feasibility and safety. The surgical procedure is a partial cystectomy, and it is performed with the Da Vinci Xi robotic surgical system.

Results

The interest of robotic assisted laparoscopy in deep infiltrating endometriosis seems to be promising. Robotic surgery is shown to have similar perioperative outcomes to conventional laparoscopy; however, provides additional advantages of 3D visualization, shorter learning curve compared to conventional laparoscopy, ergonomics for the surgeon, improved dissection in tight pelvic spaces and facilitation of suturing techniques.

Conclusions

The surgical management of ureter and bladder endometriosis is usually feasible and safe through robotic assisted surgery. The benefit of minimally invasive surgery to the patient is widely accepted with robotic-assisted laparoscopy.

Case series of non-tubal ectopic pregnancies: How to manage laparoscopically in an efficient way?

Rahul Gore¹, Zacharoula Koukoulis¹, Kamran Safdar Rao¹, Neerajavani Yeddula¹, Shane Bandara¹, Sarah Smith¹
¹Colchester General Hospital, Obstetrics and Gynaecology, Colchester, United Kingdom

Background

Nontubal ectopic pregnancies are rare with a reported incidence varying from 10/10000 to 1:30000 and they pose a great challenge for diagnosis and management.

At our district general hospital, we performed an observational study of unusual ectopic pregnancies, from Feb 2021 to May 2022.

Methods

Case summaries are as below.

Results

Case 1. 37 years old, case of **ruptured ovarian ectopic** pregnancy with 700 ml hemoperitoneum. Promptly diagnosed with clinical judgment and managed laparoscopically. The suspected trophoblastic tissue invading the ovary was excised and the ovary was conserved. Histology confirmed the diagnosis of ovarian ectopic pregnancy. HCG surveillance suggested decreasing titres. The patient received Methotrexate and recovered well.

Case 2. 39 years old, was diagnosed to have **heterotopic pregnancy** at 7 weeks GA. She was managed conservatively with safety netting advice in multidisciplinary settings and under the guidance of the tertiary care centre. The tubal ectopic pregnancy remained stable and spontaneously resolved in the first trimester. Growth scans were normal, and she had a spontaneous vaginal delivery at 37.4 weeks of gestation.

Case 3. 33 years old, case of **ruptured ovarian ectopic** pregnancy with hemoperitoneum. There was a high degree of suspicion of ovarian ectopic based on the scan findings. The patient needed ovarian wedge resection and the ovary was conserved. Histology confirmed the diagnosis of ovarian ectopic. The patient recovered well postoperative.

Case 4. 28 years old with 7 weeks ectopic pregnancy at the **caesarean scar**. Presenting symptom was a lower abdominal pulling sensation. A transvaginal ultrasound scan (TVS) had revealed scar ectopic with a mean Gestational Sac diameter of 10 mm & initial bHCG 31867. Upon careful discussion of all the options (Medical Vs Surgical), the patient opted for a conservative approach with a Methotrexate injection. With appropriate safety netting, she was managed successfully and bHCG dropped down steadily.

Case 5. 33 years old with 8 weeks **cornual ectopic pregnancy**. She presented with per vaginal spotting. The TVS revealed a left cornual ectopic pregnancy of 20 mm size and a small pseudo sac in the cavity. bHCG level was 9120. The case was managed by a multidisciplinary team and the laparoscopic excision was performed by an expert laparoscopic surgeon. The patient recovered well.

All these five cases had good outcomes.

Conclusions

1. For nontubal ectopic pregnancies, diagnosis should be with high index of suspicion and treatment should be prompt to avoid potentially catastrophic consequences such as massive haemorrhage, hysterectomy, and death.
2. In haemodynamically stable patients and with competent hands, laparoscopy has advantages over laparotomy for better recovery, safety, and satisfaction, however, this approach should be appropriately individualised.
3. Conservative and medical management can be considered with the safety netting, especially in cases of heterotopic or scar ectopic pregnancy.

ISTHMOCELE: A CLINICAL CORRELATION WITH HISTOPATHOLOGICAL FEATURES AND SURGICAL APPROACH

Bedayah Amro¹, Maria Ramirez¹, Zeinab Hakim¹, Rabia Farhan², Philippe Koninckx³, Arnaud Wattiez⁴

¹*Latifa Hospital, Obgyn, Dubai, United Arab Emirates*

²*Dubai Hospital, Pathology, Dubai, United Arab Emirates*

³*Latifa Hospital, Research, Dubai, Belgium*

⁴*Latifa Hospital, Gyn, Dubai, United Arab Emirates*

Background

As the rates of caesarean section are rising, isthmocele is an emerging complication (CSs), which is being encountered more frequently by gynaecologist, radiologist, and pathologists. An isthmocele results in a wide variety of symptoms including but not limited to postmenstrual spotting and discharge, dysmenorrhea, and dyspareunia. There is a deficiency in the literature regarding the histopathologic features of isthmocele, its clinical background and the rationale behind different techniques in Isthmocele treatment approach in this context

Objectives: Our aim is to determine the prevalence of isthmocele in women with previous caesarean section through analysing the hysterectomized specimens, and study the details of its histopathology to correlate it with the clinical symptoms, and be able to explain the rationale behind the different surgical approaches in this context

Methods

We analysed, clinically and histopathologically, 50 cases of isthmocele found in laparoscopic hysterectomized uterus by performing a prospective study. A detailed statistical analysis done

Results

All of the women were symptomatic, being dysmenorrhea the most common complaint. All the studied specimen presented at least one isthmocele, one case had 2 isthmocele. The majority of isthmocele were described as triangular shape located in the upper part of the cervical canal, only one case in the lower part and none at the level of the isthmus. This could be correlated with certain symptoms. The most common microscopic finding was mild congested blood vessels and the least common was presences of macrophages within the ishtmocele. New described histological findings; an inclusion cysts at the era of isthmocele, Elastosis replacement of the tissue, adenomyosis in the depth of the isthmocele, and the unsynchronized phase of the endometrium at the isthmocele site compared to rest of endometrium.

Conclusions

It is essential part to deeply understand the histopathological base of the ischiocele; in order to be able to correlate the patients symptoms to the type of the pathology present, and eventually to offer her the best possible option of treatment in that context. With this study especially with this number of specimens; new thinking in the way of isthmocele do cause pathology by going to the origin of it and look deeply on those pathological tissues and its physiology. Also questioning the routine surgical manoeuvres that done nowadays if it is really indicated always or if it is just unnecessary by correlating it to it effect on correction from histopathological point of view.

A newer generation of barbed suture with self-locking system for vault closure after laparoscopic hysterectomy- our experience of this promising new strategy!

Rahul Gore¹, Zacharoula Koukouli¹, Kamran Safdar Rao¹, Anahita Shahmiri¹

¹Colchester General Hospital, Obstetrics and Gynaecology, Colchester, United Kingdom

Background

Suturing is an integral part of the surgery and there have been many advances in the suture materials and the suturing techniques. Recently, new suture material called 'barbed suture' has been included in the surgeon's armamentarium. There are many commercial varieties of these sutures available such as Quill™ SRS, V-Loc™, RESORBA®, Filbloc® (a new generation of barbed suture with self-locking system), etc.

Numerous publications outline the advantages and disadvantages of various types of sutures and techniques in the context of vault closure after laparoscopic hysterectomy. Vaginal cuff dehiscence is reported as one of the serious complications in the event of inadequate wound healing, with an incidence between 0.64% and 1.35%. Whilst some reports encouraged barbed sutures because of their various benefits, the others argued about serious complications like bowel obstruction due to exposure to barbed sutures.

We decided to explore the outcomes of laparoscopic hysterectomy cases in our unit where we have used newer generation of barbed sutures (Filbloc).

Methods

Our study:

Aim: To demonstrate the benefits of the newer generation of barbed sutures (Filbloc) for vault closure.

Objectives:

1. To study the demographics of the laparoscopic hysterectomy cases with vault closure using barbed sutures
2. To study various intraoperative and postoperative complication rates, mainly vaginal cuff dehiscence and bowel obstruction.

Materials & Methods:

We performed a retrospective observational study of laparoscopic hysterectomies (n=57), over a period of 3 years (2018 -2021), at Colchester General Hospital, UK.

Results

We studied 57 cases of laparoscopic hysterectomies performed for various indications (pre-malignant lesions of cervix or endometrium, adenomyosis fibroid uterus and endometriosis) wherein Filbloc® with self-locking system was used for vaginal cuff closure. The mean age is 45.4 years [Range 28 to 84]. Our intraoperative complications remained very low, with an average intraoperative blood loss is 109 ml. There was no visceral organ damage. Postoperatively, there was an excellent recovery with an average duration of the stay in the hospital being 1.7 days. None of the patients suffered from vaginal cuff dehiscence or bowel obstruction. Four of them needed postoperative readmission for minor illnesses such as postoperative infection and were successfully managed with conservative management. In addition to this, the surgeons appreciated the ease of use of Filbloc®, which helped reduce the operative time, and facilitated effortless suturing. The surgeons had ensured basic principles such as the ends of the barbed suture are either buried, over-sewn, or cut flush with the tissue.

Conclusions

1. The newer generation of barbed sutures offer rapid wound closure with equal distribution of tissue tension across the suture line and thereby providing a more secure wound closure, especially for post-hysterectomy vault closure.
2. With appropriate technique, these barbed sutures prove to be safe for the intended use.

Impact of adenomyosis and endometriosis on chronic pelvic pain after niche repair

Marie Timmermans¹, Stavros Karampelas², Evy Gillet², Betty Kellner², Michelle Nisolle¹

¹CHU of Liege, Obstetrics and Gynecology - site Citadelle, Liege, Belgium

²CHU Brugmann, Gynecology, Bruxelles, Belgium

Background

To determine if the laparoscopic isthmocele repair in patients with endometriosis and/or adenomyosis (AD) has an impact on the post-operative outcomes on chronic pelvic pain (CPP).

Methods

A retrospective study was performed on 45 patients who underwent laparoscopic niche repair surgery between 2016 and 2021 in Liege University Hospital La Citadelle at the department of Obstetrics and Gynecology. Their preoperative ultrasonography was studied using the MUSA criteria in order to determine the presence of adenomyosis. The histology results were used to detect the presence of endometriosis. According to the clinical practice, all patients were seen in a post-operative period of 3 to 6 months and afterwards at their annual check-up. Data were collected from medical records.

Results

Out of the 45 patients, 80% had adenomyosis, 40% endometriosis and 33% endometriosis and concomitant adenomyosis. Out of the 36 patients with AD, 67% had diffuse type, while 19% had anterior focal AD. On the 18 patients with endometriosis, 83% show concomitant adenomyosis.

In post-operative period (at 3 to 6 months), only 1 out of 18 patients (5%) with endometriosis, 5/21 (24%) with AD only, and 6/15 (40%) with both pathologies had CPP recurrence. There are more CPP recurrent patients in the group of endometriosis with concomitant AD compared to endometriosis only group (statistical significance $p < 0,05$).

In post-operative period (at 12 months), only 1 out of 18 patients (5%) with endometriosis only has CPP recurrence, with AD only 2/21 (9,5%), and both 8/15 (53%).

There are more CPP recurrent patients in the group with the presence of simultaneous pathologies compared to endometriosis (statistical significance $p < 0,01$) or AD only (statistical significance $p < 0,02$).

Conclusions

Caesarean section has an important impact on adenomyosis development. In our case series, 80% of our patients treated for isthmocele present concomitant AD. Moreover, 86% of them show diffuse or anterior focal AD.

To our best knowledge, it is the first long term study on the CPP outcomes for patients who have been treated for niche repair. Our results demonstrate that there is an important CPP recurrency rate in patient with AD and concomitant endometriosis after 1 year.

Patients who undergo niche repair should be selected carefully as CPP does not seem to be a good indication for uterine scar repair in patients with concomitant adenomyosis and endometriosis.

Out-patient selective tubal test with concomitant evaluation of the uterine cavity

Luca Lukács¹, Judit Lőrincz¹, Bence Boldogh¹, Márton György Lipták¹, Tünde Herman¹, Péter Török¹

¹University of Debrecen, Department of Obstetrics and Gynecology, Debrecen, Hungary

Background

Infertility is a common problem of couples with reproductive age. Tubal abnormality is an important cause of infertility, accounting for 25%–35% of female infertility. Tubal patency testing is important during infertility work-up before any assisted reproductive technique is performed. The relevance of diagnostic hysteroscopy, especially when performed in an outpatient “office” setting, in the evaluation process of infertility has increased in the last few years. During diagnostic hysteroscopy any morphological change of the uterine cavity or endometrium can be detected, not to mention the possibility for the tubal patency test. Our aim was to investigate the results of women who underwent selective pertubation with office hysteroscopy.

Methods

A total of 212 women were included in this retrospective study, who chose diagnostic office hysteroscopy during their infertility work-up. In each case before and after the procedure 3D ultrasound was used for evaluation of the uterine cavity. The selective pertubation with office hysteroscopy was performed in an outpatient setting, without general anaesthesia.

Results

Primary infertility (in 75 %), secondary infertility (in 22,17 %), repeated abortions (in 1,89 %), positive ultrasound results (in 0,94 % of the cases) made the indication for office hysteroscopy. The mean age of the patients was 33.1 ± 4.77 . During the evaluation of uterine cavity 13 cases required polypectomy as well and 1 patient needed uterine myomectomy. Endometrial visualisation of 39 cases indicated biopsy as well during the evaluation with office hysteroscopy, this way 8 chronic endometritis were detected. Regarding the selective pertubation test, we detected positivity (tubal abnormality) in 61,32 % of the study, among them we explored unilateral occlusion in 43,08 % of the cases and bilateral occlusion in 56,92 % of the patients. No complications occurred during the 212 diagnostic office hysteroscopies.

Conclusions

Our results suggest this novel method, selective pertubation with office hysteroscopy, which is an effective, accurate, minimally invasive method to investigate tubal patency, in outpatient circumstances in order to choose proper assisted reproductive techniques. This way the complications of general anaesthesia or radiation (HSG) can be avoided. Moreover, with the examination of the uterine cavity, other factors, such as polyps, micropolyps, fibroids, chronic endometritis can be detected and treated so fertility can be improve as well.

Reproductive outcome after diagnosis and treatment of chronic endometritis in patients with recurrent implantation failure

Ana Vegas¹, Elena Carrillo De Albornoz¹, Álvaro Martínez¹, Enrique Moratalla², Irene López², Isidoro Bruna³

¹Hospital Ruber Internacional, Obstetrics- Gyneacology and Reproductive Medicine, Madrid, Spain

²Hospital Universitario HM Montepríncipe, Obstetrics and Gyneacology, Madrid, Spain

³HM Fertility Center, Reproductive Medicine, Madrid, Spain

Background

Chronic endometritis (CE) is the persistent inflammation of the endometrial layer. It seems to play an important role in patients with recurrent implantation failure (RIF). The objectives of this study are:

To assess reproductive outcome after treatment of CE in patients with RIF.

To assess the reliability of hysteroscopy, CD138 histopathology and endometrial culture for CE diagnosis.

Methods

Prospective, longitudinal, cohort study that includes all patients with RIF between May2019 and August2021 in two Tertiary Hospitals. RIF was defined as the failure to conceive after three consecutive single embryo transferes of good quality blastocysts in women under 40 or two euploid blastocysts. All patients underwent hysteroscopy, histopathological CD138 study, endometrial and vaginal cultures, to assess CE. Hysteroscopic findings, five or more plasma cells in the endometrial sample or positive endometrial cultures were considered CE. Women with an antiphospholipid syndrome and other haematological or immunological issues were excluded if they had not received the treatment for those pathologies in the previous transferes. Also, patients who received egg donation or PGTA after RIF were excluded if it was not done in previous cycles. The study was approved by the Ethical Committee. The information document was provided, and all patients signed the informed consent.

Results

103 women were included. 33% (34) showed CE signs in hysteroscopy, 30.1% (31) had plasma cells in the histopathological study and 33.6% (32) resulted in positive endometrial culture. 56% (58) revealed pathological result in at least one test. The degree of agreement was moderate between hysteroscopy and histology ($\kappa=0,48$), and low between culture and histology ($\kappa=0,257$) and culture and hysteroscopy ($\kappa=0,294$). The global rate of agreement between the three tests was 57.28%. *Enterococcus faecalis* was the most frequent isolated microorganism in the endometrial cultures, followed by *Escherichia Coli*. Vaginal swab did not reveal any coincidence with endometrial cultures. All women with at least one positive exam (58) received antibiotic therapy. Patients with positive culture were treated according to the antibiogram, and those with negative cultures received Doxycyclin 100mg/12h. Treatment was repeated until every patient presented normal results. 69% (40) were normal after a single antibiotic cycle; 22% (13) were treated twice. Finally, 3 and 2 patients needed three and four antibiotic cycles respectively to achieve normal results. Before CE treatment, implantation rate (IR) was 16.8%, clinical pregnancy rate (CPR) was 3.9% and live birth rate (LBR) was zero. After CE treatment, 49 patients underwent embryo transfer, with 72.5% IR, 68.8% CPR and 60% LBR. This increase in IR, CPR and LBR was statistically significant ($p<0.05$). No differences in endometrial thickness were found between transferes previous to the CE treatment and subsequent.

Conclusions

According to our results, it may be convenient to assess CE by hysteroscopy, histopathology and endometrial culture, as these tests do not achieve a good agreement.

Performing a careful technique to obtain the endometrial sample, it seems that there is no vaginal contamination.

Antibiotic treatment of CE improves reproductive outcome in patients with RIF.

Use of Helica System for the treatment of early-stage endometriosis- A Systematic review

Zahra Azeem¹, Evangelia Bakal²

¹*University Hospital Birmingham, Obstetrics and Gyneacology, Birmingham, United Kingdom*

²*University Hospital Birmingham, Obstetrics & Genecology, Birmingham, United Kingdom*

Background

Helica thermal coagulator is a promising novel treatment that has become a more prominent option in treatment of early-stage endometriosis nowadays. A single use probe is inserted through the port which destroys the endometriosis with the help of helium gas ionizing beam using a non -touch approach.

This review was carried out to assess the effectiveness of Helica in the treatment of endometriosis.

Methods

Sources searched CINAHL, EMBASE, EMCARE, MEDLINE, PubMed. Limits used (gender, article/study type, etc.): English language. Search terms and notes HELICA, early-stage endometriosis.

Results

Our study showed that Helica was safer than the other techniques used for ablation of endometriosis as it penetrates less tissue depth if used in some area for longer as compared to the other techniques which means it causes less thermal damage. The technique is easy to learn, and no side effects have been reported. Some studies show that it improves the fertility rate as compared to the endometrial ablation with diathermy.

Conclusions

More studies are needed to assess the long-term effect and recurrence in patients that are being treated with Helica. It appears to be a safe and cost-effective treatment that leads to more thorough treatment of endometriosis.

The Minitouch Outpatient Endometrial Ablation Procedure: Results from a Prospective, Multicentre, Pivotal Clinical Trial

Scott Chudnoff¹, Amy Brenner², Cindy Basinski³, Mark Akin⁴, Stephanie Reich⁵, Christina Sebestyen⁶

¹*Maimonides Health, OBGYN, Brooklyn, USA*

²*Amy Brenner- MD & Associates, Gynecology, Mason, USA*

³*CMB Research, Gynecology, Newburgh, USA*

⁴*AA Obgyn, Gynecology, Austin, USA*

⁵*CTOA Women's Health Texas, Gynecology, Austin, USA*

⁶*OBGYN North, Gynecology, Austin, USA*

Background

To evaluate safety and effectiveness of the Minitouch Outpatient Procedure for treatment of heavy menstrual bleeding.

Methods

A prospective, multicentre, single-arm, open label, pivotal clinical trial was conducted to evaluate safety and efficacy of Minitouch Outpatient Endometrial Procedure. The Trial was approved by the United States Food and Drug Administration (US FDA) and was conducted at 5 US physician's offices. Follow-up assessments were made at 24 hours, 2 weeks, 3-, 6-, and 12-months post-procedure.

114 premenopausal women with a history of heavy menstrual bleeding and a Pictorial Blood Loss Assessment (PBLAC) score >150 were treated with the Minitouch Procedure. The demographics were as follows - mean \pm SD (range): age 41.6 ± 4.6 (30-50) years, parity 2.3 ± 1.1 (0-5), sounding depth 8.6 ± 1.1 (7.0-11.0) cm, uterine cavity length 5.2 ± 0.8 (4.0-7.0) cm, and endometrium thickness 9.5 ± 4.2 (3.0-23.4) mm.

All 114 Minitouch Outpatient Procedures were performed without endometrial pre-treatment or period timing. Cervical dilation was not required in 93% of the procedures since the device diameter is slim at 3.8mm. The procedure does not require a cavity integrity test or cavity sealing

Results

The data was collected from 100% (114/114) of the subjects in 100% of the follow-ups; there was 0% loss to follow-up.

The primary effectiveness endpoint was reduction of menstrual blood loss to a PBLAC score ≤ 75 which was met by 90% of the subjects, with 52% of the subjects reporting amenorrhea.

Pre-procedure, 47% of the subjects reported their bleeding limiting work either 'quite a bit' or 'extremely', and an additional 30% reported 'moderately'. Post-procedure, the percentages were 0% and 3% respectively.

Pre-procedure, 50% of the subjects reported their bleeding limiting social/leisure activity either 'quite a bit' or 'extremely', and an additional 26% reported 'moderately'. Post-procedure, the percentages were 1% and 1% respectively.

Pre-procedure, 57% of the subjects reported their bleeding limiting physical activity either 'quite a bit' or 'extremely', and an additional 24% reported 'moderately'. Post-procedure, the percentages were 2% and 1% respectively

81% (92/114) of the subjects were discharged within 30 minutes post-procedure, with an average pain score of 2.6 (scale 0 to 10) at discharge.

There were no device or procedure-related serious adverse events.

Conclusions

The Minitouch Outpatient Endometrial Ablation procedure is safe and effective. It can be performed in a physician's office, does not require endometrial pre-treatment or period timing, and has a short recovery period.

Osseous metaplasia of the endometrium- The bony womb and its hysteroscopic management.

Naimah Raza¹, Lina Antoun¹, Paul Smith¹, Justin Clark¹

¹Birmingham Women's Hospital, Obstetrics & Gynaecology, Birmingham, United Kingdom

Background

Background

Osseous metaplasia of the endometrium is a rare pathological condition associated with the presence of bone in the uterine endometrium. Clinically, it presents with menstrual problems or infertility. Most cases occur following pregnancy, especially miscarriages or abortion.

Methods

Case / Method

A 29-year-old nulliparous woman attended our out-patient clinic with irregular heavy periods and secondary infertility. She underwent a surgical termination of pregnancy at 20 weeks three years ago in Nigeria. She had an out-patient hysteroscopy which showed bony fragments in the endometrial cavity. One of the bony fragments was retrieved using hysteroscopy forceps and sent for histopathological examination. Histology was suggestive of endometrial osseous metaplasia. A further hysteroscopic retrieval was planned under general anaesthesia, after pre-operative GnRH analogues. Truclear Elie Hysteroscope plus and tissue shaver was used to break down the bony parts and remove them. Check hysteroscopy showed a clear cavity with bilateral ostia visualised.

Results

Histology of the sample retrieved showed fragments of trabecular bone with non-hematopoietic marrow spaces suggestive of metaplastic changes.

We referred her to our fertility MDT where she and her partner had normal investigations. She is currently under the care of our fertility team.

Conclusions

Hysteroscopy is the gold standard for diagnosis and management of osseous metaplasia of endometrium. Clinicians need to be aware of this rare condition when they encounter such clinical presentation in a woman, especially following an abortion or miscarriage. Timely diagnosis and treatment is the key, particularly when fertility is a concern.

When you see bubbles in laparoscopic endometriosis surgery: a positive air leak test

Ayesha Mahmud¹, Gourab Misra¹

¹University Hospitals of North Midlands, Obstetrics & Gynaecology, Stoke-on-trent, United Kingdom

Background

Recognition of bowel perforation during surgery is an important learning component of endometriosis surgery. When excising endometriosis from the pouch of Douglas, pararectal dissection is needed. In these cases, careful identification of anatomical landmarks, following dissection planes, and familiarity with different techniques to assess bowel integrity is helpful. An air leak test is currently one of the most common intra-operative procedures for assessing mechanical anastomosis performance, as well as diagnosing and treating occult bowel injuries. If the test is positive, additional treatments such as bowel suturing, reinforcing stitches, or a protective ileostomy are performed to prevent complications according to the complexity of the defect or leak. However, despite its widespread use, the test lacks a unique and clear definition and standardization.

Methods

We present a case of stage 4 endometriosis where following extensive bowel dissection, a positive air leak test showed bubbles appearing through saline in the pelvis. An intraoperative bowel repair was carried out safely and is demonstrated on video. We also discuss the controversies around the various approaches to undertaking the air leak test with a literature review.

Results

The air leak test is helpful in detecting occult disruptions of the bowel, leaving out other pathologic mechanisms of Anastomotic Leak such as healing disturbances or infection. Evidence suggests that using the air leak test on a regular basis does not appreciably minimize complications. However, its use is strongly advised because, in the event of a positive result, the danger of leakage increases considerably, necessitating the consideration of further surgical intervention.

Conclusions

The air leak test is an important component of testing bowel integrity in endometriosis surgery. Knowledge and understanding of the different techniques and limitations of the air leak test in detecting bowel defects are essential for any endometriosis surgeon.

Surgical morbidity associated with total laparoscopic hysterectomy – a three-year experience from a tertiary centre

Ana Carolina Coimbra¹, Pedro Viana Pinto^{1,2,3}, João Cavaco-Gomes^{1,3}, Ana Sofia Fernandes¹, Margarida Martinho^{1,3}, Jorge Beires¹

¹*University Hospital Center of São João, Gynecology, Porto, Portugal*

²*Faculty of Medicine- University of Porto, Anatomy Department, Porto, Portugal*

³*Faculty of Medicine- University of Porto, Gynecology and Obstetrics Department, Porto, Portugal*

Background

This study aimed to evaluate the morbidity and complication rate associated with total laparoscopic hysterectomy (TLH) and to identify risk factors.

Methods

In this retrospective study, data from patients undergoing elective TLH for benign indications in a tertiary hospital from 2019 to 2021 were analysed. Complications occurring intraoperatively and within 6 weeks from surgery were registered. Major complications included deep/organ-space surgical site infection, major bleeding, blood components transfusion, all organ lesions, reoperation, readmission, and major anaesthetic complications. Minor complications included urinary tract infection and superficial wound dehiscence or infection. Categorical variables are presented as frequencies and percentages and were compared using the chi-square test. Continuous variables are expressed as means and standard deviations or medians and interquartile range (IQR) and were compared using Mann-Whitney or Student's t-test.

Results

During the study period, 271 total laparoscopic hysterectomies were performed. Patient mean age was 48.5 ± 9.4 years and median body mass index was 27.2kg/m^2 (IQR 7.81); 25.9% patients were postmenopausal and 52.6% were taking hormonal contraception/therapy. Regarding parity, 16% of patients were nulliparous and 64.5% had at least one vaginal delivery; 54.8% had previous abdominopelvic surgery. Main indications for hysterectomy were uterine fibroids (39.8%) and hereditary cancer syndromes (14.7%). Median uterine weight was 128g (22-1939 min-max; IQR 150), median greatest diameter was 8.5cm (4.4-17.4 min-max; IQR 3.2), and morcellation was required for uterine removal in 9.6% of cases. Length of hospital stay was 2 days (IQR 1 day). Surgical excision of endometriotic lesions was performed in 4.8% of patients.

Overall complication rate was 24.6%, with a rate of 9.2% and 16.4% major and minor complications respectively. Deep infection/sepsis (2.7%, n=7) and bladder lesions (1.8%, n=5) were the most frequent major complications, while intraoperative vaginal lacerations (7.8%, n=20) and urinary tract infections (4.7%, n=12) were the most common minor complications. Same-hospital readmissions occurred in 5 patients (1.8%). There were no cases of conversion to laparotomy. Parous women showed a lower rate of minor complications (10.7%) when compared to nulliparous patients (25.6%), $p=0.008$. Hormone therapy was associated with a lower rate of intraoperative complications (7.1% vs. 17.9% in women without any hormone therapy, $p=0.009$) and surgical excision of endometriotic lesions was associated with a higher rate of major complications (30.8% vs. 8.2% in women without endometriosis, $p=0.006$). Patient age, body mass index, uterus weight and size, menopause and previous abdominopelvic surgery showed no association with complications from TLH.

Conclusions

In this study, the rate of complications from TLH was similar to previously published data. Parity and hormone therapy seem to be protective factors, while excision of endometriotic lesions was associated with a higher rate of major complications.

Ovarian dermoid cysts: factors influence surgical outcome.

Khayal Gasimli¹, Caroline Victoria Otte¹, Thomas Karn¹, Sanhaji Mourad¹, Sven Becker¹, Morva Tahmasbi Rad¹
¹J. W. Goethe-University Frankfurt, Department of Gynecology and Obstetrics, Frankfurt, Germany

Background

Dermoid cysts are rare and cause pathological findings in the ovary. Deep knowledge of the condition is necessary as dermoid cysts can be both benign and malign. Furthermore, recurrence of such an ovarian cyst must be avoided to prevent further damage to the ovarian tissue and several surgeries. Elective surgery can be performed when the cyst is diagnosed but does not show any symptoms. Emergency surgery is performed in case of ovarian torsion. The challenge is to remove the dermoid cyst as a whole without rupturing.

Methods

335 cases of patients with dermoid cysts and surgery from 2012 to 2020 were reviewed retrospectively. Parameters taken into consideration were demographical, surgical, and pathology results. The study was contributed to identifying factors that might significantly impact the patients and surgical outcomes.

Results

The median age of the cohort was 33 years, and the median BMI was 24,30 kg/m². Most surgeries were performed in 2015 with a total of 89 (26%). The surgical time was significantly increased in obese patients ($p < 0.05$) and in patients with a significant volume of the dermoid cyst ($p = 0.003$). Also, the hospital stay length was significantly longer in obese patients ($p = 0.03$). The surgical management (laparoscopic vs. Laparotomy) was chosen based on the size of the cyst, and when laparotomy was performed, and the hospital stay length increased significantly ($p = 0.001$).

Conclusions

Surgical management of dermoid cysts should be based on the size of the cyst and could impact to hospital stay length.

Outcomes of laparoscopic sacropexy: complications and quality of life assessment

Ines Lourenco¹, Ana Paula Pereira², Fátima Faustino³, Carlos Veríssimo²

¹Hospital Beatriz Ângelo, Gynecology and Obstetrics, Loures, Portugal

²Hospital Beatriz Ângelo, Gynecology and Obstetrics, Loures, Portugal

³Hospital Lusíadas Lisboa, Gynecology and Obstetrics, Lisboa, Portugal

Background

Sacropexy, especially by laparoscopic approach, has emerged in recent years as the procedure of choice for the surgical treatment of pelvic organ prolapse (POP).

The primary objective of this study is to evaluate recurrences of laparoscopic sacropexy requiring subsequent surgery and the secondary objectives are to evaluate the occurrence of other complications and improvement in quality of life after surgery.

Methods

Retrospective study of laparoscopic sacropexies performed at Hospital Beatriz Ângelo (HBA), between January 2012 and December 2019. Data were collected from hospital's clinical files and a survey conducted by telephone, using a score of subjective patient-based life improvement, from 0-10. Statistical analysis was performed with Excel ®

Results

During the study period, 69 laparoscopic sacropexies were performed. Age was, on average, 57 years, women had 2 vaginal deliveries and 25.64 kg/m² of body mass index (BMI). In 46 cases (66.7%), sacropexy was the first surgery for POP.

Colposacropexy was performed in 24 women (34.78%), total hysterectomy with colposacropexy in 15 (21.74%), subtotal hysterectomy and cervicosacropexy in 29 (42.03%) and hysteropexy in just 1 case (1.45%). Concurrently, stress urinary incontinence (SUI) surgery was performed in 4 cases (5.80%) and perineoplasty in 29 (42.03%). The mean operative time was 204 minutes, blood loss was on average 110mL, and the mean hospital stay was 3days. There were 4 intraoperative complications (5.80%) – 2 anaesthetic; 2 inadvertent openings of the vagina because of multiple adhesions. In these cases, it was necessary to convert the laparotomy, as well as in 2 others, due to multiple adhesions and difficulty identifying the sacrum. The total conversion rate was 8.70%.

To evaluate the complications rate, we excluded 11 women because they had less than 1 year follow-up. In the remaining 58, the mean follow-up time was 46 months. We identified 5 mesh erosions (7.2%), asymptomatic, that were stable and didn't require additional surgical therapy. All 5 erosions occurred after a total hysterectomy. Urinary incontinence "de novo" occurred in 11 women (15.94%) – 9 SUI (13.04%) and 2 urge incontinence (2.90%); symptoms improved after conservative therapy, only 1 was proposed for SUI surgery. Moreover, there were 4 symptomatic recurrences, requiring surgery (5.80%).

Of the 69 women included in the study, 50 answered the survey (72.46%). Of these, 40 (80%) reported an improvement of 9 or 10 in quality of life, 8 (16%) between 6-8 and only 2 (4%) reported an improvement ≤5.

Conclusions

Sacropexy is a surgery with a low rate of complications and recurrences and with a great impact improving the quality of life of women with POP.

Laparoscopic abdominal cerclage as an effective option for refractory cervical insufficiency – a case report

Sara Paiva¹, Hugo Barros¹, Ricardo Santos¹, Carla Duarte¹, Pedro Oliveira¹, Luísa Machado¹

¹Hospital da Senhora da Oliveira - Guimarães, Department of Obstetrics and Gynaecology, Guimarães, Portugal

Background

Cervical insufficiency is an important cause of preterm birth, complicating up to 1% of pregnancies. It is generally treated with a vaginal cerclage; however, a cerclage may be placed abdominally in cases where the vaginal cerclage has failed, or the cervix is extremely short. For these patients, laparoscopic abdominal cerclage is emerging as the preferred treatment option. It provides added integrity to the cervix, as it is placed higher on it, with less risk of caudal suture migration as the uterus enlarges. Also, the absence of a foreign body in the vagina may reduce the risk of ascending infection. There is no consensus about the best timing for the procedure, either before or after conception. When placed preconceptionally, it is not associated with lower conception rate. Recent evidence supports abdominal cerclage as being more effective than repeated vaginal cerclage, with laparoscopy presenting similar or superior outcomes in conception, second or third-trimester loss, preterm labour and neonatal survival compared to the open abdominal approach. Patients with an abdominal cerclage require a caesarean delivery, performed electively between 37- and 39-weeks' gestation, where the suture can be removed or left in place if a future pregnancy is intended.

Methods

Review of a clinical case.

Results

A 35-year-old female, gravida 2, para 0, both pregnancies followed frozen embryo transfer, was referred to our centre for evaluation of an incompetent cervix. The patient had a history of a medical termination of pregnancy due to preterm premature rupture of membranes at 18 weeks' gestation and, since foetal autopsy, thrombophilia's study and bacteriological and cytogenetic tests did not reveal anomalies, a prophylactic vaginal cerclage was placed at 14 weeks of her second pregnancy. However, at 22 weeks she was admitted in with mild pelvic pain associated to protruding membranes and an almost fully dilated cervix, hence the suture was removed leading to foetal delivery. She subsequently had a spontaneous conception and, so, a laparoscopic cerclage was proposed and performed at 9 weeks, using a 5-mm Mersilene® tape. No tocolytic agents were used intraoperatively. The procedure was uncomplicated, and the patient was discharged in the next day. The pregnancy was then followed in our centre without major events. A caesarean section was carried out at 37 weeks' gestation and a 2765g newborn was delivered, with an Apgar score of 9/10. The cerclage was left in, and the postoperative course was uneventful.

Conclusions

Laparoscopic abdominal cerclage is a safe and effective option in patients with a prior failed vaginal cerclage, having similar or improved obstetric and neonatal outcomes compared to the other approaches, besides the advantages of a minimally invasive surgery. Therefore, this report aims to support its preference as the first line treatment for refractory cervical insufficiency.

Resection of fibroids in out-patient setting

Márton Lipták¹, Bence Boldogh², Luca Lukács¹, Tünde Herman¹, Rudolf Lampé¹, Péter Török¹

¹University of Debrecen, Gynecology and Obstetrics, Debrecen, Hungary

²University of Debrecen, Gynecology and Obstetrics, Debrecen, Hungary

Background

Introduction: In case of submucous myomas associated with a number of clinical issues such as abnormal uterine bleeding (AUB), heavy menstrual bleeding (HMB), infertility, recurrent pregnancy loss, resectoscopic myomectomy has several advantages compared to the traditional surgical treatment of myomectomy by laparotomy, in terms such as decreased time of hospitalization, less morbidity and no hysterotomy and decreased risk of postoperative adhesion formation. Without general anaesthesia the outpatient hysteroscopy with the mini-resectoscope appears to be an efficient and acceptable instrument for hysteroscopic myomectomy.

Methods

Aim and method: Our aim was to investigate the results of women who underwent myoma resection with office hysteroscopy in our practice.

Results

Result: In 2021 we performed 21 office-hysteroscopic fibroid resection in our practice. Patients age ranged from 30 to 56 years. The indication of interventions was infertility in 4 patients and AUB in 17 patients. The type of fibroids was Figo 0, 1, 2 and ranged in size from 0.8 to 4.2 cm. 3 procedures were done without any anaesthesia and 18 after intra-cervical local anaesthetic injections or nitrogen oxid gas or both. The surgical time ranged from 7 minutes to 32 minutes. 3 patients required second step procedure. The interventions were performed without operative or postoperative complications.

Conclusions

Conclusion: Hysteroscopic myomectomy currently is the "gold standard" procedure for treating submucous myomas and represents an effective and safe solution to abnormal uterine bleeding and infertility. It is a feasible technique which could be performed in an office setting, and it is associated with high level of patient satisfaction.

Development of a core outcome set for clinical trials of heavy menstrual bleeding

Natalie Cooper^{1,2}, *Carol Rivas*³, *Rosa Papodotaki*⁴, *Hilary Critchley*⁵, *Malcolm Munro*⁶, *Khalid Khan*⁷

¹Queen Mary University of London, Obstetrics and Gynaecology, LONDON, United Kingdom

²Whipps Cross University Hospital, Obstetrics and Gynaecology, London, United Kingdom

³University College London, Social Research Institute, London, United Kingdom

⁴West Middlesex Hospital, VTS GP trainee, London, United Kingdom

⁵University of Edinburgh, MRC Centre for Reproductive Health, Edinburgh, United Kingdom

⁶David Geffen School of Medicine at UCLA, Department of Obstetrics & Gynecology, Los Angeles, USA

⁷University of Granada, Department of Preventive Medicine and Public Health, Granada, Spain

Background

There are multiple underlying causes of the symptom of heavy menstrual bleeding (HMB) and a variety of effective treatments, including hormonal, medical and surgical interventions. Although these treatments have been widely explored in clinical trials, they do not all report their results using the same outcomes, impairing comparison of treatments and comprehensive data synthesis therefore diluting the strength of clinical guidance recommendations. Thus, clear definitions and standardised reporting are needed to maximise the quality of clinical research.

Our aim was to develop a core outcome set (COS) of standardised key outcomes for research on interventions for the symptom of HMB designed to improve the quality of trial reporting, minimise selective reporting and reduce research waste.

Methods

We developed this COS using methods described by the COMET (Core Outcome Measures in Effectiveness Trials) Initiative. The project had 4 distinct phases-

1. Systematic review of previously reported outcomes
2. Workshop and interviews involving patients and their partners
3. An online Delphi survey involving major stakeholders from around the world
4. Consensus meeting with international representatives from all stakeholder groups to finalise the core outcomes.

For the Delphi process participants were asked to use a 1 (not important) to 9 (critical) scale to rate the outcomes. 'Consensus in' criteria required more than 70 % of the participants to score a given outcome as 'critical' (score of 7-9) whilst fewer than 15% rated it as not important (score of 1-3).

Results

The systematic review identified 111 outcomes; qualitative work identified an additional 5. This list of 116 outcomes was considered in the Delphi survey and 38 outcomes met 'consensus in' criteria. The consensus group finalised 10 outcomes to form the COS.

Conclusions

This COS should be used in all future trials of interventions for underlying causes of the symptom of HMB to improve the accuracy of data synthesis and comparisons. The COS should also be considered when developing clinical guidance and health policy. It is essential that those performing research and caring for women with the symptom of HMB are aware of this COS.

Training of gynecologic surgical psychomotor skills in dry skill lab- Our data experience

Zsolt Farkas¹, Rudolf Lampe¹, Peter Torok¹

¹University of Debrecen Faculty of Medicine, Obstetrics and Gynecology, Debrecen, Hungary

Background

Our institute has made its first step on the road to break the traditional apprentice-tutor model as recommended by the leading professional societies. We set a dry skill lab with four workstations, two e-knot trainer (SUTT), one hysteroscopic station (HYSTT), one pelvic trainer (LASTT). Our goal was to measure the improvement of the psychomotor skills of our sixth-year students (group1) and our residents (group2).

Methods

In the last two month of 2020 11 trainees (five students and six residents) participated in our six weeks training program at the Department of Obstetrics and Gynecology University of Debrecen Faculty of Medicine. We measured their time to correctly performed exercise (TCPE), trainees had to do the tasks belonging to the LASTT and HYSTT twenty times and the tasks belonging to the SUTT fifteen times.

Results

We observed marked decrease in TCPE in both groups.

LASTT (group1, group2): camera coordination (-31%, -27,84%), hand eye coordination (-23%, -34,12%), bimanual coordination (-38,96%, -14,04%)

HYSTT (group1, group2): camera coordination (-42,69%, -32,40%), hand eye coordination (-46,64%, -10,39%)

SUTT (group1, group2) stitch in 90 degree (-11,92%, -27,12%), stitch in 110 degree (-28,76%, -13,75%), stitch in 110 degree and a knot (-27,01%, -29,73%)

Conclusions

We can observe mostly more improvement in the group1, so our data support the previous studies in this field claiming that the more unexperienced group will improve more in the dry skill lab program. Training programs in dry skill lab are inevitable for trainees to acquire the necessary knowledge to begin their education in the operating room, with increased patient safety, self-confidence and probably reduced operation time.

Fertility and clinical outcomes following surgical treatment of bowel endometriosis: a cross-sectional study

Akshara Sharma¹, Lina Antoun², Yousri Afif², Leena Nagpa³

¹Aston Medical School, Medical Student, Birmingham, United Kingdom

²Birmingham Women's and Children's NHS Foundation Trust, Gynaecology, Birmingham, United Kingdom

³Birmingham women's hospital, Obstetrics and Gynaecology, Birmingham, United Kingdom

Background

To assess the quality of life (QOL) of patients who had surgical excision of bowel endometriosis in terms of improvement in clinical features and fertility outcomes.

Methods

A retrospective analysis of prospectively collected data of patients with bowel endometriosis who attended Birmingham Women's Hospital's Endometriosis Centre between 2011 and 2021. Baseline and management characteristics are presented as absolute and relative frequencies for qualitative variables and as mean and standard deviations.

Results

We included 90 bowel endometriosis patients with complete information on the BSGE database. 75/90 (83.3 %) patients had Laparoscopic Bowel shaving, 1/90 patient (1.1%) had segmental resection, 9/90 (10%) patients had no intra-operative bowel endometriosis, and 4/90 (4.4%) had no bowel endometriosis excision. Non-cyclical pelvic pain improved in 60/84 patients (71.4%) following surgery, whilst lower Back Pain improved in 58/85 (68.2%). Furthermore, dysmenorrhoea and dyspareunia improved in 55/84 (65.5%), and 49/74 (66.2%) of patients respectively. Cyclical dyschezia improved in 60/84 (71.4%) and non-cyclical dyschezia improved in 51/76 (67.1%). Bladder pain improved in 40/64 patients (62.5%). Bladder emptying difficulty was reduced in 30/55 patients (54.5%). QOL improved post-operatively in 56/81 patients (69.1%). Late complications up to 3 months post-surgery were found in (1/90) 1.1% of patients which involved a Urinary tract leak and ureteric implantation in a patient with segmental resection. 13/69 (18.8%) patients achieved pregnancy post-treatment.

Conclusions

Our cohort indicated an overall good QOL improvement rate, improved fertility outcomes, and extremely low complication rates. Our findings can provide additional guidance to enhance counselling for patients with bowel endometriosis.

Atosiban as a potential treatment for endometriosis; results from the ENDOBAN pilot study

Mark Schoep¹, Elise Taken¹, Annemiek Nap¹, Theodoor Nieboer¹

¹Radboudumc, Obstetrics and gynaecology, Nijmegen, The Netherlands

Background

Histological studies showed high expression of oxytocin receptor in endometriosis lesions. It was demonstrated that oxytocin triggers the production of prostaglandins in these cells. Atosiban, an oxytocine receptor antagonist, has shown therapeutic potential in animals. We investigated if atosiban can be a treatment for pain caused by endometriosis.

Methods

Phase II interventional pilot study. We started our study May 2022. Ten patients with confirmed endometriosis and an average pain score of 7 or higher during their periods will be administered atosiban for a period of 6 hours on the most painful day of their period. Women on continuous use of oral contraceptives, progestagens or GnRH analogs will be excluded.

Results

The main study parameter will be the reduction in pain score at several time points. Secondary study parameters include time tot pain reduction after the start of treatment with atosiban, use of analgesic medication, amount of blood loss, experienced side effects and serum levels of prostaglandin. The results of this pilot study will be revealed exclusively on the 31st Annual congress of the ESGE.

Conclusions

This pilot study of treatment with a selective oxytocin receptor antagonist aims to provide the first available evidence of atosiban being a potential target drug in relieving pain in patients with endometriosis.

Bladder Infiltrating Endometriosis as a complication following Mitrofanoff procedure in a known endometriosis patient – A Case Report.

Akshara Sharma¹, Lina Antoun², Yousri Afif², Nagpal Leena³

¹Aston Medical School, Medical Student, Birmingham, United Kingdom

²Birmingham Women's and Children's NHS Foundation Trust, Gynaecology, Birmingham, United Kingdom

³Birmingham women's hospital, Obstetrics and Gynaecology, Birmingham, United Kingdom

Background

Deep Infiltrating Endometriosis [DIE] is a severe form of endometriosis, with a known prevalence of 3-10% in women presenting with pain. Urinary tract endometriosis (UTE) is rarer, occurring in only 1–5.5% of women with endometriosis. We saw an extremely rare case not previously reported in the English Literature to our knowledge where all the above were seen in addition to the augmented bladder with the Mitrofanoff procedure being affected and distorted by the DIE.

Methods

A Case Report

Results

A 31-year-old nulligravid woman was referred to the Endometriosis Centre for suspected endometriosis and the patient's wish to conceive. She presented with a 2-year history of significant blood loss in her urine one day before and throughout her periods. This episode settled down until the next period cycle. She reported worsening bilateral flank pain, inter-menstrual bleeding, urethral and vaginal urinary incontinence. The patient had spina bifida with Clam Ileocystoplasty, and neuropathic bladder for which she had Mitrofanoff procedure and bladder neck closure in her childhood. A pelvic MRI confirmed the presence of extensive DIE involving the adnexa bilaterally, pelvic sidewall, uterus, the left ureter, full-thickness bladder wall with a deposit, thickened recto-sigmoid colon, all cranially extending to involve a small bowel segment, and visible distortion of the Mitrofanoff dome from the tethering of the surrounding tissues.

Conclusions

This is the first reported case of bladder endometriosis in an augmented bladder following Mitrofanoff. This case was managed by adopting a multidisciplinary team approach involving colorectal, urologists, and radiologists to ensure the best outcome.

Three different cases of Isthmocele Surgical repair – a casuistic study from Hospital da Senhora da Oliveira – Guimarães

Rita Ladeiras¹, Joana Sousa Nunes¹, Adriano Soares¹, Carla Duarte¹, Pedro Oliveira¹, Luísa Machado¹

¹Hospital da Senhora da Oliveira - Guimarães, Serviço de Ginecologia e Obstetrícia, Guimarães, Portugal

Background

C-section rate has been increasing globally, now accounting for more than 20% of all childbirths. Iatrogenic complications, such as isthmocele, a new entity described in the recent literature, are an emerging health problem. Isthmocele is a thinning and indentation of the myometrium at the hysterotomy site that results from inadequate healing of the myometrium. Patients are usually asymptomatic, but they can present with postmenstrual spotting, pelvic pain, dysmenorrhea, dyspareunia, uterine rupture, and secondary infertility and more rarely have a caesarean scar pregnancy. The diagnosis is made radiologically by transvaginal sonography, magnetic resonance imaging or saline infusion sonohysterography but also by hysteroscopy. Treatment can be done by controlling abnormal uterine bleeding (AUB) with hormonal therapy, or with surgical correction improving symptoms and/or fertility. For symptomatic women, especially for those who want to preserve fertility a surgical repair is an option. For those with residual myometrial thickness (RMT)>3mm, hysteroscopic remodelling is the modality of choice with an improvement in AUB, secondary infertility and pain. When the RMT is inferior to 3mm, laparoscopic repair with simultaneous hysteroscopic guidance has been propose as a better option.

The objective of this study is to describe 3 different cases of isthmocele surgical correction with a combine procedure with both hysteroscopy and laparoscopy.

Methods

Data from isthmocele surgical repair cases performed between October 2019 and May 2022 at *Hospital da Senhora da Oliveira* were collected and described.

Results

Case 1: 36 years old, G2P2(2 C-sections), with an infertility history and symptoms of postmenstrual spotting. The transvaginal ultrasound revealed a myometrial defect of 12.1x7.8x26.7mm, with an RMT of 2.6mm.

Case 2: 38 years old, G1P1(1 C-section), with an infertility history. The ultrasonography revealed a myometrial defect of 5x8x8mm, with an RMT of 3.1mm and a uterine fundus septation with 5mm.

Case 3: 39 years old, G1P1(1 C-section), with an infertility history. The ultrasonography revealed a myometrial defect of 5x10x10mm, with an RMT of 2.8mm.

A resectoscopy was performed and the superior and inferior edges of the defect were resected using bipolar energy in all cases. In cases 1 and 3, the myometrial defect was repair with Vicryl® 1/0 by laparoscopy guided by transillumination of the lesion area by hysteroscopy. In case 2, the septal fundus was also resected by hysteroscopy and myometrial thickness was proved to be preserved by laparoscopy after transillumination and myometrium was not repair.

In case 1 the AUB symptoms were improved, and she remains at the fertility support consultation. Patients 2 and 3 are currently waiting for a frozen embryo transfer.

Conclusions

Surgical treatment of a uterine isthmocele is a good option in women who are symptomatic and infertile and a combine procedure with both hysteroscopy and laparoscopy seems to be the best surgical option in these cases.

Does women's psychological issues affect severe pain in women undergoing medical abortion?

Anna Chiara Aru¹, Alessandro Arena¹, Arianna Raspollini¹, Eugenia Degli Esposti¹, Elisa Moro¹, Renato Seracchioli¹

¹Sant'Orsola Hospital - University of Bologna, Gynecology and Human Reproduction Physiopathology, Bologna, Italy

Background

Few studies in Literature have investigated the anamnestic and medical features that might be associated with increased pain levels during medical abortion. The primary aim of our study is to identify the anamnestic and clinical characteristics that may represent risk factors for intense pain levels during medical abortion, with particular focus on women's pre-treatment psychological distress and anxiety levels. Moreover, we evaluate the correlation between pain and gestational age.

Methods

This prospective, observational, non-pharmacological, multicentric study was conducted at the Department of Obstetrics and Gynecology of Azienda USL of Bologna, and at the Department of Gynecology and Human Reproduction Physiopathology of IRCCS S. Orsola – Malpighi Hospital. We included in the study all women who opted for medical treatment for abortion, between June 1st, 2021, and November 30th, 2021. In addition to anamnestic records and ultrasound data, women were asked to fill in the following questionnaires: GHQ-12, GAD-7, STAI-6, VAS. The potential risk factors were, therefore, selected for inclusion in the multivariate regression analysis.

Results

On 242 women enrolled, 38.0% experienced severe pain during medical abortion. A previous history of intense dysmenorrhea appeared the strongest risk factor for pain during medical abortion, when evaluating the size effect of each significant predictor (OR = 6.30, 95% CI 2.66 – 14.91), followed by a GHQ-12 score > 9 (OR = 3.33, 95% CI 1.43 – 7.76). On the contrary, our analysis confirmed that a previous vaginal delivery represented a protective feature against intense pain during medical abortion (OR 0.26, 95% CI 0.14 – 0.50).

Conclusions

Our data clearly show that nulliparity, dysmenorrhea, and increased baseline anxiety levels significantly increase the likelihood of severe pain in women undergoing medical abortion. Medical abortion is a safe and effective procedure, but it is often associated with pain symptoms. The identification of women at risk for experiencing severe pain is crucial to improve women's care and pain management during this procedure.

Comparison of efficacy and pain associated removal IUD using Endosee versus Betocchi hysteroscope.

*Estela Marquez Muñoz¹, Laura Blanch Fons², Jordi Cassado Garriga³, Ivana Jordà Santamaria³,
Teresa Gironès Valle³, Oriol Porta Roda³*

¹Gynecology and obstetrics resident, Gynecology and Obstetrics, Hospital universitari mutua de Terrassa, Spain

²Gynecology and obstetrics, Histeroscopies, Terrassa- Barcelona, Spain

³Gynecology and obstetrics, Histeroscopy, Terrassa- Barcelona, Spain

Background

Endosee is a hand-held device used to perform hysteroscopies. It is flexible, compact, portable, and just 4.3mm outside diameter, making it ideal for performing a hysteroscopy in a medical room. It includes an LCD screen that gives a clear image. It is capable of taking still photos and videos and is equipped with a channel for fluid infusion.

Objectives: To assess and compare the efficacy and pain associated with diagnostictherapeutic hysteroscopy using Endosee versus Betocchi hysteroscope in the removal of IUD in an ambulatory care setting.

Methods

This is a single centre, retrospective study from May 2020 to May 2022. Analysis of the office hysteroscopy database only retrieving data concerning IUD removals. A total of 66 hysteroscopies were performed for IUD removal: 33 using Endosee and 33 using the Betocchi hysteroscope. Criteria assessed were pain experienced by patients, age, parity and complete removal of IUD.

Results

Mean age was 37±8 years old (22-52) and 39±9 years old (18-54) in the Endosee and Betocchi groups, respectively. 69.7% of the patients in the Endosee group had had at least one vaginal delivery, while the percentage in the Betocchi group was 57.6%. Mean pain scores (VAS) were 3.73 (1-10) in the Endosee group and 5.07 (1-10) in the Betocchi group. Complete removal of the IUD was achieved in all but one patient in the Endosee group, who required an inpatient hysteroscopy for the complete removal.

Conclusions

In hysteroscopic removal of IUD, Endosee had lower pain scores and achieved almost the same success rate than the Betocchi group. Although the results were similar, Endosee is easily performed in any medical room with saline infusion; as a disadvantage, since the cannula is flexible, it is a bit difficult to manage the instruments during the procedure. Limitations of this study are the small number of patients included and the differences between groups.

Comparison of surgical outcomes following Laparoscopic Hysterectomy and vNOTES Hysterectomy

Ana Rosa Andrade¹, Hélder Ferreira¹, Luís Castro¹, Rosa Macedo¹

¹Centro Materno-Infantil do Norte, Departamento da Mulher e da Medicina Reprodutiva, Porto, Portugal

Background

Natural orifice transluminal endoscopic surgery (NOTES) is a minimally invasive technique using the natural body orifices like stomach, esophagus, bladder, rectum, and vagina to access the human body for surgery. In 2012, the first vaginal NOTES (vNOTES) hysterectomy was performed. Potential benefits of vNOTES hysterectomy include no visible scars, less pain, avoidance of trocar-related complications, and a shorter hospital stay compared with total laparoscopic hysterectomy (TLH). This study aimed to compare the surgical outcomes of TLH and vNOTES hysterectomy procedures.

Methods

A retrospective cross-sectional study was conducted in a tertiary care center in Portugal with 38 women who underwent TLH (32 patients) or vNOTES hysterectomy (6 patients) for benign gynecological indications. The variables duration of surgery, intra/postoperative complications, duration of hospital stay, and Visual Analogue Scale (VAS) scores in the pre-operative and postoperative periods were compared. SPSS® v.28 was used for statistical analysis.

Results

There were no significant differences between vNOTES and TLH groups regarding age (48,17 vs. 45,41; $p=0,362$), parity ($p=0,976$), preoperative VAS score ($p=0,825$), and uterine weight (126 vs. 135,5 g; $p=0,922$). The median body mass index was 27,9 kg/m² (25,3-31,6 kg/m²) in the vNOTES group and 26,18 kg/m² (17,3-36,06 kg/m²) in the TLH group ($p=0,562$). The D0 and D1 VAS scores were significantly lower in the vNOTES groups compared to the TLH group ($p=0,01$ and $p=0,029$, respectively). No statistically significant differences were found between the groups in terms of VAS maximal score or VAS score at the time of discharge were found ($p=0,095$ and $p=0,506$, respectively). There were no differences between vNOTES and TLH groups regarding duration of surgery (58,33 vs. 70,34 min; $p=0,438$), duration of hospital stays (3,17 vs. 3,72 days; $p=0,279$) and intraoperative or postoperative complications ($p=0,830$ and $p=0,571$, respectively).

Conclusions

Although vaginal hysterectomy is the recommended approach by the American Association of Gynecologic Laparoscopists (AAGL) and American College of Obstetricians and Gynecologists (ACOG) whenever indicated and feasible, the rate of vaginal hysterectomies in many countries, such as the U.S., has steadily declined due to lack of visibility and reduced access to the anatomy. The vNOTES technique overcomes these challenges by combining the benefits of laparoscopic and traditional vaginal surgery, enabling access into the peritoneal cavity through the vagina. In our study, vNOTES displayed more favourable outcomes compared to TLH in terms of pain scores, without an increase in complications or duration of hospital stay.

Visualising Surgical training in O&G following COVID-19 pandemic- The European prospect.

Radwa Hablase¹, Rebecca Mallick², Funlayo Odejinmi³

¹Royal Sussex County Hospital- University hospitals of Sussex NHS Foundation Trust, Obstetrics and gynaecology, Brighton, United Kingdom

²Princess Royal Hospital- University Hospitals of Sussex NHS foundation Trust, Obstetrics and gynaecology, Hayward Heath, United Kingdom

³Whipps Cross Hospital- Barts Health NHS Trust, Obstetrics and gynaecology, London, United Kingdom

Background

There is no doubt that COVID-19 pandemic had created significant disruptions to medical education and surgical training across the world. Indeed, Obstetrics and Gynaecology (O&G) training programmes, traditionally relied on hands-on apprenticeship training model, became crippled by the pandemic global response. Studies evaluating the impact on training during and shortly after the peak of the pandemic emphasized the disruption. Our pan Europe Survey evaluates training areas that remain affected from trainees' perspective following the acute phase of the pandemic. We Acknowledge the differences in the health care systems across the continent and discuss the novel initiatives taken across Europe to overcome training gaps and develop surgical training resilience.

Methods

In our cross-sectional study, a web-based anonymised voluntary open survey circulated to all trainee members of the European Society for Gynaecological Endoscopy (ESGE) over 8-weeks period from the 2nd of June 2021. Descriptive and thematic analysis of the data was undertaken. Outcomes included clinical practice, mental and physical well-being, impact on training and appraisal and acceptability of simulation training alternatives.

Results

A total of 213 trainees from 20 countries responded. Using the human development index (HDI) classification 206 respondents were from very high HDI countries, mainly UK and Germany. High and medium HDI countries had a smaller representation. In total 78% (166/213) were in approved training programme and 58% (122/213) had more than 6 years of formal O&G training. Overall access to personal PPE had improved from to 81% (174/213). 36% (76/213) took time off related to COVID-19. The uptake of the vaccine was 87% (185/213) among the members. 39% (89/213) and 55% (118/213) agreed to have had negative impact on their physical and mental wellbeing. 15% (32/213) were redeployed to cover areas outside O&G. 25% (53 /213) agreed that the COVID-19 pandemic negatively impacted their obstetrics experience. The negative impact on gynaecology training was more profound. Over all 54% (114/213) had lower gynaecology surgical exposure compared to the pre-pandemic time. 43% (91/213) have not met their gynaecology surgical competencies during the pandemic. 41% (87/213) had a negative impact on their annual appraisal / outcome. 15% (31/213) had their training extended due to COVID-19. Over half of the ESGE members perceived simulation training as a suitable alternative to gain/ maintain surgical skills.

Conclusions

Institutional and national attempts to restore training in a novel approach is evident across the continent. International societies had and are developing remote or hybrid modules to deliver training to a wider range of members. The momentum created will continue to revolutionise surgical training delivery. The future holds potentials for international collaborations to unify surgical training regardless of the geographical boundaries and mobilizing funds to support disadvantaged trainees in countries with medium or low HDI.

To determine the pre-test probability of malignancy for women bleeding on “New” HRT – Are we over or under-investigating?

Anna Geraghty¹, Felicity Watson¹, Chris Hardwick¹

¹Queen Elizabeth University Hospital, Gynaecology, Glasgow, United Kingdom

Background

Micronized progesterone is increasingly fashionable despite the British Menopause Society suggesting it may be more likely to cause unscheduled bleeding than other progestogens. Scottish Guidelines suggest unscheduled vaginal bleeding on HRT does not usually need investigation in the first 6 months. Large trial data supports the safety of this approach for traditional HRT but is lacking for Utrogestan used as endometrial protection.

Methods

Data was collected retrospectively from electronic notes for all patients attending with new perimenopausal bleeding (PMB) over 4 weeks in January 2022.

Age, HRT preparation and duration were collected along with endometrial thickness, pathology, and further investigations.

Results

66 women had PMB on HRT accounting for 20% of all new reviews and 33% of all PMB reviews.

1 woman was excluded as she had previous hysterectomy. For endometrial protection: 20% (13) of women used Utrogestan; 40% (26) another oral progestogen; 43% (15) transdermal progestogen; 16.9% (11) Mirena.

Ages ranged from 43 to 75; and average age 54. HRT duration ranged from 2 months to 120 months, average 23 months. 6 patients (10.8%) had been started on HRT within 3 months, half (3/6) of these women used Utrogestan. 24 women (36.9%) were referred within 6 months, a third (8/24) of which used Utrogestan.

All women had transvaginal ultrasound except one (not tolerated) who had hysteroscopy under general anaesthetic. For 8 women without mirenas, the endometrium could not be measured – all subsequently had normal endometrial biopsies.

The average endometrial thickness was 3.4mm; range 1 to 15mm. Women utilizing Utrogestan had the largest average endometrial thickness (4.48mm) compared with oral (either continuous or sequential) with an average of 3.08mm, and transdermal was 3.6mm.

All biopsies showed benign endometrial tissue. Benign polyps were found in 11.1%, and no malignancy found. Women on Utrogestan had the highest rates of pipelle biopsy (76%) and hysteroscopy (23%) despite no difference in the incidence of pathology.

HRT progesterone preparation	Average ET	Polyp (%)	Pipelle (%)	Outpatient hysteroscopy %	GA Hysteroscopy %
utrogestan/ micronized	4.48	7.6	76	23	23
transdermal	3.6	6.7	60	13.3	13.3
other oral	3.08	15.3	53	30.7	7.6

Conclusions

20% of women investigated for PMB on HRT were taking Uterogestan, showing its popularity.

Our small numbers suggest the risk of malignant disease is likely to be low, however, women using Utrogestan had thicker endometria causing high rates of invasive investigations under Scottish Guidelines for endometrial sampling.

Women on Utrogestan are over-represented in referrals made before 3 and 6 months after commencing HRT adding further pressure to already overstretched waiting lists and clinician anxiety.

Large studies are needed to establish the prevalence of bleeding with Utrogestan for endometrial protection, the pre-test probability of malignant disease and the risk of invasive investigation compared with alternatives.

The importance of education in minimally invasive gynaecological surgery

Rajko Fureš¹, Kopjar Miroslav², Fureš Dora³

¹Faculty of Dental Medicine and Health Osijek- Josip Juraj Strossmayer University of Osijek- Republic of Croatia, Faculty of Dental Medicine and Health Osijek- Josip Juraj Strossmayer University of Osijek- Republic of Croatia, Martinišće 45, Croatia

²Faculty of Dental Medicine and Health- Josip Juraj Strossmayer University of Osijek- Croatia- Crkvena 21- 31000 0 Osijek,

Faculty of Dental Medicine and Health- Josip Juraj Strossmayer University of Osijek- Croatia- Crkvena 21- 31000 0 Osijek, Osijek, Croatia

³Faculty of Medicine- University of Šoltanska 2- 21000- Split- Croatia, Faculty of Medicine- University of Šoltanska 2- 21000- Split- Croatia, Split, Croatia

Background

Comprehensive education of young doctors and continuous renewal of knowledge of those who practice minimally invasive gynaecological surgery is a prerequisite without which there is no high level of the profession, but also without which there is no continuous development and improvement of minimally invasive gynaecological surgery. On the mentioned foundations, in 2000, the Croatian Society for Gynecological Endoscopy of the Croatian Medical Association was founded. From the very beginning, the head of the society is prof. dr. sc. Miroslav Kopjar, a pioneer of minimally invasive gynaecological surgery in the Republic of Croatia and Southeast Europe.

Methods

Comprehensive education of young doctors and continuous renewal of knowledge of those who practice minimally invasive gynaecological surgery is a prerequisite without which there is no high level of the profession, but also without which there is no continuous development and improvement of minimally invasive gynaecological surgery. On the mentioned foundations, in 2000, the Croatian Society for Gynecological Endoscopy of the Croatian Medical Association was founded. From the very beginning, the head of the society is prof. dr. sc. Miroslav Kopjar, a pioneer of minimally invasive gynaecological surgery in the Republic of Croatia and Southeast Europe.

Results

Based on the above, we are proud to note that this year, 2022, from 12 to 17 September, the traditional 23rd International Postgraduate Course I category of Minimally Invasive Gynecological Surgery "Kurt Semm" will be held. The traditional 22nd symposium of minimally invasive gynaecological surgery is also being held. Through continuous and lifelong education in the field of minimally invasive gynaecological surgery, on the one hand we educate young doctors and doctors, and on the other hand we provide our patients with the highest quality treatment using minimally invasive gynaecological surgery.

Conclusions

We are pleased that almost three decades of progress in minimally invasive gynaecological surgery are a prerequisite for further progress and development of gynaecological endoscopy and that in this way we inherit the latest advances in science, in the interest of our patients.

Functional outcomes of laparoscopic versus robotic-assisted surgery for rectosigmoid endometriosis

Benedetta Orsini¹, Diego Raimondo¹, Anna Chiara Aru¹, Carlo Albon², Paolo Casadio¹, Renato Seracchioli¹

¹IRCCS - Azienda Ospedaliero-Universitaria di Bologna, Gynecology and Human Reproduction Physiopathology, Bologna, Italy

²Azienda Ospedaliero-Universitaria Policlinico di Modena, Dipartimento di Ostetricia e Ginecologia, Modena, Italy

Background

Improving the quality of life in patients with deep infiltrating endometriosis is one of the main goals of the surgery. While standard laparoscopy (S-LPS) used to be the standard approach for these patients, robotic-assisted laparoscopic surgery (RALS) has recently gained widespread interest. The present study compared in women with rectosigmoid endometriosis (RSE) any changes in quality of life and bowel, urinary and sexual functioning after surgery between S-LPS and RALS.

Methods

This is a multicentric, observational, prospective cohort study including symptomatic patients affected by RSE from September 2018 to September 2019. Before and after 12 months from surgery, patients were asked to fulfil four questionnaires assessing overall general health (the Short Form 36 Health Survey, SF-36), digestive function (the Knowles-Eccersley-Scott-Symptom Questionnaire- KESS, and the Gastrointestinal Quality of Life Index - GIQLI), and urinary symptoms (The Bristol Female Lower Urinary Tract Symptoms - BFLUTS). Our primary outcome was to compare the two groups in terms of SF-36 dimensions' scores at a 12-month follow-up. Secondary outcomes included the comparison of delta KESS, GIQLI and BLFUTS total scores before and after surgery between the two study groups.

Results

During the study period, 44 patients were included in the study population: 22 patients underwent S-LPS, and 22 RALS. Two patients in the RALS group were lost to follow-up and excluded from the analyses. The two groups were similar in terms of age, body mass index, parity, number of previous abdominal surgical procedures for endometriosis, endometriosis-related symptoms, and hormonal medical therapy within 3 months before surgery. In both groups, from 85% to 100% of patients improved their well-being and overall evaluation of health after surgery (p-value <0.001). Similarly, gastrointestinal, and urinary functions revealed statistically significant improvement at 12-month follow-up (p-value <0.001). However, no statistically significant difference was found between the two groups in terms of delta total scores of KESS, GIQLI, BLFUTS and for every domain of SF-36.

Conclusions

Surgery for RSE seems to improve quality of life and bowel, urinary and sexual functioning, regardless of the route. RALS can be considered as an alternative surgical route to S-LPS in deep endometriosis with bowel involvement

Surgical and reproductive outcomes in patients with complete septate uterus and cervical anomalies after metroplasty

Alfonso Manzi¹, Agnese Virgilio², Virginia Foreste¹, Matilde Fabbr², Paolo Casadio², Brunella Zizolfi¹

¹University of Naples "Federico II",

Department of Neuroscience- Reproductive Sciences and Dentistry- School of Medicine, Naples, Italy

²IRCCS Azienda Ospedaliero-Universitaria di Bologna,

Division of Gynaecology and Human Reproduction Physiopathology- Department of Medical and Surgical Sciences, Bologna, Italy

Background

To evaluate surgical and reproductive outcomes in patients with complete uterine septa with or without cervical anomalies undergone hysteroscopic metroplasty.

Methods

This is a multicentre prospective observational cohort study. Infertile women with ultrasonographic and hysteroscopic diagnosis of complete septate uterus with or without cervical anomalies (group A: U2bC1; group B: U2bC2; group C: U2bC0 according to ESHRE/ESGE classification system) enrolled from January 2018 to December 2021 underwent in-patient hysteroscopic metroplasty with 26Fr or 15Fr resectoscope or 5mm hysteroscope with 5Fr instruments; a second surgical step was performed when at postsurgical 3D ultrasonography a residual septum was detected ($Y + Z > 15$ mm). Surgical outcomes (operative times; intra- and post-operative complications; surgical satisfaction) and reproductive outcomes (clinical pregnancy rate [CPR], live birth rate [LBR], miscarriage rate [MR]) were evaluated.

Results

64 women with inclusion criteria were enrolled, 8 in group A, 26 in group B and 30 in group C. All surgical procedures were performed without any significant complication. Regardless of the surgical technique, 71% of patients in group B, 50% in group A and C required a second surgical step for the presence of a residual septum ($Y+Z > 15$ mm) on 3D ultrasound post-surgical evaluation, without significant difference between the groups. Operative times in the groups A and B were like each other (27,2 min \pm 3,5 SD vs 27,7 min \pm 8,5 SD) but were statistically lower in group C (12.4 min \pm 2 SD, p-value <0.01) independently from instruments and technique used; less surgical difficulty was reported by clinicians in group C. Reproductive outcomes were evaluated for 36 patients (mean follow-up 20 months) and did not show any significant differences between three groups. CPR was 47%, higher in group C (64%) compared with group A 50 and group B (31%) but statistics did not reach the significance (p =0.09). On the same way, statistically significance was not reached for LVR and MR. Notably, no abortion was observed in the group C.

Conclusions

Hysteroscopic metroplasty is an effective and safe procedure for the treatment of complete septate uterus with or without cervical abnormalities; a second surgical step is often required for the optimal treatment of these anomalies. Surgical outcomes are better in the group of patients without cervical anomalies, regardless of the instrumentation used. The presence of cervical anomalies doesn't seem to significantly affect reproductive outcomes.

A descriptive analysis of robot-assisted myomectomy versus abdominal myomectomy: a single centre retrospective study.

Malou Tahapary¹, Stefan Timmerman¹, Ashleigh Ledger², Kobe Dewilde¹, Wouter Froyman¹

¹UZ Leuven, Gynaecology-Obstetrics, Leuven, Belgium

²UZ Leuven, Development and Regeneration, Leuven, Belgium

Background

Uterine fibroids or myomas are the most common benign gynaecological tumours in women of reproductive age. Fibroids can significantly impact quality of life, as they may induce symptoms such as pain, menstrual abnormalities, fertility issues, and obstetric complications. Myomectomy, the surgical removal of the fibroid while preserving the uterus, will often be the preferred treatment in symptomatic patients who still desire to become pregnant. In the past decades, there has been a shift from open surgery to minimally invasive techniques. Robot-assisted surgery (RAS) is increasingly applied for benign gynaecological conditions, however not yet widespread in Europe. Compared to straight-stick laparoscopy, RAS adds advantages such as wristed instruments facilitating suturing, which can be essential in difficult myomectomies. In this retrospective analysis we aim to assess the patient and operative characteristics, and follow-up of patients who underwent robot-assisted myomectomy (RAM) or abdominal myomectomy (AM). Additionally, we will assess the learning curve for RAM and the effect of implementing RAM on the rates of open surgery.

Methods

We present a single centre retrospective analysis of consecutive patients who underwent myomectomy between January 1, 2018, and February 28, 2022 in a Belgian tertiary care hospital. All RAM were performed by the same surgeon, considering the year 2018 to be the RAS learning curve. Patient characteristics, fibroid characteristics, surgical information (operating time, estimated blood loss, weight of the resected tissue), and postoperative follow-up (hospitalisation length, complications up to 6 weeks postoperatively according to the Clavien-Dindo classification) were collected by review of the medical records. A descriptive statistical analysis was performed.

Results

In total, 94 RAMs and 15 AMs were performed. The rate of AMs in 2018 was 56.5% versus 2.3% after the learning curve. Within the last 1.5 year only RAMs were performed, without decrease in pre-operative fibroid size or the weight of resected tissue (with a maximum of 1320 g for AM and 1308 g for RAM). The median operation time for RAM was 136.5 minutes and 131 minutes for AM. Operation time for RAM shortened from a median of 176.5 minutes in 2018 to 136.5 minutes over the following years after the learning curve. Conversion rate for RAM was 0%. The median postoperative hospital stay after RAM and AM was 1 and 4 nights, respectively. Postoperative complication rate was low, with only 33.3% and 14.9% of patients requiring pharmacological treatment of complications after AM or RAM, respectively. Surgical re-intervention was not required.

Conclusions

Our study shows the effect of the implementation and learning curve of RAM in our centre. After the learning curve, RAM appears to replace almost all AM, with fewer adverse events and shorter hospital stay in our cohort.

Laparoscopic excision of deep rectovaginal endometriosis: a review of practice and lessons from a COVID-19 pandemic

Ayesha Mahmud¹, Waleed Riaz², Anwar Shah², Oluwafemi Oyewole², Samantha Marsh², Gourab Misra²

¹University Hospitals of North Midlands, Obstetrics & Gynaecology, Birmingham, United Kingdom

²University Hospitals of North Midlands, Obstetrics & Gynaecology, Stoke-on-trent, United Kingdom

Background

Deep infiltrating endometriosis is a significant health burden to women of reproductive age. Surgical excision is known to improve quality of life however surgery is associated with significant morbidity. Left untreated, endometriosis can result in with serious consequences for women such as chronic pelvic pain, infertility, and organ damage. In the United Kingdom (UK), women with advanced endometriosis are managed by endometriosis centres and the British Society of Gynaecological Endoscopy (BSGE) has published multicentre data on performance standards. We set out to benchmark our performance against BSGE standards, particularly considering the impact of the COVID-19 pandemic on our services. We share our endometriosis experience and the lessons learnt from the COVID-19 pandemic.

Methods

We reviewed data for women that underwent excision of deep rectovaginal endometriosis at the Royal Stoke University Hospital Endometriosis Centre, University Hospitals of North Midlands. These included cases performed before, during and after the COVID-19 pandemic i.e., a four-year period (between 2018-2021). The relevant cases were identified from the BSGE database and data was collected regarding demographics, comorbidities, imaging, the extent of endometriosis and procedures involved, surgeons performing laparoscopic excision of endometriosis, the surgical findings and interventions undertaken along with perioperative and postoperative complications.

Results

129 women underwent laparoscopic excision of deep rectovaginal endometriosis over a four-year period. Our demographics mainly consisted of women of reproductive age with most perimenopausal women undergoing a hysterectomy. Pararectal dissection and ureterolysis were performed in all patients. The majority of the procedures were completed laparoscopically, and 3 cases required conversion to laparotomy due to known surgical comorbidities. Our perioperative and postoperative complications were comparable with the BSGE standards apart from bladder and bowel dysfunction. The BSGE database does not routinely collect neuro-complications related to bladder or bowel dysfunction making it difficult to compare with a standard. From a COVID-19 perspective as with most centres, we noted delays in surgery with a consequent drop in the number of operative cases with deep disease per annum. This was followed by a rising trend in the number of cases per annum with much deeper disease and longer waits for surgery persisting. To monitor disease progression, we introduced yearly MRIs and patient reviews. We are currently exploring other measures to tackle the current backlog of endometriosis cases and looking at reducing operative times, hospital stay, and patient morbidity.

Conclusions

Our surgical outcomes are comparable with the BSGE standards. We have observed an increasing severity of deep endometriosis in cases waiting longer for surgical treatment. The role of GNRHa therapy and its duration in these cases remains uncertain. Lessons learnt from the COVID-19 pandemic are helping us shape the future of endometriosis services at our centre.

Pelvic thrombophlebitis as the probable cause of acute pain syndrome in a patient with endometriosis

Marta Melo^{1,2,3}, Henrique Abrão^{1,3,4}, Claire Figuier^{1,3}, Pauline Chauvet^{1,3}, Michel Canis^{1,3}

¹*Centre Hospitalier Universitaire Estaing de Clermont-Ferrand, Department of Gynaecological Surgery, Clermont-Ferrand, France*

²*Hospital Vila Franca de Xira, Department of Gynaecology and Obstetrics, Vila Franca de Xira, Portugal*

³*Centre International de Chirurgie Endoscopique, Centre International de Chirurgie Endoscopique, Clermont-Ferrand, France*

⁴*BP - A Beneficência Portuguesa de São Paulo, Department of Gynaecology, São Paulo, Brazil*

Background

Pelvic vein thrombosis usually occurs in association with puerperium, post-surgery or prothrombotic disorders. The occurrence of fever may point towards the suspicion of septic pelvic thrombophlebitis, especially if accompanied by flank or lower abdominal pain. However, in the absence of fever, this condition may remain undiagnosed in the evaluation and management of acute pelvic pain in a reproductive-aged woman.

Methods

We describe the case of a patient with disseminated lupus erythematosus (DLE) and endometriosis presenting with acute abdominal pain probably related to pelvic thrombophlebitis.

Results

We present the case of a 34-year-old woman, whose medical history included obesity, DLE and endometriosis under surveillance.

She complained of pain that affected the urinary and digestive systems and had bilateral ovarian endometriotic cysts, a nodule of the torus and involvement of the sigmoid. The hormonal treatment was suspended due to the comorbidities, and she was proposed for elective surgery.

However, she presented to the emergency room earlier, complaining of acute abdominal pain with no relief with common analgesics, with no fever.

Clinically, she had diffused abdominal pain, with no obvious signs of peritoneal irritation. The laboratory evaluation excluded pregnancy, urinary infection, and systemic inflammatory syndrome. The ultrasound detected a voluminous right ovarian cyst, painful with the passage of the probe and a right adnexal torsion was suspected.

An urgent diagnostic laparoscopy was performed, observing kissing ovaries with voluminous bilateral cysts, severe utero-ovarian adhesions, with no other anomalies. A partial adhesiolysis was performed. Torsion was excluded.

She was discharged on the third postoperative day with acceptable control of the pain. However, the cause of the acute painful syndrome remained unexplained.

An elective laparoscopy was performed twelve days after, to complete the treatment of endometriotic lesions. We found bilateral endometriomas with 7cm of dimension, adherent to the uterus, the broad ligaments bilaterally and the rectum. A complex adhesiolysis was performed to achieve complete excision of the lesions. During the dissection of the left posterior vagina, we opened a 15mm-diameter vein with a thrombus inside, which we removed. We proceeded to remove a recto-vaginal nodule. Finally, a bilateral ovarian cystectomy was performed.

The postoperative period was uneventful, and the patient was discharged on the third postoperative day.

Conclusions

This case demonstrates an unusual presentation of pelvic thrombophlebitis as acute abdominal pain without fever, underlining the importance of maintaining a high level of suspicion especially in the presence of risk factors, as DLE, by adding this condition to the differential diagnosis of acute abdominal pain.

Correlation between clinical examination and perineal ultrasound in women treated for Pelvic Organ Prolapse

Perrine Capmas¹, Celia Maheut¹, Herve Fernandez¹

¹Bicetre hospital, Gynecology and Obstetrics, Le Kremlin Bicetre, France

Background

Lifetime risk of surgery for female pelvic organ prolapse (POP) is estimated between 10 and 20%. Assessment of POP is mostly done by clinical examination. Perineal ultrasound is easily available and performed to evaluate and stage POP. This study evaluated the agreement between clinical examination by POP-Q and perineal sonography in women presenting POP.

Methods

We carried out a prospective study between December 2015 and March 2018 in the gynaecologic unit of a teaching hospital. Every woman requiring surgical treatment for POP could be included. All women underwent clinical examination, perineal ultrasound and answered several functional questionnaires before and after surgery. Data for clinical and sonographic assessment were compared and correlation with functional questionnaire was evaluated.

Results

We included 83 women with a mean age of 59.4 years, 94% of them previously delivered vaginally, 18% were obese and 19% had history of incontinence or prolapse surgery. Ultrasound data were available for 70% of women, mainly for the anterior compartment. Median of perineal area was 3455mm² [2875;4035] and operineal posterior angle was 71.5° [59;84]. We found no significant agreement between POP-Q and sonographic measurement of anterior prolapse, perineal hiatus area or perineal posterior angle. There was a significant improvement of most of the functional scores after surgery.

Conclusions

Our study didn't retrieve correlation between clinical POP-Q and sonographic assessment of anterior prolapse, hiatus area or perineal posterior angle. Ultrasound datasets were limited by an important number of missing values resulting in a lack of power in the evaluation of correlation.

Predictive factors for conversion to laparotomy in women undergoing benign laparoscopic hysterectomy.

Khayal Gasimli¹, Ludwig Lamersdorf¹, Thomas Kam¹, Annette Bachmann¹, Sven Becker¹, Morva Tahmasbi Rad¹
¹J. W. Goethe-University Frankfurt, Department of Gynecology and Obstetrics, Frankfurt, Germany

Background

Abdominal hysterectomy via laparotomy has been gradually replaced by minimal invasive laparoscopy offering several advantages, as shorter duration, less complications, better outcome, and reduced costs. Nevertheless, in some situations a planned laparoscopic intervention must be replaced by laparotomy for hysterectomy. Factors associated with conversion to laparotomy are still matter of debate. Therefore, aim of this research is to better define which clinical parameters promote conversion and to develop a preoperative scoring system

Methods

Cases with hysterectomy and benign diagnosis treated from 2016-2020 were studied. Primary outcome was conversion of a preplanned laparoscopic procedure to laparotomy. Potential predictor parameters studied: age, BMI, type of diagnosis, surgeon's experience, uterus weight, myoma size, previous surgeries, and coagulopathies. Significant variables were included in a logistic regression model. Differences resulting from the conversion, as duration of surgery, morcellment, infection, and prolonged hospital stay were also studied.

Results

In n=32 of 441 cases with hysterectomy and benign diagnosis (7.26 %) conversion to laparotomy occurred. We detected significant differences for uterus weight, myoma size, and type of diagnosis. Conversion caused prolonged surgery and hospital stay, and increased infections. In multivariate logistic regression uterus weight, adnexal findings, non-physiological adhesions, as well as myoma size predicted conversion. 10 g difference in uterus weight increased risk by 7.1%, and 1 cm difference in myoma diameter by 6.8%, while adnexal findings and non-physiological adhesions displayed odds ratios of 3.2 (1.09-9.6) and 3.6 (1.3-10.0), respectively.

Conclusions

Size of the uterus or myoma seems main risks for a conversion from laparoscopy to laparotomy. Prospective and multicentre studies are needed to evaluate these results and make final statement.

Women's preferences for less active ectopic pregnancy treatment: a discrete choice experiment.

Perrine Capmas¹, Henri Panjo¹, Nathalie Pelletier - Fleury¹

¹Inserm UMR1018, Centre De Recherche Sur La Santé des Populations, Villejuif, France

Background

Less active ectopic pregnancy can be managed using two treatment options: medical treatment using intramuscular injection of methotrexate and surgical treatment by salpingotomy or salpingectomy. It appears interesting to analyse women's trade-offs between benefits and harms of these treatments. To determine women's preferences for ectopic pregnancy treatment-related attributes, and to predict women's demand for both surgical and medical treatment.

Methods

Design

Discrete choice model with 8 attributes depicting ectopic pregnancy treatments including varying levels of first-line treatment effectiveness, length of hospitalization, cost, length of sick leave, length of convalescence, need for surgical management, need for emergency care during convalescence, need for tube removal.

Setting/Patients

A total of 178 women from the French general population with no history of ectopic pregnancy were included.

Main outcome measure

The weight of treatment-related attributes

Results

The attributes displaying the highest marginal impacts on women's decisions include: a higher rate of first-line treatment effectiveness, a lower rate of tube removal, a lower rate of surgical management, and, to a lesser extent, a shorter length of hospitalization, a shorter length of convalescence, an absence of risk of emergency care during convalescence and a lower cost. A shorter length of sick leave is the less influential attribute. Out of 178 women interviewed, the estimated demanding probability for medical and surgical treatment were 56.1% and 43.9%, respectively.

Conclusions

Faced with these balanced results, shared decision-making should be encouraged in the management of less active ectopic pregnancy. This study can help physicians to provide women with useful information and researchers with material for developing decision aids.

Evaluating the presence of endometriosis of other localization in symptomatic patients with adenomyosis uteri- a retrospective study

Ina Shehaj¹, Fadi Mohammad², Morva Tahmasbi Rad³, Sven Becker³, Khayal Gasimli³

¹*Jung - Stilling- Diakonie Hospital, Department of Gynecology and Gynecologic Oncology, Siegen, Germany*

²*Jung- Stilling Diakonie Hospital, Department of Gynecology and Gynecologic Oncology, Siegen, Germany*

³*University Hospital Frankfurt, Department of Gynecology and Gynecologic Oncology, Frankfurt am Main, Germany*

Background

Adenomyosis is a common benign gynaecological disease with the trend to persistent abnormal uterine bleeding and chronic pelvic pain. The cause of adenomyosis still isn't known and it appears sometimes with the endometriosis of another localization. There is a limited data in the literature as to whether both diseases, adenomyosis alone and adenomyosis in coexisting with endometriosis of another localization share the same clinical features and inflammatory pattern. This study aims primary to compare the clinical characteristics, histological results, and intraoperative findings in patients of both diseases.

Methods

This retrospective study includes 426 patients, who underwent laparoscopic hysterectomy from January 2020 till December 2021 in the Clinic of Gynaecology in Jung-Stilling Hospital in Siegen and in University Hospital in Frankfurt. The patients who had malignant tumours, older than 50 and incomplete medical reports were excluded from the study. The reviewed data included: age of the patients, BMI, symptoms presented, intraoperative findings and pathology reports.

Results

The median age of the patients at initial diagnosis was 46 years (range: 28-49). The main symptoms the patients presented were therapy resistant hypermenorrhea (32 %), dysmenorrhea (34 %) and chronic pelvic pain (12 %). BMI varied from 21 to 48 kg/m² (median 28 kg/m²). In 352 patients a total laparoscopic hysterectomy with salpingectomy was performed, in 39 (9 %) of them robot assisted (Da Vinci) surgery.

Laparoscopic-assisted supracervical hysterectomy was performed in 35 cases (8 %) Adenomyosis uteri alone could be pathologically confirmed in 109 Patients (26 %) and endometriosis in 18 patients (4 %). Adenomyosis coexisting with endometriosis was found in only 6 Patients (1,4%). 100% of these patients suffered on dysmenorrhea and 83% on hypermenorrhea.

While as in the group of patients who only had adenomyosis, 70% (p 0,0023) of them presented hypermenorrhea and dysmenorrhea. Chronic pelvic pain was present in 12 % (p 0,0023) of the cases with adenomyosis and in 16 % (p 0,516) of the patients with adenomyosis and endometriosis.

Conclusions

The results of our current study show that adenomyosis usually occurs separately from endometriosis of other localization. This fact suggests that both diseases could be different in their physiopathological mechanism such as the inflammatory reaction and the spread pattern. Further preclinical and clinical studies are needed to evaluate these findings.

The link between intrauterine adhesions and impaired reproductive performance, a review of the literature.

Angelo Hooker¹, Robert Leeuw de², Judith Huirne²

¹Zaans Medical Centre ZMC, Department of Obstetrics and Gynaecology, Zaandam, The Netherlands

²Amsterdam UMC, Amsterdam Reproduction & Development research institute-, Amsterdam, The Netherlands

Background

Intrauterine adhesions (IUAs) are an acquired condition characterized by intrauterine scarring leading to obliteration of the uterine cavity and/or cervical canal; one of the main reproductive system diseases in women worldwide. There is little understanding of the pathogenesis of IUAs, but IUAs are a result of intrauterine injury to the basal layer of the endometrium. The uterus during or shortly after pregnancy is extremely susceptible to trauma and is the most important predisposing factor.

The link between pregnancy related IUAs and reproductive performance is complex. The impact of IUAs, even after adhesiolysis is becoming more apparent: IUAs have an adverse effect on fertility, predisposing to pregnancy and obstetric complication in subsequent pregnancies. The mechanisms and (interconnected) processes leading to impaired reproductive performance and pregnancy and obstetric complications remain undetermined.

Methods

The aim of this review is to identify and summarize mechanisms and processes that may impact fertility in case of pregnancy related IUAs. A clear understanding of the mechanisms and processes may result in targeted management and treatment perspectives. We searched MEDLINE (Ovid) and EMBASE (Ovid) from inception to October 2021 to identify published articles, containing key words intrauterine adhesion, Asherman syndrome, reproductive outcome, fertility, pregnancy, and infertility. All prospective cohort, cross-sectional studies, case reports, case series and randomized controlled trial reporting on the possible links between pregnancy related IUAs and (impaired) fertility, pregnancy disorders and obstetric complications were considered for inclusion.

Results

The search conducted in October 2021 resulted in 795 articles in MEDLINE (Ovid) and 317 articles EMBASE (Ovid). After removing 16 duplicates, 1096 articles were screened on title and abstract and 911 articles were excluded. After screening 185 full texts articles, 121 were excluded. Finally, 64 articles were included in this review.

The postulated mechanisms in pregnancy related IUAs predisposing to fertility and pregnancy disorders and obstetric complications in subsequent pregnancies are related to sperm transport, embryo implantation and placentation. The processes are impaired or obstructed sperm transport, inefficient differentiation and maturation of the endometrium, impaired uterine contraction, abnormal implantation, defective vascularization, and angiogenesis. Moreover, abnormal decidualization and altered placentation may also lead to pregnancy and obstetric complications. Whether IUAs may affect quality of life, sexual functioning and physical and mental health could not be determined, but in theory may play a role but needs further research.

Conclusions

The impact of pregnancy related IUAs on reproductive performance, even after adhesiolysis is becoming more apparent. The presence of IUAs has detrimental effects on fertility and reproductive performance, resulting in impaired fertility and pregnancy and obstetric complication in subsequent pregnancies. Despite, prevention strategies remain scarce and are unsatisfactory. Evidence based strategies for management, primary and secondary prevention (reformation), are urgently required.

Operative hysteroscopy for intrauterine adhesions: Issues' comparison between single and multiple procedures.

Perrine Capmas¹, Cecile Bleas¹, Margaux Jegaden¹, Hervé Fernandez¹
¹Bicetre hospital, Gynecology and Obstetrics, Le Kremlin Bicetre, France

Background

Hysteroscopic surgical management of intrauterine adhesions seems to present insufficiently evaluated risks with increasing obstetrical complications such as hemorrhages, abnormal placentation, premature rupture of membranes and preterm birth. Published data on the risks and benefits of multiple procedures to treat intrauterine adhesions are limited. We therefore decided to compare outcomes of women after single procedure versus multiple procedures for management of intrauterine adhesions.

Methods

Design: Retrospective cohort in a teaching hospital.

Women/Setting: Inclusion of women of childbearing age treated by operative hysteroscopy for intrauterine adhesions between January 2010 and May 2020. One or more operative hysteroscopies were performed to remove intrauterine adhesions.

Mean outcome: Occurrence of intrauterine pregnancy and live birth rate after operative hysteroscopy.

Results

A total of 454 women were included: 256 in the group "single procedure" and 198 in the group "multiple procedures". Among those 454 women, XX[H1] (22.5%) were loss to follow-up. The intrauterine pregnancy rate was 44.1% and was significantly lower in the group "multiple procedures" (36.7% versus 50.0% (p=0.02)). The mean time before pregnancy was not significantly different between groups. For women who conceived, the live birth rate was 61%, not significantly different between groups. Repeated procedures seem to increase the risk of abnormal placentation (37.5% versus 13.8% (p<0.01)) and the risk of postpartum haemorrhage (45.4% versus 19.6% (p=0.01)).

Conclusions

This study is, to our knowledge, one of the largest studies comparing the management of intrauterine adhesions by single or multiple procedures. The risks of postpartum haemorrhages and placentation abnormalities are higher in the multiple procedures group. Repeating procedures increase chances of a satisfactory uterine cavity in severe intrauterine adhesions and therefore increase chances of pregnancy and live birth.

As already mentioned in published studies, pregnancies following management of intrauterine adhesion should be considered at risk

Patient experiences of Outpatient hysteroscopy (OPH): Lessons from a national benchmarking Outpatient hysteroscopy Patient satisfaction survey (OPH-PSS)

Ayesha Mahmud¹, Preth De Silva², Paul Smith², Justin Clark²

¹*University Hospitals of North Midlands, Obstetrics & Gynaecology, Birmingham, United Kingdom*

²*Birmingham Women's and Children's NHS Foundation Trust, Obstetrics & Gynaecology, Birmingham, United Kingdom*

Background

Patient perspectives have an important role in improving the quality of outpatient hysteroscopy (OPH) services. Understanding areas of improvement can help shape the processes involved in women's OPH journey. We share reflections from the experiences of women undergoing OPH and the lessons learned from the development work undertaken to develop a national benchmarking OPH survey (UK).

Methods

The recently published BSGE National benchmarking OPH patient satisfaction survey (OPH-PSS) was developed as a tool to capture women's satisfaction with aspects of the OPH journey. Over a two-month period, 5151 women took part in the national OPH survey. As part of the survey, women were asked to reflect on their experience and make suggestions for improvement as free-text comments. Reflections drawn from this work were analysed using qualitative thematic analysis and are shared for mutual learning.

Results

One thousand seven hundred and twenty (1720) women provided comments on their OPH experience. Qualitative thematic analysis of these comments generated themes that were divided into positive (82%) and negative (7%) experiences of care. Potential areas of improvement in relation to the OPH service were also highlighted (11%). Overall, most women regarded OPH as a safe, tolerable, and well-delivered outpatient service. Reflections on the development of the OPH-PSS and future aspects are also shared.

Conclusions

OPH remains a permanent fixture in ambulatory gynaecology. The qualitative data analysis supports the usefulness, safety, tolerability, and acceptance of hysteroscopy in an outpatient setting by most women. The reasons for poor tolerability and negative experiences warrant review and exploration of individual patient factors and relevant institutional factors (training, equipment, and local processes). Reflecting and sharing our experience of this benchmarking work provides a shared-learning opportunity to improve OPH services.

A 5-year report on QoL after surgical treatment of bowel endometriosis in a tertiary centre

Hajra Khattak¹, Zaeem Moti², Anam Jawaid², Lina Antoun¹, Yousri Afifi¹

¹Birmingham Women's and Children's NHS Foundation Trust, Endometriosis Centre, Birmingham, United Kingdom

²University of Birmingham, College of Medical and Dental Sciences, Birmingham, United Kingdom

Background

Endometriosis affects 10-15% of women of reproductive age. Deep infiltrating endometriosis (DIE) (infiltration of sub peritoneal structures containing endometrial tissue) accounts for 20% of endometrial cases. DIE includes bowel endometriosis, affecting 5%-12% of endometriosis patients. Bowel endometriosis can cause debilitating symptoms such as pelvic pain, bowel symptoms and subfertility.

Methods

Patient records between 12/2016-11/2021 were accessed via the BSGE-database for Birmingham Women's Hospital. Outcomes were assessed based on bowel symptom evaluation and a QoL scale, EQVAS (1-100; higher score indicating improvement). This scale looks at 5 domains: usual activities; mobility; pain/discomfort; self-care; and anxiety/depression.

Results

Of 94 women treated for bowel endometriosis over 5-years, 39 patients (41.5%) had follow-up data. In this sample, mean age was 36.1 years (± 6.50) and 10 patients (25.6%) were trying to conceive at the time of consultation. Of the 39 patients, 35 underwent bowel shaving (89.7%), 3 had recto-vaginal endo-excision (7.69%) and 1 untreated (2.56%). At 1-year follow-up, mean EQVAS score improved from 52.3 to 66.5 ($p < 0.01$). Specifically, patients reporting 'no problems' in the usual activities domain, and 'no pain' in the pain/discomfort domain, increased following surgical intervention. Other domains remained unchanged.

Conclusions

Surgical management improves QoL in women with bowel endometriosis, in particular pain and daily activity performance. This data will assist in counselling patients when deciding on treatment options for endometriosis. However, data over a longer period is required to develop a clinical practice guideline.

Malignant Struma ovarii in a 24-year-old nulliparous asymptomatic patient

Sofia Tsiapakidou¹, Eleutherios Klonos², Christos Zymerdikas³, Georgios Pantos³, Grigoris Grimbizis³

¹1st Department of Obstetrics and Gynaecology General Hospital Papageorgiou Aristotle University of Thessaloniki, 1st Department of Obstetrics and Gynaecology Aristotle University of Thessaloniki, Thessaloniki, Greece

²Aristotle University of Thessaloniki, 1st Department of Obstetrics and Gynaecology, Thessaloniki, Greece

³Aristotle University of Thessaloniki, 1st Department of Obstetrics and Gynaecology, Thessaloniki, Greece

Background

Objectives Adnexal pathology and specifically adnexal lesions the ovarian tumours usually appear as an incidental finding on the regular gynaecological check-up. Ovarian teratomas are germ cell tumours that derive from the three germ layers and commonly contain teeth, hair, bone, or thyroid tissue. They consist of 20% of all ovarian tumours. Ovarian teratomas which contain at least 50% thyroid tissue are known as struma ovarii. Struma ovarii tumours are generically benign, appear at the median age of 40 years, and can be both unilateral, and bilateral at the time of diagnosis. This is a case report of a malignant struma ovarii in a young asymptomatic patient

Methods

Case Presentation A 24-year-old nulliparous woman presented to our outpatient clinic with a history of an incidental finding of an adnexal tumour in 2020 in her annual gynaecological screening. She did not have any symptoms or bothersome. She had no significant medical or surgical history. The transvaginal ultrasound showed a cystic lesion on the left ovary with a maximal diameter of 6.5 cm and mild free fluid in the pouch of Douglas. No other abnormalities were found. She had performed a magnetic resonance imaging during her follow-up while waiting for the surgery, which was describing a moderate adnexal cyst (67 mm x 82 mm x 56 mm). Presence of multicellular cystic formation, which was occupying the left ovary, presumably as a dermoid cyst. She underwent laparoscopic right cystectomy. The excised ovarian mass showed evidence of struma-derived papillary thyroid carcinoma. Ultrasound of the thyroid showed mild enlargement with two solid nodules. A fine needle aspirate of a thyroid nodule was recommended but the patient decided to follow expectant management with frequent follow-up visits.

Results

The data shows a conversion rate of 14% and cyst rupture rate of 14%. 86% of cases had the specimen removed intact. There were no re-admissions with most patients discharged on the same day. 1 patient stayed overnight due to her other co-morbidities.

Conclusions

Struma ovarii is a rare ovarian tumour. Malignant struma ovarii is found in less than 5% of cases. In young patients, fertility-sparing should be considered, and unilateral is a generally accepted approach.

Clinical and Patient Reported Outcomes Pre- and Post-Surgical Treatment of Uterovaginal Septum: A retrospective bicentric cohort study.

Perrine Capmas¹, Mathilde Pelissié², Olivier Garbin², Hervé Fernandez¹

¹Bicetre hospital, Gynecology and Obstetrics, Le Kremlin Bicetre, France

²CMCO, Gynecology and Obstetrics, Schiltigheim, France

Background

Based on an insufficient power of the study about efficacy of metroplasty in complete uterine setum associated with vaginal septum, we decided to evaluate metroplasty's efficacy in larger cohort of women who underwent uterine metroplasty and resection of vaginal septum by carrying out a retrospective bicentric study. The objective of this study was to assess the fertility and obstetric outcome after surgical treatment of complete uterine and vaginal septum

Methods

Design A retrospective, bicentric, cohort study.

Setting Two surgical gynaecologic department in two different teaching hospitals, performing hysteroscopic metroplasties

Participants A total of 63 women who were diagnosed with a complete uterine and vaginal septum who have experienced infertility, pregnancy losses, or dysmenorrhea.

Interventions hysteroscopic metroplasty for uterovaginal septum (section of complete uterine septum and resection of vaginal septum)

Results

Obstetrical outcome before and after metroplasty were studied evaluated for their 31 patients women out of 63 because 15 were not lost to follow up and 17 didn't have with a short term short-term desire of pregnancy's desire.

In these 31 women, 25 (74%) had at least 1 pregnancy. They conceived a total of 28 pregnancies, in a median delay of 25 months (IC95% 18-32).

Twenty had a live birth, (1 pre-term birth); 12 delivered by vaginal route, 7 by C sections and 3 had breech presentations); 4 had miscarriages (2 of them had normal birth after and 2 had recurrent miscarriages).

The miscarriage rates before and after the uterine septum resection was 72.7 % and 18.2 %, respectively ($p < 0,004$). The live birth rate was significantly different before and after surgery (9% and 64%, respectively; $p < 0,05$).

Conclusions

The results from this study suggest that resection of vaginal septum and hysteroscopic metroplasty for complete uterine septum is a safe procedure that may improve reproductive and obstetrical outcomes

In clinical practice, section of complete uterine septum and resection of vaginal septum should be recommended.

Development and preliminary evaluation of educational videos about Novasure endometrial ablation for patients

Daniëlle Huijs¹, Peggy Geomini¹, Jaklien Leemans¹, Marlies Bongers¹

¹Máxima Medical Center, Obstetrics and Gynaecology, Veldhoven and Eindhoven, The Netherlands

Background

Heavy menstrual bleeding (HMB) can effectively be treated with Novasure endometrial ablation. Since previous research mainly focused on treatment effectivity, little is known about patient experiences and education. Education about surgical procedures is suggested to have a positive effect on preoperative anxiety. Therefore, we aim to develop a short series of educational videos for patients to watch before endometrial ablation. Moreover, we study whether educational videos which contain personal experiences from patients, have an effect on preoperative anxiety, the need to obtain information about the procedure and method of anaesthesia, and procedure-related satisfaction.

Methods

The NOVEX trial is a multi-centre randomized-controlled pilot-study. Patients from Máxima Medical Center Veldhoven and Eindhoven (the Netherlands) are currently included. Before the start of the trial, we interviewed 6 patients and discussed pre-, peri- and postoperative experiences. Six educational videos which contained footage from the interviews were composed. The following topics were covered: preoperative preparation, choice for method of anaesthesia, anxiety, course of the procedure, perioperative pain and postoperative symptoms at home. In a seventh video, the procedure is explained by a gynaecologist. Patients were randomized in an alternating order and 1:1 ratio in two groups. The intervention group had the opportunity to watch the educational videos preoperatively and the control group received regular education, which included a brochure and education by the gynaecologist. Just before the procedure, we evaluated anxiety and the need to obtain information by a Visual Analogue Scale for anxiety (VAS-A) and the Amsterdam Preoperative Anxiety and Information Scale (APAIS). An anxiety score of ≥ 11 corresponded with anxiety. Additionally, patient satisfaction was evaluated by a questionnaire filled out at least two days postoperatively.

Results

To date, 11 patients have been included, of which 9 patients have completed the study (intervention group n=5, control group n=4). Mean VAS-A was 29.60 ± 26.52 mm for intervention group patients and 30.75 ± 16.50 mm for control group patients. Mean intervention group APAIS anxiety score was 8.20 ± 4.21 , which is not classified as anxious. For the control group, mean APAIS anxiety score was 11.50 ± 2.38 , indicating that patients were anxious. Mean APAIS information need score was 5.00 ± 2.83 and 5.75 ± 2.36 for the intervention and control group, respectively. Both scores corresponded with an average need to obtain information. Finally, assessments of patient satisfaction indicate that patients found the videos helpful. The mean patient satisfaction was 8/10 in the intervention group and 6.5/10 in the control group.

Conclusions

The educational videos we developed were well received by this sample of patients. Further work is needed to evaluate its utility as an aid to reduce preoperative anxiety, enhance satisfaction, and facilitate knowledge acquisition in a larger group of patients undergoing endometrial ablation.

Abnormal uterine bleeding. Causes and hysteroscopic diagnosis: a single centre experience

María Henar González de Diego¹, María Teresa Buergo Ramírez¹, María Rodríguez-Marín Giménez¹, Juan José Delgado Espeja¹, Leticia Delgado Espárrago¹, Alviaro Zapico Goñi¹

¹Hospital Universitario Príncipe de Asturias, Gynecology, Madrid, Spain

Background

The aim of this study is to evaluate the endometrial pathology via hysteroscopy among patients with abnormal uterine bleeding.

Methods

A database was made including all women with abnormal uterine bleeding from January 2020 to December 2021 in our hospital that were referred to hysteroscopy. Different items such as age, hysteroscopy indication, hysteroscopic findings, and results of anatomical pathology were analysed.

Results

386 patients were included in a retrospective study; mean age was 51.91 (range: 25-86 years old). 176 patients (45.59%) were premenopausal, and 210 patients (54.4%) were postmenopausal. Abnormal uterine bleeding was the indication of the hysteroscopy in all the patients.

Hysteroscopic findings were endometrial polyps in 122 patients (31.6%), submucosal leiomyomas in 23 patients (5.9%), atrophic endometrium in 76 patients (19.7%) and endometrial hyperplasia in 19 patients (4.9%). Functional endometrium was described in 71 patients (18.4%) and high suspicion of endometrial carcinoma was reported in 4 patients (1%).

Histological findings were: 151 patients (39.1%) had an endometrial polyp, 2 patients (0.5%) had a biopsy of leiomyoma, 43 patients (11.1%) showed an atrophic endometrium, 13 patients (3.3%) had simple endometrial hyperplasia and 5 (1.2%) had complex hyperplasia. 78 patients (20.2%) had a result of functional endometrium and 6 (1.5%) had an endometrial carcinoma. 26 patients (6.7%) did not have a representative biopsy and in 62 patients (16%) biopsy showed non endometrial pathology.

Conclusions

In our study, the most common finding in patients with abnormal uterine bleeding was endometrial polyps and functional endometrium, not only by hysteroscopic view, but also by hysteroscopic biopsy. We can also demonstrate a good reliability between direct view and anatomopathological study, especially in case of malignancy.

Laparoscopic training from Portuguese residents' point of view – is there a difference between Central and Peripheral Hospitals?

Rita Sarabando¹, Natacha Sousa¹, Ana Catarina Borges¹, Cátia Correia¹, Cristina Nogueira-Silva²

¹Hospital de Braga, Gynaecology and Obstetrics Department, Braga, Portugal

²School of Medicine- Minho University- Life and Health and Science Research Institute- Hospital de Braga, Gynaecology and Obstetrics Department, Braga, Portugal

Background

The aim was to compare residents' perspective of training in laparoscopy between Gynaecology and Obstetrics residents from Central and Peripheral Hospitals of Portugal.

Methods

A cross-sectional study was designed, and an anonymous online questionnaire was distributed to Portuguese Gynaecology and Obstetrics residents from 2nd to 6th year. A comparative analysis between Central and Peripheral Hospital residents was performed with SPSS software (statistical significance $p < 0.05$).

Results

71 residents replied to the questionnaire: 37 (52.1%) from a Peripheral Hospital (PH) and 34 (47.8%) from a Central Hospital (CH). All country regions and targeted residency years were represented, without significant differences between groups (67.5% from the 4th-6th year). About 62.0% of residents have a period of residency dedicated to endoscopic surgery, with a statistically significant difference in duration (87.0% of PH residents have a 3-month period and 60.0% of CH residents have 4-6 months; $p=0.002$). From both groups almost all agreed that theoretical and practical training is important for laparoscopic skills (97.3%;100%) and had done theoretical and/or practical courses. Only 18.9% of PH residents and 20.5% of CH residents agreed that the training skills acquired during residency are sufficient for their clinical practice in the future. When comparing factors that may represent limitations to laparoscopy training, the two groups disagreed in two: excessive number of residents in their hospital (21.6% of PH residents vs. 44.1% of CH residents; $p=0.015$) and suboptimal practical experience in laparoscopy surgery in their department (74.3% of PH residents vs. 45.5% of CH residents; $p=0.015$); for all the other reasons pointed the majority of residents agreed in both groups (insufficient number of scheduled laparoscopic surgeries (PH 86.4%; CH 73.5%), limited access to simulation trainers (PH 70.2%; CH 67.6%) and excessive cost of endoscopy courses (PH 86.4%; CH 82.4%). About internships and certifications, no differences were found; 89.2% and 88.2% of residents from PH and CH have done/want to do an optional endoscopy internship and 83.8% and 97% have done/want to do a certification in gynaecology endoscopy. According to residents, the number of laparoscopic surgeries also varied between PH and CH with significance, being less than 50% of surgeries in 97.3% of PH and 76.5% of CH ($p=0.015$). Finally, there were no differences between the laparoscopic *curriculum* of both groups, and the majority had done between 1 and 40 surgeries as first surgeon (64.8% in both groups).

Conclusions

This analysis is part of a bigger study that aims to alert for the adaptation of the residency program to the challenges of laparoscopic surgery. Differences were found between PH and CH which may lead to some reflections of how should laparoscopic training in the residency be improved. Re-thinking the number of residents in CH and gaining more experience in PH can be part of the solutions.

Application laser shock-wave destruction of patients with squamous hyperplasia of the vulva & vestibule of the vagina

Madina Umakhanova¹, Victor Yezhov², Laura Bolotaeva², Madina Tsidaeva²

¹A.I. Yevdokimov Moscow State University of Medicine and Dentistry, Department of Obstetrics & Gynecology, Moscow, Russia

²A.I. Yevdokimov Moscow State University of Medicine and Dentistry, Obstetrics & Gynecology, Moscow, Russia

Background

The share of squamous cell hyperplasia (lichen) is up to 70% of the total number of dystrophies. Search of effective methods of treatment of dystrophic diseases of the vulva is one of the priorities of modern gynaecology.

Objective: To evaluate the effectiveness of the method of shock wave destruction in the treatment of dystrophic diseases of the vulva and vestibule of the vagina.

Methods

Patients. Interventions. Examination and treatment of women with confirmed diagnosis of squamous cell hyperplasia of the vulva & vestibule of the vagina.

110 patients with dystrophic diseases of the vulva were examined, age from 18 to 78 years. All patients underwent a full clinical examination. To verify the diagnosis a vulva biopsy with morphological analysis was performed. Method of laser shock wave destruction was used.

The treatment was carried out with a laser device "Lasermid 10-01" (Russia) using photoactivatable gel. Innovative characteristics of the method are based on the exceptional possibility of local layer-by-layer destruction of biological tissue with adaptive dosing limit and depth of destructive influence.

Results

We examined and clinically confirmed the diagnosis of squamous cell hyperplasia of vulva in 110 patients.

Clinical picture of patients with dystrophic diseases of the vulva: itching (persistent) 90%, dysuric disorders 75%, dyspareunia 95%, vulvodynia 80%.

This leads to a sharp deterioration in the quality of life of patients, most patients have 2 or more symptoms.

All patients were treated using laser shock-wave destruction of the vulva & vestibule of the vagina.

As a result of treatment, all 110 patients had complete disappearance of the main symptom - itching in the vulva region, dysuric disorders, dyspareunia, vulvodynia. Duration of observations was 1 year. The effectiveness of the method during this time was 91,2±0,04%.

In 68 (61.8%) patients there was also a stable remission of the disease within 24 months. No complications were recorded.

Conclusions

This paper presents some aspects of the effective treatment of patients with squamous cell hyperplasia of the vulva & vestibule of vagina by laser shock wave destruction.

Factors influencing intra-operative blood loss at total laparoscopic hysterectomy (TLH). A retrospective review of >500 cases over a 12-year period from a single UK centre.

Jonathan Ferguson¹, Susan Addley¹, Subul Bazmi¹, Lotte Weenink¹, Victoria Cullimore¹, Summi Abdul¹
¹DELTA Centre, Royal Derby Hospital, Derby, United Kingdom

Background

Total laparoscopic hysterectomy procedures have become much more common in recent decades. This is mainly due to their less invasive nature, shorter recovery times and lower post-operative complication rates. Their less invasive nature should in theory confer lower levels of intra-operative blood loss, or estimated blood loss (EBL). EBL is a widely accepted sufficient approximation of the actual blood loss level in surgical procedures. Hence, this analysis aims to identify peri-operative factors associated with risk of increased estimated blood loss (EBL) at total laparoscopic hysterectomy (TLH).

Methods

All TLH cases carried out by one surgeon in a large UK centre between 14/08/2008-03/10/2020 were identified. Electronic care and operation records were reviewed retrospectively, and data collected on: patient age, BMI, previous surgical history, endometrial thickness (ET), and uterine fundal AP-diameter; alongside operative factors (TLH indication, operation duration, anaesthetic, entry technique, power unit, operating time, post-operative length of stay (LOS) and post-operative complication. Univariate analysis was performed, setting significance at $P < 0.05$.

Results

$N=589$. Mean EBL was 169.3mls (Range 10-1500mls), exceeding 500mls in 1.4% ($N=8/589$). Mean EBL decreased significantly between 14/08/2008-03/10/2020 (283.3mls to 144.8mls), $P < 0.05$. Patient BMI ranges 25.0-29.9kg/m² (166.3mls), 30-39.9kg/m² (152.3mls) and ≥ 40 kg/m² (193.2mls) were associated with significantly greater EBL compared to 18.5-24.5kg/m² range (113.7mls), $P < 0.05$. Similarly, for uterine fundal AP-diameter (normal range 30-50mm, 154.2mls), EBL was significantly lower below normal range (< 30 mm, 98.2mls) and significantly higher above normal range (> 50 mm, 217.1mls), $P < 0.05$. ET exhibited a positive correlation with EBL ($R^2=0.9216$), $P < 0.05$. No significant correlation was identified between EBL and patient age or previous surgical history, TLH indication, equipment used, power unit, entry technique or post-operative complication ($P > 0.05$). EBL significantly increased when operation duration prolonged > 120 mins (148.6mls to 342.5mls, $P < 0.05$). EBL at TLH under general anaesthetic (GA) compared with under combined GA/Spinal anaesthetic was significantly higher – 219.3mls versus 144.4mls respectively, $P < 0.05$. Increasing EBL also conferred a longer length of post-operative stay (LOS) ($R^2=0.8592$, $P < 0.05$), with LOS significantly increasing when EBL surpassed 400ml (1.7 days versus 3.0 days).

Conclusions

The reduction in EBL over time likely reflects the learning curve associated with increasing surgeon experience. BMI, uterine AP-diameter, and ET as predictors of higher EBL can aid patient counselling/anticipate intra-operative events. The higher EBL associated with GA can be attributed to more recent change in anaesthetic practice to using GA in combination with spinal anaesthetic, alongside increasing operator expertise. The impact of operation duration > 120 minutes on EBL underlines the importance of operator efficiency. The EBL and LOS relationship highlights the importance of meticulous haemostasis throughout. Further multivariate analysis of the data is required to identify independently significant variables.

Twelve-year trends in retained products of conception management in a tertiary centre – our transition towards minimally invasive treatment

Gregor Prša¹, Branka Žegura Andrić², Tamara Serdinšek²

¹General Hospital Murska Sobota, Department of Gynecology and Obstetrics, Murska Sobota, Slovenia

²University Medical Centre Maribor,

Department of General Gynaecology and Urogynaecology- Clinic for Gynaecology and Perinatology, Maribor, Slovenia

Background

Retained products of conception (RPOC) occur in up to 3.3% of all deliveries and even more frequently after miscarriages and pregnancy terminations. Their management is still challenging due to lack of evidence-based guidelines. Our aim was to investigate trends in RPOC management in our tertiary centre.

Methods

In this retrospective study, we included women who were referred to our clinic because of RPOC. We included patients from year 2009 to 2021 in three-year intervals. The following data were obtained: age, form of RPOC (after delivery, medical termination of pregnancy (MTP), surgical termination of pregnancy (STP), spontaneous miscarriage, medical treatment of miscarriage, surgical treatment of miscarriage), RPOC management (hysteroscopic removal, dilatation, and curettage (D&C), medical treatment, expectant treatment), treatment complications, histopathological examination results, and need for blood transfusion. IRB approval was obtained.

Data were analysed using SPSS Statistics Programme. Descriptive statistics were calculated on basic patients' characteristics. Data between groups were compared using Pearson's Chi-square/Fisher's exact test. Statistical significance was set at $p < 0.05$

Results

Four hundred thirty-nine women were included. Their average age was 32 years (range 17–44 years). RPOC occurred after delivery in 23.5% of patients, after miscarriage in 5.3%, after MTP in 50.7%, after medical treatment of miscarriage in 13.7%, after STP in 4.8%, and after surgical treatment of miscarriage in 2%. Vaginal bleeding was present in 65.5%. Initial treatment was D&C in 40%, hysteroscopic removal in 36.4%, expectant management in 10.6%, and medical management in 13% of patients. However, as seen from Table 1, a statistically significant decrease in D&C with increase in other less invasive treatment options can be observed throughout the years ($p < 0.0001$). Only 10.7% of women needed another treatment modality due to failure of the first treatment option, the second treatment most often being D&C or hysteroscopic removal.

While 86.7% of women did not experience any complications, the complications that did occur were mild. Anaemia occurred in 4%, heavy bleeding in 2.6%, endometritis in 5.1%, and intrauterine adhesions in 0.9% of patients. Only 2.1% needed blood transfusion. Number of blood transfusions did not increase throughout the years with utilization of less invasive treatments ($p = 0.434$) and the same was observed for complication rate ($p = 0.658$). Histopathological examination report was available for 256 women. RPOC were confirmed in 86.7% and there was one case (0.4%) of partial molar pregnancy.

Table 1: Initial RPOC management.

Year	Initial management (%)			
	D&C	Hysteroscopic removal	Expectant management	Medical management
2009	54.3	33.3	4.9	7.4
2012	65.4	30.8	0.9	2.8
2015	30.6	37.8	17.3	14.3
2018	21.2	34.8	19.7	24.2
2021	20	45.9	12.9	21.2

Conclusions

Our experience shows that transition to less invasive treatment of RPOC (hysteroscopic removal, expectant, or medical management) is plausible and is not associated with increased number of complications or need for blood transfusion.

Outpatient Hysteroscopic Myomectomy; Our experience

Mihai Gherghe¹, Nicola Carmichael¹, Mohamed Allam¹

¹University Hospital Wishaw, Gynaecology, Glasgow, United Kingdom

Background

While there is good evidence to support hysteroscopic outpatient treatment for submucosal leiomyomas, it wasn't until the theatre restriction due to covid that pushed forward the development of outpatient operative hysteroscopic procedures in our unit.

The study wishes to assess the effectiveness of hysteroscopic myomectomy in the alleviation of symptoms of dysfunctional uterine bleeding in multi-operator led outpatient clinics.

Methods

Data was collected prospectively with retrospective analysis of short and medium-term outcomes of patients who underwent outpatient hysteroscopic myomectomy October 2019 to December 2021. The hysteroscopic tissue removal system used was Myosure®. The procedure was carried out by 9 different operators; outcomes were documented as either complete or incomplete resection of submucosal fibroid.

Results

Abnormal bleeding was the main reason patients were referred for hysteroscopic myomectomy. This includes peri-menopausal bleeding (30.5%) and heavy menstrual bleeding (58.3%). An analgesia protocol was followed, with most patients opting for instillagel analgesia alone (63.8%). In the 36 procedures completed for submucosal fibroids, 86% of patients had either confirmed cessation of bleeding or were not referred with recurrence of bleeding. Only 4 of the 36 procedures (11.9%) had ongoing bleeding post-procedure. The fibroids removed were Type 0 and 1 with only 3 of the 36 procedures documented as incomplete resection.

Conclusions

These findings suggest that the use of hysteroscopic tissue removal systems in an outpatient setting is a reproducible, safe, and appropriate treatment with minimal risk of complications. This has reduced dramatically the use of theatre time and the number of treatments to patients

The impact of hormonal therapy on uterine fibroids' growth: a prospective observational study.

Eugenia Degli Esposti¹, Enrico Pazzaglia¹, Federica Renzulli¹, Benedetta Orsini¹, Alessandro Arena¹, Renato Seracchioli¹

¹IRCCS Azienda Ospedaliero-Universitaria di Bologna, Gynecology and Human Reproduction Physiopathology, Bologna, Italy

Background

Medical therapy is a valid alternative to surgery in some women for the treatment of fibroids-related symptoms and oral contraceptives are widely used with this indication. However, despite providing an initial improvement of clinical symptoms, it is unclear whether their prolonged use represents a risk factor for fibroids' growth, given the crucial role of sex hormones in their pathogenesis. Our study aims to evaluate the long-term effects of hormonal oral contraceptives on fibroids' growth.

Methods

For this prospective, observational study, we enrolled all women referred to our outpatient clinic due to symptomatic leiomyomas between December 2017 and January 2020 and followed them up for 24 months until January 2022. Women were divided into two groups, based on their use of hormonal oral contraceptives at the time of our first evaluation: women in group A continuously took hormonal oral contraceptives during the 24-month follow-up period, and women in group B did not take any hormonal therapy. Patients were examined every 12 months after our initial evaluation. In addition to patients' medical and gynaecological history, data on symptoms and fibroids' characteristics were acquired. In particular, all patients were subjected to a gynaecological examination and a transvaginal and transabdominal ultrasound during each visit, recording the number, FIGO type, site, vascularization, diameters, and volume of all fibroids, which were then compared between the two groups.

Results

During the study period, we enrolled 569 patients and lost 91 of them during the follow-up period. Of the remaining 478, 34 were excluded because they started or discontinued hormonal oral therapy during the study period. The remaining 444 women completed the study, 222 for each group. The two groups did not differ in terms of clinical and anamnestic characteristics. After 2 years, leiomyomas had an overall median growth rate of 18.1% (IQR 2.8-82.1%). However, women who continuously took hormonal therapy showed a significant and constant reduction of fibroids' volume over the study period, as opposed to women in group B, who mostly showed a growth rate equal to or superior to 50%. The average growth rate was also significantly lower in group A compared to group B (10.1%, IQR 2.0-71.6% vs 25.5%, IQR 4.3-105.1%).

Conclusions

Oral hormonal contraceptives seem to exert a protective effect on fibroids' growth over 2 years. Additionally, we noted that women assuming hormonal contraceptives had smaller and less vascularized myomas compared to naïve patients. Understanding the natural history of uterine fibroids and their propensity to grow, especially in response to different hormonal regimens, may help in choosing the most appropriate medical treatment for this disease, not only to reduce symptoms but also to prevent their growth.

Outpatient hysteroscopy service; a nurse perspective

Mihai Gherghe¹, Mhairi Stewart¹, Louise Kellison¹

¹University Hospital Wishaw, Gynaecology, Glasgow, United Kingdom

Background

University Hospital Wishaw, General Outpatients department proposed to establish an outpatient hysteroscopy clinic for women with menstrual and post-menopausal disorders, offering one-stop endoscopic diagnosis and treatments.

To ensure safe and effective care, resources were sourced, including endoscopic systems with camera, screen, light source, and the associated clinical sundries. Staff training was required, as this was a significant difference to the usual outpatient role.

Methods

A robust learning experience was needed to reduce and counteract the anxiety and apprehension staff experienced. Training methodology was "Train the Trainers" which was delivered from theatre staff and the specialised equipment company using a competency framework.

The gynaecology team devised patient satisfaction questionnaire. This evolved continuously, based on patients' comments, ensuring ease of use and accurate capture of information including pain scores.

The nursing team supported this questionnaire and asked the patient to complete either using I-pad or QR code. Information leaflets were also devised and available for the women to peruse at home prior to their visit. A staff questionnaire on their thoughts, perceptions and satisfaction of the clinics was also devised and completed.

Results

Staff training was an on-the-job collaborative approach, sharing knowledge and learning. Ensuring continuity to support staff learning in the clinic was challenging, due to staff planned leave, sickness and Covid isolations. However, as the number of patients seen in these clinics was approximately 400 in the twelve months from January 2021-2022, staff gained confidence at each session moving from novice to proficient or expert. 47% feel their opinion is listened to and 97% responded that their contributions were appreciated.

60% of patients felt that the pain was less than expected and 96% were satisfied with their care.

Conclusions

Overall, the established outpatient hysteroscopic clinics provide safe and effective care with

positive patient and staff outcomes with enhanced working relationships. Moving forward, we will expand the service to offer "See & Treat" to provide a one-stop service for diagnostic and therapeutic treatments.

Transition of Minitouch Outpatient Endometrial Ablation to a Community Health Service

Yatin Thakur¹, Amaju Ikomi¹, Vidya Thakur², Reetam Singh¹, Nanak Bhagat¹

¹Basildon University Hospital, Department of Gynaecology, Basildon, United Kingdom

²Broomfield Hospital, Department of Gynaecology, Broomfield, United Kingdom

Background

The first objective is to assess the feasibility of endometrial ablation in a community health service. The second objective is to evaluate the additional clinical value of new customised features of the Minitouch Endometrial ablation system.

Methods

We have performed office setting Minitouch ablations for heavy menstrual bleeding in our district general hospital since 2015. The outpatient team comprised a gynaecologist, a nurse, and a health care assistant (HCA). As cervical dilatation is not required for this 3.8mm diameter device, the procedure tray needs only a disposable speculum, vulsellum (if required), Pipelle catheter, and a cleaning preparation. Our standard heavy menstrual bleeding evaluation includes endometrial biopsy and transvaginal ultrasound scan and/or hysteroscopy. Since 2017, energy delivery customisation features (e.g., temporary pause, power adjustment) have been used when needed to further optimise patient comfort and satisfaction. As previously, patients were also instructed to take pre-procedure analgesia at home (typically paracetamol/codeine, diclofenac, ibuprofen, paracetamol). Entonox (inhaled nitrous oxide) was kept available as a rescue analgesic.

A retrospective observational cohort study of the safety outcomes of the 84 latest cases carried out between 2018 and 2022, using the customisation features of the ablation system was performed. Available data from procedure notes and routine follow up notes were analysed. Both sets were reviewed for intra and post-operative adverse events (if any).

Results

The procedure and the follow-up notes were available for all (n=84) patients. The patients received the Minitouch procedure without endometrial pre-treatment or menstrual cycle timing. Mean sounding length was 8.6cm (n=51, range 8.0-14.0cm) and mean cavity length was 5.5cm (n=57, range 4.0-9.0cm). No patients received local or general anaesthesia or sedation. The target energy dosage was set at 4800J for the main(fundus) treatment and 1200J for each extension treatment (for cavities > 4.0cm). The mean energy dose delivered was 5569J (n=81, range 3000-7200J). No cases were abandoned for patient not tolerating the procedure or for any other reason. The VAS pain scores (range 0–10) reduced immediately after the energy delivery. The mean pain score immediately post-ablation was 2.0 (n=52, range 0-7) and at discharge, it was 0.8 (n=60, range 0-6). No patient required a recovery room stay and all were discharged within 15 minutes of the procedure. Mirena was inserted in three patients after the ablation for contraception. There were no intra-operative or post-operative adverse events reported. Outcomes available for a limited number of patients were consistent with previously reported high success rates at our sites.

Conclusions

Office setting Minitouch ablation, using minimal resources, has proved to be a safe and well tolerated procedure in the community health service. Customisation features have enhanced patient comfort without affecting clinical outcomes.

Trends in laparoscopic hysterectomy - a Swiss registry analysis of 24317 cases

Dimitrios Rafail Kalaitzopoulos¹, Nicolas Samartzis¹, George Kolovos², Markus Eberhard¹, Ioannis Dedes³

¹*Catol Hospital of Schaffhausen, Gynecology, Schaffhausen, Switzerland*

²*University Hospital of Bern, Gynecology and Obstetrics, Bern, Switzerland*

³*University Hospital of Zurich, Gynecology, Zurich, Switzerland*

Background

To describe the overall trends in laparoscopic hysterectomy of benign indications in Switzerland between 2005-2018.

Methods

A retrospective cohort analysis of "working group of Swiss women's hospitals" (ASF) registry data was conducted. We included all women undergoing laparoscopic hysterectomy for benign indications between 2005 and 2018. This registry gathers anonymized data about diagnosis, intervention, risk factors, morbidity and complications during the time of an index-hospitalization. It is a quality assurance instrument of the Swiss society of gynaecology and obstetrics with anonymized gynaecological patient data of about 40 teaching hospitals. We searched for significant trends over the analysed period to the share of laparoscopic hysterectomies (LH) and the following subtypes: total laparoscopic hysterectomies (TLH), laparoscopic supracervical hysterectomies (LASH) and laparoscopic assisted vaginal hysterectomies (LAVH) by using joinpoint®-regression analysis. Further we analysed trends in concurrent additional surgical procedures and complications. Intra- and postoperative complications were evaluated by the well-established ClassIntra and Clavien-Dindo classifications.

Results

24317 LHs were included. LH accounted for 19.9% of all hysterectomies performed in 2005 and showed a threefold increase to 63.4% in 2018. The logistic regression trend-analysis for LH calculated a significant increase over study period by +10.1 AAPC.

The majority of LH were TLH (83.7%), with a small proportion of LASH (10.1%) and LAVH (6,2%) overall. The rate of TLH remained unchanged, whereas LASH significantly increased from 5.6% in 2005 to 15.7% in 2018 (+10.62 AAPC) and LAVH decreased from 10.1% in 2005 to 2.9% in 2018 (-11.33 AAPC).

Concomitant salpingectomy significantly increased over the studied period from 10.5% to 64.8% (+13.9 AAPC) as well as resection of endometriosis from 1.5% in 2005 to 4.7% in 2018 (+ 8.0 AAPC).

The rate of intraoperative complications requiring additional surgical or medical intervention significantly decreased from 2.6% to 1.9% (ClassIntra Complications II-V; -2.10 AAPC) as well as mild to moderate postoperative complications from 3.7% to 1.2% (Clavien-Dindo I-II; -8.7 AAPC). Severe postoperative complications (Clavien-Dindo III-V) remained unchanged with 2.0% on average between 2005 and 2018. The rate of conversion to an open surgical procedure due to an intraoperative complication decreased significantly from 0.5% to 0.1% over the studied period (-6.5 AAPC), whereas it remained stable for conversion laparotomy in cases of anatomical considerations (0.7%)

Conclusions

This study provides evidence of an increased use of LH with higher complexity of selected cases and fewer complications and conversion rate most probably attributable to a learning-curve effect and broader acceptance within gynaecological surgical society of Switzerland.

Reproductive outcomes after hysteroscopic metroplasty of dysmorphic uterus

Nerea Montero Pastor¹, Irene López Carrasco¹, Elena Cabezas López¹, María Miró Matos¹, Jaime Sanz Pablos¹, Enrique Moratalla Bartolomé¹

¹HM Hospitales, Gynecology and Obstetrics.GINE4 SLP, Madrid, Spain

Background

Dysmorphic uterus is a Müllerian malformation that can cause infertility. Its prevalence is underestimated, and it is a potentially treatable entity by hysteroscopic metroplasty. Reproductive outcomes after the procedure are currently under investigation.

Methods

A retrospective observational study including 55 patients with dysmorphic uterus and history of primary infertility or repeated pregnancy loss (RPL) who underwent hysteroscopic metroplasty using the HOME-DU technique, was conducted between November 2017 and November 2021. All hysteroscopic metroplasties were performed by 4 gynaecologists from the GINE4 SLP Hysteroscopy Unit at HM Hospitales University Group.

The main objective of this study was to evaluate reproductive outcomes after performing hysteroscopic metroplasty in patients with dysmorphic uterus by clinical pregnancy rate.

Secondary objectives were to analyse the live birth rate, miscarriage rate, time to pregnancy and delivery/caesarean section rate. The preterm delivery rate, surgical complications rate and obstetric complications rate were also studied.

Results

Fifty-five patients were included, 29 with primary infertility and 26 with RPL. Overall mean age at time of hysteroscopic metroplasty was 39,48 years. 70,37% patients had a T-shaped uterus, the other 29,63% had subvariants such Y (18,52%) or I-shaped uterus (11,11%). The clinical pregnancy rate after hysteroscopic metroplasty was 52.72% (44.82% in infertile group and 61.53% in RPL group), but if we break down by years, in 2021 the pregnancy rate improved to 72.72%. The live birth rate was 65.52% (76.92% in infertile group and 56.25% in RPL group) and the miscarriage rate was 34.48% (15.38% in infertile group and 32% in RPL group). The caesarean section rate was 57.14%. No statistically significant differences were found between the primary infertility group and the repeated pregnancy loss group ($p < 0.05$). The mean time to pregnancy was 164.51 days (150.07 days in the primary infertility group and 177.92 in the RPL group). The complication rate during metroplasty was 1.81% (1 patient out of 55 suffered a uterine perforation).

Conclusions

Hysteroscopic metroplasty using the HOME-DU technique is a safe and effective minimally invasive treatment for dysmorphic uterus. This procedure improves reproductive outcomes in patients with dysmorphic uterus and primary infertility or repeated pregnancy loss, without being statistically significant differences between the two groups.

Prospective studies are needed.

Does hysteroscopy have a place in the study of infertility? – A retrospective cohort study in a secondary care hospital

Ana Catarina Borges¹, Paulina Costa², Beatriz Palmeira², Ana Isabel Rodrigues², Vera Costa², Filipa Rafael^{2,3}

¹Hospital de Braga, Obstetrics and Gynecology, Braga, Portugal

²Centro Hospitalar Médio Ave, Obstetrics and Gynecology, Vila Nova de Famalicão, Portugal

³Universidade do Porto, Faculdade de Medicina, Porto, Portugal

Background

Anomalies within the uterine cavity play an important role in fertility. Hysteroscopy is the gold standard procedure for uterine cavity exploration however, in infertility study, it is generally a second-line procedure. This study aims to report the incidence of abnormal hysteroscopic findings in infertile women that undergo elective hysteroscopy before in vitro fertilization (IVF).

Methods

An observational retrospective study was performed and included all infertile women, with surveillance in the Preconception and Fertility Support Consultation at Centro Hospitalar Médio Ave, that performed hysteroscopy from 2017 to 2021. Patients clinical file was consulted, and age, infertility diagnosis, symptoms, ultrasound results and hysteroscopy findings were included. A descriptive analysis was performed, as well as a sub analysis to assess the association of intrauterine abnormalities with woman's age, type of infertility and clinical suspicion of intracavitary pathology (abnormal bleeding, recurrent miscarriages, and ultrasound changes). A p-value <0.05 was considered statically significant.

Results

In the studied period, 104 ambulatory hysteroscopies were performed. The female age ranged from 19 to 44 years (mean 34.6 ± 0.5 years). Most couples had primary infertility (61.5%) and the median duration of infertility at the time of hysteroscopy was 24 months [IQR 13-90]. Causes of infertility were ovulatory factor 21.1% (n=22), tubal factor 13.5% (n=14), uterine factor 6.7% (n=7, 3 suspected uterine septum, 3 submucous myomas and 1 endometrial polyp) and endometriosis 6.7% (n=7). A male factor was present in 23/85 cases. Abnormal findings at hysteroscopy were found in 35.6% (n=37) of women: 11.5% (n=12) had endometrial polyps, 7.7%(n=8) intrauterine adhesions, 7.7%(n=8) uterine septum, 2.9%(n=3) submucous myoma, 2.9%(n=3) cervical stenosis and 2.9%(n=3) dysmorphic uterus. In only 14 women there was previous clinical suspicion of intracavitary pathology, and in 71.4% (n=10) of those the existence of pathology was confirmed. Of the 90 women without clinical suspicion, 30% (n=27) had intracavitary pathology. This difference was statistically significant, $p=0.005$. Women with clinically suspected intracavitary pathology were older (38.1 ± 4.9 years vs. 34.1 ± 4.8 years, $p=0.005$). There were no differences in hysteroscopic findings regarding female age, type and duration of infertility.

Conclusions

In this study, uterine intracavity pathology was found in 37 infertile women. The pathologies most frequently identified were endometrial polyps, intrauterine adhesions, and uterine septum. Intracavitary pathology was found in 30% of women who underwent hysteroscopy before IVF without clinical suspicion. These data remind us that hysteroscopy still has an important role in the study of uterine cavity in infertile women.

The state of the art in Gynaecology endoscopy training – perspectives from Gynaecology residents in Portugal

Natacha Sousa^{1,2}, Rita Sarabando³, Ana Catarina Borges², Cátia Correia⁴, Cristina Nogueira-Silva²

¹*Hospital de Braga, Serviço Ginecologia e Obstetrícia, Braga, Portugal*

²*Hospital de Braga, Serviço de Ginecologia e Obstetrícia, Braga, Portugal*

³*Hospital de Braga, Ginecologia e Obstetrícia, Braga, Portugal*

⁴*Hospital de Braga, Serviço de Ginecologia e Obstetrícia, Braga, Portugal*

Background

Objectives: To describe resident's perspective on endoscopy training during Gynaecology and Obstetrics residency in Portugal.

Methods

A cross-sectional study, with descriptive analysis of a national online anonymous survey regarding laparoscopy training, directed to 2nd to 6th year Gynaecology and Obstetrics residents in Portugal.

Results

From the 71(40%) residents that replied to the survey, 94,4% were women. From these, 47,8% are from a central training hospital and 52,1% from a peripheral hospital. All country regions and targeted residency years were represented. Almost all residents (98,5%) consider that theoretical and practical training, including simulation practice, greatly contributes to the endoscopy learning curve, but only 19,7% considers that the current residency training program in endoscopy is enough to match the required competencies for future clinical practice. Forty-four (61,9%) said that they have a specific laparoscopy internship during residency, the majority lasting 3 months. Most residents consider that the following factors represent limitations to laparoscopy training: excessive number of residents in their hospital (70,4%); insufficient number of scheduled laparoscopic surgeries (80,3%), suboptimal practical experience in laparoscopy surgery in their department (57,7%), limited access to simulation trainers (69,0%) and excessive cost of endoscopy courses (84,5%). The great majority of residents did or wishes to do an optional endoscopy internship (88,4%) as well as a laparoscopy certification (88,8%). Residents consider that easing the access to endotrainers (95,6%), to establish a mandatory endoscopy internship in residency program (70,4%) and to promote feedback sessions with their mentors (69,1%) could optimize their training in endoscopy. Around one third of the residents replied that they have a simulation training centre in their hospital, half of them with free access to endotrainers, 30,4% only in the setting of organized courses, and 8,6% said they have free access under specialist supervision. The majority of inquired residents (76,4%) would like to include laparoscopy in their clinical practice when they finish their residency.

Conclusions

The practice of endoscopic gynaecological surgery has grown exponentially in recent decades, significantly contributing to the reduction of patient's morbidity and mortality. In response to this evolving reality and considering the learning curve that laparoscopic surgery imposes, it becomes increasingly urgent to update the internship programs, to ensure that trainees are technically capable when they finish residency. This work aims to enhance residents' perspective in laparoscopy training in order to optimize the quality of training programs and, consequently, the health care provided.

Arteriovenous malformation of the uterus as a potentially life-threatening cause of bleeding

Maria Oliveira¹, Marisa Moreira¹, Helena Nascimento¹, Clara Moreira¹, Paulo Donato², Mário Oliveira¹

¹Centro Hospitalar Baixo Vouga, Serviço de Ginecologia e Obstetrícia, Aveiro, Portugal

²Centro Hospitalar Universitário de Coimbra, Serviço de Radiologia, Coimbra, Portugal

Background

Arteriovenous malformation of the uterus (AVMU) is an uncommon cause of abnormal uterine bleeding. Its incidence is unknown. Most of them are acquired after uterine surgery, such as dilation and curettage, mainly in the setting of induced or spontaneous abortion, or in association with neoplastic disorders or with maternal exposure to diethylstilbestrol. Bleeding presumably occurs when the vessels erode through the endometrium, resulting in a variable amount of bleeding.

Methods

In the following report, we describe a patient with uterine arteriovenous malformation.

Results

A 22-year-old girl presented to the emergency department with severe and active uterine haemorrhage, two months after a medically induced second-trimester pregnancy termination. No previous relevant history is known. On the ultrasound (US), a heterogeneous, hyper vascularized, intrauterine formation suggestive of trophoblastic retention/AVMU was seen on the uterine fundus, measuring 19x23x25mm. The endometrial-myometrial transition was difficult to identify. The analytic study revealed a haemoglobin of 9,2mg/dl. She was admitted for bleeding control and etiological study. A hysteroscopy was performed to exclude trophoblastic retention. During the exam, a giant pulsatile mass embracing all the posterior uterine wall was found. For better categorization of the anomaly, a computed tomography angiography was performed confirming the suspected diagnosis of an AVMU involving, mainly, the left uterine artery. The patient was transferred to a differentiated hospital with interventional radiology for embolization of the afferent branch of the left uterine artery to be performed. The procedure was uneventful, with no recurrence of the haemorrhage. One month after the procedure there was no bleeding recidivation and the US showed a linear and homogeneous endometrium with no abnormal vascularization found.

Conclusions

AVMU should always be considered in the differential diagnosis when a woman presents with abnormal uterine bleeding, particularly after intrauterine instrumentation. Imaging is crucial when it is suspected and should always be performed before further invasive interventions, since some procedures can be life-threatening. Ultrasound with Doppler is typically the first-line imaging study but can be complemented with angiography for better clarification.

Office Hysteroscopy – when to interrupt and reschedule?

Mafalda Laranjo¹, Ana Mesquita Varejão¹, Mariana Dória¹, Gisela Fornelos¹, Pedro Tiago Silva¹

¹Hospital Pedro Hispano, Gynaecology, Matosinhos, Portugal

Background

The increasing clinical training, smaller diameter hysteroscopes, and the growing demand for outpatient-based procedures have opened the way for the rising number of office hysteroscopies. In our department, since 2000, vaginoscopic approach and “see-and-treat” methodology have been systematically applied in what concerns to office hysteroscopies. These procedures provide a quicker, simpler, minimally invasive approach to common intracavitary pathology. In our hospital, both major and minor hysteroscopies are outpatient procedures performed in the operation room. Minor hysteroscopies are procedures performed without presence of anaesthesiologist – office hysteroscopy. In 2014, a retrospective study conducted in our hospital (including a 14-year period) concluded that only 9.3% of office hysteroscopies require further reschedule of a major procedure. According to literature, the most common reasons for failure to complete an office hysteroscopy are pain, cervical stenosis, and poor visualization. In this study, we reach to see if our failure rate remains low and which were the main causes of office hysteroscopy interruption and rescheduling as a major procedure (with sedation).

Methods

A retrospective, descriptive study was performed. The sample included patients who underwent hysteroscopy at Hospital Pedro Hispano between 2020 and 2021. We selected patients who had to interrupt an office hysteroscopy requiring rescheduling of a major hysteroscopy.

Results

During the study period, 322 office and 365 major hysteroscopies were performed.

Twenty-nine office hysteroscopies (9%) were interrupted, requiring hysteroscopy with sedation at another surgical time. With a mean age of 53 years, 52% of these women had a history of previous vaginal delivery. Seventeen of these 29 procedures were postponed due to poor tolerance to the procedure and in 12 of these 17, internal cervical stenosis was reported. The 12 remaining procedures were postponed due to endometrial polyps (bigger than 20 mm in size) or myomas, anticipating a long procedure or the need for a resectoscope approach, which would not be tolerated without sedation.

Conclusions

In our sample, the frequency of interrupted office hysteroscopies was similar to a previous study in the same centre. The most common reasons for office hysteroscopy interruption were the patient's low tolerance, either due to cervical stenosis or large volume intracavitary formations that would predictably require longer procedures. It is important to have adequate selection criteria for minor hysteroscopy to reduce the frequency of procedures that need to be rescheduled.

Laparoscopic sacrocolpopexy and long-term quality of life: a multicentric retrospective study of 22 years in two iberian tertiary centers

*Joana Oliveira*¹, *Fakhreldin Marwa*², *Sara Campos*¹, *Kristina Agababyan*³, *Fernanda Águas*¹, *Juan Gilabert-Estellés*^{3,4}

¹*Centro Hospitalar e Universitário de Coimbra, Gynaecology Department, Coimbra, Portugal*

²*Corniche hospital, Obstetrics and Gynecology Department, Abu Dhabi, United Arab Emirates*

³*University Hospital General of Valencia, Obstetrics and Gynecology Department, Valencia, Spain*

⁴*European Gynecology Endoscopy School E.G.E.S., European Gynecology Endoscopy School E.G.E.S., Valencia, Spain*

Background

To assess the long-term quality of life (QoL) before and after laparoscopic sacrocolpopexy (LSC), including the outcomes in relation to the degree of pelvic organ prolapse (POP), and identify possible recurrence risk factors for POP.

Methods

A multicentric retrospective study was performed at University Hospital General (Valencia, Spain) and University Hospital Centre (Coimbra, Portugal) including 169 patients with symptomatic stage \geq II POP (\geq 1 compartment), submitted to LSC (1999-2021). Demographic, clinical, and perioperative details were collected through medical records. Outcomes were measured by comparing preoperative and postoperative anatomical findings and two QoL questionnaires were applied: The Pelvic Floor Distress Inventory short form (PFDI-20) and the Pelvic Floor Impact Questionnaire short form (PFIQ-7). Additionally, each centre's first 30 surgeries were selected to evaluate the correlation between the surgeon's experience and the risk of recurrence.

Results

The mean age was 57.38 \pm 11.09 years, the median body mass index was 26.0 [6.30 IQR] kg/m². Previous pelvic surgeries were found in 113 patients, including 36 cases of total abdominal hysterectomy (TAH) and 50 vaginal hysterectomies. Another 83 patients underwent supracervical hysterectomy during the LSC procedure.

Patients with previous TAH remained longer without POP symptoms warranting surgical intervention, with a mean of 18.03 [9.78 IQR] versus 4.0 [7.0 IQR] years of the patients with previous vaginal hysterectomy.

The mean surgery duration was 192,1 \pm 61,62 minutes; 26 patients had concomitant procedures for pelvic floor repair, and 28 for stress urinary incontinence (SUI). The median duration of hospital stay was 2.0 [1 IQR] days.

The intraoperative and postoperative complications rate was 4.7%(n=8) and 25.4%(n=42), respectively – the last ones were mainly constipation 28.6%(n=12) and SIU 28.6%(n=12).

The total POP recurrence rate was 11.2%(n=19), with a median time surgery-to-recurrence of 3.04 [3IQR] months. There were no cases of recurrence with rectocele or enterocele, 4 cases had apical recurrence, 6 anterior compartment, and 2 cases both. Five patients needed another POP surgery following the relapse. The rate of recurrence in the first 30 surgeries at each centre was 15% versus 9.6% in the latter ones($p=0.27$). There was no statistically significant correlation between demographic variables and POP recurrence.

The follow-up was performed using QoL questionnaires-69.8% replied: 91.9% were satisfied/very satisfied and 6.25% were not satisfied. The results demonstrated a significant improvement in all subscales with a statistically significant difference, except for the Colorectal–Anal Impact Questionnaire (CRAIQ) subscale($p=0.096$).

Conclusions

LSC is the gold standard surgical technique for POP, confirmed by long follow-up and a high- level patients' satisfaction.

Each centre improves the technique along with the increasing experience, which is proven by the higher recurrence rate in our sample's first surgeries.

Only in CRAIQ subscale there was no significant improvement, which may be due to a superior hypogastric plex lesion during the dissection or an insufficient preoperative evaluation of defecatory dysfunction.

Diagnosis of irritable bowel syndrome in the Portuguese population with endometriosis

Ana Dagge¹, Cristiana Soares², Catarina Reis-de-Carvalho¹, Castro Catarina¹, Ana Luísa Ribeiro¹, Filipa Osório³

¹*Centro Hospitalar Universitário Lisboa Norte, Obstetrics- Gynecology and Reproductive Medicine, Lisbon, Portugal*

²*Centro Hospitalar Universitário Lisboa Norte, Ginecologia- Obstetrícia e Medicina da Reprodução, Lisbon, Portugal*

³*Hospital da Luz, Gynecology, Lisbon, Portugal*

Background

To evaluate the presence of gastrointestinal symptoms suggestive of Inflammatory Bowel Disease (IBD) in women with endometriosis.

Methods

A self-reporting questionnaire for women with endometriosis consisting of eleven questions related to gastrointestinal symptoms was shared online through social media and at the endometriosis. The questionnaire included validated questions for Portuguese from the ROME IV questionnaire, used in the diagnosis of IBD.

Results

We gathered 1158 responses. The median age was 37.5 +- 6.7 years. On a scale of 0 to 5, almost 50% of women reported the maximum impact of endometriosis on their quality of life. Almost a third of the women (29.6%) had a diagnosis of IBD performed by a clinician. The most reported symptoms were abdominal pain (78,6%), abdominal distension (70.1%), flatulence (70.4%) and tenesmus (64.1%). More than 60% of the women reported a high impact of gastrointestinal symptoms on their quality of life (4 or 5 on a scale of 0 to 5). More than 80% reported having had abdominal pain at least once a week for the past three months, mostly associated or aggravated during the menstrual period. In 57.6% the beginning of the pain was associated with a change in the frequency or form of the stool and in 70% the pain improved with defecation. A quarter (25.8%) of the women fulfilled the Rome IV criteria for IBD.

Conclusions

The link between endometriosis and IBD has been investigated over the last years. Previous studies reported a 50% increase in the risk of IBD in women with endometriosis in comparison with the general population. This study reports a high incidence of gastrointestinal symptoms in this population, with almost a third of the women with a confirmed diagnosis of IBD. This study highlights the overlapping of symptoms of both these conditions. Clinicians must remain aware as the co-existence of both diseases has a very important impact on the therapeutic approach.

Deep Infiltrating Endometriosis of Diafragma. A systematic review

Mónica Gomes Ferreira¹, Rui Viana¹

¹hospital Cuf Descobertas, Gynecology and Obstetrics, Lisboa, Portugal

Background

Endometriosis most commonly affects the pelvis. The thorax is a frequent extra-pelvic involvement of endometriosis, the diaphragm being the most common site. The first case of diaphragmatic endometriosis was described in 1954 by Brews. Since then, a limited number of series of diaphragmatic endometriosis have been reported.

Methods

We carried out a systematic review on diaphragmatic endometriosis from 1985 to January 2022 in the main search systems for scientific articles (PubMed, Medscape).

Results

The majority of patients with diaphragmatic endometriosis are asymptomatic. For that reason, all patients with pelvic endometriosis need to have direct exploration of the diaphragms at laparoscopy, in particular along the coronary ligament of the liver.

Symptomatic patients usually experience catamenial chest, upper quadrant, shoulder pain, or a combination of them. There may be a delay of as long as 10 years since the start of the symptoms. Other clinical manifestations are pneumothorax, hemothorax, diffuse thoracic pain, scapular or cervical pain, the latter (due to phrenic irradiation).

In many cases, the diagnosis is discovered incidentally during the thoracoscopic evaluation of patients with catamenial pneumothorax or hemothorax or during laparoscopy for pelvic endometriosis.

There are no specific guidelines for the treatment of diaphragmatic endometriosis other than surgical excision and suppression of menses, as for endometriosis in any other location.

When the patient present catamenial pneumothorax the indicated treatment is primarily treated with chest tube drainage of pneumothorax followed by secondary prevention of recurrence with blebectomy and pleurodesis and hormonal suppression during 6 to 12 months.

When the patient present catamenial hemothorax due to thoracic endometriosis is primarily treated by definitively managing the presenting feature with chest tube drainage followed by secondary prevention of recurrence with thoracoscopy and hormonal suppression 6 to 12 months.

The presence of lesions should be extirped by minimally invasive surgery.

Conclusions

The DIE is rare but disabling and potentially serious for the health of our patients, so we must be aware of the symptoms to avoid delay in diagnosis.

During the follow-up, patient should be followed by a multidisciplinary team with gynaecologists, pneumologists, thoracic surgeons.

Modern concepts in advanced endometriosis surgery

Caius Simedrea¹

¹Athena Hospital, Gynecology, Timisoara, Romania

Background

EndoInstitute Timisoara is a tertiary endometriosis centre accredited by EEL. We have operated last year 263 advanced endometriosis surgeries.

we have the continuous challenge to improve our surgery by optimising the results (higher QOL, better cumulative pregnancy rates), lowering the complication rates and reducing the trauma that surgery has on patient.

Methods

We have developed a retrospective study on our 263 patients cohort ,and we assessed the impact that modern concepts have on patients perioperative evolution .

As modern concepts we have applied :ERAS -enhanced recovery after surgery ;LIL-low impact laparoscopy; and less traumatic devices as harmonic scalpels ,Ar-plasma cautery.

We compared perioperative evolution in patients where these measures were applied (181) vs patients operated in classic laparoscopy and postoperative management methods.(82)

we assessed the QOL ,the ambulation ,restoration of bowel function ,pain scores ,risk of fall scores ,hospitalisation period.

Results

We observed a better postoperative evolution in all the parameters measured in the group of patients where modern measures were applied.

Conclusions

Endometriosis advanced surgery is a challenging multidisciplinary effort, but it can be delivered in style.

Comparison of Operative Results Between Standard And Robotic Laparoscopic Surgery For Endometrial Cancer: Case Reports

Mónica Gomes Ferreira¹, Tatiana Costas²

¹Hospital Cuf Descobertas, Gynecology and Obstetrics, Lisboa, Portugal

²Hospital Clínico Universitario de Salamanca, Gynecology and Obstetrics, Salamanca, Spain

Background

Randomized controlled trials support the use of laparoscopic techniques over laparotomy for endometrial cancer. Standard laparoscopy for endometrial cancer is possible but may be difficult to perform due to comorbidities such as patient obesity. Robotic surgery has been proposed to be easier to learn than laparoscopy, and several studies have shown better ergonomics and in vitro results.

Methods

We conducted a retrospective descriptive study between May 2018 and February 2019 comparing the operative results of laparoscopic and robotic surgery in our randomly selected patients with early-stage endometrial cancer. The patients presented a homogeneous distribution in terms of epidemiological characteristics, thus constituting comparable groups. A questionnaire assessing the quality of life of each patient (SF-36) was delivered 1 month prior to surgery and in the immediate postoperative period and one month later. We use the Clavier-Dildo system to describe complications. For each analysis, the recommended statistical test was used, and statistical significance was considered $p < 0.05$.

Results

Blood loss in laparoscopy was lower than in robotic surgery (1.3 vs 2.0 mL), $p < 0.05$. In general, robotic surgery improved 4 points on the SF-36 ($p < 0.05$) while robotic surgery worsened 13 points postoperatively. Immediate postoperative pain was lower in cases of robotic surgery ($p < 0.05$). In robotic surgery there were 2 post-surgical complications and in laparoscopy 1.

Conclusions

Robotic surgery is safer and more reliable than laparoscopy in patients with endometrial cancer. Robotic surgery is associated with higher blood loss than laparoscopy, possibly associated with a learning curve; fewer conversions, but more complications than laparoscopy; and less pain and better quality of life in the postoperative period. Additional studies are required.

Impact of anemia on treatment management and clinical outcomes of women hospitalized for uterine leiomyomas: A national database analysis.

Dora Antunes^{1,2}, Inês Gante^{1,3}, Maria João Carvalho^{1,3,4,5,6}, Cláudia Medeiros-Borges⁷, Fernanda Águas¹

¹Coimbra Hospital and University Centre, Gynecology, Coimbra, Portugal

²Faculty of Medicine, University of Coimbra, Coimbra, Portugal

³University Clinic of Gynecology- Faculty of Medicine, University of Coimbra, Coimbra, Portugal

⁴Clinical Academic Center of Coimbra CACC, Coimbra Hospital and University Centre - University of Coimbra, Coimbra, Portugal

⁵Centre for Innovative Biomedicine and Biotechnology CIBB, University of Coimbra, Coimbra, Portugal

⁶Coimbra Institute for Clinical and Biomedical Research iCBR- Area of Environment Genetics and Oncobiology CI MAGO, Faculty of Medicine- University of Coimbra, Coimbra, Portugal

⁷Central Administration of the Portuguese Health System, Administração Central do Sistema de Saúde ACSS, Lisbon, Portugal

Background

Uterine leiomyomas are the most common benign gynecological tumors. Symptomatic leiomyomas represent a major cause of hospitalization, particularly those associated with abnormal uterine bleeding and anemia. Despite the post-operative morbimortality associated with anemia in some surgical areas, there is actually insufficient evidence regarding the effect of anemia in patients hospitalized for uterine leiomyomas. Therefore, the aim of this study is to evaluate the impact of anemia on treatment management and clinical outcomes of hospitalized patients due to uterine leiomyomas.

Methods

Population and register-based retrospective study of women who were hospitalized with a primary diagnosis of uterine fibroid in public hospitals in mainland Portugal between 2010 and 2015. Data were extracted from the national database of the Central Administration of the Portuguese Health System. Comparative and multivariable logistic regression analysis was performed to assess the impact of anaemia on treatment approaches and clinical outcomes, namely on the need of surgical treatment, surgical management (conservative/radical), surgical route (laparotomy/endoscopy/vaginal), type of hospitalization (inpatient/outpatient, elective/urgent), number of hospitalization days and intra- and post-operative complications (dehiscence of the surgical wound, post-operative infection, haemorrhage, hematoma and/or seroma). A secondary analysis comparing acute versus chronic anaemia was also performed. All calculations were achieved using the STATA® software, version 16.0. Statistical significance was set at $p < 0.05$.

Results

A total of 36 295 patients were hospitalized due to uterine leiomyomas during this period. Of those, 11.5% presented with anaemia (50.7% with chronic anemia, 17.0% with acute anaemia and 32.3% with non-specified blood loss anaemia). This condition was associated with a high risk of inpatient hospitalization (OR: 5.161, 95%CI: 4.376-6.085), urgent admission to the Hospital (OR: 1.953, 95%CI: 1.797-2.121), radical surgical approach (OR: 2.559, 95%IC: 2.298-2.849), laparoscopic hysterectomy (OR: 1.575, 95%IC: 1.393-1.780) and intra- and post-operative complications (OR: 5.285, 95%IC: 4.332-6.448). It was also associated with longer hospital stays ($p < 0.001$). These outcomes were more pronounced in acute anaemic patients.

Conclusions

Anaemia has a significant impact on treatment approaches and clinical outcomes of women hospitalized for uterine leiomyomas. Our results corroborate those published in the literature that suggest that minimally invasive surgical procedures should be preferred in anaemic patients in order to reduce the risk of surgical bleeding and decrease perioperative morbidity. Indeed, the prompt identification and correction of anaemia may lead to a reduction in clinical and surgical complications, thus improving patient care.

Diagnostic hysteroscopy vs resectoscopy as a first approach for intrauterine pathology

Rita Lobo¹, Mariana Santos¹, Rita Torres Martins¹, Fernanda Vilela¹, Tatiana Semedo Leite¹

¹Centro Hospitalar Universitário do Algarve - Faro, Gynecology, Faro, Portugal

Background

Endometrial polyps are one of the most common etiologies of abnormal genital tract bleeding. Hysteroscopy is a minimally invasive approach to diagnose and treat this condition. In our Unit after a suspicion of endometrial polyp during ultrasound, we first choose to performed diagnostic hysteroscopy without anaesthesia, which most patients are able to undergo, and, only if confirmed, it is proposed to resectoscopy, this one under anaesthesia.

The aim of this paper is to evaluate if the two-step approach (first diagnostic hysteroscopy and, only after confirmation, the treatment with resectoscopy) has any advantage in the management of endometrial polyps.

Methods

A retrospective study was carried out at Centro Hospitalar Universitário do Algarve – Faro Unit with the selection of all women followed in a gynaecology consultation with suspected endometrial polyps on ultrasound who were referred for diagnostic hysteroscopy.

Results

105 women with ultrasound suspicion of endometrial polyps who performed diagnostic hysteroscopy were selected, in 62% (65) the presence of endometrial polyps was confirmed and 58% of these were referred for resectoscopy, being the rest referred to new imaging tests or for a new attempt at diagnostic hysteroscopy. Of the unconfirmed cases, 15% were also referred for resectoscopy because of the presence of other lesions, such as myomas and the cases that did not tolerate pain during the procedure were referred for hysteroscopy under anaesthesia. Only 42% of all women with ultrasound suspicion of polyps (even the cases without confirmation of this diagnosis) effectively required resectoscopy.

Conclusions

Given the significantly higher cost of performing a resectoscopy and the inherent risks of anaesthesia, we found our approach acceptable since less than half of the referred patients actually required a more invasive procedure.

Laparoscopic hysterectomy: impact of uterus weight in operative time

Mariana A. Santos¹, Rita Lobo¹, Joana Simões¹, Tatiana Semedo Leite¹, Rita Martins¹, Fernanda Vilela¹

¹Centro Hospital Universitário do Algarve, Gynecology, Faro, Portugal

Background

The current study was performed to evaluate the possible association between the postoperative uterus weight and operative time in women undergoing laparoscopic total hysterectomy for a benign indication.

Methods

We analysed retrospectively the data of 44 women underwent laparoscopic hysterectomy (LH) with bilateral salpingectomy (BS) or bilateral adnexectomy (BA), without intraoperative complications, between 2017 and 2021 in Centro Hospitalar Universitário do Algarve. Women with other surgeries planned in addition to LH and SB or LH and AB, at the same surgical time were excluded (n=3). The uterus weight was evaluated after specific treatment in pathology department.

Normal distribution was checked using skewness and kurtosis test. Pearson`s correlation coefficient was used to assess the correlation between uterus weight and surgical time. Reported p value is two-tailed, with p value of 0.05 or less indicating statistical significance.

Results

The data of 41 women were analysed. The average operative time was 193,0 minutes (min), standard deviation +/- 54,5 min; minimum and maximum, 100 and 329 min, respectively. The average of uterus weight was 166.8 g (grams), standard deviation +/- 88.3g, minimum 30g and maximum 367g.

Our results shows that there is a positive correlation, statistically significant but weak between uterus weight and operative time in laparoscopic hysterectomy (r=0.317; p= 0.043)

Conclusions

The uterus weight is a weak predictive factor in operative time of laparoscopic hysterectomy. Other factors, such as the surgeon's experience, will probably also influence the surgical time.

Hysteroscopic findings in asymptomatic postmenopausal women with endometrial thickening

Patrícia Ferreira¹, Susana Saraiva¹, Matilde Martins¹, Ana Paula Reis¹, Vânia Ferreira¹, Cristina Costa¹

¹Centro Hospitalar de Entre Douro e Vouga, Department of Obstetrics and Gynaecology, Santa Maria da Feira, Portugal

Background

Endometrial pathology may be present in the absence of postmenopausal bleeding. In many cases, uterine pathology may be asymptomatic. Today hysteroscopy is commonly regarded as the gold standard for the diagnosis and assessment of intrauterine pathology.

We aimed to correlate hysteroscopic and pathological findings in asymptomatic postmenopausal women with sonographically thickened endometrium (≥ 5 mm).

Methods

Retrospective study that included postmenopausal women who underwent surgical hysteroscopy with endometrial thickening (≥ 5 mm), between 1 January 2020 and 31 December 2020. Excluded criteria: vaginal bleeding; history of breast cancer with use of tamoxifen.

Of the total of 300 surgical hysteroscopy, 64 were selected. These were compared with ultrasonography and anatomopathological results.

Results

The mean age of the patients was $59,3 \pm 5,2$ years and the mean time of menopause was $50,1 \pm 4,1$ year. The diagnostic hysteroscopic findings were polypoid lesion in 22 patients (59,5%); diffuse thickening in 13 patients (35,1%); polypoid lesion and myoma in 2 patients (5,4%). The anatomopathological results were endometrial atrophy in 28 patients (75,7%); endometrial hyperplasia without atypia in 4 patients (10,8%); myoma in 4 patients (10,8%); endometrial hyperplasia with atypia in 1 patient.

Conclusions

Hysteroscopy has replaced blind procedures and is now considered the gold-standard technique for the diagnosis and management of intrauterine pathology.

In many of the patients, the hysteroscopic examinations revealed that there was no real endometrial thickening but rather other types of lesions in the uterine cavity. The main hysteroscopic finding was endometrial polyp.

Factors affecting pain experienced during hysteroscopy without anaesthesia

Rita LOBO¹, Santos Mariana¹, Rita Torres Martins¹, Fernanda Vilela¹, Tatiana Semedo Leite¹

¹Centro Hospitalar Universitário do Algarve - Faro, Gynecology, Faro, Portugal

Background

Hysteroscopy is a minimally invasive procedure widely used in Gynaecology to diagnose and treat common problems, such as abnormal uterine bleeding, endometrial polyps, fibroids and more. One of the main reasons for failure of hysteroscopic without anaesthesia is intolerance to pain. Increasingly experienced operators and smaller diameter hysteroscopes are mitigating this issue. Recognizing if there are common characteristics among women who experienced a high degree of pain can also contribute to avoid failure, as management can be improved by forwarding for procedure under anaesthesia promptly, for example.

The aim of this paper is to investigate prevalence and intensity of pain during diagnostic hysteroscopy and related factors.

Methods

A total of 92 women were questioned about the intensity of pain after performing diagnostic hysteroscopy at Centro Universitário do Algarve – Faro Unit. The procedure was performed without analgesia or anaesthesia, without pre- or intra-procedure cervix ripening, using a 4-4,5 mm rigid hysteroscope, by physicians with different levels of expertise. Visual analog scale from zero (no pain) to ten (intolerable pain) was used to score pain intensity. Parameters such as age, parity, menopausal status, history of infertility, history of curettage, previous diseases were also assessed.

Results

The mean age of the group was 52 years (standard deviation 11.89). 37 patients (40%) reported no pain or slight discomfort (0-3 score), 36 patients (39%) reported moderate pain (4-7 score), 13 patients (14%) reported severe pain (8-9 score) and 6 patients (7%) reported intolerable pain. The study revealed that there is no statistically significant difference in pre- and post-menopausal women at any score of pain, as it happens in the pre-menopausal group between nulliparous and multiparous. Severe and intolerable pain was experienced more frequently in women with previous curettage (50,0% vs 20,5%, p value = 0,0016). Depression, arterial hypertension, hypothyroidism, and obesity are pathologies frequently found in the group with severe or intolerable pain (without static significance).

Conclusions

The majority of patients are able to undergo through diagnostic hysteroscopy, being perceived as a mild discomfort procedure by most. Pain perception is linked to previous curettage. Some pathologies, such as depression, can often be found in women who experience severe pain. Relationship regarding menopausal status or parity was not found in this sample, contrary to what is found in most of the available data.

Accuracy of hysteroscopy in predicting endometrial histopathology: leiomyomas and endometrial polyps

Mariana A. Santos¹, Rita Lobo¹, Rita Martins¹, Fernanda Vilela¹, Tatiana Semedo Leite¹

¹*Centro Hospital Universitário do Algarve, Gynecology, Faro, Portugal*

Background

The current study was performed to assess hysteroscopic accuracy in estimating pathologic conditions, specifically, submucous myomas and polyps.

Methods

The data of seventy-nine women undergoing diagnostic hysteroscopy in Centro Hospitalar Universitário do Algarve for suspected endometrial pathology, mostly because of abnormal uterine bleeding, were collected for a retrospective study. Sensitivity, specificity, and negative (NPV) and positive (PPV) predictive values of hysteroscopy in detecting leiomyomas and polyps were calculated.

Results

When compared with the histologic diagnosis of the uterus, the hysteroscopic findings showed a global diagnostic sensitivity for leiomyomas and polyps of 87%, a specificity of 88.2%, a PPV of 91.1%, and a NPV of 87%.

Hysteroscopy showed sensitivity, specificity, PPV, and NPV of 97.0%, 71.4%, 90.3%, and 71.4%, respectively, in predicting presence or absence of endometrial polyps.

In other hand, the results in estimating submucous myomas by hysteroscopy show us a sensitivity, specificity, PPV, and NPV of 46.7%, 96.9%, 77.8%, and 88.6%, respectively

Conclusions

Diagnostic hysteroscopy is a basic tool that allows diagnosis of intrauterine lesions such as polyps and submucous myomas with high grade of precision. Nevertheless, better knowledge of relationship between hysteroscopic imaging and pathophysiologic states of endometrium is necessary to improve its accuracy.

Total Laparoscopic Hysterectomy and bilateral salpingectomy for recurrent Cervical Intraepithelial neoplasia - A dilemma or a practical solution.

Stewart A Disu¹

¹*London Northwest University Healthcare NHS Trust, Gynaecology, Mill Hill, United Kingdom*

Background

Hysterectomy is a known and acceptable treatment regimen for histologically proven cervical intraepithelial neoplasia especially if there are co-existing conditions. Hysterectomy is also acceptable for treatment of abnormal cervical cytology and endocervical pathology which contributes to endocervical cytology.

Total Laparoscopic Hysterectomy is fast becoming the leading type of hysterectomy surgery in the United Kingdom. This depends on availability of surgeon, surgical techniques, type of theatre venue. There is also improvement in selecting a total laparoscopic hysterectomy as the gold standard procedure to reducing any residual or incomplete vaginal cuff.

Methods

This is a case series of recurrent cervical intraepithelial neoplasia that have been discussed at a multidisciplinary team meeting with a resultant decision to offer a Total Laparoscopic Hysterectomy and bilateral salpingectomy with ovarian conservation.

The primary laparoscopic entry is the modified palmers point entry, 8cm from the midline - point A and 3cm inferior to the left subcostal margin marked as point B.

A veress needle is inserted with a resultant 3 clicks indicating a puncture pneumoperitoneum ratio of 1:1 and successful in over laparoscopic 300 surgeries. A resultant entry pressure of less than 7mmhg indicated an appropriate location of the veress within the pneumoperitoneum.

A opti-trocar is then inserted via the modified palmers point to gain access to the abdominal cavity. Secondary trocars are inserted under vision. A medium sized v-care uterine manipulator instrument is inserted to a 7cm uterine depth with pressure applied onto the uterosacral ligaments. A concentric ring is then noted for colpotomy. The round ligament is first ligated and divided prior to skeletonizing the uterovesical fold. The bladder is filled with 150mls of sterile water to delineate the bladder muscularis border prior to skeletonizing uterine arteries. A posterior peritoneal reflection to the level of the uterosacral ensures a safe and wide colpotomy. The uterus is retrieved via the vaginal opening and intracorporeal stratafix suture - Ethicon, United States of America is used for laparoscopic closure of the vault with uterosacral plication.

Results

All cases had uncomplicated Total laparoscopic Hysterectomy surgery via the modified palmers point view with no incomplete margins of cervical intraepithelial neoplasia.

Average surgical time was 75 minutes, minimal blood loss of less than 50mili-litre and an inpatient stay of 1.25 days. There were no bladder or bowel injuries. The margins were clear of cervical intraepithelial neoplasia on histology.

Conclusions

A novel technique using the modified palmer's approach and uterosacral plication gives support to avoiding incomplete margins during Total Laparoscopic Hysterectomy and bilateral salpingectomy for Cervical intraepithelial neoplasia treatment.

Assessment of Quality of Life in women with severe endometriosis post-surgical treatment: Results from a Tertiary Centre

Jameela Sheikh¹, Halimah Khalil¹, Hajra Khattak², Akhshara Sharma³, Lina Antoun², Yousri Afiff²

¹University of Birmingham, College of Medical and Dental Sciences, Birmingham, United Kingdom

²Birmingham Women's and Children's Hospital NHS Foundation Trust, Birmingham Women's Hospital, Birmingham, United Kingdom

³Aston University, Aston Medical School, Birmingham, United Kingdom

Background

Endometriosis is the presence of endometrial-like tissue outside the uterus and affects 10-15% of women of reproductive age, 50% of women with infertility, and 70% of women with chronic pelvic pain. Symptoms vary significantly and may persist even after surgical treatment, which can significantly impact the day-to-day lives of these women, and therefore, quality of life is an important indicator for symptom-led management of Endometriosis. This study aims to assess the quality-of-life follow-up rates in women with severe Endometriosis post-surgical management.

Methods

All women who underwent laparoscopic surgery at the Birmingham Endometriosis Centre (BEC) were retrospectively evaluated on QoL questionnaire completion from 1 September 2016 to 30 September 2021, assessing data from the Birmingham Women's Hospital from the BSGE Endometriosis Centres Database. Completion of questionnaires were analysed at six-month, one-year and two-year intervals compared to pre-operative results. Two validated questionnaires were used for quality-of-life assessment. Firstly, the EQUVAS scored 1-100, where a higher score denotes improvement, and secondly, the EQ5D questionnaire with five domains (usual activities, pain, anxiety and depression, mobility, and self-care) scored 1-3, where higher scores denote a declining quality of life. Results are presented as means and standard deviations (SD).

Results

134 women who underwent laparoscopy at BEC were included (mean age 38 SD ± 8 ; mean BMI 27.5 SD ± 5.5). 87.4% (n=118/135) had completed QoL at initial consultation. Thereafter, 43.7% (n=59/135), 36.3% (n=49/135) and 11.9% (n=16/135) completed follow-up at 6-months, 1-year, and 2-years post-surgery, respectively. Only 5.2% (n=7/135) completing all assessments, whilst 43% (n=58/135) did not complete any QoL assessment post-surgery.

Compared to pre-operative EQUVAS mean scores (50.2 ± 22.8), women showed improvement in quality of life at one-year (64.8 ± 24.4 ; p=0.0014) and two years (61.5 ± 24.5 ; p=0.0371) post-surgery. Significant improvements were noted in EQ5D domains of usual activities (1.77 ± 0.5 vs 1.5 ± 0.57), pain (2.19 ± 0.55 vs 1.85 ± 0.69), and anxiety and depression (1.79 ± 0.64 vs 1.57 ± 0.65) at six months follow-up. 90 women with Endometriosis were trying to conceive, of whom 18.8% achieved pregnancy following surgical treatment.

Conclusions

This study reports the surgical management of severe Endometriosis significantly improves the quality of life in the long term. These results also highlight the irregular quality of life assessment preventing adequate evaluation. Therefore, strategies to improve quality of life follow-up are essential; public and patient involvement should be incorporated to re-design material, tailor patient education and introduce regular text reminders. Additionally, a longer follow-up period is required to assess the effects of surgical treatment on the overall quality of life.

Retrospective analysis of the rate of laparoscopic surgery for endometrial cancer in University Hospital Wishaw Scotland.

Uzma Minhas¹, Calum Richardson¹, Sreedevi Gurram¹

¹NHS Lanarkshire Scotland, Gynaecology, Glasgow, United Kingdom

Background

One of the Quality Performance Indicator (QPI) for Endometrial Cancer Care in Scotland is achieving >70% rate of laparoscopic surgery for endometrial cancer patients. The aim of our study was to analyse how we are performing against the standard. We investigated the rate of complications and the duration of hospital stay after laparoscopic surgery as compared to open operation. We reviewed the presence of risk factors, grade, stage, and histological subtype of endometrial cancer in our population.

Methods

A retrospective analysis of all endometrial cancer cases discussed in the multi-disciplinary team meetings between June-December 2021 was carried out. A total of 63 patients' notes were reviewed.

Results

7.9% (5/63) patients were not fit for surgery or had palliative management. 13.8% (8/58) were referred for central surgery. 92.1% (58/63) had surgery of which 86.2% (50/58) were operated in Wishaw Hospital 90% (45/50) had laparoscopic surgery. 10% (5/50) had open operation. 2 of these 5 had a planned open approach (1 for fibroids, 1 for 3 x peri umbilical hernia) and the other 3 were converted to open for poor access (1 for adhesions, 1 bicornate uterus, 1 for tubo-ovarian abscess). The mean hospital stay after a laparoscopic surgery was 1.94 days (1-6 days) and for open operations was 3 days (1-5 days). None of the open or laparoscopic patients had any per-operative complications or needed to go back to theatre.

4.4% (2/45) of the laparoscopic patients had vault haematoma. Both were managed conservatively. Only one of them needed readmission. None of the patients who had open operation needed readmission. The risk factors assessment showed that all patients had either postmenopausal bleeding or heavy menstrual bleeding at presentation. The mean Body Mass Index (BMI) of these patients was 37.1. 6.3% (4/63) of the patients had a history of breast cancer and took tamoxifen. 15.9% (10/63) had type 2 diabetes.

Conclusions

We exceeded the QPI for Laparoscopic Surgery in endometrial cancer patients. Post operative hospital stay for laparoscopic patients was shorter than the open surgery. Our conversion rate from laparoscopic to open surgery was low. Per-operative complications and return to theatre was nil. Mild self-resolving vault hematoma was the only post operative complication. Postmenopausal bleeding, high BMI and diabetes were the most common risk factors in these patients. Overall, our success rate and safety profile are high for laparoscopic surgery in the University Hospital Wishaw.

Patient awareness of association between obesity and endometrial cancer in postmenopausal bleeding clinic.

Uzma Minhas¹, Harkiran Narang¹

¹NHS Lanarkshire Scotland, Gynaecology, Glasgow, United Kingdom

Background

Endometrial cancer is the fourth most common cancer affecting women with over 1900 British women dying from it each year. It ranks the highest amongst all cancers in its association with obesity. Its incidence has risen over the past 20 years largely due to the rising of obesity rates. Recently published data highlight that the number of new cases of endometrial cancer is predicted to increase by 55% between 2008-2012 and 2023-2027.

Combating obesity can be a preventative oncology measure to decrease the risk of endometrial cancer. Through our survey, using a patient questionnaire, we explored patient awareness of obesity, its health consequence, and how we could help these women to achieve a healthy body mass index (BMI).

Methods

Women attending the post-menopausal bleeding (PMB) clinic in our hospital filled in a questionnaire designed to check their perception of their own BMI and its health implications. They were asked what they thought a normal BMI is and what their estimation of their own BMI was. They were asked if a high BMI is associated with medical morbidities and increased risk of cancer. We enquired if they had tried to lose weight before and if they felt embarrassed to ask for help. We checked if they had been advised to lose weight by a health care professional and what helped them the most to do so.

Results

108 women participated. The majority of women, 60%, could correctly estimate their BMI but only 41% knew what a healthy BMI is. Around 49% of the women were aware that >60% of the population is obese. There was greater awareness of the increased risk of heart disease, diabetes, or stroke (89.8%) with obesity than with the increased risk of cancer. Amongst all cancers included in the questionnaire, the association of endometrial cancer with obesity was the least well known (only 25%). 57% of the women had never been recommended weight loss despite their BMI being over 25. For most women diet and exercise were the main methods of weight loss over medical or surgical interventions.

Conclusions

In our hospital we need to design a long-term plan to decrease the incidence of endometrial cancer through the implementation of strategies focusing on preventative oncology. Those at high risk of cancer should have access to a clinical psychologist, dietary advice, and prophylactic bariatric surgery. The results of our survey highlighted the need for an open discussion between health care professionals and patients about their BMI and its association with endometrial cancer. We concluded that improving patient awareness through simple measures like posters and patient information leaflets focussing on the increased risk of cancer with obesity and providing strategies to combat obesity could make a difference.

Outcomes after laparoscopic treatment of symptomatic isthmoceles and/or in women with secondary infertility.

Enrique Moratalla Bartolomé¹, Javier Ernesto Sancho Sauco¹, Maria Miro Matos², Elena Cabezas López¹, Nerea Montero Pastor², Irene López Carrasco²

¹*University Hospital Ramón y Cajal. University Hospital HM Montepíncipe, Obstetrics and Gynecology, Madrid, Spain*

²*University Hospital HM Montepíncipe, Obstetrics and Gynecology, Madrid, Spain*

Background

The aim of this study was to assess the effectiveness of laparoscopic surgical treatment of isthmoceles in women with associated symptoms or reporting pregnancy in patients with secondary infertility.

Methods

A prospective case series study was performed. This study included all women with ultrasonographic diagnosis of isthmocele, with maximum myometrial thickness of 2.5 mm (if it was greater than 2.5-3 mm they were not included in the study because the correction in this case was performed by hysteroscopy) and symptoms (abnormal uterine bleeding or pelvic pain) or secondary sterility, who had undergone laparoscopic correction between January 2018 and December 2021 (4 years) in our hospital.

Results

Twenty-six women underwent laparoscopy for correction of symptomatic isthmoceles or for secondary infertility. Mean age of the women was 36.5 (30-44) years. All women had at least one previous caesarean section (mean 1.4 (range 1-3)). Mean time between the last caesarean section and isthmocele correction was 3.39 (1.5-6) years.

Regarding the clinic, 45.83% presented abnormal uterine bleeding, mainly spotting, while 50% presented pelvic pain. 25% of the patients had secondary infertility and 14 patients had reproductive desire.

The ultrasound evaluation of the isthmoceles was performed with a 2D ultrasound machine. 16.67% of the patients presented a retroverted uterus. Mean myometrial thickness measured by ultrasound was 1.91 (0.75-2.5) mm.

2 patients underwent a myomectomy simultaneously with the correction, while another patient had an ectopic pregnancy in the isthmocele that was removed. There was only one intraoperative complication (bladder injury that was repaired without incident). No complications or adverse effects were reported after laparoscopic correction.

Follow-up was performed one month and two months after surgery. There was complete resolution of symptoms in 23 patients (88.46%). Spotting persisted in 2 patients (in less quantity) and pelvic pain and bleeding persisted in 1 patient.

Secondary infertility was assessed one year after surgical isthmoplasty. Of the 14 patients with reproductive desire, 11 completed the first year of follow up and 6 (54.54%) of them reported pregnancy after treatment. Among the patients who reported pregnancy, 1 had a full-term pregnancy (cesarean section), 3 have a pregnancy in progress at this time and 2 presented a miscarriage.

Conclusions

Laparoscopic correction of isthmoceles may constitute a safe and effective technique for resolving symptoms in patients with abnormal uterine bleeding or pelvic pain. In patients with secondary infertility and isthmocele, it could improve the possibility of future successful pregnancy, although longer-term follow-up and further studies are needed to assess this indication.

Benefits of combined laparoscopy and hysteroscopy in cases of Asherman's syndrome-case series.

Raxshanda Aliyeva¹, Islam Magalov¹, Arzu Polukhova¹

¹Baku branch of the First Moscow State Medical University named after I.M. Sechenov- Baku Health Center, Obstetrics and Gynecology, Baku, Azerbaijan

Background

Asherman's syndrome most commonly occurs after dilatation and curettage (D&C) for incomplete abortion (50%), postpartum haemorrhage (24%), and elective abortion (17.5%). Other, less common etiological factors, including myomectomy, hysterotomy and caesarean section (2-2.8%). Due to the sharp increase in caesarean section rates in Azerbaijan, the incidence of severe Asherman's syndrome is also increasing. A distinctive and complicating feature of this type of Asherman's syndrome is the fusion of the uterus with the anterior abdominal wall, which changes the normal axis of the uterus and complicates the hysteroscopic adhesiolysis.

For Asherman's syndrome patients with a history of Caesarean section and other uterine surgeries, we proposed a combination of hysteroscopy and laparoscopy for definitive and one-procedure treatment.

Methods

This case series included 4 patients with severe Asherman's syndrome between September 2022 and May 2022. All of them had previously undergone 2-4 ineffective hysteroscopic adhesiolysis. One patient had 4 hysteroscopies and 2 uterine perforations during surgery in anamnesis. At the beginning of surgery, diagnostic hysteroscopy was performed by 4 mm Bettocchi hysteroscope using vaginoscopic approach. After confirming the diagnosis, a standard laparoscopic approach was used by 2 trocars 10 mm trocars and 3 trocars 5 mm. All patients had adhesions of the uterus with the anterior abdominal wall. After laparoscopic adhesiolysis and full uterus detachment from abdominal wall, simultaneous hysteroscopy with Bettocchi 4 mm hysteroscope and 5 Fr hysteroscopic scissors was performed. Cooper intrauterine device was placed for 2 months. Oestrogen-progesterone therapy was initiated for 1 month. Control hysteroscopy was performed 2 months later.

Results

Complete restoration of normal uterine cavity and visualization of both tubal ostia was performed in all patients. Control hysteroscopy revealed no restoration of adhesions. All have resumption of menses. All patients under follow-up in the reproductive department and are preparing for IVF for other reasons (low AMH, male infertility).

Conclusions

The combination of laparoscopy with hysteroscopy in severe forms of Asherman's syndrome in patients with a history of uterine surgery seems to be feasible, safe, and promising in terms of radical treatment with a single procedure.

The impact of hysterectomy on oncological outcomes in patients with borderline ovarian tumors: a multicentre retrospective study.

*Manuela Maletta*¹, *Raffone Antonio*¹, *Raimondo Diego*¹, *Stefano Restaino*², *Giuseppe Vizzielli*², *Renato Seracchioli*¹

¹*IRCCS Azienda Ospedaliero-Universitaria di Bologna, Division of Gynaecology and Human Reproduction Physiopathology, Bologna, Italy*

²*Azienda Sanitaria Universitaria Friuli Centrale, Clinic of Obstetrics and Gynecology- "Santa Maria della Misericordia" University Hospital, Udine, Italy*

Background

Data about the oncological outcomes in Borderline ovarian tumour (BOT) women undergoing uterine-sparing surgery without ovarian preservation are poor. The aim of the study was to assess the oncological outcomes in BOT women undergoing uterine-sparing surgery without ovarian preservation.

Methods

A multi-centre observational retrospective cohort study was performed including all consecutive patients who underwent surgical treatment for BOT at three tertiary level referral centres for gynaecologic oncology from January 2005 to December 2016. Patients were divided into two groups for comparisons: patients undergoing hysterectomy (hysterectomy group) and patients undergoing uterine-sparing surgery (no hysterectomy group). Study outcomes were disease-free survival (DFS), overall survival (OS), disease-specific survival (DSS) and surgical complications rate.

Results

Ninety-eight patients were included: 44 in the hysterectomy group and 54 in the no hysterectomy group. The 5- and 10-year DFS rates were 97.7% (95% CI: 84.9–99.7) and 92.3% (95% CI: 69.7–98.2), in the hysterectomy group, and 86.8% (95% CI: 74.3–93.5) and 86.8% (95% CI: 74.3–93.5), in the no hysterectomy group, respectively, without significant differences ($p=0.16$). Hazard ratio for DFS was 0.26 (95% CI: 0.06–1.68) for the hysterectomy group. The 5- and 10-year OS rates were 100.0% (95% CI: -) and 100.0% (95% CI: -), in the hysterectomy group, and 98.2% (95% CI: 87.6–99.7) and 94.4% (95% CI: 77.7–98.7), in the no hysterectomy group, respectively, without significant differences ($p=0.23$). No significant difference in complication rate was reported among the groups ($p=0.48$).

Conclusions

As hysterectomy appears to not impact survival outcomes of BOT women, it might be avoided in the surgical staging.

The role of intra-operative sigmoidoscopy in laparoscopic excision of bowel endometriosis

Lina Antoun¹, Nigel Sugget², Yousri Afifi¹

¹*Birmingham Women's Hospital, Minimal access team- Gynaecology department, Birmingham, United Kingdom*

²*University Hospitals Birmingham, Colorectal cancer services- General Surgery, Birmingham, United Kingdom*

Background

Bowel endometriosis can present with non-specific symptoms consisting of dysmenorrhoea and dyspareunia. Specific bowel-related symptoms such as diarrhea, constipation, dyschezia and rarely bowel obstruction depend on the endometriosis nodule localisation, size, and depth of involvement of the bowel wall. Surgical treatment is effective in improving pain but can be associated with significant complications, which can be as high as 22% in case of deep infiltrating endometriosis. We describe our new laparoscopic technique we used to perform shaving and disc resection in deep infiltrative symptomatic bowel endometriosis.

Methods

Prospective cohort study at Birmingham Women's Hospital endometriosis centre

Results

A series of 25 women with deep infiltrating endometriosis involving the bowel were included in our study. All our patients did not respond to previous conservative surgical and hormonal therapy. Patients did not have special preparation (enemas or laxatives) to empty the colon. All our patients had bowel endometriotic nodules not exceeding 3 cm in size, and not involving more than 50% to 60% of circumference of the rectum or sigmoid wall. A short, rigid sigmoidoscope that contain a light source was used to assess for the infiltration of bowel endometriotic nodules. Bowel shaving was performed in 21/25 (84%) of patients and bowel disc resection was performed in 4/25 (16%) of patients. All patients had the procedure done under sigmoidoscopy guidance to ensure accurate removal of the nodules. Both shaving and disc resection were performed using Monopolar scissor. All patients had good recovery post-operatively. No Clavien-Dindo complication was reported in any of our patients. In 3 months postoperative follow up, nineteen women reported complete relief of the symptoms, whilst six had ongoing pelvic pain. One woman underwent an additional procedure for further excision of endometriosis and was found to have extensive adhesions which were present in her first surgery where extensive adhesiolysis was performed. Two infertility patients achieved pregnancy.

Conclusions

Our presentation describes our laparoscopic surgical technique for shaving and excision of bowel endometriosis under sigmoidoscopy guidance, which was proved to be feasible, effective, and safe

Diagnostic accuracy study of sonography in adenomyosis: a study in current practice

Perrine Capmas¹, Constance Maudot¹, Hervé Fernandez¹

¹Bicetre hospital, Gynecologic and Obstetrics department, Le Kremlin Bicetre, France

Background

Clinical expression of adenomyosis is very heterogeneous. The gold standard for diagnosis is pathology. Several non-invasive exams are used to diagnose adenomyosis: pelvic MRI, abdominal and intra-vaginal 2D or 3D sonography. The aim of this study is to estimate diagnostic accuracy of sonography in the diagnosis of adenomyosis in current practice, compared to pathology as a gold standard.

Methods

This diagnosis accuracy study is observational and retrospective, including women managed by hysterectomy for benign pathology from January 2015 to November 2018. Preoperative pelvic sonography reports were collected, including details on diagnosis criteria for adenomyosis. Sonographic findings were compared to pathological results of hysterectomy.

Results

We included 510 women, 242 had adenomyosis at pathological examination. The pathological prevalence of adenomyosis was 47.4% in this study.

A preoperative sonography was available for 89.4% of women, with a suspicion of adenomyosis in 32.7%.

In this study, sensitivity is 52%, specificity 85%, positive predictive value 77%, negative predictive value 86%.

Conclusions

Pelvic sonography is the first non-invasive exam used in gynaecology. It is also the first recommended examination for the diagnosis of adenomyosis because of its acceptability and its cost, even if diagnosis' performances are moderate. However, these performances are comparable to MRI's performances. The use of a standardized sonographic classification could improve and harmonize the diagnosis of adenomyosis.

“Comparison of peri-operative surgical outcomes between protected and free manual vaginal morcellation of large uteruses following total laparoscopic hysterectomy”

Agnese Virgilio¹, Camilla Franceschini¹, Diego Raimondo¹, Manuela Maletta¹, Renato Seracchioli¹, Paolo Casadio¹

*¹IRCCS Azienda Ospedaliero-Universitaria di Bologna,
Division of Gynaecology and Human Reproduction Physiopathology- IRCCS Azienda Ospedaliero-
Universitaria di Bologna-, Bologna, Italy*

Background

To the best of our knowledge, there are no studies in literature making a comparison between protected and free vaginal morcellation following laparoscopic hysterectomy in terms of feasibility and safety. The aim of the present study was to compare peri-operative surgical outcomes (operative time and surgical complications) between protected and free manual vaginal morcellation of large uteruses after total laparoscopic hysterectomy in women at low risk of uterine malignancy.

Methods

A retrospective and monocentric study on medical records and electronic clinical databases of all consecutive eligible patients undergoing laparoscopic total hysterectomy and manual vaginal morcellation by expert surgeons between January 2015 and August 2021 was conducted. Patients were divided in two groups according to the type of manual vaginal morcellation: protected with an endo-bag or free one. The two groups were compared in terms of demographic, clinical, surgical, and pathological data.

Results

During study period, we included for study analyses 271 patients that were divided as follows: 186 (68.6%) patients underwent the protected morcellation, while the remaining 85 (31.4%) the free one. Despite no significant differences were found in terms of age, BMI, previous abdominal surgery, clinical symptoms and uterine weight, the mean operative time was statistically lower in the endobag group compared to the free morcellation group (134 ± 43 minutes vs $156 \text{ minutes} \pm 54$ minutes, $p < 0.001$). At the end of surgery, no macroscopic leakage of the endobag was reported. Overall surgical complications occurred in 21 (11%) and in 6 (7%) patients of the protected and free morcellation groups respectively, without a statistically significant difference. The rate of occult uterine malignancy did not differ between the two groups.

Conclusions

Protected vaginal manual morcellation of the uterus after total laparoscopic total hysterectomy using an endo-bag seems to reduce operative time, thus potentially reducing hospital costs. It seems to be a safe procedure since it is not associated to a higher risk of surgical complications. Larger prospective studies are needed to confirm our data.

Optimising laparoscopic training for junior trainees to minimise training disruption as part of the post Covid-19 recovery plan

Benjamin Twist¹, Rebecca Smith¹

¹Wirral University Teaching Hospital NHS Foundation Trust, Obstetrics and Gynaecology, Wirral, United Kingdom

Background

For gynaecological trainees, one of the main impacts of the Covid-19 pandemic seems to be a restricted access to regular theatre sessions. Whilst this likely affected everyone equally during the pandemic itself, as theatres re-open it now seems that the more junior trainees are disproportionately affected (perhaps a reflection of a higher urgency for more senior trainees to acquire specific skills). I wanted to explore ways to minimise the impact of reduced theatre exposure for these junior trainees.

Methods

Across two separate tertiary referral laparoscopic units, I lead individual training sessions on a laparoscopic box trainer with trainees in their first three years of specialty training. Each trainee only received one session each. These sessions lasted an hour and focused specifically on laparoscopic suturing, traditionally viewed as an advanced skill. Each trainee who undertook one of these sessions completed a before and after survey exploring their views on barriers to training, as well as their views on the taught sessions. The teaching outcomes for each training session (scores on a warmup game, success in completing a laparoscopic throw, time taken to achieve this and trainee's global view on the session) were recorded.

Results

All (100%) of the trainees managed to successfully throw at least one laparoscopic knot during the session. The times to first success and the complexity level of the knot tied showed an improving trend as I taught more sessions. The student's self-assessment also showed a trend towards more positive the more sessions I taught. There was no clear trend in the initial 'laparoscopic skill assessment' taken at the start of the session (moving small beads from one pot to another in a given time)

Conclusions

The results suggest that it is the quality of the teaching the students received, rather than their innate laparoscopic skill, that was the most significant factor in achieving success in their learning outcomes. The more sessions I taught, the more refined my teaching became. This evidence the value of units having a named lead for laparoscopic training who can enhance their skills as a teacher, which should improve learning outcomes. I also believe these results show that we should challenge the view that laparoscopic suturing is something that should only be taught to advanced trainees, given the success demonstrated in this pilot.

A rare hysteroscopic “pathology”- hysteroscopic diagnosis of endometrial vascular dystrophy

Shaun McGowan¹, Charlotte Goumalatsou², Andrew Kent³

¹*Belfast City Hospital, Gynaecology, Belfast, United Kingdom*

²*St Richard's Hospital, Gynaecology, Chichester, United Kingdom*

³*Royal Surrey County Hospital, Gynaecology, Guildford, United Kingdom*

Background

This case was presented as an oral presentation at the British Society of Gynaecological endoscopy annual scientific meeting 2021

We present an overview of a rare hysteroscopic diagnosis- that of endometrial vascular dystrophy.

Methods

Case Report-

A 45-year-old P3+1 with a history of 2 previous CS and a TCRE presented with ongoing menorrhagia. An ultrasound suggested focal adenomyosis and a uterine niche.

Results

A hysteroscopy was performed showing a central adhesion septum with the surrounding endometrium having a highly unusual appearance. Reddish brown vessels were arranged in whorls and spirals covering the endometrium. We were initially unsure of the diagnosis and biopsies were taken. Pathology showed secretory endometrium with endometrial glands showing luminal blood. Subsequent literature review suggested a diagnosis of endometrial vascular dystrophy. The patient declined further investigation or treatment

Conclusions

This distinctive condition has been reported rarely in the literature with 2 cases being first described in 1991 by Hamou, a 2-case series reported in JMIG by Paoletti et al in 2012, and an 8 case series reported in *Obsterica y Ginecologia* by Sopolana et al in 2017. This condition has been characterised initially as a vascular disorder with small, dilated capillaries arranged in a parallel pattern covering the surface of the endometrium. It appears to be more common in the luteal phase of the cycle and has been shown to regress. Pathology is benign, that of secretory endometrium with stromal decidualisation appears common. Recent controversy has arisen in the nomenclature and aetiology of the condition, some propose a variant of normal while histology suggests that the tortuous structures are in fact glandular rather than vascular as in our case.

Avoiding prosthetic material in vaginal cuff prolapse: lateral suspension with not absorbable suture

Gabriele Centini¹, Francesca Marchetti², Matteo Giorgi³, Francesco Martire⁴, Lucia Lazzari², Errico Zup²

¹University of Siena, Molecular and Developmental Medicine, San Rocco A Pilli, Italy

²University of Siena, Molecular and Developmental Medicine, Siena, Italy

³University of Siena, Molecular and Developmental Medicine, Siena, Italy

⁴Ospedale La Gruccia- Montevarchi, Obstetrics and Gynecology, Montevarchi, Italy

Background

Surgery for pelvic organ prolapse POP is common among women. The lifetime risk of undergoing at least one surgical intervention by the age of 80 was estimated to be between 6,3 % and 19%, with 30% of women experiencing recurrence.

To improve outcomes and reduce recurrence, the use of mesh implants increased in the last decade. However, the use of prosthetic materials implies specific risks such as vaginal erosion, infections or vesico-vaginal fistula leading to dyspareunia and chronic pain.

In recent time mesh-related complication became a big deal especially in certain country causing the banding of several type of meshes.

Laparoscopic lateral colposuspension, as described by J. Doubisson, is used to correct POP anchoring the vaginal cuff to the abdominal fascia. Considering the recent legal issues, we changed our practice moving to not absorbable sutures.

Methods

We retrospective selected all the patients undergone laparoscopic colposuspension for cuff prolapse between January 2018 and April 2021 in Siena University Hospital and compared surgical outcomes, relapse, operating time between colposacropexy and lateral suspension performed with not absorbable suture with a follow up at 6 and 12 months.

Results

a total of 83 patients were included in the study 43 performed with lateral suspension with not absorbable suture (Group A) and 40 with sacrocolpopexy (Group B).

The operative time was significantly shorter in Group A ($p<0.05$) and short term follow up evaluation didn't show any clinical difference in term of apical prolapse (point C), while a better outcome in Ba point was detected in patients of Group B ($p<0.05$).

At the 12 months follow up 6.9% (n=3) of the patients of the group A had a complete relapse of the prolapse that needed a reintervention while Group B had a worsening in the clinical evaluation that didn't require additional procedure with 2 (5%) patients reporting vaginal mesh and 3 (7.5%) moderate dyspareunia.

Conclusions

In our clinical experience this technique is a valid alternative to laparoscopic sacrocolpopexy in term of clinical outcomes and is a safe, easily reproducible technique, with a good success rate and rare peri and post-operative complications. Furthermore, this technique, despite a little higher risk of recurrence, avoid the use of prosthetic material and the dissection of the sacral promontory, a demanding procedure especially in obese patients.

Outcomes after hysteroscopic treatment of symptomatic isthmoceles and/or in women with secondary infertility

Elena Cabezas^{1,2}, Javier Sancho Saúco^{1,2}, Enrique Moratalla Bartolomé^{1,2}, Irene López Carrasco², Nerea Montero Pastor², María Miró Matos²

¹University Hospital Ramón y Cajal, Gynecology, Madrid, Spain

²University Hospital HM Montepríncipe, Gynecology, Madrid, Spain

Background

The aim of this study was to assess the effectiveness of hysteroscopic surgical treatment of isthmoceles in women with associated symptoms or reporting pregnancy in patients with secondary infertility.

Methods

A prospective case series study was performed. This study included all women with ultrasonographic diagnosis of isthmocele, with minimum myometrial thickness of 3 mm (if it was less than 3 mm they were not included in the study because the correction in this case was performed by laparoscopy) and symptoms (abnormal uterine bleeding or pelvic pain) or secondary sterility, who had undergone hysteroscopic correction between June 2014 and December 2021 (7.5 years) in our hospital.

Results

Seventy-one women underwent hysteroscopy for correction of symptomatic isthmoceles or for secondary infertility. Mean age of the women was 40.07 (31-51) years. All women had at least one previous caesarean section (mean 1.61 (range 1-4). Mean time between the last caesarean section and isthmocele correction was 4.69 (1-10) years.

Regarding the clinic, the majority of patients (86.96%) presented abnormal uterine bleeding, mainly inter or postmenstrual spotting. The remaining patients presented pelvic pain, mainly dysmenorrhea (21.74%) and secondary sterility (26.09%). 23 patients had reproductive desire.

The ultrasound evaluation of the isthmoceles was performed with a 2D ultrasound machine. 31.81 % of the patients presented a retroverted uterus. Mean myometrial thickness measured by ultrasound was 4 (3-7) mm.

15 patients underwent a polypectomy simultaneously with the correction, 3 patients a myomectomy and another 5 patients a dysmorphic uterus correction. There were no intraoperative complications, and no complications or adverse effects were reported after hysteroscopic correction.

Follow-up was performed one month and two months after surgery. There was complete resolution of symptoms in 59 patients (83.1%). Spotting persisted in 9 patients (in less quantity in most cases) and pelvic pain persisted in the remaining 3 patients.

Secondary infertility was assessed one year after surgical isthmoplasty. Of the 23 patients with reproductive desire, 14 completed the first year of follow up and 7 (50 %) of them reported pregnancy after treatment. Among the patients who reported pregnancy, 6 had a full-term pregnancy (5 caesarean section and 1 vaginal delivery) and 1 presented a miscarriage.

Conclusions

Hysteroscopic correction of isthmoceles may constitute a safe and effective technique for resolving symptoms in patients with abnormal uterine bleeding or pelvic pain. In patients with secondary infertility and isthmocele, it could improve the possibility of future successful pregnancy, although longer-term follow-up and further studies are needed to assess this indication.

Laparoscopic Davydov versus Vecchietti neovaginoplasty in women with Mayer-Rokitansky-Küster-Hauser syndrome; a systematic review and meta-analysis

Lisanne Martens¹, Linde Tannenbaum¹, Sander Van Kuijk², Kim Notten¹, Kirsten Kluivers¹

*¹Radboud university medical center- Radboud Institute for Health Sciences,
Department of Obstetrics and Gynecology, Nijmegen, The Netherlands*

²Maastricht University Medical Centre+,

Department of Clinical Epidemiology and Medical Technology Assessment, Maastricht, The Netherlands

Background

To summarize available evidence on the laparoscopic Davydov and Vecchietti method and to compare these techniques with focus on operative time, neovaginal length, and sexual function.

Methods

A systematic electronic search up till August 2020 using PubMed and Embase is performed. All published clinical studies concerning the laparoscopic Davydov and laparoscopic Vecchietti procedure as a surgical technique to create a neovagina in women with MRKH syndrome are obtained. The PRISMA guidelines are followed. The following data are extracted: operative time, hospital stay, major early complications (within 3 months post-surgery), dilation therapy, neovaginal length, vaginal discharge, vaginal stenosis, time to sexual activity, sexual satisfaction, penetrative sexual activity, dyspareunia, total score of the Female Sexual Function Index (FSFI), and duration of follow-up. The Newcastle Ottawa Scale is used to assess the quality of articles.

Results

A total of 1153 articles are identified of which 30 studies are included in this systematic review. Of these, 11 studies (333 patients) are related to the Davydov method, 18 studies (817 patients) to the Vecchietti method and 1 article concerns both. Eighteen studies are included in the meta-analyses. The operative time of the Davydov method is 126 minutes (95%CI 106-146) compared to 46 minutes (95%CI 30-62) of the Vecchietti method. The mean neovaginal length 12 months after the Davydov method is 8.3 cm (95%CI 8.0-8.7), versus 8.9 cm (95%CI 6.2-11.5) after the Vecchietti method. The mean FSFI score after the Davydov method is 30.45 (95%CI 27.61-33.28), compared to 27.31 (95%CI 23.89-30.73) after the Vecchietti method.

Conclusions

The operative time of the Davydov method is significantly longer. The operations yield comparable complication rates, neovaginal lengths, and sexual function. The mean FSFI scores indicate no sexual dysfunction in either group. Clinical heterogeneity and variety in quality of the studies hampers the meta-analyses.

Laparoscopic Retrieval of an Intrauterine Contraceptive Device, Embedded in the Rectosigmoid Epiploic Fat - a Case Presentation and Literature Review

Mihaela Gotseva¹, Amelie Benbara¹

¹Hopital Jean Verdier, Obstetrics and Gynaecology, Paris, France

Background

Intrauterine devices (IUDs) are one of the most popular long-term reversible contraceptive methods. They provide reliable contraception and in the case of hormone containing IUDs, can be used for the treatment of pelvic pain and heavy menstrual bleeding. Uterine perforation at insertion is a rare complication, which can potentially have serious implications and requires surgical retrieval by a laparoscopy or laparotomy. This poster aims to demonstrate the surgical difficulties which can be encountered in the process of IUD retrieval.

Methods

This is a case presentation of the laparoscopic retrieval of a copper IUD, embedded in the in the space within the rectosigmoid epiploic fat and adherent to the left adnexa and a literature review of the technical difficulties encountered in similar cases.

Results

A 33-year-old patient who had a copper IUD inserted 8 years ago. At follow-up it was thought that the IUD was expelled, but no imaging was performed to confirm that. 7 years after insertion, the patient presented with left iliac fossa pain and at imaging, the IUD was visualized in proximity to the left adnexa. The imaging report specified that it was not in contact with bowel loops. At laparoscopy, we discovered that the IUD was almost entirely embedded in the rectosigmoid epiploic fat, adherent to the left adnexa and was successfully retrieved laparoscopically after dissection with the help of a general surgeon colleague and without any surgical complications.

Conclusions

Our case and literature review demonstrate that it is important to retrieve even asymptomatic IUDs due to the potential late complications, such as bowel perforation, bowel infarction, volvulus, etc. Conversion to laparotomy in the process of retrieval is also still relatively common. It is wise to do IUD retrieval operations with the availability of a gynaecologist trained in advanced laparoscopic surgery and in a centre where a general surgeon is readily available. Patients should be counselled in detail about the potentially serious risks related to the surgery, irrespective of the imaging findings and the delay between IUD insertion and surgery.

5 years results of a novel simple laparoscopic needle retractor - Ney-Lift

Joerg Neymeyer¹, Diana-Elena Moldovan¹, Sarah Weinberger¹, Thorsten Schlomm¹

¹Medical University Charité - Berlin, Pelvic Floor Competence Center Charité PF3C, Berlin, Germany

Background

When operating laparoscopically the surgeon often encounters difficulties in exposing the surgical field adequately. Hereby we want to present an innovative technique which facilitates the necessary exposure drastically, without using additional trocars. It is the Ney Lift.

Methods

From 01.2011 to 02.2021 we performed laparoscopic sacropexy by using 4 trocars (1 optic + 3 working trocars) till 09.2015 by using 3 trocars (1 optic + 2 working trocars + Ney-Lift) in 866 patients: 699 were performed laparoscopically with a reusable helical tunnelling device, 9 were operated with the DaVinci using standard instruments and 158 were performed laparoscopically using standard instruments. We place the port in a usual manner (10 mm umbilical camera port and two 5 mm lateral trocars). Equipment needed: 10cm hollow needle - 3x0 monofil suture - cotton pieps. Organs can now be easily retracted by slinging.

Results

The mean treatment time was 60min (45-75 min) by using NEY-LIFT and only 3 Trocars. Learning curve for usage the NEY-Lift was 2. The average operation time using NEY-Lift was significantly reduced by 15min, although one trocar was used less. Due to the better visibility through the Ney-Lift and the lower number of trocars, the assistant only had to operate the camera.

Conclusions

The Ney Lift is a novel and simple way of exposing the operating site appropriately without using further trocars. It is a step towards performing an even more minimally invasive and atraumatic laparoscopic surgery and reduce the treatment-time.

Pneumocystoscopy - an alternative to conventional cystoscopy?

Joerg Neymeyer¹, Diana-Elena Moldovan¹, Sarah Weinberger¹, Thorsten Schlomm¹

¹Medical University Charité - Berlin, Pelvic Floor Competence Center Charité PF3C, Berlin, Germany

Background

Cystoscopy is an established standard urological procedure. Occasionally, however infected putrid bladder, macrohaematuria or fistulae can lead to limited visibility. By means of pneumocystoscopy (PnCysto), these interfering factors are no longer a visual limiting the diagnosis. Pneumocystoscopy should be used as a simple procedure with available instruments in the outpatient setting, practice, and clinic.

Methods

296 patients were diagnosed and operated on by pneumocystoscopy between 01/2016 - 02/2022.operated. "Pneumocystoscopy" is a cystoscopy using only gas (CO₂ or air) instead of liquid.or air) instead of liquid. Insufflation takes place via the luer lock connection of the cystoscope. An existing carbon dioxide insufflator at 15-18 cm H₂O was used both in the operating theatre and for outpatient use.and for outpatient use only one syringe with a luer lock connection was used for insufflation. The syringe proved to be syringe proved to be advantageous, as not only is insufflation possible, but suction can also be actively performed without having to change it. Pneumocystoscopy not only improves diagnostics, but also surgical procedures such as transurethral surgery (TUS-NOTES - fistula repair, partial bladder resection,ostium resection, diverticulum ablation) and stent placement can be performed in a more optimised manner.

Results

Compared to classical liquid-based cystoscopy, there is no difference with pneumocystoscopy. Pneumocystoscopy, there is no difference in the performance of cystoscopy in diagnostics or in the operative use. However, pneumocystoscopy is superior in the assessment of the bladder. Interfering factors such as cloudy or restricted vision due to puss or bleeding could be reduced by pneumocystoscopy and thus the mean operating time (time saving pneumocystoscopy vs. cystoscopy: 2 -10 min) is lower.

Conclusions

The outpatient and operative use of pneumocystoscopy as a simple method for diagnosis and / for diagnosis and therapy proved to be advantageous. Existing instruments can be used. There were no additional costs. Prospective studies will follow.

Designing an Endometriosis Specific Surgical Companion

Tamica Lawrence¹, Rebecca McMurray¹, Karolina Afors¹

¹The Whittington Health Trust, Obstetrics & Gynaecology, London, United Kingdom

Background

Protocols for enhanced recovery early discharge and virtual follow-up to decrease costs have become even more prevalent in the post-COVID era. This means the health behaviour of patients has an important impact on their outcomes after surgery. Several surgical recovery apps exist, but an app specifically designed for patients undergoing surgery for endometriosis could be a vital pre- and post-operative companion for patients and clinicians. The aim of this study is to elucidate the pre- and post-operative needs of both patients and clinicians and integrate this into a mobile application to optimize short- and long-term success of surgical intervention specifically for endometriosis.

Methods

In this qualitative study the participants, patients underwent a short semi structured interview in person and their answers were immediately transcribed. The patient interviews focused on how a mobile application could improve upon the pre- and post-operative experience in conjunction with routine care. Clinicians answered a short free text questionnaire. The clinician interviews were focused on how the mobile application could increase collaboration with these surgical patients to improve the surgical journey of patients and improve outcomes. Reflexive thematic analysis was used to identify themes from the data.

Results

Through these interviews we derived design considerations for development of a post operative digital companion. Key design qualities included: meeting basic accessibility, usability, security, and data compliance; patient centred care; facilitation for improved communication; support for personalised management plans. Lastly, long-term lifestyle advice and preventative measures were also considered important to patients.

Conclusions

The potential use of mobile health apps as adjuncts to traditional medicine is impressive. A mobile app could be used to advise patients when to seek medical advice, as well as collect data on their recovery process and quality of life pre- and post-operatively. Through our collaboration with Syrona Health, an established class 1 medical device, we have incorporated these design considerations into a mobile application. We present use of this app as a digital surgical companion tool to those users undergoing surgical procedures for the management of chronic disease such as endometriosis.

Adolescent adenomyosis. An emerging challenging condition

Sayed Elakhras¹, Vasilios Tanos², Bassem Sobhy³, Mohamed Salama⁴

¹*Oram Hospital, Dept. of Minimally Invasive Gynaecology, Cairo, Egypt*

²*Medical School of Nicosia University, Obstetrics and Gynaecology, Nicosia, Cyprus*

³*Al Galaa Teaching Hospital, Department of Obstetrics and Gynaecology, Cairo, Egypt*

⁴*Ain Shams University, Department of Obstetrics and Gynaecology, Cairo, Egypt*

Background

Adenomyosis is closely linked to endometriosis. It has traditionally been encountered in relatively older women, especially those with higher parity, leading to chronic pelvic pain and irregular vaginal bleeding.

More recently, we have been coming across this condition in younger women and even in adolescent girls.

We hereby present our experience with this population

Methods

We report our experience, in a tertiary comprehensive endometriosis centre, with a rising number of cases in the adolescent and younger age groups suffering from adenomyosis.

The various clinical presentations, radiological findings and lines of management applied to this population are presented and discussed, along with the response rates for these different approaches.

Results

The various responses to the discussed lines of management are presented, in terms of symptomatic pain relief, and improvement of abnormal bleeding patterns.

Among the various treatment lines discussed are medical therapy, various laparoscopic and hysteroscopic techniques, and radiological interventions (such as HIFU; High frequency focused ultrasonic waves).

Conclusions

Adenomyosis is becoming more frequently encountered in populations younger than traditionally reported.

Adolescents are a very particular group among these patients as they pose special diagnostic and management challenges.

A spectrum of interventions could be used in such cases, with different success rates.

Laparoscopic combined hypogastric neural plexus block and uterosacral nerve block for patients with chronic idiopathic pelvic pain

Sayed Elakhras¹, Ramy Ahmed Mahrose², Mohamed Salama³

¹*Omam Hospital, Dept. of Minimally Invasive Gynaecology, Cairo, Egypt*

²*Ain Shams University, Department of anaesthesia- intensive care and pain management, Cairo, Egypt*

³*Ain Shams University, Department of Obstetrics and Gynaecology, Cairo, Egypt*

Background

Chronic idiopathic pelvic pain is a commonly encountered condition with a major impact on women's health-related quality of life. It is estimated that this condition cost the NHS in the UK about 158 million pounds alone.

Various therapeutic approaches have been tried to address this condition, with variable rates of success, usually with less than satisfactory outcomes.

The aetiology of Chronic idiopathic pelvic pain is unclear, hence, specific diagnostic and therapeutic measure fail to control it.

Pelvic innervation is mainly carried through the superior hypogastric plexus, making it a suitable target for innovative therapeutic approaches.

Methods

We hereby present a novel approach for the management of Chronic idiopathic pelvic pain, which constitutes a combined nerve blockade of the superior hypogastric plexus and the uterosacral nerve.

This is accomplished through a laparoscopic approach, where the superior hypogastric plexus is attacked at its retroperitoneal position at the level of the sacral promontory. A combination of Bupivacaine and betamethasone are injected at this site to cause the desired nerve blockade.

The short- and intermediate-term results in terms of pain relief are followed up for up to 6 months post-procedure. Additionally, the potential side effects, such as urinary and excretory functions are assessed.

Results

Combined laparoscopic superior hypogastric plexus and uterosacral nerve block is an effective therapeutic intervention for cases with Chronic idiopathic pelvic pain.

The side effect profile of this intervention is minor on the short and intermediate terms.

Conclusions

Combined laparoscopic superior hypogastric plexus and uterosacral nerve block is an effective therapeutic intervention, with a very good safety profile for cases with Chronic idiopathic pelvic pain

'Goal Attainment Scaling' as an outcome measurement for conservative and surgical treatments for menorrhagia: a pilot study

Peggy Geomini¹, Jacques Maas¹, Ashley Moonen¹, Marlies Bongers¹

¹Máxima Medisch Centrum, Gynaecology, Veldhoven, The Netherlands

Background

This research aims to implement Goal Attainment Scaling (GAS) as an evaluation method for menorrhagia in clinical practice. The attempt is to personalize treatments for menorrhagia since patients may pursue different outcomes than their health care provider.

Methods

This pilot study was performed between October 2021 and May 2022 in the Máxima Medical Centre in the Netherlands. Women diagnosed with menorrhagia, receiving treatment, formulated, and evaluated treatment goals using a 5-point GAS, ranging from -2 to +2. The baseline level of functioning is scored as -2. Level -1 is a partially achieved goal. Level 0 means that the expected goal is achieved. Level +1 means the achieved level is more than expected and level +2 is the best possible outcome. These women also filled in the Pictorial Blood Loss Assessment Chart (PBAC), the Menorrhagia Multi-Attribute Scale (MMAS) and the EuroQol 5D (EQ-5D) including a Visual Analog Scale (VAS). For analysis, the population was divided into subgroups based on the achieved GAS score. The primary outcome was the difference in blood loss after three months between the subgroups, measured with a PBAC score. The secondary outcome was the difference in quality of life between the subgroups, measured with the MMAS and EQ-5D including a VAS.

Results

133 women were eligible for this study, of whom 60 women initially decided to participate. The data of 44 women were used for analysis, a Kruskal-Wallis test was used to establish statistical significance. At three months, the mean PBAC scores for the groups with a GAS level of -2, -1, 0, +1 and +2 were 940 (SD 637); 235 (SD 321); 100 (SD 58); 33 (SD 47) and 5 (SD 13) respectively. These PBAC scores were significantly different ($H(4) = 22.68, p = 0.000$), as were the mean MMAS scores (56; 79; 77; 93 and 97 respectively, $H(4) = 17.34, p = 0.002$). The mean EQ-5D and mean VAS scores for the groups with an achieved GAS score of -2, -1, 0, +1 and +2 were 0.818 and 58; 0.820 and 71; 0.802 and 74; 0.911 and 84; 0.916 and 85 respectively. The EQ-5D scores did not differ significantly, $H(4) = 5.80, p = 0.214$. The difference in VAS scores between the GAS groups was statistically significant, $H(4) = 10.54, p = 0.032$.

Conclusions

Three months after treatment, a higher GAS score is associated with less blood loss, a higher menorrhagia-specific quality of life and a lower VAS score. This provides evidence that GAS may be appropriate as an evaluation method for women receiving treatment for menorrhagia.

Subserous myoma as indicator of the presence of pelvic endometriosis

Sayed Elakhras¹, Mohamed Nageh², Mohamed Salama³

¹*Omam Hospital, Dept. of Minimally Invasive Gynaecology, Cairo, Egypt*

²*Omam Hospital, Department of Obstetrics and Gynaecology, Cairo, Egypt*

³*Ain Shams University, Department of Obstetrics and Gynaecology, Cairo, Egypt*

Background

Uterine fibroids and endometriosis are common diseases affecting ladies in the reproductive age group. Both are potential causes of infertility, chronic pelvic pain, and abnormal uterine bleeding.

From the etiological point of view, both conditions are related to hyper-estrogenic states, that promote the growth and development of such conditions.

Additionally, genetic, and environmental factors responsible for the development of these 2 pathologies are closely related.

Methods

We hereby report a series of cases where the presence of subserous myomata, despite being of a small size, was indicative of the presence of pelvic endometriosis, sometimes reaching into deep infiltrating endometriosis.

Results

There seems to be a strong correlation between the presence of subserous myomata and the presence of pelvic endometriosis, as shown in this case series.

It is note-worthy to consider the presence of such myomata a red flag for the association with endometriosis. We have likened this to the "bluestreak cleaner wrasse" fish, that accompany sharks in the oceans.

Conclusions

The presence of subserous myomata on radiological investigation, although that they might not have a direct contribution to the pelvic pathology, when small-sized, may be indicative of the presence of a more serious pathology, namely pelvic endometriosis.

In such cases, it is better to investigate and search for endometriosis, especially in cases where medical treatment or assisted reproductive techniques have failed.

Impact of COVID-19 pandemic on surgical management of endometrial cancer

Lisandra Mendonça¹, Dora Antunes^{2,3}, Ângela Melo¹, Sónia Gonçalves¹, António Pipa¹, Nuno Nogueira Martins¹

¹Tondela and Viseu Hospital Centre, Department of Gynecology, Viseu, Portugal

²Coimbra Hospital and University Centre, Department of Gynecology, Coimbra, Portugal

³University of Coimbra, Faculty of Medicine, Coimbra, Portugal

Background

Endometrial cancer is a common gynaecological malignancy. According to the literature, COVID-19 pandemic affected gynaecological cancer management worldwide, including surgical procedures. In Portugal, significant COVID-19 restrictions affecting healthcare assistance occurred in 2020 considering institutional resources management and disease control. In most of the hospitals, only urgent surgeries were performed, including those associated with malignant diseases. In 2021, the reduction of COVID-19 restrictions allowed a healthcare recovery. Therefore, the aim of this study is to evaluate the impact of COVID-19 pandemic on endometrial cancer surgical management, including surgical approach, time of hospitalization and postoperative outcomes.

Methods

Retrospective and comparative analysis including 104 women with the diagnosis of endometrial cancer that were submitted to a staging surgery in our department between January 2019 and December 2021. We considered three groups: 2019–pre-pandemic (group 1), 2020–pandemic period with high restrictions (group 2) and 2021–pandemic recovery (group 3). Demographic features, tumour characteristics and clinical/surgical outcomes were collected and compared between groups. Data were analysed using SPSS[®]v26.0 and a *p-value*<0.05 was considered statistically significant.

Results

We included 29 cases in group 1, 35 cases in group 2 and 40 cases in group 3. There weren't statistical differences between groups related to age of diagnosis, menopausal status, or tumour staging (*p*=n.s.). However, the histological types differed between groups, with an emphasis for the carcinosarcoma in 2019 (10%), clear cells type in 2020 (9%) and serous type in 2021 (10%) (*p*<0.05). Concerning the surgical outcomes, a statistically significant increase in laparoscopic approaches was observed in groups 2 and 3, mainly in the last one (36%vs 64% and 24%vs 76% *p*<0.05). Moreover, laparoscopic sentinel lymph node mapping was also more frequent in group 3 comparing to groups 1 and 2 (11%vs 100% and 15%vs 85%, *p*<0.05). A significant reduction in the number of hospitalization days was also observed between group 1 and 3 (10±9 vs 6±4 days, *p*<0.05). No major differences were found in postoperative complications between groups (*p*=n.s.).

Conclusions

In spite of the impact of COVID-19 pandemic on healthcare assistance, our results revealed that it didn't have interference on endometrial cancer diagnosis, what could be explained by the fact that most of the patients presented with postmenopausal abnormal uterine bleeding that motivated the prompt demand for medical care and doesn't depend on a screening detection. On the other hand, there were some differences between recovery and pandemic period regarding surgical management with a higher rate of laparoscopic surgeries, sentinel lymph node mapping and a short hospital stay in 2021. This could be justified by the attempt to return to normality after COVID-19 restrictions of 2020, associated with a higher experience in laparoscopy and the benefit in reducing hospital stay in order to avoid nosocomial infections due to COVID-19.

Hysteroscopic and ultrasound evaluation of a novel degradable polymer film for the prevention of intrauterine adhesion formation after hysteroscopic surgery

Alessandra Gallo¹, Gabriele Saccone², Elena Cancelliere¹, Maria Chiara De Angelis¹, Jose Carugno³, Brunella Zizolfi¹

¹*University Federico II, Public Health, Naples, Italy*

²*University Federico II, Neuroscience, Naples, Italy*

³*University of Miami,*

Obstetrics- Gynecology and Reproductive Sciences- Minimally Invasive Gynecology Division, Miami, USA

Background

To assess the behavior, from insertion to degradation, of a novel triblock degradable polymeric film (DPF), Womed Leaf[®], designed specifically for intrauterine use as an adhesion prevention barrier device, and to collect information on its effectiveness in preventing intra-uterine adhesions (IUAs) after hysteroscopic surgery.

Methods

Women scheduled to undergo hysteroscopic myomectomy, metroplasty or adhesiolysis were enrolled in a prospective observational pilot study, conducted from March to July 2021 at "Federico II" University Hospital in Naples, Italy. The operative procedures were performed under general anesthesia with 5 Fr bipolar electrode, 15 Fr bipolar miniresectoscope or 27 Fr bipolar resectoscope with a 4 mm loop, depending on the procedure. At the end of the procedure the DPF was inserted through the cervix and released into the uterine cavity using a 5mm flexible inserter. Ultrasonographic and hysteroscopic evaluation were performed immediately after the DPF insertion and at different follow-up intervals (2 hours, 2-5 days, and 6 weeks). Main outcome was to assess the behavior of the DPF, from insertion to degradation, by ultrasound and hysteroscopy. Secondary outcomes included ease of DPF insertion, the adverse events due to film insertion, and the presence of IUAs at 6 weeks.

Results

15 patients with a mean age of 37 ± 8 were enrolled. 7 myomectomies, 7 metroplasties and 1 hysteroscopic adhesiolysis were performed. Based on both ultrasound and hysteroscopic assessments, the undeployed uterine film was present in all patients (15/15) immediately after surgery and by 2 hours after surgery. On the third follow-up (days 2-5), the DPF was still present in 7/15 (46.6%) participants, either in its entirety or partially hydrolysed in 5 and 2 women respectively. In 8/15 participants the device was not visible. One participant reported the film being spontaneously expelled 4 hours after its insertion. At 6 weeks follow-up, the film was absent in all women, and none had IUAs. No adverse events were reported.

Conclusions

The solid degradable polymeric film, Women Leaf, is a promising, easy to apply and well-tolerated novel option for the prevention of intrauterine adhesion formation after hysteroscopic surgery.

Vaginally Assisted Minimally Invasive Manchette (VAMM): a novel approach to the no-touch isolation techniques for early stage cervical cancer

Andrea Rosati¹, Matteo Pavone¹, Nicolò Bizzarri¹, Virginia Vargiu², Giovanni Scambia¹, Salvatore Gueli Alletti³

¹Fondazione Policlinico Universitario A. Gemelli- IRCCS- Roma- Italy.,

Dipartimento per la salute della Donna e del Bambino e della Salute Pubblica, Rome, Italy

²Gemelli Molise Spa, Dipartimento di Oncologia, Campobasso, Italy

³Ospedale Buccheri La Ferla- Fatebenefratelli, UOC Ginecologica e Ostetricia- Dipartimento Materno-Infantile, Palermo, Italy

Background

With the publication of the results from the LACC trial, a debate was opened on the surgical management of early-stage cervical cancer that still struggles to find a shared conclusion.

In the wake of LACC trial results, some articles suggested that the association of MIS with the “no touch isolation technique”, including vaginal protective manoeuvres, could potentially be the key to realign the survival outcomes with those of the laparotomic surgery.

The present article describes the feasibility and surgical outcomes of a novel technique to perform a Vaginally Assisted Minimally Invasive Manchette (VAMM).

Methods

This pilot study was conducted between May 2019 and December 2020. 12 consecutive patients were enrolled in the study and underwent to radical hysterectomy plus VAMM at the Division of Gynecologic Oncology, “Fondazione Policlinico Universitario A. Gemelli” IRCCS of Rome. Inclusion criteria were: age 18-80 years, no absolute contraindications to laparoscopy, body mass index (BMI) ≤ 35 , no history of major abdominal surgery, nor of previous pelvic radiation therapy, cervical tumour dimension less than 2 cm.

Results

We reported a median operative time of 229.5 min while the median time to perform VAMM was of 14.2 min. The median EBL was 50 ml with a median hospital stay of 3 days. No blood transfusions were needed. No intra and post-operative VAMM-related complications were reported.

Conclusions

In the post-LACC trial era the “no touch isolation technique” should be considered one of the keystones to reshape the role of MIS in the treatment of early-stage cervical cancer. VAMM is demonstrated to be a technically feasible and a safe alternative to the “classic vaginal manchette”. Further studies exploring this new technique in a larger set of patients are necessary to confirm the promising results of our single-institution series.

Tubal ligation: are residents a risk factor?

Patrícia Pereira Amara¹, Sara Sardinha Abrantes¹, Rita Palmar Ribeiro², Mariana Souto Miranda¹, Elsa Landim¹, José Silva Pereira¹

¹Hospital Professor Doutor Fernando Fonseca- E.P.E., Gynecology, Lisbon, Portugal

²Hospital do Espírito Santo de Évora, Gynecology, Évora, Portugal

Background

The only reason to perform a tubal ligation is the patient's desire for permanent contraception and the gold standard is to do it by laparoscopy. This procedure is very safe, with an overall rate of intraoperative and postoperative complications of 0.9 per 100 women (rate of major medical complications is reported to be 0.1 % and conversion to laparotomy in 0.15 % of the cases). After training on surgical simulators, tubal ligation is one of the first procedures in laparoscopy performed during residency in order to gain more experience for more complex procedures.

Methods

Retrospective descriptive study based on analysis of tubal ligation procedures performed between May 2019 and May 2022 (3 years) in Hospital Professor Doutor Fernando Fonseca, Lisbon, Portugal. All the procedures were done by Bipolar electrosurgery, and cut, and tubal ligations performed in association with other surgeries were excluded. The analysed variables included sociodemographic characteristics of the populations, surgical procedure and its complications. Statistical analysis was conducted on Microsoft Excel©.

Results

In total, there were 94 tubal ligations of which 43 were performed by residents and 52 performed by consultants. The women had an average of 37.2 years (16-47) and 3.25 past pregnancies including abortions and ectopic pregnancies, although 4 were nulliparous.

The resident's tubal ligation lasted an average of 31 minutes (9-75) and consultant's lasted for 28 minutes (11-127), which was not statistically significant (p-value 0.31). In the resident's group there were 2 cases of failure to create the pneumoperitoneum with the Veress needle. In the consultant's group there was a cervical laceration with Pozzi forceps, 1 case of a functional ovarian cyst rupture and 1 case of mesosalpyng laceration with salpingectomy. There were no major complications registered and no conversion to laparotomy.

Conclusions

Although residents took, on average, more time to perform a tubal ligation, that was not statistically significant from the consultant's group (probably because the more complex cases were done by the consultants, which introduced a bias to this analysis). Complications were similar in both groups. Nevertheless, surgical simulators are very important to help residents to train outside the operating rooms, focusing on patient safety and mitigating medical error and to acquire the necessary skills to perform laparoscopic surgery.

Establishing 'Ectopic Live': A Real-Time Ectopic Pregnancy Database

Ora Jesner¹, Ryan Peggs², Funlayo Odejinmi¹

¹Whipps Cross Hospital, Gynaecology, London, United Kingdom

²Homerton Hospital, Foundation training doctor, London, United Kingdom

Background

Whipps Cross Hospital has a 20-year tradition of auditing ectopic pregnancy data: examining the clinical presentations of ectopic pregnancies and whether their management follows best practice. Historically, this data was always collected retrospectively and presented annually. The Cumberledge report highlighted the need for comprehensive databases in the interest of patient safety. This project aimed to initiate, evaluate and adapt a continuous database to replace previous retrospective paper data collection. This was an exciting opportunity to improve accuracy and quality of the data and facilitate real-time evaluation of the performance of the unit.

Methods

'Ectopic Live' was created as a live database on the Trust website. It was the collective responsibility of the on-call gynaecology teams to update the database. All patients who underwent surgical management for a suspected or confirmed ectopic pregnancy were included. A user's survey and a snapshot of the data collected was presented 9 months after initiation. QI methodology was followed to make incremental changes and find solutions for issues as they arose.

Results

The snap-shot audit of surgically managed ectopic pregnancies revealed 96% data capture when compared with the emergency theatre log. The user's survey demonstrated 92% agreed the database was user-friendly with main obstacles to completion being time during busy shifts and IT access. Over half said it took <5 minutes to complete. 86% of respondents would recommend it if they moved to another unit. Using PDSA cycles the functionality of the database increased, subsequently incorporating all ectopic pregnancies managed both surgically and non-surgically.

Conclusions

Ectopic Live has been incorporated into the on-call Gynaecology practice with meaningful improvement locally. The success of this database, with improved data capture enabling observations on current unit activity, is evident in that it has been emulated across the department and adopted at other units.

Live birth rate following laparoscopic endometrioma stripping surgery

Vera Kovacevic¹, Luka Anđelić², Ana Mitrović Jovanović³

¹*Gynecologist, General Hospital and Health Center, Subotica, Serbia*

²*Gynecologist, General Hospital, Subotica, Serbia*

³*Clinics For Gynaecology and Obstetrics "Narodni Front", Gynaecology and Obstetrics, Belgrade, Serbia*

Background

The first description of endometriosis was given by Carl Von Rokitansky back in 1860 but even today 160 years later endometriosis remains an enigma. Laparoscopic cystectomy of endometrioma with the use of bipolar current for haemostasis leads to damage to the ovarian reserve in women with endometrioma. Fertility of women is determined by ovarian reserve. AMH is a marker of ovarian reserve.

Methods

In this prospective cohort study (2013-2020) we present the rate of live birth after laparoscopic endometrioma stripping surgery. Endoscopy unit of a general hospital. The serum anti-mullerian hormone (AMH) concentration was assessed before and at 6 and 12 months after the surgery. Patients interested in pregnancy who did not become pregnant in the previous period were followed on an outpatient basis after the operation. The patients were presented with the possibility of including in IVF as well as spontaneous conception. Study included fifty-four patients with unilateral (n= 37) and bilateral (n= 17) endometriomas ≥ 4 cm. The primary outcome was the rate of live birth after the laparoscopic endometrioma stripping surgery especially natural conception rate. The second outcome was to identify the main factors associated with the rate of live births after surgery.

Results

In the 31 (57.4%) patients out of 54 who desired pregnancy, we noted satisfactory incidence of live births rate up to 70.96% in 22 patients, 16 patients (51.61%) got pregnant naturally and 6 patients (19.35%) by IVF. In the group of patients who became pregnant and gave birth to a live-born child: ≤ 30 y.o. Were 15 (48.38%), from 31-35 y.o. 5 (16.12%) and ≥ 35 y.o. 2 (6.45%). Women who spontaneously became pregnant and gave birth to a live child: 8 women gave birth to 1 live child; 6 women gave birth to 1 live child twice and 3 women gave birth to 1 live child 3 times. In one of these 22 patients the first pregnancy that results in a live birth occurred by IVF and the other spontaneously two years later. Four women gave birth to one live child by in vitro fertilization, one woman got twins by in vitro fertilization and one woman gave birth to one live child, and two years later by frozen et gave birth to another live child. 22 women out of a total of 31 interested in pregnancy after the operation gave birth to 37 live children.

Conclusions

The age of patient and serum AMH concentration are the main prognostic factors that affect the fertility of women after laparoscopic cystectomy of endometrioma. In women with endometrioma, IVF should be advised as a primary option when there are additional causes of infertility or where there are contraindication for surgery. In patients who have not become pregnant after surgery, we advise IVF.

Artificial intelligence (AI) in obstetrics and gynaecology: are we more intelligent than AI or too ignorant to adopt it?

Rahul Gore¹, Pallavi Gore², Rowan Connell³

¹*Colchester general hospital, Obstetrics and Gynaecology, Colchester, United Kingdom*

²*5GoreConn, Innovations, London, United Kingdom*

³*KIMS hospital, Gynaecology, Maidstone, United Kingdom*

Background

Since Mr Alan Turing invented the computer in 1936, computer programming and artificial intelligence – machine learning (AIML) has evolved at an astonishing pace. Machine learning is a subset of AI, which allows a machine to automatically learn from past data without explicit programming. AI adoption in the various sectors differs dramatically. Maximum adoption is witnessed in the electronics and technology sector (17%), whilst contribution by healthcare is just at an average of 9%.

In healthcare, accelerated entry is seen, mainly in imaging and oncology screening. There are over 1000 PubMed publications about AI in obstetrics and gynaecology (the majority, proofs-of-concept) and these have risen exponentially over the last 2 decades. On one hand, reports such as MedTech Europe (2020), highlight the socio-economic impact of AI in healthcare. We, as clinicians, on the other hand, are still facing unfortunate scenarios resulting from human errors and resultant medico-legal implications.

Methods

Aim: To identify the barriers to the application of AI in obstetrics and gynaecology

Objectives:

1. To systematically review the published literature
2. To conduct a multi-professional pilot survey
3. To identify the barriers to clinical validation of AI in obstetrics and gynaecology

Materials & Methods:

We performed a systemic review of published 1105 articles on PubMed. We decided to choose the topic of 'intrapartum monitoring' for the pilot study as it is such a basic and universal process in obstetrics and gynaecology. After reviewing the literature, questionnaires were sent, and a multi-centre survey was performed.

Results

Our pilot survey had 108 participants from various parts of the world (USA, UK, Europe, UAE, India, China, and Australia). 70% were doctors and others were midwives & nurses. A majority agreed that high-risk patients received monitoring in labour. There was no universal guideline (32.4% followed NICE, 21.3% followed FIGO, 18.5% trust local hospital guidelines, 13.9% followed physiological guidelines and 13.9% followed no guidelines and preferred to trust their individual experience and 'instinct'). 46 % highlighted that human error can happen during interpretation, with the majority as interpersonal human error (44%) as opposed to intra-person (2%). 77% agreed that their patients would prefer safer, smart decision-making tools with universal guidance and 85 % suggested that this tool would protect them from medico-legal litigations. The summary of participants advise is reflected in the conclusions.

Conclusions

1. Human errors, potentially could be avoided with the help of artificial intelligence-enabled clinical decision-making tools.
2. The barriers to the clinical validation of AI are: security of (sensitive) clinical data, technological and financial support at an institutional level, lack of knowledge of the potential of AI and a lack of driving force and/or 'medico-engineering expertise' to initiate and implement such innovative solutions, especially in a rural situation.
3. With appropriate institutional support and governance, these barriers could be addressed efficiently.

How safe is hysteroscopic surgery in a large base endometrial polyp in a 50 year's old peri-menopausal woman?

Asimakis Pappas¹, Christina Ifigeneia Sierrou², Iliana Mamouri¹, Dimitrios Kortesiadis³, Gennaro Castaldo⁴, Georgios Salvanos⁵

¹Iaso Maternity Hospital, Obstetrics and Gynaecology, Marousi, Greece

²Evangelismos General Hospital, Radiology, Athens, Greece

³National Insurance Institute, Obstetrics and Gynaecology, Athens, Greece

⁴Mitera Maternity Hospital, Obstetrics and Gynaecology, Athens, Greece

⁵Elena Maternal Hospital, Obstetrics and Gynaecology, Athens, Greece

Background

A 50-year-old lady was presented with abnormal uterine bleeding (AUB), for the last 6 months, lasting more than 10 days. At the ultrasound scan was discovered a large endometrial polyp measuring 2cm.

The lady expressed some concerns regarding the safety of the procedure, regarding the possibility that may have endometrial cancer and possibly the hysteroscopy would not be safe, since the normal saline could spread malignant cells in her abdominal cavity.

That's why she requested laparoscopic total laparoscopic hysterectomy with bilateral salpingo-oophorectomy.

I reassured her that hysteroscopic procedures had very low complication rates, so are safe procedures with which to evaluate intrauterine pathology. Hysteroscopy allows direct visualization of the uterine and endocervical cavities.

Methods

Technique and procedure of operative hysteroscopy

1. diagnostic hysteroscopy with 5-mm-hysteroscope
2. dilatation of the cervical canal up to Hegar 6
3. insertion of the outer sheath with obturator
4. replacement of the obturator by a hysteroscopescope with matching electrode and 12° angle lenses
5. checking of the connections a) check of the correct distending medium (Ringer's solution or Sorbitol-Mannitol-solution) b) inflow tube for the distending medium—airless and connected with the hysteroscope (irrigate beforehand!)
- c) checking of the pressure and flow selection on the hysteroscope d) outlet tube in collect container
6. opening of the inflow tube and distension of the cavum uteri often an irrigation is primarily necessary because the dilatation of the cervix often causes bleedings in the cavum uteri
7. starting of the surgery as soon as view and distension are sufficient

Results

The polyp with the large base was identified and removed with surgical scissors gradually and sent for histology. No excessive blood loss was identified.

The surgery was successful, and the woman was discharged the same day.

Conclusions

Recent innovations in endoscopic techniques have increased the accessibility of diagnostic and therapeutic procedures. However, hysteroscopic surgery should be performed by an appropriately trained gynaecologist to ensure safe practice and good patient outcome

Cochrane reviews: Endometrial resection and ablation versus hysterectomy for heavy menstrual bleeding (1999). Endometrial destruction techniques for heavy menstrual bleeding. (2005) Endometrial resection/ablation techniques for heavy menstrual bleeding (2009). Pre-operative endometrial thinning agents before endometrial destruction for heavy menstrual bleeding (2003). Local anaesthesia for cervical dilatation and uterine intervention (2009).

Laparoscopic removal of Essure device techniques, perioperative findings and evaluation of patient's satisfaction: A case series

Lina Antoun¹, Paul Smith¹, Indira Buduru¹, T Justin Clark¹

¹Birmingham Women's Hospital, Obstetrics and Gynaecology, Birmingham, United Kingdom

Background

The Essure[®] device was a form of hysteroscopic sterilisation. Increasing concerns about the adverse effects of the Essure[®] device has led to women desiring Essure removal. There are limited reports on technique and effectiveness of surgical removal of Essure[®] device. Our objective is to evaluate perioperative outcomes and symptom resolution in women undergoing Essure[®] removal.

Methods

Single centre cohort study at a large University Teaching Hospital in the UK. Essure[®] devices removal was performed by laparoscopic salpingectomy-cornuectomy with fluoroscopic guidance, or hysterectomy with bilateral salpingectomy. Additional procedures performed because of persistent symptoms were recorded. Symptoms and Quality of life (QoL) were assessed using a standardised questionnaire at least 6 months and up to 10 years following surgical removal of Essure[®] devices

Results

61 women underwent surgical removal of Essure[®] devices of which 52 had the initial Essure[®] sterilisation at the Birmingham Women's Hospital, representing 52/1087 (4.8%) of all women undergoing this hysteroscopic form of sterilisation. Patients who had Essure[®] removal were more likely to be older [Mean 36 vs 42; P = <0.001] and to have had a previous caesarean section [38% vs 18%; P = <0.001]. The main reasons for Essure[®] removal were pelvic pain (49/61, 80%), depression/anxiety (13/61, 21%) and heavy menstrual bleeding (12/61, 20%). Removal of Essure[®] devices was most commonly achieved by laparoscopic bilateral salpingectomy + cornuectomy (44/61, 71%) followed by hysterectomy (17/61, 28%; laparoscopic 14/17 (82%) and open 3/17 (18%). At surgery the Essure[®] devices were correctly sited in 57/61 (93%) patients, whilst a perforated Essure[®] device was seen in 4/61 (7%) cases. 26/61 (43%) patients who underwent removal had concomitant pelvic pathology associated with pelvic pain; 12/26 (46%) had fibrous adhesions, 8/26 (31%) had endometriosis, 4/26 (15%) had adenomyosis, and 2/26 (8%) had endometriosis and adenomyosis. 10 patients underwent a further procedure following Essure[®] removal for ongoing symptoms (1 surgical management of miscarriage following IVF, 8 hysterectomies (6 laparoscopic and 2 abdominal), 1 laparoscopic bilateral oophorectomy). 55/61 women (90%) responded to the post Essure[®] removal symptom survey. Most respondents 42/55 (76%) reported total or some improvement in their quality of life. 42/53 (79%) had total or some improvement in pelvic pain, 9/13 (69%) in mental health, 10/12 (83%) in bleeding, 4/8 (50%) in dyspareunia, 2/2 (100%) in dysmenorrhea and no improvement was reported in hair loss.

Conclusions

The surgical removal of Essure[®] devices appears to improve symptoms thought to be attributable to the presence of these uterine implants in the majority of women. However, patients should be counselled that one in five women may experience persistent or even worsening symptoms following surgical removal of Essure[®] devices. Women choosing uterine sparing salpingectomy-cornuectomy should be aware that one in five of them will ultimately require a hysterectomy to resolve symptoms.

Hysteroscopic resection of submucosal fibroids: a multicentre retrospective cohort study

Lina Antoun¹, Ilias Lipais¹, Nishi Jaiswal¹, T Justin Clark¹

¹Birmingham Women's Hospital, Obstetrics and Gynaecology, Birmingham, United Kingdom

Background

Uterine fibroids are a common concern in women, and submucous fibroids are especially known to cause multiple symptoms like menorrhagia, infertility, recurrent pregnancy loss and pain. Submucous fibroid resection by hysteroscopy is a safe procedure with low morbidity and is a good option to treat women with abnormal uterine bleeding and infertility.

Methods

A multicentre, retrospective cohort study. Data was obtained from BSGE SICS hysteroscopic removal of submucous fibroids database, which is a secure, cloud-based database system for all gynaecological endoscopies across the UK. Complete fibroid resection, and serious perioperative and postoperative complications including major haemorrhage, infection, fluid overload, and visceral injury were recorded

Results

Out of the 205 patients 42 (20%) had the procedure done in outpatient settings. Median age was 38 (range 30-45). The main reason for fibroid resection was heavy menstrual bleeding 120/205 (%) followed by subfertility 66/205 (%) and postmenopausal bleeding 19/205 (%) respectively. 76% of patients had non-opioids pain control before fibroid removal. The distension medium used was isotonic saline. Vaginoscopic technique was used in 68 patients (33%) of patients. 44% of patients had fibroid measuring 2-3 cm, while 34% had smaller fibroid measuring less than 2 cm. 22% had larger fibroid over 4 cm. Majority of the fibroid was located on side walls with 15/206 (7.3%) being cervical. 48% had FIGO grade 1 fibroid while 28% had FIGO grade 2 fibroids. Bipolar device was mostly used for fibroid resection. 12/205 (6%) patients had fluid deficit more than 2500ml, and 7 of them (3%) had to return for a second stage resection. 1 patient had bleeding following fibroid resection requiring hysterectomy.

Conclusions

Hysteroscopic resection appears to be effective in type 1-2 fibroids equally in outpatient's settings and under general anaesthetic. It has a low rate of major complications when performed in specialist centres

Spontaneous distal tubal pregnancy after bilateral laparoscopic sterilization: a case report

Helena Šavc¹, Katja Juvan¹

¹General hospital Slovenj Gradec, Gynecology and obstetrics, Slovenj Gradec, Slovenia

Background

Tubal sterilization is a common method of contraception. It also carries a low risk of incidental pregnancy, which could be ectopic. We report a rare case of ectopic pregnancy in distal tube remnant after laparoscopic bilateral tubal electrocoagulation.

Methods

A 40-year-old woman presented with pregnancy symptoms 7 months after laparoscopic bilateral tubal electrocoagulation. Because of a gestational sac seen in uterine cavity, she was referred as having intrauterine pregnancy after sterilization. She was offered laparoscopic salpingectomy in addition to uterine evacuation. Laparoscopy revealed right distal fallopian tube pregnancy despite obvious disruption of the middle part of the tube. A complete bilateral residual tubal stump excision was performed.

Results

Histopathological assessment confirmed the presence of ectopic pregnancy in right distal tubal stump. The patient recovered well after surgery, with reduction in β -hCG level, and was discharged the next day.

Conclusions

Ectopic pregnancy after tubal sterilization is extremely rare. However, it cannot be completely ruled out, even years after sterilization. New evidence showing ovarian cancer starting in the Fallopian tube has increased the use of salpingectomy as a preferred method of sterilization. Studies have confirmed that the surgical risks with tubal interruption and salpingectomy are likely equivalent. Salpingectomy, unlike tubal occlusion or hysteroscopic sterilization, reduces the risk for future tubal pregnancy including life threatening complications. So, the rationale seems to be in place to change our clinical practice.

Retrospective audit of elective laparoscopic surgery for pelvic pain

Alexandra Bouzouki¹, Shahin Qadri¹, Alvaro Bedoya-Ronga¹

¹SWBH - City Hospital Birmingham, Gynaecology, Birmingham, United Kingdom

Background

To review elective laparoscopic surgery in women presenting with pelvic pain at City Hospital Birmingham.

Methods

Retrospective notes reviews including 1-year pre-COVID from 1/1/2019 to 31/12/2019. Cases were identified by the coding department. We used Excel for data collection and analysis.

Results

A total of 116 cases were identified. The interval from presentation to surgical treatment was 1-21 months with a mean of 8.5 months. 104 women were premenopausal, however 12 of them were postmenopausal presenting with pelvic pain. The mean BMI was 29.5 kg/m². The indication for surgery were chronic pelvic pain in 60%, ovarian cyst in 40%. Pelvic pain was lasting for many years in 45% of women, six months to a year in 28%. 43% had symptom of dysmenorrhoea, and 10% had deep dyspareunia. 91% did not disclose any history of sexually transmitted infection. 14% had bladder symptoms in the form of dysuria, overactive bladder, and lower urinary tract symptoms. 17% had associated bowel symptoms such as constipation, irritable bowel syndrome, bloatedness, dyschezia. 40% of the patients were nulliparous. 22% had a previous abdominal surgery. 46% had a positive ultrasound. 62% did not use analgesics whereas the remaining were using oral analgesia. The operative findings were 39% endometriosis, 24% had cyst or hydrosalpinx, in 19% there were normal findings, 11% had adhesions as cause of pain, and the rest 7% had other findings. The surgeries undertaken were 25% cystectomy, 22% had a diagnostic laparoscopy, 18% had treatment of endometriosis, 15% had salpingectomy or salpingo-oophorectomy, 5% had adhesiolysis and the remaining had deroofing or total laparoscopic hysterectomy with bilateral salpingectomy or salpingo-oophorectomy. Vast majority (97%) had no complication post-operatively. One patient had urinary retention, one had a small haematoma and one had granulation tissue at wound site. Regarding the post-operative treatment 77% of women did not require any further treatment post laparoscopic surgery. The remaining had mainly either combined contraceptive pill or progesterone treatment or Leuprorelin treatment, fertility referral and pain clinic referral. 11% of these women who undergone surgery re-presented with lower abdominal pain or pelvic pain. In summary in one year, we performed 116 laparoscopies for pelvic pain. Majority of women were nulliparous, overweight, and premenopausal with no previous surgery. No patient suffered a major complication intraoperatively or post-operatively. Most of the reasons for pain found were endometriosis mild, moderate, or severe.

Conclusions

Laparoscopy, though minimally invasive surgery can have serious complications, therefore should be kept as last resort. In this unit retrospective audit of elective laparoscopic surgery in women with chronic pelvic pain we found endometriosis as main reason attributed to pain. Negative laparoscopy was more common on those who had normal ultrasound scan. Majority of patients did not require any further treatment post-surgery.

Herlyn-Werner-Wunderlich syndrome: the safe hysteroscopic approach

Waldir Modotti¹, Rafaela Assmann¹, Larissa Marques¹, Camila Romero¹, Daniel Dias², Flavia Bueloni-Dias²

¹*IAM - Atendimento Médico Hospitalar, Gynecology, Assis, Brazil*

²*Universidade Estadual Paulista "Júlio de Mesquita Filho" - Unesp, Gynecology and Obstetrics, Botucatu, Brazil*

Background

To report a Herlyn-Werner-Wunderlich Syndrome case and demonstrate the safety and effectiveness of hysteroscopic approach.

Methods

A case report that demonstrates the Herlyn-Werner-Wunderlich Syndrome diagnosis and treatment. It is a mullerian duct malformation, characterized by uterus didelphys, obstructed hemivagina and ipsilateral renal agenesis. The syndrome varies according to hemivagina morphology. We can find patients with completely obstructed hemivagina (classification 1) or incompletely obstructed hemivagina (classification 2) and due to this variation, the course of clinical manifestations can be different. Classification 1 is divided in two sub-classes: characterized by a blind hemivagina (classification 1.1) or cervicovaginal atresia without communication to contralateral hemiuterus (classification 1.2). Classification 2 also is divided in two sub-classes: characterized by a partial reabsorption of the vaginal septum (classification 2.1) or with communicating to contralateral hemiuterus (classification 2.2). A 11-year-old patient, with abdominal pain and a vagina bowing, had a ultrasonographic pelvis exam demonstrating the uterus didelphys and hematocolpos in left hemiuterus. A pelvis magnetic resonance suggested the obstructed hemivagina. Using a hysteroscopic approach with bipolar Gubinni mini-resectoscope, during the vaginoscopy, a blind hemivagina was confirmed and the vaginal septum was completely excised, which allowed the drainage of hematocolpos.

Results

Safe approach to excise the vaginal septum found in Herlyn-Werner-Wunderlich Syndrome using a hysteroscopic during vaginoscopy. Our patient had abdominal pain relief and recovery before completing twenty-four hours from the treatment.

Conclusions

The vaginoscopy using hysteroscopy allows a safe septum excision. The treatment resulted in hematocolpos improvement and abdominal pain relief.

Intestinal Endometriosis in Disguise as Auto-immune diseases

Mohamed Salama¹, Elakhras Sayed², Vasilios Tanos³, Mohamed Temraz⁴

¹*Ain Shams University, Obstetrics and Gynaecology, Cairo, Egypt*

²*Omam hospital, Minimally Invasive Surgery, Cairo, Egypt*

³*University Of Nicosia Medical School, Obstetrics and Gynecology, Nicosia, Cyprus*

⁴*Omam Hospital, Obstetrics and Genecology, Cairo, Egypt*

Background

Endometriosis can virtually affect any tissue or organ in the human body. Among these is the gastro-intestinal tract.

Intestinal affection by endometriosis involves some misleading characteristics. Firstly, it presents with non-specific symptoms that might include constipation, diarrhea, tenesmus, and even intestinal obstruction. Secondly, the diagnosis, as is with most cases of endometriosis is often well delayed. This ensures that many patients pass through rounds of misdiagnosis and mismanagements until they are finally correctly diagnosed.

Furthermore, aberrant immune mechanisms are believed to be crucial in the development and progress of endometriosis. Thereby, patients with established and correct diagnosis of auto-immune diseases are prone to attack by endometriosis pathology. In this context, we report on our experience with cases diagnosed with Juvenile Rheumatoid Arthritis (JRA), who developed recurrent ascites, who were diagnosed with peritoneal endometriosis.

Methods

We hereby report a series of cases, where were misdiagnosed, and hence, mismanaged for years, as different variants of Inflammatory Bowel Disease (IBD), before they were eventually diagnosed laparoscopically to be cases of intestinal endometriosis.

Similarly, we discuss a few cases in our experience with JRA and recurrent haemorrhagic ascites that was proved by laparoscopy and histopathology to be attributed to endometriosis.

Results

The cases in this reported series were submitted for laparoscopy, where endometriotic lesions were found to involve the bowels, along with other pelvic organs. Histopathological samples were obtained that confirmed this diagnosis and ruled out the previous misdiagnosis of IBD.

Cessation of the anti-inflammatory and disease-modifying medications, along with appropriate management of endometriosis lead to remarkable symptomatic improvements.

Conclusions

Endometriosis can present, in disguise, as different variants of auto-immune diseases. Endometriosis in such cases may be the true underlying pathology, rather than the presumed auto-immune condition, or otherwise, it may further complicate it and confuse management options.

Both gynaecologists and internists dealing with such cases should be aware of these disguised presentations.

Moms on poor reserve

Mohamed Salama¹, Sayed Elakhras², Bassem Sobhy³, Vasilios Tanos⁴

¹Ain Shams University, Obstetrics and Gynaecology, Cairo, Egypt

²Omam hospital, Minimally Invasive Surgery, Cairo, Egypt

³Al Galaa Teaching Hospital, Obstetrics and gynecology, Cairo, Egypt

⁴University of Nicosia Medical School, Obstetrics and Genecology, Nicosia, Cyprus

Background

Markers of ovarian reserve have, and continue to emerge to predict the chances of conception, and predict the reproductive performance of women, especially those at older age or with prior surgical interventions involving the ovaries.

Anti-Mullerian hormone (AMH) is by far the star of these biomarkers, and it has been extensively utilised in patient counselling and in choosing the best assisted reproductive techniques (ART) protocols to be implemented for such cases.

However, low results of this predictive marker has been mis-used to either confine motherhood hopes for some such ladies to exclusive ART conceptions pathways, or in other cases to completely deprive those ladies from their mom-dreams.

Methods

In the presented cases series, we report our extensive experience over many years of practice, and many cases of conception, with ladies with very low AMH levels.

It is notable that most of these ladies were subjected to either failed attempts at ART, or even made hopeless in previous fertility consultations.

These reported cases were subjected to laparoscopy either to address their fertility concerns or their chronic pelvic pains, and consequently, managed to achieve conception, either spontaneously, or with successful ART trials.

Results

Demographic, clinical, and biochemical characteristics of the reported population are presented, along with the findings at laparoscopy.

Successful pregnancy outcomes are also discussed, whether spontaneously achieved, or through ART trials.

Conclusions

Markers of ovarian reserve, especially AMH, should not be solely the determinants of the reproductive projections of hopeful moms-to-be. These should not prohibit them from aiming at spontaneous conception, prevent them from seeking help in minimally invasive surgical techniques, nor should they be used to waive off their dreams altogether.

Spreading of endometrial cells into the peritoneal cavity in laparoscopic hysterectomies for benign indication depending on the time of salpingectomy

Jule Schophaus¹, Bashar Haj Hamoud¹, Gregor Olmes¹, Erich-Franz Solomayer¹, Mariz Kasoha¹, Barbara Linxweiler¹

¹Saarland University Hospital, Clinic for Gynaecology- Obstetrics and Reproductive Medicine, Homburg, Germany

Background

The spreading of endometrial cells is an important issue in laparoscopic surgery. The aim of this study is, to compare separate salpingectomy with en bloc salpingectomy according to the spreading of endometrial cells during laparoscopic hysterectomy.

Methods

This prospective study is a randomized controlled trial and is planned to include 60 patients. 30 patients receive total laparoscopic hysterectomy (TLH) and 30 patients receive supracervical laparoscopic hysterectomy (LASH). To investigate if the time point of salpingectomy affects the spread of endometrial cells into the abdominal cavity, patients will be randomly assigned to one of the following groups:

Group 1: Fallopian tubes are removed separately before uterus removal.

Group 2: Fallopian tubes and uterus are removed en bloc.

Irrigation of Douglas pouch with 10 ml of 0.9 per cent sodium chloride solution are performed at the beginning and end of the operation for cytologic assessment. In the case of morcellation, the second irrigation is taken beforehand. The fluid from the Douglas pouch is prepared and stained according to Papanicolaou, May-Grünwald-Giemsa and immunohistochemically with BerEP4 and calretinin. Then they are analysed for endometrial cells by expert cytologists.

Results

So far, data from 55 patients have been analysed, 25 of whom were randomised to group 1 and 30 to group 2. In the situation of separate salpingectomy (group 1), endometrial cells were spread in 68% of the patients. In those with en bloc removal (group 2), this was the case in 57% of patients.

Conclusions

According to the results to date, there is no significant difference between the timepoint of salpingectomy according to the spreading endometrial cells.

Successful pregnancy after conservative treatment of borderline serous carcinoma of ovary. Report of two cases in district general hospital

Katja Juvan¹, Helena Šavc¹

¹General Hospital Slovenj Gradec, Gynecology and Obstetrics, Slovenj Gradec, Slovenia

Background

Borderline tumours of ovary account for 14 to 15 percent of all primary ovarian neoplasms. Approximately one-third of patients diagnosed with a borderline ovarian tumor are younger than 40 years of age. This makes issues related to fertility preservation of increased importance.

Methods

We present two cases of patients with borderline ovarian tumours that underwent laparoscopic surgery at the Department of Gynecology and Obstetrics in General Hospital Slovenj Gradec, over a 3-year period.

Results

Spontaneous successful pregnancies occurred in both patients. Both of them delivered healthy babies at term, one of them vaginally and the second with urgent caesarean section. The second patient even had another caesarean section, giving birth to healthy twins. Both patients are under careful surveillance and disease free.

Conclusions

Fertility-sparing surgery is the best option to preserve childbearing capacity in young patients with borderline ovarian tumours.

Careful selection of candidates for this kind of treatment is, of course, necessary, and careful follow-up is mandatory to ensure safety of this procedure.

The gynaecological liver!

Sayed Elakhras¹, Hareth Mira², Abdel Ghany Ibrahim³, Nassr Islam³, Mohamed Salama⁴

¹*Omam Hospital, Dept. of Minimally Invasive Gynaecology, Cairo, Egypt*

²*Omam hospital, Obstetrics and Genecology, Cairo, Egypt*

³*omam Hospital, Obstetrics and Gynecology, Cairo, Egypt*

⁴*Ain Shams University, Obstetrics and Gynecology, Cairo, Egypt*

Background

Laparoscopy offers the great advantage of enabling the surgeon to view the full interior of the abdominal cavity. Liver, being the largest organ of the human body, is liable to many pathological and non-pathological conditions that can be viewed through its surface on performing a 360-degree inspection of the peritoneal cavity.

Methods

We present a wide spectrum of finding accidentally discovered during laparoscopy for various gynaecological reasons. Some of these findings were spot diagnosis based on their characteristic morphological features. Others needed biopsies fore histopathological diagnosis.

Some of these lesions were eligible for laparoscopic excision while others necessitated other lines of management.

Results

Among the interesting pathologies encountered in our cases were endometriotic lesions, haemangiomata, fatty liver, hepatic cirrhosis due to viral hepatitis B and C, hydatid cysts, peri-hepatitis due to Gonorrhoea and Chlamydia infections, in addition to other findings.

Conclusions

Although not an essential part of the practice of the minimally invasive gynaecological surgeon, awareness of the appearances and possible laparoscopic managements of different hepatic lesions is an added value in the course of evaluation of the whole peritoneal cavity during various laparoscopic interventions

Prevalence of adenomyosis among patients who undergone postpartum hysterectomy

Simona Martone¹, Lucia Lazzeri¹, Alessandro Arena², Matteo Giorgi¹, Renato Seracchioli², Errico Zupi¹

¹University of Siena, Department of Molecular and Developmental Medicine, Siena, Italy

²University of Bologna,

Division of Gynaecology and Human Reproduction Physiopathology- Department of Medical and Surgical Sciences- IRCCS Azienda Ospedaliero-Universitaria di Bologna- S. Orsola Hospital, Bologna, Italy

Background

To assess the prevalence of adenomyosis among specimen of postpartum hysterectomy and to evaluate the role of adenomyosis in postpartum haemorrhage and in other obstetrical complications.

Methods

This was a multicentre, retrospective, no profit, cohort study that has involved three adenomyosis-endometriosis referral centres (tertiary centres with a specific gynaecological unit).

Data were extracted from hospital databases of participants centres and clinical records. Data on patients that have undergone either peri- or postpartum hysterectomy between 2010 and 2022 have been collected. Presence of adenomyosis has been reported on histopathological examination of uteri specimens. Anomalies of placentation (in terms of location and/or development), together with other obstetrical complications, were also reported.

Results

Seventy-five patients responded to inclusion criteria. Among the uteri specimens, adenomyosis has been reported in twenty-one patients (28%) although in all cases diagnosis has been made only retrospectively with histological examination. Among patients with adenomyosis, ten patients (47%) had other gynaecological conditions (mostly fibromas).

Moreover, eleven patients showed anomalies of placenta praevia spectrum (52%), and nine patients (43%) had other obstetrical complication such as intra uterine growth restriction, preeclampsia, and preterm birth.

Conclusions

Adenomyosis' prevalence among patient who undergone postpartum hysterectomy is higher than general population. Adenomyosis is also related to other obstetrical complications. Further studies are necessary to confirm those data.

Patient satisfaction with pain management in outpatient hysteroscopy

Sule Medha¹, Neeraja Kuruba¹, Nicola Tuck¹

¹Norfolk and Norwich University Hospital NHS trust, Gynaecology, Norfolk, United Kingdom

Background

The objective of this study was to establish patient experience of pain management, to assess patient satisfaction with our outpatient hysteroscopy service and improve quality of patient care.

Outpatient hysteroscopy is considered best practice. Norfolk and Norwich University Hospital is a large university tertiary hospital. We perform around a 1000 cases of Outpatient hysteroscopies every year.

We offer local anaesthetic and Entonox during the procedure. We also request the patients to take analgesia half hour prior to their appointment.

Methods

We studied the notes of 100 consecutive patients attending the outpatient hysteroscopy (OPH) clinic and collected data regarding pre-procedure information leaflet being available to the patient prior to the appointment, whether the option of local anaesthesia and general anaesthesia has been discussed with the patient and whether local anaesthetic and entonox were offered to the patients. The data also captured if the patients were reassured that procedure can be stopped at any time if pain not acceptable.

Results

85% of our patients had received the pre procedure information leaflet and 15% had not due to administrative error. 97% had some form of verbal information. All the 85% who had received the written information had taken the oral analgesia half an hour prior to the appointment, the rest 15% missed out.

97% thought that they were adequately prepared and had realistic perception of pain control during the procedure. 100% of the patients thought that the procedure was verbally well explained in the clinic detailing the possible discomfort.

92% women were given a choice between general anaesthesia and local anaesthesia. 98% were aware to request local anaesthetic and 94% were aware regarding availability of entonox although only 65% chose to have local anaesthetic and 69% chose entonox. 73% thought they tolerated the procedure without any problems and 26% thought they tolerated with acceptable discomfort.

All 100% patients were reassured that if the pain is not acceptable the procedure will be stopped and 100% were satisfied by the care in the OPH clinic. 98% would recommend OPH to GA hysteroscopy, 84% without reservation and 14% with some reservation.

Conclusions

The 2017 Cochrane review shows that there was no consistent good-quality evidence of a clinically meaningful difference in safety or effectiveness between different types of pain relief compared with each other or with placebo or no treatment in women undergoing outpatient hysteroscopy.

Management of pain and expectations related to pain relief are important to enable success and good patient satisfaction.

Thorough counselling and discussions regarding all the pain relief options available during the procedure and making a shared decision are paramount to the experience of women undergoing outpatient hysteroscopy.

Successful fertility outcome of sequential hysteroscopic and vaginal metroplasty

Nikolaos Machairiotis¹, Stewart Disu²

¹Northwick Park Hospital- London Northwest Healthcare NHS Trust, Post-CCT endometriosis fellow- Gynaecology Department- BSGE Accredited Endometriosis Centre, Harrow, United Kingdom

²Northwick Park Hospital- London Northwest Healthcare NHS Trust, Consultant- Gynaecology Department- BSGE Accredited Endometriosis Centre, Harrow, United Kingdom

Background

A 35-year-old patient G1P0 with secondary infertility was referred to our Minimal Access Clinic following a MRI scan which was suggestive of septate uterus with a complete fibro-muscular septum. The MRI was requested 8 weeks following her early pregnancy scan which was keeping of bicornuate uterus and missed miscarriage. The patient opted for surgical management. Operation notes suggested vaginal septum and 2 cervixes.

Methods

During the consultation, the patient did not complain of any type of pelvic pain. Her first priority was fertility; an ultrasound renal scan excluded any abnormality. Outpatient hysteroscopy was performed with vaginoscopy approach. Complete vertical vaginal septum was identified with one cervix. Both ostia seen and a broad uterine septum from the fundus of the uterus to the internal cervical os noticed. The endometrial cavity was completely divided, and a twizzle bipolar electrode used to create a hole at the fundus of the uterus to connect the two cavities. Patient was updated that she needs a General Anaesthesia procedure to complete the metroplasty. Mirena coil inserted at the end under direct hysteroscopic vision to the divided area.

Results

Second stage procedure started under laparoscopic guidance to ensure the normal contour of the uterus. Vaginal septum divided with finger switch diathermy pen and bipolar twizzle electrode used to complete the division of uterine septum. Mirena coil was inserted at the end of the procedure to the endometrial cavity. Patient was reviewed in the clinic 3 months after the metroplasty and the Mirena coil was taken out. She became pregnant naturally and had her dating scan within 5 months from her clinic appointment.

Conclusions

All patients with infertility should be referred to the expert gynaecology doctors who deal with advanced minimal invasive techniques. It is fundamental to establish a process to all the gynaecology departments to treat patients with primary or secondary infertility. Patients with recurrent miscarriages should have meticulous work-up, careful consultation and treatment which address her priorities.

Predictive Factors for Pregnancy after Tubal Sterilization Reversal

Bárbara Gomes¹, Simone Subtil¹, Vera Ramos¹, Maria João Carvalho², Francisco Falcão¹, Fernanda Águas¹

¹*Coimbra Hospital and University Centre CHUC, Gynecology, Coimbra, Portugal*

²*Coimbra Hospital and University Centre CHUC- University Clinic of Gynecology Faculty of Medicine of the University of Coimbra, Gynecology, Coimbra, Portugal*

Background

Although wide ranges of contraceptive options are available, tubal sterilization is still a popular form of birth control. Although it is done as a permanent method of sterilization, 1–3% of these women subsequently demand reversal of sterilization, which can be achieved through laparotomic microsurgical or laparoscopic tubal recanalization.

The purpose of the study was to assess factors predicting a successful pregnancy after recanalization.

Methods

Retrospective chart review of women at a tertiary care centre submitted to tubal sterilization reversal between 2004 and 2021.

Results

From total of 41 women, the majority were Portuguese (68%, n=28), 23 lived in rural areas (56.1%) and 33 were married (80.5%).

Seventeen (41.5%) were submitted to sterilization by Pomeroy's method, 15 (36.6%) by rings, 3 (7.3%) by electrocoagulation and 6 (14.6%) had unknown method, at a median age of 29.5±3.8 [21-37] years. These women resorted to recanalization 9.2±4.3[2-19] years after sterilization, at a median age of 38.6±4.6[27-48] years. The main reason for seeking sterilization reversal was second marriage (75.6%, n=31). Only 2 (4.9%) were attributed to death of one or more children and in 8 (19.5%) the reason was new pregnancy.

Tubal sterilization reversal by laparotomy was done in 31 (75.6%) and by laparoscopy in 10 (24.4%) women. Recanalization was performed bilaterally in half of women (53.7%, n=22), and unilaterally in 19 (46.3%). Tubal patency at surgery was bilateral in 10 (24.4%) women, unilateral in 13 (31.7%) women, not patent in 4 (9.8%) women and unknown in 14 (34.1%). The mean length achieved was 6.1±1.0[4.5-8] cm. Women with laparoscopic approach had a 3-month patency control by hysterosalpingography and only one tube recanalized was not patent.

Fourteen (34.1%) women became pregnant in 11.8±9.9[3-33] months after recanalization. Nine (22%) women underwent normal term delivery, 1 (2.4%) preterm delivery, 2 (4.9%) ectopic pregnancies and 2 (4.9%) spontaneous abortion. Comparing the pregnancy group with the non-pregnancy group, we found no significant differences at median age at sterilization and median length achieved after recanalization. Median age at recanalization (33.4±5.5[27-42] years vs. 38.7±4.4[33-48], p=0.008) and median time after sterilization until recanalization (7.0±2.5[5-11] years vs. 10.1±4.6[2-18], p=0.007) were significantly lower in the pregnancy group. We found a positive moderate correlation between those two variables (ρ=0.416, p=0.007; ρ=0.430, p=0.006, respectively). When fixing a cut-off point for age of 40, there was no difference to get a pregnancy (p=0.923). Serum Anti-Müllerian Hormone (HAM) median in women submitted to laparoscopy was 1.98±1.76[0.3-5.6] ng/mL, but there was no significant difference considering pregnancy. Comparing the route of recanalization (laparotomy vs. laparoscopic), we found no difference in the pregnancy rate.

Conclusions

The main predictor factors to pregnancy after recanalization were younger age at recanalization and shorter time between sterilization and recanalization. Nevertheless, our conclusions are limited by the small number of our sample.

Is laparoscopic emergency cervicoisthmic cerclage in second trimester of pregnancy a treatment option? Outcomes of a case series report.

Dimitrios Zygouris¹, Sofia Papadimitriou², Evgenia Stergiannakou¹, Andreas Kavallaris¹

¹St. Luke's hospital- Thessaloniki- Greece, Department of minimally invasive Gynecology, Thessaloniki, Greece

²University Hospital of Ioannina- Ioannina- Greece., Department of Blood Transfusion, Ioannina, Greece

Background

The aim of this study was to evaluate the feasibility and safety of Laparoscopic emergency cervicoisthmic cerclage in second trimester of pregnancy.

Methods

Between November 2015 and March 2019 5 patients underwent Laparoscopic emergency cervicoisthmic cerclage. All women had showed cervical insufficiency with dilation in the second trimester due to extensive conisation (3 patients) or re-conisation (2 patients) and failed transvaginal cerclage (5 patients) due to a short vaginal cervix. Patients' characteristics were obtained from hospital's medical record, and we evaluated surgical data, intra, postoperative complications, and perinatal outcome. All operations were performed by the same surgeon.

Results

The average operation time was 88 min (ranging from 80 to 95 minutes), the average estimated blood loss during the procedure was less than 100 mL and there were no perioperative or postoperative complications. The mean gestational age at surgery was 14.4 (ranging from 14.2 to 16) weeks. All women underwent an elective CS after 38 weeks of gestation. The overall pregnancy survival rate was 100 %, the mean gestational age at delivery was 38.1 weeks (ranging from 38.0 to 38.5 weeks) and the mean birth weight was 3190 g (g) (ranging from 2980 g to 3350 g).

Conclusions

Laparoscopic cervicoisthmic cerclage might be an alternative approach even in the early second trimester of pregnancy. Our study's success rates compare favourably to the laparotomy approach and the laparoscopic cervicoisthmic cerclage showed a relatively high success rate in women who are at risk of poor obstetric outcomes. Of course, the surgeon's experience and competence play a key role and this approach should only be attempted in well-organized units.

Does prior abdominal surgery limit the laparoscopic approach in tubal ligation?

Maria Inês Nogueira E Sousa¹, Ana Almeida², Tiago Meneses¹, Helena Veloso¹, Rosa Macedo³

¹CMIN - CHUPorto, Departamento da Saúde da Mulher e Medicina Reprodutiva, Porto, Portugal

²CMIN -CHUPorto, Departamento de Saúde da Mulher e Medicina Reprodutiva, Porto, Portugal

³CMIN -CHUPorto, Departamento da Saúde da Mulher e Medicina Reprodutiva, Porto, Portugal

Background

Laparoscopic sterilization is usually an easy and quick procedure which can be performed in an outpatient setting, with a low complication rate. However, some factors such as previous surgery (laparotomy mainly), surgeon's experience, presence of adhesions and obesity may influence the risk and outcome of any laparoscopic surgery, including tubal ligation (TL).

The aim of this study is to compare the patients' characteristics and surgical outcomes of TL in women with or without prior abdominal surgery (PAS).

Methods

A retrospective observational study was performed at a tertiary centre, including women proposed to laparoscopic tubal ligation as contraceptive method during a 2-year period (2020-2021). Patients' records were revised, and two groups were evaluated: women with prior abdominal surgery (G1) and without this surgical background (G2). Statistical analysis was performed using SPSS, with a p-value <0.05 as statistically significant.

Results

A total of 212 women met the inclusion criteria: 95 with PAS (G1) and 126 without PAS (G2). By the time of the procedure, age was significantly increased in G1 (G1: Md 39y vs G2: Md 36y, p=0.01). Lysis of adhesions was made in 11 women (11.6%) from G1 and 3 women (2,4%) from G2 (p=0.01). One-port laparoscopy was performed in 92.6% of G1 and 97.6% of G2 (p=0.10), having the umbilical incision been the preferred entry site to access the abdominal cavity in both groups (G1: 96.6%; G2: 100%) – the alternative in G1 was the Palmer's point. The conversion rate to mini laparotomy was 2.1% and 1.6% respectively. Electrocoagulation and cut were the preferred method of tubal ligation in both groups (G1: 95.8%; G2: 99.2%, p=0.17). Ambulatory surgery was performed in 68.4% in G1 and 82.5% in G2 (p=0.04) and the median time for inpatient discharge was the day after surgery in both groups. No major intraoperative complications occurred in any group. Regarding postoperative morbidity, wound infection was the only complication reported (G1: 4.3% vs G2: 1.6%, p=0.41). Differences related to body mass index (G1: Md 28.0kg/m²; G2: Md 26.0kg/m²), rate of direct entry and duration of surgery (G1: Md 20.0min; G2: 18.0min) were nonsignificant. No failure of sterilization was observed in any group.

Conclusions

In our study, prior abdominal surgery was associated with older age, increased need for additional operative procedures such as lysis of adhesions and higher rate of inpatient tubal ligation. As reported in this series, pelvic organ adhesions are more frequent in women with PAS. Their severity might be influenced by the complexity of previous procedures, being highly recommendable to obtain a detailed clinical history and physical examination. In conclusion, despite the need of a careful pre and intraoperative approach, laparoscopic TL is a safe procedure in women with PAS.

Endometrial anomalies in breast cancer women with or without abnormal uterine bleeding: impact of hormone therapy on hysteroscopic and histological findings

Maria Chiara De Angelis¹, Mario Palumbo¹, Paolo Serafino¹, Alfonso Manzi¹, Salvatore Giovanni Vitale²

¹University of Naples " Federico II",

Department of Neuroscience- Reproductive Sciences and Dentistry- School of Medicine, Naples, Italy

²University of Catania- Catania- Italy,

Department of General Surgery and Medical Surgical Specialties- Obstetrics and Gynecology Unit, Catania, Italy

Background

the primary aim of this study was to evaluate the endometrial diseases associated or not with abnormal uterine bleeding (AUB), in women with previous breast cancer treated with the first-line hormone therapy

Methods

a retrospective observational study was conducted. Patients with a history of breast cancer were included and divided in Group 1, with AUB, and Group 2, without AUB. Both of the group were divided in 4 subgroups: treated with selective estrogenic receptor modulators (SERMs), aromatase inhibitors (AIs), GnRH analogues or SERMs + GnRH analogues. All patients had undergone office hysteroscopy for clinical or ultrasonographic suspicion of endometrial pathology. All data were collected in a dedicated database

Results

a total of 60 patients were included for the statistical analysis, 25 (42%) in Group1 and 35 (58%) in Group 2. 42/60 (70%) patients used SERMs in monotherapy and 4/60 (6.7%) combined with GNRH analogues. GnRH-analogues as monotherapy were administered in 8/60 (13.3%) patients; 6/60 (10%) patients were treated with Ais. Histological diagnoses did not recognize a statistically significant difference between Group 1 and Group 2. Patients in Group1 treated with Ais presented more atrophic or normal endometrium respect the patients that used SERMs and didn't present AUB. Only one patient in group 2, treated with SERMs had an adenocarcinoma of the endometrium.

Conclusions

different hormone therapies after breast cancer did not impact the endometrial pathology onset between the group of women with or without AUB.

Single incision – one port laparoscopic tubal ligation: 2-year experience of a tertiary centre

Maria Inês Nogueira E Sousa¹, Ana Almeida², Tiago Meneses², Lúcia Moleiro², Rosa Macedo²

¹*CMIN - CHUPorto, Departamento da Saúde da Mulher e Medicina Reprodutiva, Porto, Portugal*

²*CMIN -CHUPorto, Departamento da Saúde da Mulher e Medicina Reprodutiva, Porto, Portugal*

Background

Laparoscopic surgery has become the standard of care in many surgical specialties, including Gynaecology. Single-incision laparoscopic surgery (SILS) is an innovation in the field of minimally invasive techniques, reducing complications related to trocar entry and allowing faster recovery, less pain, and better cosmetic results. However, there are scarce data in the literature regarding the outcomes of single incision laparoscopic tubal ligation. The aim of this study is to report and analyse the experience of a tertiary centre.

Methods

Records from patients who got a single incision – one port laparoscopic tubal ligation as contraceptive method during a 2-year period (2020-2021), in a tertiary centre, were revised. A retrospective observational study evaluated patients' characteristics, operative time, surgical complications, conversion rate and failure of sterilization rate. Statistical analysis was performed using SPSS, with a p-value <0.05 as statistically significant.

Results

A total of 212 patients were included in this study. Median age at the time of surgery was 37, ranging from 19 to 45 years old. Eighty-nine patients (42.0%) had a background of prior abdominal surgery. In this subgroup, 71.9% had a previous caesarean-section (35.9% with an history of two or more). Median body mass index was 27.0kg/m² and 23.1% were considered obese (with 11.8% of missing results). An incision was performed in the umbilicus in 98.6% and in the Palmer's point in the remaining 1.4% – in all of them, a 11-mm trocar was used as a single port. Conversion to mini laparotomy occurred in 3 cases (1.4%) due to multiple adhesions among pelvic organs (2) and failed placement of the port (1). The mid-portion of the tubes was coagulated and cut bilaterally in 208 patients and bilateral salpingectomy was performed in the remaining 4 (2 laparoscopic + 2 laparotomic). Median operating time was 19 minutes (IQR 13 minutes). The most common intraoperative complication was uterine perforation, caused by manipulation (2.4%); no major complications occurred. Regarding postoperative morbidity, wound infection was reported in 2.9%. Ambulatory surgery was performed in 79.2% and the inpatient discharge occurred the day after surgery in all the other cases. No port site hernias or failure of sterilization was observed (follow-up period of 5-28 months).

Conclusions

SILS is the least invasive procedure for tubal ligation, and it appears to be safe and effective. The overall complications rate is low, so this technique should be considered as the first line option. It can be easily performed by a laparoscopic surgeon who is familiar with basic laparoscopy in an outpatient setting, unless if associated with severe comorbidities or conditions which increase the complexity of the procedure.

Unexpected Ovarian Malignancy in Laparoscopic surgery for benign or inconclusive results on preoperative classification by IOTA group Simple Rules. A single centre study.

María Dolores Muñoz González¹, Cristina Aramburu Anglada¹, Cristina German Fernandez¹, Mar Gil Mira¹, Vanesa Pérez Simón¹, Vega García Garzón¹

¹Gynecologist, Gynecology and Obstetrics Department in Hospital Universitario de Torrejón, Madrid, Spain

Background

Laparoscopy has become the standard surgical approach for the treatment of benign ovarian tumours. However, laparotomy remains the preferred approach for malignant lesions. Therefore, preoperative diagnosis is key for the correct treatment of these tumours. The preoperative evaluation is recommended to be done by an expert sonographer. In the absence of one, Simple Rules from IOTA may help to classify the mass.

We had the objective, first, to evaluate the rate of unexpected ovarian malignancy in patients that underwent laparoscopic surgery for benign or inconclusive results on preoperative classification by the Simple Rules (SR) published by the IOTA (International Ovarian Tumor Analysis) group; second, to analyze the appropriateness of laparoscopy in these masses.

Methods

We performed a retrospective cohort descriptive study. We included all 141 laparoscopic surgeries to remove apparently benign adnexal masses at Hospital Universitario de Torrejón from January 2017 to December 2019.

Results

There were 11 (7,8%) cases of unexpected ovarian malignancy. Simple Rules presurgical assessment classified 85.8% (121/141) of the lesions as benign (including 117 truly benign and 4 histologically confirmed malignant) and 20 as inconclusive (13 benign and 7 malignant). The sensibility of SR in our population was 63% with a 90% of specificity. All surgeries were successful and all patients with malignancies are currently in complete remission.

Conclusions

With an accurate preoperative algorithm that includes evaluation of the SR, laparoscopic approach of apparently benign lesions is safe and the preferred option in a general hospital. SR combined with an expert sonographer assessment can improve the accuracy of preoperative diagnosis.

Systematic Review and Diagnostic Accuracy Meta-analysis of the use of Real-Time Near Infrared Fluorescence Imaging in Minimally Invasive Surgery of Endometriosis

Artemis Alexopoulou¹, Mohamed Fayez Hassouna², Sameh Hany Emile Sameh Hany Emile³, Manish Chand²

¹401 General Military Hospital, Department of Gynaecology, Neo Psychiko-Athens, Greece

²University College London, Division of Surgical and Interventional Sciences, London, United Kingdom

³Mansoura Faculty of Medicine- Mansoura University, General Surgery Department, Mansoura, Egypt

Background

The surgical management of symptomatic endometriosis could be challenging, often resulting in incomplete resection of endometriosis and postoperative presence of recurrence of symptoms.

The objective of this study was to provide a systematic review and meta-analysis for the diagnostic accuracy of real time fluorescence imaging (NIR-ICG) during minimally invasive surgery (MIS) for symptomatic endometriosis.

Methods

Search strategy: PubMed/ MEDLINE, Embase and Cochrane CENTRAL databases, were searched between January 2000 and December 2020.

Selection criteria: We included studies referring to symptomatic women aged 18-50 years with endometriosis who underwent minimally invasive surgery (MIS) guided by NIR-ICG imaging compared to white light (WL) MIS procedures or no comparison.

Data collection and analysis: Methodological quality of studies was assessed using QUADAS-2. Data analysis was performed using a bivariate model for meta-analysis.

Results

A total of 199 studies were identified from which 11 studies were included and 4 of them with a total of 513 lesions compared NIR-ICG to the pathological confirmation of endometriosis as the reference standard. The use of ICG to detect endometriosis had a pooled sensitivity of 72.8%, (95% CI: 68.3%, 77.1%) and a pooled specificity of 86%, (95% CI:78.2%, 92.7%) whereas the use of white light (WL) laparoscopy had a pooled sensitivity of 89.4% (95% CI:85.7%, 92.4%) and a pooled specificity of 71.6% (95% CI:62.1%, 79.8%).

Conclusions

The combination of NIR-ICG imaging with the conventional WL 2D or 3D imaging allows better detection rates.

How to survive to big-sized uterus' hysterectomy: tips and tricks in laparoscopic surgery

Matteo Pavone¹, Andrea Rosati¹, Giuseppe Vizzielli², Stefano Cianci³, Giovanni Scambia¹, Salvatore Gueli Alletti⁴

¹Fondazione Policlinico Universitario A. Gemelli- IRCCS- UOC Ginecologia Oncologica, Dipartimento per la salute della Donna e del Bambino e della Salute Pubblica, Roma, Italy

²Ospedale Universitario di Udine- DAME- Unità di Ostetricia e Ginecologia, Dipartimento di Ostetricia- Ginecologia e Pediatria, Udine, Italy

³Policlinico G. Martino- Università degli studi di Messina, Dipartimento di Ginecologia Oncologica e Chirurgia Ginecologica Miniinvasiva, Messina, Italy

⁴Ospedale Buccheri La Ferla- Fatebenefratelli, UOC Ginecologica e Ostetricia- Dipartimento Materno-Infantile, Palermo, Italy

Background

The steps of total laparoscopic hysterectomy have been standardized by several authors. The removal of a bulky uterus is always challenging due to hurdles in mobilization and exposure of the surgical field with a difficult visualization of the ureter and vascular structures in laparotomic surgery. In minimally invasive techniques instead is difficult to find the exact balance of tractions crucial to carry out an effective dissection. Several studies have shown that the minimally invasive approach is superior to open surgery in terms of perioperative outcomes specifically in bulky uterus hysterectomy. Due to inconclusive results present in literature, we plan a study to provide a systematic description of technical aspects in bulky uterus hysterectomy with laparoscopic approach.

Methods

This is a monocentric observational retrospective study including 70 patients submitted to total hysterectomy for a bulky uterus. All the included patients have had a confirmed diagnosis of fibroids at histopathological evaluation resulting in a bulky uterus. All the uteri were classified according to the Large Uterus Classification System (LUCS). Data on technical aspects and on perioperative variables were collected.

Results

According to LUCS the distribution of uterine weight (mean (SD): Type1 987(57) gr, Type2 1040(84) gr, Type3 1353(150) gr, $p=0.76$) and the maximum fibroid diameter (median (range): Type1 80(55-148)mm, Type2 77(50-216)mm, Type 3 111(63-119)mm, $p=0.139$) did not significantly differ between groups. Central trocar placement was trans-umbilical in the 92% of cases and in only 5 patients the trocar was placed supraumbilical or in the palmer's point due to previous laparotomic surgery and post-surgical adhesions.

The uterine manipulator was positioned in 62.8% of cases while in the remaining 37.1% of cases a vaginal sponge was positioned. The relative distribution of uterine manipulator and vaginal sponge varies in the three groups and there is a progressive increase in the use of vaginal sponge in types 2 and 3 (type 1 26.2%, type2 40%, type 3 87.5%) and a contextual decrease in the positioning of the uterine manipulator (type 1 73.8%, type2 60%, type 3 12.5%, $p = 0.04$).

The need for integrated energy devices also significantly increases in the context of the three classes (Type 1 14.3%, Type2, 35%, Type3 87.5%, $p = <0.001$)

The operating times differ according to the type of extraction (mean (SD): vaginal 131 (8) min, vaginal "downsizing technique" 143 (10) min, miniLPT 191 (18) min, mini-LPT "Downsizing technique" 177 (16) min, ($p = 0.003$).

Conclusions

Hysterectomy in the case of bulky uteri represents a technical challenge that is difficult to standardize due to the high number of intra-operative and anatomical variables of the uterus. In this single surgeon experience we present some useful tips and tricks based on preoperative large uteri classification and intraoperative scenario helping the surgeon to tailor a personalized surgical strategy

Recurrence of Intracavitary Uterine Findings after Surgical Hysteroscopy

Ana Beatriz Almeida¹, Diana Rodrigues-Martins¹, Tiago Meneses Alves¹, Sandra Soares¹, Susana Carvalho¹, Rosa Zulmira Macedo¹

¹Centro Materno-Infantil do Norte Dr Albino Aroso - Centro Hospitalar Universitário do Porto, Women and Reproductive Medicine, Porto, Portugal

Background

Submucosal myomas (SMM) and endometrial polyps (EP) consist in benign uterine findings presenting recurrence rates up to 20% and 44%, respectively, after surgical hysteroscopy (SH).

The aim of this study was to compare the intraoperative findings and outcomes of SH between women with and without a previous procedure. A sub analysis evaluating the correlation of surgical indications and intraoperative findings between the previous and the current SH was also performed.

Methods

Retrospective cohort study including all women submitted to SH in a tertiary centre between 2018 and 2021.

Two groups of women were considered: those with (group 1) and without (group 2) history of a previous SH procedure. Women characteristics of both groups were analysed, as well as their intraoperative findings (type, number and maximum diameter of lesions) and surgical outcomes (complete/incomplete procedure and presence of intraoperative complications).

Results

A total of 370 women performed SH during the considered period. Of them, 20 patients presented a previous procedure (5.4%) while 350 women performed SH for the first time. Mean age of both groups were 48 years-old, with a postmenopausal rate of 15% and 29% for groups 1 and 2, respectively. Smokers (6% vs 17%) and higher body mass indices (26,8 kg/m² vs 27,3 kg/m²) were found more frequently in group 2, although results were not statistically different ($p>0.05$). Neither arterial hypertension nor obstetrical history have shown significant differences.

In both groups, the main indication to perform SH was abnormal uterine bleeding, followed by asymptomatic incidental findings in routine gynaecological ultrasounds. SMM was the main intraoperative finding in group 1, whereas EP was more frequently found in group 2. Two or more intracavitary lesions were observed more often during the procedure in group 1 (60% vs 33%, $p=0.03$) but no differences were found between their maximum diameter (25 mm vs 23.7 mm, $p=0.68$). The rate of complete SH was similar between both groups; however, a greater rate of complications was observed in group 1 (15% vs 1.2%, $p<0.01$).

The overall recurrence rate of the same type of intracavitary lesions was about 4.6%. A sub analysis of group 1 found a mean time interval between SH procedures of 3 years, and surgical indication was the same in 70% of cases. In 85% of cases, intraoperative findings correlated to those observed in the previous SH, however no differences were found regarding their number or maximum diameter.

Conclusions

SMM tended to recur more often after SH, however the overall recurrence rate of intracavitary uterine pathology remained low. Surgical complications, although rare, were more frequent in recurrent cases. Besides a higher number of intracavitary lesions, no other clinicopathologic features have been found to predict recurrences.

Improving the Pregnancy Outcomes in Endometriosis Infertility

Irina Ramilo¹, Ana Gonçalves Andrade¹, Sandra Sousa², Angelo Ferreira³, Luis Ferreira Vicente⁴, Fatima Faustino¹

¹Hospital Lusíadas Lisboa, Gynaecology Department, Lisboa, Portugal

²Hospital Lusíadas Lisboa, Radiology Department, Lisboa, Portugal

³Hospital Lusíadas Lisboa, Surgery Department, Lisboa, Portugal

⁴Hospital Lusíadas Lisboa, ART Department, Lisboa, Portugal

Background

To present 5-year statistics of a Specialized Center for Endometriosis. In addition will be presented the description of the surgical procedure and the follow up focusing on future fertility and pregnancies in patients with endometriosis and infertility.

Methods

Retrospective study with detailed analysis of the cases for 5 years (2016-2020). Analysis of future fertility prospects, clinical pregnancy rates, live birth rates, obstetrical outcomes and spontaneous pregnancy and the need for assisted reproductive techniques. The patients were contacted by telephone or by email in cases that the data were not available in the hospital database.

Results

Ectopic implants of endometrial cells produce intraperitoneal bleeding and create a state of inflammation with biochemical alterations of peritoneal fluid; this factor is responsible of poor oocyte quality, reduced sperm motility and impaired interaction between sperm and oocyte.

The Endometriosis Specialist Center from 2016 to 2020 treated surgically more than 276 women, with a mean age of 35 years and the youngest at 25 years.

Of the 276 patients, 207 women had deep endometriosis and 88% of them were operated on by laparoscopy. 191 women underwent bowel intervention, of which 85 with rectal shaving, 18 with anterior segmental resection of the rectum, 7 with discoid resection of the rectum, 8 with colon resection and 2 with small intestine, in addition to 11 appendectomies. About other interventions 83 women had ureter/bladder intervention, with 63 ureterolysis, 3 ureter reimplantation and 1 nephrectomy.

We evaluated from these data, women with desire for a future pregnancy. We have a good clinical pregnancy rate, live birth rates, obstetrical outcomes and with a considerable number of spontaneous pregnancies. More than 30% of women with endometriosis turn to ART treatments.

Conclusions

The severity of the symptoms, the possible progressive and disabling intensity, the infertility, and the limitation of the woman's quality of life made us study, investigate, and invest in the early diagnosis of the pathology and in the progressive improvement of the endoscopic surgical technique.

We are a specialized centre dedicated to these women, with a complete and multidisciplinary team in an integrated logic. An approach with monthly meetings to discuss clinical cases including a laparoscopic gynaecologist, assisted reproductive specialist and urology, gastroenterology, radiology, colorectal surgery and pathology specialist. This approach is responsible for our good results in terms of pregnancy and live births rates. Furthermore, the study analyses the disease with the same surgical and medical strategy of the same team.

One Stop Menstrual Disorders Clinic: Introduction of a New Service in Lanarkshire

Lauren Donnelly¹, Louise Kellison¹, Rebecca Thomas¹, Rebecca Parsonson¹

¹NHS Lanarkshire, Obstetrics and Gynaecology, Glasgow, United Kingdom

Background

Background: Menstrual disorders greatly impacts patient quality of life and accounts for 20% of vetted gynaecology referrals in NHS Lanarkshire, Scotland's third largest health board with a population of 655,000. The traditional pathway for women presenting with menstrual disorders includes attendance at general gynaecology clinic; referral for ultrasound scanning (USS) and admission for day case surgical hysteroscopy under general anaesthetic.

Our objective was to implement a One-Stop Menstrual Disorders Clinic (MDC) incorporating trans-vaginal ultrasound scan (TVUSS), outpatient hysteroscopy and treatment options as recommended by 2018 Heavy Menstrual Bleeding (HMB) NICE guidelines.

Methods

Prospective audit of a database including all patients attending the menstrual disorders clinic from July 2020 until August 2021. On average, the MDC accommodates 30 patients per month. Patients are vetted against urgent criteria as per NICE HMB guidance. Demographics, investigations and their subsequent findings, management, and follow-up were extrapolated for each patient. Outcomes measured included: numbers undergoing TVUSS, outpatient hysteroscopy, treatment, and discharge.

Results

A total of 361 patients were identified, aged between 17-58 years with an average of 42.71 years. More than 75.6% of patients had a BMI >25, with an average BMI of 32.47. 83 (22%) patients had a medical condition that increased their risk of endometrial pathology.

311 patients had a TVUSS in clinic. The endometrium appeared normal in 208 (66%), proliferative in 2 (0.6%), thickened in 23 (7.4%) and suspicious in 5 (1.6%). 37 (11.9%) patients had polyps and 63 (20%) had fibroids. 31 (8.5%) patients went on to have a departmental USS.

200 (55%) patients had a hysteroscopy. Endometrium was normal in 140 (70%); proliferative in 6 (3%); thickened in 5 (2.5%); suspicious in 4 (2%); and atrophic in two (1%). Fifty-five (27.5%) patients had polyps and 17 (8.5%) had fibroids.

188 (52%) patients had a pipelle biopsy taken. Of these, 170 (90%) were benign; 4 (2%) demonstrated hyperplasia; and 2 (1%) demonstrated cancer. 12 (6.4%) of pipelle biopsies were inadequate samples.

194 (54%) patients-initiated treatment on their first MDC appointment. Of those, the most common was the Mirena coil insertion or replacement in 85 (23.5%) patients. 160 (44%) patients were discharged after one appointment, 57 (15.8%) were referred for outpatient Myosure, 6 (1.6%) for hysterectomy and 28 (7.6%) patients were referred for hysteroscopy or Myosure under general anaesthetic.

Conclusions

This audit has shown that the menstrual disorders clinic (MDC) introduced in NHS Lanarkshire has met the NICE recommendations set out in 2018 by providing patients with gold standard assessment and investigations in a one-stop outpatient clinic format. This has resulted in efficient diagnosis and management of the majority of patients in one appointment. The MDC has reduced general anaesthetic exposure compared to the traditional pathway and had demonstrated a reduction in health board costs.

Fighting Intestinal Endometriosis with a Multidisciplinary Team (2016-2020)

Ana Gonçalves Andrade¹, Irina Ramilo¹, Sandra Sousa², Ângelo Ferreira³, Luís Ferreira Vicente⁴, Fatima Faustino¹

¹Hospital Lusíadas Lisboa, Gynaecology Department, Lisboa, Portugal

²Hospital Lusíadas Lisboa, Radiology Department, Lisboa, Portugal

³Hospital Lusíadas Lisboa, Surgery Department, Lisboa, Portugal

⁴Hospital Lusíadas Lisboa, ART Department, Lisboa, Portugal

Background

A Specialized Center for Endometriosis was created in 2016.

We review the data for 5 years of the centre's activity. We emphasize cases with intestinal involvement analysing the surgical interventions, the mobility, and the follow-up of the patients with intestinal endometriosis.

Methods

Retrospective study with detailed analysis of the cases for 5 years (2016-2020) in the perspective of the involvement of colorectal surgery and deep endometriosis.

Results

The incidence of intestinal endometriosis is estimated to be from 3% to 37% of all endometriosis cases. In most cases (> 90%), intestinal endometriosis involves the sigmoid colon or rectum and the posterior pelvic compartment peritoneum.

The symptoms include diarrhea, constipation, tenesmus, and rectal bleeding. Pelvic pain and infertility can also occur.

The Specialized Centre for Endometriosis surgically treated 276 women from 2016 to 2020, with a mean age of 35 years and the youngest at 25 years.

Of the 276 patients, 207 women had deep endometriosis and 88% of them were operated on by laparoscopy. 191 women underwent bowel intervention, of which 85 with rectal shaving, 18 with anterior segmental resection of the rectum, 7 with discoid resection of the rectum, 8 with colon resection and 2 with small intestine, in addition to 11 appendectomies. About other interventions 83 women had ureter/bladder interventions, with 63 ureterolysis, 3 ureter reimplantation and 1 nephrectomy. There were 21 hysterectomies and about 21 (8%) cases of complications.

Conclusions

Understanding the complexity of this disease, we created a Specialized Centre for Endometriosis, equipped with a multidisciplinary team, where professionals dedicated to all aspects of this disease are gathered to diagnose and treat endometriosis in the same Centre, in an integrated logic, with a low incidence of complications.

TruClear Hysteroscopic Myomectomy- 5 years of experience in a District General Hospital

Aine McNally¹, Rachel Farr¹, Suha Abdalla¹, Sally Mohammed Ahmed¹

¹Ulster Hospital, Obstetrics and Gynaecology, Dundonald, United Kingdom

Background

Hysteroscopic myomectomy has revolutionised the treatment of submucosal fibroids, allowing low risk, day case management of affected patients, and avoiding more invasive surgery in many cases.

The aims of our audit were to: review short and longer term outcomes of TruClear myomectomy in a local context, compare these with quoted literature, identify any areas where clinical practice could be modified to improve outcomes and to extrapolate our local data for use in patient counselling and information on available treatment options.

Methods

Retrospective review of all TruClear myomectomy cases performed in the South Eastern Trust, N.Ireland, between 2016-2021. Outcomes were assessed by review of the patient's electronic care record.

Results

82% of patients had complete resection of the fibroid with 8% of patients requiring a two-stage procedure. Only 2% had intra-op complications and 4% needed antibiotics post-operatively. Following treatment, 70% of patients had resolution of symptoms. 24% of patients required or were on the waiting list for a further procedure due to ongoing symptoms. 6% opted for repeat TruClear and 18% required a hysterectomy. The risk of additional surgery was 50% in women with fibroid size >5cm.

Conclusions

TruClear myomectomy is a safe procedure with low complication rate in our local context. It is an effective treatment option for women with symptomatic submucosal fibroids. Documentation of type and size of fibroid could be improved in our unit to allow further comparison of outcomes in future.

Surgical complications in endometrial cancer surgery. ¿Are older patients undertreated?

Rocio Luna Guibourg¹, Alba Farres-Rubi¹, Natalia Teixeira¹, Cristina Soler-Moreno¹, Ramon Rovira¹

¹Hospital de la Santa Creu i Sant Pau, Obstetrics and Gynecology, Barcelona, Spain

Background

Endometrial cancer is the most frequently diagnosed gynaecologic cancer among European women. In 2020, 130.051 new cases were diagnosed in Europe. It is estimated that over a 45% of cases are diagnosed in women over 65 years old. The increase in life expectancy is challenging gynaecological oncologists to face an increasing proportion of older patients with endometrial cancer. It has been described that older patients (OP) are less likely to receive an optimal surgical treatment than non-older patients (NOP). This undertreatment can imply a worse prognosis among these patients. However, few studies have shown evidence about surgical outcomes of OP compared to NOP undergoing the same surgical staging. The objective of the study was to compare intraoperative and postoperative complications according to the Clavien-Dindo severity score between NOP and OP with EC undergoing primary surgery.

Methods

Retrospective observational study including women undergoing staging surgery for endometrial cancer at our University Hospital between 2010 and 2019.

Patients were classified according to their age as NOP (younger than 75 years) or OP (75 years or older).

Surgical complications were compared in total complication rate and severity of complications according to the Clavien-Dindo severity score.

Results

A total number of 281 patients were diagnosed of EC in our hospital and underwent complete surgery between 2010 and 2019. 184 of them were younger than 75 years, and 97 were older than 75. An 83% of patients underwent minimally invasive surgery. Complete lymphadenectomies were more frequently performed in NOP compared to OP (Pelvic 58,2% vs. 37,1%, $p=0,001$ and para-aortic 46,7% vs. 23,7%, $p<0,001$).

Rates of intra-operative (6,5% vs. 12,4%, $p=0,116$) and post-operative (13,0% vs. 20,6%, $p=0,120$) complications were not statistically different between NOP and OP, and neither was the rate of severe complications according to Clavien-Dindo classification (5,4% vs. 8,2% of complications grade III-V respectively, $p=0,387$). Considering only patients in whom complete surgical staging was performed, OP presented similar DSS to NOP, with comparable complication rate.

Conclusions

Age is not related to surgical complication rate or severity of complications in patients with endometrial cancer undergoing surgical treatment.

Laparoscopic tubal ligation in an ambulatory setting - postoperative complications in last 2 years

Susana Saraiva¹, Patricia Ferreira¹, Ana Paula Reis¹, Soledade Ferreira¹, Cristina Costa¹

¹Centro Hospitalar de Entre o Douro e Vouga, Gynecology, Santa Maria da Feira, Portugal

Background

Female sterilization is a method of contraception used worldwide and it is overall safe and effective. Female permanent contraception could be performed immediately after childbirth (postpartum) or at a time unrelated to a pregnancy (interval). There are various laparoscopic techniques such as electrocautery, silicone band, titanium clip and salpingectomy.

Major complications from laparoscopic tubal ligation are uncommon and according to United States Collaborative Review of Sterilization (CREST) cohort the overall rate of intraoperative and postoperative complications was 1.6 per 100 women.

Methods

Retrospective observational study of complications of laparoscopic tubal ligation in an ambulatory in 2020 and 2021 in a tertiary hospital.

The objective was to assess the immediate and late complications of laparoscopic tubal ligations performed between January 1, 2020, and December 31, 2021, in an outpatient setting. Data analysis was performed using Microsoft Excel ®.

Results

A total of 143 women underwent laparoscopic tubal ligation by electrocautery. The mean age of women undergoing sterilization was 38 years (minimum 29 years; maximum 46 years). Among the women analysed, 1 was nulliparous, 26 were primiparous and 116 had at least 2 children. Regarding the mode of delivery, 105 women had at least one vaginal delivery and 44 women underwent at least 1 caesarean section.

Postoperative complications occurred in 1,4% of cases (n=2). Supraumbilical pain 15 days after surgery and subcutaneous emphysema in the umbilical region 2 days postoperatively were observed.

Conclusions

To conclude, although the population sample is small, the results of our study are in line with the literature, which reveal low rates of postoperative complications.

Office hysteroscopic management of retained products of conception as first-line treatment: our results after one year of protocol implementation

Marta Bailón Queiruga¹, Lourdes Sala Climent¹, Laura Melé Olivé¹, Elvira Mestres Betsebé¹, Ana Calvo Redol¹, Marta Simó González¹

¹Hospital Universitari Arnau de Vilanova, Gynecology & Obstetrics, Lleida, Spain

Background

Retained product of conception (RPOC) is defined by retention of trophoblastic tissue inside the uterine cavity after a delivery or an abortion. Its incidence can reach up to 20% and its persistence can lead to endometritis or uterine synechiae, which can affect future fertility.

Dilation and curettage have been considered the gold standard for RPOC removal, but it is associated with incomplete evacuation and synechiae. Hysteroscopic removal of RPOC is a minimally invasive alternative since, as it is performed under direct vision, allows selective evacuation of RPOC without affecting the healthy endometrium, therefore reducing the probability of adhesions.

In January 2021, we implemented a new RPOC management protocol in our hospital. Office hysteroscopy was established as RPOC first line treatment, except in cases of acute bleeding.

The aim of this study is to evaluate the effectiveness and safety of office hysteroscopy in RPOC during the first year of protocol implementation.

Methods

This retrospective observational study was performed in the gynaecologic unit of a teaching hospital between January 2021 and December 2021.

Primary objective was assessment of effectiveness measured as the rate of complete resolution in one-time procedure. Secondary objectives were evaluation of pain and complications.

According to our protocol, RPOC was suspected by ultrasound and office hysteroscopy were scheduled at 5-6 weeks of the end of pregnancy.

Results

During the study period, 74 office hysteroscopies due to RPOC were performed.

Mean age of patients was 32.4 years. Causes of RPOC were: 71% after voluntary interruption of pregnancy, 20% after spontaneous abortion treated pharmacologically and 8% after vaginal delivery.

63.51% of patients presented abnormal uterine bleeding, while 36.49% remained asymptomatic. The mean largest diameter of RPOC measured by ultrasound was 15.76 mm. According to Gutenberg's classification, 25.62% were type 0, 47.35% type 1, 18.92% type 2 and 8.11% type 3.

The procedures were performed with 4.3-5.5 mm-diameter hysteroscopes. 87.82% were treated with a mechanical morcellator, 4.04% were resolved with forceps and/or scissors and 2.70% with a bipolar loop. In 4 cases no intracavitary remains were observed in the hysteroscopy.

The effectiveness of the technique, measured as the complete resolution in one-time procedure was 94.59%. The 4 remain cases were solved in a second time procedure.

The mean maximum pain score (VAS) during the procedure was 5/10, and at the end it was 1.96/10.

Regarding the complications: 91.89% of the procedures were carried out without complications, 5.40% presented a mild vasovagal overreaction which could be solved with positional manoeuvres and 2.70% presented bleeding that did not require any intervention.

Conclusions

Our results after one-year experience support that office hysteroscopic approach is a feasible, safe and effective method to manage RPOC. Operative hysteroscopy should be considered the surgical treatment of choice in women with RPOC.

Management of Patients Presenting to the One-stop Menstrual Disorders Clinic and Diagnosed with Fibroids in Lanarkshire

Lauren Donnelly¹, Louise Kellison¹, Rebecca Thomas¹, Rebecca Parsonson¹

¹NHS Lanarkshire, Obstetrics and Gynaecology, Glasgow, United Kingdom

Background

Menstrual disorders greatly impact patient quality of life and account for 20% of vetted gynaecology referrals in NHS Lanarkshire, Scotland's third largest health board. Menstrual disorders are one sign of uterine fibroids, the most common benign tumour in women. A diagnosis of fibroids should be confirmed on ultrasound scan, as recommended by the 2018 Fibroids NICE guidelines.

Our objective was to identify patients diagnosed with fibroids at the One-Stop Menstrual Disorders Clinic (MDC) using trans-vaginal ultrasound scan (TVUSS) and outpatient hysteroscopy and identify which treatment options are utilised.

Methods

Prospective audit of a database including all patients attending the menstrual disorders clinic from July 2020 until August 2021.

On average, the MDC accommodates 30 patients per month, on average 5 patients per month are diagnosed with fibroids. Demographics, investigations, subsequent findings, management, and radiological follow-up were extrapolated for each patient. Outcomes measured included: numbers diagnosed on TVUSS; diagnosed with outpatient hysteroscopy; and subsequent management.

Results

A total of 68 patients were identified, aged between 21-55 years with an average of 45.5 years. Average BMI was 30.7. 12 (17.6%) patients had a pre-existing medical condition that increased their risk of endometrial pathology.

66 patients underwent TVUSS in the clinic. The endometrium appeared normal in 39 (57%); proliferative in 1 (1.4%); and thickened in 2 (2.8%). Endometrial thickness was ≤ 4 mm in 19 (28.7%) patients and >4 mm in 22 (33.3%) patients. TVUSS diagnosed fibroids in 62 (93.9%) patients and 4 (5.8%) patients were diagnosed with polyps. TVUSS identified 23 (37%) fibroids ≤ 3 cm and 27 (43.5%) >3 cm.

45 (66%) patients underwent outpatient hysteroscopy. Endometrium was normal in 29 (64%); thickened in 1 (2%); and proliferative in 2 (4%). 18 (40%) patients had fibroids and 9 (20%) patients had polyps.

26 (38.2%) patients had fibroids identified on TVUSS but not subsequent hysteroscopy. 4 (6%) patients had fibroids identified on hysteroscopy that were not identified on prior TVUSS. 10 (14.7%) patients had a follow-up TVUSS.

39 (57%) patients initiated treatment at their first MDC appointment. The most common was the Mirena intra-uterine system (IUS) in 19 (49%) patients. 29 (42.6%) patients required no treatment.

Including follow up, 33 (48.5%) patients were treated with a Mirena IUS; 10 (14.7%) with progesterone only pill; 2 (2.9%) with Norhisterone; 3 (4.4%) with Gonadotrophin-releasing hormone (GnRH); and 3 (4.4%) with tranexamic acid.

22 (32.3%) patients were treated surgically; 16 (23.5%) underwent a Myosure procedure; 4 (5.9%) underwent a laparoscopic hysterectomy; and 2 (2.9%) underwent a laparoscopic myomectomy.

Conclusions

This audit has shown that fibroids diagnosed in the MDC were overwhelmingly identified on TVUSS. Patients are managed both medically and surgically as recommended by NICE guidelines, with the Mirena intrauterine system and Myosure being the most commonly utilised medical and surgical options respectively.

Hysteroscopic polypectomy in an outpatient setting

Bence Zoltán Boldogh¹, Luca Lukács², Márton György Lipták¹, Rudolf Lampé², Tünde Herman², Péter Török²

¹Faculty of Medicine- University of Debrecen, Department of Obstetrics and Gynecology- Kenézy Gyula Campus, Debrecen, Hungary

²Faculty of Medicine- University of Debrecen, Department of Obstetrics and Gynecology, Debrecen, Hungary

Background

Endometrial polyps are the most frequently observed benign lesions inside the uterine cavity. The incidence of them is reported about 20 % to 30 % in the female population. Endometrial polyps can be single or multiple, their size varies from a few millimetres to several centimetres. They can be totally asymptomatic or can cause abnormal uterine bleeding and/or infertility. They can be diagnosed by transvaginal ultrasonography, saline infusion ultrasonography, or by direct hysteroscopic visualization, but only the last can offer histological confirmation and proper treatment. Polyps can be removed by blind Dilatation and Curettage (D&C), or by hysteroscopy with direct visualization. Due to the miniaturization of the hysteroscopic devices, polypectomy can be made in an outpatient setting without general anaesthesia and hospitalization. The office-hysteroscopic removal of the polyp can be done with many operative techniques for example: with miniaturized instruments (grasping forceps, scissors), with mini-resectoscope, with tissue removal device (TRD), or with laser.

Methods

We retrospectively analysed the data of 125 patients, who underwent hysteroscopic polypectomy without general anaesthesia, in an outpatient office, between November 2016 to January 2022.

Results

The mean age was 41.46 ± 10.50 years, and the mean Body Mass Index (BMI) was 25.22 ± 5.87 . The indications for performing office-hysteroscopy were the following: 79 (63.20%) abnormal sonographic findings, 27 (21.60%) infertility, and 19 (15.20%) abnormal uterine bleeding. Out of the 125 polypectomies, 74 (59.20%) were done with mechanical instruments (grasping forceps, scissors), 50 (40.00%) with mini-resectoscope, and 1 (0.80%) with laser.

Conclusions

Our data show that the toolkit of office-hysteroscopy is appropriate for the treatment of endometrial polyps furthermore, the polypectomy can be performed in an outpatient, cost-effective way without general anaesthesia and hospitalization.

Robotic assisted (Da Vinci X) repair of vesico-vaginal fistula: first reported case report in Greece

Elias Tsakos¹, Emmanouil M. Xydias², Apostolos C. Ziogas², Georgios Karydas³, Vassilis Moros⁴, Vassilis Poulakis⁴

¹Embryoclinic, Department of Robotic surgery, Thessaloniki, Greece

²University of Thessaly- School of Health Sciences, Department of Medicine, Larissa, Greece

³St. Lukes Hospital, Department of Urology, Thessaloniki, Greece

⁴Metropolitan Hospital, Department of Urology, Athens, Greece

Background

The aim of this case report is to present a novel technique of robotic vesico-vaginal fistula repair in a patient four months following robotic hysterectomy for a large fibroid uterus, that was conducted using the Da Vinci X surgical system; and to showcase this technique for uro-gynecological surgery in Greece, with the help of ancillary detailed video recordings.

Methods

The patient underwent routine bowel preparation and antibacterial prophylaxis. The operation was conducted using the Da Vinci X surgical system along with the use of 4 robotic arms, namely: 30 degrees scope, Maryland bipolar, scissors and needle holder. The multidisciplinary operating team consisted of senior robotic urology and gynaecology surgeons surgery and lead by a world expert in urology robotic surgery (V.P.). Initial steps entailed cystoscopy and catheterization of ureters, identification of the fistula during cystoscopy and marking via insertion of a different uro-catheter, which was subsequently pulled through and outside, via the vaginal introitus. Following that, trocars were placed abdominally and peritoneoscopy was performed to assess the abdominal and pelvic cavities. Minor adhesiolysis ensued to mobilize the intestine and reveal the superior surface of the bladder, which was then filled via the inserted Folley catheter for optimal anatomical identification. The fistula was identified with the help of a bedside assistant who moved the inserted catheter from the outside and subsequently cystostomy was performed along the direction of the catheter. Once the bladder was accessed, the fistula along with adequate healthy tissue margins was excised to facilitate complete removal of necrotic tissue and improve healing. Following that, final repair could commence, firstly with suturing of the vagina, secondly with the interposition of a well-vascularized omental pedicle between vaginal and bladder walls and ultimately continues suturing of the bladder.

Results

The procedure's duration (console time) was 55 minutes and was uneventful. The patient recovered swiftly and was discharged home 24 hours after the operation. Apart from minor pain and irritation in the vaginal area, the patient reported no other complications and in fact noted improvement of her symptoms. Since at the time of writing the patient is still in the early post-operative period, the possibility of late complications or recurrence cannot be eliminated yet, however the early encouraging signs give us hope that such unfavourable outcomes may be avoided, and further clinical improvement shall be noted at the follow-up examination.

Conclusions

Robotic vesico-vaginal repair is a minimally invasive technique to treat a surgically challenging complication with impressive outcomes and yet not widely applied in Greece. With the presentation of this case along with detailed video material we hope to promote this safe and effective treatment option into a more widely used and established methodology, especially in our country.

Setting up a new service: Laparoscopic Transabdominal Cervical Cerclage

Catherine Taylor¹, James Rowland¹

¹Lancashire Teaching Hospital Foundation Trust, Obstetrics and Gynaecology, Preston, United Kingdom

Background

Reducing preterm birth is a priority for maternity services, as a result of this a preterm birth clinic, Bluebell, has been established at our local unit. This clinic identifies people requiring a cervical cerclage. Unfortunately some of these patients will go on to require a transabdominal cervical cerclage (TAC). Transabdominal cerclage is indicated when cervical cerclage is not possible or has previously failed. This has historically been done via a laparotomy with the associated morbidity and recovery time. Patients in our region who required this procedure had to be referred out of area. We identified an opportunity to be able to offer this procedure locally, with the added benefit of performing it laparoscopically. There is good evidence that laparoscopic TAC has favourable pregnancy outcomes compared to laparotomy but without the associated morbidity.

Methods

We are now able to easily identify patients that require this procedure due to our preterm birth clinic and the newly established referral pathway if a cervical cerclage fails. This is an observational case study of the laparoscopic procedures performed to date via a single surgeon and the pregnancy outcomes.

Results

3 procedures have successfully been performed without any complications and are awaiting pregnancy outcome data.

Conclusions

We will continue to record the data at our unit. There is already good evidence that the laparoscopic procedure compares favourably to the laparotomy approach. So now we can safely offer TAC, not only locally but also with the added benefit of reducing the morbidity associated with major abdominal surgery. We aim to extend the service to other units within our region to offer this option to wider range of patients.

Laparoscopic vs. laparotomic Wertheim-Meigs surgery in the treatment of early-stage cervical cancer- 7-year experience at Instituto Português de Oncologia do Porto

Ana Cunha¹, Mariana Vide Tavares², Almerinda Petiz²

¹Hospital Senhora da Oliveira- Guimarães, Serviço de Ginecologia e Obstetrícia, Guimarães, Portugal

²Instituto Português de Oncologia do Porto, Serviço de Ginecologia, Porto, Portugal

Background

Cervical cancer is the leading cause of mortality among gynecological malignancies worldwide. Wertheim-Meigs surgery consists of a radical hysterectomy with pelvic lymphadenectomy and is used in the treatment of early-stage cervical cancer. Since the Laparoscopic Approach to Cervical Cancer Trial demonstrated that minimally invasive radical hysterectomy was associated with lower rates of disease-free and overall survival than open procedure, the laparotomic surgery became the preferential approach.

Objectives:

Comparison of the outcomes of laparoscopic versus laparotomic Wertheim-Meigs surgery performed in the treatment of early-stage cervical cancer.

Review and critical analysis of the clinical processes of patients who underwent Wertheim-Meigs surgery.

Methods

Retrospective study of 84 patients submitted to Wertheim-Meigs surgery between 2013 and 2020 at Instituto Português de Oncologia (IPO)-Porto.

Results

Among the 84 cases evaluated, the mean age at diagnosis was 50 years and most patients (70,2%) were asymptomatic. The histologic subtype was squamous-cell carcinoma in 51,2% (n=43) of patients, adenocarcinoma in 47,6% (n=40) and adenosquamous carcinoma in 1,2% (n=1). Most patients (85,7%) had stage IB1 disease. Adjuvant therapy was performed in 28,6% of cases, the main indication being lymphovascular invasion.

A total of 69 patients (82,1%) underwent laparotomic approach and 15 patients (17,9%) underwent laparoscopic surgery. There were three intraoperative complications: two in the open surgery group (bilateral ureteral laceration and obturator nerve lesion) and one in the laparoscopic group (vesical laceration). The difference between groups was not statistically significant ($p>0.05$). The mean time of hospitalization reached a statistically significant difference between the open and the laparoscopic groups (9,3 days vs. 6,9 days; $p<0.05$). The laparotomic group had an early post-operative complication rate of 17,4% (n=12) and the laparoscopic group a rate of 6,7% (n=1).

The difference of early post-operative complications between groups was not statistically significant ($p>0.05$).

Amongst the 84 patients, two abandoned follow-up and 3 died precociously to causes not related to the cervical cancer. Of the remaining 79 cases, 39,2% (n=31) completed the 5-year follow-up and were discharged and 60,8% (n=48) maintain hospital surveillance (minimal follow-up time:23 months; mean=49,4 months). At the time of the analysis, 2 patients had had a recurrence (1 in the open surgery group and 1 in the minimally invasive surgery group). The open surgery recurrence occurred in the vaginal vault, liver and lymph-nodes and the patient died at 32 months post-surgery. The laparoscopic recurrence occurred in the vaginal vault. The patient was treated with chemo-radiotherapy and was disease-free at 46 months post-surgery.

Conclusions

In this study, there were no statistically significant differences between the open and laparoscopic groups concerning intra and post-operative complications. The hospitalization time was significantly longer in the laparotomic approach group. There were only two recurrences in this study not allowing us to infer the impact of surgical approach on recurrence rate.

Outpatient adnexal laparoscopic surgery – a year experience

Marta Xavier¹, Inês Filipe Gouveia¹, Marta Campos¹, Evelin Pinto¹, Andrea Quintas¹, Sandra Batista¹

¹Vila Nova de Gaia/Espinho Hospital Center, Gynaecology and Obstetrics, Vila Nova de Gaia, Portugal

Background

Adnexal pathology is a common gynaecological issue and may be found in females of all ages. Ovarian masses are the most common type of adnexal mass. Laparoscopy, when compared to an abdominal laparotomic approach, is associated with fewer peri- and post-operative complications, less blood loss and shorter length of hospital stay for patients undergoing gynaecological procedures. Ambulatory procedures allow to improve patient recovery and reduce institutional costs.

The objective is to describe our centre's experience in outpatient laparoscopic adnexal surgery (salpingo-oophorectomy, salpingectomy, cystectomy, and ovarian drilling).

Methods

Retrospective observational study of women submitted to gynaecological laparoscopy due to adnexal pathology in our ambulatory unit between May 2021 and May 2022 (n= 24).

Results

24 women were included in this study, with a median age of 49-year-old. Previous medical conditions were present in 21 women, with depression (n=6) and breast cancer (n=4) being the most frequent pathologies. Abdominal surgical antecedents were present in 7 patients, with cesarean section being the most common procedure (n=5). The mean Body Mass Index (BMI) was 27 (range 22-35). The ASA Physical Status Classification System was used, and patients were classified as ASA 1 (n=2) or ASA 2 (n=22).

The adnexal laparoscopic procedures performed were bilateral salpingo-oophorectomy (n=12), unilateral salpingo-oophorectomy (n=3), unilateral salpingo-oophorectomy with contralateral salpingectomy (n=3), ovarian drilling (n=4) and unilateral ovarian cystectomy (n=2). Indications for surgery were unilocular cyst (n=7), multilocular cyst (n=4), Polycystic Ovarian Syndrome and infertility (n=4), unilocular tumour with mixed ecogenicity, suggestive of benign cystic teratoma (n=3), surgical castration (n=3), prophylactic salpingo-oophorectomy in BRCA mutation carrier (n=1), multilocular-solid cyst (n=1) and solid tumour (n=1). The mean post-operative hospital stay was 6.1 hours (range 2.5 -9.5). No surgical or medical complications were reported. Histological examination revealed normal or benign lesions.

Conclusions

Although our study has a small number of women, outpatient laparoscopic adnexal procedures seem to be a safe and cost-efficient procedure. A detailed patient history and physical examination play a fundamental role in patient selection, allowing us to minimize the risk of medical and surgical complications as well as selecting the appropriate pathology for an ambulatory setting.

Evaluation of Minitouch Outpatient Procedure with respect to 12 Demographic and Procedure Parameters as a Treatment for Heavy Menstrual Bleeding (HMB)

Junny Chan¹, Yatin Thakur², Gillian Steele³, Vidya Thakur⁴, Suman Kadian⁵, Mohamed Shahin¹

¹Royal Stoke University Hospital, Department of Gynaecology and Obstetrics, Stoke-on-Trent, United Kingdom

²Basildon University Hospital, Department of Gynaecology, Basildon, United Kingdom

³Arrowe Park Hospital, Department of Gynaecology, Upton, United Kingdom

⁴Broomfield Hospital, Department of Gynaecology, Chelmsford, United Kingdom

⁵Royal Stoke University Hospital, Department of Gynaecology, Stoke-on-Trent, United Kingdom

Background

To evaluate the safety and efficacy of Minitouch Outpatient Procedure with respect to 12 parameters, namely, site, user's clinical background, user's Minitouch experience, patient age, parity, cavity length, Caesarean-sections, need for endometrial pre-treatment, menstrual cycle phase, cervical dilatation, need for block/sedation/anaesthesia, and follow-up duration.

Methods

All Minitouch procedures performed by seven users in 2019 in the United Kingdom were evaluated. The procedures followed the National Health Service (NHS) guidelines and Instructions for Use accompanying the device. The seven users at the four sites included five gynaecologists, one registrar and one nurse practitioner.

All patients were routinely referred to the seven users for endometrial ablation with a diagnosis of heavy menstrual bleeding. The procedures were performed using the energy delivery customisation features (e.g., temporary pause, power adjustment) to optimise patient comfort. Relevant data from patient files was anonymised and aggregated. Patients were followed-up as necessary via visits or calls to collect their outcome data. Success was defined as amenorrhea, spotting (oligomenorrhea) or light bleeding (less HMB), plus patient not needing or desiring additional treatment. The patients were typically discharged within 30 minutes post-treatment and were advised to contact their clinical team in case of any complications. The patients were followed up after at least 90 days post-treatment.

Results

A total of 98 Minitouch procedures were identified. All attempted procedures were completed. None required endometrial pre-treatment, menstrual cycle timing, cervical dilatation, cervical or fundal block, sedation, or anaesthesia. 80/98 patients had completed the minimum 90-day follow-up period at the audit. Follow-up data was available for 67 patients. Mean patient age was 45.8 years (n=67, range 31-56), mean parity was 2.1 (n=43, range 0-5), mean C-sections were 0.3 (n=44, range 0-2), and the mean cavity length was 5.5cm (n=56, range 4-8cm). The mean energy dose delivered was 4981J (n=63, range 4000-8400J).

94% (63/67) (p<0.001) patients had successful outcomes. 54% (36/67) patients reported amenorrhea or spotting. The outcomes were consistent across the four sites, between new and experienced users, and across full range of the following parameters - patient age (31-56 years), parity (0-5), cavity length (4-8 cm), Caesarean-sections (0-2), duration of follow-up (96-297 days), and menstrual cycle phase.

There were no major adverse events. Post-treatment, one patient felt faint, one patient experienced nausea and one patient experienced cramping pain prior to discharge.

Conclusions

Minitouch Outpatient Procedure was found to be safe and effective for treatment of HMB in real world outpatient use. Success and amenorrhea/spotting rates were high and consistent across all sites, operators, and patient demographics.

**Exploring European trends and attitudes towards vaginal birth after laparoscopic myomectomy (VBALM).
A survey amongst 65 European endoscopists.**

Alexandros Lazaridis¹, Nicolas Galazis², Mehrnoosh Aref-Adib³, Funlayo Odejinmi⁴

¹Oxford University Hospitals, Gynaecology, Oxford, United Kingdom

²St. Marys Hospital- Imperial College NHS Trust, Gynaecology, London, United Kingdom

³Whipps Cross Hospital- Barts Health NHS Trust, Gynaecology, London, United Kingdom

⁴Whipps Cross Hospital- Barts Health NHS Trust, Gynaecology, London, United Kingdom

Background

Even though fibroids are a prevalent benign gynaecological condition that account for a common surgical intervention (myomectomy) either open (OM) or laparoscopic (LM), there has not been a standardized approach to pregnancies following myomectomy and the mode of delivery because of concerns about uterine rupture.

Methods

We conducted a survey of 65 European (EU & UK) endoscopists who voluntarily completed a standard electronic questionnaire during the 30th annual congress of the European Society for Gynaecological Endoscopy (ESGE) (October 2021 - Rome, Italy).

Results

Sixty-five (65) participants from twenty countries took place on our VBALM survey. Forty-five (45) of them were specialists and twenty were still in training. The median number of laparoscopic myomectomies (LM) was 15/year for trainees and 40/year for specialists/consultants. Fifty-two participants were also practicing obstetrics (80%), while the other 20% only practiced gynaecology.

60% of responders would offer elective caesarean section to their patients while the remaining 40% would allow a trial of vaginal birth after laparoscopic myomectomy (VBALM).

Most important deciding factor for a trial was whether the endometrial cavity was breached, with almost 70% of the responders not allowing VBALM in such cases.

There was no consensus on how soon after LM a patient can try for pregnancy or the duration of labour, the results showed a bimodal distribution. There was significant heterogeneity on preference of induction of labour methods.

Conclusions

Due to the large heterogeneity and lack of evidence-based consensus we need larger population studies to identify best practice.

A national database of outcomes is essential and will help guide management.

A rare congenital mullerian anomaly - case report

Marília Freixo¹, Luísa Cerqueira², Ana Sofia Fernandes², Margarida Martinho²

¹Centro Hospitalar Tâmega e Sousa, Gynaecology, Porto, Portugal

²Centro Hospitalar São João, Gynaecology, Porto, Portugal

Background

Evaluate the importance of the sonography and hysteroscopy for the diagnosis of uterine anomalies by presenting a clinical case.

Methods

Retrospective review of clinical files of a patient with a complex mullerian anomaly.

Results

This is a case of a 23-year-old woman who was admitted to our hospital for further management of a genital tract anomaly. She was followed in nephrology appointments for unilateral renal agenesis but did not present any pathogenic variant in the NGS CAKUT panel; menarche had occurred at age 14; after menarche the patient experienced slightly heavy and painful regular menstruation every 28 days that lasted for 4 days each. She was sexually active and has an etonogestrel implant.

Gynecological examination showed that the vulva development was normal, and the speculum exam revealed a vaginal septum (apparently longitudinal) and two cervices.

Transvaginal sonography showed that the uterine morphology was abnormal, revealed two uterine echoes, what appeared to be complete uterine didelphys bicollis. A hypoechoic area was seen below one of the cervix. The endometrium was in the middle, with a clear display and a thickness of 3 mm. Also, a vaginal duplication was seen. The adnexa were normal, and the right ureter was seen.

Diagnostic hysteroscopy was performed and revealed normal vaginal walls. A small cervix was observed to the right of the vaginal vault. The hysteroscope was introduced through the cervical canal and reached the uterine cavity. After that, an oblique septum that came from under the cervix and ran diagonally to the left was seen. The hysteroscope was introduced through another small uterine cervix. We progressed further into the left-side uterine cavity and showed the uterine orifice of the left fallopian tube. Both uterine cavities were lined with normal-shaped endometrium.

Conclusions

During embryogenesis, the urinary and reproductive system development is closely related, which may explain the ipsilateral renal agenesis with the reproductive tract abnormalities. As such, suspicion should be heightened in patients with a single kidney.

The correct diagnosis of uterine anomalies requires familiarity with diagnostic criteria, recognition of corresponding imaging, and accuracy in obtaining those images. Sonography plays a vital role in diagnosis as the most common initial imaging performed.

This case shows the importance of two easily accessible exams that can be performed in real-time and are a low-cost option for the diagnosis of complex Müllerian anomalies.

First versus second generation endometrial ablative techniques: a retrospective cohort study comparing representation with pain, menorrhagia and long-term outcomes.

Johanna Breen¹, Keith Johnston², David Morgan², Geoff McCracken¹, Michael Graham¹

¹*Craigavon Area Hospital, Obstetrics & Gynaecology, Craigavon, United Kingdom*

²*Antrim Area Hospital, Obstetrics & Gynaecology, Antrim, United Kingdom*

Background

Endometrial ablation has been used for many decades as an alternative to hysterectomy when managing abnormal bleeding. There are a number of techniques currently used in gynaecological practice to achieve this. In first generation techniques such as trans-cervical resection of the endometrium (TCRE) the endometrium is stripped under direct vision. In second generation techniques a device is inserted into the uterine cavity and uses heat or bipolar radiofrequency to ablate the endometrium.

The aim of this project is to compare the outcomes following first generation techniques (TCRE) under three surgeons specialising in this procedure with second generations techniques (Novasure and Thermablate).

Methods

Patients were identified from theatre logs across two sites in Northern Ireland (Craigavon and Antrim Area Hospitals) who underwent an endometrial ablation for menorrhagia. 268 patients were identified of which 80 patients underwent a Novasure endometrial ablation, 107 patients underwent a TCRE, and 82 patients underwent a Thermablate endometrial ablation. Information on preoperative demographics, operative details and postoperative reviews were obtained from the Northern Ireland Electronic database (NIECR).

The primary outcome measured was hysterectomy within 4 years following the procedure. Secondary outcomes included surgical complications, representation with abnormal bleeding or pain and inpatient stay.

Results

Significantly less patients underwent a hysterectomy following a Novasure ablation (7/80, 8.8%) when compared with a TCRE (25/107, 23.4% (p=0.009)). However, when comparing hysterectomy rates between Novasure and Thermablate ablation (7/80, 9% vs 15/87, 17% (p=0.061)) and Thermablate with TCRE (15/82, 18% vs 25/107, 23% (p=0.254)) there was no significant difference.

Significantly less patients represented with abnormal bleeding following a Novasure ablation compared with TCRE (10/80, 12.5% vs 32/107, 30% (p=0.005)). However, there was no significant difference between Novasure and Thermablate (10/80, 13% vs 19/82, 23% (p=0.058)) or between TCRE and Thermablate (32/107, 30% vs 19/82, 23% (p=0.193)) regarding representation with abnormal bleeding.

Significantly less patients represented with pain following a Novasure ablation compared with TCRE (2/80, 2.5% vs 14/107, 13% (p=0.008)). However, there was no significant difference between Novasure and Thermablate (2/80, 2.5% vs 5/82, 6% (p=0.232)) or between TCRE and Thermablate (14/107, 13% vs 5/82, 6% (p=0.089)) regarding representation with pain.

There was no significant difference between the ability to adequately evaluate the uterine cavity at subsequent hysteroscopy between any of the groups, but the numbers were relatively small. Overall, the cavity was visualised in 13/23 cases (56.5%).

Conclusions

This study has shown how Novasure endometrial ablation results in significantly lower rates of hysterectomy, representation with pain or abnormal bleeding after 4 years when compared with TCRE. There was however no difference when comparing Thermablate with both Novasure and TCRE.

How much cost saving can be achieved by introducing a scoring system predicting hysterectomy in women with heavy menstrual bleeding?

Shamma Al-Inizi¹, Sandeep Kaur², Amr Mohammed²

¹Consultant obstetrician and gynaecologist, Obstetrics and Gynaecology- South Tyneside NHS Foundation Trust, South Shields, United Kingdom

²South Tyneside and Sunderland NHS Foundation Trust, Obstetrics and gynaecology, South Shields, United Kingdom

Background

Heavy menstrual bleeding (HMB) is one of the commonest causes of referral to gynaecology outpatient departments. Women suffer a lot during their treatment especially when different uterine sparing medical and surgical interventions have been used prior to hysterectomy.

Women's choice for hysterectomy and complete amenorrhoea should always be kept in mind during the consultation. Different parameters should be also considered including a scan finding of a sizable fibroid, adenomyosis, known endometriosis, associated chronic pelvic pain, dysmenorrhoea, dyspareunia, anaemia, and multiple blood transfusions, and large uterine cavities where most uterine sparing surgical modalities fail.

We introduced a scoring system after reviewing all women referred with HMB and ended up with a hysterectomy in order to calculate the cost-saving in similar women by avoiding the length of time needed for hysterectomy, avoiding suffering, and avoiding performing uterine sparing medical and surgical modalities, which would usually fail.

Methods

We used a detailed electronic data collection proforma where women's details including age, parity, length of HMB, associated pelvic pain, endometriosis, ultrasound evidence of fibroid/adenomyosis, and associated anaemia needing a blood transfusion and women's preference was documented retrospectively. All uterine sparing modalities used were also documented.

We reviewed over 2000 hysterectomy cases performed over the 5 years study period at South Tyneside and Sunderland NHS Foundation trust and identified 300 cases of hysterectomies performed for heavy menstrual bleeding. Histopathology was compared to pre-hysterectomy ultrasound findings.

Results

300 women with HMB ending up having a hysterectomy were included in the study. Age ranged from 31-to 56 with a mean of 45.

36.6% of women had chronic pelvic pain, dysmenorrhoea, dyspareunia, or known endometriosis.

44% had scan evidence of a fibroid > 3 cm and 25% had scan evidence of adenomyosis. 39% of women had failed Mirena IUS and the same number had failed endometrial ablation. 47% of women wished to have complete amenorrhoea during their first consultation.

Histology confirmed that 85% had an abnormal pathology mainly a benign fibroid, adenomyosis, or both.

A scoring system of 1-5 was introduced. Women with a score>3 should be counselled about hysterectomy. Each of the following would score 1 including: scan evidence of a fibroid>3 m, scan evidence of adenomyosis, chronic pelvic pain/endometriosis/dysmenorrhoea, and dyspareunia, persistent anaemia needing a blood transfusion, large uterine cavity >10 cm would score 2.

Significant cost savings would have been made if those women ended up having a hysterectomy from the start which exceeds a hundred thousand pounds.

Conclusions

Triaging women presenting with HMB according to a scoring system is beneficial and aims at significant cost savings and would reduce women's suffering by shortening their treatment journey and improving their satisfaction.

Endometrial polyps: size matters?

Sara Abrantes¹, Patrícia Pereira Amaral¹, Mariana Souto Miranda¹, José Silva Pereira¹, Antónia Nazaré¹

¹Hospital Prof. Doutor Fernando Fonseca, Gynaecology, Amadora, Portugal

Background

Endometrial polyps are hyperplastic overgrowth of glands and stroma on the uterine surface and one of the main causes of abnormal bleeding in women pre and postmenopause. However, incidence is difficult to define because many are asymptomatic. Risk factors include age, obesity, hypertension, tamoxifen, and hormone replacement therapy use as well as genetic syndromes. Main concerns are malignization (rare) and infertility. Hysteroscopy is the gold standard to study endometrial cavity, confirming the diagnosis and allowing treatment. Polypectomy is recommended in postmenopause women and in premenopause if symptoms, infertility, multiple or recurrent polyps, prolapsed polyp, size superior to 15mm or risk factors for endometrial cancer. The choice of instruments depends on surgical training, availability, costs and size and location of polyp, being possible office-hysteroscopy or resectoscopy in operative room.

This work aims to characterize and compare polyps undergoing polypectomy (type, number, location and size) between office-hysteroscopy and operative resectoscopy groups.

Methods

Retrospective descriptive study based on sociodemographic and clinic data of all women with diagnosis of endometrial polyp undergoing office-hysteroscopy during 2021 in Hospital Prof. Doutor Fernando Fonseca (Amadora, Portugal). Statistical analysis through Microsoft Excel®.

Results

In Hospital Prof. Doutor Fernando Fonseca during 2021 there were realized 240 office-hysteroscopies - 73% (n=176) with evidence of endometrial polyp. It was performed total polypectomy in 56% (n=99), partial polypectomy in 3% (n=6), biopsy in 34% (n=59) and no surgical intervention in 7% (n=12). Polypectomy in office setting used scissors and grasping forceps.

Main motives to operative bipolar-resectoscopy after office-hysteroscopy were multiple polyps (36%, n=28), large polyp (30%, n=23) and patient intolerance (17%, n=13).

In the subgroup that underwent total polypectomy, 81% (n=80) were postmenopause, with mainly pedunculated polyps (68%, n=67) of anterior (24%, n=24) and lateral (21%, n=21) location and median size of 17mm. In the subgroup that underwent partial polypectomy, biopsy or no procedure with consequent second time resectoscopy (n=77), 83% (n=64) were postmenopause, with mainly pedunculated polyps (69%, n=53) of lateral location (25%, n=19) and median size of 23mm.

In the subgroup that underwent resectoscopy because of large polyp, polyps had a median size of 33mm.

The difference of polyp size between groups had statistical significance ($p < 0,005$).

There were no differences with statistical significance regard polyp location and type.

Conclusions

Beside surgical skills and experience, polyps characteristics influence the ability of total polypectomy in office-setting. This work corroborates that bigger and multiples polyps are more associated with the need of operative resectoscopy.

Surgeons' obsession for ovarian reserve: time for a reappraisal

Giulia Galati¹, Valentina Bonanni², Marco Reschini³, Alessia Romito⁴, Edgardo Somigliana⁵, Ludovico Muzii⁶

¹*Sapienza- University of Rome, Department of Pediatrics- Obstetrics and Gynecology- Urology, Roma, Italy*

²*Sapienza- University of Rome, Department of Gynecology- Obstetrics and Urology, Roma, Italy*

³*Fondazione IRCCS Ca' Granda Ospedale Maggiore Policlinico, Infertility Unit, Milan, Italy*

⁴*Sapienza- University of Rome-, Department of Pediatrics- Obstetrics and Gynecology- Urology, Roma, Italy*

⁵*University of Milan- Fondazione IRCCS Ca' Granda Ospedale Maggiore Policlinico,*

Department of Clinical Sciences and Community Health, Milan, Italy

⁶*Sapienza University of Rome, Department of Pediatrics- Obstetrics and Gynecology- Urology, Roma, Italy*

Background

During the last two decades, utmost consideration was given to surgically related damage to ovarian reserve, in particular for ovarian endometriomas. However, albeit not univocal, there is growing evidence that the residual ovarian reserve is unremarkable to natural conception. Damage to ovarian reserve may influence responsiveness to ovarian hyperstimulation, and therefore IVF success, but may not affect natural ovarian function up to extremely low residual levels. Provided that the woman has not entered menopause and the remnant reserve is sufficient to ensure regular ovulation, women may normally conceive. If confirmed, this notion would have fundamental implications for surgeons. If surgery can restore natural fertility, the possible surgically related damage to ovarian reserve would be of scant clinical relevance.

Methods

To address this issue, we retrospectively recruited infertile women younger than 40 whose infertility diagnostic work-up was unremarkable (unexplained infertility) and matched them by age and study period to a control group of infertile women who were diagnosed with a severe male factor cause of infertility. Ovarian reserve was not considered for selection. Women with unexplained infertility were considered cases (infertile subjects) while those with male infertility were considered controls (theoretical fertile women). If the null hypothesis (ovarian reserve does not affect natural fertility) is valid, one had to expect similar levels of serum Follicle Stimulation Hormone (FSH), Anti-Mullerian Hormone (AMH), and Antral Follicular Count (AFC) in the two study groups. Conversely, if ovarian reserve impacts on natural fertility, one had to expect lower levels among women with unexplained infertility.

Results

Two-hundred women with male infertility and 200 women with unexplained infertility were included. Baseline characteristics of the two studied groups were mainly similar; only the duration of infertility, parity and BMI mildly differed. The median [Interquartile - IQR] day 3 serum FSH in women with unexplained and male factor infertility was 6.8 [5.9-8.3] and 6.8 [5.7-8.4] IU/ml, respectively ($p=0.86$). The median [IQR] serum AMH was 2.1 [1.2-4.1] and 2.1 [1.4-3.4] ng/ml, respectively ($p=0.76$). The median [IQR] AFC was 14 [9-20] and 13 [8-18], respectively ($p=0.36$). Significant differences did not also emerge when performing dichotomous comparisons using established thresholds for the definition of low ovarian reserve (data not shown).

Conclusions

Ovarian reserve is unremarkable to natural conceptions. Surgeons should not be obsessed by the fear of ovarian damage provided that they are confident that their intervention is able to drastically improve the woman's capacity to naturally conceive.

Use of double mirena ius and hysteroscopy in management of early-stage endometrial cancer in an obese lady with heavy vaginal bleeding

Ejike Nnamani¹, Anusha Sivasuriam¹

¹Prince Charles Hospital, Obstetrics and Gynaecology, Merthyr Tydfil, United Kingdom

Background

Endometrial cancer is the commonest gynaecological cancer in UK and should be suspected in young women with obesity and abnormal uterine bleeding. Use of progestins has been documented as alternative treatment for atypical hyperplasia and early-stage disease in those that decline surgery or are unfit. This abstract aims to assess the efficacy of use of double levonorgestrel (mirena® intrauterine system) for control of bleeding in endometrial cancer.

Methods

We present the investigation and treatment of a 34-year-old nulliparous lady with BMI of 51kg/m², diagnosed with endometrial carcinoma. She presented with continuous vaginal bleeding, had a hysteroscopy and guided endometrial biopsies. The uterine cavity appeared highly suspicious, and the histology confirmed a grade 1 adenocarcinoma. She had an MRI investigation, which confirmed Stage 1a disease. She had no other known medical problems. She declined surgery and wished to try the mirena® intra-uterine system (IUS). She was fully counselled regarding regression rates, and also understood the possibility of progression of disease. The uterine cavity length from the fundus to the internal cervical os was 8cm. She was correctly fitted with a mirena® IUS. Her bleeding continued necessitating introduction of medroxyprogesterone acetate(provera®). She also declined bariatric surgery and not keen on receiving metformin. Her reason for rejecting hysterectomy was not related to fertility as she also declined egg retrieval and ivf consultation.

Results

A subsequent hysteroscopy and targeted biopsies at 3 months revealed that the endometrial carcinoma had regressed. She continued follow up with regular hysteroscopies and endometrial biopsies. She required provera® in addition to the mirena® IUS to settle the vaginal bleeding. Given her high BMI there was reluctance to continue on the provera® as a long-term medication. With the discontinuation of provera® her bleeding recurred. As the uterine cavity length was 8cm a decision was made to insert two mirena® IUS instead of one. One mirena® IUS was inserted at the fundus of the uterus and the second coil was inserted slightly below this. The introduction of the double mirena® IUS was checked with hysteroscopy. She has since stopped bleeding, and her regular assessments have shown that the malignancy has regressed completely. Repeated MRI assessment did not show any invasion into the myometrium.

Conclusions

There was difficulty in controlling bleeding in this lady, therefore, we explored the option of inserting two levonorgestrel IUS, which have given excellent results. Evidence for this is quite scanty and this may be one of the rare instances where two mirena® IUS have been used to achieve symptomatic relief in endometrial malignancy. Furthermore, it opens up the discussion of whether two mirena® IUS could be used in controlling heavy menstrual bleeding which has not been addressed by one mirena® IUS, especially in those women with large uterine cavities.

Resectoscopic approach for the management of uterine fibroids – experience of a tertiary centre

Tiago Meneses Alves¹, Ana Beatriz de Almeida¹, Diana Martins¹, Maria Lúcia Moleiro¹, Helder Ferreira², Rosa Zulmira³

¹Centro Materno Infantil do Norte- Centro Hospitalar Universitário do Porto- Portugal, Department of Gynecology and Obstetrics, Porto, Portugal

²Centro Materno Infantil do Norte- Centro Hospitalar Universitário do Porto- Portugal, Department of Gynecology and Obstetrics- Endoscopy and Endometriosis Unit- Instituto Ciências Biomédicas Abel Salazar – ICBAS- University of Porto- Portugal, Porto, Portugal

³Centro Materno Infantil do Norte- Centro Hospitalar Universitário do Porto- Portugal, Department of Gynecology and Obstetrics- Instituto Ciências Biomédicas Abel Salazar – ICBAS- University of Porto- Portugal, Porto, Portugal

Background

Although most uterine fibroids are asymptomatic, they can be an important cause of abnormal uterine bleeding (AUB), pelvic pain or infertility. The resectoscopic surgery is currently the preferred method for the treatment of symptomatic submucosal fibroids, avoiding invasive interventions such as abdominal myomectomy or hysterectomy.

In this study, we evaluate the safety and efficacy of resectoscopic myomectomy for the management of AUB, resolution of gynaecologic ultrasound findings and improvement of reproductive outcomes.

Methods

A retrospective observational study was conducted. We examined all clinical charts of women who had undergone resectoscopic myomectomy, in a Portuguese tertiary care centre, between January 2018 and December 2021. The clinical indications for myomectomy, procedure complications, symptoms resolution, comparison between ultrasound findings pre- and post-myomectomy and reproductive outcomes were evaluated.

Results

A total of 370 resectoscopic procedures were performed, 115 (31,1%) of which were resectoscopic myomectomies. The mean patient age was 45,6 years (29 to 71). AUB was the main indication for resectoscopic surgery (75,7%); unexplained infertility associated with a submucous fibroids suspected on ultrasound represented 3,5% cases. According to the International Federation of Gynecology and Obstetrics (FIGO) classification, type 1 myomas were the most operated (37,4%). In 30 patients (26,1%) the resection was not complete, 8 of which surgical reintervention was realized. Registered complications were rare. Most of the cases (72,2%) were performed in an ambulatory setting. Approximately 98,2% of the histological studies confirmed leiomyomas. After a follow-up of 1 to 4 months of the myomectomy, AUB symptoms improved in 82,8 % of the patients; the reduction or disappearance of myomas was observed in 77,4% of gynaecologic ultrasounds. Eleven reoperations were executed: 5 myomectomies and 6 hysterectomies (5 for the management of AUB and 1 for the treatment of endometrial stromal sarcoma).

Conclusions

Resectoscopic myomectomy was an effective procedure in the management of AUB cases with a significant reduction or extinction of myomas evaluated on post-procedure ultrasound. The few numbers of cases with infertility problems doesn't allow clear evidence about the benefit of this procedure in conception outcomes.

Service Evaluation of Outpatient Diagnostic and Operative Hysteroscopy

Sioned Powell¹, Khadija Janoowala¹, Caryl Thomas¹, Anju Sinha¹

¹University Hospital of Wales- Cardiff and Vale University Health Board, Gynaecology, Cardiff, United Kingdom

Background

To audit the outpatient diagnostic and operative hysteroscopy service over a six-month period at University Hospital of Wales (UHW), Cardiff in order to improve our services.

Methods

Patients were identified retrospectively using the hysteroscopy register from August 2021 to February 2022. Analysis of the total number of patients referred, the indications for referral, patient-waiting times from referral to diagnostic or therapeutic procedure and number of patients eventually referred for a procedure under general anaesthetic was performed.

Results

A total of 255 patients were referred for outpatient hysteroscopy during the period of our study. Approximately 66% of patients were referred as urgent suspected cancer and 54% as urgent. 47% of patients were seen within 8 weeks of referral. Most of the patients were aged between 50 and 59 (63%). Postmenopausal bleeding (PMB) was the commonest cause of referral (92%). Dysfunctional uterine bleeding (DUB) was the second most common cause of referral (22%) followed by incidental finding of endometrial pathology (12%). There were 142 referrals for PMB: 52 had successful outpatient hysteroscopy out of which 31 were discharged after final histology. Hysteroscopy was abandoned in 8 patients because of pain. 8 patients were referred for further procedure under general anaesthetic. In the DUB group, hysteroscopy was successful in 51 of 57 patients. 37 out of 51 patients who had a successful hysteroscopy were discharged. 3 patients were referred for further procedure under general anaesthetic.

Conclusions

UHW has an effective outpatient hysteroscopy service; however, there is a need to further invest and expand this service to reduce waiting times by incorporating more outpatient therapeutic procedures, increasing staff training and availability of equipment.

Influence of obesity and overweight on clinical outcomes of patients undergoing total laparoscopic hysterectomy

Paulina Costa¹, Ângela Silva¹, Rita Sousa¹, Sara Azevedo¹, Maria Manuel Torrão¹

¹Centro Hospitalar do Médio Ave, Gynecology and Obstetrics, Vila Nova de Famalicão, Portugal

Background

Performing laparoscopic gynecological procedures in obese patients may sometimes be challenging for the surgeon. Although in this population, laparoscopy offers various advantages, such as shorter hospital stay, less post-operative pain and fewer wound infections, they may have a higher risk of other complications such as a higher number of attempts for successful laparoscopic entry and higher rate of conversion to laparotomy.

Methods

We performed a retrospective analysis of the patients who underwent total laparoscopic hysterectomy (TLH) in Centro Hospitalar do Médio Ave in the previous 5 years. We analyzed the complications and outcomes by comparing 2 groups: G1 – normal weight vs G2 – obese/overweight. For statistical analysis, SPSS 25.0 was used with a p-value of 0.05 indicating statistical significance.

Results

In the studied period, 74 women underwent TLH, 33 (44,6%) of them were included in G1 and 41 (55,4%) in G2. Mean body mass index was $22,7 \pm 1,6$ kg/m² in G1 and $29,4 \pm 3,7$ kg/m² in G2. In G2 16 were obese and 25 overweight. Hospital stay did not differ significantly between groups and the same was verified for other post-operative complications such as organ injury, post-operative pain, vaginal cuff dehiscence/bleeding and reoperation. Operative time was higher in G2, with a mean of $3,5 \pm 1,4$ hours, in comparison to G1 (mean of $3,0 \pm 0,7$ hours) although this difference was not significant ($p=0,241$). Conversion to laparotomy only occurred in G2, in 3 patients due to technical difficulties. Cases of post-operative anemia also were all in G2, 4 in total (1 with the need for transfusion and 2 with the need for intravenous iron infusion).

Conclusions

Overall, we consider that TLH can be conducted successfully in patients with obesity or overweight and that these patients are suitable for TLH. Nevertheless, in our sample, this group showed a higher risk of conversion to laparotomy, higher rate of post-operative anemia and longer operative time. After overcoming entry difficulties, these patients are the ones who benefit even more from the advantages of laparoscopic procedures. Further studies with a larger sample may be helpful to provide stronger evidence.

Submucous myomas: analyzing STEPW and ESGE classifications performance in evaluating complete or incomplete removal rates of hysteroscopic myomectomy at Ramón y Cajal Hospital (Madrid, Spain)

Ana Tarjuelo Amor¹, Elena Cabezas¹, Enrique Moratalla¹, Maria Jesús de Pablos¹, Irene Pelayo¹, Jesús Lázaro¹
¹Hospital Universitario Ramon y Cajal, Gynecology Department, Madrid, Spain

Background

To correlate ESGE (European Society for Gynaecological Endoscopy) and STEPW (Size, Topography, Extension, Penetration and Wall) myoma classifications with complete or incomplete hysteroscopic removal in order to analyse if any of these classifications is better than the other one to predict the success rate of hysteroscopic myomectomy at our hospital.

Methods

We evaluated 118 hysteroscopic myomectomies done in our centre between December 2018 and January 2022. Myomas were scored according to the ESGE and STEPW classifications. Only in 78 of the patients both classifications scores were registered. We retrospectively analysed the complete removal rate of each of the groups of myomas based on its ESGE and STEPW punctuation.

Results

According to the ESGE classification there were 11 level 0 myomas, 45 level 1 myomas and 22 level 2 myomas. Using the STEPW classification there were 28 group I myomas (< or = 4 points) and 50 group II-III myomas (>4 points). Of these 50 group II-III myomas, 37 scored STEPW 5-6 and 13 scored STEPW 7-9.

In 15 of 78 patients (19.2%) the myomectomy was considered incomplete. According to ESGE classification in 4 of 56 type 0-1 and 11 of 22 type 2 myomas the removal was incomplete. Using the STEPW classification in 15 of 50 group II-III myomas the removal was incomplete. A second procedure was needed in all of them.

In 63 of 78 patients (80.8%) the myoma removal was complete. According to ESGE classification 52 of 56 type 0-1 myomas and 11 of 22 type 2 myomas were completely removed. Whereas using the STEPW classification 28 of 28 group I myomas and 35 of 50 group II myomas were completely removed.

Conclusions

In our patients both ESGE and STEPW classifications showed significant differences ($p < 0.05$) in the complete removal rate between their two different groups.

We couldn't probe any of the classifications to be better than the other one to evaluate the viability and the degree of difficulty of hysteroscopic myomectomy. But reviewing our data we conclude that when doing a surgical planning it could be interesting to separate STEPW group II-III (>4), which has a 70% complete removal rate, in 2 groups: II and III. None of the articles reviewed made this separation. When we do that, the complete removal rate increases up to 83.8% in STEPW II group (5-6) and decreases to 30.8% in STEPW III group (7-9), delimiting better to which patients should we recommend an alternative non hysteroscopic technique.

Endometrial pathology in the postmenopausal women: a three-year experience of office hysteroscopy in a general Portuguese hospital

Catarina Ferreira¹, Catarina Soares², Inês Rato², Jorge Ribeiro³

¹Hospital Fernando Fonseca, Gynecology, Lisbon, Portugal

²Centro Hospitalar do Oeste, Gynecology and Obstetrics, Caldas da Rainha, Portugal

³Centro Hospitalar do Oeste, Gynecology and Obstetrics, Caldas da Rainha, Portugal

Background

Postmenopausal bleeding usually occurs due to benign gynecological conditions, but for about 10% of women, bleeding after menopause is a sign of endometrial malignancy. The aim of this study was to describe the group of women undergoing office hysteroscopy and to characterise the hysteroscopic and histologic findings.

Methods

In this retrospective study, data from patients undergoing office hysteroscopy in a Portuguese general hospital from 2019 to 2021 was analysed. Categorical variables are presented as frequencies and percentages and continuous variables are expressed as means.

Results

During this period, a total of 307 office hysteroscopies were performed, 186 of them in post-menopausal women (61%). Among these patients, the mean age was 63 ± 8.9 years and 75% had at least one vaginal delivery. Regarding some of the risk factors for endometrial cancer: 49% (n=91) had hypertension, 18% (n=33) had diabetes, 8% (n=14) have done hormone replacement therapy and 2% (n=3) used tamoxifen. The main indications for hysteroscopy were sonographic findings - including endometrial thickening (55%) and suspicion of polyp (31%) - and abnormal uterine bleeding (45% - n=83). The vaginoscopic entry technique was used in 62% (n=115), but cervix dilatation was necessary in 23% (n=42). The procedure was complicated in 19% (n=35) cases due to cervical stenosis in 14% (n=26%), vasovagal syncope in 3% (n=5) and intolerable pain in 2% (n=4). The most frequent intraoperative findings were endometrial polyps (59%, n=92), endometrial hyperplasia (13%, n=20) and endometrial atrophy (11%, n=18). Removal of lesions or endometrial sampling was performed in 73% of hysteroscopies. In 21% (n=39) of cases a second surgical procedure was required. Histopathological examination of the lesions observed by office hysteroscopy revealed endometrial polyp in 61% (n=83), endometrial atrophy in 10%, endometrial hyperplasia without atypia in 4%, atypical hyperplasia in 3% and malignancy in 5% of cases (n=7). All the cases with malignancy had postmenopausal bleeding.

Conclusions

Office hysteroscopy is a minimally invasive procedure, well-tolerated and safe. In this study, endometrial polyp was the most frequent hysteroscopic finding in postmenopausal women. Despite study limitations, mainly due to its retrospective nature and small sample, postmenopausal bleeding appears to be the main risk factor for malignancy, consistent with literature.

Office hysteroscopic findings: a three-year experience from a general Portuguese hospital

Catarina Soares¹, Catarina Ferreira², Inês Rato³, Jorge Ribeiro³

¹*Centro Hospitalar do Oeste, Gynaecology, Caldas da Rainha, Portugal*

²*Hospital Fernando Fonseca, gynaecology, Lisbon, Portugal*

³*Centro Hospitalar do Oeste, gynaecology, Lisbon, Portugal*

Background

Hysteroscopy is the gold standard for the diagnosis and treatment of intrauterine pathology.

The aim of this study is to describe the group of women undergoing office hysteroscopy and to characterise the hysteroscopic and histologic findings.

Methods

In this retrospective study, data from patients undergoing office hysteroscopy in a Portuguese general hospital between 2019 to 2021 was analysed. Categorical variables are presented as frequencies and percentages and continuous variables are expressed as means.

Results

During this period, a total of 307 office hysteroscopies were performed. The mean age at the time of the procedure was 55 ± 13 years and 186 of these patients were postmenopausal women. The majority (75,2%) had at least one vaginal delivery, 32,9% (101) had hypertension and 11,7% (36) had diabetes.

The main indications for hysteroscopy were ecografic findings - including endometrial thickening (40,7%) and suspicion of polyp (35,5%); and abnormal uterine bleeding (of which 16,3% premenopausal and 27% posmenopausal).

The procedures had complications in 13,7% cases, due to cervical stenosis (8,8%), vasovagal syncope (2,9%) and intolerable pain (2,0%).

The most frequent hysteroscopic findings were endometrial polyps (n= 136, 49,8%), endometrial hyperplasia (n=30; 11,0%) and endometrial atrophy (n=19; 7,0%).

Polypectomy was performed in 33,7% and endometrial sampling in 42,1% of the cases.

In 21% (n=39) of the cases, a second surgical procedure was necessary.

Histological examination revealed polyps in 76,2%, endometrial atrophy in 8,3%, included polyps (n=128, 76,2%), endometrial atrophy (n=14, 8,3%), endometrial hyperplasia without atypia in 7,1%, atypical hyperplasia in 3,6% and malignancy in 4,8% of cases. Of the 8 cases of endometrial cancer, all presented with abnormal haemorrhage, one in a premenopausal woman and 7 in postmenopausal women.

Conclusions

Office hysteroscopy is a minimally invasive procedure, well-tolerated and safe.

An investment in training and new surgical instruments can reduce the need of repeating surgical interventions

In this study, endometrial polyp was the most frequent hysteroscopic finding in postmenopausal women.

Despite study limitations, mainly due to its retrospective nature and small sample, postmenopausal bleeding appears to be the main risk factor for malignancy, consistent with literature.

Adnexal masses requiring surgery after hysterectomy – is laparoscopy safe and feasible?

Sara Silva¹, Dora Antunes², Maria João Carvalho³, Francisco Falcão⁴, Fernanda Águas⁴

¹*Centro Hospitalar Tondela-Viseu- EPE, Obstetrics and Gynecology, Viseu, Portugal*

²*Centro Hospitalar Universitário de Coimbra- Faculdade Medicina Universidade Coimbra, Obstetrics and Gynecology, Coimbra, Portugal*

³*Centro Hospitalar Universitário de Coimbra- Clínica Universitária de Coimbra da Faculdade Medicina Universidade de Coimbra, Gynecology, Coimbra, Portugal*

⁴*Centro Hospitalar Universitário de Coimbra, Gynecology, Coimbra, Portugal*

Background

To analyze the safety and feasibility of laparoscopy after hysterectomy regarding adnexal pathology and compare surgical morbidity between this subset of patients and women without prior hysterectomy.

Methods

A single-institution, retrospective review was conducted considering women who underwent laparoscopic surgery for adnexal or pelvic masses between September 2019 and February 2022. Operative time, blood loss estimation, peritoneal adhesion grade, length of hospital stay, and surgical morbidity were ascertained. A p-value less than 0.05 was considered statistically significant.

Results

A total of 66 women were submitted to laparoscopy due to a pelvic mass, 16 (24.2%) had a history of prior hysterectomy (group 1). The majority previously underwent total hysterectomy (81.25%, n=13), 2 (12.5%) had hysterectomy and bilateral salpingectomy and 1 (6.25%) hysterectomy and unilateral adnexectomy. Indications for prior hysterectomy were mainly abnormal uterine bleeding (31.2%, n=5) and uterine leiomyoma (18.75%, n=3). The median time interval from hysterectomy to diagnosis of the adnexal mass was 13±13.3 years. Hysterectomies were performed by laparotomy in 14 (87.5%) cases and vaginal in 2 (12.5%) cases. The median age at the time of adnexal surgery was similar amongst women with and without prior hysterectomy (61,00±10.1vs. 62.5±10.3 years, p=n.s.). In patients with prior hysterectomy, operative time was longer (median 115±35.9 minutes vs 70±27,0 minutes, p<0.001), strong adhesions were found more frequently (p < 0.001) and blood loss estimation was higher (median 35.0±36.2 mL vs 12.5± 22.2 mL, p<0.008). No significant differences in hospital stay were found. Iatrogenic serosal tear amongst women in group 1 occurred twice and small bowel perforation once in group 2. Laparoconversion was needed in 2 cases, one in each arm, due to extensive adhesions and lack of access to the pelvic cavity. The majority of adnexal masses requiring reoperation after hysterectomy arised from the ovary and were benign. Amongst women with prior hysterectomy, 3 adnexal masses were classified as suspicious according to IOTA Simple Rules and 1 was malignant on histological analysis. In the other group, 1 adnexal mass was suspicious on ultrasound and was determined malignant on hystology. No adnexal masses classified as benign on ultrasound were malignant on histological examination. The most common histological diagnosis was serous cystadenoma in both arms.

Conclusions

Laparoscopic surgery on residual adnexae is complex, though safe and effective. In patients with prior hysterectomy, adnexal surgery is more time consuming, associated with higher blood loss estimation and strong adhesions were frequently found.

Gender Inequality: The Impact of Operating Table Height on Laparoscopic Performance and Surgeon Performance

Sophie Broughton¹, Visha Taylor¹, Vik Khullar¹

¹St Mary's Hospital- Imperial College Healthcare, Gynaecology, London, United Kingdom

Background

Operating tables favour the male surgeon performing open surgery, posing a potential height barrier affecting females as surgeons of shorter stature. This is exacerbated in laparoscopy where operating height is raised due to induced pneumoperitoneum and Trendelenburg positioning for gynaecology surgery.

This study aimed to investigate the optimal relationship between the height of the surgeon and the laparoscopic operating height.

Methods

Gynaecology students, trainees and consultants were recruited. A laparoscopic simulation study was performed at 4 'operating' heights determined by the participants' floor to elbow height measurement (cm). A factor of 0.5, 0.7, 0.9 and 1.1 was applied to the elbow height to set the 'operating' height. Time to task completion, errors made, and surgeon comfort using a Visual Analog Score questionnaire were measured. GraphPad Prism 9.0 and SPSS 28.0 were utilised for statistical analysis.

Results

There were 30 participants. Simulation at the factor of 0.7 elbow height yielded a faster time to task completion ($p = 0.026$) with fewer errors ($p = 0.023$) compared with performance at the highest simulated height with a factor of 1.1 to elbow height.

There were increased precision errors for simulations at 1.1 factor of elbow height compared to factor 0.7 ($p = 0.021$) and increased bimanual dexterity errors compared to all other heights.

Overall comfort scores were highest for simulation at factors 0.7 and 0.9 to elbow height. Simulation at factor 1.1 of elbow height was associated with increased shoulder discomfort ($p < 0.05$).

There were no differences in the simulation times, number of errors or comfort score between males ($n=14$) and females ($n=16$) for the simulation study. However, the mean elbow height differed between males ($113.0\text{cm} \pm 5.61$, $n=75$) and females ($104.9\text{cm} \pm 5.48$, $n=75$) ($p < .0001$).

Conclusions

Simulation at the operating level of factor 0.7 of elbow height optimises performance, with optimal comfort at factor 0.7 to 0.9. To accommodate the depth of the pneumoperitoneum (~35cm) and Trendelenburg positioning (~5cm), a table height range of 28cm-112cm is necessary to accommodate this. However, available operating tables range from 72cm-112cm, appropriate for under 25% of males and not appropriate for females.

Laparoscopic operating tables with a lower height range are therefore necessary to optimise surgeon performance and wellbeing without bias against those with shorter stature. Ergonomic training and further guidelines should be developed.

Learner satisfaction with animal tissue model simulator for laparoscopic management of ectopic pregnancy

Sule Medha¹, Neeraja Kuruba²

¹Norfolk and Norwich University Hospital, Gynaecology, Norfolk, United Kingdom

²Norfolk and Norwich University Hospital, Gynaecology, Norwich, United Kingdom

Background

To determine learner satisfaction with animal tissue model simulator developed to train novice gynaecology trainees in performing a laparoscopic salpingectomy/salpingostomy

Methods

The animal tissue stimulator model was developed at the Norfolk and Norwich University hospital clinical skills laboratory by a group of minimal access surgeons to train trainees develop skills in laparoscopic salpingectomy. It uses pig intestine and cherry tomatoes. The trainee cohort was made of trainees at different levels of their training and included novices who have not performed the procedure before, as well as those who have varying levels of competency in the procedure up to the level of independent practice. Following completion of training session, the trainees were given a questionnaire to evaluate the animal tissue model with respect to its resemblance to real life case, resemblance in skills to real life while operating on the model, whether the model helped them improve their skills, it was useful and their opinion on whether such a model should be regularly used to improve skills. Free comments from the trainees were collated

Results

10 trainees from speciality training year 2 to completion of speciality training took part in the laparoscopic training for laparoscopic salpingectomy/salpingostomy using the animal model simulator.

All the scores were calculated on a scale of 1-10. The score for resemblance to real life cases was a mean of 8.4 (1=no resemblance and 10=very high resemblance), similarity to skills required at surgery was 9 (1=no similarity and 10=very high similarity), improvement in skills for salpingectomy was a mean of 9.2 (1=no improvement and 10=significant improvement) and usefulness to regularly improve skills was 9.6 (1 = not useful to 10 = very useful).

The overall satisfaction rates regarding the usefulness were a mean of 9.8 and S.D 2.04

Conclusions

Laparoscopic management is the gold standard for surgical management ectopic pregnancy and competency at this skill is a requirement for every trainee. Training novice surgeons in specific laparoscopic procedures can be challenging for the trainer. The opportunity to be trained for laparoscopic management of ectopic pregnancy in real time scenario varies, depending on the time and the clinical condition of the patient. There is high fidelity, high-cost simulators in the market but may not be easily and regularly available to all. The animal model developed by us is low cost, repeatable multiple times and has high scores for its face validity and usefulness leading to high learner satisfaction. There was very little difference noted among trainees of different levels of competency for the procedure, thus it being accepted by trainees of all levels who want to master the procedure.

Mullerian malformations and endometriosis: is it a coincidence?

Daniela David¹, Joana Mafra¹, Ângela Rodrigues¹, Maria João Carvalho¹, Fernanda Geraldés¹, Fernanda Águas¹

¹Centro Hospitalar e Universitário de Coimbra, Gynecology Department, Coimbra, Portugal

Background

Uterine malformations are associated with higher rates of infertility, spontaneous abortions, preterm births and endometriosis. The aim of this study is to determine if there is an association with endometriosis in patients with uterine malformations

Methods

A retrospective study of patients with uterine malformations who were admitted to our hospital between January 2015 and March 2022. All uterine abnormalities were classified by 2013 ESHRE/ESGE consensus. For the diagnosis of endometriosis, we considered the histological report, laparoscopic and MRI findings suggestive of endometriosis.

Results

In our series, we found 116 cases of women with Mullerian anomaly, of whom 19 (16,3%) had endometriosis. The mean age at diagnosis was 27,3 [12-47] years. In this population, septate uterus (60,3% n=70) was the most common malformation, followed by bicorporal uterus (18,9% n=22), uterine aplasia (15,5% n=18) and hemi-uterus (3,4% n=4). In 14 (12,1%) of these patients, the malformation was considered obstructive. The main symptom was infertility (19,8%), followed by dysmenorrhea (16,7%). Ultrasonography findings consistent with endometriosis were described in 7,8% and 33,6% underwent an MRI scan, confirming endometriosis in 12,8%. Laparoscopy was performed in 24,1%, with findings consistent with endometriosis in 60,7% of cases. Peritoneal endometriosis was found in 14,7% of patients, 5,1% had ovarian endometriosis and two women had deep endometriosis. Endometriosis was diagnosed more frequently in the obstructive malformations group (42,9% vs 12,7%, p=0,04).

Conclusions

Our results seem to support an association between uterine malformations, particularly obstructive malformations and the development of endometriosis. Awareness of the increased prevalence of endometriosis in patients with uterine abnormalities could facilitate early diagnosis of endometriosis and prompt intervention.

Le Fort Colpocleisis – revisited procedure: about two clinical cases

Fernanda Cristina Alves¹, Mariana Morais¹, Mário Moura¹, Yida Fan¹, Ana Moreira¹, Osvaldo Moutinho¹

¹Centro Hospitalar de Trás-os-Montes e Alto Douro, Ginecologia/Obstetrícia, Vila Real, Portugal

Background

Pelvic organ prolapse (POP) affects millions of people worldwide. In Portugal, there was an 105% increase on the total number of hospital admissions for POP surgery between 2000 and 2012.

On one hand, reconstructive surgery corrects the prolapsed vagina and aims to restore normal anatomy, on the other, obliterative surgery rectify prolapse by removing and/or closing off all or a portion of the vaginal canal (colpocleisis) to reduce the viscera back into the pelvis.

The Le Fort partial colpocleisis is based on the premise that apposition of the vaginal walls could prevent uterine prolapse and that a widened genital hiatus may lead to unsuccessful outcomes.

This study is aimed to review and describe the most important aspects of the Le Fort procedure, surgical indications and possible outcomes of this technique. In addition, the authors intend to report their recent experience regarding this surgical approach.

Methods

Data were obtained from the patients clinical database including demographics, comorbidities, medications, and evaluation of pelvic organ prolapse using the simplified pelvic organ quantification system (simplified POP-Q).

Operative characteristics were recorded, and surgical results were assessed in function of intraoperative and postoperative surgical complications, hospital stays, necessity of further intervention and satisfaction rates.

Results

Two patients were submitted to the procedure in our institution. One of them was 80 years old and the other one was 75 years old, both with multiple co-morbidities. Mean operative time was 75 minutes and mean hospital stay was 3 days. No intraoperative or postoperative complications occurred. Both patients were satisfied with the procedure.

Conclusions

Le Fort colpocleisis is a highly effective and low-risk procedure: success rates range from 90-100%, with long-term success rates of 78%. Besides it does not appear to alter body image and regret after the procedure is uncommon.

Our results confirm the efficacy, the low morbidity rate and high satisfaction level with this procedure.

This way, it remains an excellent surgical option for the elderly patients with advanced pelvic organ prolapse who cannot tolerate more extensive surgery and/or who aren't planning future vaginal intercourse.

Laparoscopic unilateral adnexectomy or laparoscopic removal of a large cystic, ovarian cyst in a 45 year old woman? Which one is safer?

*Asimakis Pappas*¹, *Christina Ifigeneia Sierrou*², *Iliana Mamouri*³, *Dimitrios Kortesiadis*⁴, *Gennaro Castaldo*⁵, *Georgios Salvanos*⁶

¹*Iaso Maternity Hospital, Obstetrics Gynaecology, Marousi, Greece*

²*Evangelismos General Hospital- Athens- Greece, Radiology, Athens, Greece*

³*Iaso Maternity Hospital, Midwifery, Marousi, Greece*

⁴*National Insurance Institute, Obstetrics & Gynaecology, Athens, Greece*

⁵*Mitera Maternity Hospital, Obstetrics & Gynaecology, Marousi, Greece*

⁶*Elena Maternity Hospital, Obstetrics & Gynaecology, Athens, Greece*

Background

A 45 years old lady, fit and healthy, presented with a large ovarian cyst measuring 6 centimetres on transvaginal Ultrasonography (US) . Color Doppler US identified vascularized components within the mass. Magnetic Resonance Imaging (MRI) was used to evaluate the ovarian tumour. The ovarian cyst was cystic, not solid, with a maximum diameter of 6 cm. There was presence of papillary projection (vegetation) and thick wall and septa greater than 3 mm in a cystic lesion

It is well known that benign ovarian diseases can simulate malignancies. The knowledge of clinical syndromes and MRI features of these conditions is crucial in establishing an accurate diagnosis and determining appropriate treatment.

All tumour markers were normal. She complained of lower abdomen pain, dyspareunia, and bowel problems. She has 2 children delivered vaginally many years ago.

Methods

Laparoscopic adnexectomy is a very well-standardized procedure.

Laparoscopic removal of the ovarian cyst or laparoscopic unilateral adnexectomy using pneumoperitoneum is hindered by several factors, such as the risk of perioperative bleeding, and the risk of conversion to laparotomy. Its major risk is the injury of the ureter at the level of the infundibulopelvic (IP) ligament.

Patient is placed in lithotomy position. Routine skin preparation using alcoholic chlorhexidine for skin and aqueous povidone-iodine for vagina and vulva. A uterine manipulator is placed. Pneumoperitoneum is achieved by the surgeon's preferred method of entry. A 10 mm port is inserted on the patient's left side. The port is placed 1 cm lateral to the surface landmark of McBurney's point – one third of the way between the anterior superior iliac spine (ASIS) and umbilicus. This is done to avoid the inferior epigastric vessels running along the anterior abdominal wall. Port sites may vary depending on size of the cyst, previous surgeries, and surgeon preference. Two further 5 mm ports are placed – one on the right side and the other in the high-suprapubic position.

The infundibulopelvic (IP) ligament was cut after diathermy was applied. The fallopian tube was cut as well as the ovarian ligament, after cautery was applied.

A laparoscopic bag was applied, and the adnexa was removed as a piece through left lateral trocar.

Results

The adnexa was removed safely without spillage during laparoscopic management of suspect adnexal mass.

The patient stayed only one night in the hospital. The next day was discharged home.

Conclusions

The laparoscopic management of suspect adnexal mass at women of age 45 or more should include adnexectomy in a laparoscopic bag instead of laparoscopic removal of the cyst of the ovary.

1. Pierce N, Narayanan P, Sahdev A, Reznik R, Rockall A. Ovarian lesions pose diagnostic dilemmas. *Diagnostic Imaging Europe*. 2008;24(3):14–18.

2. RCOG, Royal College of Obstetricians and Gynaecologists. Management of Suspected Ovarian Masses in Premenopausal Women. Guideline no. 62. 2011.2.

Adnexal surgery using vNOTES: the first results in the Netherlands

Rebecca Henschen¹, Ilse Bekkers¹, Nicol Smeets¹, Martine Wassen¹

¹Zuyderland Medical Centre, Gynaecology, Heerlen, The Netherlands

Background

NOTES (Natural Orifice Transluminal Endoscopic Surgery) is an emerging minimal invasive surgery technique. In 2019, the first vaginal NOTES (vNOTES) hysterectomy in the Netherlands was performed in the Zuyderland Medical Centre (MC)¹; vNOTES expertise centre in Europe. With the development of expertise and knowledge about vNOTES, research shows that adnexal surgery with vNOTES is a safe and non-inferior option compared to laparoscopic adnexal surgery². In this abstract, we present the first 23 cases of adnexal procedures with vNOTES in the Netherlands.

Methods

It concerns a prospective data collection of patients who received adnexal surgery with vNOTES between March 2020 and March 2022 in the Zuyderland MC. Baseline characteristics, peri-operative- and postoperative outcomes were registered and analysed.

Results

The study population (n=23), with a mean age and BMI of respectively 44 years (range 25-72) and 26.2 kg/m² (range 20.4-30.9), had an average vaginal parity of 1 (1-3). A total of 23 adnexal vNOTES procedures were performed; 14 bilateral salpingectomy because of definitive contraception, 1 unilateral salpingectomy because of extra uterine gravidity, 7 bilateral and 1 unilateral salpingo-oophorectomy because of ovarian cysts (n=6) and prophylactic surgery because of genetic predisposition (n=2). Mean surgery time was 42 minutes. There were no conversions and intra-operative complications, with a mean blood loss of 30mL (range 5-300) and CO₂ use of 35.8 L (range 11.8-103). In 83% (n=20) same day discharge was achieved. There were 2 post-operative complications; 1 urinary tract infection (Clavien Dindo grade 2) and 1 phlebitis (grade 1).

Conclusions

This abstract shows the first results of adnexal vNOTES surgery in the Netherlands. Adnexal surgery using vNOTES is a feasible and safe technique with the advantages of less pain, blood loss and no scars. This is in line with earlier literature^{2,3}. However, it concerns a small study group, future research is necessary to clear up the differences between vNOTES and conventional laparoscopy regarding adnexal surgery.

Literature:

1. Bekkers IPW, Wassen MMLH, Belgers HJ, de Krom G, Smeets NAC. Nieuwe manier om baarmoeder te verwijderen 'Natural Orifice Transluminal Endoscopic Surgery', Ned Tijdschr Geneeskd. 2020;164:D488.
2. Baekelandt J, De Mulder PA, Le Roy I, Mathieu C, Laenen A, Enzlin P, Morlion B, Weyers S, Mol BWJ, Bosteels JJA. Adnexectomy by vaginal Natural Orifice Transluminal Endoscopic Surgery versus laparoscopy: results of a first randomised controlled trial (NOTABLE trial). BJOG 2021;128:1782–91.
3. Lee CL, Wu KY, SU H, Ueng SH, Yen CH. Transvaginal Natural-Orifice Transluminal Endoscopic Surgery (NOTES) in Adnexal Procedures. JMIG 2012;19:509-13.

Effectiveness of the 'One Step' Outpatient Hysteroscopic Management Of Endometrial Polyp In Maidstone And Tunbridge Wells NHS Trust.

Osemen Okojie¹, Milica Perovic¹, Ying Yiing Lou¹

¹Maidstone and Tunbridge Wells NHS Trust, Women and Children, Kent, United Kingdom

Background

Outpatient hysteroscopy is a viable option in managing endometrial polyps in properly selected women, avoiding the risks associated with general anaesthesia and other complications. The 'one step' process, in which, after a pelvic ultrasound scan, an operative hysteroscopy is done, rather than first a diagnostic hysteroscopy before an operative hysteroscopy was introduced, as a cost saving approach, and to reduce repeat hospital attendances during the pandemic and improve patient satisfaction. We describe a 1-year review of the procedures done in the outpatient operative hysteroscopy clinic.

Methods

This was a retrospective review of hysteroscopic endometrial polypectomy done with the MyoSure device from January – December 2021. Data regarding the effectiveness of the service, similarity between ultrasound and hysteroscopic findings and patient satisfaction was reviewed, analysed, and presented with descriptive statistics.

Results

A total of 100 procedure were done and a total of 44 patient feedback forms were retrieved after the procedure. 45/100 (45%) of patients were postmenopausal and the most prevalent symptoms were post-menopausal bleeding 40/100(40%) and heavy menstrual bleeding 36/100 (36%). During the period of review, 60% of MyoSure procedures were done per clinic. 77/79 (97%) of endometrial polyps were completely removed, while 2/79(3%) were partially removed. In 21/100 (21%) of cases, the MyoSure procedure was not done, due to no polyp seen in 14/21 (66.7%), while in 2/21 (9.5%) each, the reasons for abandoning the procedure were a stenotic cervix, discomfort, and in 1/21 (4.8%), there was poor vision with the scope. In 43% of pelvic ultrasounds prior to the MyoSure procedure, there were similar findings between the scan findings and hysteroscopic findings. Forty-four patients filled the patient feedback forms. All 44/44 (100%) felt being supported throughout the procedure and felt the procedure was well explained to them prior. 41/44(93.2%) received the information leaflet prior to procedure. The highest pain threshold recorded was 7 using the visual analogue score in 12/44(27.3%), while majority of the patients had a pain threshold of less than 7. In 68/77 (88%), the histological findings of completely removed polyps was benign.

Conclusions

Outpatient operative hysteroscopy is effective in managing endometrial polyps in women who are carefully selected. Improving pelvic scan accuracy prior to the procedure can further optimize the service by ensuring scans are done where possible between day 5- 10 of the menstrual cycle, when the endometrium is thinnest, to increase sensitivity of diagnosing endometrial polyps prior to operative hysteroscopy.

“Digital transformation in MIS”

*Olarik Musigavong*¹

¹*Chaophya Abhaibhubjejr Hospital, Obstetrics and Gynecology, Prachinburi, Thailand*

Background

2022 is the era of digital disruption. Many technologies such as artificial intelligence (AI), augmented reality (AR), big data, blockchain, cloud computing, fifth-generation technology for the broadband cellular network(5G), internet of things (IoT), quantum computing, virtual reality(VR), metaverse, etc. Especially pandemic of COVID-19 is the catalyst of technology implementation. Gartner defines digital transformation as “anything from IT modernization (for example, cloud computing), to digital optimization, to the invention of new digital business models”. Minimal invasive surgery adopts many technologies such as 5G for telesurgery and VR for a training program. The Healthcare industry and providers have to understand these technologies for application in daily practice, for example, to deliver better care for the patient, better training programs, and optimize the cost of treatment.

Methods

Review the article in PubMed, google scholar, Scopus since 2000-2022, Article publish in English.

Results

Digital transformation in MIS use in the training program, patient care pre-op, intra-op, post-op, etc. Most advanced technology such as artificial intelligence augmented reality, and 5G integrate in the solution

Conclusions

Digital technology can improve patient care and healthcare provider capability. Surgeons need to have an open mindset to continuously learn new things and apply these techniques in daily practice for the optimal goal is the patient benefit.

Full Endoscopic Non-Vaginal Phase VNOTES Hysterectomy (Total VNOTES Hysterectomy) on obliterated culdesac Patient

*Ichnandy Rachman*¹

¹Fertility Center Gatot Soebroto Central Army Hospital- Jakarta Indonesia, Obstetry Gynecology, Selatan, Indonesia

Background

Vaginal hysterectomy (VH) has been recommended as the route of choice on our daily practice; however, its application is restricted by the poor visualization and limited space for manipulation, and that are especially notable uteri that present without descensus or with adhesions. When pathology is not confined to the uterus (adnexal pathology, known or suspected, adhesions, and endometriosis), thereby precluding VH, it is advisable to perform laparoscopic assisted vaginal hysterectomy (LAVH) to restore anatomy or to free the adnexal before proceeding to VH. LAVH has its place where there is uncertainty of a successful VH, or in order to perform adhesiolysis, treat endometriosis, and restore pelvic anatomy.

Vaginal NOTES Hysterectomy is a marriage between the vaginal approach hysterectomy technique combine with the advantage of single port Laparoscopy technique to overcome the limitation of vaginal hysterectomy while maintain the benefit of it. Su et al, published the first series of 16 women undergoing transvaginal NOTES (vNOTES) hysterectomy in humans in 2012. Many publications have confirmed vNOTES to be a safe and feasible procedure for hysterectomy and also adnextomy, but no for patient with obliterated culdesac.

Methods

We perform this technique at Gatot Soebroto Indonesia Army Central Hospital the Presidential Hospital for adenomypsis patient with obliterated culdesac. Full Endoscopic non vaginal phase VNOTES Hysterectomy or what we call Total VNOTES Hysterectomy is perform by eliminating the vaginal phase by directly put the wound retractor in the vagina and the single port on top of it.

Results

We performed 4 cases of Total VNOTES Hysterectomy from April 2021 to April 2022 (limited number operation due to covid) and on all patient we manage to perform hysterectomy safely without any complication. This modification technique will make us able to perform adhesiolysis safely under the scope and on what we thought used to be contraindication for VNOTES hysterectomy patient with obliterated or adhesion in culdesac.

Conclusions

Full Endoscopic phase vaginal NOTES hysterectomy / Total Vnotes Hysterectomy technique are safe and effective for adhesiolysis on the culdesac area. It will need certain learning curve and time to master the classic VNOTES hysterectomy before continuing to perform this technique.

Hysteroscopic Management of Asherman's Syndrome

Shrikant Ohri¹, Namrata Ray²

¹Newlife Hospital, gynaecological laparoscopic surgeon, Varanasi, India

²Newlife Hospital and Healthcare pvt ltd, obstetrics and gynaecology, varanasi, India

Background

Asherman syndrome is common in countries like India, predominantly due to a prior intrauterine operative trauma. If symptomatic it may result in hypo or amenorrhea, infertility, and pregnancy complications.

Methods

Current methodology of diagnosis with 3D USG and Hysteroscopic treatment to restore the uterine cavity have given clinically effective results. Re-adhesion prevention plays a major role in the management.

We discuss all these modalities in the treatment of Asherman syndrome.

Results

3D USG combined with Hysteroscopic Surgery and re-adhesion prevention methods have excellent outcome in terms of symptom relief and fertility.

Conclusions

Asherman syndrome management with 3D USG and Hysteroscopic procedure is effective for uterine restoration with high pregnancy rate outcome.

A rare case of ovarian ectopic and corpus luteum at the same site; with successful conservation of ovary.

Asma Khalil¹, Muhammad Abbas Khaled¹

¹King Abdulaziz Medical City- Ministry of National Guard Health Affairs. King Saud bin Abdulaziz University for Health Sciences, Obstetrics and Gynecology, Jeddah, Saudi Arabia

Background

Ovarian pregnancy is uncommon form of ectopic pregnancy with an incidence of 1/7000-1/40,000 live births and 0.5-3% of all ectopic pregnancies. We present a rare case of ovarian ectopic seen at the same site as corpus luteum.

Methods

A 26-year-old lady, G2P1 presented to the emergency department with severe lower abdominal pain. She had a previous Caesarean section 4 months ago for abnormal CTG in early labour. She was unsure of her periods and was not breastfeeding. This was her second attendance to ER. Three days prior to that she presented with severe left sided pain. At that time, she was diagnosed with renal colic although her HCG was 2373. She discharged herself against medical advice during her first visit before ultrasound. She had past history of cardiac disease, Patent ductus arteriosus closure, severe mitral regurgitation and tricuspid regurgitation.

At her second presentation, she was complaining of severe pain. Her HCG was now 3730. Haemoglobin had dropped to 7.8 from 11.9 in 3 days. Ultrasound showed a large lesion in right adnexa, separate from ovary measuring 7.3 x 4.4 x 7.7 cm. There was moderate free fluid in pelvis. Both ovaries were seen on scan as normal. The diagnosis was of impending rupture of a tubal ectopic pregnancy.

She was taken for urgent Laparoscopy and proceed. Intraoperatively, both ovaries and tubes were found to be normal. However, there was a haemorrhagic cyst seen on left ovary which was bleeding. There were 2 litres of haemoperitoneum. Electrocautery was used to obtain haemostasis. Haemostatic agent was applied at the base of the cyst. The sample was sent for histopathology. Patient had uneventful recovery.

Histopathology confirmed the diagnosis of haemorrhagic corpus luteum and ovarian ectopic with immature chorionic villi.

Results

Finding of ovarian ectopic is very rare and finding ovarian ectopic at the same site as hemorrhagic corpus luteum is even rarer. We could not confirm the diagnosis operatively. It was deemed as pregnancy of unknown location. Patient was given Methotrexate single dose intramuscular. The final diagnosis was reached only after histopathology review.

Conclusions

This case demonstrates diagnostic difficulty in the presence of double findings intraoperatively. Our approach led to saving of the ovary and resolution of the ovarian ectopic.

Humble beginning, but we've boarded the train! Our experience of starting total laparoscopic hysterectomy service at a teaching hospital in a conservative society.

Asma Khalil¹, Nouf Harbi¹

¹King Abdulaziz Medical City- Ministry of National Guard Health Affairs. King Saud bin Abdulaziz University for Health Sciences, Obstetrics and Gynaecology, Jeddah, Saudi Arabia

Background

Hysterectomy is one of the most common procedure performed in Gynaecology. Traditionally, abdominal approach has been used, with more than half of the hysterectomies still done via laparotomy. Vaginal and laparoscopic approach are associated with less blood loss, quick recovery and fewer abdominal wall adhesions compared to abdominal approach. We share our experience and initial data from starting the total laparoscopic hysterectomies in a teaching hospital in Saudi Arabia. We discuss our experience, patient details, complications and learning curve. Although our numbers are still very small, and we are still taking our baby steps but we have boarded the global train to innovation and development.

Methods

All the cases have been performed jointly by the same two surgeons. The first case was performed nine months ago and since then eleven cases have been done so far.

Age range from 45 – 59. Parity from P0 to P9. Indication for hysterectomy was abnormal uterine bleeding in 3 cases, endometrial hyperplasia (on histology) in 2 cases, postmenopausal bleeding in 2 cases, menorrhagia in 2 cases and fibroids were present in 3 cases and one case was performed for large ovarian cyst 12x8 cm.

Ten out of 11 cases were completed laparoscopically, whilst one case was converted to laparotomy due to technical difficulties and poor view. Operating time ranged from 135 to 233 minutes. Average blood loss was around 100 ml. In 70% of the cases, vaginal cuff was closed by intracorporeal suture and in the rest, it was closed vaginally. There was bladder injury in one case which was repaired laparoscopically. However, that lady had previously had TVT and sacro-spinous fixation. Histology was benign in 90% of the cases with majority (50%) showing adenomyosis. Majority of our patients were discharged the next day

Results

As we are in a teaching hospital, our operating time is longer due to the teaching and training of our residents. Our population, due to cultural values, are very reluctant to have hysterectomy performed. They will choose it only as a last resort when all other options have been exhausted. That's why the case selection for laparoscopic hysterectomy is limited. Furthermore, in almost all our cases there were issues like large fibroids, high BMI, ovarian cyst and bulky uterus.

Conclusions

Laparoscopic hysterectomy has clearly shown to reduce the patient stay and improve patient experience. We will continue to do ongoing review of our cases to improve our outcomes and propose to have an elaborate review of our learning curve in due course. At the same time, we will be continuing to do teaching and training. We are aware of our very humble start in the ever-expanding global stage but we are determined to be part of it.

Adnexal torsion with gangrenous fallopian tube – a diagnostic nightmare.

Asma Khalil¹, Taghreed Shams¹

¹King Abdulaziz Medical City- Ministry of National Guard Health Affairs. King Saud bin Abdulaziz University for Health Sciences, Obstetrics and Gynaecology, Jeddah, Saudi Arabia

Background

Ovarian torsion is fifth most common gynaecological emergency. Adnexal torsion is twisting of the ovary and the fallopian tube, interrupting the arterial supply, and causing ischemia leading to gangrene. However, the exact incidence of adnexal torsion is not known. The risk factors are pregnancy, ovulation induction and cyst more than 4 cm in size. Adnexal torsion of normal adnexa is rare and is more common in children than adults. Adnexal torsion causes sudden, severe pelvic pain and sometimes nausea and vomiting. For days or occasionally weeks before the sudden pain, women may have intermittent, colicky pain, presumably resulting from intermittent torsion that spontaneously resolves.

Methods

We present a rare case of adnexal torsion in which there was a delay in diagnosis leading to gangrenous fallopian tube and unilateral salpingectomy. This is a 24-year-old, single (not sexually active) lady who presented with chronic pelvic pain for a year. She had multiple visits to Emergency room (ER) with pelvic pain. In addition, she had been to private hospitals with similar complaints of pain requiring analgesia. One month prior to the final presentation she presented to ER with exacerbation of her symptoms. MRI was done and demonstrated an ovarian cyst 2x3 cm likely to be endometrioma. However, a week later, upon review of the images it was reported that there is ovarian torsion. She presented ten days later to ER with severe pain, ultrasound showed that the ovarian cyst on left side had increased in size to 4x5 cm and there was demonstration of hydrosalpinx. Again, a conservative approach was decided due to the symptomatic improvement. The next day the scan report was amended and described torsion. At that time, patient was taken for laparoscopy.

Intraoperatively, she was found to have adnexal torsion on left side with gangrenous left fallopian tube. There were severe intraperitoneal adhesions. Left ovarian cyst 5x4 cm (endometrioma) was seen. Left adnexa was twisted twice. Detorsion of the left adnexa was done and left ovarian cystectomy was performed.

Results

This case demonstrates the diagnostic difficulties as the patient did not present with typical signs and symptoms of ovarian torsion. Her symptoms were not constant and kept improving intermittently. In our case, there were no risk factors for torsion and the cyst size was initially small (less than 4 cm). There were discrepancies and delays in reporting the radiological investigations. All these led to the delay in management.

Conclusions

Clinical judgement should be the mainstay in management of young patients with acute presentation pointing to torsion. There should be a low threshold for surgical intervention to avoid organ damage. As demonstrated in this case, the fallopian tube had to be removed due to necrosis and gangrene.

Infertility and hysteroscopy: 3 years of experience.

Maria Teresa Buergo Ramirez¹, Maria del Henar González De Diego¹, Angela Maria García De La Chica¹, Juan Antonio Solano Calvo², Rocío García Berrio², Álvaro Zapico Goñi²

¹Residente de Ginecología y Obstetricia, Hospital Universitario Príncipe de Asturias, Madrid, Spain

²FEA Ginecología y Obstetricia, Hospital Universitario Príncipe de Asturias, Madrid, Spain

Background

Objectives:

To describe hysteroscopic findings in infertility patients from January 2019 to December 2021.

Methods

Study Design: Retrospective observational descriptive study.

Study Population: Infertile women undergoing a hysteroscopy from January 2019 to December 2021.

In addition, other data such as age, hysteroscopy indication, hysteroscopy results and pathological anatomy results were also analysed.

Results

A total of 1608 hysteroscopies were done in our hospital, and only 47 were due to infertility. The mean age of the infertile patients was 33.933 (range: 27-45 years old).

Previously to hysteroscopy, 6 (12.7%) patients had suspected uterine malformation, 4 of them was confirmed a septate uterus, in one of them no malformations were observed and in another the hysteroscopy could not be completed.

In 18 (38.2%) patients the vaginal ultrasound before to hysteroscopy was normal, they did not present any alteration, however, in the hysteroscopy in 3 of these patients one or several polyps were visualized and polypectomized that were later confirmed with pathological anatomy.

In total, 14 patients (29.7%) had endometrial polyps that underwent polypectomy. In 19 patients (40.2%) during the hysteroscopy no alteration was observed, an endometrial biopsy was taken, and the pathological result was functional endometrium.

Conclusions

In conclusion, hysteroscopy is the definitive method for evaluation of abnormalities of the endometrial cavity and also offers the opportunity for treatment at the time of diagnosis when performed in the operating room.

Limitations of hysteroscopy in infertility study include lack of information about the myometrium, fallopian tubes, and adnexal structures.

Therefore, hysteroscopy is very useful for patients who do not need information on the status of the fallopian tubes.

Minitouch Outpatient Endometrial Ablation Procedure – Suitability for Physician’s Office

Scott Chudnoff¹, Amy Brenner², Cindy Basinski³, Mark Akin⁴, Stephanie Reich⁵, Christina Sebestyen⁶

¹*Maimonides Health, OBGYN, Brooklyn, USA*

²*Amy Brenner- MD & Associates, gynecology, Mason, USA*

³*CMB Research, gynecology, Newburgh, USA*

⁴*AA ObGyn, gynecology, Austin, USA*

⁵*CTOA Women’s Health Texas, gynecology, Austin, USA*

⁶*OBGYN North, gynecology, Austin, USA*

Background

Evaluate suitability of Minitouch Procedure for its use in Physician’s office from perspectives of safety, efficacy, patient comfort, post-procedure recovery and impact on office routine.

Methods

A prospective, multicentre, single-arm, open label, pivotal clinical trial was conducted to evaluate safety and efficacy of Minitouch Outpatient Endometrial Procedure. The Trial was approved by the United States Food and Drug Administration (US FDA) and was conducted at 5 US physician’s offices. Follow-up assessments were made at 24 hours, 2 weeks, 3-, 6-, and 12-months post-procedure.

114 premenopausal women with a history of heavy menstrual bleeding and a Pictorial Blood Loss Assessment (PBLAC) score >150 were treated with the Minitouch Procedure. The demographics were as follows - mean \pm SD (range): age 41.6 ± 4.6 (30-50) years, parity 2.3 ± 1.1 (0-5), sounding depth 8.6 ± 1.1 (7.0-11.0) cm, uterine cavity length 5.2 ± 0.8 (4.0-7.0) cm, and endometrium thickness 9.5 ± 4.2 (3.0-23.4) mm.

All 114 Minitouch Outpatient Procedures were performed without endometrial pretreatment or period timing. Cervical dilation was not required in 93% of the procedures since the device diameter is slim at 3.8mm. The procedure does not require a cavity integrity test or cavity sealing.

Results

The data was collected from 100% (114/114) of the subjects in 100% of the follow-ups; there was 0% loss to follow-up.

90% of the subjects met the effectiveness endpoint - PBLAC score of ≤ 75 at 12 months. 52% (59/114) reported amenorrhea. There were no device or procedure related serious adverse events.

81% of the subjects were discharged within 30 minutes post-procedure, with a mean of 21 minutes and median of 13 minutes. Average pain scores (scale 0 – 10) 0.7 at pre-procedure screening, 2.7 at discharge and at 1.2 at 24 hours post-procedure.

On a pre-determined basis, 1 physician (8 subjects) used general anesthesia, 1 physician (26 subjects) used oral and intravenous (IV) meds, and the remaining 3 physicians (80 subjects) used neither general anesthesia nor IV meds.

Physician time per subject was approximately 10 minutes on average. One investigator routinely performed 10 to 13 procedures in a single session. Minimal staff and space were required as the short recovery period ensured a smooth patient flow through the facility, making a staffed recovery room not necessary.

Conclusions

The Minitouch Procedure is well-suited for physician’s office from the perspectives of safety, efficacy, patient comfort, recovery space, and its impact on the office routine.

Laparoscopic approach to staging for ovarian cancer: comparison of entry techniques and outcomes

Tabassum Khan¹, Amarbaj Chandock²

¹*University Hospitals Birmingham, Obstetrics and Gynaecology, Birmingham, United Kingdom*

²*University Hospitals Birmingham, Gynaecological Oncology, Birmingham, United Kingdom*

Background

Surgical practice is changing towards a minimally invasive approach. Predominantly this has been with benign pathology however surgical practice is now also changing in oncological surgery. We present a 6-month review of laparoscopic staging surgery for ovarian and peritoneal malignancy comparing entry techniques and surgical and staging outcomes as well as reviewing advantages of this approach.

Methods

Over a 6-month period in 2020, a single oncology consultant performed, 7 staging laparoscopies for malignant disease with only 1 being converted to laparotomy. All surgeries were performed after staging imaging and MDT discussion. The largest cyst operated on was 18cm, which was removed in a bag and drained in the bag before removal through a suprapubic approach. The conversion to laparotomy was for a mucinous cyst that had already ruptured when inspected on laparoscopy.

Results

The data shows a conversion rate of 14% and cyst rupture rate of 14%. 86% of cases had the specimen removed intact. There were no re-admissions with most patients discharged on the same day. 1 patient stayed overnight due to her other co-morbidities.

Conclusions

The Palmer's approach is the pre-dominant primary entry approach used by this single surgeon which has many advantages. Although this is not a novel technique it is underutilised as a primary entry port and reserved for cases where umbilical entry can't be used. It is particularly useful in oncology cases where previous laparotomy is performed for unsuspecting large ovarian cysts, which are malignant on histology, requiring further staging. It also allows good access to the infracolic omentum to perform omentectomy as well as giving a birds-eye view of the pelvic mass and associated disease and organ involvement. This allows the laparoscopy to be safer with less secondary organ damage. It also serves as an ideal port to drain ascites as it's at a higher level and allows a safe and clear view to be established preventing blind organ damage. The secondary advantages are the enhanced recovery rates which improve patient outcomes and reduce delay in commencing systemic chemotherapy improving overall patient outcomes for advanced malignancy.

The modified optic entry technique; overcoming entry obstacles

Tabassum Khan¹, Mohan Kumar²

¹*University Hospitals Birmingham, Obstetrics and Gynaecology, Birmingham, United Kingdom*

²*University Hospitals Birmingham, Gynaecology, Birmingham, United Kingdom*

Background

There are many entry laparoscopic entry techniques mentioned in literature and practiced across all specialties engaging in laparoscopy with port entry at the umbilicus. We present a demonstration of the modified direct optic entry technique at the umbilicus for gynaecological surgery where the standard approach is contraindicated. This can be in cases of raised BMI, low BMI, umbilical scarring, and multiple previous laparoscopies.

Methods

The technique described involves everting and lifting the scarred edges of the umbilicus and cutting the band of scarred and thickened skin or fascia under direct vision. The peritoneum is still kept intact and then a direct optic entry technique is achieved by lifting and everting the abdomen whilst inserting the trochar at 180-degree angle, visualising the sheath and peritoneum as entering.

Results

The result of this technique is a safe optic entry technique without the increased risk of vascular and bowel injury associated with increased resistance and an uncontrolled entry.

Conclusions

This modified technique has been safely used in extremely challenging cases allowing safe optic entry and avoiding blind entry techniques in high-risk cases. This skill has been perfected by the surgeon and has been adapted from the Scandinavian laparoscopic entry technique where a small incision is made through the scarred umbilicus and is then dilated with a blunt point or trochar.

We have case examples of extremes of BMI and complex endometriosis cases that have been successfully managed with laparoscopic surgery with this entry technique without any associated bowel or vascular injuries.

This entry technique is different to the Hasson technique that is traditionally used as the open entry technique in more challenging cases and is novel in its approach to complex cases that may have otherwise been managed with lateral port entries or with increased risk of morbidity and complications.

Long-term outcomes of Reduced-Port Robotic Surgery (RPRS) for uterine myomectomy with the da Vinci surgical system

Woo Young Kim¹, E Sun Paik¹

¹Kangbuk Samsung Hospital- Sungkyunkwan University School of Medicine, Obstetrics & Gynecology, Seoul, Korea- Republic Of

Background

To evaluate the long-term outcomes, including recurrence rate and pregnancy outcome after Reduced-Port Robotic Surgery (RPRS) for uterine myomectomy using the single-port system.

Methods

This result is analysis of a prospective, non-randomized study of 115 patients who underwent RPRS myomectomy from April 2016 through July 2021. We presented operative outcomes and long-term outcomes, including recurrence rate and pregnancy outcome.

Results

Overall, 115 patients were included for analysis. Patients' median age was 42 years (range 28 ~52). The largest myoma was mostly located on the anterior uterine wall in 59 patients. The median myoma size and weight were 7.5cm (range, 3–12) and 163g (range, 42–753), respectively. The median myoma enucleation time and suture time were 10 minutes (range, 4–82) and 14 minutes (range, 5–63). Trend of shorter docking time and console time was shown with experience. The procedure was successfully performed via RPRS in 104 patients (91.5%); 10 patients required placement additional ports, conversion to open surgery was conducted in one case. There were 6 patients (5.2%) with postoperative complication with surgical wound infection (1.7%), bleeding (0.9%), peritonitis (1.7%), and pneumonia (0.9%). For long-term outcomes, 12 recurrences (10.4%) were observed in median follow-up of 25 months (range, 6~62 months). Total of 4 patients became pregnant after RPRS, and three patients had delivered with Caesarean section without complications.

Conclusions

Our long-term results demonstrate the safety and feasibility of RPRS for uterine myomectomy as a valid treatment modality.

Surgical approaches in adenomyosis; Fertility preservation in the young woman

Tabassum Khan¹, Mohan Kumar²

¹*University Hospitals Birmingham, Obstetrics and Gynaecology, Birmingham, United Kingdom*

²*University Hospitals Birmingham, Gynaecology, Birmingham, United Kingdom*

Background

Adenomyosis is an underdiagnosed condition affecting a large proportion of women with subfertility and infertility. It is often associated with many investigations and ultimately diagnosed following hysterectomy. It is formally defined as the presence of heterotopic endometrial glands and stroma. The exact mechanism is unknown however is associated with an enlarged uterus associated with dysmenorrhoea and heavy menstrual bleeding.

In the UK, there is no defined surgical practice in managing these cases with a view to preserve fertility. The surgical challenge is enhanced by whether the adenomyosis is correctly identified as local or diffuse. Many times, focal adenomyosis is mistaken for fibroids and mixed adenomyosis can be undertaken for surgery with increased blood loss and morbidity with negative fertility outcomes.

Methods

A literature review is presented and comparison of practice of uterus sparing surgical approaches to adenomyosis and patient selection criteria for procedures. Novel procedural techniques are also reviewed with their efficacy and emerging data including HIFU (high intensity focused ultrasound) and radio ablative techniques to foci of adenomyosis.

Results

The literature review performed demonstrates that there is a vast variation in surgical approaches to Adenomyosis with hysterectomy still being the most common. There has been an emergence of increased popularity of fertility preserving and uterus sparing techniques, however practice is variable with no uniform guidelines or recommendations on this. The successful techniques are surgeon specific and limited to cases of focal adenomyomectomy.

Conclusions

Adenomyosis has improved in recognition and early diagnosis overall. There is increased awareness in both patients and clinicians however the surgical approaches to preserve fertility are still not fully established or standardised. Each case is managed individually as per case. The main focus in Adenomyosis remains symptom management through medical options. The future advances are looking promising and point towards procedural as well as disease reducing excisional techniques associated with significant improvement in quality of life and fertility outcomes.

Cervical Pregnancy and Pregnancy in Scar can be Treated in Similar Methods with Low-Risk Potential

Nissim Arbib¹, Hadar Gluska², Chen Manor-Bar², Oshrat Raviv², Yair Daykan², Zvi Klein²

¹Meir Medical Center- Kfar Sava- Israel, Obstetrics and Gynecology, Ramat Pinkas, Israel

²Meir Medical Center, Obstetrics and Gynecology, Kfar Sava, Israel

Background

In contrast to tubal ectopic pregnancies, in which the acceptable management is well established, in rare case of ectopic pregnancies such as cervical pregnancy or pregnancy in cesarian scar, there isn't a worldwide accepted treatment regime. In our department the acceptable treatment in these two cases is relatively similar and combines in most cases medical treatment with MTX and dilation curettage. Surgical scar pregnancies and cervical pregnancies are in close proximity to each other, with problematic blood supply. Moreover, both can be easily diagnosed as a missed abortion. This study designed to closely addressed the similarities and differences between these two rare ectopic pregnancies in terms of risk factors, presentation, and treatment.

Methods

This is a retrospective study that was conducted in Meir Medical Center between the years 2016-2021. Data was collected from the medical records. All surgical interventions were performed at the same departments under ultrasound guidance.

Results

Our study included 10 cases of cervical pregnancies and 32 cases of pregnancies in scar diagnosed and treated in a single centre.

Demographic, laboratory, and sonography features: There were no significant differences between the groups in terms of age at presentation ($p=0.573$) and bleeding as presenting symptom ($p=0.071$). Differences were found between the groups in BHCG levels at presentation (23394.9 ± 25091.3 for pregnancy in scar vs. 6247.5 ± 5738.7 for cervical pregnancies, $p=0.04$), gravida (4.2 ± 2.3 , $p=0.035$) and parity (2.6 ± 1.0 , $p=0.045$).

Risk factors: There were no differences in smoking ($p=0.577$), previous EUP and spontaneous conception ($p=0.181$). Differences were found between the groups in the number of previous CS (1.8 ± 1.1 vs. 1.0 ± 1.0 , $p=0.032$).

Treatment regimen and outcomes: There were no differences in the selected treatment regimen between the two groups ($p=0.191$). In cases MTX was used, there were no differences in the MTX protocol that was used ($p=1.000$).

Conclusions

Our study demonstrated that cervical pregnancy and pregnancy in scar can be treated similarly, although both can be missed diagnosed as missed abortion and both may cause massive blood loss. Further study and worldwide collection of data is needed.

Cervical Pregnancy Can Be Treated Safely and Effectively with Suction Curettage with or Without MTX

Hadar Gluska¹, Zvi Klein¹, Chen Manor-Bar¹, Michal Ovadia¹, Yair Daykan¹, Nissim Arbib²

¹Meir Medical Center, Obstetrics and Gynecology, Kfar Sava, Israel

²Meir Medical Center- Kfar Sava- Israel, Obstetrics and Gynecology, Ramat Pinkas, Israel

Background

Cervical pregnancy is the rarest of all ectopic pregnancies, accounting for less than 1% of the cases. Several management options are available, including surgical, medical and a combined option. Given its rarity, the ideal treatment regimen is yet established. In this study we aimed to better understand the efficacy and safety of the diverse treatment options.

Methods

This is a retrospective study that was conducted in Meir Medical Centre between the years 2016-2021. Data was collected from the medical records. All surgical interventions were performed under ultrasound guidance.

Results

Our study included 10 cases of cervical pregnancies diagnosed and treated in a single centre. All patients met literature criteria for cervical pregnancy.

Demographic, laboratory, and sonography features: Patients mean was 34.8±4.1 years. The mean gestational age at presentation was 6.5±1.8 weeks, mean BHCG levels at presentation at diagnosis were 6247.5±5738.7 mIU/mL, while mean endometrial thickness was 12.4±2.7 mm. Only one patient presented with fetal cardiac activity. The most common presenting symptoms was vaginal bleeding, which occurred at 8 of the 10 cases.

Risk factors: Four patients conceived using assisted reproductive technique, while the other 6 conceived spontaneously. Two of the patients were smokers. Interestingly, 6 patients underwent previous caesarean-section.

Treatment regimen and outcomes: Two patients (20%) were treated in a conservative manner, with a following spontaneous abortion and resolution of the cervical pregnancy.

One patient was first diagnosed with missed abortion, and treated with Cytotec and in further sonography examination, cervical pregnancy was diagnosed. Later, this patient, alongside two other patients (30%) were treated in a conservative manner with a spontaneous decrease in BHCG levels, without any cervical intervention.

Only one patient treated with single dose of MTX without further need of surgical intervention.

Four patients (40%) required combination of medical and surgical treatment: two of them were treated with one dose of MTX, the other two were treated with a multidose MTX, all four patients eventually underwent a suction curettage.

Two patients (20%) were treated solely with suction curettage. These two patients had much lower BHCG levels (mean 547.5±252.4 mIU/mL) compared with the four patients who treated in the combination regimen (mean 9853.7±6831.3 mIU/mL).

None of the patients received blood products. Only in one case we used foley catheter for bleeding control.

Conclusions

Our study demonstrated that surgical treatment or combination of MTX with following suction curettage are highly effective treatments for cervical pregnancies. Patients with low levels of BHCG can be treated with direct suction curettage. None of the patients underwent surgical treatment needed blood products and none of them needed extensive surgery such as hysterectomy. We may assume that treatment with dilation and curettage with or without MTX therapy is safe and effective for cervical pregnancy.

A morphic sonographic uterine endometrial finding is highly suspicious and should be sent directly to hysteroscopy: a retrospective cohort study

Zvi Klein¹, Michal Ovadia¹, Doron Mulla², Hanoch Schreiber¹, Yair Daykan¹, *Nissim Arbib*¹

¹Sackler School of Medicine- Tel Aviv University, Department of Obstetrics and Gynecology- Meir Medical Center, Kfar Saba, Israel

²Sackler School of Medicine- Tel Aviv University, Schneider's Children Medical Center, Petach-Tikva, Israel

Background

Diagnosing uterine abnormalities is an important tool for early intervention in cases of endometrial cancer. Transvaginal ultrasonography (TVUS) uses a small ultrasound probe to produce detailed images of the organs in the pelvic region. This technique has gained popularity, allowing for the identification of abnormal uterine structure and content with high accuracy. Upon detection of irregularities, TVUS may be followed by diagnostic hysteroscopy and, when surgery is needed, an operative hysteroscopy intervention. The aim of the current study was to examine whether TVUS provides a high positive predictive value (PPV) for diagnosing women with abnormal uterine content, without the need for additional diagnostic hysteroscopy.

Methods

This retrospective cohort study included women referred to a single tertiary university-affiliated medical center for hysteroscopy between January 2013 and May 2016, comparing women with polyps ≥ 1.5 cm to those with amorphous uterine content.

Results

We found 205 cases with amorphous uterine content and 114 cases with a polyp size ≥ 1.5 cm. Patients with amorphous uterine content were found to be significantly older with a higher percentage of postmenopausal women. TVUS reached a PPV of 66.8% in women with unspecific amorphous endometrium. This value increased to 71.5% in cases where the bleeding was an indication for TVUS examination. Based on these findings, determining the profile of patients who can avoid diagnostic hysteroscopy and for whom an operative hysteroscopy is indicated might be helpful and cost-effective.

Conclusions

Our finding demonstrates that women with thick endometrium are more prone to develop hyperplasia or malignancy than women with polyp size ≥ 1.5 cm. TVUS provides high PPV for detecting abnormal amorphous endometrium which could be related to endometrial cancer. Therefore, we hypothesize that TVUS may be used in these cases as the sole diagnostic tool, without the need for diagnostic hysteroscopy and with patients being directly referred to surgical hysteroscopy.

Hysterectomy and sexual (dys)function: a systematic review and meta-analysis.

Suzanne Dedden¹, Marlene Werner², Judith Huirne³, Peggy Geomini⁴, Jacques Maas⁵

¹Maxima Medical Centre, Obstetrics and Gynaecology, Veldhoven, The Netherlands

²Amsterdam University Medical Center- University of Amsterdam,

Department of Sexology and Psychosomatic Gynaecology, Amsterdam, The Netherlands

³Amsterdam University Medical Center, Department of Obstetrics and Gynaecology, Amsterdam, The Netherlands

⁴Maxima Medical Centre, Obstetrics and Gynaecology, Veldhoven, The Netherlands

⁵Maastricht University Medical Centre+, Obstetrics and Gynaecology, Maastricht, The Netherlands

Background

There is a growing interest in the role of hysterectomy in sexual (dys)function in women. Hysterectomy is one of the most frequently performed major gynecological surgery in women worldwide. 80-90% of the hysterectomies are performed on benign indication. Hysterectomy can be performed using a vaginal, laparoscopic, and abdominal approach or a combination of techniques, and can be performed as a total or subtotal procedure with or without a bilateral salpingo-oophorectomy. Sexual function after hysterectomy can be a concern for women undergoing hysterectomy. Until present, research remains inconclusive about the effect of hysterectomy on sexual functioning.

We systematically reviewed the literature to analyze change in sexual function from before to after hysterectomy, and the role of subtotal vs. total hysterectomy and the role of concomitant bilateral salpingo-oophorectomy in differences in pre-post hysterectomy change.

Methods

We selected randomized controlled trials, and prospective and retrospective cohort studies assessing sexual function before and after hysterectomy. The outcome parameters that were assessed were overall sexual function, dyspareunia, desire, arousal, lubrication, and orgasm. The PROSPERO ID of this Systematic Review is CRD42020177473.

Results

32 articles were included in the systematic review. All studies provided data for at least one of the outcome parameters. Data were pooled for meta-analysis using multi-level random effects models. Sexual function from pre- to post-intervention for hysterectomy in general and subdivided according to surgical route did not significantly change. Sexual function after subtotal hysterectomy seemed to improve statistically significant and pain after total hysterectomy decreased statistically significant. However, no differences could be demonstrated when comparing the two techniques. Hysterectomy without BSO is associated with a substantial and statistically significant improvement in overall sexual function, whereas hysterectomy with BSO was associated with a non-significant slight improvement in overall sexual function.

Conclusions

We could not demonstrate statistically significant differences between various surgical routes in the magnitude of change of sexual function after hysterectomy. Concomitant BSO was associated with significant differences in the magnitude of pre-post change in lubrication and orgasm but not in desire and arousal nor overall sexual function.

Accuracy of the diagnostic value of endometrial biopsy using the hysteroscopic tissue removal system compared with targeted hysteroscopic biopsy in women with abnormal uterine bleeding

Rossana Cicinelli¹, Luca Maria Schonauer¹, Gianluca Raffaello Damiani¹, Giuseppe Muzzupapa¹, Donatella Guglielmi¹, Ettore Cicinelli¹

¹University of Bari- Policlinico- Piazza Giulio Cesare 11- 70124,

Department of Biomedical and Human Oncological Science- Unit of Obstetrics and Gynecology, Bari, Italy

Background

Hysteroscopic endometrial biopsy nowadays represents the gold standard in the diagnostic process of abnormal uterine bleeding (AUB) in pre and postmenopausal age. This technique allows the visual exploration of the uterine cavity, and the sampling of endometrial mucosa in suspicious areas without the need for anesthesia in an outpatient setting. However, the hysteroscopic endometrial biopsy with 5 Fr forceps, has the limit of the size of the sampling linked to the bite of the forceps which results inconclusive in most cases. The Hysteroscopic Tissue Removal system (HTRs) is an outpatient hysteroscope system that allows mechanical resection and aspiration of the endometrium without electro-cauterization, the inspection of the cavity and the collection of larger biopsy samples. The purpose of this prospective study was to compare the diagnostic accuracy of biopsy with 5r Fr forceps and with HTRs in women with AUB.

Methods

In the period October 2021-March 2022, women referred for AUB were enrolled and underwent outpatient hysteroscopy and biopsy with 5 Fr forceps (technique A) followed, in the same session, by endometrial biopsy by morcellation and aspiration with the HTRs (technique B). The pain intensity of the procedure expressed with a VAS scale (from 1 to 10), the execution time, the volume of endometrial sampling and the correspondence of the diagnoses even with definitive histological examination in the patients who underwent hysterectomy, were compared. All procedures were performed on an outpatient setting and without any type of anesthesia.

Results

54 patients were enrolled (20 in menopausal status). The pain intensity according to VAS scale was 3 + for hysteroscopy with forceps and 5 + for HTRs (p 0.05). The time to biopsy was 160 ± 20 sec for the 5 Fr forceps and 260 ± 40 sec for the HTRs (p NS). The mean size of the collected tissue was $0.7\text{cm}^3 \pm 0.2$ SD for the biopsy forceps and $2.5\text{cm}^3 \pm 0.6$ SD for the biopsy sample performed with HTRs (p <0.0001). The diagnosis with the two techniques was comparable in 48 cases and different in six patients: three cases with diagnosis of proliferative endometrium with A vs benign hyperplasia with B, two cases of benign hyperplasia with A vs atypical hyperplasia with B and one case of atypical hyperplasia with A vs adenocarcinoma with B.

Conclusions

The data of the present study show that biopsy with HTRs provided significantly greater amounts of endometrium for histological examination even if more painful than biopsy with forceps. The differences in the histological diagnosis suggest greater accuracy of the HTRs system compared to the 5 Fr forceps biopsy but it needs confirmation with a larger study.

Diagnostic value of hysterosalpingo foam graphy and laparoscopy for hydrosalpinx in infertile women

Müge Keskin¹, Didem Demir¹, Gamze Sinem Yuçel¹, Sevim Dincer Cengiz¹, Asli Yarcı Gursoy¹

¹*Ufuk University Faculty of Medicine, Obstetrics and Gynecology, Ankara, Turkey*

Background

Laparoscopy is the gold-standard technique for HS diagnosis but due to its invasiveness, high costs and risks it was replaced by hysterosalpingo graphy (HSG), which is commonly used. Considering the X-ray radiation exposure, abdominal pain and allergic reactions related to HSG, HyFoSy was introduced as a feasible, tolerable, safe and less painful alternative for outpatient tubal assessment and has become widely adopted in infertility clinics. Although there are studies evaluating the diagnostic accuracy of HyFoSy for the assessment of tubal patency, reliability of HyFoSy in the diagnosis of HS is not clear.

Methods

The was a prospective cohort study conducted in a gynecology and obstetrics clinic between june 2020 and january 2022. Twenty women with hydrosalpinx detected by HSG and undergoing LS were included for further analysis with HyFoSy. HyFoSy was performed on the day of laparoscopy before the operation for the assessment of hydrosalpinx in patients previously diagnosed by HSG. During the procedure, width of isthmus, ampulla and infundibulum of tubes were measured. Catheter of ExEm® Foam kit (GynaecologIQ/GISKIT BV, Delft, the Netherlands) which contains glycerol, hydroxyethyl cellulose and purified water was used for introduction of 5 mL foam into the endometrial cavity. Then 2D-transvaginal ultrasound was performed to achieve visualization of tubes.

Results

LS was performed in 20 patients and 40 tubes were evaluated with HyFoSy, HSG and LS. There were 25 tubes with hydrosalpinx (62.5%) and 15 normal patent tubes (37.5%). Mean width of isthmus, ampulla and infundibulum were 1.42 ± 0.54 vs 1.37 ± 0.45 , $p:0.615$; 2.67 ± 1.54 vs 1.63 ± 0.59 , $p:0.023$ and 5.09 ± 1.23 vs 2.42 ± 1.36 $p<0.001$, respectively in tubes with HS and normal tubes. Cutoff value for diagnosis of HS was 1.84 and 2.74 with a sensitivity of 68% and 100%, for ampulla and infundibulum respectively, specificity was 80% for both parts. Assessment of hydrosalpinx by HyFoSy showed a total concordance with the results of LS in 96% (n:24) of the tubes. 2 tubes (13.3 %) were misdiagnosed as hydrosalpinx with HyFoSy. Assessment of hydrosalpinx by HSG showed a total concordance with the results of LS in 88% (n:22) of the tubes. In 4 tubes (16%), HSG failed to diagnose hydrosalpinx. Considering LS as the gold standart, inter-test agreement Kappa was 0.78 and 0.62 for HyFoSy and HSG respectively. Showing a substantial concordance for both procedures. Sensitivity, specificity, accuracy, positive predictive and negative predictive value were 96% vs 88%, 80% vs 73%, 90% vs 82%, 88% vs 84%, 92% vs 78% for HyFoSy and HSG respectively

Conclusions

HyFoSy is an accurate diagnostic tool for the assessment of hydrosalpinx in infertile women.undergoing laparoscopy. Studies with larger sample size are needed for confirming the results of our study suggesting HyFoSy as the most precise diagnostic method for hydrosalpinx.

Hysterectomy in a male? Once in a life operation for a surgeon

Müge Keskin¹, Ahmet Hakan Haliloglu², Gamze Sinem Yucel¹

¹*Ufuk University Faculty of Medicine, Obstetrics and Gynecology, Ankara, Turkey*

²*Ufuk University Faculty of Medicine, Urology, Ankara, Turkey*

Background

Persistent Mullerian duct syndrome (PMDS) is a rare form of male pseudo-hermaphroditism characterized by the presence of Mullerian duct structures in phenotypically and genotypically normal man and poses a challenge to clinicians. It is characterized by the persistence of the uterus, fallopian tubes and upper vagina, in otherwise normally virilized boys. Despite the normal male genotype (46 XY) and the subsequent normal development of fetal testes, müllerian structures do not regress either due to absence of Müllerian Inhibiting Substance (MIS) or lack of response to it. This entity is often misdiagnosed due to a lack of familiarity. Surgical correction of internal genitalia for functional goals and prevention of degenerative changes in the remnants and malignant transformation of gonads is imperative. Here we are reporting a rare case of PMDS where the late presentation was due to infertility.

Methods

A 31-year-old patient presented at our outpatient clinic with the complaint of azoospermia. The patient was phenotypically male with normal secondary sexual characters. He had previously presented with abdominal pain at an emergency department of another hospital. General physical examination revealed a man of sub-average built with well-developed secondary sexual characters. His urethra and penis were fully developed. Both testicles were found to be absent in scrotal sac. His previous abdomen computer tomography (CT) with contrast showed a rudimentary uterus measuring 79x21 mm and proximal vagina. Along with the fallopian tubes, symmetric solid masses were observed on both sides mimicking undescended testicles. A karyotype was conducted, and this revealed a 46, XY variant. Patient was hospitalised for surgery. During surgery, both testicles were found to be occupying the position of ovaries measuring approximately 6x4 cm which were excised along with the uterus and adnexa.

Results

Our patient had an uneventful postoperative period. Grossly, the specimens removed were identified as a uterus with patent endometrial and endocervical linings and two fallopian tubes and two testes. The specimen was sent for histopathological examination which revealed uterine muscular tissue with its cavity lined by endometrial tissue and congested fallopian tubes. No ovarian tissue was seen. Histopathology report also revealed testicular germ cell neoplasia in situ (seminoma) arising from testis.

Conclusions

PMDS is a rare form of male pseudo-hermaphroditism characterized by the presence of Mullerian duct structures in an otherwise phenotypically, as well as genotypically, normal man. Since patients are phenotypically male, it is possible for the disease remain undetected until patient's referral to a physician for another reason. Late presentations can have various detrimental effects starting from problems of infertility to development of malignancy. Even in patients presenting with infertility, the possibility of PMDS should be kept in mind.

VIDEO ePOSTERS

ES31-0077 - VP001

Transanal full-thickness discoid excision of rectal endometriosis nodule: a structured approach using SOSURE technique

Benedetto Mondelli¹, Michael Adamczyk², Pasha Nisar³, Shaheen Khazali^{1,4}

¹CEMIG Centre for Endometriosis and Minimally Invasive Gynaecology at HCA The Lister Hospital, Gynaecology, London, United Kingdom

²CEMIG Centre for Endometriosis and Minimally Invasive Gynaecology at Ashford & St. Peter's Hospitals NHS Foundation Trust, Gynaecology, Chertsey, United Kingdom

³Ashford & St. Peter's Hospitals NHS Foundation Trust, General surgery, Chertsey, United Kingdom

⁴Royal Holloway, University of London, London, United Kingdom

Background

Deep endometriosis invading the bowel constitutes a major challenge for the gynaecologist. In addition to the significant impact on the quality of life, the higher incidence of surgical morbidity involved with bowel endometriosis poses a therapeutic dilemma for the surgeon. The different surgical options for managing rectosigmoid endometriosis are well known however, there is no clear cut off regarding the patient's eligibility for shaving, bowel resection and discoid resection. When the disease only involves a limited area of the bowel, this can be treated with a full-thickness discoid excision, with the goal of preserving rectal function, preventing rectal stenosis and avoiding post-operative unfavourable functional outcomes due to the removal of the lower and middle rectum.

Methods

To minimise the potential complications from this surgical procedure and maximise the outcome, the adoption of a standardised surgical technique and careful patient selection are of utmost importance.

The video presents a discoid excision of endometriosis involving the rectum using a transanal circular stapler. The excision of the endometriosis was preceded by the optimisation of the surgical field using the SOSURE technique. After rectal mobilisation and rectovaginal space opening, the intestinal nodule was isolated, and a 33-mm transanal circular stapler was inserted into the rectum through the anus and used to perform disc excision.

Results

The use of staplers for full-thickness discoid excision of endometriosis can offer a more secure and faster alternative to laparoscopic suturing and avoids the opening of the rectal lumen.

Conclusions

<https://player.vimeo.com/video/709436450?autoplay=1>

Robot-assisted Sacro colpopexy and Burch colposuspension as surgical treatment for Pelvic Prolapse and Anovesical Incontinence

Izabella Dalbuquerque¹, Luisa Martins¹, Mira Zlotnik¹, Vanessa Alvarenga¹, Aley Talans², Renato Moretti¹

¹Hospital Israelita Albert Einstein, Gynecology, São Paulo, Brazil

²Hospital Israelita Albert Einstein, Radiology, São Paulo, Brazil

Background

A 61-year-old patient diagnosed with Endometrial Adenocarcinoma who underwent surgical treatment with Total Hysterectomy, Salpingo-oophorectomy, Pelvic and periaortic lymphadenectomy, Omentectomy and Adjuvant Brachytherapy 11 years ago.

The patient complains of vaginal pressure, urinary leakage on small efforts and fecal incontinence. The physical examination showed a vaginal vault prolapse. The urodynamic study demonstrates stress urinary incontinence and magnetic resonance defecography demonstrated indirect signs of endopelvic fascia injury and a multicompartamental perineal descent.

In this scenario, the purpose of this video was to demonstrate the steps of Robot-assisted Sacro colpopexy and Burch colposuspension as surgical treatment for treatment of Pelvic Prolapse and Anovesical Incontinence.

Methods

Robot-assisted Sacro colpopexy and Burch colposuspension as surgical treatment was performed. During surgery, vaginal dome was exposed by the assistant surgeon using a breisk valve through the vagina, the vesicovaginal and rectovaginal space were developed. Incision of the presacral fascia exposed the promontory. A y shaped polypropylene mesh was fixed on the anterior and posterior wall of the vagina by a continuous suture with 2.0 PDS. This mesh was also tension-free fixed to the anterior longitudinal ligament of the sacrum with PDS. Posterior and anterior celiorrhaphy was performed with a 3.0 barbed suture, covering the entire length of the mesh. Finally, Burch technique was performed with fixation of the paravaginal fascia to the ileopectineal ligament.

The surgery lasted 120 minutes and the patient was discharged on the 1st postoperative day.

Results

We obtained efficient diagnosis and treatment with resolution of the prolapse, although she maintained urinary incontinence.

Conclusions

Pelvic floor dysfunction is a complex condition that may be asymptomatic or may involve multiple symptoms. In this case, the surgical correction of the vaginal vault prolapse was essential to improve quality of life even though the Burch correction did not improve urinary incontinence.

We report the case of a successful laparoscopic robotic-assisted pelvic organ prolapse correction treatment.

<https://player.vimeo.com/video/710587759?autoplay=1>

Laparoscopic management of papillary serous endometrial carcinoma with laparoscopic omentectomy, pelvic lymphadenectomy and total laparoscopic hysterectomy and bilateral salpingoophrectomy.

Fayyad Abdalla¹

¹*Yarmouk University School of Medicine, Obstetrics and Gynaecology, Irbid, Jordan*

Background

Papillary serous endometrial carcinoma is a high-risk endometrial malignancy. The standard management should include omentectomy and pelvic lymphadenectomy. In this video presentation, we demonstrate the technique of laparoscopic total hysterectomy, bilateral salpingoophrectomy, pelvic lymphadenectomy and infra colic omentectomy for papillary serous endometrial carcinoma.

Methods

Five consecutive women with a diagnosis of papillary serous endometrial carcinoma underwent laparoscopic management incorporating laparoscopic omentectomy and bilateral pelvic lymphadenectomy. Three women presented with post-menopausal bleeding and two were incidental findings on transvaginal ultrasound endometrial assessment. The technique involves four port laparoscopies, with supra umbilical and suprapubic 10 mm ports, and two lateral 5 mm ports. The procedures were performed using advanced ultrasonic energy devices and started with laparoscopic omentectomy followed by total laparoscopic hysterectomy and bilateral salpingoophrectomy and then pelvic lymphadenectomy. The omentum was delivered through the vagina and pelvic lymph nodes in endoscopic bags.

Results

All procedures were completed laparoscopically with no major complications. None of the patients required blood transfusion, with average blood loss of 300 ml. Two women had microscopic peritoneal spread despite being superficial carcinomas of the endometrium (less than 50% invasion of the myometrium). All patients were discharged 24 hours after surgery.

Conclusions

Papillary serous carcinoma of the endometrium is a high-risk malignancy that can be managed laparoscopically with all the advantages of laparoscopic surgery. We demonstrate laparoscopic omentectomy and pelvic lymphadenectomy. In this video, we present tips for this laparoscopic procedure including port and camera placement and the safe entry to tissue planes.

<https://player.vimeo.com/video/691978205?autoplay=1>

Bilateral laparoscopic temporary uterine artery ligation with "Ribbon Technique" and bag knife morcellation for laparoscopic myomectomy

*Fayyad Abdalla*¹

¹*Yarmouk University School of Medicine, Obstetrics and Gynaecology, Irbid, Jordan*

Background

The two major challenges of laparoscopic myomectomy are controlling the bleeding during myomectomy and tissue extraction of the myoma from the abdominal cavity. Permanent Uterine artery ligation has been proposed as one method to control the bleeding during my laparoscopic myomectomy. However, the proposed technique involved permanent ligation of the uterine arteries with unknown consequences. In this video, the uterine artery or its ascending branch is identified in the pelvic side wall and is temporally ligated with an innovative technique called the "ribbon technique". I will demonstrate how to perform the "ribbon technique" and how the suture will be removed at the end of the procedure, which significantly reduce the blood supply to the uterus during surgery. In addition, the blood supply to the uterus is resumed after removal of the ribbon suture. The technique of safe fibroid extraction will also be demonstrated.

Methods

Sixty-five women with intramural fibroids underwent laparoscopic myomectomy with uterine artery ligation with the "Ribbon technique". The technique involved opening the peritoneum lateral to the ovarian vessels and identifying the main branch or the ascending branch of the uterine artery. A 2/0 vicryl suture on a needle (length 20 cm) is then passed around the uterine artery. The needle is cut, and a folded ribbon is formed. The fold is then tied around the uterine artery with one throw maintaining the folded ribbon. The myomectomy is then completed laparoscopically, and the uterus closed. The myoma/s are then put in a bag and extracted through an extension of the suprapubic incision to 4 cm, where knife morcellation in a bag is performed.

Results

The average blood loss during surgery was 150 ml (100-400 ml). 8 women needed intra operative blood transfusion due to preoperative low haemoglobin (less than 8 g/dl). The average myoma size was 10 cm (range 6-18 cm) in preoperative imaging (ultrasound or MRI). All procedures were completed laparoscopically with no intraoperative complications. The ribbon suture was successfully removed in all cases and uterine artery pulsation restored. The average hospital stay was less than 24 hours and none of the women developed febrile morbidity afterwards. Fibroid recurrence was not reported up to 12 months after surgery. The histology was benign in all cases, with significant symptom improvement in menorrhagia and pressure symptoms in all patients.

Conclusions

the "Ribbon technique" for reversible uterine artery ligation during laparoscopic myomectomy is feasible and safe and significantly reduces intra operative blood loss during laparoscopic myomectomy. Bag knife morcellation through a small extension of the suprapubic incision is feasible and safe even in large myomas.

<https://player.vimeo.com/video/695260563?autoplay=1>

Endometrial Osseous Metaplasia: Hysteroscopic removal and subsequent outcome. A case report.

Steve Mutiso¹

¹Aga Khan University, Obstetrics and Gynaecology, Nairobi, Kenya

Background

Endometrial osseous metaplasia is a rare clinical entity that can present in varied ways. Patients may present with abnormal uterine bleeding or subfertility in most of the cases. It usually results from prior endometritis with subsequent osseous metaplasia. Its management involves hysteroscopic removal with good outcomes reported in literature. We present a case of endometrial osseous metaplasia resulting to subfertility with its management and subsequent outcome.

Methods

Study Objective: To describe a case of endometrial osseous metaplasia and its hysteroscopic treatment.

Design: Case report

Setting: N/A

Patients or Participants: N/A

Interventions: Hysteroscopic excision of endometrial osseous metaplasia.

Results

A 38-year-old presented with 8 years history of subfertility. She had no significant symptoms in her history with a regular and painless menstrual cycle. Her ultrasound revealed a linear calcification within the endometrial cavity that measured approximately 2 centimetres. The ovaries and adnexa appeared normal. Hysteroscopic excision was done as a day case with no complications. She subsequently conceived spontaneously in the next cycle and went on to deliver a term infant via caesarean delivery due to obstetric indications.

Conclusions

EOM is a rare clinical entity and can cause subfertility as presented in the case. It usually is a result of prior endometritis with subsequent osseous metaplasia. Hysteroscopy is the gold standard of diagnosis and treatment. Most patients have an excellent prognosis as described in the case.

<https://player.vimeo.com/video/699366325?autoplay=1>

ES31-0031 - VP006

Hysterectomy for uterus myomatosus by Vaginal Natural Transluminal Endoscopic Surgery (V-NOTES)

Basilio Pecorino¹, Liliana Mereu¹, Andrea Benedetto Di Stefano¹, Maria Gabriella D'Agate¹, Vito Fabio Guardalà¹, Paolo Scollo²

¹*Cannizzaro Hospital, Obstetrics and Gynecology, Catania, Italy*

²*Kore University, Kore University, Enna, Italy*

Background

To prove the feasibility V-NOTES hysterectomy approach in case of uterus myomatosus

Methods

A step-by-step video demonstration (Canadian Task Force classification III).

Obstetrics and Gynecologic Department Cannizzaro Hospital. IRB was not required.

Results

A 49-year-old woman with metrorragia and uterine myomas underwent a total hysterectomy with bilateral adnexectomy by V-NOTES. Gel Point V-path transvaginal access platform has been used with standard laparoscopic instruments. Uterus has been removed after vaginal cold knife morcellation inside an endobag. The total operating time was 48 minutes, with negligible blood loss. Uterine weight was 305 gr. The patient was hospitalized for 2 days. There were no intra or postoperative complications at 30 days.

Conclusions

Natural Office Transluminal Endoscopic Surgery has the advantages of avoiding abdominal incisions, eliminating complications of trocar sound, less operative pain, shorter hospital. Vaginal-NOTES provides a safe entry, easy access and direct vision of the peritoneal cavity and pelvic anatomy. V Notes hysterectomy is feasible also in case of uterus myomatosus.

<https://player.vimeo.com/video/705026267?autoplay=1>

Laparoscopic oocyte retrieval for fertility preservation in a patient with squamous cell carcinoma of the vagina

Mario Palumbo¹, Paolo Serafino¹, Antonio Mercorio¹, Francesco Viciglione¹, Luigi Della Corte¹, Pierluigi Giampaolino²

¹University of Naples Federico II, Department of Neuroscience- Reproductive Sciences and Dentistry, Naples, Italy

²University of Naples Federico II, Department of Public Health, Naples, Italy

Background

Video case report with demonstration of diagnostic work-up and laparoscopic oocyte retrieval under regional anesthesia, to describe a fertility preservation strategy in a woman with vaginal carcinoma.

Methods

A 35-year-old nullipara presenting vaginal bleeding and malodorous discharge. After an accurate diagnostic work-up a final diagnosis of squamous cell carcinoma of the vagina stage II (FIGO classification) was made. According to patient' wishes, before being submitted to radio-chemotherapy, patient underwent oocytes cryopreservation. Transvaginal retrieval of oocytes was not possible due to the stenosis of the vaginal introitus and the risk of intracavitary tumour's spillage. Transabdominal ultrasound guided oocyte retrieval was not deemed possible due the increased abdominal wall thickness (BMI 29). The patient underwent ovarian stimulation for in vitro fertilization. In order to limit high estrogens levels, letrozole has been used during the controlled ovarian stimulation (COS). After adequate counselling a laparoscopic oocyte retrieval was performed under regional anesthesia. Institutional review board approval was not required for this case report as per our institution's policy; Patient consent was obtained for publication of the case.

Results

A total follicular count of 9 was estimated at before the oocyte retrieval. A total of 8 oocytes were retrieved at laparoscopy and 8 mature oocytes were cryopreserved. No intravenous drugs were required for post operative pain and patient was discharged the same day of surgery.

Conclusions

This is the first case of fertility preservation in a patient with vaginal cancer. Letrozole is a valid strategy to reduce high oestrogen in patient with gynaecological cancer submitted to COS. Laparoscopy oocyte retrieval, performed under regional anaesthesia, can be performed in ambulatory setting and could be considered an effective strategy to preserve fertility in patients and to prevent the risk of tumour spillage.

<https://player.vimeo.com/video/708292542?autoplay=1>

Novel technique of hysteroscopy combined with transvaginal repair without processing scar resection in the treatment of caesarean scar niche

Minjiao Zhu¹, Wei Xia¹, Yan Liang¹, Jian Zhang¹

¹International Peace Maternity and Child Health Hospital- School of Medicine- Shanghai Jiao Tong University, Obstetrics and Gynecology, Shanghai, China

Background

Niche in the caesarean scar is a common complication after caesarean section. Surgical treatment options for niche include laparoscopic, hysteroscopic, and transvaginal surgery. The hysteroscopic approach has been demonstrated to be effective for the treatment of abnormal post-menstrual spotting. Laparoscopic and vaginal surgery can increase the residual myometrium thickness and may reduce the risk of subsequent pregnancy. Hence, they are more commonly used in women with fertility plans. Previous studies have confirmed that transvaginal repair is comparably effective to the laparoscopic repair, which may be a more economical and convenient method for the treatment of niche.

Methods

In this study, we describe a new technique of hysteroscopy combined with transvaginal repair for a niche in the caesarean scar, this novel method does not remove the original scar defect. Instead, it retains the integrity of the myometrium, which may have the benefit of shorter contraception times after the operation. A total of 11 patients diagnosed with niche in the caesarean scar were included in our study between December 2021 and April 2022. Spotting symptoms and magnetic resonance imaging (MRI) anatomical indicators of niche were evaluated preoperatively and postoperatively.

Results

The average operation time was 34 ± 14 minutes, and the estimated blood loss was 30 ± 11 mL. Patients were hospitalized for observation and discharged 1 or 2 days after operation. So far, 5 of the 11 participants have been followed up for more than three months. Three months after surgery, the average post-menstrual spotting time of these patients was notably shortened (from 8.3 ± 3.5 days to 2.0 ± 1.2 days, $p < 0.05$). MRI showed that the average thickness of remaining myometrium was increased (from 1.5 ± 0.8 mm to 6.9 ± 3.6 mm, $p < 0.05$) and the niche volume was decreased significantly.

Conclusions

Hysteroscopy combined with transvaginal repair without processing scar resection is an efficacious way to treat caesarean scar niche. This novel surgery with a minimal invasive approach provides faster postoperative recovery yet a lower cost. Theoretically, this operation is especially suitable for patients with large niche who have urgent fertility intention in short term. However, further studies with larger sample size, longer follow-up time and more postoperative follow-up indicators including fertility outcomes are needed to comprehensively evaluate the curative effect of this novel technique.

<https://player.vimeo.com/video/709031924?autoplay=1>

Resectoscopic management of hematocolpos in Herlyn-Werner-Wunderlich syndrome.

Kamila Kenbayeva¹, Yelena Luchshayeva¹, Galymzhan Toktarbekov¹, Berik Primbetov¹, Zaure Tobylbayeva¹, Dulat Tazhibayev¹

¹Corporate Fund "University Medical Center", Gynecological Department, Nur-Sultan, Kazakhstan

Background

Herlyn-Werner-Wunderlich syndrome is a rare congenital malformation that involves abnormal development of Müllerian and Wolffian ducts during embryogenesis. A triad of uterine didelphys, blind hemivagina, and ipsilateral renal agenesis characterizes this syndrome

Methods

A 12-year-old girl was admitted to the gynaecological department in 2021, complaining of dysmenorrhea and recurrent progressive lower abdominal pain after menarche.

The ultrasound showed uterus didelphys and hematocolpos. The absence of the right kidney was confirmed by ultrasound examination. There were MRI signs of a duplicated uterus. The MRI signal intensity of the contents of the right distended hemivagina matched with blood products that confirmed the diagnosis of hematocolpos. The right uterus communicated with the hematocolpos. The collapsed left hemivagina connected with the left cervix and uterus.

Investigations confirmed the diagnosis of Herlyn-Werner-Wunderlich syndrome. Severe cyclic abdominal pain was caused by extended hematocolpos that had to be evacuated. For this reason, the patient underwent hysteroscopic resection of the vaginal wall, which is a mini-invasive approach.

In the beginning, a vaginoscopy was performed without compromising the hymen. During the observation, a deformed vagina was visualized, and a bulge of the vaginal wall was noted. One cervix was also observed. The dark blood flowed out, once the hematocolpos was opened with the bipolar resectoscope, in the place of the maximal bulge. Small endometriosis lesions can be seen on the vaginal wall and cervix, which is quite common in patients with genital malformations. You can also see the blood flow from the second cervix. A hole between the two vaginas was enlarged resectoscopically to prevent the occlusion.

Results

The postoperative course was uneventful. The patient was discharged the next day after the surgery. At 6-months follow-up, the patient experienced no abnormal bleeding, dysmenorrhea, and pelvic pain.

Conclusions

Blind hemivagina, complicated by hematocolpos, can be successfully drained resectoscopically. It is a minimally invasive approach and effective management, especially for girls with acute lower abdominal pain caused by extended hemivagina.

<https://player.vimeo.com/video/709422649?autoplay=1>

The Gynecological NOTES for the patients with Hereditary Breast and Ovarian Cancer (HBOC)

Shozo Kurotsuchi¹, Yukiyo Kasahara¹, Mayo Miura¹, Chizuru Asai¹

¹Tokoname City Hospital, Gynecology, Tokoname, Japan

Background

The main indications for Risk-Reducing Salpingo-Oophorectomy (RRSO) are the surgery in women at risk of developing ovarian or fallopian tube cancer such as BRCA1 or BRCA2 germline mutations or Hereditary Breast and Ovarian Cancer (HBOC).

Natural orifice transluminal endoscopic surgery (NOTES) is a surgical technique using laparoscopic devices introduced through a natural orifice (mouth, urethra, anus or vagina). In recent years, the NOTES has been performed using an access platform placed into the vagina.

Methods

We report the gynaecological NOTES for the patients with HBOC. As far as our investigation went, this report is the first case where NOTES was performed in a patient with HBOC.

Results

When the RRSO is performed as NOTES, its quality must be the same as that of a conventional laparoscopic surgery. However, the gynaecological NOTES presents a high degree of difficulty compared with the conventional laparoscopic surgery. Its indication should be limited to simple cases such as small, non-adhesive adnexal tumours. Therefore, the gynaecological NOTES is more suitable for the RRSO.

Conclusions

The gynaecological NOTES is feasible and safe to perform and improves patient's QOL.

<https://player.vimeo.com/video/710067826?autoplay=1>

Laparoscopic reconstructive surgery: Creation of a neovagina by Davydov's laparoscopic modified technique in patients with vaginal shortening after radio and brachytherapy

Jesus Molero^{1,2}, Ester Martínez Lamela^{1,3}, Marta Heras^{1,4}, Miguel Rejas⁵

¹Hospital Ntra Sra del Rosario, Oncologic Gynaecology, Madrid, Spain

²TocoGyn Gynecological Clinic, Oncological Gynaecology and Endoscopic Surgery, Alcalá de Henares, Spain

³Infanta Leonor University Hospital, Gynecology and Obstetrics, Madrid, Spain

⁴Santa Cristina University Hospital, Obstetrics and Gynecology, Madrid, Spain

⁵Hospital Ntra Sra del Rosario, Obstetrics and Gynecology, Madrid, Spain

Background

Surgical technique of creation of neovagina is still a challenge for a surgeon, in order to create a functional vagina in terms of sexual intercourse. A method that is still the most used is the interposition of pelvic peritoneum, first inaugurated by Davydov and modified and popularized by Friedberg, Vecchietti and Adamyanova.

Methods

This video abstract demonstrates the modified laparoscopic Davydov technique in a 55 yo patient treated with adjuvant external radiation therapy and brachytherapy for stage Ib cervical adenocarcinoma with risk factors for recurrence four years ago. Before the procedure, length of vagina was 4 cm and had no regular intercourses. A 4-cm transverse incision is made on the vaginal cuff. Peritoneal margins were sutured to the edge of the incised vaginal vestibulum with 8 points (2-0 Vicryl). To create a vaginal space between the bladder and the rectum, it is needed the mobilization of the bladder and release of the peritoneal flaps, dissecting, and releasing both ureters from the peritoneum. Laparoscopic creation of the purse-string suture (ethibond 2-0) is done by consecutively transfixing the bladder serosa, round ligament, the lateral peritoneal leaf, and the rectal serosa in both sides (with ureters under vision). Finally, sutures to reduce tension in neovagina. The anatomic and functional results were evaluated after 3, 6 and 12 months.

Results

The surgical procedure was performed with no major complications. The duration of surgery was 125 minutes. Length of the neovagina was 10,5 after the procedure, and 10.4, 9.5 and 10 cm at 3, 6 and 12 postoperative months, respectively. She had regular intercourses, what was the actual aim of the procedure.

Conclusions

The laparoscopic Davydov procedure seems to be a safe and effective autologous surgical procedure for patients with vaginal shortening after radiotherapy.

<https://player.vimeo.com/video/710084090?autoplay=1>

Laparoscopic repair of big symptomatic isthmocele with hysteroscopic control

Ester Martínez^{1,2}, Jesús Molero Vilchez^{2,3}, Marta Heras García^{2,4}, Antonio Navarro Soler⁵

¹*Infanta Leonor University Hospital, obstetrics and gynecology, madrid, Spain*

²*Hospital Ntra Sra del Rosario, Oncologic Gynaecology, Madrid, Spain*

³*TocoGyn Gynecological Clinic, Oncologic Gynaecology and Endoscopic Surgery, Alcaá de Henares, Spain*

⁴*Santa Cristina University Hospital, Gynecology and Obstetrics, Madrid, Spain*

⁵*Hospital Ntra Sra del Rosario, Gynecology and Obstetrics, Madrid, Spain*

Background

Previous studies have shown an association with the diagnosis of uterine scar defect – referred as 'niche', and symptoms such as postmenstrual spotting, chronic pelvic pain, dysmenorrhoea, and subfertility. The most studies report a niche detection rate of ~ 50% in women after caesarean delivery. This is a case report of a 34-year-old woman with a caesarean scar defect who previously underwent two caesarean sections. The patient complained of dysmenorrhea, postmenstrual spotting, chronic pelvic pain. Patient had a wish to conceive. A transvaginal sonography revealed a niche (sizes 16x11mm) in the area of the scar and the residual myometrium was not visualized, the defect was covered only by serosa and vesico-uterine plica.

Methods

During the hysteroscopy the interruption of the myometrium in the area of isthmus were detected (the presence of crypts, fibrotic tissue, blood clot and mucus). The bladder was attached to isthmus. At first, the bladder was dissected by using bipolar forceps and scissors. The dissection was performed from lateral to medial area. The lowest level of dissection was 2-3 cm from the scar edge, the side borders were the uterine arteries. Afterwards the scar was excised under hysteroscopic view (volcano image). We removed the endometrial mucosa of the isthmocele to prevent recurrences. We catheterized the cervix and isthmus to guide the suture. The uterine wound was sutured in two layers. The first layer in loose stitches, which are knotted at the end (to be able to properly see the edges). The second layer was a continuous suture invaginating the previous one. The last step was peritonization only if is possible.

Results

We ended with the check-up with hysteroscopy and cytoscopy. The post-operative course was uncomplicated. We recommended the patient to use contraceptives for 6 months after the intervention to allow the uterine scar to heal properly.

Conclusions

Laparoscopic isthmocele repair is a mini-invasive and adequate procedure when is indicated.

<https://player.vimeo.com/video/710092496?autoplay=1>

Maximizing the teaching effect of a cadaver model for minimally invasive gynaecological surgery

Dimitrios Balafoutas¹, Olga Triantafyllidou¹, Emmanouil Kalampokas¹, Constantine Mavrantonis²,

Ralf Joukhadar³, Nikolaos Vlahos¹

¹University of Athens, Obstetrics & Gynecology, Athens, Greece

²Node Institute, Network of Doctors Education, Athens, Greece

³University of Wuerzburg, Obstetrics & Gynecology, Wuerzburg, Germany

Background

Several training models have been suggested to steepen the learning curve of minimally invasive gynaecological surgery. It has been recommended that trainees improve their basic manual skills in pelvic-trainer boxes, whereas complex operations can be simulated in cost-effective virtual reality consoles. However, these options do not enable trainees to explore the precise surgical planes and expand their knowledge of pelvic anatomy. Formalin-fixed cadavers are of little value in laparoscopic surgical training due to changes in colour, consistency, and strength of tissues. Fresh frozen cadavers have been found to be superior; nevertheless, due to the high cost and limited availability, exact exercise protocols are important to maximize the teaching effect.

Methods

We organized the first gynaecologic cadaveric hands-on educational program in Greece using two fresh frozen cadaver trunks imported from the United States of America. The presence of intact uterus and ovaries was confirmed with computer tomography. After a theoretical course, two teams, each with two tutors and four trainees, performed laparoscopic hysterectomies. Complete equipment for operative laparoscopy was available, including ultrasound energy devices.

Results

The pneumoperitoneum could be established without difficulty. The uterine manipulation was realistic. The colour and consistency of the tissue simulated those of the living patient. All surgical steps of the total laparoscopic hysterectomy could be simulated successfully. All the important anatomical landmarks were identified. To maximize the teaching effect, we used a retroperitoneal approach and switched roles among the trainees for every major step. Finally, a bilateral pelvic lymphadenectomy was performed. Odour development from leaking port sites remained in tolerable levels.

Conclusions

The fresh frozen cadaver offers as-real-as-it-gets training for advanced gynaecological surgery. The parallel use of two cadavers in small team setting according to this protocol optimizes their utilization.

<https://player.vimeo.com/video/710114124?autoplay=1>

Total Laparoscopic Hysterectomy for a 4 kg Uterine fibroid - Why size doesn't really matter?

Sangeetha Palaparthi¹, Mihai Gherghe¹, Mohammed Allam¹

¹University Hospital of Wishaw, Obstetrics and Gynaecology, Wishaw- Lanarkshire, United Kingdom

Background

Total laparoscopic hysterectomy (TLH) has demonstrated to be feasible and safe in the presence of very large uteri. However, there is not much evidence regarding the upper uterine weight limit for successful performance of a laparoscopic hysterectomy. There are no definite guidelines concerning the procedure for a large uterus, and the literature is vague regarding the best surgical procedure for these cases. The size of the uterus does not seem to be an absolute contraindication for endoscopic surgery. This procedure relies entirely on the surgeon's ability.

Methods

Presentation of a video of Total Laparoscopic hysterectomy with bilateral salpingo - oophorectomy in a 52-year-old lady with a large 34-week fibroid uterus

Results

52-year-old, nulliparous lady with large fibroid

Uterus 34 weeks with dominant part to right side occupying whole abdomen. Anterior lip of cervix normal but high under symphysis pubis. Utero cervical length 16 cm. Medium V – care to manipulate uterus. Cystoscopy performed and guidewire to place right ureteric catheter.

Nasogastric tube placed. Direct Palmer's point entry using 5mm port, 30-degree scope aiming to navigate the camera around the fibroid. Placement of ports planned for easy and useful movement of the camera between the ports, considering access to each side of uterine pedicles. 5 x 5 mm ports placed under direct vision as shown. Patient in Lloyd – Davies position with side tilt.

Left pelvic side wall peritoneum opened and round ligament sealed and cut using Enseal device. Left ureterolysis and 5mm Liga clip was placed on the uterine artery at the origin. Anterior peritoneum dissected and bladder reflected. High bladder dissection as stretched over the fibroid.

Left infundibulo-pelvic ligament, right round ligament and infundibulo-pelvic ligament sealed and cut with Enseal. Both the ureters visualised throughout the procedure. Both uterine pedicles sealed and cut. Colpotomy performed using Monopolar diathermy hook. Vault closed with 3 x interrupted PDS sutures using extra and intracorporeal tying.

5 cm Pfannenstiel incision and abdomen opened using diathermy. Medium Alexis retractor used. Cold Uterine morcellation using coring and bisecting technique with traction and counter traction. Uterus used as recipient for fibroid to achieve no spill within the abdomen. Uterus removed once fibroid cored.

Flo-seal to pedicles. Size 20 Robinson drain placed. Ports removed under direct vision. Loop PDS TO rectus sheath, biosyn to subcuticular layer and glue to skin.

Bladder intact on post procedure cystoscopy. Ureteric catheters removed urine flow seen. Foleys catheter inserted.

Weight of fibroid 2770 g and of whole specimen 3973g.

Conclusions

Our case demonstrates that uterine size is not a determinant for final surgical decision to use laparoscopic approach and surgical techniques used are fundamental to safe surgical practice.

<https://player.vimeo.com/video/710510876?autoplay=1>

vNOTES hysterectomy for polymyomatous uterus and removal by extracorporeal C-Incision Tissue Extraction (ExCITE) technique

Ester Martínez^{1,2}, Jesús Molero Vilchez^{2,3}, Marta Heras García^{2,4}, Jose Luis Prieto Alonso⁵

¹Infanta Leonor University Hospital, Obstetrics and Gynecology, Madrid, Spain

²Hospital Ntra Sra del Rosario, Oncologic Gynaecology, Madrid, Spain

³Toco-Gyn Gynaecological Clinic, Oncologic Gynaecology and Endoscopic Surgery, Alcalá de Henares, Spain

⁴Santa Cristina University Hospital, Gynecology and Obstetrics, Madrid, Spain

⁵Hospital Ntra Sra del Rosario, Gynecology and Obstetrics, Madrid, Spain

Background

Natural Orifice Transluminal Endoscopic Surgery (NOTES) is a minimally invasive surgical technique that uses natural orifices of the human body to get access to the abdominal cavity, for example through the vagina (vNOTES). The Vaginal Assisted NOTES Hysterectomy is being performed in the Rosario's Hospital in Madrid (Spain) since October 2021.

Our objective is to present our experience in performing VNOTES. The advantages of this new technique are less postoperative pain, no visible scars, shorter surgery time and more women treated in a daycare-setting compared to a laparoscopic hysterectomy.

Methods

This abstract presents the results of the first 13 cases in our hospital. Patient-related characteristics, operative characteristics and post-operative recovery were registered and analysed with IBM SPSS Statistics 20. The video shows two vNOTES hysterectomies with polymyomatous uterus, one of them with intraligamentary myoma, and the extraction the specimens by extracorporeal C-Incision Tissue Extraction (ExCITE) technique

Systematic steps in this procedure. (1) insertion of anterior and posterior retractor, (2) posterior and anterior colpotomy, (3) placement of Alexis®, (4) placement of port cover, trocars and creation of pneumoperitoneum, (5) proceed with hysterectomy procedure, (6) revision and hemostasis (7) removal of the specimen, (8) removal of the port cover and wound retractor, (9) and finally, suturing of the vaginal cuff.

Results

13 vNOTES hysterectomies were performed for benign indications. Indications were uterus myomatous (61,5%), abnormal vaginal bleeding (7.7%) and cervical dysplasia (23.1%). The mean age was 51.9 years (range 42-63 years) and mean BMI was 23.27 kg/m² (range 19.1-27.5 kg/m²). 15.3% with previous cesarean deliveries.

The mean surgical time was 89.6 minutes (SD 29.5 minutes) with a range of 45-150 minutes and the mean blood loss was 719.5 mL (SD 242.5 mL). The weight of the specimens was high (mean 268.5 grams, range 53.8-650 grams).

Same day discharge was achieved in 92.3 % of the patients (mean hospital stay was 1.08 days (SD 0.2). No conversions have been performed. No reported intra-operative nor postoperative complications.

Conclusions

vNOTES hysterectomy is a safe and feasible option for surgical management of select cases.

<https://player.vimeo.com/video/710138706?autoplay=1>

ES31-0156 - VP020

The feasibility of laparoscopic multi-articulating instrument, artisential, in single site robotic, endometrial cancer staging surgery

Ji Min Seo¹, Seongeun Bak¹, Keun Ho Lee¹

¹Seoul Saint Mary's hospital- The Catholic university of Korea, Obstetrics & Gynecology, Seoul, Korea- Republic Of

Background

In single site robotic surgery, the size of the incision site limits the number of equipment that may simultaneously enter the operation field to one camera and two robot arms. Therefore, in cases where an additional laparoscopic instrument is needed, creating another incision site is required.

Methods

We performed single site robotic surgery using the multi-articulating laparoscopic instrument, the Artisential.

Results

The Artisential allowed multiple degrees of movement to perform more complex techniques in surgery compared to rigid or straight instruments.

Conclusions

In surgeries that previously would have called for an additional incision site, we were able to successfully finish the single site robotic endometrial cancer staging surgery using the Artisential.

<https://player.vimeo.com/video/710152626?autoplay=1>

Laparoscopic management a perforated pyometra in a patient with locally advanced cervical cancer: a video case report

Marie Monnier¹, Samuel Khiat¹, Pascale Siles², Diane Mege³, Aubert Agostini¹, Patrice Crochet¹

¹Aix Marseille University, Gynecologic surgery, Marseille, France

²Aix Marseille University, Department of radiology, Marseille, France

³Aix Marseille University, Department of digestive surgery, Marseille, France

Background

Pyometra, the build-up of pus in the uterine cavity, is seen in <1% of patients with locally advanced cervical cancer. Spontaneous perforation of pyometra is rare and may cause a generalised peritonitis, mimicking gastrointestinal origin. Despite an adequate management, consisting of an emergency surgical drainage, morbidity and mortality rates are high. Additionally, this emergency procedure should allow for the subsequent optimal treatment of this cancer, which is radiochemotherapy.

Methods

This video presents a rare case of conservative laparoscopic management of spontaneous uterine rupture of pyomyetra in cervical cancer in a fifty-six-year-old woman, gravida 2 para 2, with past medical history of deep venous thrombosis of lower limb, endometriosis and sleeve gastrectomy. She presented with abdominal pain and tenderness. A peritonitis due to a spontaneous uterine perforation of pyometra was diagnosed. We performed a laparoscopic peritoneal lavage, transperitoneal drainage and suturing of the uterine fundus. Gynaecological examination under general anesthesia revealed a budding tumour of the cervix with involvement of anterior and posterior vaginal fornix to the upper third of the vagina (FIGO stage IIB). Following this emergency procedure, the patient received concomitant radio-chemotherapy and brachytherapy. Re-evaluation examinations showed complete response. A completion surgery (ie, hysterectomy, bilateral salpingo-oophorectomy and paraaortic lymphadenectomy) was decided due to the initial case presentation.

Results

Postoperative course was uneventful. No residual tumour was found on the hysterectomy specimen. Follow-up did not show any recurrence at 3 years.

Conclusions

This was the first reported case of laparoscopic management to treat a peritonitis due to a spontaneous uterine perforation of pyometra on cervical cancer. The use of laparoscopy seems to be an acceptable alternative to laparotomy in this clinical presentation. Conservative treatment allowed for a less morbid procedure and allowed for rapid initiation of radio-chemotherapy treatment in accordance with current recommendations for locally advanced cervical cancer.

<https://player.vimeo.com/video/710225584?autoplay=1>

Cold enucleation of a Submucous Myoma using a Diagnostic Scope

Mikaela Erlinda Bucu¹, Regina Tan-Espiritu¹

¹*University of the Philippines Manila College of Medicine, Obstetrics and Gynecology, Manila, Philippines*

Background

This video aims to demonstrate cold enucleation using a diagnostic scope to allow single-step hysteroscopic myomectomy in order to avoid energy- and fluid volume-related complications

Methods

The case is a 43-year-old G5P4 (4014) woman with prolonged and heavy menstrual bleeding of eight months duration. Saline infusion sonography revealed a 3.5 x 3.4 x 3.4 cm submucous myoma with <50% intramural component (FIGO Grade 1). Ultrasound-guided hysteroscopic myomectomy was done using a 30° diagnostic hysteroscope and normal saline solution as liquid medium. Using the bevel of the scope, blunt dissection was attained with gentle thrusts under direct visualization of the avascular subcapsular plane of the myoma. Cold scissors were used to release the remaining fibres of the capsule. Once the myoma was completely enucleated, progressive dilatation of the cervix was done and a resectoscope was used to bisect the large specimen. The specimen fragments were then completely evacuated using ovum forceps under ultrasound-guidance to avoid perforation.

Results

Hysteroscopic myomectomy of a large submucous myoma was successfully performed using cold enucleation with a diagnostic scope. The operative time for the enucleation was 20minutes. Blood loss was minimal, total fluid used was 2500cc with an acceptable negative fluid balance of 300cc. The patient tolerated the procedure well and had an unremarkable post-operative course.

Conclusions

Cold enucleation using a diagnostic scope is a novel approach in the management of submucous myomas with intramural component. This technique utilizes readily available equipment and was seen to potentially result in lesser intraoperative blood loss, decreased amount of distention media used and shorter operative time. Moreover, this technique lowers the risk for potential myometrial injury from electrosurgery. Lastly, it obviates the need for a second stage hysteroscopic myomectomy since the myoma is enucleated in toto.

<https://player.vimeo.com/video/710326048?autoplay=1>

Successful surgical management of a cornual ectopic pregnancy: a case presentation

Despina Demetriou¹, Konstantinos Kalfoutzos¹, Athanasios Argyriadis¹, Jens Kosse¹, Christian Jackisch¹

¹Sana Klinikum Offenbach, Obstetrics and Gynaecology, Offenbach am Main, Germany

Background

Cornual pregnancies are located in the interstitial part of the fallopian tube and account for 2-4% of all ectopic pregnancies. They pose a diagnostic and therapeutic challenge with significant morbidity and mortality due to the extreme vascularity of the area of implantation. The purpose of this video is to demonstrate the management of an unruptured cornual ectopic pregnancy with an optimal outcome.

Methods

We report a case of an oligosymptomatic 27-year-old G4P2, who presented with abnormal uterine bleeding and abdominal pain at 5 weeks and 3 days of gestation. The diagnosis of a right cornual ectopic pregnancy was made prior to rupture with ultrasound. Previous obstetric history included an early miscarriage followed by curettage, as well as two full term deliveries, one vaginal and one caesarean section. There was no history of medical disorders or drug intake.

Results

Transvaginal ultrasound revealed an empty uterus, with a gestational sac lateral of the uterine cavity on the right side, surrounded by thin myometrial layer, with great tissue vascularization. By amorphous embryonic parts, absence of heartbeat, β -HCG titer 1360 mIU/ml and no evidence of free fluid in the pouch of Douglas, methotrexate was applied intramuscular. Serial β -HCG titers were followed weekly until undetectable. Laparoscopic cornual wedge resection and myometrial re-approximation were carried out without complications after eight weeks and the patient was discharged on the second postoperative day.

Conclusions

Early diagnosis and appropriate preoperative planning are the key to effective management of cornual ectopic pregnancy. Systemic methotrexate use can be an effective initial therapeutic treatment for hemodynamically stable patients, especially in the presence of low HCG titers and absence of cardiac activity, before proceeding to surgical intervention.

<https://player.vimeo.com/video/710361667?autoplay=1>

Laparoscopic approach to ectopic pregnancy in a rudimentary uterus

Rita Dunkel¹, Maria Oliveira¹, Ana Marta Pinto¹, Marisa Moreira¹, Nuno Oliveira¹, Mário Oliveira¹

¹Centro Hospitalar Baixo Vouga, Ginecologia e Obstetrícia, Aveiro, Portugal

Background

Mullerian duct anomalies (MDAs) are rare developmental anomalies of the female reproductive tract, estimated to occur in 1-5% of all women. Despite these anomalies being common, the majority are asymptomatic. When symptomatic, ectopic pregnancy is the most common. Using the ESHRE/ESGE classification, Class U4 or hemi-uterus incorporates all cases of unilateral formed uterus. A sub-class: Class U4a or hemi-uterus with a rudimentary (functional) cavity, is characterized by the presence of a communicating or non-communicating functional contralateral horn. The presence of a functional cavity in the contralateral part is the only clinically important factor for complications, such as hemato-cavity or ectopic pregnancy in the rudimentary horn. Ectopic or extrauterine pregnancy accounts for 1.3-2.4% of all pregnancies. With the advancement in diagnostic modalities, almost all ectopic pregnancies are being detected and managed timely. However, ectopic pregnancies occurring in cases with Mullerian anomalies still pose diagnostic challenges. We report a case of ectopic pregnancy in a non-communicating functional contralateral horn safely managed by laparoscopic approach. The objective of this video is to call attention to this uncommon entity and how it can be safely managed by laparoscopic approach

Methods

We present a stepwise demonstration of the laparoscopic technique with narrated video footage

Results

Interventions: Total laparoscopic approach of ectopic pregnancy in a rudimentary horn. 1- Identification of the Müllerian Anomaly, the pelvic anatomy and the ectopic pregnancy. 2- Right salpingectomy. 3- Excision of the right rudimentary horn, with ectopic pregnancy in it

Conclusions

In this video, we demonstrate the surgical steps to perform an effective and safe laparoscopic approach to an ectopic pregnancy in a rudimentary horn.

<https://player.vimeo.com/video/708850240?autoplay=1>

Hysteroscopic Removal of Retained Gestational Products Using a New-style 12-Fr Spoon-shaped Forceps

Dan Sun¹, Zhenkun Guan², Nidhi Kashyap¹, Zengzi Zhou¹, Aiqian Zhang¹, Dabao Xu¹

¹the Third Xiangya Hospital of the Central South University, Obstetrics and Gynecology, Changsha, China

²Baylor College of Medicine, Obstetrics and Gynecology, Houston, USA

Background

To present a surgical technique using a new-style 12-French (Fr) spoon-shaped forceps in the management of retained gestational products.

Methods

The patient has retained gestational products in the right uterine cornu, sized 24*14*23mm, with placental accreta and severe intrauterine adhesions (IUAs). At first, a 4.8mm outer sheath hysteroscope with a 5-Fr working channel and an automatic open-and-close valve, combined with a 5-Fr double action spoon-shaped forceps, were used for hysteroscopic adhesiolysis (HA) using the blunt spreading dissection technique. After the adhesiolysis, an operative Z-shaped hysteroscope with an outer sheath diameter of 8.8 mm and a 12-Fr working channel, combined with a new-style 12-Fr double action spoon-shaped forceps with chute structure joint were used to remove the retained gestational products.

Results

The "see and treat" strategy of using the blunt spreading dissection technique successfully performed HA in one step without prior dilatation, which may reduce the risk of uterine perforation caused by blind dilatation. Owing to the powerful ability of grasping and pulling back tissues, the retained gestational product was quickly (10'20") and safely removed by using the new style 12-Fr spoon-shaped forceps. What's more, the spoon-shaped grasper can contain a big bite of the placental tissues, which is much effective than the Kelly forceps. The total amount of bleeding was about 20ml. Serum β -HCG decreased significantly on the first day after the surgery from 286.2 mIU/ml to 119.4 mIU/ml.

Conclusions

Removal of retained gestational products using a new-style 12-Fr forceps is simple, safe and effective. This new technique also helps in protecting the endometrium and worthy of further study.

<https://player.vimeo.com/video/724475546?autoplay=1>

Combined septoplasty technique with mechanical tools: scissors and morcellator.

Maria Carbonell Lopez¹, Angela Sanz Mase², Elena Rodriguez Gonzalez², Tamara Ruiz Martinez², Alicia Hernandez Gutierrez², Covadonga Álvarez Lopez¹

¹Hospital Universitario La Paz, Gynecology, Madrid, Spain

²Hospital La Paz, Gynecology, Madrid, Spain

Background

Congenital uterine malformations have a low prevalence in the general population (0.5-6.7%). These entities may affect the reproductive outcome of patients, as well as increase the incidence of repeat miscarriages, abnormal fetal presentations or preterm deliveries. Among congenital uterine malformations, uterine septum is the most common, reaching 90% of all cases. According to Betocchi, we can differentiate between two types of septa. The first type is fibrous while the second type is fibromuscular histology. Hysteroscopy is currently the gold standard technique since it allows evaluation and treatment at the same time. The aim of this video is to show the use of the combined hysteroscopic technique with scissor and morcellator in the treatment of the fibromuscular septal uterus in order to resect as much tissue as possible and avoid the use of energy and its potential impact on subsequent sinechia.

Methods

We present the case of a 38-year-old patient with a history of primary infertility. During the sterility study, a müllerian malformation of the complete uterus septum type was discovered. A 3D ultrasound was performed (Image 1).

Results

During hysteroscopy, a complete 2cm wide septum is observed, reaching the lower 1/3 of the endocervical canal. The septum is sectioned with scissors leaving as much tissue as possible on the anterior wall of the uterus. Subsequently, the anterior left tissue was resected with a Myosure-type hysteroscopic morcellator to remove as much tissue as possible and allow greater distension of the uterine cavity in the event of a future pregnancy.

Conclusions

Early diagnosis and treatment can lead to successful reproductive techniques in patients with infertility or repeated miscarriages. Hysteroscopic resection is therefore considered a simple, safe and effective therapeutic method. The use of a combined technique with scissor and morcellator could improve obstetric outcomes by avoiding the use of energy and removing more tissue allowing greater distension of the uterine cavity.

<https://player.vimeo.com/video/710463312?autoplay=1>

Osseous metaplasia of the endometrium- The bony womb and its hysteroscopic management.

Naimah Raza¹, Lina Antoun¹, Paul Smith¹, Justin Clark¹

¹Birmingham Women's Hospital, Obstetrics & Gynaecology, Birmingham, United Kingdom

Background

Background

Osseous metaplasia of the endometrium is a rare pathological condition associated with the presence of bone in the uterine endometrium. Clinically, it presents with menstrual problems or infertility. Most cases occur following pregnancy, especially miscarriages or abortion.

Methods

Case / Method

A 29-year-old nulliparous woman attended our out-patient clinic with irregular heavy periods and secondary infertility. She underwent a surgical termination of pregnancy at 20 weeks three years ago in Nigeria. She had an out-patient hysteroscopy which showed bony fragments in the endometrial cavity. One of the bony fragments was retrieved using hysteroscopy forceps and sent for histopathological examination. Histology was suggestive of endometrial osseous metaplasia. A further hysteroscopic retrieval was planned under general anaesthesia, after pre-operative GnRH analogues. Truclear Elite Hysteroscope plus and tissue shaver was used to break down the bony parts and remove them. Check hysteroscopy showed a clear cavity with bilateral ostia visualised.

Results

Histology of the sample retrieved showed fragments of trabecular bone with non-hematopoietic marrow spaces suggestive of metaplastic changes.

We referred her to our fertility MDT where she and her partner had normal investigations. She is currently under the care of our fertility team

Conclusions

Hysteroscopy is the gold standard for diagnosis and management of osseous metaplasia of endometrium. Clinicians need to be aware of this rare condition when they encounter such clinical presentation in a woman, especially following an abortion or miscarriage. Timely diagnosis and treatment is the key, particularly when fertility is a concern.

<https://player.vimeo.com/video/717908182?autoplay=1>

vNOTES hysterectomy in difficult cases

Marta Hinarejos Companyó¹, Estela Márquez Muñoz¹, Ana Paula Vélez Vintimilla¹, Antoni Pessarrodona Isern¹, Jordi Cassadó Garriga¹, Jordi Rodríguez González¹

¹Hospital Universitari Mútua de Terrassa, Gynaecology and Obstetrics, Terrassa, Spain

Background

Among others, one of the objectives of the introduction of the V-NOTES (Vaginal Nature Orifice Transluminal Endoscopic Surgery) technique in hysterectomy is being able to perform hysterectomies via the vagina that would be very complex or impossible with the classic access.

Methods

We present three different special hysterectomies approached by V – NOTES technique that would have been very difficult to resolve by laparoscopy or via vaginal.

Results

The first case is a 68 -year-old patient who consulted for acute urinary retention due to an incarcerated retrocervical fibroid. This fibroid was located in an extraperitoneal location and it was necessary to morcellate it in order to access the pouch of Douglas.

After placing the vaginal port, the hysterectomy was performed without any difficulty. Laparoscopic access would have been extremely complicated in this case due to the size and location of the fibroid.

The second case is a 45-year-old patient with a polymyomatous uterus and metrorrhagia. The larger myoma was 9 cm and the MRI showed a calcified periphery.

A V-notes hysterectomy was performed without difficulty. During morcellation we reached the calcified myoma which was impossible to section. We tried to remove it with a Simpsons forceps without success. Thanks to the use of orthopaedic instruments, Bone Riunger and Wire Cutter we were able to fragment and remove it.

The third case is a woman with metrorrhagia and myomatous uterus with a history of myomectomy six years before for a 10 cm fibroid. On ultrasound the uterus was not mobile, but on MRI there was a minimal amount of fluid in the pouch of Douglas.

With v – NOTES, we had easy access to the abdomen, observing the posterior aspect of the uterus completely adhered to the right presacral space. Under good vision, we could liberate the adhesions without difficulty and easily performed the hysterectomy.

Conclusions

In conclusion, V-Notes allows excellent vision in cases of complex vaginal hysterectomies.

<https://player.vimeo.com/video/710477482?autoplay=1>

Laparoscopy for the treatment of ureteral, intestinal, ovarian and appendix endometriosis

Priscilla Pessoa¹, Mira Zlotnik¹, Fernanda Dishchekian¹, Bruna Bottura¹, D'Amico Ricardo², Fernanda Asencio¹

¹*Hospital Israelita Albert Einstein, Gynecology and Obstetrics, São Paulo, Brazil*

²*Grupo NotreDame-Intermédica, Gynecology and Obstetrics, São Paulo, Brazil*

Background

To present a case of deep endometriosis with uterine, ovarian, ureteral, rectal and appendix involvement and the importance of anatomical knowledge and surgical technique for a better operative approach.

Methods

We present the case of a 42-year-old woman with symptoms of severe pain due to endometriosis, reporting dysmenorrhea and profound dyspareunia.

Ultrasound showed a 4.2 cm retrocervical lesion attached to the ovaries and rectum that also compromised the ureters bilaterally, with upstream dilatation, another rectal lesion, 15 cm from the anal border, affecting 20% of the loop circumference, and an endometrioma in the right ovary.

Faced with the ineffectiveness of previous clinical treatment and imaging findings, we proposed laparoscopy to treat the endometriosis and perform hysterectomy.

To access the cavity, four conventional laparoscopic portals were positioned: one in the umbilical scar for optics, two in the right and left iliac fossae, and one in the suprapubic region, completing the triangulation.

Results

The duration of surgery was four hours, with minimal blood loss and no complications.

Despite the surgical complexity, it was possible to resect the ureter lesions bilaterally, uterine torus, rectum and appendiceal lesions.

The patient had a satisfactory postoperative clinical course, with good postoperative pain control.

The pathological report of the material confirmed endometriosis.

Conclusions

Endometriosis affects about 15% of the female population of reproductive age and has high rates of morbidity, such as infertility and chronic pelvic pain.

Surgery is usually indicated when clinical treatment fails, involves the ureter or appendix, causes infertility or intestinal obstruction.

Moreover, depending on the severity of the disease, the surgical complexity increases, and a thorough anatomical knowledge is essential for the best surgical approach, thus avoiding serious complications such as ureteral, bladder, intestinal and nervous damage.

<https://player.vimeo.com/video/710211035?autoplay=1>

Laparoscopic surgical approaches to treat giant adnexal cysts

*Ana Paula Velez Vintimilla¹, Estela Márquez Muñoz¹, Marta Hinarejos Companyó¹, Laura Blanch Font¹,
Jordi Cassadó Garriga¹, Jordi Rodríguez González¹*

¹Hospital Universitari Mútua de Terrassa, Gynaecology and Obstetrics, Terrassa, Spain

Background

Large benign ovarian cysts often require surgical management due to its size and associated symptoms. Although size may hinder the laparoscopic management, the techniques we present may help to succeed in a minimally invasive approach of large ovarian cysts. It is very important to rule out malignancy, performing imaging and tumour markers.

Methods

The objective of this video is to show some safe techniques for laparoscopic cystectomy or adnexectomy of large benign ovarian cysts.

Results

The first technique starts by inserting a 5mm balloon trocar directly to the cyst by direct visualization, then, aspiration of the fluid is performed, and we proceed by ligating the cyst to avoid any spillage. We carry on by performing the adnexectomy.

In the second case, we puncture the cyst with a 5 mm balloon trocar, and we empty the hole content while blocking the cyst with the trocar in the anterior abdominal wall. We proceed on doing the adnexectomy and then we deflate the balloon and introduce the hole cyst inside an endobag.

In cysts that fill all the abdominal cavity, a possible surgical technique starts by inserting a 5mm suprapubic trocar directly to the cyst, and then aspirating all the fluid content. Then, we proceed to perform the cystectomy and we place the piece in a laparoscopic bag for a safe extraction by umbilical 12 mm trocar.

Conclusions

In conclusion, with an accurate previous diagnosis, these techniques allow a minimally invasive approach of large benign cysts and are safe and feasible techniques.

<https://player.vimeo.com/video/710502926?autoplay=1>

Double trouble with double ureters: a rare occasion

Ayesha Mahmud¹, Gourab Misra¹

¹University Hospitals of North Midlands, Obstetrics & Gynaecology, Stoke-on-trent, United Kingdom

Background

Congenital anomalies of the kidney and urinary tract (CAKUT) is a group of abnormalities with a reported incidence of 1 in 500. Such anomalies can result in anatomical displacement of the kidneys and the ureters. Similar anatomical displacements can be found in the presence of endometriosis, fibroids, and pelvic tumours. Congenital anomalies, such as ureteral duplication (incomplete or complete variety), ectopic ureter, or an ectopic kidney can all increase the risk of injury during surgery. To prevent injury, knowledge of congenital anomalies and identification of ureteric anatomy at laparoscopy is essential.

Methods

We present a short video of a case where ureteric anomalies (double ureter) were identified during surgery for endometriosis.

Results

The anatomy is clearly defined by undertaking ureterolysis with safe completion of surgery by avoiding injury.

Conclusions

Duplication of the renal collecting system impacts approximately 0.5% to 4% of the population. As such, incomplete variety is more common than complete duplication. This occurs secondary to the early bifurcation of a single ureteric bud before meeting the metanephros, resulting in a duplicate pelvicalyceal system where the two ureters merge before entering the bladder at a single orifice. The fusion can happen anywhere along the ureteral course, and most patients are asymptomatic. With complete duplication, 2 separate ureteric buds emerge from the mesonephric duct forming 2 ureters that drain the upper and lower renal poles separately with individual openings into the bladder. This uncommon variation is associated with recurrent urinary tract infections and vesicoureteral reflux. In this case, knowledge of congenital anomalies and identification of ureteric anatomy at laparoscopy prevented injury.

<https://player.vimeo.com/video/710503477?autoplay=1>

Hysteroscopic injury of the left uterine artery

Mathis Wüster¹, Haytham Elmeligy¹, Brigitte Dietze²

¹St. Elisabeth Hospital Germany, Gynecology, Damme, Germany

²St. Elisabeth Hospital, Gynecology, Damme, Germany

Background

69 years old patient presents herself with a uterine polyp and an adnexal cystical tumour of the left side 39x30 mm without symptoms. She also had a 4 cm intramural myoma and a serometra with a possible stenosis of the cervix.

Methods

Surgery: operative Hysteroscopy with a removal of a cervical polyp, operative laparoscopy with bilateral adnexectomy and suture of the uterine vessels due an injury, ureterolysis left

Results

We performed a hysteroscopic excision of the cervical polyp after opening the stenosis of the cervix uteri. During the procedure there was no *via falsa* or bleeding visible. Because of the cystical tumour from the left ovary a laparoscopic adnexectomy was planned. Entering the abdominal cavity, we could see a big hematoma of the left pelvic sidewall which occurred due to a perforation of the uterus wall and lead to an injury of the uterine artery. After an uncomplicated bilateral adnexectomy we had to find the injured vessel. Therefore, it was mandatory to open up the retroperitoneal space to find the injury, stop the bleeding and to remove the hematoma. We did a suture of the left uterine vessel and dissected the left ureter. Afterwards to protect the ureter it is recommended to put a DJ stent inside for a few weeks to prevent stenosis.

Conclusions

Also, minor surgeries can lead to major injuries. It is important to make good visual contact the structures to prevent further damage. We prefer a suture of injured vessels close to the ureter as far it is possible because like this you have the possibility of removing the suture and avoid thermal damage.

<https://player.vimeo.com/video/710509416?autoplay=1>

Laparoscopic removal of a 20 years forgotten needle in the lower abdomen

Theodoros Theodoridis¹, Christos Zymperdikas¹, Tilemachos Karalis¹, Eva Zioga¹, Eleftherios Klonos¹, Grigoris Grimbizis¹

¹Medical School- Aristotle University of Thessaloniki, 1st Department of Obstetrics and Gynaecology, Thessaloniki, Greece

Background

This is the case of a G1P1 patient who presents at the emergency department with severe the lower abdomen pain.

She underwent a Caesarean Section performed 20 years ago in another Balkan country.

The rest of her history was unremarkable. During the imaging procedure of the case's investigation, a foreign material (surgical needle) was discovered through the x-ray at the lower part of the abdomen. In the sequel, MRI was performed and the presence of the foreign material was established in an abscess cavity at the abdominal wall respectively to the left horn of the uterus.

The aim of the present video is to point out the surgical steps of laparoscopic excision of the foreign material from the patient's abdomen.

Methods

A 4-port-laparoscopy was performed. The first step of the surgery was to divide the sigmoid colon adhesions. Secondly, the division of the adhesions between the right ovary and the abdominal wall was performed. In the sequel, according to the MRI, incisions were performed on the lower section of the left uterovesical space, in order to reveal the abscess cavity. Under careful dissection, the abscess cavity was intersected and the needle was identified and removed from the abdomen under continuous surveillance. Finally, the retroperitoneal spaced was sufficiently washed by warm saline and an extended control of haemostasis was performed.

Results

The patient's recovery was uncomplicated. The patient was discharged 2 days post-operatively and provided with antibiotic treatment for 7 days.

Conclusions

The surgical steps of laparoscopic excision of a foreign material from the abdomen are demonstrated in the present video. Careful surgical handling is necessary in order to remove the needle and efficiently treat the abscess cavity with the lowest possible complication rate.

<https://player.vimeo.com/video/710511315?autoplay=1>

Laparoscopic iatrogenic lesion of a left renal vein during extra-peritoneal lomboaortic lymphadenectomy – can we manage this?

Joana Oliveira¹, Cristina Celada-Castro², Kristina Agababayan³, Bárbara Gomes¹, Juan Gilabert-Aguilar⁴, Juan Gilabert-Estellés^{3,4}

¹*Centro Hospitalar e Universitário de Coimbra, Gynaecology Department, Coimbra, Portugal*

²*Hospital Universitari de Vic, Department of Gynecology and Obstetrics, Barcelona, Spain*

³*Hospital General Universitario de Valencia, Endoscopy and Gynecologic Oncology Unit, Valencia, Spain*

⁴*European Gynecology Endoscopy School E.G.E.S., European Gynecology Endoscopy School E.G.E.S., Valencia, Spain*

Background

Objectives: To emphasize the potential vascular risks that the gynecological oncology surgeons should be aware of during a laparoscopic para-aortic lymphadenectomy and how to manage these possible complications.

Methods

Case description: A 68-year-old woman, G1 P0, suffering from metabolic syndrome (body mass index of 47 kg/m², type 2 diabetes mellitus, chronic hypertension, and dyslipidemia) was referred to the gynecological appointment of a tertiary referral hospital due to a post-menopausal haemorrhage. The ultrasound revealed an endometrial thickening with score 3 vascularization. She was proposed for hysteroscopy, during which some hypertrophic and hypervascularized areas suggestive of atypical hyperplasia/malignancy were biopsied. The pathology result was a well-differentiated low-grade endometrioid carcinoma. The magnetic resonance imaging described endometrial irregularity, with loss of endometrium-myometrium junction, and invasion of > 50% of the myometrium but an intact uterine serosa. The cervix, parametria, and lymph nodes seemed not to be involved, thus suggesting a IB grade 1 endometrial tumour. The patient was then proposed for extra-peritoneal lomboaortic(LA) laparoscopic lymphadenectomy(LFN), trans-peritoneal bilateral pelvic lymphadenectomy, and a total hysterectomy with bilateral salpingo-oophorectomy.

Results

During the dissection of the superior limit of the LA LFN, there was an incidental lesion of the left renal vein with the LigaSure™ Maryland. In order to stop the bleeding, the surgeon successfully applied the Fibrin Sealant Patch - Tachosil® and the starch-based hemostatic powder - Arista®. The postoperative period was uneventful, with hospital discharge on day eight.

Conclusions

This case highlights the need for a high-level knowledge of retroperitoneal vascular anatomy. Sometimes the preoperative analysis of imaging methods can provide the casual finding of a vascular anomaly, but they are frequently not reported. Thus, the surgeon must also have accurate surgical skills in order to avoid potential vascular injuries during laparoscopic. lomboaortic lymphadenectomy. It is crucial to identify intraoperative complications and to develop abilities to manage them.

<https://player.vimeo.com/video/710527896?autoplay=1>

Literature review and surgical strategy of isthmocele

Estela Marquez Muñoz¹, Laura Blanch Fons², Gemma Escribano Montesdeoca³, Anna Carmona Ruiz³, AnaPaula Velez Vintimilla¹, Marta Hinarejos Companyo¹

¹*Gynecology and Obstetrics Resident, Gynecology and Obstetric, Hospital universitari mutua de Terrassa, Spain*

²*Gynecology and Obstetrics, Hysteroscopy, Terrassa- Barcelona, Spain*

³*Gynecology and Obstetrics, Surgery, Terrassa, Spain*

Background

Worldwide caesarean section rates have risen from around 7% in 1990 to 21% today and are projected to continue increasing over this current decade, therefore, the diagnosis of caesarean scar defects has also increased. Isthmocele is mainly an asymptomatic condition, but in some patients, infertility, spotting and dismenorrea can occur. There are some complications that cannot be forgotten such as uterine rupture, caesarean scar pregnancy and placenta accrete.

Methods

We searched information on Pubmed database using the words "surgical isthmocele". We performed a combined surgery recommended for RMT under 2mm (hysteroscopy and laparoscopy) and recorded it. We asked the patient for permission.

Results

The patient is nowadays pregnant 20 week pregnant. In the video, we explain the technique and show how we usually do this kind of surgery in our hospital.

Conclusions

The most important factor to decide which treatment would be indicated is the Residual myometrial thickness (RMT). A good diagnosis allows gynaecologist to choose the best option and perform an accurate excision.

<https://player.vimeo.com/video/710531304?autoplay=1>

The applicability of minimally invasive surgery for high volume ovarian tumour in postmenopausal women

Fernanda Dishchekenian¹, Priscilla Pessoa², Vinicius Campos², Gustavo Barison², Carolina Resende², Mariano Tamura²

¹Hospital Moriah- Hospital Israelita Albert Einstein, Gynecology, Sao Paulo, Brazil

²Hospital Israelita Albert Einstein, Gynecology, Sao Paulo, Brazil

Background

To present the applicability of a robot-assisted hysterectomy and salpingo-oophorectomy in a case of large ovarian mass.

Methods

52 years- old postmenopausal patient was followed during five years due to an ovarian mass with slowly increasing size. Patient remained asymptomatic since diagnosis and CA 125 has always presented a normal value. MRI showed uterine volume of 60 cc and left solid ovarian mass with dimensions of 8,2 x 9,0 x 11,2 cm.

Patient was eligible for robot-assisted laparoscopy for hysterectomy and bilateral salpingo-oophorectomy. Patient was placed in semi gynaecological position, under general anaesthesia, with arms alongside the body and legs 80 grades abducted in adjustable leggings. Three robotic portals were positioned: one in the umbilical scar for the optics and two on the right and left iliac fossae. In addition, a conventional laparoscopic portal was positioned in the right flank.

At the cavity inventory it was visualized a solid ovarian tumour adhered to the abdominal wall and occupying great part of the pelvis. In addition, there was a vesical peritoneal retractile lesion and some suspicious mesocolon small lesions. Peritoneal fluid was aspirated for cytological analysis. Because of tumour aspect and the impossibility to exclude malignancy the surgery strategy was a protective extraction in two times: starting by uterus and right ovary in block followed by left adnexal mass. Both were carefully extracted protected by an endobag. It was also performed adhesiolysis, vesical peritoneal lesion excision and partial omentectomy.

Results

Surgical duration was three hours and a half, with minimal blood loss and no complications. Patient had satisfactory postoperative evolution, discharged on the second postoperative day. Pathology report indicated adenomyosis, endometriosis and ovaries with bilateral serous adenofibroma. Peritoneal fluid had no evidence of malignancy.

Conclusions

This report demonstrated a challenging surgery in which the strategy needed to be adapted according to the intraoperative findings. In such complex cases, the applicability of the robotic platform with its precise movements and optimal abdominal vision allows a safer management. Based on malignancy scores, risks and protocols the procedure followed important fundamentals and had proportioned patients cure. To conclude, this case illustrates a robot-assisted minimally invasive surgery as a safe alternative for high volume ovarian tumour.

<https://player.vimeo.com/video/710533518?autoplay=1>

laparoscopic management of frozen pelvis and excision of large endometrioma

Gaurab Gurung¹, Ahmed Elgohar², Samantha Mader², Arpan Chatterjee²

¹East Kent Hospitals University NHS Foundation Trust- Queen Elizabeth The Queen Mother Hospital, Department of Women's Health, Maidstone, United Kingdom

²East Kent Hospitals University NHS Foundation Trust- Queen Elizabeth The Queen Mother Hospital, Department of Women's Health, Margate, United Kingdom

Background

Endometriosis is a chronic inflammatory disease defined as the presence of endometrium-like tissue outside the uterus. The prevalence of endometriosis is 5-10% within the general female population but can be up to 50% in infertile women.

Laparoscopic management of frozen pelvis is a challenging and difficult surgical procedure as there are high risks of injuries to vital organs due to distortion of normal anatomical landmarks, spaces and surgical plane.

We present a case of a young 29-year-old nulliparous woman who presented to our endometriosis centre with the history of lower abdominal pain, heavy menstrual bleeding, dysmenorrhoea, dyschezia and dyspareunia for 2 years. Her frequent visits to emergency for symptom relief medications further impacted her quality of life and studies. Her periods were regular 28-day cycles with bleeding days of 5-7 but they were heavy and painful. USS showed a large multiloculated right ovarian cyst measuring 16 cm suggestive of endometriosis with minimal ovarian stroma which was distorting pelvic anatomy.

Preoperative MRI pelvis showed the left ovary was positioned postero-laterally, adherent to the top of the uterus with a clear recto-vaginal nodule and tethering with the rectosigmoid colon to the back of this nodule. It also showed thickened uterosacral ligament and endometrial polyp. We offered surgery in the form of laparoscopy, bilateral ureterolysis, excision of endometriosis, shaving of recto-vaginal shaving and ovarian cystectomy with a high risk of oophorectomy. She had bowel preparation on the day of operation.

Methods

Video showing the safe approach and systematic steps

Results

The patient had an uneventful operation and was discharged on day 2 post-op. Histopathological examination confirmed endometriosis and routine six-week follow-up showed complete resolution of her pelvic pain, dyschezia and dysmenorrhoea. However, dyspareunia was not quantified as she was not sexually active.

Conclusions

We showed the video of excision of a large endometrioma and frozen pelvis via laparoscopy using a systematic approach and visualizing the anatomical areas most at risk and achieving complete excision of endometriosis.

<https://player.vimeo.com/video/715534471?autoplay=1>

Total Laparoscopic hysterectomy - Does size matter?

Kunal Rathod¹, Yatin Thakur², Mahmoud Awaly¹, Premila Kollipara¹, Reetam Singh², Vidya Thakur³

¹*Queens Hospital Romford, Gynaecology, London, United Kingdom*

²*Basildon Hospital, Gynaecology, Essex, United Kingdom*

³*Broomfield Hospital, Gynaecology, Essex, United Kingdom*

Background

The aim of this video is to describe surgical strategies to approach the laparoscopic hysterectomy for the very large uterus.

Hysterectomy for large uteri is challenging, especially so when attempted with the laparoscopic approach as large fibroids fill the pelvis obstructing the view and ability to reach the pedicles. These uteri are also difficult to mobilise and manipulate, thus obscuring surrounding anatomic structures. One cannot deny the advantages of laparoscopic surgeries such as less blood loss, less post-operative pain due to less insult to the abdominal wall, quick mobilisation and recovery. There are no clear guidelines about surgical approach to large uteri, but each surgeon should approach with the method they are most competent with.

Methods

Our case demonstrates that uterine size is not a determinant for a final surgical decision to use laparoscopic hysterectomy. Therefore, if not contraindicated by the patient's comorbidities or peculiar anatomical conditions, we believe that laparoscopic hysterectomy could be performed in the presence of large uteri without hypothetical weight limits.

Results

Here we report the case of a TLH performed for a very large fibromatous uteri weighing 1560 gms in a 44-year-old Caucasian woman. The surgery had no complications with an operating time of approximately 110 min. The patient was discharged from the hospital on postoperative day 1 in very good condition.

Conclusions

Laparoscopic hysterectomy is technically feasible and safe procedure for large uteri. The learning curve can be variable and can be performed by experienced surgeons regardless of the size, number or location of the fibroids without much morbidity.

<https://player.vimeo.com/video/710534401?autoplay=1>

ES31-0311 - VP040

How to open the road for a safe TLH in severe and deep endometriosis

Dimitrios-Efthymios Vlachos¹, Konstantinos Kypriotis¹, Nikolaos Kathopoulos¹, Michael Diakosavvas¹, Joanna Lardou¹, Athanasios Protopapas¹

¹National and Kapodistrian University of Athens, Endoscopic Surgery Unit, Athens, Greece

Background

Deep infiltrating endometriosis (DIE) is a chronic inflammatory disease that causes chronic pelvic pain and has a detrimental effect on the quality of patients' life. Cornerstone of the DIE treatment is surgical excision of infiltrating nodules. Hysterectomy is not usually performed because of the DIE patients' young age. Nevertheless, patients' that have finished their reproduction or have very intense symptomatology from DIE opt for hysterectomy as a last resort for symptom alleviation.

Methods

Step-by-step video presentation of a total laparoscopic hysterectomy in a patient with deep infiltrating endometriosis.

Results

Video presentation.

Conclusions

Total laparoscopic hysterectomy in DIE patients is a demanding procedure, due to the adhesions, parametrial fibrosis and increased vascularization. The surgent must be aware of the necessary steps, that should be undertaken in order to conduct the operation safely and be capable to detect and repair complications from neighboring organs.

<https://player.vimeo.com/video/710537379?autoplay=1>

Laparoscopic isthmocele correction assisted with hysteroscopy

Ana Vegas¹, Rafael Jiménez¹, Daniel Ordóñez¹, Fátima Martínez¹, Álvaro Martínez¹, Elena Carrillo de Albornoz¹
¹Hospital Ruber Internacional, Obstetrics- Gyneacology and Reproductive Medicine, Madrid, Spain

Background

The number of deliveries by caesarean section (CS) has increased during the last years. This increasement has also involved a greater number of complications.

Among the gynaecological complications of the CS, we find the isthmocele. It is defined as a reservoir-like pouch in the isthmus of the anterior uterine wall, at the site of the CS scar.

The main symptoms of the isthmocele are abnormal uterine bleeding, abdominal pain and secondary infertility.

It can be identified by transvaginal ultrasound, hysterosonography and hysteroscopy that even permits the correction of the defect.

Isthmoceles can be repaired by hysteroscopy or laparoscopy. The residual myometrial thickness (RMT) above the defect is the condition that stablish the surgical approach. If the RMT is less than 2,5-3mm it is recommended the laparoscopic approach with hysteroscopic assistance.

We present a video of a laparoscopic isthmocele correction assisted with hysteroscopy.

Methods

We present the case of a 37-year-old patient, with a previous C-section who came to our office refering secondary infertility and postmenstrual bleeding.

In the ultrasound examination an isthmocele with <1mm RMT was observed. Laparoscopic repair of the defect was proposed.

Patient accept the surgery and sign the informed consent.

Laparoscopy was performed. Pneumoperitoneum was done with Veress needle through Palmer's Point.

At the beginning of the surgery adhesions between the bladder and the uterus were found. First of all, the dissection of the bladder was performed to expose the area where the isthmocele would be found. This dissection should be made very carefully, to avoid injuring the bladder

Once the dissection of the bladder was finished, the hysteroscope was introduced through the cervix until reaching the isthmocele. The light of the hysteroscope allowed to identify the isthmocele in the laparoscopy.

After locating the isthmocele we proceeded to open it. The resection of the fibrotic areas around the isthmocele was performed, leaving healthy tissue around the defect.

The resection of the fibrotic tissue was performed with scissors avoiding the use of energy in order to get a correct healing

After removing all fibrotic tissue, we performed the suture of the defect. Barbed suture was used

The hysteroscope was introduced again to prevent the stenosis of the cervical canal.

Once the two-layer suture was completed, the correct closure of the defect was checked with the hysteroscope.

Results

6 months after surgical correction patient got spontaneously pregnant. In the 38th week of gestation a programmed C-Section was performed giving birth to a healthy newborn.

Conclusions

Surgical repair of the caesarean scar defect may improve reproductive outcome and also reduces postmenstrual bleeding in symptomatic patients.

<https://player.vimeo.com/video/710539908?autoplay=1>

Adenomyosis; challenges in laparoscopic surgery

Abhijeet Shah¹, Ahmed Mohamed Abdelmohsen², Vinu Krishna Das³, Janani Ponnambalathan², Syeda Khairunnisa²

¹*East Kent Hospitals NHS Trust, Gynaecology, Ashford, United Kingdom*

²*East Kent University Hospitals NHS Trust, Obstetrics & Gynaecology, Ashford, United Kingdom*

³*Dartford General Hospital, Obstetrics & Gynaecology, Dartford, United Kingdom*

Background

Adenomyosis is still not very well understood and there is no global consensus on definition and pathogenesis. Patient and General practitioner awareness is still poor and needs more emphasis in development of this significant debilitating condition. We present a video of women who struggled for many years for diagnosis and eventually had laparoscopic Hysterectomy for her medical condition.

Methods

A 46-year-old woman presented to the Gynaecology clinic with history of prolonged bleeding and pain for many years. She is a para 2 with 2 previous caesarean sections. Her last cervical smear was normal. There was no medical or surgical history of note. Her BMI in the clinic was 39. MRI revealed possible adenomyosis and small fibroids which were intramural. She had diagnostic laparoscopy for pelvic pain and mild endometriosis was excised. Her symptoms continued hence had hysterectomy. Alternative options discussed were GnRH analogues.

Results

Total laparoscopic hysterectomy, bilateral ureterolysis and bilateral salpingo-oophorectomy was performed under GA and spinal. Procedure was uneventful and no complications. The procedure was performed with Harmonic ACE and colpotomy was done with monopolar scissors. Vault was sutured with 2-0 V-lock PDS.

The procedure was challenging as large uterus was a bit difficult to manipulate with uterine manipulator (V CARE cup) and also re-reeval post colpotomy was challenging.

Blood loss was minimal and less than 20 ml. She stayed overnight and was discharged home next day. Histology confirmed adenomyosis and small fibroids.

Conclusions

Regarding the current management of adenomyosis, there are no international guidelines or consensus for management. This is very significant in discussions with patient and primary care. Patient awareness also needs to be improved just similar to endometriosis. This is not same as endometriosis although many symptoms are similar.

<https://player.vimeo.com/video/710544991?autoplay=1>

Ureterolysis in a Patient with Deep Endometriosis And Bilateral Ureteral Duplication

Cristiana Soares¹, Margarida Cal¹, Carla Nunes¹, Catarina Castro¹, Ana Luísa Ribeiro¹, Filipa Osório²

¹Centro Hospitalar Universitário Lisboa Norte, Ginecologia- Obstetrícia e Medicina da Reprodução, Lisbon, Portugal

²Hospital da Luz Lisboa, Ginecologia, Lisbon, Portugal

Background

Authors present a case of a laparoscopic ureterolysis in a patient with bilateral ureteral duplication. Ureteral duplication is the most common renal abnormality, estimated to occur in 1% of the population. Complete bilateral duplication is found in around 1:500 persons.

Methods

The patient was a 49-year-old woman with a diagnosis of deep endometriosis and adenomyosis and associated chronic pelvic pain. She was proposed for total laparoscopic hysterectomy (TLH), bilateral adnexectomy (BA) and rectovaginal septum nodule (RVSN) excision. A unilateral ureteral duplication was known preoperatively.

Results

During surgery, extensive adhesions between the ureters and ovaries were visualized bilaterally. During blunt dissection of the adhesions, a bilateral ureter duplication was found. Ureteral peristalsis in all four ureters was identified. With blunt and sharp dissections, ureterolysis was possible and TLH and BA were performed. Although part of the RVSN was removed with the uterus, further excision from the vaginal wall was needed and a vertical closure of the vagina was performed to keep a normal vaginal length. Postoperatively, the urinary catheter was removed 18 hours later, with normal diuresis thereafter. Patient evolution was without complications. Pathology results are awaited, and post-surgery revision is scheduled within a month after surgery.

Conclusions

With this video, we aim to show a technically difficult lysis of pelvic adhesions performed laparoscopically, in a patient with a urinary tract malformation. Surgeons must be watchful for anatomical variants.

<https://player.vimeo.com/video/711723359?autoplay=1>

Laparoscopic Treatment of Accessory Cavitated Uterine Mass (ACUM): 2 Cases

Salih Yilmaz¹, Aysel Ozkaynak¹, Ahmet Kale², Engin Oral³, Taner Usta⁴

¹Acibadem Altunizade Hospital, Gynecology and Obstetrics, Istanbul, Turkey

²Health Sciences University- Kartal Lutfi Kirdar Training and Research Hospital, Gynecology and Obstetrics, Istanbul, Turkey

³Bezmi Alem Vakif University- School of Medicine, Gynecology and Obstetrics, Istanbul, Turkey

⁴Mehmet Ali Aydinlar Acibadem University- Acibadem Altunizade Hospital, Gynecology and Obstetrics, Istanbul, Turkey

Background

Accessory cavitated uterine mass (ACUM) is a rare entity, more frequently observed in young, nulliparous women, and is characterized by severe dysmenorrhea and chronic pelvic pain. Previously it is described as juvenile cystic adenomyosis or juvenile cystic adenomyoma.

Herein, we report two cases of successful laparoscopic ACUM excision in young women who complained of severe dysmenorrhea and recurrent pelvic pain, diagnosed as ACUM.

Methods

Case 1: A 23-year-old woman complained of severe dysmenorrhea, dyspareunia and chronic pelvic pain. She had taken oral analgesics during these periods, oral contraceptive pill and dienogest for 2 years before admission; however, they did not relieve the pain. Transvaginal ultrasonography revealed a 3 cm diameter thick-walled cyst on the right side of uterus proximity to right broad ligament. MRI revealed noncommunicating cystic lesion on the right side of uterus. Laparoscopic excision of the mass was performed.

Case 2: A 24-year-old woman presented with severe dysmenorrhea and chronic pelvic pain for 3 years. She attained menarche at 16 years of age. She had previously taken analgesic drugs, oral contraceptive pills, dienogest and GnRH analogues. She had undergone hysteroscopy and cystic mass was determined on the posterior wall of the uterus. On her gynaecological examination a 4 cm diameter cystic mass revealed on the posterior wall of the uterus. On MRI cystic mass is not communicating with endometrial cavity. Laparoscopic excision of the ACUM was performed.

Results

Both of the patients were discharged on the postoperative first day and symptom-free from the first period after operation. Histopathological examination confirmed the diagnosis. Second patient conceived a year after the surgery and on the 39th week of pregnancy delivered a baby by c-section.

Conclusions

Laparoscopic excision of the ACUMs was successful and completely resolved the dysmenorrhea and chronic pelvic pain.

<https://player.vimeo.com/video/710549783?autoplay=1>

Techniques for safe laparoscopic hysterectomy for large cervical fibroid

Mihai Gherghe¹, Naomi Griffiths¹, Mohamed Allam¹

¹University Hospital Wishaw, Gynaecology, Glasgow, United Kingdom

Background

Describe techniques used to aid safe laparoscopic hysterectomy for large cervical fibroid

Methods

Presentation of a video from Total Laparoscopic Hysterectomy with Bilateral Salpingo-oophorectomy for a 51-year-old female with an 8.8 x 9.6 x 8.8 cm benign cervical leiomyoma causing heavy menstrual bleeding. Techniques described 1) Ureteric catheterisation 2) Dissection techniques 3) Opening of the vagina. Ureteric catheterisation was carried out by the operating gynaecologist with an operative cystoscope using standard urological techniques. This aided easy identification of the ureters throughout their course, reducing the requirement for extensive pelvic sidewall dissection in anatomy with expected distortion secondary to fibroid size and position. We suggest this skill can be learned easily by most gynaecological surgeons regularly undertaking complex laparoscopic cases. Dissection techniques aimed to reduce the depth and width of the dissection by keeping close to the specimen whilst exposing key tissue and skeletonising vessels at key pedicles prior to ligation. This minimised blood loss intra-operatively whilst reducing post operative pain and analgesic requirements. The vaginal fornices were identified at their highest point with the aid of an atraumatic probe placed into the vagina at the start of the procedure, allowing opening of the vagina at the highest point possible. This conserves maximal sexual function for the patient as well as easing the approach for laparoscopic suturing of the vault; improving ergonomics and reducing operative time at the end of complex procedures.

Results

The patient made an excellent post-operative recovery and was discharged home at 36hours with no re-presentation

Conclusions

A safe approach with good outcome for this patient. Skills transferrable to other benign laparoscopic surgeries including hysterectomy with previous cervical amputation, myomectomy, multiple fibroid uterus and general dissection of benign pelvic masses.

<https://player.vimeo.com/video/710562739?autoplay=1>

Contained Morcellation of a Leiomyoma

Kunal Rathod¹, Yatin Thakur², Vidya Thakur³, Premila Kollipara¹

¹*Queens Hospital Romford, Gynaecology, London, United Kingdom*

²*Basildon Hospital, Gynaecology, Essex, United Kingdom*

³*Broomfield Hospital, Gynaecology, Essex, United Kingdom*

Background

In the 1990s, power morcellation was introduced to allow laparoscopic removal of myomas (fibroids) and larger uteri. Due to the potential dissemination of tissue extracted during the morcellation process, cases of parasitic fibroid development and the inadvertent spread of previously unrecognised malignancies have been described.

It is important for clinicians to remember that, even when surgery is being contemplated for presumed benign conditions, the exact nature of any specimen removed cannot be confirmed until histopathological examination has been undertaken. This is the case when removing fibroids, where there could be undiagnosed uterine sarcoma or in hysterectomy without fibroids, when there could be undiagnosed cervical, endometrial, fallopian tube or ovarian carcinoma.

Methods

Laparoscopic myomectomy was performed in a 38-year-old patient with sub-fertility due to a very large intramural fibroid. Ultrasound scan and MRI was done prior to the procedure which did not show any suspicious findings. Laparoscopic myomectomy was performed using a standard technique with 4 ports. Size of the intramural fibroid was approximately 10 cm. Morcell bag was used for fibroid containment with mouth end of the bag on left side of the abdomen and tail end inserted at supraumbilical location. After morcellation was completed tail end of the bag was tied and entire bag was removed through 10 mm port on left side of the abdomen. There was no fibroid dissemination in the peritoneal cavity.

Results

In bag morcellation was completed successfully with an overall time of around 30 minutes. A perfect seal was obtained without any gas leakage. Overall surgical time was 150 minutes, and a significant time was saved as there were negligible disseminated fibroid fragments.

Conclusions

The protected manual in-bag morcellation technique represents a time-efficient and feasible alternative, which does not interfere with surgical outcomes in women undergoing laparoscopic myomectomy. Learning curve is minimum for a trained laparoscopic surgeon already performing myomectomy. The patient should be informed of the possible risk of disseminating an occult uterine malignancy by open morcellation, as well as the risk of disseminating benign uterine tissue.

<https://player.vimeo.com/video/710575072?autoplay=1>

Robot-assisted laparoscopic hysterectomy with bulky cervical fibroid extraction

Izabella Dalbuquerque¹, Luisa Martins¹, Mira Zlotnik¹, Mariana Corinti¹, Vanessa Alvarenga¹, Renato Moretti¹

¹Hospital Israelita Albert Einstein, Gynecology, São Paulo, Brazil

Background

The patient was placed in a semi-gynaecological position, arms at her sides and legs 80 degrees abducted in adjustable leggings. Three 8mm robotic portals were placed on the umbilicus and on both flanks. An additional 5 mm port was placed in the right flank for laparoscopic assistance.

Patients or Participants: A 51-year-old woman reports constipation, pelvic pain, and urge incontinence for 1 year, with progressive worsening.

Magnetic resonance imaging of the pelvis showed an enlarged uterus, at the expense of a voluminous mass centered on the uterine cervix, a probable leiomyoma. The lesion measured 11.0 x 9.5 x 10.0 cm and had a compressive effect on the posterior bladder wall.

The purpose of this video is to demonstrate the effectiveness and safety of performing hysterectomy of a large uterus due to bulky cervical leiomyoma using robotic platform

Methods

Robot-assisted total laparoscopic hysterectomy was indicated. In the abdominal inventory, an enlarged uterus with the presence of a voluminous cervical myoma was observed. The procedure was performed safely, with little blood loss, and the uterus was removed by vaginal access, with morcellation by cold blade, protected by a bag.

Results

We obtained a safe and efficient surgical treatment in a hysterectomy of a large uterus with the presence of cervical myoma through robotic surgery.

The patient evolved with complete resolution of symptoms and satisfactory postoperative recovery.

Conclusions

We show with our case report the steps to safely perform robotic hysterectomy of large uterus with bulky cervical fibroids, showing that the robotic platform can be an effective tool when dealing with bulky uterus and fibroids.

<https://player.vimeo.com/video/710581986?autoplay=1>

Laparoscopic Plural Myomectomy

Kunal Rathod¹, Charlotte Austen¹, Riddhi Rathod², Yatin Thakur³, Mahmoud Awaly¹, Premilla Kollipara¹

¹Queens Hospital Romford, Gynaecology, London, United Kingdom

²Queens Hospital Romford, Anaesthesiologist, London, United Kingdom

³Basildon Hospital, Gynaecology, Essex, United Kingdom

Background

Laparoscopic myomectomy for large myomas (≥ 8 cm) is hindered by several factors, such as the increased operative time, the risk of perioperative bleeding, and the risk of conversion to laparotomy. The aim of this video is to show a stepwise approach to perform multiple myomectomy laparoscopically.

Methods

Laparoscopic myomectomy was selected for 33-year-old women with main concerns of primary sub-fertility, heavy menstrual bleeding and pressure symptoms due to large multiple fibroid uterus. Ultrasound scan and MRI was performed prior to the procedure for fibroid mapping. Patients' haemoglobin was optimised, and blood was reserved for her during surgery. Vasopressin was used in a dilution of 20 IU in 100 ml normal saline. Myomectomy was performed using 4 ports. Thunder beat was used as the energy device with a terminal grasper for myoma enucleation.

Results

The myoma was totally enucleated and removed without disturbing her endometrial cavity. The myometrial defect was repaired with a continuous suture using the V-loc suture in a single layer. The entire myoma was removed using a tissue morcellator. The total weight of the myoma removed was 2000g, and the operation lasted for 150 minutes. Her postoperative course was unremarkable, and she was discharged on day 2.

Conclusions

Laparoscopic myomectomy offers many advantages compared with abdominal myomectomy. Although the use of a laparoscopic approach to treat very large myomas is controversial and technically demanding, we successfully performed a laparoscopic myomectomy in a patient with a giant myoma. This case confirms the efficiency, reliability, and safety of a minimally invasive surgical approach to treating a giant uterine myoma. Laparoscopic myomectomy can be performed by experienced surgeons regardless of the size of the myoma.

<https://player.vimeo.com/video/710562668?autoplay=1>

Surgical technique for the laparoscopic removal of ESSURE microinserts

Lina Antoun¹, T Justin Clark¹

¹Birmingham Women's Hospital, Minimal access team- Gynaecology department, Birmingham, United Kingdom

Background

The minimally invasive Essure procedure for hysteroscopic sterilisation was launched in 2002 and has been an ongoing target for litigation. Although efficacious, this device has been scrutinised by the US Food and Drug Administration (FDA) owing to alleged complications. Patients affected by these potential complications are filing lawsuits against Bayer, the manufacturer of Essure. Several techniques for removal of Essure have been documented, including use of hysteroscopy, laparoscopic salpingectomy, and cornuectomy. Our objective is to demonstrate the surgical technique of Essure® device removal by laparoscopic salpingectomy-cornuectomy resection and the utility of intraoperative X-ray to confirm complete removal.

Methods

The patient underwent hysteroscopy to locate the Essure® device in the endometrial cavity, this was followed by bilateral laparoscopic salpingectomy-cornuectomy. The Essure® devices were initially located by palpation and visualisation of the tubes. Bilateral salpingectomy was performed using bipolar and monopolar scissor. Cornuectomy was performed using bipolar coagulation and monopolar scissor. Cornua were sutured using Stratofix 2-0. The specimens were removed in one piece to prevent Essure® device from breaking. An intraoperative X-ray was performed to confirm complete Essure® device removal.

Results

The video demonstrates complete removal of Essure device using the surgical techniques shown in the video

Conclusions

Laparoscopic removal of Essure® device appears to be a safe procedure. Intra-operative X-ray is important to confirm complete removal of Essure.

<https://player.vimeo.com/video/713886068?autoplay=1>

The Laparoscopic Management of a Torted Left Ovary in 22-week pregnant primigravida

Ian Heath¹, Andrew Kent¹, Brendan Gallagher¹, Pavle Dimitrijevic¹

¹Royal Surrey County Hospital, Gynaecology, Guildford, United Kingdom

Background

Ovarian cysts are relatively rare in pregnancy with an incidence of 0.05-1.2% and ovarian cyst accidents are even rarer with an estimated torsion rate of 1:70,000. The risk of torsion increases with cyst size and decreases with advancing gestation. Specific complications in pregnancy include fetal loss and prematurity.

Laparoscopy is considered a safe option, compared to open surgery and is associated with equal or better maternal and similar fetal outcomes in adnexal surgery when performed by an experienced laparoscopic surgeon. There are many important considerations in planning laparoscopic surgery in pregnancy including anaesthetic effects on maternal and fetal physiology. All stages of a laparoscopic procedure in pregnancy need to be considered including patient positioning, intra-abdominal pressure, and primary and secondary port placement, size of ports, procedure type, energy use, port closure and post-operative care.

The Royal College of Obstetricians and Gynaecologists (RCOG) and The British Society for Gynaecological Endoscopy (BSGE) produced a joint guideline in 2019 for the management of non-obstetric, abdominal conditions in pregnancy: Laparoscopy in Pregnancy, demonstrating its safety and evidence.

Methods

We would like to demonstrate how we managed a 33-year-old primigravida who presented with acute and severe left iliac fossa pain at 22 weeks gestation with a known 4cm dermoid cyst and suspected torsion. The on-call team initially considered a left para-median incision before requesting our input. We used the direct entry approach at Palmer's point and ipsilateral secondary ports.

Results

On laparoscopy, we identified a torted left ovary with a 5cm dermoid cyst. We confirmed a viable ovary after de-torsion and then proceeded to perform an ovarian cystectomy. There was no spillage, and the patient had an unremarkable recovery and was discharged on the same day. The pregnancy is progressing well.

Conclusions

This video demonstrates how we performed a safe laparoscopic procedure at 22 weeks gestation. Laparoscopy in pregnancy is safe in the hands of an experienced laparoscopic surgeon and their advice should be part of the multi-disciplinary team approach to patient care. The joint RCOG/BSGE provides clinical guidance for laparoscopic surgery in pregnancy.

<https://player.vimeo.com/video/714399173?autoplay=1>

Management of recto-vaginal endometriosis in Guildford UK: Disc resection and demonstration of rectal air test

Ian Heath¹, Andrew Kent¹, Timothy Rockall²

¹Royal Surrey County Hospital, Gynaecology, Guildford, United Kingdom

²Royal Surrey County Hospital, General Surgery, Guildford, United Kingdom

Background

Colorectal endometriosis is estimated to occur in 5-12% of women with endometriosis. It is associated with severe and debilitating pelvic pain and reduced quality of life. The surgical management may be complex and associated with both short- and long-term complications.

Various surgical techniques have been described, including rectal shaving, disc excision and segmental resection. There are numerous studies demonstrating the merits of each technique but there is no consensus opinion or guidelines.

Methods

In our tertiary level unit, our approach is that that rectovaginal endometriosis is best managed surgically and we have a well-established pathway for its management. The surgery is performed by long-standing partnership between the gynaecologist and a named colorectal surgeon on a dedicated list. All patients have a known diagnosis of rectovaginal endometriosis from a previous laparoscopy. All patients have been downregulated with GnRH analogues.

The decision between a shave, disc excision and segmental resection is made intra-operatively. We feel this produces the best results in clinical outcomes and is associated with a low rate of complications.

Data from our unit from 450 cases, shows our disc excision rate of approximately 6%. Our risk of colostomy, fistula formation and anastomotic leak are all less than 1%.

Results

We would like to demonstrate an example of a disc resection on a patient presenting with dyspareunia, dyschezia and chronic pelvic pain which caused significant morbidity. The patient had previously undergone a rectal shave but due to persisting symptoms was offered pelvic clearance after 6 months down-regulation. The decision for the disc resection was made intra-operatively. The bowel had been prepared. The resection was straight-forward but after closure a small defect was noted that was re-inforced with an additional suture.

The patient had an uncomplicated recovery and was discharged on day 1. There has been a significant improvement in quality of life at the 3-month review and she is now completely asymptomatic.

Conclusions

We strongly feel that a 2-stage procedure with interim downregulation in severe recto-vaginal endometriosis in a collaborative partnership with our colorectal surgical colleagues produces the best results. Our unit has very low rates of colostomy and bowel complications. The decision on its management is made intra-operatively and we do not rely on pre-operative imaging.

<https://player.vimeo.com/video/714401200?autoplay=1>

Hysteroscopy after uterine artery embolisation: The endometrial-myoma fistula

Nick Galazis¹, Alexandros Lazaridis², Tom Setchell¹, Tariq Miskry¹

¹*Imperial College Healthcare NHS Trust, Obstetrics and Gynaecology, London, United Kingdom*

²*Oxford University Hospitals, Obstetrics and Gynaecology, Oxford, United Kingdom*

Background

Endometrial-myoma fistula (EMF) is a rare entity which has scarcely been reported in the literature. It occurs secondary to treatment or intervention such as uterine artery embolisation (UAE). Patients with EMF may be asymptomatic or report persistent vaginal discharge and/or spotting, months after UAE.

We present a case of 44-year-old patient with a history of UAE a year ago for symptomatic uterine fibroids. She reports persistent menorrhagia and was counselled for further options including medical management, hysterectomy or hysteroscopic endometrial resection (TCRE), with the patient opting for the latter.

Methods

Endometrial cavity was entered with a resectoscope, and a bar electrode was used for endometrial resection. EAF was identified and fistula cavity was explored. There were no obvious signs of fibroid necrosis and the embolisation beads/microspheres were clearly seen.

The remaining endometrial surfaces was resected to good effect avoiding the endocervical canal as they may cause cervical stenosis and haematometra. Because of the defect in the endometrial cavity owing to the EMF, levonorgestrel intrauterine system (LG-IUS) was not sited.

Results

The patient was reviewed three months later and reported light periods only with no vaginal discharge.

Conclusions

EMF is a rare condition and may occur after UAE. This video demonstrates the characteristic features of this entity. TCRE can still be effective in managing persistent menorrhagia however insertion of LG-IUS should be avoided as it may cause myometrial infiltration or intra-abdominal migration

<https://player.vimeo.com/video/714721654?autoplay=1>

Laparoscopic washout of tubo-ovarian abscess and bilateral adnexectomy

Nick Galazis¹, Alexandros Lazaridis², Tariq Miskry¹, Tom Setchell¹

¹*Imperial College Healthcare NHS Trust, Obstetrics and Gynaecology, London, United Kingdom*

²*Oxford University Hospitals, Obstetrics and Gynaecology, Oxford, United Kingdom*

Background

Tubo-ovarian abscess (TOA) is an uncommon diagnosis which can lead to significant morbidity and even mortality. Standard treatment includes broad-spectrum intravenous antibiotics and if that fails, percutaneous or laparoscopic drainage.

We present a case of laparoscopic drainage of TOA with lateral adnexectomy in a 54-year-old woman. The patient had a recent history of lymphoma and was undergoing chemotherapy. She reported postmenopausal bleeding which prompted hysteroscopy and biopsy. Five days following that, she was admitted with abdominal pain and fevers. Transvaginal ultrasound and computed tomography showed bilateral TOAs. Following days of intravenous antibiotics and microbiology assessments, her clinical picture was deteriorating so a decision was made to proceed with laparoscopy.

Methods

Laparoscopy demonstrated a congested pelvis with widespread inflammatory exudate and adhesions which were divided using blunt and sharp techniques. Moreover, copious irrigation and drainage of pus was performed as well as bilateral adnexectomy. A drain was placed at the end.

Results

The patient had a significant improvement in her symptoms and was discharged 3 days later. Laparoscopy offers several advantages to patients compared to laparotomy including shorter recovery times and reduced post-operative wound infections.

Conclusions

Laparoscopic management of TOA is necessary and effective when conservative measures have failed. The aim of the surgeon should be to restore the anatomy safely, perform copious irrigation and drainage and, when possible, eliminate the cause such as performing an adnexectomy.

<https://player.vimeo.com/video/714726564?autoplay=1>

Laparoscopy for uterine perforation: A step-by-step approach

Nick Galazis¹, Alexandros Lazaridis², Tom Setchell³, Tariq Miskry³

¹*Imperial College NHS Healthcare Trust, Obstetrics and Gynaecology, London, United Kingdom*

²*Oxford University Hospitals, Obstetrics and Gynaecology, Oxford, United Kingdom*

³*Imperial College Healthcare NHS Trust, Obstetrics and Gynaecology, London, United Kingdom*

Background

A 43-year-old woman attended for hysteroscopic endometrial resection (TCRE) for persistent menorrhagia. Examination under anaesthesia showed a retroverted uterus and the cervical canal was dilated to size 10 Hagar. At the time of TCRE, it was noted that uterine cavity distension was not maintained despite adjustments of the inflow and outflow cannulae.

At the end of the three-litre saline bag, it was noted that there was already a positive balance of 2.5L. This raised the suspicion of uterine perforation which was confirmed at the level of the endocervical canal anteriorly. Due to the significant fluid deficit and the use of bipolar energy, the decision was made to perform a laparoscopy.

Methods

The abdomen appeared distended owing to the large amount of intra-abdominal fluid. Veress needle entry demonstrated high intra-abdominal pressures so open entry (Hasson) technique was used.

The following operative steps were performed:

1. Drainage of the fluid at various points such as the pouch of Douglas and the Morrison's space.
2. Assessing the pelvic side walls for vascular or ureteric injury
3. "Walking" the bowel to identify any injury, starting from the ileo-caecal junction to the stomach
4. Intracorporeal haemostatic suturing to the uterine defect and ensuring haemostasis

Results

The patient was debriefed and discharged the next day without any concerns

Conclusions

Uterine perforation is a recognised complication during hysteroscopic surgery. Laparoscopy should always be performed in cases where energy was used. A systematic approach is essential identify any visceral injury which can be repaired at the same time.

<https://player.vimeo.com/video/714729511?autoplay=1>

ES31-0418 - VP056

Dermoid cysts- What to do when things go wrong!

Shaun McGowan¹, Andrew Kent²

¹Belfast City Hospital, Gynaecology, Belfast, United Kingdom

²Royal Surrey County Hospital, Gynaecology, Guildford, United Kingdom

Background

This case was presented as a video presentation at the British society of gynaecological endoscopy annual scientific meeting 2021.

The video shows the laparoscopic management of a large right sided ovarian dermoid cyst.

Methods

Taking into account the patient's request for a fertility sparing procedure an initial attempt was made at ovarian cystectomy progressing to laparoscopic right salpingo-oophorectomy.

Results

We demonstrate the various techniques at managing a large dermoid including laparoscopic ovarian cystectomy, the management of small leaks from a dermoid and the identification of dermoid fusion to the ovary precluding further cystectomy. We finally present the resulting oophorectomy with the harmonic ultrasonic scalpel and management of dermoid spill within the abdomen.

Conclusions

This video highlights laparoscopic management of dermoid cysts and what to do when things do not go to plan.

<https://player.vimeo.com/video/714729469?autoplay=1>

Unusual Presentation of Rectovaginal Septum Endometriosis: Cystic Endometrioma

Patrick Bellelis¹, Daniel Bier Caraça², Victor Sergio Stockler Brusca³, Mariana Corinti²

¹University of Sao Paulo, Endometriosis Division, Sao Paulo, Brazil

²Hospital Israelita Albert Einstein, Laparoscopic Division, Sao Paulo, Brazil

³Santa Casa de São Paulo, General Surgery, Sao Paulo, Brazil

Background

We present the case of a 39-year-old woman diagnosed with endometriosis in 2016. At the time, diagnosis was due to anal pain during menstrual period, however, we do not have access to old imaging exams.

Since then, symptoms diminished using continuous dienogest, and she had been amenorrhea for 4 years.

In physical examination she had a painful bulging retrocervical nodule occupying the posterior vaginal fornix up to 4 cm to vaginal introitus.

Transvaginal sonography with bowel preparation shows normal uterus and adnexa, an endometriotic nodule in rectosigmoid measuring 4.3cm, at 10cm from anal verge affecting 20% of its circumference. Also, a cystic endometrioma in rectovaginal septum measuring 6.3 x 4.7 x 4.5 cm.

Methods

In February 2021, the patient was scheduled for a laparoscopic surgery to treat deep endometriosis. We performed the exeresis of a 6 cm cystic endometrioma of rectovaginal septum, rectosigmoidectomy with end-to-end anastomosis at 2 cm from anal verge and protective loop ileostomy, colporrhaphy and exeresis of peritoneal endometriosis.

Results

Surgery duration time was 3h30min, estimated blood loss was about 50 ml. The patient was discharged in the second postoperative day. And the final pathological report confirmed endometriosis of all specimens.

Conclusions

Endometriosis of the rectovaginal septum is quite rare. Due to the distal topography, a precise imaging report is necessary. Once the anastomosis was at 2 cm from anal verge and we opened the vagina, we opted for the protective loop ileostomy to reduce the anastomotic leak rates.

<https://player.vimeo.com/video/714759902?autoplay=1>

The evaluation of pelvic floor nerves is still a diagnostic challenge by image exams

Patrick Bellelis¹, Victor Sergio Stockler Bruscin², Mariana Corinti³

¹University of Sao Paulo, Endometriosis Division, Sao Paulo, Brazil

²Santa Casa Hospital of Sao Paulo, General Surgeon Division, Sao Paulo, Brazil

³Hospital Israelita Albert Einstein, Laparoscopic Division, Sao Paulo, Brazil

Background

We describe a case of a 40 years-old woman referred to our centre complaining of dyspareunia, chronic pelvic pain and dyschezia. The patient had no relevant past medical. The pre-operative investigation involved a transvaginal ultrasound with bowel preparation that showed a 4cm endometrioma at the left ovary, a 1,2cm retrocervical lesion, a retossigmoid plaque with 0.9cm of diameter and 16cm from de anal verge and kissing ovaries. The patient was in clinical treatment with LNG-IUS, without response. We scheduled a surgical procedure for radical eradication of the deep infiltrating endometriosis.

Methods

A step-by-step surgical video, demonstrating a systematic approach in case of deep infiltrating endometriosis, indicating surgical landmarks and a proper technique. It emphasizes mainly the development of the avascular spaces, isolation of the ureteral course, identification of the parametrial ligaments, preservation of the cranial, middle and caudal parts of the hypogastric plexus. Besides, during the surgical approach, we discovered that the retro and paracervical nodule were deeper than expect and reached the pudendal nerve.

Results

The main indication for surgical treatment in women with endometriosis is pain and impairment in quality of life and the radical eradication of deep endometriosis is related not only with the relieve of symptoms, but also with the minimization of recurrences. The nerve-sparing technique is considered a feasible, safety and reliability approach and clearly is associated with lower post-operative complication rate and better results in terms of debilitating impairments in neurological functions.

Conclusions

The evaluation of pelvic floor nerves is still a diagnostic challenge by image exams. Whenever there is suspicion of nervous involvement, the ideal is to perform two complementary imaging methods: magnetic resonance imaging and ultrasound with bowel preparation.

A highly skilled surgeon who has extensive knowledge of the superficial and deep anatomy of the pelvis is required.

<https://player.vimeo.com/video/714793328?autoplay=1>

Resection of Villar's nodule with vNotes-assistance

Kei Kato¹, Masaaki Andou¹, Tomonori Hada¹, Tadayoshi Kunitomo², Masako Omori²

¹Kurashiki Medical Center, Department of Obstetrics and Gynecology, Kurashiki, Japan

²Kurashiki Medical Center, Departments of Pathology, Kurashiki, Japan

Background

Umbilical endometriosis, described as "Villar's nodule", is the most common site of cutaneous endometriosis. It is rare, occurring between 0.5-1.2% of all cases of endometriosis. Some cases are treated by laparoscopically assisted omphalectomy as a way of detecting eventual pelvic endometriosis. We present a case of umbilical endometriosis treated with vNOTES-assisted surgery. This report was approved by the institutional review board, and written informed consent was obtained from the patient.

Methods

A 46-year-old woman (Gravida2, Para2) without history of abdominal surgery complained of cyclic umbilical swelling and pain during her menstrual cycle. Additionally, the patient suffered from dysmenorrhea and hypermenorrhea, and was referred to our hospital. MRI scan showed a 13×12×18mm nodule at the umbilicus suggesting endometriosis and a uterus with a submucosal fibroid, but no clear indication of pelvic endometriosis. As the patient didn't opt for conservative therapy including GnRH-analogues and progestins, surgery was performed. Hysterectomy and salpingectomy were performed by vNOTES and the umbilical peritoneum was observed through the transvaginal scope. Visual findings were not significantly different from a normal peritoneum free of endometriosis. We resected umbilical lesions transabdominally and reconstructed the umbilicus. Just before closing the vaginal cuff, we observed the abdominal wall to confirm the integrity of the resection.

Results

Pathology revealed endometrial tissue in the umbilical specimens. Superficial dehiscence of the umbilicus occurred as a postoperative complication but was treated conservatively within a few weeks of surgery. Over the three-month observation period, the patient's umbilical endometriosis symptoms improved without recurrence.

Conclusions

To our knowledge, this is the first reported case vNOTES-assisted surgery for umbilical endometriosis. Our vNOTES technique has the potential to lead to a safer minimally invasive excision of umbilical endometriosis.

<https://player.vimeo.com/video/714870063?autoplay=1>

Combined Hysteroscopic retrieval & Laparoscopic cornuectomy as a technique for removal of Essure micro inserts: A case report.

Pooja Mathur¹, Timothy Kundodyiwa¹, Claire Stewart¹

¹St Helen's and Knowsley NHS trust, Obstetrics and Gynecology, Liverpool, United Kingdom

Background

Essure is a permanent method of hysteroscopic sterilization, aiming at inflammatory tubal occlusion, which was introduced internationally in 2001. Although it has good rates of successful sterilisation, it has emerged with increased reports of adverse effects and many patients are hence requesting for removal of device. The knowledge of safe surgical practices in Essure™ removal is therefore gaining importance in modern gynaecological practice. These can include hysteroscopic removal, laparoscopic salpingectomy, combined hystero-lap approach with bilateral salpingectomy & cornuectomy and laparoscopic hysterectomy. “En-bloc” resection precludes any residual fragments being left behind in the uterine cornua necessitating future surgery. Some Essure™ components are radiolucent and will not be visible on a standard radiograph or fluoroscopy, so an awareness of imaging limitations is important. Many of such patients are young and uterus preserving options should be considered in such cases. The authors wish to demonstrate one such uterus preserving technique in an improperly placed Essure™ device.

Methods

Authors present a successful technique of combined hysteroscopy - laparoscopic approach for removal of Essure™ microinserts in a symptomatic 28-year-old patient who had Essure™ devices for 5 years. After failed conservative approach to resolve her symptoms of increased heavy painful menstrual periods and severe dyspareunia with use of Mirena IUS, Mefenamic acid and Tranexamic acid.

Results

A combined approach of diagnostic hysteroscopy with laparoscopic bilateral cornuectomy & salpingectomy with hysteroscopic retrieval of intrauterine Essure™ microinserts fragments was performed. Hysteroscopy allowed exact localization of any broken fragments preventing the need for reoperation and eventually hysterectomy. The patient's symptoms completely resolved after the procedure and continues to be well and was discharged from follow up.

Conclusions

Essure device removal is a safe minimally invasive option for patients where other organic causes of symptoms have been ruled out. Combined hysteroscopy and laparoscopic approach prevent the theoretical concern of incomplete removal of the clip or proximal portion that may result with a cut and pull approach

<https://player.vimeo.com/video/714897540?autoplay=1>

A case of laparoscopic myomectomy of a large interstitial fibroid

Mohamed Elsherbiny¹, Zahid Khan²

¹Advance Laparoscopy trainee ST7 -Health Education England NWHEE, Gynaecology - Manchester Foundation Trust, Manchester, United Kingdom

²Manchester Foundation Trust, Gynaecology, Manchester, United Kingdom

Background

24 year old female who was presented with Heavy menstrual bleeding (HMB), dysmenorrhea and pelvic pain.

Abdominal examination showed enlarged uterus equivalent to 20 weeks gestation size.

MRI 2019 showed a large 10-12 cm myoma compressing the cavity. No suspicious features in the MRI.

Listed for Laparoscopic Myomectomy and surgery was done at the end of 2021 due to covid 19 pandemic delay.

Methods

1-Ports configuration

2-Energy devices/ instruments used

3-Technique of dissection.

4-Suturing techniques

5-Morcellation

Results

Total blood loss 250 ml.

Patient had made smooth postoperative recovery with no early or delayed complication

Discharged home the next day.

Conclusions

Laparoscopic myomectomy needs advanced laparoscopic skills.

Laparoscopic myomectomy has several advantages including shorter recovery and less intra-abdominal adhesions

<https://player.vimeo.com/video/714990261?autoplay=1>

Vaginally assisted laparoscopic radical hysterectomy: A surgical technique in which the tumor was closed vaginally without the use of uterine manipulator

Nasuh Utku Doğan¹, Selen Dogan¹, Mert Cenker Guney¹, Burcu Yagmur¹, Mustafa Ozer¹

¹Akdeniz University, Gynecology, Antalya, Turkey

Background

The results of LACC study showed that over-all and disease-free survival is worse in women undergoing laparoscopic radical hysterectomy when compared to open surgery. Moreover, risk of recurrence and death follow the same tendency in favour of open surgery. However, in retrospective series published from referral centres in which no manipulator was used, and the tumour was closed vaginally in the beginning of the- surgery, survival and recurrence rates were comparable to open surgical arm of LACC study.

Methods

In this video, a woman diagnosed with cervical cancer undergoing vaginally assisted laparoscopic radical hysterectomy and pelvic lymphadenectomy was presented

Results

To note, the dimension of the tumour was 25 mm which was confirmed with LEEP before the surgery. We did not use any vaginal manipulator or any vaginal manipulation of the tumour. Moreover, the tumour was closed by forming vaginal manchette, in the beginning of the surgery. The total operation time was 270 minutes with 30 cc of blood loss. The Patient was discharged on the third day of operation without any problems.

Conclusions

Vaginally assisted laparoscopic radical hysterectomy without the use of uterine manipulator eliminates the risks associated with tumour spillage without worsening the oncological outcomes. There are a couple of RCT on the way with the use of same technique. With these surgical modifications, the risks associated with tumour spillage will high probably be prevented.

<https://player.vimeo.com/video/715225020?autoplay=1>

Management of unrecognized full-thickness bladder perforation in a case of megacystis in the course laparoscopic hysterectomy performed for a huge myoma

Nasuh Utku Doğan¹, Selen Dogan¹, Gizem Seckin¹, Unzule Korkmaz¹, Hasan Dogukan Copur¹
¹Akdeniz University, Gynecology, Antalya, Turkey

Background

Chronic compression of a huge myoma on to the bladder could cause chronic globe vesicale which could be thought to be a pelvic mass. If a surgery is planned, the location and orientation of the bladder should be evaluated before the surgery

Methods

Video presentation.

Results

A 51 year old woman referred to our unit with complaints of heavy menstrual bleeding and pelvic mass. The pelvic mass was revealed to be globe vesicale associated with compression of a huge myoma. On transvaginal ultrasound, there were multiple myomas, the biggest being 9 cm in diameter. A laparoscopic hysterectomy was planned. During the surgery, after the introduction of suprapubic trocars, a suspicious peritoneal fold was detected on the anterior abdominal wall. On the course of the surgery, the size of this peritoneal fold was increased, which then realized to be megacystis despite the presence of bladder catheter. The suprapubic trocar transversed the full length of the bladder which was confirmed with intraoperative cystoscopy. The trocar was deplaced and a cysto-fix was replaced under the direct visualisation of cystoscopy. We continued and completed the hysterectomy without any further problems and sutured the perforation site of the bladder laparoscopically. Total operation time was 160 minutes with a 30-cc blood loss. We discharged the patient on the second day of surgery kept the cysto-fix for seven days.

Conclusions

Chronic compression of a myoma to surrounding visceral organs could cause globe vesicale or other obstruction problems. If a surgery is planned in such a case, the location and orientation of the bladder should be evaluated before the surgery.

<https://player.vimeo.com/video/715237473?autoplay=1>

Vaginal assisted laparoscopic radical hysterectomy + upper 2/3 vaginectomy and pelvic lymphadenectomy for vaginal cancer

Nasuh Utku Doğan¹, Selen Dogan¹, Saniye Merve Gul¹, Aytac Mehdiyeva¹, Omer Tolga Guler²

¹*Akdeniz University, Gynecology, Antalya, Turkey*

²*Pamukkale University, Gynecology, Denizli, Turkey*

Background

Vaginal cancer is the rarest genital cancer. The treatment is the surgery for small volumed, early-stage tumours.

Methods

Video presentation

Results

A 59-year-old woman with complaints of postmenopausal bleeding referred to our unit. The biopsy taken from 3 cm lesion on the upper anterior vaginal wall revealed to be vaginal adenocarcinoma. The cervical and endometrial evaluation and biopsies were all normal. In PET-CT scan, apart from primary tumour, there was no significant finding. Laparoscopic radical hysterectomy along with upper 2/3 vaginectomy and pelvic lymphadenectomy was performed. We did not use any uterine manipulator or manipulation on any stage of the surgery. In the final stage of the surgery, the vaginal route was used. With colpotomy performed vaginally, surgical specimen was extracted through vagina. We did not perform any colpotomy laparoscopically. Total operation time was 270 minutes with a 30-cc blood loss. The patient was discharged on the third post-operative day without any per-op complication.

Conclusions

Laparoscopic approach is a feasible way to resect early-stage vaginal cancer.

<https://player.vimeo.com/video/715259209?autoplay=1>

Laparoscopic management of a big intraligamentary uterine mass with uterine smooth muscle tumor of uncertain malignant potential (STUMP): A surgical case report.

Jesus Molero^{1,2}, Ester Martínez Lamela^{1,3}, Yolanda Expósito Lucena⁴, Marta Heras García^{1,5}

¹*Hospital Ntra Sra del Rosario, Oncologic Gynaecology, Madrid, Spain*

²*Toco-Gyn Gynecologic Clinic, Oncologic Gynaecology, Alcalá de Henares, Spain*

³*Infanta Leonor University Hospital, Gynecology and Obstetrics, Madrid, Spain*

⁴*Toco-Gyn Gynecologic Clinic, Gynecology and Obstetrics, Alcalá de Henares, Spain*

⁵*Santa Cristina University Hospital, Gynecology and Obstetrics, Madrid, Spain*

Background

Uterine smooth muscle tumours of uncertain malignant potential (STUMPs) is a heterogeneous group of tumours with histological and biological diversity that cannot be defined as a benign leiomyoma or malignant leiomyosarcoma. In terms of preoperative radiologic imaging and laboratory tests, it is difficult to distinguish between these tumours prior to pathological confirmation at surgery. The conventional surgical management of STUMP includes hysterectomy or myomectomy in limited cases may be considered in women who wish to preserve fertility.

Methods

We present the laparoscopic approach in a case of a 41-year-old nullipara woman who complained of heavy menstrual bleeding and severe pressure symptoms in the lower abdomen for 6 months. Physical examination revealed a solid pelvic mass of approximately 9 cm in the right parauterine area; was hard and generally round with limited mobility. Transvaginal ultrasound confirmed an 89 × 70 × 64 mm cm heterogenous mass with increased vascularity on colour Doppler. The magnetic resonance imaging (MRI) of the pelvis confirmed a large right parauterine pedunculated subserosal fibroid with cystic degeneration. Tumoral haemorrhage and necrosis were not determined. Both ovaries were normal and there was no associated lymphadenopathy or ascites. The appearance was suggestive to represent an atypical pediculated uterine myoma. Her body mass index was 17.65 kg/m². Her baseline blood tests were normal. The level of CA-125 was 37.4 U/ml, CEA was 1,2 U/ml and that of CA 19–9 was 13 U/ml. After discussing the various treatment options, the patient consented to multiple myomectomies by laparoscopy.

In video format, the complex surgical technique is shown with the dissection of the pelvic avascular spaces, the adhesiolysis of the right ureter and removal of the surgical specimens with bag protected extraction.

Results

Surgical time was 100 minutes, and the blood loss was 804,23 ml. The patient was normally discharged 2 days after surgery. No complications were reported.

The uterine mass measured 8.5 × 7 × 5 cm and weighed 141,6 g. Pathological analysis revealed a STUMP according to the following 2014 WHO criteria: (1) tumour cell necrosis (TCN), no atypia, and a mitotic index <10 mitoses per 10 high-power fields (HPFs); (2) moderate-to-severe atypia, no TCN, and a mitotic index <10 mitoses per 10 HPFs; and (3) no TCN, no atypia, and a mitotic index >15 mitoses per 10 HPFs. The other tumours were typical leiomyomas.

Conclusions

It is important to consider the possibility of an underlying malignancy and to perform frozen biopsy and protected surgery. During follow-up, patients should undergo consultation and should be surveilled closely because of the possibility of recurrence or metastasis (7.3%–26.7%).

<https://player.vimeo.com/video/715267809?autoplay=1>

Adnexal torsion of ovarian cyst: Laparoscopic approach in the emergency service

Inês Gouveia¹, Marta Xavier¹, Ana Mações¹, Evelin Pinto¹

¹Centro Hospitalar de Vila Nova de Gaia e Espinho/EPE, Gynecology and Obstetrics, Vila Nova de Gaia, Portugal

Background

A 40-year-old woman presented in the emergency service with 3-day history of diffuse abdominal pain in the inferior left quadrant. On clinical examination she revealed pain on palpation of the left iliac region.

Abdominal and transvaginal ultrasound scan confirmed the presence of a left sided mass measuring 8,5 x 6 x 5cm with 2 cystic structures: one unilocular with 5 x 2 cm and the other with characteristics of a dermoid cyst with 4 x 3 cm. There was presence of whirlpool sign in the left adnexal area, suggestive of adnexal torsion.

Given the clinic and ultrasound findings, the team decided in favour of a diagnostic laparoscopy to exclude torsion of the ovarian pedicle.

Methods

A closed entry with Veress needle was performed at the umbilical level, followed by umbilical trocar insertion. A 30-degree scope was introduced, and lateral ports were placed under vision. Visualisation of the abdominal cavity confirmed the left ovarian cyst with 8 cm. The left tube had signs of oedema and low-grade ischemia and a two-loops torsion of the infundibulopelvic (IP) ligament was confirmed. The right ovary and other pelvic and abdominal organs were normal.

We decided to do a left adnexectomy given the age of the patient, characteristics of the cyst such as complexity and size. We started by performing an abdominal cavity wash for cytological analysis, followed by correction of the torsion and reposition of normal anatomy. Traction of the ovary through the tubal surface was followed by coagulation and section of the IP ligament and broad ligament partially. Coagulation and section of the proper ligament of the ovary and mesosalpinx. Removal of the cyst without spillage in endoscopic bag.

Results

Overall, this was an uncomplicated procedure and post operative recovery was uneventful. The patient was discharged in day one post operatively. The histopathological analysis revealed a dermoid cyst with no malignancy.

Conclusions

Our experience shows that diagnostic laparoscopic surgery in cases of torsion can have greater benefits than risks in the resolution of this emergency diagnostic, providing also in this case the resolution and study of the ovarian mass.

<https://player.vimeo.com/video/715298652?autoplay=1>

Migration of intrauterine device: case report

Beatriz Kehde¹, Heitor Andrade Pinheiro¹

¹*Unifesp, Gynecology and Obstetrics, São Paulo, Brazil*

Background

Intrauterine devices (IUDs) are globally one of the most popular methods of contraception. The ultrasonography, mainly the three-dimensional US, is also beneficial for determining if the IUD is entirely within the endometrial cavity.[1] If the IUD is not seen by ultrasound, refer to recommendations that prescribe a computed tomography (CT) or magnetic resonance imaging (MRI) scan. [2]

Methods

It is a case report from a hospital in São Paulo, Brazil. The patient authorized the exposure of her case, having signed the free and informed commitment term, respecting the privacy of her identification.

Results

CMO, female, 51 years old, is admitted in the emergency room due to abdominal pain for 2 days. In the gynaecological history, the patient had two pregnancies, both caesarean, and she was using a hormonal IUD for contraception for 2 years. Routine examination 8 months ago showed on ultrasound that the IUD was well positioned. Abdominal CT performed on admission showed an IUD in the abdominal cavity. The patient underwent a video laparoscopy to remove the IUD. She evolved well in the postoperative period and was discharged after 24 hours of hospitalization.

Conclusions

The IUD migration is very rare with an incidence of 0.12-0.68/1000 insertions and usually takes place years after IUD insertion. Esposito et al. suggest that uterine perforation might be caused by immediate traumatic perforation and late "secondary" perforation by gradual erosion through the myometrium. Physiological events, such as spontaneous uterine contraction, bowel peristalsis, and bladder contraction, might result in uterine perforation. Post-partum, hypoestrogenism occurs, causing uterine atrophy and thinning of the uterine walls, thereby increasing the risk of uterine perforation. The soft consistency of the uterus in breast feeding women is also a risk factor for uterine perforation.

Possible sites of IUD migration are to the bladder (intravesical), peritoneum, omentum, rectosigmoid, appendix, small bowel, colon, adnexa and iliac vein. The symptoms vary according to the affected structure. Rare complications include IUD appendicitis, gangrene of the small intestine and ureterohydronephrosis due to retroperitoneal fibrosis caused by the migration of an IUD through the peritoneum.

In the present case, the main symptom was the pain, without migration to other organs.

The World Health Organization (WHO) recommends that an IUD displaced from the uterine cavity should be removed as soon as possible after diagnosis, regardless of its type and location, even in asymptomatic patients. What occurred in this case report.

As for the placement of a new IUD, there are studies that show a 30% chance of recurrence. Given this possibility, the patient chose to use condoms until menopause, since it is close.

As conclusion, IUD migration is rare, but when it occurs, removal of the IUD is recommended as soon as diagnosed.

<https://player.vimeo.com/video/715343450?autoplay=1>

vNOTES hysterectomy for adnexial mass and endometriosis of the posterior compartment of the pelvis

Jesus Molero^{1,2}, Ester Martínez Lamela^{1,3}, Yolanda Expósito Lucena⁴, Marta Heras García^{1,5}

¹*Hospital Ntra Sra del Rosario, Oncologic Gynaecology, Madrid, Spain*

²*Toco-Gyn Gyneacologic Clinic, Oncologic Gynaecology, Alcalá de Henares, Spain*

³*Infanta Leonor University Hospital, Gynecology and Obstetrics, Madrid, Spain*

⁴*Toco-Gyn Gyneacologic Clinic, Gynecology and Obstetrics, Alcalá de Henares, Spain*

⁵*Santa Cristina University Hospital, Gynecology and Obstetrics, Madrid, Spain*

Background

Vaginal Natural Orifice Transluminal Endoscopic Surgery (vNOTES) is a minimally invasive surgical technique that uses the vagina to get access to the abdominal cavity. This technique is being performed in the Rosario's Hospital in Madrid (Spain) since October 2021. The aim is to present, in our short experience in performing vNOTES, a case with previous diagnosis of pediculated leiomyoma and history of surgery for endometriosis 20 years ago, with final unsuspected diagnosis.

Methods

13 vNOTES hysterectomies were performed for benign indications. The mean age was 51.9 years (range 42-63 years) and mean surgical time was 89.6 minutes (SD 29.5 minutes) and the mean blood loss was 719.5 mL (SD 242.5 mL). No conversions have been performed.

The video shows a difficult surgical case of a 64-year-old woman who complained of abnormal uterine bleeding and pressure symptoms in the lower abdomen for 6 months. Hysteroscopy and endometrial biopsy were performed with benign results. Physical examination revealed a solid pelvic mass of approximately 5 cm in the right side; was hard and generally round with limited mobility. Transvaginal ultrasound confirmed a heterogenous mass with low increased vascularity on colour Doppler, suggestive of the pediculated myoma. Size 53 x 28 mm. The magnetic resonance imaging (MRI) of the pelvis confirmed a mass suggestive of pedunculated fibroid with cystic degeneration (size 60 x 40 x 33 mm). Tumoral hemorrhage and necrosis were not determined. Both ovaries were not visualized. There was no associated lymphadenopathy or ascites. Her body mass index was 26.22 kg/m². The level of CA-125 was 5 U/ml, CEA was 2.13 U/ml and that of CA 19-9 was 17 U/ml. After discussing the various treatment options, the patient consented to hysterectomy and residual adnexectomy by single port laparoscopy (vNOTES) for relative anaesthetic contraindication.

Results

In video format, the complex surgical technique is shown with the adhesiolysis of the complete posterior pelvic compartment, between posterior side of the uterus and the rectum. Surgical time was 90 minutes, and the blood loss was 804,23 ml. The patient was normally discharged 2 days after surgery. No complications were reported.

Pathological analysis revealed an ovarian high grade serous carcinoma of 5.5 cm of maximum diameter, on endometriosis, with ovarian surface involvement. Stage pTNM 8th edition 2017, (FIGO): at least pT1c2 Nx Mx, (IC2). No disease spreading on CT. The subsequent staging surgery in two weeks, peritoneal washings, infrarenal paraaortic and pelvic lymphadenectomy, omentectomy, appendicectomy and peritoneal biopsies were performed. Final stage: pT1c2 N0 (0/56) M0, (IC2). Complete cytoreduction (residual tumor = 0).

Conclusions

vNOTES hysterectomy is a safe and feasible option but it is important to consider the possibility of an underlying malignancy and to perform surgeries with oncologic protection.

<https://player.vimeo.com/video/715363208?autoplay=1>

Video presentation of the use of indocyanine green for intraoperative recognition and localization of ureter in laparoscopic surgery

Sofia Tsiapakidou¹, Stergios Tzitzimikas², Themistoklis Mikos¹, Grigoris Grimbizis¹

¹1st Department of Obstetrics and Gynecology Aristotle University of Thessaloniki, General Hospital Papageorgiou, Thessaloniki, Greece

²Genesis, Private Clinic, Thessaloniki, Greece

Background

The presentation of an Innovative technique for intraoperative imaging of the ureters using indocyanine green (ICG) and the endoscopic imaging equipment RUBINA CARL STORZ in laparoscopic surgeries in the context of training video projection.

Methods

Pilot application of a new technique in a case series. Admission criteria: preoperative diagnosis of gynaecological malignancy and any precancerous condition. Exclusion criteria: (a) history of prior abdominal surgery or surgery for malignancy, (b) extension of malignancy in the urinary tract. Informed consent was obtained from all patients. Technique: Before creating a pneumoperitoneum, we use a rigid 19F cystoscope 70°, and a Nelaton 6F neonatal feeding catheter, to inject ICG through the ureteric orifices into the ureter lumen bilaterally.

Results

The technique was applied to 3 women. Successful fluorescence imaging of the ureters was achieved in all cases with the use of fluoride and NIR (Near Infra Red) endoscopic equipment during the operations. Fluorescent imaging of the bladder was also observed, offering additional protection against possible intraoperative damage or injury of the lower urinary tract during laparoscopic surgery. No complications were observed during the dye injection or postoperatively.

Conclusions

This proposed new ureter intraoperatively imaging technique described seems to be an easy-to-learn method, real-time, low cost, minimal additional surgical time, effective and safe for patients. It avoids possible injuries from the use of intraurethral catheters or problems from their "splinting" when they are selected. Future larger studies are needed to study the ideal dosage and dilution of ICG.

<https://player.vimeo.com/video/715367312?autoplay=1>

Case Presentation of Mullerian Duct Anomaly: Safety Comes First!

Mohamed Nasr¹, Emer O'Donnell¹, Johnson Amu¹

¹Blackpool Teaching Hospital NHS Foundation Trust, Obstetrics & Gynaecology, Blackpool, United Kingdom

Background

Congenital uterine anomalies are deviations from normal anatomy resulting from embryological maldevelopment of the Mullerian ducts. The presentation will vary from incidental findings to amenorrhea, subfertility, and miscarriage. Magnetic resonance imaging (MRI) is the most accurate technique for evaluation of congenital uterine anomalies. Associated renal abnormalities are reported in up to 40% of women and these include renal agenesis, ectopic kidney, horseshoe kidney and ectopic ureter.

Methods

We present a case study of a 50-year-old patient who was scheduled for total laparoscopic hysterectomy and bilateral salpingo-oophorectomy (TLH+ BSO) for incompletely excised CIN III. Initial Preoperative MRI report suggested a normal size uterus with solitary left kidney however findings intraoperatively showed distorted pelvic anatomy as shown in the video presentation.

Results

The intraoperative video demonstrates an unexpected unusual pelvic anatomy with difficult visualisation of left ureter. There was a small posterior uterine perforation with Hegar dilator; this was recognised and cauterised. It was unsafe to proceed with hysterectomy therefore procedure was abandoned. Additional history obtained from patient suggested that she had 'half uterus' from laparoscopy performed 3 decades ago in another unit. A second review of MRI scan, post operatively, confirmed a left hemi pelvic unicornuate uterus and left solitary kidney.

Further counselling has been arranged with patient to discuss management options. This includes a joint operation by gynaecology and urology teams to perform TLH+BSO, ureteric stenting and cystoscopy. Ureteric injury rates at laparoscopic gynaecological surgery estimated at 1 - 2% but only 30% will be recognised intraoperatively. Ureteric stenting or transillumination using ureteroscopy would be useful to minimize the chances of such injuries.

Alternatively, a conservative management as preferred by patient would involve further colposcopy surveillance of disease progression and/or repeat loop excision of cervical abnormality.

Conclusions

This case demonstrates the importance of safe surgical practice and patient influenced care. This is dependent on detailed patient history and adequate counselling with relevant information, correctly reported imaging modalities, sound knowledge of pelvic anatomy, limitations of surgical expertise, effective collaboration with allied specialist to reduce untoward patient outcome and potential for litigation.

<https://player.vimeo.com/video/715384652?autoplay=1>

Eight Tubo-Ovarian Abscesses in seven minutes

Alvaro Bedoya-Ronga¹

¹*Birmingham City Hospital, O&G, Birmingham, United Kingdom*

Background

Severe pelvic abscess can be very challenging. There is no absolute guideline of how to manage them. It is generally accepted that small collections can be managed conservatively, while large collections require drainage. Usually, radiological drainage is preferred to surgical as it has lower morbidity. The surgical approach to these cases is infrequent and always stressful due to the complexity and potential complications. The limited frequency limits the development of expertise in managing them and also in finding surgical patterns as what technique might be better.

Methods

Single surgeon, 3 years videos and case notes review to find patterns and outcomes.

Results

A total of eight tubo-ovarian abscesses requiring surgical drainage were found. All of them had emergency surgery after other management methods have been exhausted and the patients were not improving on intravenous antibiotics.

None of our patients tested positive for sexually transmitted infection. Four out of the eight ladies had Copper Coil as adjuvant to ascending infection (associated with endometrioma in 1 case). Infected endometriomas were present in two cases (Cu Coil, and Post Hysteroscopy). One lady had septic ectopic pregnancy, other lady had acute on chronic pelvic infection, and one patient had no risk factors.

No serious complication occurred as result of the laparoscopic drainage.

Two patients returned to theatre, one due to re-collection and in the other no cause was found.

At 3 to 6 months follow up, there was recurrence of pain with collection in one lady.

Conclusions

A systematic approach to this surgery could be summarised as

- Profuse washing to soften fibrin adhesions.
- Profuse washing for hydro-dissection and developing planes.
- Blunt dissection with careful bowel guarding.
- Follow anatomical landmarks.
 - Round ligament.
 - Tube.
 - Contour of the uterus.
 - Pelvic side wall.
- Use traction and counter traction to detach adherent structures.
- Cauterise and cut after the anatomy has become recognisable and its safe.
- Remove as much tissue as possible providing its safe
- Live drain well secured
- Give follow up for patient's reassurance but also to witness evolution of the case.

<https://player.vimeo.com/video/715431842?autoplay=1>

Large endometrioma: What does the evidence for fertility say?

Abhijeet Shah¹, Abdelmohsen Ahmed Mohamed¹, Vinu Krishna Das², Robyn Patrick³, Khairunnisa Syeda¹, Gaurab Gurung¹

¹East Kent Hospitals NHS Trust, Gynaecology, Ashford, United Kingdom

²Dartford General Hospital, Obstetrics & Gynaecology, Dartford, United Kingdom

³Maidstone & Tunbridge Wells NHS Trust, Obstetrics & Gynaecology, Tunbridge Wells, United Kingdom

Background

21-year nulliparous woman is referred by the fertility specialists for surgical excision of endometrioma. She has been trying to conceive for the last 2 years.

Methods

MRI confirms large endometrioma measuring 14 cm in the right and normal left ovary. Discussion about medical or surgical management was discussed and she opted for laparoscopy as was also suffering with pelvic pain and fertility clinic was not progressing with IVF due to endometrioma.

Results

Laparoscopic excision of large 12-14 cm endometrioma on right was completed in full. Left ovary was normal and both tubes normal. She made uneventful recovery and was discharged same day.

Conclusions

The right ovary developed 10 follicles reaching 16-20 mm and left ovary developed 6 follicles measuring 18-20 mm.

She further went on to have a successful IVF and delivered a healthy baby boy through a planned caesarean section.

<https://player.vimeo.com/video/715476591?autoplay=1>

Endometrial polyp resection with bipolar resectoscope – an easy way to prevent recurrence and to extract specimens for analysis

Inês Gouveia¹, Marta Campos¹, Andrea Quintas¹

¹Centro Hospitalar de Vila Nova de Gaia e Espinho/EPE, Gynecology and Obstetrics, Vila Nova de Gaia, Portugal

Background

This is a case report of a 32-year-old woman, G2 P1 (1 eutocic delivery, 1 miscarriage), referred to consultation for complaints of abnormal uterine bleeding (abundant menses and intermenstrual bleeding) and dysmenorrhea, with 1 year of evolution. This patient had not completed her reproductive plan. A transvaginal sonography revealed a FIGO type 3 fibrome of 22x19x17mm in the antero-fundic myometrial wall and presence of an endometrial polyp localized in the anterior wall with 15x12 mm of dimension. The patient was booked for an hysteroscopic resection of the endometrial lesions under general anaesthesia.

Methods

We present a stepwise resection technique of an endometrial polyp with narrated video footage.

The endometrial cavity was entered directly with a resectoscope, and careful inspection revealed the area of contact of a type 3 fibrome in the right anterior wall and a large polyp with a broad pedicle on the left antero-fundic wall.

A 5mm bipolar loop electrode at 100W for cutting was used to resect the lesions. Adequate visual field was achieved by removing the lesions' chips at intervals and adjusting the outflow function.

The lesions were resected completely and sent to histopathology. Coagulation at 50W was performed to ensure haemostasis. The fluid deficit was 300ml positive balance.

Results

The patient was fit for discharge the same day. Histopathology confirmed fragments of polyp and myometrial tissue with no malignancy. The patient mentioned resolution of the symptoms in the first consultation after surgery.

Conclusions

The gold standard is endoscopic resection under general anaesthesia in large formations like these, especially if the patient is symptomatic and the intent is therapeutic. We believe that resectoscopic resection facilitates the complete resolution of the lesions, reduces relapses and formation of new polypoid lesions in the site of resection and finally, facilitates complete extraction of the specimens for histopathological examination.

<https://player.vimeo.com/video/715521977?autoplay=1>

Transvaginal ultrasound appearance of complicated and uncomplicated intestinal diverticula.

Mariateresa Mirandola^{1,1}, Cristina Chiamenti¹, Federica Pozzati¹, Cristiana Paniga¹, Antonia Carla Testa¹, Giovanni Scambia¹

¹IRCCS Fondazione Policlinico Universitario A. Gemelli- Università Cattolica del Sacro Cuore, Department of Woman and Child Health and Public Health, Rome, Italy

Background

Diverticula are a frequent pelvic ultrasonographic finding over the gynaecological pelvic examination. When complicated, they present with pelvic pain the patient can be referred to the specialist to investigate other causes of gynaecological pelvic pain. The aim of this video is to describe the transvaginal features of intestinal diverticula and to highlight the gynaecological interest in the pathology when evaluating different causes of pelvic pain.

Methods

We present a case of a patient affected by diverticulitis referred to our gynaecological department because of pelvic pain and a suspicion of adnexal pathology. Ultrasound appearance and subsequent intraoperative findings are described.

Results

A 63-year-old woman likely to have an inflammatory adnexal pathology was referred to our department. Ultrasound examination revealed a saccular paraovarian lesion, with anechoic content and incomplete septa, not vascularized at colour-Doppler and extensive adhesions with a sigmoid loop. The sigmoid walls were thickened with anechoic rounded areas within the muscular layer. The patient underwent surgery with hysterectomy, bilateral adnexectomy and rectal-sigma resection because of pelvic abscess. Final histology was positive for large intestine diverticulitis with associated abscess.

Conclusions

The thickening of sigmoid wall detected at ultrasound in patient affected by diverticula can mimic other conditions of severe adhesion such as posterior compartment endometriosis and the clinical presentation with pelvic pain can lead to misdiagnosis with pelvic inflammatory disease: the knowledge of diverticula's transvaginal ultrasonographic feature is of gynaecological interest, especially when in differential diagnosis with other causes of pelvic pain.

<https://player.vimeo.com/video/715553992?autoplay=1>

A medically unfit women with early-stage endometrial cancer treated with levonorgestrel releasing intrauterine system (LNG-IUS): a new endoscopic positioning technique

Ilaria Romito¹, Alessia Romito², Giorgia Garganese^{1,3}, Francesco Fanfani³, Giovanni Scambia³, Ursula Catena³

¹Mater Olbia Hospital, Gynecology and Breast Care Center, Olbia, Italy

²Policlinico Universitario Umberto I, Maternal-Child and Urological Sciences Department, Roma, Italy

³Fondazione Policlinico Universitario Agostino Gemelli- IRCCS. Catholic University of Sacred Heart, Division of Gynaecological Oncology. Department Woman and Child Health and Public Health, Roma, Italy

Background

Endometrioid adenocarcinoma of the endometrium is directly associated with an oestrogen-related pathway. One of the main risk factors is obesity. Excess of oestrogens, not antagonized by progesterone, can lead to pre-malignant endometrial disease and to endometrial cancer. In early stages endometrioid adenocarcinoma, the management is surgical (total hysterectomy, bilateral salpingo-oophorectomy, with lymph nodes assessment), but patients with high body mass index often are unsuitable for it. Radiotherapy or hormone therapy are options in these patients' category.

Methods

We present a case of a new total endoscopic LNG-IUS positioning technique, in an obese patient with early stage endometrioid adenocarcinoma, whose multiple co-morbidities made the standard surgical management too risky to undertake.

Results

An 82-year-old woman with morbid obesity (BMI, 48.9 Kg/m²) was referred to our gynaecological department for abnormal uterine bleeding. Computed tomography showed endometrial thickening confined to the uterus; neither pelvic or para-aortic lymph adenomegaly, nor ascites was observed. Patient underwent office hysteroscopy with multiple endometrial biopsies with 5 Fr grasping forceps. Final diagnosis was endometrioid adenocarcinoma, Grade 1, Stage FIGO 1A.

Patient was assessed by experienced anesthesiologists and scheduled as "high-risk patient" according to Boyd and Jackson definition and assigned to American Society of Anaesthesiologists (ASA) class III. Due to the characteristics of the patient (long and tight vaginal canal, small cervix), probably due to her two previous caesarean sections, she received megestrol acetate 160 mg given orally daily, because of the impossibility to position a LNG-IUS inside the uterine cavity. She underwent office hysteroscopy with endometrial biopsies every three months. After one-year, endometrial biopsy confirmed a stable disease.

Patient was scheduled for an office hysteroscopy with an expert surgeon to position a LNG-IUS inside the uterine cavity. A 5 mm hysteroscope, 36 cm in length, with a 30° forward oblique lens (Karl Storz, Tuttlingen, Germany) was used for the procedure, with 5 Fr grasping forceps. The hysteroscopic examination showed focal endometrial thickening with atypical vascularization. The surgeon introduced a 5Fr grasping forceps into the working channel of the hysteroscope to grab the LNG-IUS arms and push it into the uterine cavity vaginoscopically toward the vagina and the cervix, without using vaginal valves or Schroeder tenaculum to grasp the cervix.

Conclusions

Total endoscopic LNG-IUS positioning technique avoids using vaginal valves and to grasp the cervix with a Schroeder tenaculum. This technique allows positioning LNG-IUS also in very difficult cases in which the only way to approach the cervix is vaginoscopically and permits to have a pain free procedure in these very fragile patients.

<https://player.vimeo.com/video/715541294?autoplay=1>

What if I suspect a carcinosarcoma? Recognize it, see it, treat it.

Mariateresa Miranda¹, Irene Ladisa¹, Cristina Paniga¹, Antonia Carla Testa¹, Giovanni Scambia¹, Ursula Catena¹

¹IRCCS Fondazione Policlinico Universitario A. Gemelli- Università Cattolica del Sacro Cuore, Department of Woman and Child Health and Public Health, Rome, Italy

Background

Uterine carcinosarcoma is a rare type of endometrial cancer that account for 5% of all uterine malignancies. It is a biphasic epithelial-stromal neoplasm characterized by high-grade carcinomatous component and sarcomatous component. Diagnosis can be suspected by an accurate preoperative management and an adequate sampling is necessary in order to achieve an accurate histological diagnosis. Complete surgical staging is mandatory in case of carcinosarcoma diagnosis. The aim of this video is to show how an accurate preoperative assessment in suspected uterine carcinosarcoma may lead to adequate surgical management.

Methods

We present a case of an accurate preoperative management through pelvic ultrasound and office hysteroscopy in a patient diagnosed with uterine carcinosarcoma underwent subsequently a complete surgical demolition.

Results

A 70-year-old patient was referred to our clinic because of vaginal bleeding. Preoperative transvaginal ultrasound suspected a malignant endocavitary lesion with stromal component. Patient underwent office hysteroscopy with pouch biopsy. Histology showed endometrial carcinoma, but the amount of tissue was not sufficient for a correct histotype diagnosis. Patient underwent a second office procedure with an expert hysteroscopic surgeon who performed the procedure by using a Tissue Removal Device (TRD), collecting a larger amount of tissue and reaching the correct histological diagnosis (uterine carcinosarcoma). Patient underwent complete surgical debulking and staging, including omentectomy. Final histology confirmed the hysteroscopic histology and final FIGO stage of disease was IVB because of positive omentum.

Conclusions

The recognition of the lesion by an expert ultrasonographer and the achievement of an office histological diagnosis led to an accurate preoperative assessment allowing a tailored surgical management for uterine carcinosarcomas.

<https://player.vimeo.com/video/715585750?autoplay=1>

Tips and tricks for challenging cases of laparoscopic multiple myomectomy

Charles Gerard¹, Stavros Karampelas¹, Deliar Yazdanian Masouleh¹, Evy Gillet¹, Sara Engels¹

¹CHU Brugmann, Gynecology, Laeken, Belgium

Background

About one-third of women with fibroids present with symptoms severe enough to warrant treatment. We demonstrate a case of a 37-year-old woman with complaints of primary infertility and menorrhagia. On examination the uterus was enlarged up to 24 weeks size. A complementary Magnetic Resonance was performed in order to have a precise mapping of the myomas. The MRI mapped 3 large myomas: a fibroma of 110x80 mm, classified as International Federation of Gynecology and Obstetrics class II-V, a second fibroma of 70x80 mm classified as FIGO class V and a third pediculated fibroma of 70x30 mm FIGO class VII.

A total laparoscopic approach in case of multiple big myomas is challenging but offers benefits if performed following safe steps.

Methods

We present a stepwise demonstration of the laparoscopic technique with narrated video footage.

The following were the key steps of surgery: (1) Higher optical port position (2) temporary clipping of the uterine artery (3) use of 7 mm forceps tenaculum in order to manipulate the myoma (4) multiple layer suturing leaving no dead spaces (5) ureteral dissection in case of retroperitoneal myoma and (6) in-bag power morcellation using a 2-port bag to prevent any intra-abdominal dissemination.

Results

A laparoscopic multiple myomectomy was performed, no complications occurred. A total blood loss was estimated at 200 mL. The patient was discharged 48 hours after surgery.

Conclusions

A total laparoscopic multiple myomectomy is feasible and safe if some key steps are performed, as temporary clipping of the uterine arteries, and in bag morcellation to prevent dissemination in the abdominal cavity.

<https://player.vimeo.com/video/715615119?autoplay=1>

Multi-joint articulating laparoscopic instruments in gynecologic surgery

Joseph Noh¹, Jungeun Jeon¹, Tae-Joong Kim¹

¹Samsung Medical Center, Obstetrics and Gynecology, Seoul, Korea- Republic Of

Background

Minimally invasive surgery has gained popularity in the field of gynaecologic surgery since the late 1980s and early 1990s. Major advancements in laparoscopic instruments such as the development of robotic surgical system and energy devices have allowed gynaecologic surgeons to perform procedures more efficiently and safely. In the present video, we illustrate total laparoscopic hysterectomy performed with a multi-joint articulating laparoscopic instrument and an advanced energy device.

Methods

A 66-year-old woman with FIGO stage IB_r of grade 1 endometrioid adenocarcinoma was scheduled for total laparoscopic hysterectomy, bilateral salpingo-oophorectomy, and bilateral pelvic sentinel lymph node biopsy. The tumour size was 4 cm in preoperative magnetic resonance imaging (MRI). She did not have underlying comorbidities except for well-controlled diabetes.

Results

Bilateral pelvic lymph node biopsy was performed prior to the initiation of hysterectomy. A multi-joint articulating laparoscopic fenestrated grasper and an advanced energy device were used. The articulating instrument held the tissue at an appropriate angle with sufficient grasping power. It allowed the surgeon to approach the contralateral side of the uterus without struggles. The total operative time for hysterectomy and bilateral salpingo-oophorectomy was 60 minutes. The estimated blood loss was minimal, and the patient was discharged on the second postoperative day without any immediate complications.

Conclusions

Total laparoscopic hysterectomy by a multi-joint articulating instrument and an advanced energy device is feasible. This new type of instrument may provide extended dexterity during surgical procedures in the field of gynaecology.

<https://player.vimeo.com/video/715636449?autoplay=1>

Laparoscopic excision of sciatic nerve schwannoma

Dimitrios Zygouris¹, Sofia Papadimitriou², Evgenia Stergiannakou¹, Andreas Kavallaris¹

¹St. Luke's hospital- Thessaloniki- Greece, Department of minimally invasive Gynecology-, Thessaloniki, Greece

²University Hospital of Ioannina- Ioannina- Greece., Department of Blood Transfusion, Ioannina, Greece

Background

Sciatic nerve schwannoma is a rare entity. It should always be considered as a possible cause of sciatica in patients that present with symptoms of sciatica with no prolapsed disc in the lumbar spine and a negative crossed straight leg raise test.

Methods

We present the case of a 24-year-old patient diagnosed with a tumour on the left parametrium and pain in the Gynecological examination. There was no intraoperative or postoperative complication

Results

The patient had foot drop symptom (superficial fibular nerve) postoperatively, but after a 3-week physiotherapy the majority of the symptoms were gone.

Conclusions

Laparoscopic treatment is useful and feasible in case of retroperitoneal pelvic schwannoma, with minimal tissue damage and fast post-operative recovery. Thus, this procedure may be the first-choice surgical procedure for retroperitoneal pelvic schwannomas.

<https://player.vimeo.com/video/717584597?autoplay=1>

Atypical location of the sentinel lymph node in a patient with low-grade endometrial cancer

Margarida Cal¹, Rita Torres², Adelaide Vitorino², Luís Vieira Pinto², Henrique Nabais²

¹Hospital de Santa Maria- Centro Hospitalar Universitário Lisboa Norte, Obstetrics- Gynaecology and Reproductive Medicine, Lisbon, Portugal

²Champalimaud Clinical Center, Gynecology Unit, Lisbon, Portugal

Background

We aimed to present a case of an atypical, asymmetrical sentinel lymph node (SLN) location in a patient who underwent a robotic surgery for a low-grade endometrioid endometrial cancer.

Methods

We present a stepwise demonstration of the robotic sentinel lymph node dissection with narrated video footage.

Results

This video reports a case of an intraoperative SLN dissection, performed in a patient with low-grade endometrioid endometrial cancer. The patient presented with complaints of post-menopausal abnormal uterine bleeding and imaging studies showed a thickened endometrial lining. A hysteroscopy-guided biopsy confirmed the diagnosis of low-grade endometrioid endometrial. The patient was proposed to surgery, with bilateral SLN biopsy followed by hysterectomy and bilateral salpingo-oophorectomy by robotic surgery.

Interventions: A robotic surgery was performed; key steps from the surgery were:

1. Cervical injection of indocyanine green (ICG);
2. Identification and biopsy of the left SLN in an external iliac location;
3. The right SLN was not identified neither in external iliac nor in obturator location; therefore, atypical locations were searched and the right SLN was identified in the common iliac location and biopsied;
4. After SLN biopsies, hysterectomy and bilateral salpingo-oophorectomy were performed. There were no complications both during the surgery of in the post-operative period.

Conclusions

Sentinel pathways tend to be symmetrical in the majority of patients, although in about one quarter of all cases they may be asymmetrical. The vast majority of SLNs are mapped to the medial external iliac or obturator locations; however, about 5-10% of patients have SLNs mapped in other locations, which would not be sampled with standard pelvic lymphadenectomy, as in this case. A thorough exploration of these atypical locations or ICG reinjection enables the identification of SLN, thus avoiding the performance of standard pelvic lymphadenectomy.

<https://player.vimeo.com/video/715728828?autoplay=1>

Systematic Management of Rectovaginal Endometriosis in 4 Steps

Gonzalo Mezquita¹, Fevzi Shakir²

¹Hospital Universitario Ramon y Cajal, Gynecology, Madrid, Spain

²Royal Free Hospital, Gynecology, Londres, United Kingdom

Background

To demonstrate the systematic management of rectovaginal endometriosis in 4 steps, including mobilisation of the sigmoid and rectum, bilateral ureterolysis and finally excision of endometriosis.

Methods

Tertiary referral center referral for management of endometriosis due to extent of disease.

Results

After systematic dissection and preoperative insertion of ureteric stents, all endometriosis was excised. Dissection using traction/counter traction with an ultrasonic device facilitates the removal of disease in a safe multi-disciplinary approach. Anatomical locations of structures and dissections are demonstrated. The endometriosis was completely excised, from the side walls and rectum, with bilateral ureterolysis. This safe and systematic excision decreases morbidity.

Conclusions

Safe systematic multi-disciplinary approach to complex endometriosis is the most appropriate strategy for management. We demonstrate safe dissection techniques as well as anatomical landmarks that can be adopted for management of such cases, as a learning and teaching tool.

<https://player.vimeo.com/video/715730078?autoplay=1>

Complete CO₂-laser vaporisation of an endometriotic cyst: a surgical video.

Celine Bafort¹, Christel Meuleman¹, Carla Tomassetti¹

¹*UZ Leuven, Obstetrics and Gynaecology/Leuven University Fertility Center, Leuven, Belgium*

Background

To present the technique of a complete CO₂-laser vaporisation of an endometriotic cyst in a patient with pain and active childwish reluctant for assisted reproductive treatment.

Methods

This is an edited video of a laparoscopic procedure performed at a tertiary referral centre for endometriosis. We present the case of a 42-year-old woman with dysmenorrhea and childwish since 6 months. Transvaginal ultrasound showed a partial obliteration of the pouch of Douglas, an endometrioma on the left ovary of 54x56x48 mm as well a nodule on the left uterosacral ligament.

Results

Intraoperatively endometriosis rASRM stage-III and #ENZIAN P2O2/0T0+0+A0B1/0C0F/ was found. Excision of the endometriotic lesions was done using the CO₂-laser (Lumenis) . For the endometrioma we decided to perform a complete CO₂-laser vaporisation of the cyst wall following those ten different steps:

1. Drainage of the endometriotic cyst at the lowest point
2. Rinsing and aspiration of cyst content
3. Releasing the ovary from the ovarian fossa by traction and use of the CO₂-laser
4. Deperitonealisation of the ovarian fossa
5. Biopsy of the endometriotic cyst wall
6. Turning the cyst wall inside-out & inspection of the inner wall of the cyst
7. Complete CO₂-laser vaporisation of the cyst wall (Surgitouch modus – 30W CW)
8. CO₂-laser vaporisation of the superficial lesions on the ovary
9. Folding back the ovary
10. Excision of all other endometriotic lesions was performed as well during the procedure

Postoperative course was uneventfull, endometriosis fertility index 5/10.

Conclusions

Step-by-step demonstration of the technique of endometrioma CO₂-laser vaporisation, which can be considered as an alternative to cystectomy in women wishing to preserve their reproductive potential.

<https://player.vimeo.com/video/715750681?autoplay=1>

Cystoscopy-assisted laparoscopic partial cystectomy for bladder endometriosis

Luís Ferreira de Castro¹, Ana Andrade¹, Carlos Ferreira², Rosa Macedo¹, Hélder Ferreira¹

¹*Centro Hospitalar Universitário do Porto, Gynecology, Porto, Portugal*

²*Centro Hospitalar Universitário do Porto, Urology, Porto, Portugal*

Background

Bladder endometriosis is defined as an endometriotic lesion that infiltrates the detrusor muscle. Partial cystectomy allows the complete resection of the nodule which is crucial in endometriosis management. A simultaneous laparoscopy and cystoscopy may be considered for the treatment of this disease.

Methods

In this video we demonstrate step by step the combination of a cystoscopy and a laparoscopic partial cystectomy for the complete removal of a bladder endometriotic nodule.

Results

We present the case of a 39-year-old nulliparous woman with severe dysmenorrhea, deep dyspareunia and catamenial dysuria and hematuria. Gynaecological examination revealed a painful indurated area in the anterior cul-de-sac. Magnetic resonance imaging showed a transmural nodule in the bladder dome measuring 2,5 cm, suggestive of endometriosis implant.

In the cystoscopy evaluation, we observed a group of red and white nodular lesions with bluish areas, representative of endometriosis. We also reported that the lesion was distant from the ureters. However, we decided to place bilaterally double-J ureteral stents to avoid direct ureteral injury. At laparoscopy we visualized the vesicouterine space obliterated, the round ligaments being pulled to the pelvic midline, both ovaries adhered to the uterine walls and adhesions between the sigmoid colon and left pelvic wall. Both paravesical spaces were carefully dissected. Dissection continued over the obliterated vesicouterine space until the uterus isthmus was separated from the bladder. An extensive fibrotic lesion was excised from the bladder wall and then, a partial cystectomy with a monopolar hook was performed for complete resection of the transmural nodule. The bladder was reapproximated in two layers with continuous absorbable sutures.

Conclusions

This video presented the feasibility of intraoperative combination of laparoscopy and cystoscopy for the management of bladder endometriosis. Cystoscopy allow the direct identification of the lesion which supports the complete resection of the disease by laparoscopy, avoiding unnecessary excision of the normal bladder wall.

<https://player.vimeo.com/video/715668739?autoplay=1>

Surgical management of a complex tubal ectopic pregnancy. Case report and video demonstration with discussion.

Alexandros Lazaridis¹, Nicolas Galazis², Ahmad El-Zibdeh¹, Kirana Arambage¹

¹Oxford University Hospitals, Gynaecology, Oxford, United Kingdom

²St. Marys Hospital- Imperial College NHS Trust, Gynaecology, London, United Kingdom

Background

A 37yo lady (BMI 42 kg/m²) presented to the emergency gynaecology department with left sided pelvic pain and nausea. She had a positive pregnancy test and was on her second pregnancy. She previously had an emergency caesarean section for presumed fetal distress that was complicated by small bowel injury requiring small bowel resection and end-to-end anastomosis. On her background she had two previous open myomectomies where multiple fibroids (sizes 5-10cm) were removed, first by a Pfannenstiel and then by a midline incision.

Methods

The Palmers point was utilized for laparoscopic entry with a 5mm optic trocar. Immediately upon entry the omentum was densely and extensively plastered over the subumbilical anterior wall, extending towards the uterine fundus.

The gravid uterus was also plastered to the anterior abdominal wall, with only a small portion of the fundus visible. The uterovesical fold was completely obliterated. There were extensive left side wall adhesions involving the left ovary and rectosigmoid. The left adnexal anatomy was distorted, and the left tube was passing underneath and medially to the ovarian ligament.

After careful dissection the tube was eventually visualized. The tube appeared distended with blood (hematosalpinx) and a possible ampullary ectopic pregnancy. There was evidence of moderate volume of blood (haemoperitoneum) in the Pouch of Douglas.

Results

The surgical team in a methodological approach restored pelvic and adnexal anatomy prior to undertaking surgical treatment of the ectopic pregnancy with salpingectomy. This step is crucial in ensuring that all reference structures are clearly identified (round ligament, ovarian ligament and tube) such that the correct structure is ligated without compromising further patients' pelvic anatomy and function.

Conclusions

This interesting case highlights the surgical challenges of complex tubal ectopic pregnancies in the presence of a hostile adhesions-laden surgical field.

As an endoscopic gynaecology society, we need to disseminate learning points from such cases and further clinical skills and experience that will improve patient care.

<https://player.vimeo.com/video/715773792?autoplay=1>

Surgical technique for the laparoscopic removal of ESSURE microinserts

Lina Antoun¹, T Justin Clark¹

¹Birmingham Women's Hospital, Minimal access team- Gynaecology department, Birmingham, United Kingdom

Background

The minimally invasive Essure procedure for hysteroscopic sterilisation was launched in 2002 and has been an ongoing target for litigation. Although efficacious, this device has been scrutinised by the US Food and Drug Administration (FDA) owing to alleged complications. Patients affected by these potential complications are filing lawsuits against Bayer, the manufacturer of Essure. Several techniques for removal of Essure have been documented, including use of hysteroscopy, laparoscopic salpingectomy, and cornuectomy. Our objective is to demonstrate the surgical technique of Essure® device removal by laparoscopic salpingectomy-cornuectomy resection and the utility of intraoperative X-ray to confirm complete removal.

Methods

The patient underwent hysteroscopy to locate the Essure® device in the endometrial cavity, this was followed by bilateral laparoscopic salpingectomy-cornuectomy. The Essure® devices were initially located by palpation and visualisation of the tubes. Bilateral salpingectomy was performed using bipolar and monopolar scissor. Cornuectomy was performed using bipolar coagulation and monopolar scissor. Cornua were sutured using Stratofix 2-0. The specimens were removed in one piece to prevent Essure® device from breaking. An intraoperative X-ray was performed to confirm complete Essure® device removal.

Results

The video demonstrates complete removal of Essure device using the surgical techniques shown in the video

Conclusions

Laparoscopic removal of Essure® device appears to be a safe procedure. Intra-operative X-ray is important to confirm complete removal of Essure.

<https://player.vimeo.com/video/715777595?autoplay=1>

Natural Orifice Transluminal Endoscopic Surgery (NOTES) - Applications in Gynaecology

Ana Rosa Andrade¹, Hélder Ferreira², Luís Castro², Rosa Macedo²

¹*Centro Materno-Infantil do Norte, Departamento da Mulher e da Medicina Reprodutiva, Porto, Portugal*

²*CMIN, Ginecologia, Porto, Portugal*

Background

Transvaginal Natural Orifice Transluminal Endoscopic Surgery (NOTES) yields access to the abdominal cavity without any incisions on the abdominal wall (scarless surgery). With this new technique the natural orifices of the body surface, such as the mouth and the vagina, serve as the gateway to the peritoneal cavity. Recently, the clinical application of transvaginal NOTES has broadened significantly in Gynaecology.

The goal of this video is to demonstrate the feasibility of the new NOTES technique in Gynaecology, which can be used for hysterectomy and salpingo-oophorectomy in patients with uterine and adnexal pathology.

Methods

.

Results

A 61-year-old woman (grávida 1 para 1) was referred to our clinic with left-sided abdominal pain and a history of a persistent ovarian cyst. The ultrasound revealed a left complex hypoechoic ovarian cyst of 5 cm. Tumour markers were normal, and there was no suspicion of malignancy. The NOTES technique was planned due to the possibility of pelvic adhesions and her concerns about cosmesis. Transvaginal NOTES hysterectomy with bilateral adnexectomy was performed using one grasper and a vessel sealing instrument under the visualization of a 0° scope through an ALEXIS system. The procedure was performed under the Trendelenburg position without any abdominal scar. There were no complications during the procedure or in the post-operative period.

Conclusions

Using transvaginal NOTES by applying the method of single-incision laparoscopic surgery via the vaginal route, adnexal surgery and hysterectomy could be performed safely and effectively in selected patients.

<https://player.vimeo.com/video/720044551?autoplay=1>

Colossal chocolate cyst !!

Kunal Rathod¹, Mandeep Grewal¹, Abrie Botha², Yatin Thakur³, Premila Kollipara¹, Vidya Thakur⁴

¹Queens Hospital Romford, Gynaecology, London, United Kingdom

²Guys and St Thomas' hospital, General Surgery, London, United Kingdom

³Basildon Hospital, Gynaecology, Essex, United Kingdom

⁴Broomfield Hospital, Gynaecology, Essex, United Kingdom

Background

Endometriosis is thought to affect up to 15% of women and can cause dysmenorrhoea, dyspareunia, sub-fertility, and reduced quality of life. There is no difference in incidence rates between ethnic groups.

Ovarian endometrioma are found in up to 44% of women with endometriosis and are significantly associated with the presence of pelvic deep infiltrating endometriosis, ovarian adhesions, and pouch of Douglas obliteration. The recurrence rate can be as high as 50%.

Ovarian cystectomy appears to be superior to ablation in terms of endometrioma recurrence, pain symptoms and increased spontaneous conception rate among sub fertile patients. Surgical excision of endometrioma is preferred over drainage in order to reduce recurrence risk, particularly if the cyst size is greater than 3cm.

Methods

38 years old patient presented with primary sub-fertility, dysmenorrhoea, dyspareunia and chronic pelvic pain. She had laparotomy a year ago for endometriosis and endometrioma. Abdominal examination revealed mass arising from pelvis measuring around 20-week size.

Speculum examination was normal. On vaginal examination a fixed 20-week size uterus was felt. MRI pelvis was performed which showed left ovarian endometrioma-hemosalpinx complex measuring 18 cm and a right ovarian 3 cm endometrioma.

She was seen by a colorectal surgeon in her clinic and a joint procedure was planned to improve her quality of life. Risks and benefits were discussed with the patient including a small risk of reduction in ovarian reserve.

Results

Laparoscopy was performed with 4 ports. Veress needle was used for CO2 insufflation. 10 mm primary port and 10 mm laparoscope was used for the procedure. Veress needle and suction tube was used to drain endometrioma (800 mls). Monopolar scissor with settings of 25w was used for bowel adhesiolysis and restoring anatomy. Left ovarian cystectomy was performed with harmonic scalpel. Ovary was sutured with 2,0 vicryl with minimal use of diathermy to prevent loss of ovarian reserve. Right ovary and tube were released from its dense attachment to right pelvic side wall. Dye test was performed after left side ovarian reconstruction and drainage of right ovarian endometrioma. Dye test showed patent tubes on both the sides. Robinson size 20 was inserted for a day and patient was discharged home the very next day.

Conclusions

Cystectomy of ovarian endometrioma has been the first-line treatment for management for many years because it provides improved pain relief and reduces recurrence rates. Proper surgical planning should be done with thorough history, examination, excellent quality ultrasound or MRI. Substantial number of adhesions especially for recurrent cases should be anticipated. When surgical intervention is appropriate, careful ovarian cyst excision with goal of ovarian tissue preservation and treatment of additional endometriosis by a trained surgeon can provide the patient the best long-term outcome and preservation of ovarian tissue and function.

<https://player.vimeo.com/video/715787828?autoplay=1>

Laparoscopic management of a ruptured spontaneous heterotopic pregnancy in the second trimester

Michail Diakosavvas¹, Nikolaos Kathopoulos¹, Konstantinos Kyriotis¹, Ioannis Chatzipapas¹, Ekaterini Domali¹, Athanasios Protopapas¹

¹National and Kapodistrian University of Athens,

Endoscopic Surgery Unit- 1st Department of Obstetrics & Gynecology- "Alexandra" Hospital, Athens, Greece

Background

The coexistence of an intrauterine and an ectopic gestation, defined as heterotopic pregnancy (HP), is an extremely rare condition in natural conceived pregnancies.

Methods

A G2P1 woman presented to our emergency unit at 10 weeks of a spontaneously conceived pregnancy, for abdominal pain. The transvaginal ultrasound revealed an intrauterine pregnancy, and an 8 cm mass of mixed echogenicity in the left adnexa. Based on the clinical and laboratory findings, she was admitted, with differential diagnosis including pelvic inflammatory disease, ruptured corpus luteum cyst and adnexal torsion. After conservative management with iv antibiotics for two days, the patient's condition was improved and she was discharged on her own will, despite the opposite recommendations of the attending physicians. After 6 weeks, she returned to the clinic, at the gestational age of 16 weeks, due to severe abdominal pain. The sonographic exam depicted an intrauterine pregnancy with hydramnios, along with intraabdominal haemorrhage and hematoma of the left parametrium.

Results

An emergent exploratory laparoscopy was performed. A mild amount of blood clots and a mass in the ampulla of the left fallopian tube were discovered. The findings were consistent with a ruptured tubal ectopic pregnancy; thus, a left salpingectomy was performed. The patient had an uneventful postoperative period and was discharged after 3 days, with an ongoing viable intrauterine pregnancy. The pathologic examination confirmed the suspected diagnosis of HP. The patient delivered at 37 weeks of gestation, via caesarean section, a healthy female new born.

Conclusions

The majority of HP are discovered and treated in the first trimester, while only few cases remain undiagnosed until the second trimester. Regarding the spontaneously conceived HP, to the best of our knowledge, this case is only the second reported spontaneous HP, which was successfully treated laparoscopically in the second trimester, and resulted in the birth of a healthy new born.

<https://player.vimeo.com/video/715672935?autoplay=1>