ISSN (PRINT): 2032-0418 ISSN (ELECTRONIC): 2684-4230

FACTS, VIEWS & VISION in ObGyn

Journal of the European Society for Gynaecological Endoscopy (ESGE)

VOLUME: 18 ISSUE: SUPPL 2 NOVEMBER 2026



www.fvvo.eu

FACTS, VIEWS & VISION
Journal of the European Society for Gynaecological Endoscopy (ESGE)
in ObGyn
VOLUME: 18 | ISSUE: SUPPL 2 | NOVEMBER 2026

EDITORIAL BOARD

Editor-in-Chief

T. Justin Clark, Birmingham, UK

Deputy Editor

Ayesha Mahmud, Stoke, UK

Associate Editors

Arvind Vashisht, London, UK
Baris Ata, Istanbul, Turkey
Bertho Nieboer, Nijmegen, The Netherlands
Cagri Gulumser, Ankara, Turkey
Maria Chiara De Angelis, Naples, Italy
Diego Raimondo, Bologna, Italy
Ertan Sarıdoğan, London, UK
Evrim Erdemoglu, Isparta, Turkey
Francesco Fanfani, Rome, Italy
Gautier Chene, Lyon, France
George Pados, Thessaloniki, Greece
Grigoris Grimbizis, Thessaloniki, Greece
Harald Krentel, Duisburg, Germany
Laurent de Landsheere, Liège, Belgium
Liliana Mereu, Catania, Italy
Maribel Acién, Alicante, Spain
Martin Hirsch, Oxford, United Kingdom
Michelle Nisolle, Liège, Belgium
Mikos Themistokles, Thessaloniki, Greece
Philippe R. Koninckx, Leuven, Belgium
Simone Ferrero, Genova, Italy
Stefania Saponara, Cagliari, Italy
Stephan Gordts, Leuven, Belgium
Tina Tellum, Oslo, Norway
Yavuz Emre Şükür, Ankara, Turkey

Publisher Contact
Address: Molla Gürani Mah. Kaçamak Sk. No: 21/1 34093 İstanbul, Turkey
Phone: +90 (530) 177 30 97 / +90 (539) 307 32 03
E-mail: info@galenos.com.tr/yayin@galenos.com.tr
Web: www.galenos.com.tr
Publisher Certificate Number: 14521

Publication Date: November 2026
ISSN (print): 2032-0418 / **ISSN (electronic):** 2684-4230
International periodical journal published four times a year.

FACTS, VIEWS & VISION
Journal of the European Society for Gynaecological Endoscopy (ESGE)
in ObGyn
VOLUME: 18 | ISSUE: SUPPL 2 | NOVEMBER 2026

EDITORIAL BOARD

ESGE Editorial Board

Arnaud Wattiez, Dubai, UAE
Attilio Di Spiezio Sardo, Naples, Italy
Benoit Rabischong, Clermont, France
Brunella Zizolfi, Naples, Italy
Cagatay Taskiran, Istanbul, Turkey
Carlo De Angelis, Rome, Italy
Caterina Exacoustos, Rome, Italy
Fatih Sendag, İzmir, Turkey
Frank Willem Jansen, Leiden, the Netherlands
Gabriele Centini, Rome, Italy
Gaby Moawad, Washington, United States
George Vilos, London, Ontario, Canada
Hélder Ferreira, Porto, Portugal
Jon Einarsson, Harvard, USA
Jörg Keckstein, Villach, Austria
Joseph Nassif, Houston, United States
Keith Isaacson, Harvard, USA
Limin Feng, Beijing, China
Luis Alonso Pacheco, Malaga, Spain
Mohamed Mabrouk, London, United Kingdom
Peter O'Donovan, Bradford, UK
Philippe R. Koninckx, Leuven, Belgium
Ramon Rovira, Barcelona, Spain
Robert T. O'Shea, Flinders, Australia
Roger Molinas, Asuncion, Paraguay
Rudi Campo, Leuven, Belgium
Rudy Leon De Wilde, Oldenburg, Germany
Saad Amer, Nottingham, UK
Sara Brucker, Tuebingen, Germany
Stefano Bettocchi, Bari, Italy
Sunita Tandulwadkar, Pune, India
Sven Becker, Frankfurt, Germany
Taner Usta, İstanbul, Turkey
Thomas Ignatius Siebert, Cape Town, South Africa
Togas Tulandi, Montreal, Canada
Ursula Catena, Rome, Italy

ESGE Editorial Team

Amy Chan, Birmingham, United Kingdom
Oscar Barnick, London, United Kingdom
Jessica Spalding, Staffordshire, United Kingdom
Prince Osam-Duodu, Staffordshire, United Kingdom

Please refer to the journal's webpage (**https://fvvo.eu/**) for "Journal Policy", "Ethics" and "Instructions to Authors".
The editorial and publication processes of the journal are shaped in accordance with the guidelines of the ICMJE, COPE, WAME, CSE and EASE.
Facts, Views and Vision in ObGyn is indexed in the **PubMed**, **PMC**, **Emerging Sources Citation Index, CNKI, Scopus** and **DOAJ.**
The journal is published online.
Owner: The European Society for Gynaecological Endoscopy
Responsible Manager: T. Justin Clark

REVIEW ARTICLE

DOI: 10.52054/FVVO.2026.261511
Facts Views Vis Obgyn 2026;18(Suppl 2):15-35

Diagnosis and management of adenomyosis and its impact on ART–an international expert consensus from GynFoch 2025

Alexandre Vallée[1], Paul Pirtea[2], Gaby Moawad[3], Maribel Acién[4], Luis Alonso[5], Baris Ata[6], Simona Barbuto[7], Mats Brannstrom[8], Marcello Ceccaroni[9], Attilio Di Spiezio Sardo[10], Caterina Exacoustos[11], Hélder Ferreira[12], Jamal Fikri[13], Stefano Guerriero[14], Grigoris Grimbizis[15], Samir Hamamah[16], Antonis Makrigiannakis[17], Mohamed Mabrouk[18], Michel Mueller[19], Ertan Saridogan[20], Gábor Szabó[21], Linda Tebache[22], Tina Tellum[23], Dirk Timmerman[24], Anis Feki[25], Jean-Marc Ayoubi[2,26]

[1]Department of Epidemiology and Public Health, Foch Hospital, Suresnes, France
[2]Department of Obstetrics, Gynaecology and Reproductive Medicine, Foch Hospital, Suresnes, France
[3]Department of Obstetrics and Gynaecology, The George Washington School of Medicine and Health Sciences, Washington, United States of America
[4]Department of Gynaecology, Miguel Hernandez University of Elche, San Juan Campus, Alicante, Spain
[5]Hospital Universitario Doce de Octubre, Madrid, Spain
[6]Department of Obstetrics and Gynaecology and Assisted Reproduction, Koç University Hospital, Istanbul, Turkey
[7]Medics SRL, Moncalieri, Italy
[8]Department of Obstetrics and Gynaecology, University of Gothenburg, Gothenburg, Sweden
[9]Department of Obstetrics and Gynaecology, Gynaecological Oncology and Minimally Invasive Pelvic Surgery, International School of Surgical Anatomy, IRCCS Ospedale Sacro Cuore, Negrar di Valpolicella, Italy
[10]Department of Neuroscience, Reproductive Sciences and Dentistry, University of Naples Federico II Faculty of Medicine, Naples, Italy
[11]Department of Surgical Sciences, Obstetrics and Gynaecological Unit, University of Rome Tor Vergata, Rome, Italy
[12]Department of Gynaecology and Obstetrics, Centro Materno Infantil do Norte-Unidade Local de Saúde de Santo António (CMIN-ULSSA), Porto, Portugal
[13]Reproductive and Infertility Unit, University of Abulcassis, Morocco
[14]Centro Integrato di Procreazione Medicalmente Assistita (PMA) e Diagnostica Ostetrico-Ginecologica, Azienda Ospedaliero Universitaria Cagliari-Policlinico Duilio Casula, Monserrato, Italy
[15]Department of Obstetrics and Gynaecology, Aristotle University of Thessaloniki, Thessaloniki, Greece
[16]ART/PGD Department, Arnaud de Villeneuve Hospital, University Hospital of Montpellier, Montpellier, France
[17]Department of Obstetrics and Gynaecology, University Hospital of Heraklion, Heraklion, Greece
[18]Department of Fish Production, Faculty of Agriculture in Cairo, Al-Azhar University, Cairo, Egypt
[19]Department of Obstetrics and Gynaecology, University Hospital of Berne and University of Berne, Berne, Switzerland
[20]Women's Health Division, University College London Hospital, London, UK
[21]Department of Optics and Quantum Electronics, University of Szeged, Szeged, Hungary
[22]Department of Clinical and Experimental Medicine, Division of Obstetrics and Gynaecology, University of Pisa, Pisa, Italy
[23]Department of Gynaecology, Oslo University Hospital, Oslo, Norway
[24]Department of Development and Regeneration - Woman and Child, KU Leuven, Leuven, Belgium
[25]Department of Gynaecology and Obstetrics, University Hospital of Fribourg, Fribourg, Switzerland
[26]Medical School, University of Versailles Saint-Quentin-en-Yvelines (UVSQ), Versailles, France

Corresponding Author: Alexandre Vallée, MD, PhD, Department of Epidemiology and Public Health, Foch Hospital, Suresnes, France
E-mail: al.vallee@hopital-foch.com **ORCID ID:** orcid.org/0000-0001-9158-4467

Cite this article as: Vallée A, Pirtea P, Moawad G, Acién M, Alonso L, Ata B, et al. Diagnosis and management of adenomyosis and its impact on ART–an international expert consensus from GynFoch 2025. Facts Views Vis Obgyn.

Copyright© 2026 The Author(s). Published by Galenos Publishing House on behalf of European Society for Gynaecological Endoscopy.
This is an open-access article under the Creative Commons Attribution-NonCommercial 4.0 International (CC BY-NC 4.0) License.

ABSTRACT

Background: Adenomyosis is an oestrogen-dependent uterine disorder characterised by endometrial tissue infiltration into the myometrium, leading to chronic inflammation and fibrosis. Its diagnosis remains challenging due to the absence of standardised criteria and variable clinical presentations.

Objectives: To establish expert consensus on the management of adenomyosis, particularly concerning its impact on assisted reproductive technology (ART) outcomes.

Methods: An international panel of experts in reproductive medicine, imaging, and surgery convened in Paris in March 2025. A review of English-language studies from January 2020 to March 2025 was conducted, focusing on diagnostic modalities, ART outcomes, and treatment options.

Results: Transvaginal ultrasound with the Morphological Uterus Sonographic Assessment criteria and magnetic resonance imaging are primary diagnostic tools, providing a standardised approach. Emerging biomarkers, including KRAS mutations, show potential for non-invasive diagnosis. Adenomyosis adversely affects ART outcomes, notably reducing implantation and live birth rates, especially in symptomatic cases. Medical treatments such as GnRH agonists and aromatase inhibitors have demonstrated promising efficacy in improving ART success. Surgical interventions, including adenomyomectomy and high-intensity focused ultrasound, may benefit selected patients.

Conclusion: Adenomyosis significantly impacts fertility, necessitating standardised diagnostic criteria and individualised management strategies. Differentiating between symptomatic and asymptomatic forms is crucial for optimising ART outcomes. Further randomised controlled trials are essential to refine treatment protocols and improve reproductive success rates.

Keywords: Adenomyosis, surgery, endometrial receptivity, IVF failure, frozen embryo transfer

Introduction

Adenomyosis is a common yet often underdiagnosed gynaecological condition characterised by the presence of ectopic endometrial glands and stroma within the myometrium, leading to chronic inflammation, myometrial hypertrophy, and fibrosis.[1] Historically considered a disease of multiparous women in their late reproductive years, advancements in imaging modalities such as transvaginal ultrasound (TVUS) and magnetic resonance imaging (MRI) have led to increased recognition of adenomyosis in younger women, including those experiencing infertility.[2] Despite its high prevalence, the pathophysiology of adenomyosis remains incompletely understood, with several hypotheses suggesting mechanisms such as the disruption of the endometrial-myometrial interface, hormonal dysregulation, and immune dysfunction.

Clinically, adenomyosis is associated with a wide spectrum of symptoms, including dysmenorrhoea, abnormal uterine bleeding, pelvic pain, and infertility. The severity of symptoms varies widely among affected individuals, making diagnosis challenging and often leading to delays in treatment.[3] Epidemiological studies suggest that adenomyosis frequently coexists with other gynaecological conditions such as endometriosis and uterine fibroids, further complicating its clinical presentation. Although historically diagnosed through histopathological evaluation following hysterectomy, non-invasive diagnostic criteria based on imaging have significantly improved early detection, allowing for the implementation of conservative treatment strategies.

The impact of adenomyosis on reproductive health has gained increasing attention, particularly in the context of infertility and adverse pregnancy outcomes.[4] The condition has been implicated in reduced implantation rates, recurrent pregnancy loss, and poor assisted reproductive technology (ART) outcomes. The mechanisms underlying adenomyosis-associated infertility include altered uterine peristalsis, defective endometrial receptivity, progesterone resistance, and a pro-inflammatory intrauterine environment. These factors collectively contribute to implantation failure and increased miscarriage rates, posing significant challenges for women attempting to conceive.

Management of adenomyosis remains complex and requires an individualised approach based on symptom severity, reproductive goals, and disease extent.[5] Medical therapy, including hormonal agents such as progestins, gonadotrophin-releasing hormone analogues, selective oestrogen and progesterone receptor modulators as well as aromatase inhibitors, is widely used to alleviate symptoms. Non-hormonal treatments, including non-steroidal anti-inflammatory drugs (NSAIDs) and antifibrinolytic agents, offer symptomatic relief in select cases. For women seeking fertility preservation, conservative surgical techniques such as

adenomyomectomy and non-surgical interventions such as high-intensity focused ultrasound (HIFU) and uterine artery embolization have been explored. However, the role of interventional techniques in improving reproductive outcomes remains a subject of ongoing research.[6,7]

Given the rising clinical awareness of adenomyosis and its implications for reproductive health, further studies are needed to elucidate its pathogenesis, refine diagnostic criteria, and develop targeted therapies that improve both symptom management and fertility outcomes. This review aims to provide a comprehensive overview of adenomyosis, including its pathophysiology, classification, medical and surgical management, and its impact on fertility and pregnancy. By synthesising current knowledge, we hope to enhance understanding and optimise therapeutic strategies for this increasingly recognised condition.

Methods

The Workshop and the Working Group

The GynFoch 2025 Paris meeting was organised in Paris in March 2025. The members of the workshop comprised a panel of international experts who met in Paris, France on March 8, 2025. Experts were selected based on their overall research activities and their publications on the subject. Each member of the working group received a defined topic and the searches to be covered. Topics included the definition(s) and diagnosis of adenomyosis, its clinical characteristics, correct uterine assessment and the soundness of diagnostic means and therapeutic measures commonly proposed.

Literature Search and Consensus Building

A literature search through PUBMED and Cochrane Library was performed using the following key terms "adenomyosis", "recurrent reproductive failure", "medical treatment for adenomyosis", "surgical treatment of adenomyosis" and "imaging diagnosis of adenomyosis". All titles and abstracts, written in English and published from January 2020 to March 2025, were screened to identify relevant studies, for which full-text papers were collected and summarised.

Consensus conclusions were stated based on this literature search and the expert opinions of the working group. At the end of the meeting, key points were established, and conclusions reached.

Preparation of the Manuscript

The Writing Group prepared successive drafts of recommendations that were shared among the Working Group experts for feedback and suggestions. The feedback received was discussed online. The list of experts who contributed to the consensus is included as authors at the beginning of the manuscript.

Commentary with Results

1. Pathophysiology of Adenomyosis

Adenomyosis is a benign uterine disorder characterised by the infiltration of endometrial epithelial and stromal cells into the myometrium, leading to chronic inflammation, myometrial hypertrophy, and fibrosis.[1] This condition is frequently associated with dysmenorrhoea, abnormal uterine bleeding, and infertility. Although its exact pathogenesis is not entirely understood, several mechanisms have been proposed to explain its development.

Junctional Zone Disruption

One widely accepted theory suggests that adenomyosis results from the disruption of the junctional zone, the interface between the endometrium and myometrium.[8] This disruption can occur due to trauma, such as childbirth, uterine surgery, or chronic inflammation, which weakens the barrier at the endometrial-myometrial interface.[9] As a result, basal endometrial cells invade the myometrium, where they continue to proliferate and behave aberrantly (Figure 1).

Retrograde Menstruation

Another proposed mechanism involves retrograde menstruation, like what has been suggested for endometriosis. In this scenario, endometrial cells, instead of being expelled during menstruation, travel into the myometrium and implant there, leading to the characteristic lesions seen in adenomyosis.[10] However, this theory does not fully explain why adenomyosis is primarily localised to the uterine muscle rather than spreading extensively like endometriosis.

Oestrogen Receptor Overactivity

Hormonal dysregulation plays a significant role in the pathogenesis of adenomyosis.[11] Oestrogen receptor overactivity is thought to play a critical role in its development, with research indicating that increased oestrogen receptor activity, particularly phosphorylation of oestrogen receptor alpha at Serine-118, contributes to

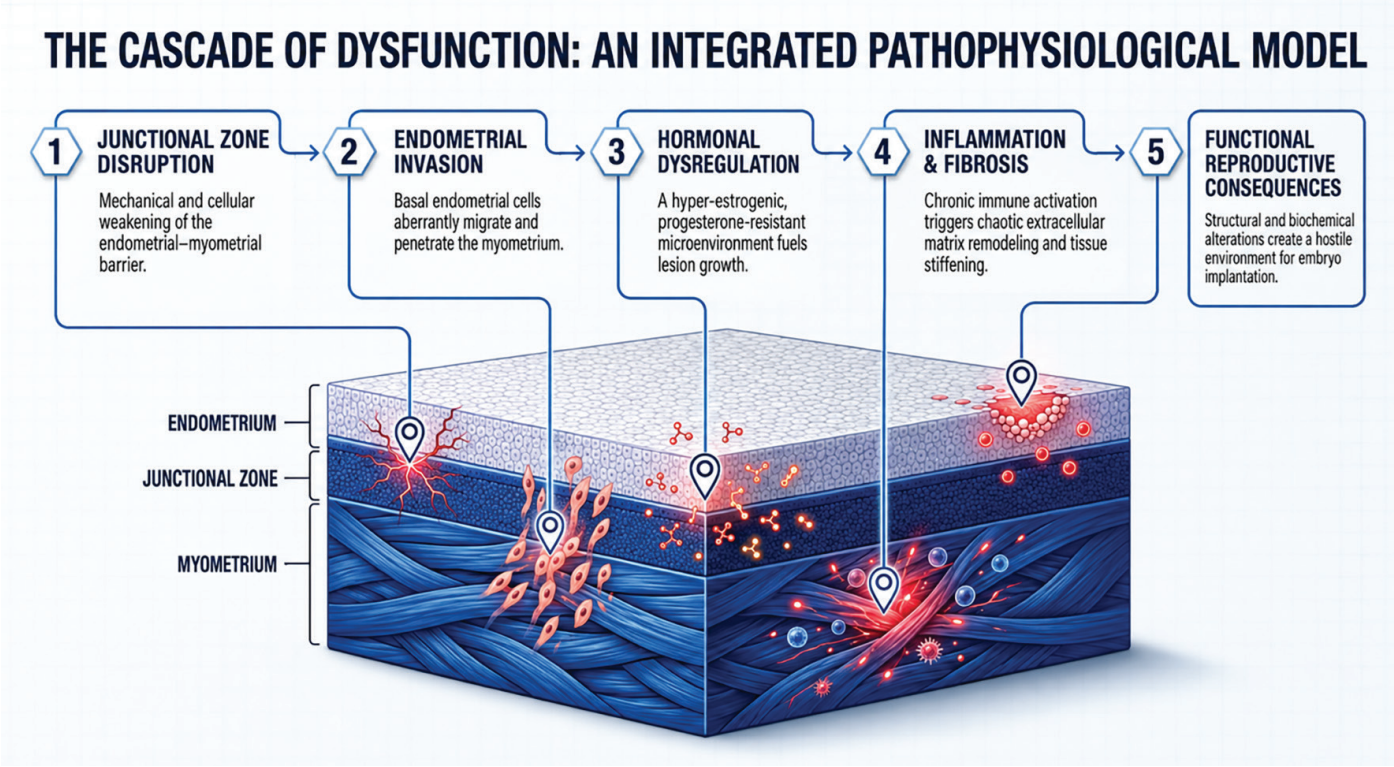

Figure 1. Integrated pathophysiological model of adenomyosis. Adenomyosis is represented as a progressive cascade beginning with disruption of the junctional zone, followed by invasion of basal endometrial cells into the myometrium. This process is sustained by hormonal dysregulation, particularly oestrogen dominance and progesterone resistance, and by chronic inflammation, extracellular matrix remodelling, fibrosis, and myometrial stiffening. Together, these structural and biochemical alterations may create a hostile uterine environment and contribute to impaired implantation and adverse reproductive outcomes.

the abnormal proliferation of endometrial cells within the myometrium.[11] This results in enhanced local oestrogen production, increased myometrial contractility, and a state of progesterone resistance, where the anti-inflammatory effects of progesterone are diminished, exacerbating symptoms.

Genetic Factors

In addition to oestrogen, emerging research highlights the role of genetic factors, such as mutations in genes involved in uterine contractility, as potential contributors to adenomyosis. The progesterone resistance hypothesis also explains the failure of the endometrial tissue to undergo regular shedding, contributing to the growth of adenomyosis.

Inflammation and Alterations in Immune Function

Inflammation is another key component in the development of adenomyosis.[12] The presence of inflammatory cytokines such as interleukin-6 (IL-6), tumour necrosis factor-alpha (TNF-α), and IL-1 beta (IL-1β) leads to chronic tissue damage and fibrosis.[13] Oxidative stress further contributes to this process, promoting abnormal uterine remodelling. In addition to inflammation, alterations in immune function have been observed in adenomyotic tissues, including an increased presence of macrophages and natural killer cells, which may contribute to the persistence and progression of the disease.[14]

Structural changes in the uterus are a hallmark of adenomyosis.[1] The thickening of the junctional zone is often detected through imaging and serves as an early marker of the disease. Myometrial hyperplasia and fibrosis occur in response to the invasion of endometrial cells, leading to uterine enlargement and increased rigidity.[8] Abnormal vascularisation, characterised by excessive angiogenesis and irregular blood vessel formation, further contributes to the symptoms, particularly heavy menstrual bleeding (HMB).[15]

Clinically, adenomyosis presents with chronic pelvic pain, dysmenorrhoea, and HMB due to increased myometrial contractility, inflammation, and vascular abnormalities.[16] The disease can also impair fertility, as the structural changes in the uterus interfere with implantation and embryo development. Studies suggest that adenomyosis

may negatively impact pregnancy outcomes by altering uterine function and disrupting endometrial receptivity.[17]

The endometrium in women with adenomyosis exhibits significant structural, molecular, and functional alterations that contribute to abnormal uterine bleeding, infertility, and pregnancy complications.[18] Unlike healthy endometrium, which undergoes well-regulated cycles of proliferation, differentiation, and shedding, the endometrium in adenomyosis is characterised by increased invasiveness, hormonal dysregulation, chronic inflammation, and abnormal vascularisation. These changes not only affect menstrual function but also impair embryo implantation and increase the risk of adverse pregnancy outcomes.[19]

One of the primary alterations in the endometrium of adenomyosis patients is its disrupted architecture.[3,20,21] Histological studies reveal that the endometrial glands appear irregular and more densely packed, with increased glandular penetration into the myometrium. This invasive behaviour is driven by an overexpression of matrix metalloproteinases, enzymes responsible for extracellular matrix degradation, which facilitates the migration of endometrial cells beyond their usual boundaries. As a result, the junction between the endometrium and myometrium, which is normally well-defined despite absence of a basal lamina, becomes weakened and indistinct, allowing for deeper penetration of endometrial tissue.

Hormonal dysregulation plays a central role in the dysfunction of the endometrium in adenomyosis.[22] Studies have shown that the expression of oestrogen receptors is significantly altered, particularly with increased activation of oestrogen receptor alpha, which enhances oestrogen-driven proliferation. This heightened oestrogenic activity promotes excessive endometrial growth, contributing to abnormal uterine bleeding and pain. In contrast, progesterone resistance is commonly observed, meaning that the endometrium does not respond adequately to the regulatory effects of progesterone. This resistance prevents proper differentiation of the endometrium during the secretory phase of the menstrual cycle, leading to incomplete shedding and prolonged menstrual bleeding. The imbalance between oestrogen and progesterone also creates an inflammatory environment that exacerbates symptoms.[23]

Chronic inflammation is another defining feature of the endometrium in adenomyosis. The presence of inflammatory cytokines such as IL-6, tumour TNF-α, and IL-1 beta leads to increased recruitment of immune cells, including macrophages and natural killer cells, which contribute to tissue remodelling and fibrosis. Elevated levels of oxidative stress markers further indicate persistent cellular damage within the endometrial tissue.[24] This inflammatory state not only perpetuates menstrual pain but also affects the ability of the endometrium to support embryo implantation, making conception more difficult.

The vascularisation of the endometrium is also significantly altered in adenomyosis.[25] Increased expression of vascular endothelial growth factor leads to the formation of fragile and dysfunctional blood vessels. These vessels are more prone to rupture, contributing to HMB. Unlike the well-organised blood vessel networks seen in healthy endometrium, the vasculature in adenomyosis is often disorganised, leading to inefficient blood flow and poor oxygenation of tissues.[26] The presence of these abnormal blood vessels further disrupts normal menstrual shedding and contributes to irregular bleeding patterns.

These structural and functional abnormalities in the endometrium have significant implications for fertility and pregnancy.[27] The ability of the endometrium to support implantation is compromised due to reduced expression of key implantation markers such as HOXA10, HOXA11, and integrins.[28] These molecules are essential for embryo attachment and endometrial receptivity. The chronic inflammatory state and poor progesterone response shorten the window of implantation, making it more difficult for an embryo to establish a stable connection with the uterine lining. Additionally, the increased uterine contractility associated with adenomyosis, driven by heightened prostaglandin activity, further disrupts implantation and increases the risk of early pregnancy loss[29] (Figure 2).

Pregnant women with adenomyosis face a higher risk of miscarriage, preterm birth, and placental abnormalities. The altered uterine environment affects placental implantation and vascular remodelling, leading to complications such as pre-eclampsia and fatal growth restriction. The myometrium in adenomyosis is less capable of accommodating the expanding pregnancy, and abnormal uterine contractions can contribute to preterm labour. Studies have shown that women with adenomyosis have higher rates of caesarean delivery due to dysfunctional labour patterns, and they are also at increased risk for postpartum haemorrhage because of impaired uterine contractility following delivery.[17,30]

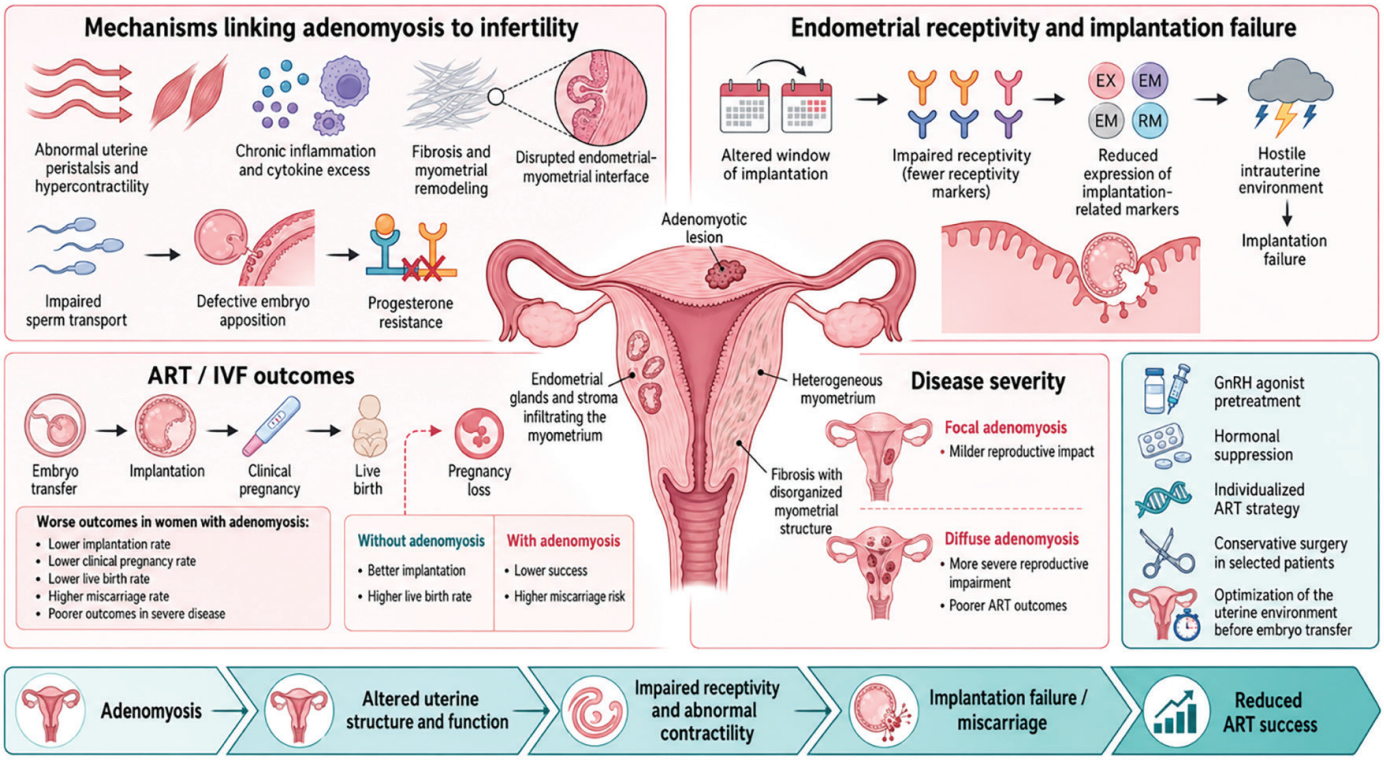

Figure 2. Mechanisms linking adenomyosis to infertility and impaired ART outcomes. Adenomyosis may impair fertility through multiple interconnected mechanisms, including abnormal uterine peristalsis, disrupted endometrial–myometrial interface, chronic inflammation, fibrosis, progesterone resistance, and impaired endometrial receptivity. These changes can alter the window of implantation, reduce embryo apposition and implantation, and contribute to lower clinical pregnancy and live birth rates as well as higher miscarriage rates in women undergoing assisted reproductive technology. The reproductive impact appears more pronounced in diffuse or severe adenomyosis, supporting individualised pretreatment and ART strategies.

ART: Assisted reproductive technology, IVF: In vitro fertilisation.

Overall, adenomyosis is a complex condition involving oestrogen-progesterone receptor imbalance, immune system dysregulation, chronic inflammation, and structural changes within the uterus (Figure 1). These factors contribute to the progressive nature of the disease, making early diagnosis and targeted management crucial for improving patient outcomes.

2. The Impact of Adenomyosis on Infertility and ART Outcomes

Adenomyosis is increasingly recognised as a significant contributor to infertility, with its impact extending beyond uterine structural changes to include altered endometrial receptivity, impaired implantation, and adverse pregnancy outcomes (Figure 2).[4] Epidemiological studies provide evidence that adenomyosis is more prevalent in infertile women than in the general population, with reported rates ranging from 20% to 50% among women undergoing ART, compared to an estimated prevalence of 5% to 25% in the general female population of reproductive age.[31,32] The association between adenomyosis and infertility has been extensively investigated, with multiple studies demonstrating that women with adenomyosis have lower pregnancy rates, increased implantation failure, and higher miscarriage rates compared to women without the condition.[4,33] Additionally, patients with adenomyosis compared to the general population, more frequently undergo treatment for infertility problems (30% vs. 6,6%) and achieve a pregnancy with ART treatment (19,3% vs. 3%).[34]

Adenomyosis and Fertility

One of the primary mechanisms through which adenomyosis affects fertility is through disruption of the endometrial-myometrial interface, where ectopic endometrial glands infiltrate the myometrium, leading to chronic inflammation, fibrosis, and abnormal myometrial contractility. This invasion alters uterine peristalsis, which is crucial for sperm transport, embryo positioning, and implantation.[35] Studies using advanced imaging modalities, such as three-dimensional TVUS and MRI, have revealed that adenomyosis is associated with an

increased frequency of abnormal uterine contractions, which may hinder embryo implantation by disrupting the precise coordination of endometrial receptivity and embryo apposition.[36,37]

Adenomyosis and ART Outcomes?

The impact of adenomyosis on ART outcomes, with numerous studies reporting lower pregnancy and live birth rates in women with adenomyosis undergoing *in vitro* fertilisation (IVF) compared to controls. ART outcomes in women with adenomyosis found that the clinical pregnancy rate was significantly reduced, with a 30% to 40% lower chance of achieving pregnancy per IVF cycle.[38] Moreover, the miscarriage rate in women with adenomyosis undergoing IVF was nearly double that of women without adenomyosis, suggesting that even when implantation occurs, the altered endometrial environment may compromise pregnancy maintenance.[39] The adverse effects of adenomyosis on IVF outcomes are particularly pronounced in women with more severe disease, as evidenced by findings that women with diffuse adenomyosis have even lower pregnancy rates than those with focal adenomyosis. Given these challenges, several therapeutic strategies have been explored to improve fertility outcomes in women with adenomyosis.[40] Short-term gonadotropin-releasing hormone (GnRH) agonist therapy before embryo transfer has been shown to improve implantation and clinical pregnancy rates by temporarily inducing a hypo-oestrogenic state, reducing inflammation, and shrinking adenomyotic lesions.[41] Other interventions, such as selective progesterone receptor modulators (SPRMs), aromatase inhibitors, and HIFU, have been investigated for their potential to restore endometrial receptivity and improve fertility outcomes, though further research is needed to establish standardised treatment protocols.

Surgical interventions, including adenomyomectomy, have been performed in select cases to improve reproductive outcomes, particularly in women with focal adenomyosis who have failed previous ART attempts.[42] However, the potential benefits of surgery must be weighed against the risk of uterine rupture in subsequent pregnancies, necessitating careful patient selection and close obstetric monitoring.[43] Despite the growing body of evidence linking adenomyosis to infertility, challenges remain in defining standardised diagnostic criteria, as variations in imaging techniques and histopathological definitions have contributed to heterogeneity in reported prevalence rates.[1] The increasing recognition of adenomyosis as a distinct pathological entity, separate from endometriosis, has led to renewed efforts to refine diagnostic criteria and develop targeted therapeutic strategies to optimise fertility outcomes in affected women.

3. Which Classification Use?

The classification of adenomyosis has evolved over the years as researchers and clinicians have sought to better understand the condition and its impact on reproductive and overall gynaecological health.[1] Evolution in the classification proposals was actually the result of the advances in the diagnostic methods. Historically, adenomyosis was considered a homogeneous disease affecting the uterus diffusely but advances in imaging and histopathology have led to the recognition of multiple subtypes with distinct clinical implications.[44] Various classification systems have been proposed, incorporating factors such as lesion location, depth of invasion, and extent of myometrial involvement (Table 1).

Recent proposals for the classification of adenomyosis are based on the imaging features of the disease, particularly findings from TVUS and MRI.[49,52,53] Imaging based classification systems frequently categorise adenomyosis into focal and diffuse types.[54] Focal adenomyosis, also referred to as adenomyomas, presents as localised nodular lesions within the myometrium, often mimicking fibroids but differing in their ill-defined margins and heterogeneous echotexture on ultrasound.[55] Diffuse adenomyosis, in contrast, involves widespread infiltration of the myometrium by endometrial glands and stroma, leading to global uterine enlargement and thickening of the junctional zone. This distinction is clinically significant, as focal adenomyosis may be more amenable to localised surgical excision, whereas diffuse adenomyosis typically requires more comprehensive management strategies.[54]

Another important classification criterion is the depth of myometrial invasion.[48] Studies suggest that adenomyotic lesions can be classified into superficial, intermediate, and deep forms based on how far they penetrate into the myometrium.[47] Superficial adenomyosis involves the innermost layers of the myometrium and is often asymptomatic or mildly symptomatic. Intermediate adenomyosis extends deeper into the muscle layer and is more likely to cause significant menstrual pain and abnormal bleeding. Deep adenomyosis, which infiltrates nearly the entire thickness of the myometrium, is strongly associated with severe dysmenorrhoea, infertility, and adverse pregnancy outcomes. Some researchers have

Table 1. Summary of the main classification systems of adenomyosis.

System/reference	Basis/modality	Main categories or grades	Key diagnostic criteria/ features	Clinical relevance
Histopathological classification[25,45]	Microscopic/post-hysterectomy tissue	Grade I = superficial (<1/3 myometrium) ; Grade II = intermediate (1/3–2/3) ; Grade III = deep (>2/3)	Endometrial glands/stroma >1–2 HPF below endometrial–myometrial junction±fibrosis, inflammation	Correlates with symptom severity and infertility risk
Topographic classification[18]	Imaging (TVUS/MRI)	Focal vs. diffuse	Focal = adenomyoma (nodular, ill-defined); diffuse = widespread myometrial infiltration	Guides surgical feasibility (adenomyomectomy vs. medical therapy)
Inner/outer myometrium type[46,47]	MRI/aetiological	Inner (internal) = junctional zone origin; outer (external) = serosal origin, often with endometriosis	Inner → endomyometrial junction disruption; Outer → endometriotic infiltration	Reflects different pathogenesis; prognostic for coexistence with endometriosis
Depth-of-invasion grading[48]	MRI	Grade I = superficial (<25% myometrium) ; Grade II = intermediate (25–50%); Grade III = deep (>50%)	Based on junctional-zone thickening and extent of low-signal areas	Predicts pain severity and reproductive impact
MUSA classification[49,52]	Standardised TVUS	7-step reporting: diagnostic certainty, location, type, extent, lesion size, junctional-zone features, associated pathology	Asymmetric myometrial thickening, cysts, hyperechogenic islands, fan-shaped shadowing, irregular JZ Revised criteria group findings under direct and indirect findings	Standardisation of imaging and interobserver agreement
MRI morphological subtypes[50]	MRI	Type I = focal adenomyoma ; Type II = diffuse ; Type III = adenomyosis with fibroids	Signal heterogeneity, JZ >12 mm, myometrial cysts	Useful for pre-surgical mapping
Molecular/genetic profiling[51]	Genomic/ transcriptomic	Emerging subtypes: hormone-receptor dysregulation; inflammatory; fibrotic; mutational (e.g., KRAS)	Based on ER/PR expression, cytokine signatures, KRAS mutations	Toward precision medicine and targeted therapy

HPF: High-power field, TVUS: Transvaginal ultrasound, MRI: Magnetic resonance imaging, MUSA: Morphological Uterus Sonographic Assessment, JZ: Junctional zone, ER: Oestrogen receptor, PR: Progesterone receptor, KRAS: Kirsten rat sarcoma viral oncogene homolog.

proposed using a grading system based on the depth of invasion, with grades I, II, and III corresponding to superficial, intermediate, and deep involvement, respectively.[1]

More recently, the Morphological Uterus Sonographic Assessment (MUSA) criteria have been developed to provide a standardised approach to diagnosing and classifying adenomyosis via ultrasound.[49,52,56] This system identifies specific ultrasound features such as asymmetric myometrial thickening, cystic areas within the myometrium, heterogeneous echotexture, and the presence of an irregular or thickened junctional zone. By applying these criteria, clinicians can more accurately distinguish adenomyosis from other uterine conditions such as fibroids and endometriosis. The group later proposed an ultrasound classification of adenomyosis in seven steps starting from differential diagnosis up to the full reporting of the disease morphological characteristics.[49,53] Furthermore, direct and indirect ultrasound findings of adenomyosis were defined. Direct findings were echogenic subendometrial lines and buds, hyperechogenic islands and myometrial cysts. Indirect findings were globular uterus, asymmetrical myometrial thickening, fan-shaped shadowing, translesional vascularity, and irregular or interrupted junctional zone.[52]

Histopathological classification also plays a crucial role, particularly in cases where adenomyosis is confirmed post-hysterectomy.[45] Traditional histological criteria

require the presence of endometrial glands and stroma at least one to two high-power fields below the endometrial-myometrial interface. More refined histopathological grading systems have been proposed, incorporating factors such as gland density, stromal fibrosis, and the presence of inflammatory infiltrates. These classifications help correlate histological severity with clinical symptoms.

In addition to these structural classifications, some researchers have begun to explore molecular and genetic subtypes of adenomyosis.[47] Emerging evidence suggests that different molecular signatures may underlie the varying clinical presentations of adenomyosis, with some cases exhibiting features of hormone receptor dysregulation, while others show signs of increased inflammatory activity or fibrosis. These insights may pave the way for future precision medicine approaches, tailoring treatments to the specific pathophysiological mechanisms driving the disease in individual patients (Figure 3).

Overall, the classification of adenomyosis remains an area of active research, with ongoing efforts to refine imaging, histological, and molecular criteria to improve diagnosis and management (Table 2). The recognition of distinct subtypes is essential for developing personalised treatment strategies, minimising symptoms, and optimising reproductive outcomes for affected individuals.

4. Medical Therapy for Adenomyosis

Medical management of adenomyosis focuses on symptom control, particularly dysmenorrhoea, abnormal or HMB, and chronic pelvic pain, while also addressing fertility concerns in women seeking to conceive. Since adenomyosis is an oestrogen-dependent disease, most treatments aim to reduce oestrogen levels or counteract its effects on the adenomyotic foci.[11] The choice of therapy depends on the patient's symptoms, reproductive goals, and severity of the disease (Figure 4).[57]

4.1 Hormonal Therapy

Hormonal treatments are the first-line approach for adenomyosis, targeting the hormonal dysregulation and endometrial invasiveness associated with the disease.[58]

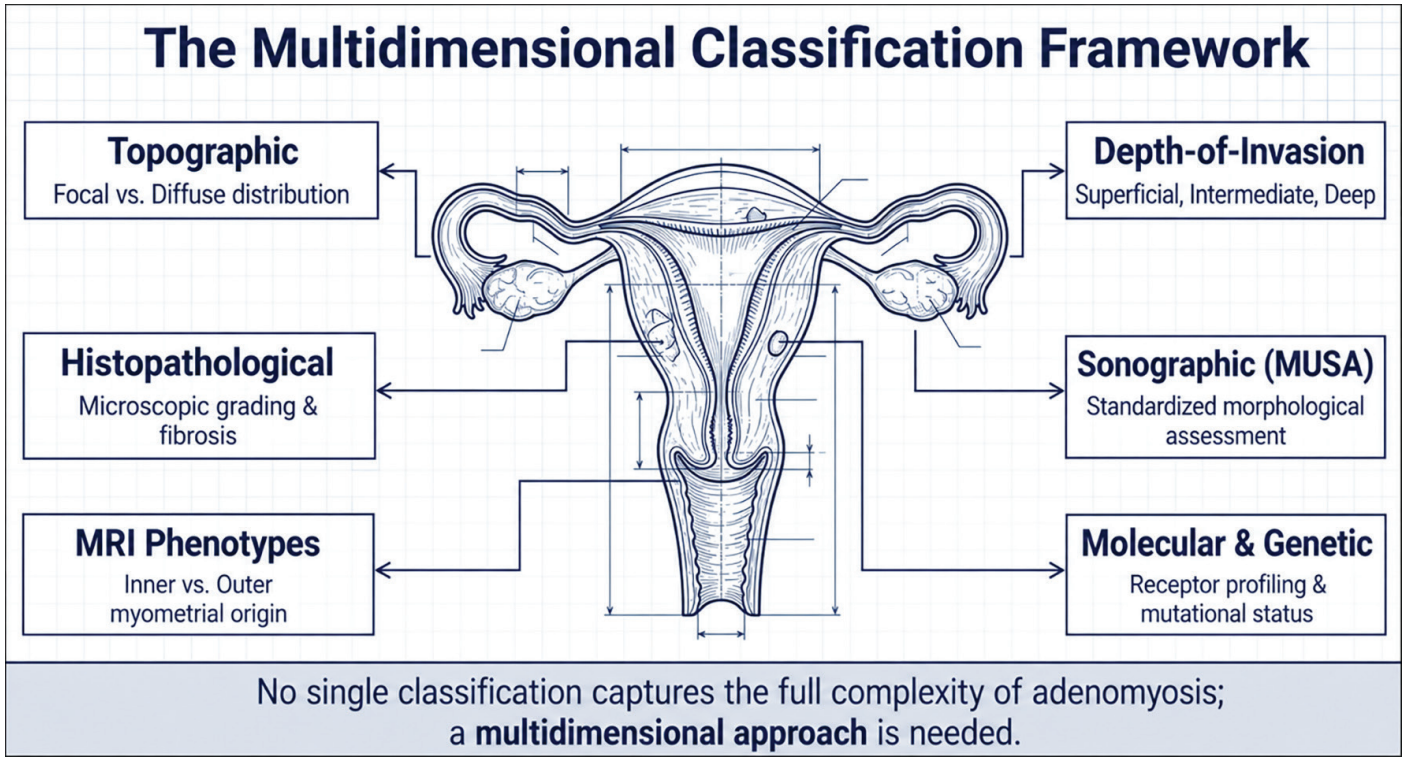

Figure 3. Multidimensional classification framework for adenomyosis. Adenomyosis classification requires an integrated approach combining topographic distribution, depth of myometrial invasion, histopathological grading, MRI phenotypes, standardised sonographic assessment using MUSA criteria, and emerging molecular or genetic profiling. No single system fully captures the heterogeneity of the disease; therefore, a multidimensional framework may improve diagnostic standardisation, phenotyping, therapeutic decision-making, and prognostic assessment.

MUSA: Morphological Uterus Sonographic Assessment, MRI: Magnetic resonance imaging.

Table 2. Summary of main features of adenomyosis in comparison to endometriosis.

Feature	Adenomyosis	Endometriosis
Clinical definition		
Definition	Presence of endometrial glands and stroma within the myometrium, leading to uterine hypertrophy, inflammation, and fibrosis.	Presence of endometrial-like tissue outside the uterus (peritoneum, ovaries, fallopian tubes, bowel, bladder, diaphragm, lungs).
Primary symptoms	Heavy menstrual bleeding, dysmenorrhoea, chronic pelvic pain, infertility, uterine enlargement.	Dysmenorrhoea, chronic pelvic pain, dyspareunia, cyclic bowel/bladder symptoms, infertility.
Menstrual flow	Heavy, prolonged, and often irregular periods.	Normal or slightly altered menstrual flow.
Infertility risk	Present, but less severe than in endometriosis.	High, due to peritoneal inflammation, adhesions, and implantation failure.
Pain location	Central, deep pelvic pain, often associated with uterine contractions.	Lateralised pelvic pain, worse before and during menstruation.
Imaging definition		
Ultrasound findings	Heterogeneous myometrium, thickened junctional zone, myometrial cysts, ill-defined hyperechoic areas.	Ovarian endometriomas ("chocolate cysts"), hypoechoic nodules, adhesions.
MRI findings	Thickened junctional zone (>12 mm), T2 hypointense areas (fibrosis), microcystic spaces.	T2 hyperintense endometriomas, adhesions, deep nodular infiltrates.
Affected structures	Myometrium (uterine muscle).	Pelvic peritoneum, ovaries, fallopian tubes, bowel, bladder, diaphragm, lungs.
Subtypes	Diffuse, focal, cystic, adenomyoma.	Peritoneal, ovarian, deep infiltrating.
Genetic and epigenetic definition		
Genetic alterations	KRAS, PIK3CA, PTEN mutations, leading to abnormal cell proliferation and fibrosis.	KRAS, ARID1A, PIK3CA, PTEN, BAF250 mutations, linked to epithelial-mesenchymal transition and endometriotic lesion survival.
Epigenetic changes	Aberrant DNA methylation in hormone receptor genes (ESR1, PR-B).	Histone modifications, DNA methylation changes affecting immune tolerance, pro-inflammatory genes (IL-6, TNF-α).
Molecular pathway definition		
Hormonal dysregulation	Oestrogen overexpression (↑CYP19A1, ↑ESR1), Progesterone resistance (↓PR-B).	Oestrogen dependency (↑ERβ), Progesterone resistance (↓PR-A/PR-B imbalance).
Inflammatory markers	COX-2, NF-κB, IL-6, TNF-α overexpression, leading to chronic myometrial inflammation.	COX-2, IL-1β, IL-6, TNF-α, MCP-1, driving local peritoneal immune dysfunction.
Fibrosis and ECM remodelling	TGF-β1 overactivation, leading to excessive extracellular matrix deposition, fibrotic stiffening of the uterus.	Increased TGF-β1 and VEGF, driving peritoneal adhesion formation and neovascularisation.
Neuroangiogenesis	VEGF-mediated nerve infiltration contributes to deep uterine pain.	VEGF-mediated neurogenesis leads to excessive innervation of ectopic lesions, amplifying neuropathic pain.
Pathophysiology-based differences		
Tissue origin	Likely due to invasion of endometrial cells into the myometrium, potentially influenced by mechanical and hormonal factors.	Likely caused by retrograde menstruation, coelomic metaplasia, and immune dysregulation.
Tissue interaction	Expands within the uterine muscle, causing hypertrophy, fibrosis, and inflammation.	Grows outside the uterus, affecting multiple organs and forming adhesions.
Role of immune dysfunction	Local inflammation with increased macrophage infiltration.	Systemic immune dysregulation, reduced natural killer cell activity, and altered T-cell response.

Table 2. Continued

Feature	Adenomyosis	Endometriosis
Treatment implications		
First-line treatment	Hormonal therapy (progestins, GnRH agonists, aromatase inhibitors, LNG-IUD).	Hormonal therapy (hormonal contraceptives, progestins, GnRH analogues, aromatase inhibitors).
Surgical treatment	Hysterectomy (definitive treatment in severe cases), conservative excision of focal lesions.	Laparoscopic excision of lesions, ablation, adhesiolysis.
Fertility considerations	May impair fertility, but uterus-preserving treatments possible (e.g., GnRH analogues).	Higher infertility risk, often requiring ART (assisted reproductive technology).
Key takeaways		
Location	Within the myometrium (uterine muscle).	Outside the uterus (peritoneum, ovaries, bowel, bladder, etc.).
Main symptoms	Heavy menstrual bleeding, painful periods, infertility, enlarged uterus.	Chronic pelvic pain, cyclical symptoms, infertility, dyspareunia.
Primary imaging sign	Thickened junctional zone on MRI (>12 mm), heterogeneous myometrium.	Endometriomas (chocolate cysts), adhesions, deep infiltrating nodules.
Genetics	KRAS, PTEN, PIK3CA mutations.	KRAS, ARID1A, BAF250 mutations.
Hormonal response	Oestrogen-driven, progesterone-resistant.	Oestrogen-driven, progesterone-resistant.
Fibrosis and neuroangiogenesis	TGF-β1 and VEGF-mediated myometrial fibrosis.	TGF-β1 and VEGF-mediated adhesion formation, nerve infiltration.
Definitive treatment	Hysterectomy (for severe cases), hormonal therapy.	Laparoscopic excision of lesions, hormonal therapy.

MRI: Magnetic resonance imaging, KRAS: Kirsten rat sarcoma viral oncogene homolog, PTEN: Phosphatase and tensin homolog, ESR1: Oestrogen receptor 1, ERβ: Oestrogen receptor beta, COX-2: Cyclooxygenase-2, NF-κB: Nuclear factor kappa B, IL-1β: interleukin-1 beta, TNF-α: tumour necrosis factor alpha, ECM: Extracellular matrix, TGF-β1: Transforming growth factor beta 1, VEGF: Vascular endothelial growth factor, NK: Natural killer, GnRH: Gonadotropin-releasing hormone, LNG-IUD: Levonorgestrel-releasing intrauterine device, ART: Assisted reproductive technology.

4.1.1 Combined Oral Contraceptives (COCs) and Progestin-Only Pills (POPs)

Oestrogen-progestin combination pills and *POPs* help regulate menstrual cycles, suppress ovulation, and reduce endometrial proliferation.[59] This results in lighter and less painful periods. COCs containing ethinyl estradiol and various progestins can be taken continuously to induce amenorrhea and reduce the cyclical pain associated with adenomyosis. However, their long-term use may be limited by side effects such as breakthrough bleeding and thromboembolic risk.

4.1.2 Levonorgestrel-Releasing Intrauterine System

One of the most effective treatments for adenomyosis, the levonorgestrel intrauterine system (LNG-IUS) provides local progestin therapy that thins the endometrium, reduces menstrual bleeding, and alleviates pain.[60] Studies show that LNG-IUS can significantly decrease uterine volume and junctional zone thickness, making it a preferred choice for women with adenomyosis who wish to preserve fertility.[61] The device is effective for up to eight years, offering long-term symptom relief, although some patients may experience irregular bleeding in the first few months.

4.1.3 Dienogest and Other Oral Progestins

Dienogest, a selective progestin, has demonstrated efficacy in reducing adenomyosis-related pain and bleeding.[62,63] Dienogest has potent anti-inflammatory and antiproliferative effects on endometrial cells. It works by inhibiting ovulation, suppressing oestrogen production, and inducing endometrial atrophy. Patients on dienogest report a reduction in menstrual blood loss and dysmenorrhoea, although some experience side effects such as weight gain and mood changes.[64,65]

4.1.4 Gonadotropin-Releasing Hormone Agonists and Antagonists

GnRH analogues suppress ovarian oestrogen production and induce a hypo-oestrogenic state, leading to a temporary menopausal-like condition.[66] This results in atrophy of adenomyotic tissue, decreased uterine volume, and improved symptoms. However, the hypo-oestrogenic effects often lead to bone density loss, vasomotor symptoms (hot flushes), and vaginal dryness, limiting their long-term use. To mitigate these effects, add-back therapy (low-dose oestrogen and progestin) is often prescribed alongside GnRH agonists. GnRH

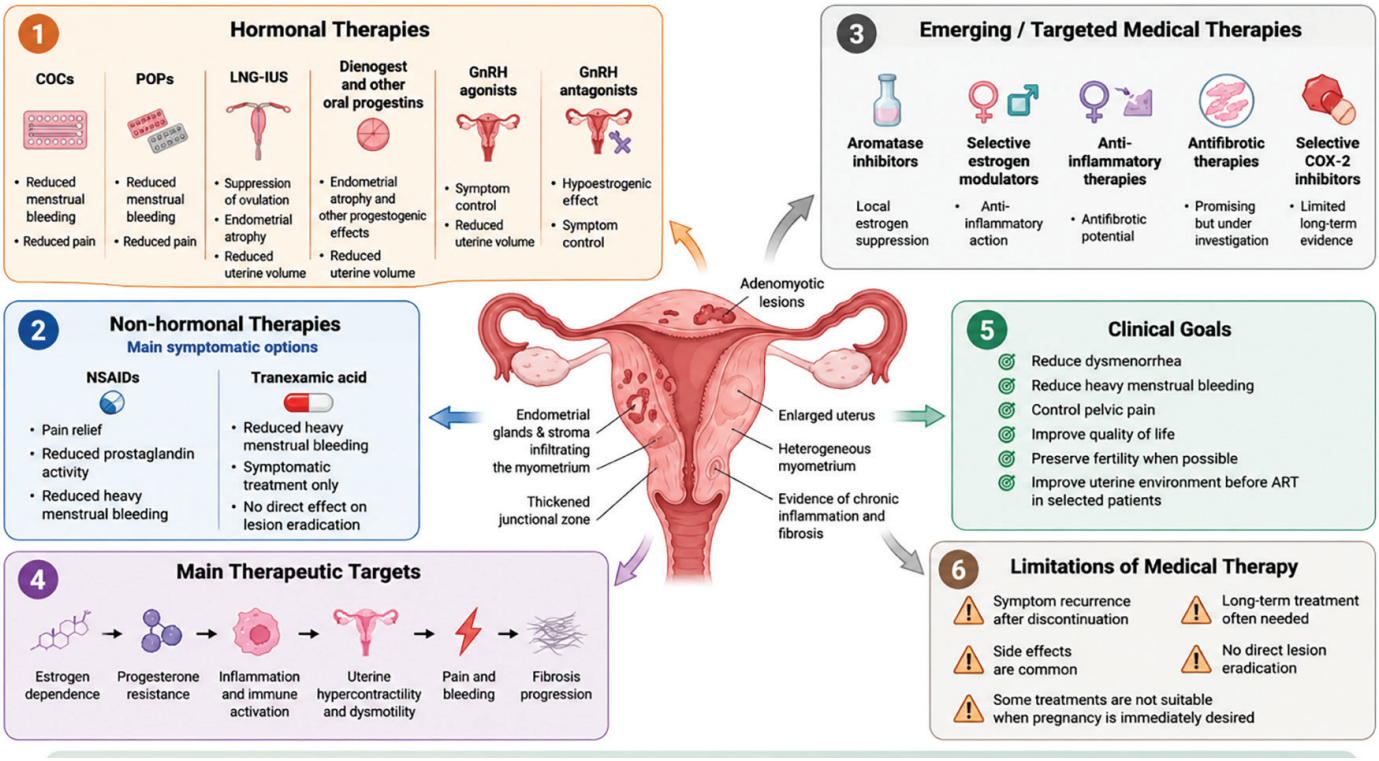

Figure 4. Medical management of adenomyosis: therapeutic targets and limitations. Medical treatment of adenomyosis includes hormonal, non-hormonal, and emerging targeted therapies aimed at reducing pain, heavy menstrual bleeding, inflammation, oestrogen-driven lesion activity, and impaired endometrial function. Progestins, levonorgestrel-releasing intrauterine systems, and GnRH analogues remain key therapeutic options, while aromatase inhibitors, anti-inflammatory agents, and antifibrotic strategies represent potential future approaches. Treatment should be individualised according to symptom severity, reproductive goals, vascular and metabolic risk profile, tolerance, and the likelihood of symptom recurrence after discontinuation.

GnRH: Gonadotropin-releasing hormone, LNG-IUS: Levonorgestrel-releasing intrauterine system, COC: Combined oral contraceptive, POP: Progestogen-only pills, NSAID: Non-steroidal anti-inflammatory drug, ART: Assisted reproductive technology.

antagonists, such as elagolix, relugolix and linzagolix,[67] offer an alternative with a more immediate onset of action and fewer side effects but are still under study for long-term use in adenomyosis management.[68,69]

4.2 Non-Hormonal Medical Therapy

For patients who cannot tolerate hormonal treatments or prefer alternative options, non-hormonal approaches may be considered.

4.2.1 Non-steroidal Anti-Inflammatory Drugs

NSAIDs, such as ibuprofen and naproxen, are commonly used for pain relief in adenomyosis.[70] They work by inhibiting prostaglandin synthesis, reducing inflammation and uterine contractions. While effective for dysmenorrhoea and pelvic pain, NSAIDs do not address the underlying hormonal and structural changes in the uterus and are best used as adjunct therapy. However, NSAIDs could be considered for managing recurrent exacerbations of adenomyosis symptoms in women already receiving optimised hormonal treatment or in women seeking pregnancy who are not undergoing any treatment other than symptomatic relief.[71]

4.2.2 Tranexamic Acid

This antifibrinolytic agent is used to reduce HMB in adenomyosis patients.[72] By stabilising fibrin clots, tranexamic acid can decrease menstrual blood loss by up to 50%. It does not affect hormone levels or disease progression and is particularly useful for women who do not tolerate hormonal therapies.

4.2.3 Selective oestrogen and Progesterone Receptor Modulators (SERMs and SPRMs)

Selective oestrogen receptor modulators (SERMs), such as raloxifene, and SPRMs, such as ulipristal acetate, have been investigated for their potential role in controlling adenomyosis-related bleeding and pain.[73] SPRMs act by modifying progesterone signalling, leading to endometrial suppression and shrinkage of adenomyotic lesions. However,

safety concerns regarding endometrial hyperplasia and liver toxicity have limited their widespread use.

4.3 Emerging Medical Therapies

Recent research has focused on novel therapeutic targets for adenomyosis. Aromatase inhibitors, such as letrozole, block local oestrogen production within adenomyotic lesions, leading to oestrogen depletion and symptom relief.[74] While promising, their long-term safety and efficacy require further study. Additionally, drugs targeting inflammation and fibrosis, such as selective COX-2 inhibitors and antifibrotic agents, are being investigated for their role in modifying disease progression.[75]

4.4 Limitations of Medical Therapy

While medical treatment provides symptom relief, it does not eliminate adenomyotic lesions. Symptoms often recur upon discontinuation of therapy, requiring long-term management. Additionally, some women may experience side effects that limit adherence to treatment. For those with severe symptoms unresponsive to medical therapy, surgical options may be necessary.

4.5 Summary of Medical Therapies

Medical therapy for adenomyosis includes a range of hormonal and non-hormonal treatments aimed at controlling symptoms and improving quality of life. While progestins, LNG-IUS, and GnRH analogues remain the most effective options, emerging therapies targeting oestrogen metabolism, inflammation, and fibrosis offer potential new avenues for treatment. Individualised therapy, considering symptom severity, reproductive goals, and treatment side effects, is essential for optimising patient outcomes.

Given these challenges, targeted treatments have been developed to improve endometrial function in women with adenomyosis. Hormonal therapies such as progestins and GnRH agonists aim to suppress oestrogen activity, and reduce inflammation. Localised treatments, such as the LNG-IUS, help regulate endometrial growth and control HMB.[76] Anti-inflammatory therapies, including NSAIDs and COX-2 inhibitors, target prostaglandin production to alleviate pain and reduce inflammatory responses. In fertility patients, pre-treatment with short-term GnRH therapy before IVF may improve implantation rates by reducing endometrial inflammation and enhancing receptivity.[77]

Despite these advances, the management of endometrial dysfunction in adenomyosis remains complex, and ongoing research continues to explore new therapeutic targets. Understanding the intricate interplay between the endometrium and adenomyosis is essential for developing effective treatment strategies that not only alleviate symptoms but also improve reproductive outcomes for affected women.

5. Surgical and Interventional Therapies for Adenomyosis

Surgical treatment for adenomyosis is considered when medical therapy fails to provide adequate symptom relief, when symptoms significantly impact a patient's quality of life, or when fertility-preserving options are required for individuals seeking pregnancy.[42] The selection of an appropriate surgical approach depends on several factors, including the extent of adenomyotic lesions, symptom severity, patient age, reproductive goals, and the overall structural integrity of the uterus. Surgical options can be broadly categorised into conservative, uterus-preserving procedures and definitive treatment through hysterectomy.

Minimally invasive approaches, such as laparoscopic or robotic-assisted adenomyomectomy, have gained popularity due to their ability to reduce surgical trauma, minimise intraoperative blood loss, and promote faster recovery.[78] These techniques employ advanced imaging and precision instrumentation to excise adenomyotic lesions while preserving as much healthy myometrial tissue as possible.[79] However, laparoscopic adenomyomectomy requires highly specialised surgical expertise, as excessive myometrial resection can weaken the uterus, increasing the risk of postoperative adhesions and uterine rupture in subsequent pregnancies.[80]

Uterine artery embolisation (UAE) represents another minimally invasive alternative for the management of adenomyosis, particularly in patients who do not desire future pregnancies.[81] This procedure involves the selective catheterisation of the uterine arteries and the injection of embolic agents to obstruct blood flow to the adenomyotic uterus, thereby inducing ischaemic shrinkage of the affected tissue. While UAE has demonstrated efficacy in reducing HMB and dysmenorrhoea, its impact on fertility remains controversial. Some studies suggest that UAE may impair endometrial receptivity and increase the risk of placental abnormalities in future pregnancies.[82] Therefore, it is typically recommended for women who prefer a non-surgical alternative to hysterectomy but do not plan to conceive.

HIFU and magnetic resonance-guided focused ultrasound surgery (MRgFUS) have emerged as non-invasive, uterus-preserving options that use thermal energy to ablate adenomyotic tissue.[83] These techniques utilise either ultrasound or MRI guidance to precisely target and destroy adenomyotic lesions while sparing adjacent healthy tissue. HIFU and MRgFUS have shown promise in providing symptom relief with minimal recovery time and a lower complication profile compared to traditional surgical approaches.[84] However, their long-term efficacy, particularly in deeply infiltrating or diffuse adenomyosis, remains under investigation. These methods are most effective in patients with localised disease and may not be suitable for those with widespread myometrial involvement.[85]

For patients with severe, diffuse adenomyosis who do not desire future pregnancies, hysterectomy remains the most effective and permanent treatment.[36] This procedure involves the complete removal of the uterus, thereby eliminating adenomyotic lesions entirely and providing definitive relief from pain and abnormal uterine bleeding. Both total or subtotal hysterectomy may be considered, though subtotal hysterectomy approach is less frequently recommended due to the potential persistence of symptoms from residual adenomyotic tissue. In some cases, hysterectomy is performed in conjunction with bilateral salpingo-oophorectomy, particularly if coexisting ovarian pathology, such as endometriosis, is present.[86]

Hysterectomy for adenomyosis can be performed through several surgical techniques, depending on the size of the uterus, the presence of adhesions, and patient preference. Abdominal hysterectomy, the traditional open surgical approach, is typically reserved for cases involving very large uterine size or significant adhesions. Laparoscopic or robot-assisted hysterectomy is a minimally invasive alternative that offers the advantages of smaller incisions, reduced postoperative pain, and a faster recovery period. Vaginal or vNOTES hysterectomy is another option, particularly in cases where the uterus is not excessively enlarged, and extensive pelvic adhesions are not expected.

The postoperative course following surgical treatment for adenomyosis varies depending on the type of procedure performed.[87] Minimally invasive surgeries, such as laparoscopic adenomyomectomy or UAE, are associated with shorter recovery times and a lower risk of complications compared to open abdominal surgeries. In contrast, hysterectomy, being a more extensive procedure, necessitates a longer recovery period. Patients undergoing uterus-preserving surgery must be closely monitored for symptom recurrence, as residual adenomyotic tissue may lead to disease progression. Women who have undergone adenomyomectomy or other conservative surgical interventions should also be counselled on the risks associated with future pregnancies, particularly the potential for uterine rupture, and should undergo careful obstetric surveillance.[88]

The selection of an appropriate surgical intervention for adenomyosis should be individualised, considering the severity of symptoms, failure of medical therapy, the extent of the disease, and reproductive goals. Young women desiring pregnancy may benefit from adenomyomectomy despite the risk of recurrence, as it provides symptom relief while preserving uterine function.[89] In contrast, hysterectomy remains the definitive treatment for patients who have completed childbearing and seek permanent resolution of symptoms.[90] The choice between conservative and definitive surgical management must balance efficacy, safety, and long-term reproductive outcomes to optimise the quality of life for patients with adenomyosis. Given the complexity of adenomyosis, a multidisciplinary approach integrating surgical expertise, imaging modalities, and long-term follow-up is essential to ensure optimal treatment outcomes.

6. Hysteroscopy and Adenomyosis

Hysteroscopy is utilised by some teams in the diagnosis and management of adenomyosis, particularly in patients experiencing abnormal uterine bleeding, infertility, and recurrent pregnancy loss.[79] As a minimally invasive technique, it provides direct visualisation of the uterine cavity, allowing for the assessment of adenomyotic changes and facilitating targeted therapeutic interventions. While hysteroscopy alone does not serve as a definitive diagnostic tool for deep adenomyosis, it is increasingly recognised as a valuable adjunct when combined with imaging techniques such as TVUS and MRI.[91] The hysteroscopic findings in adenomyosis may be characterised by an irregular, cystic endometrial surface, where small glandular openings may be seen within the myometrium, sometimes containing old blood, creating a honeycomb-like appearance.[18] The presence of endometrial defects and cryptic glandular openings suggests adenomyotic invasion, whereas a heterogeneous endometrial texture with increased vascularisation correlates with abnormal bleeding patterns.[1] Additional hysteroscopic features such as

microcystic areas and haemorrhagic spots indicate the presence of trapped menstrual blood within ectopic endometrial glands, a key factor contributing to cyclical pelvic pain. Furthermore, altered endometrial receptivity can be inferred from poor endometrial wave patterns and hypervascularisation, factors that may negatively affect implantation and fertility outcomes (Figure 5).

Although hysteroscopy provides important visual clues, it has limitations in evaluating deep adenomyotic lesions extending into the outer myometrium.[92] Consequently, histological confirmation remains necessary in suspected cases, with hysteroscopically guided myometrial biopsy serving as a useful technique. In histopathological evaluation, the presence of endometrial glands and stroma within the myometrium confirms adenomyosis. However, the diagnostic accuracy of myometrial biopsy depends on the sampling depth, and superficial biopsy specimens may fail to detect deeper lesions, thereby reducing sensitivity.[93]

Beyond diagnosis, hysteroscopy also offers therapeutic options for managing adenomyosis-related symptoms, particularly in patients with HMB, infertility, or recurrent pregnancy loss. One of the primary hysteroscopic treatments is endometrial ablation, a procedure that destroys the endometrial lining to reduce excessive menstrual bleeding and pain.[94] This is particularly beneficial for patients with diffuse adenomyosis who do not wish to conceive. While endometrial ablation can significantly reduce menstrual blood loss and pain, it does not eliminate adenomyotic lesions, and recurrence is common over time.[95] Moreover, this procedure compromises fertility, making it unsuitable for women desiring future pregnancies.

For patients with focal or cystic adenomyosis, hysteroscopic myometrial reduction, also known as hysteroscopic adenomyomectomy, offers an alternative treatment approach in experienced hands.[96] This procedure involves resecting adenomyotic nodules within the inner myometrium to alleviate symptoms while preserving uterine integrity. However, hysteroscopic adenomyomectomy presents significant technical challenges, as it requires precise resection to avoid excessive myometrial damage, which is particularly critical in patients planning for future pregnancies. Another hysteroscopic intervention, the resection of submucosal adenomyotic lesions, can be performed when adenomyotic nodules protrude into the uterine cavity.[97] This technique is particularly beneficial for patients with focal submucosal adenomyosis, as it helps improve menstrual symptoms and may enhance fertility outcomes. The procedure involves the use of a resectoscope to excise adenomyotic tissue while ensuring

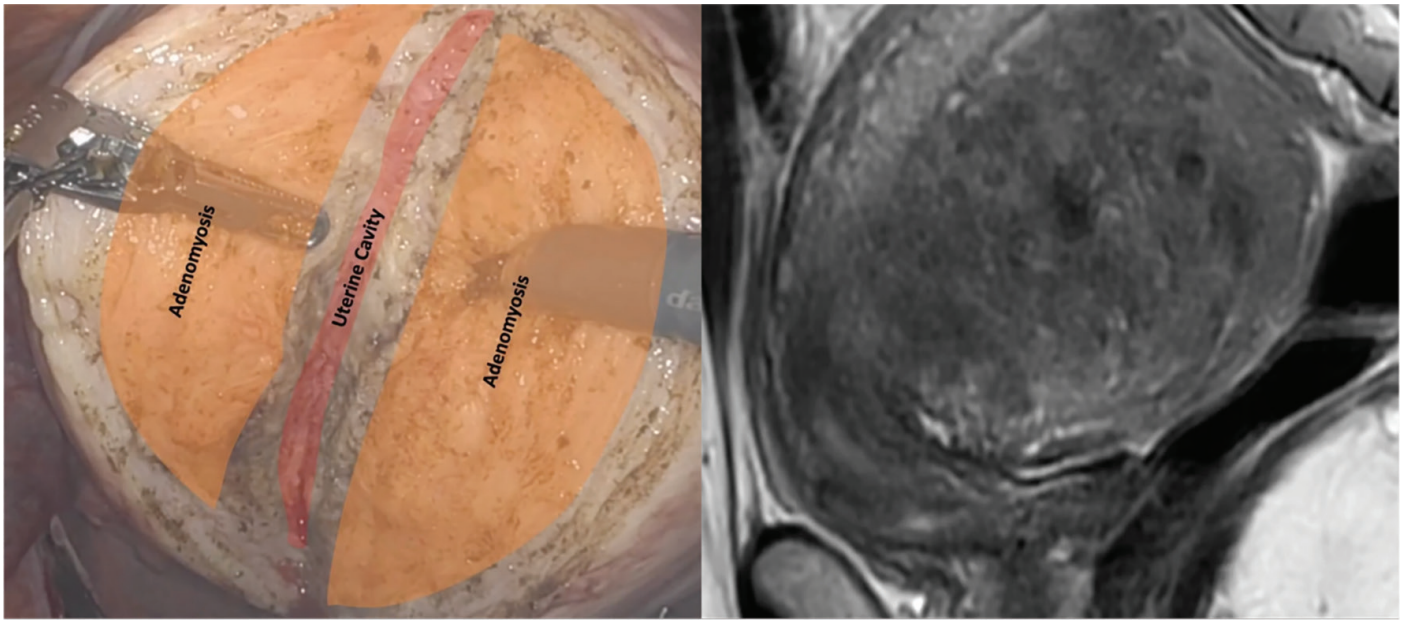

Figure 5. Anatomical and radiological correlation in adenomyosis. Left: Laparoscopic view after myometrial incision showing diffuse adenomyotic infiltration within the myometrium (highlighted areas) surrounding the uterine cavity. Right: Sagittal T2-weighted magnetic resonance imaging (MRI) demonstrating junctional-zone thickening and heterogeneous myometrial signal consistent with diffuse adenomyosis. This figure illustrates the concordance between intraoperative findings and MRI features in the diagnosis of adenomyosis.

that excessive penetration into the myometrium is avoided to prevent uterine rupture or scarring.

Hysteroscopy has demonstrated a significant impact on fertility outcomes in patients with adenomyosis by improving endometrial receptivity and enhancing implantation potential.[98] Several mechanisms contribute to these benefits. The removal of obstructive submucosal adenomyotic nodules reduces endometrial distortion, thereby improving embryo implantation rates. Hysteroscopic ablation and resection techniques may restore endometrial wave patterns, optimising the uterine environment for conception. Additionally, by removing abnormal endometrial tissue, hysteroscopy may help by reducing inflammation and hypervascularisation, factors that can negatively affect implantation. Some studies suggest that hysteroscopic pre-treatment before IVF may improve implantation rates and pregnancy outcomes in women with adenomyosis by creating a more favourable endometrial environment.[98] However, it is crucial to carefully select the appropriate intervention based on the severity and type of adenomyosis. In women with diffuse adenomyosis, hysteroscopy alone may not be sufficient, and additional medical or surgical treatments may be required to improve reproductive outcomes.

Despite its advantages, hysteroscopy has several limitations in the management of adenomyosis. One of the primary challenges is its limited depth of penetration, as it primarily evaluates the endometrial surface and submucosal layer but cannot fully assess deep myometrial involvement. This restriction makes hysteroscopy an inadequate standalone diagnostic tool for adenomyosis that extends beyond the endometrial-myometrial junction.[99] Another limitation is the risk of uterine perforation, particularly in cases of diffuse adenomyosis where excessive myometrial resection may weaken uterine integrity, increasing the likelihood of uterine rupture in future pregnancies. Additionally, symptom relief achieved through hysteroscopy may be temporary, as adenomyotic tissue can regrow over time, particularly in cases where diffuse disease is present. This high recurrence rate necessitates long-term follow-up and, in some cases, complementary medical therapy to sustain symptom control. Furthermore, certain hysteroscopic procedures, such as endometrial ablation, are not suitable for women who wish to conceive, as they may compromise endometrial function and limit fertility potential.[94]

Hysteroscopy remains a valuable tool in the diagnosis and management of adenomyosis, offering both diagnostic precision and therapeutic potential. It allows for direct visualisation of endometrial abnormalities and facilitates targeted interventions for symptom relief. While hysteroscopy is not the primary modality for diagnosing deep adenomyosis, it is highly effective in detecting submucosal lesions and guiding biopsies for histological confirmation. In terms of treatment, hysteroscopic resection and reduction provide fertility-preserving options for women with focal adenomyosis. However, given its limited penetration into the deep myometrium, hysteroscopy is most effective when combined with other diagnostic and therapeutic approaches, particularly in patients with extensive adenomyosis who may require multimodal management. By integrating hysteroscopy with medical therapy and imaging-based diagnostic tools, clinicians can optimise treatment strategies and improve outcomes for women affected by adenomyosis.

Discussion

A Way Forward

We acknowledge the limitations of this consensus document and the shortfall of a review without meta-analysis. Nevertheless, a common definition of adenomyosis is needed to harmonise and interpret ongoing and future research of this condition. Also, a stricter estimate of the prevalence of adenomyosis offers the added benefit of avoiding over diagnosis and thereby improved management.

Classically, adenomyosis was associated with symptoms–dysfunctional/heavy uterine bleeding–and an enlarged uterus.[8,100-102] Typically, the diagnosis was made on hysterectomy specimens performed for these symptoms.[103] In these data, the factor most commonly associated with adenomyosis was multiparity.[104]

The interest for diagnosing adenomyosis in case of infertility is recent and linked to the availability of non-invasive diagnostic means.[102,105,106] Hence, less data is available. In a recent systematic review and meta-analysis reviewing 21 longitudinal studies evaluating 25,600 women, Mishra et al.[31] reported an overall pooled prevalence of isolated adenomyosis of 10% (95% confidence interval, 6-15%). Unfortunately, this study failed to sort the incidence of symptomatic and asymptomatic adenomyosis. This was also a shortcoming of an extensive review on adenomyosis.[107]

The issue of whether image-diagnosed adenomyosis is symptomatic or not is important when it comes to analysing its impact on ART outcome. In a recent systematic review and meta-analysis, Wang et al.[108] reported that asymptomatic adenomyosis–routinely diagnosed in ART patients–bore no negative consequences on outcome. On the contrary, symptomatic adenomyosis had negative consequences on ART outcome.[108] Hence, all reports on the negative consequences of adenomyosis on ART outcome have to be pondered when asymptomatic and symptomatic cases are not sorted.[109]

The putative mechanism(s) through which adenomyosis and notably, the asymptomatic forms diagnosed on ultrasound and MRI interfere with fertility remain(s) to be elucidated.[110,111] We know from the recent work Bulun et al. that adenomyosis and endometriosis share their origin in similar mutations–including of KRAS type–of present in the eutopic endometrium.[112] We however ignore whether asymptomatic adenomyosis diagnosed on ultrasound and/or MRI impact on natural fecundity.[4,113]

Other mechanisms by which adenomyosis alters fertility include inflammatory processes altering the anatomical structure of the tube[114] and dyspareunia interfering with sex life.[115] These latter factors–also bypassed by ART–should not be overlooked, however.

Conclusion

Adenomyosis is a complex and heterogeneous gynaecological disorder with significant implications for menstrual health, fertility, and overall quality of life. Advances in imaging techniques have improved early diagnosis, allowing for better characterisation and individualised treatment approaches. The impact of adenomyosis on fertility is increasingly recognised, with evidence supporting its role in implantation failure, recurrent pregnancy loss, and reduced ART success rates. While medical therapies such as hormonal modulation and anti-inflammatory agents provide symptomatic relief, their long-term efficacy in preserving fertility remains limited. Conservative surgical interventions, including adenomyomectomy and minimally invasive procedures, offer potential benefits but require careful patient selection due to risks such as recurrence and uterine rupture. Despite progress in understanding the disease, further research is needed to elucidate its pathophysiology, refine diagnostic criteria, and develop targeted therapeutic strategies. A multidisciplinary approach integrating gynaecologists, reproductive specialists, and radiologists is essential to optimise patient outcomes and improve fertility management in women affected by adenomyosis.

Acknowledgements: None.

Contributors: All the authors wrote the article and validated it.

Funding: The authors declared that this study received no financial support.

Competing interests: Maribel Acién, Baris Ata, Grigoris Grimbizis, Ertan Saridogan, MD, serve as Associate Editor for Facts, Views and Vision in ObGyn. Gaby Moawad, Luis Alonso, Attilio Di Spiezio Sardo, Caterina Exacoustos, Hélder Ferreira, Mohamed Mabrouk, MD, are members of the ESGE Editorial Board of the Facts, Views and Vision in ObGyn. They had no involvement in the peer-review of this article and had no access to information regarding its peer-review. The other authors declared that there is no conflict of interest.

Ethical approval: Not required.

Informed consent: Not required.

Data sharing: Not required.

Transparency: Not required.

References

1. Moawad G, Fruscalzo A, Youssef Y, Kheil M, Tawil T, Nehme J, et al. Adenomyosis: an updated review on diagnosis and classification. J Clin Med. 2023;12:4828.
2. Moawad G, Kheil MH, Ayoubi JM, Klebanoff JS, Rahman S, Sharara FI. Adenomyosis and infertility. J Assist Reprod Genet. 2022;39:1027-31.
3. de Ziegler D, Ayoubi JM. Endometriosis and adenomyosis in the crosshair: variants of one disorder or fortuitous coincidence. Fertil Steril. 2023;119:709-10.
4. Harada T, Khine YM, Kaponis A, Nikellis T, Decavalas G, Taniguchi F. The impact of adenomyosis on women's fertility. Obstet Gynecol Surv. 2016;71:557-68.
5. Sharara FI, Kheil MH, Feki A, Rahman S, Klebanoff JS, Ayoubi JM, et al. Current and prospective treatment of adenomyosis. J Clin Med. 2021;10:3410.
6. Moawad G, Feki A, Ayoubi JM, Naem A, Youssef Y. Tips and tricks for robotic management of diffuse adenomyosis. Fertil Steril. 2025;123:537-9.
7. Youssef Y, Alkatout I, Ayoubi JM, Feki A, Moawad G. Robotic-assisted excision of diffuse adenomyosis. Facts Views Vis Obgyn. 2024;16:365-8.
8. Zhai J, Vannuccini S, Petraglia F, Giudice LC. Adenomyosis: mechanisms and pathogenesis. Semin Reprod Med. 2020;38:129-43.
9. Guo SW. The pathogenesis of adenomyosis vis-à-vis endometriosis. J Clin Med. 2020;9:485.

10. Vercellini P, Piccini M, Caprara F, Cetera GE, Viganò P, Somigliana E. Potential anatomical determinants of retrograde menstruation: a comprehensive narrative review. Reprod Biomed Online. 2024;49:104345.
11. Sztachelska M, Ponikwicka-Tyszko D, Martínez-Rodrigo L, Bernaczyk P, Palak E, Półchłopek W, et al. Functional implications of estrogen and progesterone receptors expression in adenomyosis, potential targets for endocrinological therapy. J Clin Med. 2022;11:4407.
12. Vannuccini S, Tosti C, Carmona F, Huang SJ, Chapron C, Guo SW, et al. Pathogenesis of adenomyosis: an update on molecular mechanisms. Reprod Biomed Online. 2017;35:592-601.
13. Huang BS, Tsai HW, Wang PH, Twu NF, Yen MS, Chen YJ. Epithelial-to-mesenchymal transition in the development of adenomyosis. Gynecol Minim Invasive Ther. 2015;4:55-60.
14. Herington JL, Bruner-Tran KL, Lucas JA, Osteen KG. Immune interactions in endometriosis. Expert Rev Clin Immunol. 2011;7:611-26.
15. Middelkoop MA, Don EE, Hehenkamp WJK, Polman NJ, Griffioen AW, Huirne JAF. Angiogenesis in abnormal uterine bleeding: a narrative review. Hum Reprod Update. 2023;29:457-85.
16. Stratopoulou CA, Donnez J, Dolmans MM. Conservative management of uterine adenomyosis: medical vs. surgical approach. J Clin Med. 2021;10:4878.
17. Tsikouras P, Kritsotaki N, Nikolettos K, Kotanidou S, Oikonomou E, Bothou A, et al. The impact of adenomyosis on pregnancy. Biomedicines. 2024;12:1925.
18. Gordts S, Grimbizis G, Campo R. Symptoms and classification of uterine adenomyosis, including the place of hysteroscopy in diagnosis. Fertil Steril. 2018;109:380-8.e1.
19. Vannuccini S, Clifton VL, Fraser IS, Taylor HS, Critchley H, Giudice LC, et al. Infertility and reproductive disorders: impact of hormonal and inflammatory mechanisms on pregnancy outcome. Hum Reprod Update. 2016;22:104-15.
20. García-Solares J, Donnez J, Donnez O, Dolmans MM. Pathogenesis of uterine adenomyosis: invagination or metaplasia? Fertil Steril. 2018;109:371-9.
21. Pirtea P, de Ziegler D, Ayoubi JM. Endometrial receptivity in adenomyosis and/or endometriosis. Fertil Steril. 2023;119:741-5.
22. Leyendecker G, Wildt L, Mall G. The pathophysiology of endometriosis and adenomyosis: tissue injury and repair. Arch Gynecol Obstet. 2009;280:529-38.
23. Marquardt RM, Kim TH, Shin JH, Jeong JW. Progesterone and estrogen signaling in the endometrium: what goes wrong in endometriosis? Int J Mol Sci. 2019;20:3822.
24. Scutiero G, Iannone P, Bernardi G, Bonaccorsi G, Spadaro S, Volta CA, et al. Oxidative stress and endometriosis: a systematic review of the literature. Oxid Med Cell Longev. 2017;2017:7265238.
25. Benagiano G, Brosens I, Habiba M. Structural and molecular features of the endomyometrium in endometriosis and adenomyosis. Hum Reprod Update. 2014;20:386-402.
26. Meenakshi M, McCluggage WG. Vascular involvement in adenomyosis: report of a large series of a common phenomenon with observations on the pathogenesis of adenomyosis. Int J Gynecol Pathol. 2010;29:117-21.
27. Bonavina G, Taylor HS. Endometriosis-associated infertility: from pathophysiology to tailored treatment. Front Endocrinol (Lausanne). 2022;13:1020827.
28. Zhang S, Lin H, Kong S, Wang S, Wang H, Wang H, et al. Physiological and molecular determinants of embryo implantation. Mol Aspects Med. 2013;34:939-80.
29. Lin PW, Chern CU, Li CJ, Lin PH, Tsui KH, Lin LT. Improvement of early miscarriage rates in women with adenomyosis via oxytocin receptor antagonist during frozen embryo transfer-a propensity score-matched study. Reprod Biol Endocrinol. 2024;22:79.
30. Mandelbaum RS, Melville SJF, Violette CJ, Guner JZ, Doody KA, Matsuzaki S, et al. The association between uterine adenomyosis and adverse obstetric outcomes: a propensity score-matched analysis. Acta Obstet Gynecol Scand. 2023;102:833-42.
31. Mishra I, Melo P, Easter C, Sephton V, Dhillon-Smith R, Coomarasamy A. Prevalence of adenomyosis in women with subfertility: systematic review and meta-analysis. Ultrasound Obstet Gynecol. 2023;62:23-41.
32. Pados G, Gordts S, Sorrentino F, Nisolle M, Nappi L, Daniilidis A. Adenomyosis and Infertility: a literature review. Medicina (Kaunas). 2023;59:1551.
33. Horton J, Sterrenburg M, Lane S, Maheshwari A, Li TC, Cheong Y. Reproductive, obstetric, and perinatal outcomes of women with adenomyosis and endometriosis: a systematic review and meta-analysis. Hum Reprod Update. 2019;25:592-632.
34. Yamaguchi A, Kyozuka H, Fujimori K, Hosoya M, Yasumura S, Yokoyama T, et al. Risk of preterm birth, low birthweight and small-for-gestational-age infants in pregnancies with adenomyosis: a cohort study of the Japan Environment and Children's Study. Acta Obstet Gynecol Scand. 2019;98:359-64.
35. Khan KN, Fujishita A, Mori T. Pathogenesis of human adenomyosis: current understanding and its association with infertility. J Clin Med. 2022;11:4057.
36. Szubert M, Koziróg E, Olszak O, Krygier-Kurz K, Kazmierczak J, Wilczynski J. Adenomyosis and infertility-review of medical and surgical approaches. Int J Environ Res Public Health. 2021;18:1235.
37. Latif S, Saeed SU, Hu Y, De Braud L, Yasmin E, Saridogan E, et al. Quantitative analysis of uterine peristalsis in women with adenomyosis using optical flow for motion quantification. Reprod Biomed Online. 2026;52:105073.
38. Nirgianakis K, Kalaitzopoulos DR, Schwartz ASK, Spaanderman M, Kramer BW, Mueller MD, et al. Fertility, pregnancy and neonatal outcomes of patients with adenomyosis: a systematic review and meta-analysis. Reprod Biomed Online. 2021;42:185-206.
39. Martínez-Conejero JA, Morgan M, Montesinos M, Fortuño S, Meseguer M, Simón C, et al. Adenomyosis does not affect implantation, but is associated with miscarriage in patients undergoing oocyte donation. Fertil Steril. 2011;96:943-50.
40. Kim H, Frisch EH, Falcone T. From diagnosis to fertility: optimizing treatment of adenomyosis for reproductive health. J Clin Med. 2024;13:4926.
41. Chen M, Luo L, Wang Q, Gao J, Chen Y, Zhang Y, et al. Impact of gonadotropin-releasing hormone agonist pre-treatment on the cumulative live birth rate in infertile women with adenomyosis treated with IVF/ICSI: a retrospective cohort study. Front Endocrinol (Lausanne). 2020;11:318.
42. Moawad G, Youssef Y, Fruscalzo A, Faysal H, Merida M, Pirtea P, et al. The impact of conservative surgical treatment of adenomyosis on fertility and perinatal outcomes. J Clin Med. 2024;13:2531.
43. Dueholm M. Uterine adenomyosis and infertility, review of reproductive outcome after in vitro fertilization and surgery. Acta Obstet Gynecol Scand. 2017;96:715-26.

44. Gordts S, Koninckx P, Brosens I. Pathogenesis of deep endometriosis. Fertil Steril. 2017;108:872-85.e1.

45. Vannuccini S, Petraglia F. Recent advances in understanding and managing adenomyosis. F1000Res. 2019;8:F1000 Faculty Rev-283.

46. Kishi Y, Yabuta M, Taniguchi F. Who will benefit from uterus-sparing surgery in adenomyosis-associated subfertility? Fertil Steril. 2014;102:802-7.e1.

47. Habiba M, Gordts S, Bazot M, Brosens I, Benagiano G. Exploring the challenges for a new classification of adenomyosis. Reprod Biomed Online. 2020;40:569-81.

48. Takeuchi M, Matsuzaki K, Harada M. Evaluating myometrial invasion in endometrial cancer: comparison of reduced field-of-view diffusion-weighted imaging and dynamic contrast-enhanced MR imaging. Magn Reson Med Sci. 2018;17:28-34.

49. Van den Bosch T, de Bruijn AM, de Leeuw RA, Dueholm M, Exacoustos C, Valentin L, et al. Sonographic classification and reporting system for diagnosing adenomyosis. Ultrasound Obstet Gynecol. 2019;53:576-82.

50. Bazot M, Daraï E. Role of transvaginal sonography and magnetic resonance imaging in the diagnosis of uterine adenomyosis. Fertil Steril. 2018;109:389-97.

51. Benagiano G, Habiba M, Brosens I. The pathophysiology of uterine adenomyosis: an update. Fertil Steril. 2012;98:572-9.

52. Harmsen MJ, Van den Bosch T, de Leeuw RA, Dueholm M, Exacoustos C, Valentin L, et al. Consensus on revised definitions of Morphological Uterus Sonographic Assessment (MUSA) features of adenomyosis: results of modified Delphi procedure. Ultrasound Obstet Gynecol. 2022;60:118-31.

53. Van den Bosch T, Dueholm M, Leone FP, Valentin L, Rasmussen CK, Votino A, et al. Terms, definitions and measurements to describe sonographic features of myometrium and uterine masses: a consensus opinion from the Morphological Uterus Sonographic Assessment (MUSA) group. Ultrasound Obstet Gynecol. 2015;46:284-98.

54. Grimbizis GF, Mikos T, Tarlatzis B. Uterus-sparing operative treatment for adenomyosis. Fertil Steril. 2014;101:472-87.

55. Kepkep K, Tuncay YA, Göynümer G, Tutal E. Transvaginal sonography in the diagnosis of adenomyosis: which findings are most accurate? Ultrasound Obstet Gynecol. 2007;30:341-5.

56. Biasioli A, Degano M, Restaino S, Bagolin M, Moro F, Ciccarone F, et al. Innovative ultrasound criteria for the diagnosis of adenomyosis and correlation with symptoms: a retrospective re-evaluation. Biomedicines. 2024;12:463.

57. Moawad G, Youssef Y, Fruscalzo A, Khedhri S, Faysal H, Pirtea P, et al. Effects of pretreatment strategies on fertility outcomes in patients with adenomyosis. Front Reprod Health. 2024;6:1484202.

58. Vannuccini S, Clemenza S, Rossi M, Petraglia F. Hormonal treatments for endometriosis: the endocrine background. Rev Endocr Metab Disord. 2022;23:333-55.

59. Wang Y, Nisenblat V, Tao L, Zhang X, Li H, Ma C. Combined estrogen-progestin pill is a safe and effective option for endometrial hyperplasia without atypia: a three-year single center experience. J Gynecol Oncol. 2019;30:e49.

60. Abbas AM, Samy A, Atwa K, Ghoneim HM, Lotfy M, Saber Mohammed H, et al. The role of levonorgestrel intra-uterine system in the management of adenomyosis: a systematic review and meta-analysis of prospective studies. Acta Obstet Gynecol Scand. 2020;99:571-81.

61. Ota I, Taniguchi F, Ota Y, Nagata H, Wada I, Nakaso T, et al. A controlled clinical trial comparing potent progestins, LNG-IUS and dienogest, for the treatment of women with adenomyosis. Reprod Med Biol. 2021;20:427-34.

62. Osuga Y, Fujimoto-Okabe H, Hagino A. Evaluation of the efficacy and safety of dienogest in the treatment of painful symptoms in patients with adenomyosis: a randomized, double-blind, multicenter, placebo-controlled study. Fertil Steril. 2017;108:673-8.

63. Hassanin AI, Youssef AA, Yousef AM, Ali MK. Comparison of dienogest versus combined oral contraceptive pills in the treatment of women with adenomyosis: a randomized clinical trial. Int J Gynaecol Obstet. 2021;154:263-9.

64. Del Forno S, Orsini B, Verrelli L, Caroli M, Aru AC, Lenzi J, et al. Dienogest alone or dienogest combined with estrogens in the treatment of ovarian endometriomas, that is the question. A retrospective cohort study. Arch Gynecol Obstet. 2023;308:1341-9.

65. Kim SA, Um MJ, Kim HK, Kim SJ, Moon SJ, Jung H. Study of dienogest for dysmenorrhea and pelvic pain associated with endometriosis. Obstet Gynecol Sci. 2016;59:506-11. Erratum in: Obstet Gynecol Sci. 2017;60:322.

66. Magon N. Gonadotropin releasing hormone agonists: expanding vistas. Indian J Endocrinol Metab. 2011;15:261-7.

67. Di Spiezio Sardo A, Ciccarone F, Muzii L, Scambia G, Vignali M. Use of oral GnRH antagonists combined therapy in the management of symptomatic uterine fibroids. Facts Views Vis Obgyn. 2023;15:29-33.

68. Ali M, Raslan M, Ciebiera M, Zaręba K, Al-Hendy A. Current approaches to overcome the side effects of GnRH analogs in the treatment of patients with uterine fibroids. Expert Opin Drug Saf. 2022;21:477-86.

69. Viviano M, Benagiano G, Guo SW, Pluchino N. Why do oestrogens matter: systematic review and meta-analysis assessing GnRH antagonists, considering add-back therapy, for endometriosis-associated pain. Reprod Biomed Online. 2024;49(4).

70. Brown J, Crawford TJ, Allen C, Hopewell S, Prentice A. Nonsteroidal anti-inflammatory drugs for pain in women with endometriosis. Cochrane Database Syst Rev. 2017;1:CD004753.

71. Etrusco A, Barra F, Chiantera V, Ferrero S, Bogliolo S, Evangelisti G, et al. Current medical therapy for adenomyosis: from bench to bedside. Drugs. 2023;83:1595-611.

72. Maybin JA, Critchley HO. Medical management of heavy menstrual bleeding. Womens Health (Lond). 2016;12:27-34.

73. Islam MS, Afrin S, Jones SI, Segars J. Selective progesterone receptor modulators-mechanisms and therapeutic utility. Endocr Rev. 2020;41:bnaa012.

74. Attar E, Bulun SE. Aromatase inhibitors: the next generation of therapeutics for endometriosis? Fertil Steril. 2006;85:1307-18.

75. Che X, Wang J, Sun W, He J, Wang Q, Zhu D, et al. Effect of mifepristone vs placebo for treatment of adenomyosis with pain symptoms: a randomized clinical trial. JAMA Netw Open. 2023;6:e2317860.

76. Creinin MD, Barnhart KT, Gawron LM, Eisenberg D, Mabey RG Jr, Jensen JT. Heavy menstrual bleeding treatment with a levonorgestrel 52-mg intrauterine device. Obstet Gynecol. 2023;141:971-8.

77. Zhang W, Han B, Ma C, Qiao J. Effect of GnRH-a pretreatment before frozen-thawed embryo transfer on pregnancy outcome of adenomyosis-associated infertile patients with 56 cm^3 ≤ uterine volume ≤100 cm^3. Ann Transl Med. 2022;10:509.

78. Lawrie TA, Liu H, Lu D, Dowswell T, Song H, Wang L, et al. Robot-assisted surgery in gynaecology. Cochrane Database Syst Rev. 2019;4:CD011422.

79. Di Spiezio Sardo A, Calagna G, Santangelo F, Zizolfi B, Tanos V, Perino A, et al. The Role of hysteroscopy in the diagnosis and treatment of adenomyosis. Biomed Res Int. 2017;2017:2518396.

80. Kim JK, Shin CS, Ko YB, Nam SY, Yim HS, Lee KH. Laparoscopic assisted adenomyomectomy using double flap method. Obstet Gynecol Sci. 2014;57:128-35.

81. Englander MJ. Uterine artery embolization for the treatment of adenomyosis. Semin Intervent Radiol. 2008;25:387-93.

82. Yan X, Zhou L, He G, Liu X. Pregnancy rate and outcomes after uterine artery embolization for women: a systematic review and meta-analysis with trial sequential analysis. Front Med (Lausanne). 2023;10:1283279.

83. Zhang L, Rao F, Setzen R. High intensity focused ultrasound for the treatment of adenomyosis: selection criteria, efficacy, safety and fertility. Acta Obstet Gynecol Scand. 2017;96:707-14.

84. Liu L, Wang T, Lei B. High-intensity focused ultrasound (HIFU) ablation versus surgical interventions for the treatment of symptomatic uterine fibroids: a meta-analysis. Eur Radiol. 2022;32:1195-204.

85. Piriyev E, Dieter A, Schiermeier S, Renner S, Römer T. Could transcervical radiofrequency ablation become a therapy option for focal adenomyosis? In Vivo. 2025;39:961-8.

86. Fayyad A, Said M, Hasan M, Saleh M. Total laparoscopic hysterectomy and bilateral salpingo-oophrectomy for stage 1 endometrial carcinoma under regional anaesthesia. Gynecol Oncol Rep. 2023;48:101222.

87. Osada H. Uterine adenomyosis and adenomyoma: the surgical approach. Fertil Steril. 2018;109:406-17.

88. Sayama S, Iriyama T, Hashimoto A, Suzuki K, Ariyoshi Y, Yano E, et al. Possible risks and benefits of adenomyomectomy on pregnancy outcomes: a retrospective analysis. AJOG Glob Rep. 2023;3:100265.

89. Yu W, Liu G, Liu C, Zhang Z. Recurrence-associated factors of laparoscopic adenomyomectomy for severely symptomatic adenomyoma. Oncol Lett. 2018;16:3430-8.

90. Madueke-Laveaux OS, Elsharoud A, Al-Hendy A. What we know about the long-term risks of hysterectomy for benign indication-a systematic review. J Clin Med. 2021;10:5335.

91. Molinas CR, Campo R. Office hysteroscopy and adenomyosis. Best Pract Res Clin Obstet Gynaecol. 2006;20:557-67.

92. Gkrozou F, Vatopoulou A, Skentou C, Paschopoulos M. Diagnosis and treatment of adenomyosis with office hysteroscopy-a narrative review of literature. Diagnostics (Basel). 2023;13:2182.

93. Dijkhuizen FP, Mol BW, Brölmann HA, Heintz AP. The accuracy of endometrial sampling in the diagnosis of patients with endometrial carcinoma and hyperplasia: a meta-analysis. Cancer. 2000;89:1765-72.

94. Vitale SG, Della Corte L, Ciebiera M, Carugno J, Riemma G, Lasmar RB, et al. Hysteroscopic endometrial ablation: from indications to instrumentation and techniques-a call to action. Diagnostics (Basel). 2023;13:339.

95. McCausland V, McCausland A. The response of adenomyosis to endometrial ablation/resection. Hum Reprod Update. 1998;4:350-9.

96. Gordts S, Campo R, Brosens I. Hysteroscopic diagnosis and excision of myometrial cystic adenomyosis. Gynecol Surg. 2014;11:273-8.

97. Loddo A, Djokovic D, Drizi A, De Vree BP, Sedrati A, van Herendael BJ. Hysteroscopic myomectomy: the guidelines of the International Society for Gynecologic Endoscopy (ISGE). Eur J Obstet Gynecol Reprod Biol. 2022;268:121-8.

98. Vitale SG, Angioni S, Parry JP, Di Spiezio Sardo A, Haimovich S, Carugno J, et al. Efficacy of hysteroscopy in improving fertility outcomes in women undergoing assisted reproductive technique: a systematic review and meta-analysis of randomized controlled trials. Gynecol Obstet Invest. 2023;88:336-48.

99. Naftalin J, Jurkovic D. The endometrial-myometrial junction: a fresh look at a busy crossing. Ultrasound Obstet Gynecol. 2009;34:1-11.

100. Bourdon M, Maignien C, Giraudet G, Estrade JP, Indersie E, Solignac C, et al. Investigating the medical journey of endometriosis-affected women: results from a cross-sectional web-based survey (EndoVie) on 1,557 French women. J Gynecol Obstet Hum Reprod. 2024;53:102708.

101. Bourdon M, Santulli P, Marcellin L, Maignien C, Maitrot-Mantelet L, Bordonne C, et al. Adenomyosis: an update regarding its diagnosis and clinical features. J Gynecol Obstet Hum Reprod. 2021;50:102228.

102. Schrager S, Yogendran L, Marquez CM, Sadowski EA. Adenomyosis: diagnosis and Management. Am Fam Physician. 2022;105:33-8.

103. Maheshwari A, Gurunath S, Fatima F, Bhattacharya S. Adenomyosis and subfertility: a systematic review of prevalence, diagnosis, treatment and fertility outcomes. Hum Reprod Update. 2012;18:374-92.

104. Ferenczy A. Pathophysiology of adenomyosis. Hum Reprod Update. 1998;4:312-22.

105. Exacoustos C, Malzoni M, Di Giovanni A, Lazzeri L, Tosti C, Petraglia F, et al. Ultrasound mapping system for the surgical management of deep infiltrating endometriosis. Fertil Steril. 2014;102:143-50.e2.

106. Van den Bosch T, Van Schoubroeck D. Ultrasound diagnosis of endometriosis and adenomyosis: state of the art. Best Pract Res Clin Obstet Gynaecol. 2018;51:16-24.

107. Chapron C, Vannuccini S, Santulli P, Abrão MS, Carmona F, Fraser IS, et al. Diagnosing adenomyosis: an integrated clinical and imaging approach. Hum Reprod Update. 2020;26:392-411.

108. Wang XL, Xu ZW, Huang YY, Lin S, Lyu GR. Different subtypes of ultrasound-diagnosed adenomyosis and in vitro fertilization outcomes: a systematic review and meta-analysis. Acta Obstet Gynecol Scand. 2023;102:657-68.

109. Brulport A, Bourdon M, Vaiman D, Drouet C, Pocate-Cheriet K, Bouzid K, et al. An integrated multi-tissue approach for endometriosis candidate biomarkers: a systematic review. Reprod Biol Endocrinol. 2024;22:21.

110. Sunkara SK, Khan KS. Adenomyosis and female fertility: a critical review of the evidence. J Obstet Gynaecol. 2012;32:113-6.

111. Campo S, Campo V, Benagiano G. Infertility and adenomyosis. Obstet Gynecol Int. 2012;2012:786132.

112. Bulun SE, Yildiz S, Adli M, Chakravarti D, Parker JB, Milad M, et al. Endometriosis and adenomyosis: shared pathophysiology. Fertil Steril. 2023;119:746-50.

113. Abbott JA. Adenomyosis and Abnormal Uterine Bleeding (AUB-A)-Pathogenesis, diagnosis, and management. Best Pract Res Clin Obstet Gynaecol. 2017;40:68-81.

114. Approbato FC, Approbato MS, Rezende DF, Silva TM, Lima YAR, Benetti BBDC. Endometriosis III and IV as a risk factor for tubal obstruction in infertile women. JBRA Assist Reprod. 2019;23:333-5.

115. van Poll M, van Barneveld E, Aerts L, Maas JWM, Lim AC, de Greef BTA, et al. Endometriosis and sexual quality of life. Sex Med. 2020;8:532-44.