FACTS, VIEWS & VISION
Journal of the European Society for Gynaecological Endoscopy (ESGE)
in ObGyn

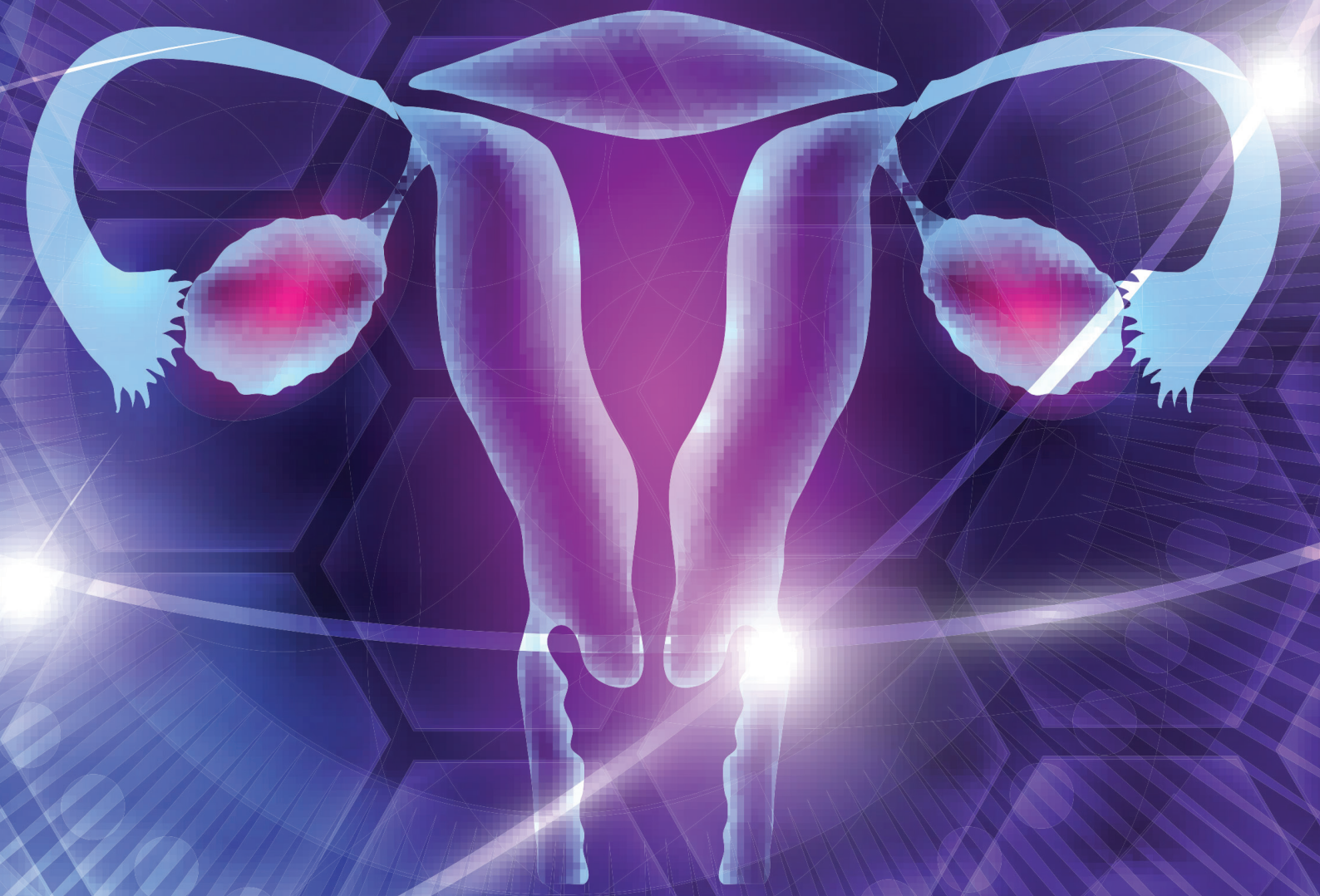

UTERINE SPARING MANAGEMENT OF AUB/HMB IN OUTPATIENTS SETTING

OCTOBER 2023

FACTS, VIEWS & VISION
in ObGyn

MONOGRAPH 2023

Uterine Sparing Management of AUB/HMB in the Outpatients Setting

FOREWORD

Uterine sparing management of abnormal uterine and heavy menstrual bleeding in the outpatients setting
E. Saridogan 1

REVIEWS

AUB – symptomatology, clinical impact and diagnosis
A. Gallo, A. Di Spiezio Sardo 3

An overview of International AUB/HMB Guidelines
E. Saridogan 11

Non-surgical treatment options for HMB
M. Bongers, T. Oderkerk, M. Herman, P.M.A.J. Geomini 17

Endometrial Ablation in the Outpatient Setting
S. Martinez, A. Megia, C. Alvarez 25

Hysteroscopic removal of polyps and fibroids in the Outpatient Setting
L. Antoun, L.E. Clark, T.J. Clark 33

Hysteroscopic removal of RPOCs in the Outpatient Setting
N. Smorgick, Y. Melcer, O. Levinsohn-Tavor, S. Haimovich 51

Fluid Management for hysteroscopy
D.P. van der Ham 61

ISSN: 2032-0418

FOREWORD

Uterine sparing management of abnormal uterine and heavy menstrual bleeding in the outpatients setting

Abnormal uterine bleeding (AUB), including heavy menstrual bleeding (HMB), is one of the most common symptoms together with pelvic pain in women during their reproductive years. It results in a high number of consultations both in primary and secondary care settings.

Technological advances in the diagnosis and treatment of conditions that cause AUB and HMB have changed clinical practice in the last few decades. Concomitant developments in both hysteroscopic equipment and ultrasound technology have influenced our ability to diagnose and manage uterine pathology that cause AUB/HMB; we now approach the underlying conditions in a substantially less invasive manner. High resolution ultrasound has become very accurate in assessing the uterine wall, cavity and endometrium, hence conditions such as uterine fibroids, adenomyosis, endometrial polyps, hyperplasia/malignancy, retained products of conception and caesarean section scar defects can now be reliably detected with detailed description in experienced hands. Fibroid mapping by defining the number, location and size of fibroids has made it possible to plan appropriate treatment, including the type and place of surgery. Improved ultrasound imaging may have reduced the need for diagnostic hysteroscopy, but at the same time it may have resulted in detection of less obvious pathology which may prompt the clinician and patient to take action. As a result we may be performing more therapeutic procedures than we would have done in the past.

Improved hysteroscopic technology as a result of smaller diameter hysteroscopes, energy modalities for hysteroscopic surgery and development of hysteroscopic tissue removal systems has enabled us to perform hysteroscopy not only to diagnose but also treat uterine lesions in the outpatient setting. In addition, second generation endometrial ablation techniques have made it possible to perform highly effective treatment of HMB in the outpatient/ambulatory setting. These resulted in a substantial change in the treatment procedures we currently perform for AUB/HMB. The hysterectomy rates are declining, but at the same time the endoscopic or other minimally invasive procedures we perform are now moving from the operating theatres to the outpatient clinics.

In this special issue of Facts, Views and Vision we have a complete package that describes approaches to diagnose and treat AUB and HMB in the outpatient setting. All articles have been written by internationally renowned experts/teams who not only contributed to the global literature in this field, but at the same time have a very much hands-on practical experience. Therefore, the articles give not only the most up-to-date information on the subject, but provide practical information to the reader. I am confident that the clinicians, patients and manufacturers will find this issue most useful.

Ertan Saridogan

Professor of Gynaecological Surgery,
Elizabeth Garrett Anderson Institute for Women's Health, University College London.

Consultant in Reproductive Medicine and Minimal Access Surgery,
Women's Health Division, University College London Hospital, 250 Euston Road, London NW1 2PG, United Kingdom.

Review

Abnormal uterine bleeding: symptomatology, clinical impact and diagnosis*

A. Gallo[1], A. Di Spiezio Sardo[1]

[1]*Department of Public Health, University of Naples "Federico II", Naples, 80131, Italy.*
This article was not peer reviewed by Facts, Views and Vision. The lead author was commissioned by Hologic.

Correspondence at: Attilio Di Spiezio Sardo, Department of Public Health, University of Naples "Federico II", Naples, 80131, Italy. E-mail: attiliodispiezio@libero.it. Phone: +393397720932.

Abstract

Abnormal uterine bleeding (AUB) is one of the most common gynaecological disorders in women of all age groups, it affects quality of life (QoL) and carries high direct and indirect socioeconomic costs. The present article aims to summarise the different aetiologies of AUB, using the unambiguous terminology and systematic approach provided by the International Federation of Gynecology and Obstetrics (FIGO) PALM-COEIN classification system with its periodic evolutions; the objective is also to evaluate the clinical impact and the most accurate diagnostic management, due to continuous improvements in imaging and outpatient hysteroscopy in order to improve patient care and reduce healthcare costs.

Keywords: **Abnormal uterine bleeding, heavy menstrual bleeding, outpatient hysteroscopy, healthcare, quality of life.**

Introduction

Abnormal uterine bleeding (AUB) is one of the most common gynaecological disorders in women of all age groups, and accounts for approximately 400,000 hospital admissions (Finco et al., 2015). It is estimated that up to one-third of women will experience AUB in their lifetime, with greater frequency at the time of menarche and perimenopause (Davis and Sparzak, 2023). The condition describes irregularities in the menstrual cycle involving frequency, regularity, duration, and volume of flow outside of pregnancy, and is generally not life threatening but is important as it directly affects quality of life (QoL) and entails high socioeconomic costs.

Management of AUB in the past has been hindered by both confusing and inconsistently applied nomenclature and the lack of standardised methods for investigating and categorising the various potential aetiologies. Terms such as metrorrhagia, menorrhagia, AUB, heavy menstrual bleeding (HMB), have often been used interchangeably and confusingly, not universally defined. For HMB alone, 100 different terms were used interchangeably (Woolcock et al., 2008). The development of a universally accepted nomenclature and classification system was complicated by the fact that several potential causes may coexist in a single individual and that many definable entities that often contribute to or cause AUB are often asymptomatic.

Shedding light on the issue was the classification system approved by the Executive Committee of the International Federation of Gynecology and Obstetrics (FIGO), which in 2011 (Munro et al., 2011) proposed for the first time to use the expression AUB to describe any deviation from the normal menstruation or menstrual cycle, and older terms such as oligomenorrhoea, menorrhagia, and dysfunctional uterine bleeding have been discarded. This new classification system had 9 main categories (Figure 1), enclosed in the acronym PALM-COEIN (Polyp; Adenomyosis; Leiomyoma; Malignancy and hyperplasia; Coagulopathy; Ovulatory Dysfunction; Endometrial; Iatrogenic; Not yet classified). These categories apply to chronic, non-gestational AUB and refer to irregularities in menstrual bleeding for most of the previous 6 months (ACOG, 2013).

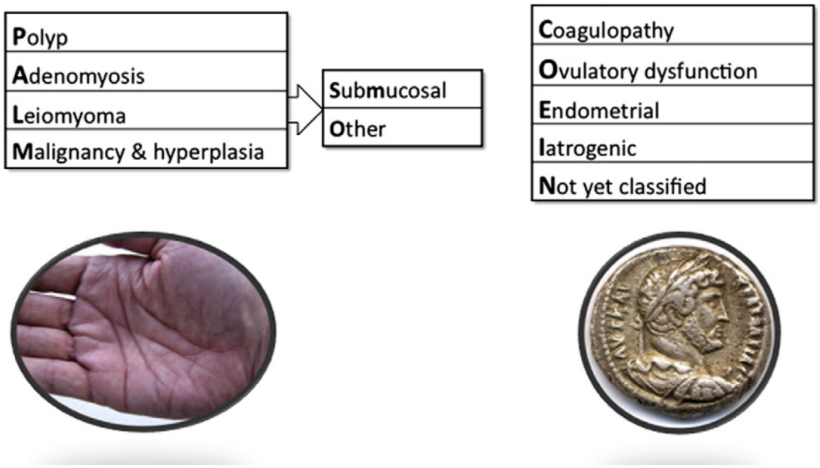

Figure 1: International Federation of Gynecology and Obstetrics (FIGO) PALM-COEIN abnormal uterine bleeding (AUB) classification system (Reproduced with permission from Munro et al., 2011).

The FIGO classification was updated in 2018 (Munro et al., 2018), with some changes (Figure 2).

Among them, the ultrasonographic diagnostic criteria for adenomyosis were refined (AUB-A), Type 3 myoma was included among submucosal myomas (AUB-L), the category AUB-N was changed from "Not Yet Classified" to "Not Otherwise Classified", and isthmocele was included in it as a cause of AUB.

Achieving an unambiguous terminology, together with the PALM-COEIN classification system, has mainly enabled the management of the patient with AUB.

This article aims to summarise the different aetiologies of AUB, its clinical impact on QoL, and diagnostic management to improve patient care and reduce healthcare costs.

Epidemiology

The prevalence of AUB varies from 3% to 30%, with such a wide range due to several factors. The age groups in which the incidence is highest are those around menarche and perimenopause. In addition, several studies have shown a wide discrepancy between subjective and objective measures of

System 2 category	Change
AUB-A	Refined sonographic diagnostic criteria
AUB-L	Inclusion of Type 3 as a submucous leiomyoma
	Type definitions and distinctions
	Distinction between Types 0 and 1; 6 and 7
	Distinction between Types 2 and 3; 4 and 5
AUB-C	No longer includes AUB associated with pharmacologic agents that impair blood coagulation which are now included in AUB-I
AUB-I	Now includes AUB associated with all iatrogenic processes including the use of pharmacological agents used for anticoagulation and those thought to interfere with ovulation
AUB-O	Diagnostic threshold changes based upon the revisions of System 1, described above
	No longer includes ovulatory disorders associated with drugs known or suspected to interfere with ovulation
AUB-N	The name of the category has been changed from "Not Yet Classified" to Not Otherwise Classified
	There is a brief discussion of a potential new cause of AUB the so-called uterine "niche" or isthmocele following lower segment cesarean section

Figure 2: Summary of changes to the International Federation of Gynecology and Obstetrics (FIGO) PALM-COEIN abnormal uterine bleeding (AUB) classification system (Reproduced with permission from Munro et al., 2018).

blood loss; about 10% of women of reproductive age were found in population-based studies to have objective evidence of HMB (i.e., menstrual blood loss greater than 80 ml). In contrast, in studies based on self-reported information, the percentage rises to 30%. However, some determinants for diagnosis are objective while others are subjective, making it difficult to determine the exact prevalence (Liu et al., 2007).

Discordance also exists on the degree of symptoms, depending on who evaluates the condition. One study estimated that 57.1% of patients who considered their symptoms severe were rated by their physicians as having only moderate symptoms. In contrast, 28.7% of patients reporting mild or moderate severity were diagnosed as having severe symptoms (Coulter et al., 1994).

To remedy these variances, objective criteria are needed, such as the objective defining of a blood loss of more than 80 ml; therefore, tools for quantifying the amount of menstrual bleeding, such as the Pictorial Blood Assessment Chart (PBAC), can be of help; it is a simple tool by which the woman herself can estimate the degree of impregnation of each pad at the time of change and record it on a pre-printed card. With this card, a total score for blood loss during a menstrual period can be calculated. A total score of 150 or more makes a diagnosis of severe menstrual bleeding likely (van den Brink, 2021).

A core outcome set (COS) for HMB has recently been developed. Ten outcomes were included in the final COS: subjective blood loss; flooding; menstrual cycle metrics; severity of dysmenorrhoea; number of days with dysmenorrhoea; quality of life; adverse events; patient satisfaction; number of patients going on to have further treatment for HMB and haemoglobin level. The final COS includes variables that are feasible for use in clinical trials in all resource settings and apply to all known underlying causes of HMB symptom (Cooper et al., 2023).

Clinical impact of AUB

AUB has significant psychosocial, emotional and economic implications; it may have a significant negative impact on QoL as it is associated with financial loss, decreased productivity, poor health, and increased use of health care resources (Woukand Helton, 2019). In fact, United Kingdom National Institute for Health and Care Excellence (NICE) states that HMB should be recognised as having a major impact on a woman's QoL, and that any intervention should aim to improve this rather than focusing on menstrual blood loss (NICE, 2018).

In a large case-control study of more than 29,000 subjects (Jensen et al., 2012), the authors found that average annual resource consumption was significantly higher in individuals diagnosed with HMB, linked to an overall increase in the use of inpatient, outpatient and emergency room health care services. In addition to direct medical costs, indirect costs (work absenteeism, home management costs) are responsible for large reported financial losses per patient per annum, according to a US study (Frick et al., 2009).

A survey of a randomised sample of Swedish women aged 40-45 years found that 32% of them experienced HMB. These women had significantly worse QoL than women with normal menstruation patterns. In general, menstruation was associated with negative perception and limitation of social and professional activities, although this aspect was significantly more pronounced for the HMB group. Practical inconveniences, such as bleeding through pads and planning social life with menstrual bleeding in mind, are, not surprisingly, more associated with the HMB group (Karlsson et al., 2013).

QoL indicators, pain scores, and perceived stress instruments are commonly used in gynaecological settings to assess the impact of AUB (Santer et al., 2007). Numerous instruments, both retrospective questionnaires and prospective diaries, have been developed over the years to assess menstrual cycle symptoms, especially in the premenstrual phase. The menstrual stress questionnaire (MEDI-Q) is a reliable and valid instrument developed to identify and monitor menstruation-related discomfort, and its impact on well-being. The MEDI-Q explores a number of areas affected by menstruation (pain, bleeding, mood, cognitive function, energy, nutrition, sleep, and sexuality) and provides a score ranging from 0 to 125. A MEDI-Q value at or above the cut-off of 20 indicates a clinically relevant condition (Vannuccini et al., 2021).

The wide impact of AUB on QoL is mainly related to iron deficiency anaemia, of which HMB is the leading cause in women in the developed world (Nazaryan et al., 2023). Iron deficiency anaemia has a significant negative impact on health, neurocognitive, immunologic, and haematologic function, with sequelae such as fatigue, weakness, unexplained weight loss, mood swings, and impaired cognitive functioning. This has an impact on social and economic well-being, related to the overall reduction in productivity (De Benoist et al., 2018).

One study (Fraser et al., 2015) found that the iron deficiency or iron-deficiency anaemia due to AUB is often untreated or inadequately treated in these patients. In fact, the management of AUB requires more than just iron supplementation; the underlying cause needs to be investigated and therapeutic options set up to reduce blood loss.

Another obstacle is determined by the fact that women with AUB tend to delay treatment, for a variety of reasons; uncertainty that uterine bleeding is abnormal, a perceived lower priority of gynaecological health, and difficulty in accessing services.

A recent study designed to assess awareness of HMB among the Saudi female population identified that 65.2% of women suffer from HMB, but only 35.6% are aware that they have it, while 64.4% are either unaware or unsure about having it. Among those who are aware they have HMB, only 32% seek medical advice, while 28% and 3.9% of those who are not aware of having HMB require iron supplementation and blood transfusion, respectively (Alsalman et al., 2020).

One study (Fraser et al., 2015) showed that in Europe 46% of women with HMB symptoms had never consulted a physician, and among those who had consulted a physician in the previous 12 months, 53.2% were not prescribed any medication. Consistent with these observations, a recent estimate (da Silva Filho et al., 2021) shows that an average of 3 years elapse from the onset of AUB to the patient's request for help; only 66% of women who begin to experience the symptom have an awareness that this condition is abnormal, but concern often first prompts them to discuss it with friends or family members and look for answers online. At this point, 60% of patients discuss the problem with their primary care physician and only 47% see their gynaecologist, while 40% believe they can manage it themselves. But even among women who have consulted a doctor, only 33% receive a diagnosis, and of these only 34% are properly treated.

It is clear from all this that it is important to define what is normal, and to adopt unambiguous terminology. Indeed, to reduce the socio-economic burden of AUB, it is first necessary to frame the diagnostic aspect appropriately and promptly, and then the therapeutic one. Since it is beyond the scope of this paper, we will not discuss treatment in detail.

Diagnosis of AUB

The initial evaluation of a woman presenting with genital tract bleeding thought to be an AUB must start with detailed history and clinical examination, which aim to rule out pregnancy and origin from other sites (urethra, anus, vulva, vagina, perineum). Laboratory tests can include a urine/serum assay for the presence of the β-subunit of human chorionic gonadotropin (β-HCG), full blood count - including platelets, ferritin, coagulation panel, thyroid function tests, gonadotropins, and prolactin (Davis and Sparzak, 2023).

Once it is assumed that the bleeding originates from the cervical canal or uterine cavity, the patient must be systematically evaluated for each of the most common aetiologies, which can be remembered by the acronym PALM-COEIN, according to the 2011 FIGO classification as later modified. In general, components of the PALM group represent structural entities, which can be objectively assessed by imaging and/or histopathology techniques, while the COEIN group includes non-structural entities, which therefore cannot be defined by imaging techniques. These aetiologies are not mutually exclusive; it must also be considered that one or more factors may contribute to the genesis of AUB, and that the presence of a pathology that is among the possible causes of AUB does not mean that it must necessarily contribute to it (Munro et al., 2018).

After the initial general evaluation, ovulatory status should be determined to investigate any irregularities in timing and flow, which are responsible for the bleeding. Anovulatory cycles, due to unbalanced oestrogenic effects on the endometrium, cause marked endometrial proliferation and thickening resulting in HMB. Ovulatory disorders causing AUB are classified as AUB-O and should have endocrine evaluation, in order to investigate possible endocrinopathies such as polycystic ovary syndrome (PCOS), hyperprolactinaemia, hypothyroidism, as well as factors such as obesity, anorexia, weight loss, mental stress, and extreme exercise, which impact the hypothalamo-pituitary-ovarian (HPO) axis (Whitaker and Critchley, 2016). In doubtful cases, serum progesterone assay may need to be performed to confirm ovulation in the current cycle for better estimation of mid-luteal phase; endometrial biopsy may also help in determining any alterations in secretory phase, although it is not recommended as a routine investigation.

A structured history can identify a bleeding disorder in 90% of women (Kouides et al., 2005; Kadir et al., 1998); further testing is then required, after consultation with a haematologist, including von Willebrand factor, ristocetin cofactor, and partial thromboplastin time (PTT) assay. If the results are positive for a coagulopathy, the woman with AUB is classified as having AUB-C.

AUB also occurs in 2/3 of women who undertake anticoagulant therapy (Patel et al., 2023), so this needs to be considered and recognised measures taken to minimise this problem for menstruating women prescribed this therapy. The 2018 updated FIGO classification (Munro et al., 2018) shifted individuals with AUB associated with the use of anticoagulant/antiplatelet therapies therapy from

AUB-C to the AUB-I (Iatrogenic) category, which also include continuous oestrogen or progestin systemic therapy or intrauterine systems (Fraser, 1999), or gonadotropin-releasing hormone agonists (GnRH-a) and aromatase inhibitors, with action on ovarian steroid release, or selective oestrogen receptor modulators (SERMs) and more rarely selective progesterone receptor modulators (SPRMs).

Once coagulopathy or other systemic disease or menstrual cycle disorders have been ruled out, the presence of an underlying endometrial cause (AUB-E) should be investigated. Diagnosis depends on a careful history and exclusion of other causes, as the role of endometrial disorders in AUB is not yet fully understood and there are no specific tests or clinically available biomarkers (Whitaker and Critchley, 2016). AUB-E may be associated with altered local endometrial haemostasis and angiogenesis mechanisms, with a deficiency in local production of vasoconstrictors and increased local production of vasodilator-promoting substances, or by altered local glucocorticoid metabolism (Critchley and Maybin, 2011).

Patients reporting AUB, with a diagnosis of established chronic endometritis, should also be categorised as having AUB-E; therefore, it may be reasonable to consider evaluating for the possible presence of chlamydia in these patients, given the apparent correlation between endometrial chlamydial infection and AUB (Toth et al., 2007).

Rare or ill-defined conditions that cannot easily be included in the other categories are enclosed in the AUB-N (Not otherwise classified) category. This is a category undergoing periodic revisions, scheduled every 3-5 years by FIGO (Munro et al., 2011); in the 2018 revision, the lower segment or upper cervical niche or "isthmocele" frequently found in association with a previous caesarean delivery was included in this category (Bij et al., 2014; Tulandi and Cohen, 2016). A recent meta-analysis (Murji et al., 2022) demonstrated a strong and consistent association between patients with caesarean scar defect (CSD) and AUB: in patients with at least one caesarean delivery and CSD, the prevalence of AUB was 25.5%, and it was higher in patients with larger CSD. These patients have a unique bleeding pattern, i.e., prolonged menstruation, "brown discharge", and early-cycle intermenstrual bleeding.

Structural Causes – PALM group

Evaluation of structural causes usually begins with imaging studies, transvaginal ultrasonography (TV-USG), sonohysterography, magnetic resonance imaging (MRI).

TV-USG, complemented also by the three-dimensional (3D) study, can provide an accurate assessment of the uterine cavity (size, shape, endometrial thickness, volume) but also of the myometrium, junctional area, any ovarian abnormalities, and concomitant pathologies. Thus, it is an important tool that should be employed in the first line in the investigation of AUB (Finco et al., 2015). Sonohysterography (TV-USG with intrauterine contrast, either saline or gel) can be useful in cases where TV-USG images are inconclusive or endocavitary pathology is observed, but it is more invasive. MRI provides detailed images that may prove useful in surgical planning, but it is expensive and is not the first-line choice for imaging in patients with AUB.

If imaging features indicate the presence of endometrial polyps or leiomyomas that may footprint or affect the endometrial cavity, outpatient hysteroscopy is recommended (Munro et al., 2018).

The increased availability of new hysteroscopic technology and equipment has led to a trend toward single-step, outpatient-based techniques for diagnosis and treatment of AUB. First, however, the meaning of "outpatient" needs to be clarified, since the terminology that applies to hysteroscopic procedures is often not unambiguously used. Therefore, an international working group of experts in hysteroscopy from the American Association of Gynecologic Laparoscopists (AAGL), the European Society for Gynaecological Endoscopy (ESGE) and the Global Community of Hysteroscopy (GCH) developed recently a consensus statement of recommended terminology to use for describing different aspects of hysteroscopic procedures: (i) pain management, (ii) the setting where procedures are conducted, (iii) the model of care relating to the length of stay and need for admission, (iv) the type of procedure and (v) the approach to hysteroscopy (Carugno et al., 2021). In this scenario, the term "outpatient" refers to the hysteroscopic procedure performed in a health care facility where pain control up to level 3a (oral or inhaled medications with sedative effect) can be eventually administered and to a model of care in which the patient arrives and leaves the facility on the same calendar day.

The tendency of hysteroscopy to move itself towards the outpatient setting closed the gap with TV-USG. Actually, office hysteroscopy presents some major advantages (Di Spiezio Sardo et al., 2016). The characteristic of "direct view" represents a huge benefit, ensuring a very high diagnostic sensitivity and specificity in uterine cavity and endometrial evaluation. Moreover, thanks to modern instrumentation, the visual endoscopic examination

is generally completed by the "target-eye" biopsy of the suspected areas.

There is a case in which hysteroscopy is the first-level investigation of AUB, and that is when the woman is considered to be at high risk for hyperplasia or neoplasia; performing a hysteroscopic endometrial biopsy is indeed necessary in the presence of AUB and risk factors for malignancy, which include age over 45 years, Lynch syndrome, whose lifetime risk of developing endometrial cancer reaches 60% (Lu and Broaddus, 2001; Lu et al., 2005), age under 45 years but unopposed oestrogen exposure (obesity and/or PCOS). In addition, in case of treatment failure or persistent or unexplained bleeding, hysteroscopic evaluation of the uterine cavity (ACOG, 2013; NICE, 2018) with endometrial sampling is also necessary.

Several techniques can be used to perform endometrial sampling. Blind dilatation and curettage (D&C) was long considered the gold standard, although its well-recognized deficiencies. Hysteroscopic targeted biopsy, with the "grasp" technique, replaced blind D&C, achieving a high concordance of histologic type and tumour grade, especially in presence of an endometrioid-type tumour (Di Spiezio Sardo et al., 2020). 5 Fr scissors or 15 Fr bipolar office resectoscope can be used to collect adequate tissue samples from hypo/atrophic endometrium, from the subendometrial layer or from the endocervical canal, when needed. And last but not least, a new technique,performed with hysteroscopic tissue removal systems (HTRS), provides a type of atraumatic curettage performed under direct visualisation, mechanically collecting targeted and larger amount of endometrial tissue (Di Spiezio Sardo and Gallo, 2022).

AUB-P

The first "P" of the classification system stands for "polyps". Endometrial polyp is a frequent cause of AUB, which is reported in 3.7–65% of these patients (Whitaker and Critchley, 2016). Its prevalence is around 7.8–34.9%, lower in young women than in postmenopausal women (Finco et al., 2015). Intermenstrual bleeding is the most common presenting symptom, but many polyps are asymptomatic; their transformation in pre-malignant and malignant lesions is estimated to occur in 0 to 12.9% of cases, higher for post-menopausal women and for those with significantly greater bleeding (Lieng et al., 2010). TV-USG, and even more so sonohysterography (Bahamondes and Ali, 2015), can raise the suspicion of endometrial polyp, appearing as a focal, hyperechoic and well-defined thickening of the endometrium. Diagnostic confirmation is provided by hysteroscopy, with sensitivity and specificity described of 90% and 93%, respectively (De Cunha Vieira et al., 2022); it provides an evaluation of number, dimensions, location and relationship to the tubal ostia, adjacent mucosa; performed in outpatient setting, it also allows immediate removal. A review of the literature (Nathani and Clark, 2006) points out that polypectomy led to improvement in AUB symptoms (range 75–100%).

AUB-A

The "A" stands for adenomyosis, which is defined as the presence of endometrial tissue within the myometrium, and it can be diffuse (involving most of the myometrium or dispersed within the myometrium) or focal (confined nodular lesion) or presenting as an adenomyoma (focal adenomyosis with additional compensatory hypertrophy of the surrounding myometrium (Van den Bosch et al., 2015). Its prevalence ranges from 5% to 70%, but its association with AUB is unclear (Taran et al., 2013). TV-USG has similar sensitivity and specificity for the diagnosis of adenomyosis when compared to MRI (Bazot and Daraï, 2018); although the diagnosis of certainty can only be provided by histological analysis, the use of criteria based on the ultrasound features suggested by the Morphologic Uterus Ultrasound Assessment Group (MUSA) for the diagnosis of adenomyosis is recommended (Munro et al., 2018); they include asymmetrical thickening, cysts, hyperechoic islands, fan-shaped shadowing, echogenic subendometrial lines and buds, translesional vascularity, irregular junctional zone and interrupted junctional zone. The application of 3D-USG allows the evaluation of the junctional zone (JZ), the inner myometrial layer underlying the endometrium, composed of higher cellular density and a higher nuclear area compared to the outer myometrium, which appears thickened, interrupted, irregular or ill-defined (Van den Bosch et al., 2015). Some hysteroscopic aspects are generally indicative of adenomyosis, even if restricted to the endometrial surface layer and so not definitively diagnostic; irregular endometrium with tiny openings seen on the endometrial surface, pronounced hypervascularisation, endometrial "strawberry" pattern, fibrous cystic appearance of intrauterine lesions, haemorrhagic cystic lesions assuming a dark blue or chocolate brown appearance (Di Spiezio Sardo et al., 2017). Biopsy sample from the endometrium and underlying myometrium can be obtained using grasping forceps, 5 Fr scissors, 5 Fr bipolar electrodes bipolar, bipolar resectoscope or bipolar mini-resectoscope (Di Spiezio Sardo and Campo, 2022). In order to improve collection of samples from the subendometrial myometrium,

the "Spirotome" (Bioncise and Wellen, Belgium), inserted to the outer sheath of Campo Trophyscope® (KARL STORZ, Germany) can be used, under sonographic guidance (Di Spiezio Sardo et al., 2017).

AUB-L

The "L" stands for leiomyomas, also known as fibroids, benign smooth muscle tumours that arise from the myometrium. They are present in about 80% of women (Wouk and Helton, 2019), with increasing prevalence with increasing age. AUB is a common symptom, associated with pelvic pain or pressure (Borah et al., 2013) and consequences for fertility and obstetric outcomes (Van den Bosch et al., 2015).

The primary classification of leiomyomas involves their identification by a combination of TV and transabdominal (TA) USG; any lesion identified leads to the assignment of an "L." It is then necessary to determine the relationship of the leiomyoma to the endometrium by adopting a secondary classification, which divides leiomyomas into submucosal (SM) and other (O) (Whitaker and Critchley, 2016). Tertiary classification aims to clarify the relationship of leiomyoma with the endometrial cavity, myometrium, and uterine serosa by a combination of TV-USG, hysterosalpingography, hysteroscopy and MRI. Leiomyomas are thus further subdivided into nine categories, adopting the FIGO subclassification system of leiomyoma (Munro et al., 2018). Type 0, 1, 2, or 3 for woman in whom L-SM was detected, Type 4, 5, 6, 7, and/or 8 for women in whom L-O was detected.

MRI may be useful to distinguish between leiomyomas and adenomyosis or adenomyomas (Van den Bosch et al., 2015) and to measure the extent of the myometrium of submucosal leiomyomas, with superior reliability to TV-USG, sonohysterography, and hysteroscopy (Munro et al., 2018). The distinction between type 2 and type 3 leiomyomas should be based on hysteroscopy, infusing the distention medium at low pressure so that the natural relationships of the leiomyoma with the endometrium are not distorted.

Hysteroscopy also allows the evaluation of several criteria essential for the decision on surgical treatment: location, size (best evaluated by combining hysteroscopy and USG), consistency, depth of myometrial invasion (the wider the angle, the greater the depth of myometrial penetration within the uterine wall should be, and vice versa), vascularization (which may contribute to bleeding), and characteristics of the surrounding endometrium (Di Spiezio Sardo and Campo, 2022).

AUB-M

Any premalignant hyperplastic or malignant process would be classified as AUB-M. Bleeding patterns in patients with uterine malignancy are highly variable (Wouk and Helton, 2019). As mentioned above, hysteroscopy with endometrial biopsy is the gold standard diagnostic tool and it should be used first-line when there is a high risk of hyperplasia or neoplasia; the different methods of performing endometrial biopsy have been explained above. Subclassification of malignant lesions should be done using the appropriate WHO or FIGO system.

Conclusions

AUB is a common and debilitating condition for women of all age groups, directly affecting quality of life (QoL) and incurring high direct and indirect costs. A systematic approach to establish the cause using the FIGO PALM-COEIN classification system with its periodic evolutions facilitates accurate management of AUB and ensures improved quality of life for women with this symptom, thanks to continuous improvements in imaging and outpatient hysteroscopy.

Acknowledgements: None.

References

ACOG. Committee opinion no. 557: Management of acute abnormal uterine bleeding in nonpregnant reproductive-aged women. Obstet Gynecol. 2013;121:891-6.

Alsalman M, Albarak A, Busaleh F et al. Heavy menstrual bleeding awareness among Saudi female population and clinical implications. Health Sci Rep. 2021;4:e244.

Bahamondes L, Ali M. Recent advances in managing and understanding menstrual disorders. F1000Prime Rep. 2015;7:33.

Bazot M, Daraï E. Role of transvaginal sonography and magnetic resonance imaging in the diagnosis of uterine adenomyosis. Fertil Steril. 2018;109:389-97.

Bij dVA, van der Voet LF, Naji O et al. Prevalence, potential risk factors for development and symptoms related to the presence of uter ine niches following Cesarean section: Systematic review. Ultrasound Obstet Gynecol. 2014;43:372–82.

Borah BJ, Nicholson WK, Bradley L et al. The impact of uterine leiomyomas: a national survey of affected women. Am J Obstet Gynecol. 2013;209:319.e1-319.e20.

Carugno J, Grimbizis G, Franchini M et al. International Consensus Statement for recommended terminology describing hysteroscopic procedures. Facts Views Vis Obgyn. 2021;13:287-94.

Cooper NAM, Rivas C, Munro MG et al. Standardising outcome reporting for clinical trials of interventions for heavy menstrual bleeding: Development of a core outcome set. BJOG. 2023;130:1337-45.

Coulter A, Peto V, Jenkinson C. Quality of life and patient satisfaction following treatment for menorrhagia. Fam Pract 1994;11:394–401.

Critchley HO, Maybin JA. Molecular and cellular causes of abnormal uterine bleeding of endometrial origin. Semin Reprod Med 2011;29:400e9.

De Cunha Vieira M, Vitagliano A, Costa Rossette M et al. Endometrial Polyps: Update Overview on Etiology, Diagnosis, Natural History and Treatment. Clin. Exp. Obstet. Gynecol. 2022;49:232.

Da Silva Filho AL, Caetano C, Lahav A et al. The difficult journey to treatment for women suffering from heavy menstrual bleeding: a multi-national survey. Eur J Contracept Reprod Health Care. 2021;26:390-8.
Davis E, Sparzak PB. Abnormal Uterine Bleeding. 2022. In: StatPearls [Internet]. Treasure Island (FL): StatPearls Publishing; 2023.
De Benoist B, Cogswell M, Egli I et al. Worldwide prevalence of anaemia 1993-2005; WHO Global Database of anaemia. 2018. Retrieved from: https://www.who.int/nutrition/publications/micronutrients/anaemia_iron_deficiency/9789241596657/en/.
Di Spiezio Sardo A, Calagna G, Laganà AS et al. Is Hysteroscopy Better than Ultrasonography for Uterine Cavity Evaluation? An Evidence-Based and Patient-Oriented Approach. J Endometriosis Pelvic Pain Disorders. 2016;8:87-93.
Di Spiezio Sardo A, Calagna G, Santangelo F et al. The Role of Hysteroscopy in the Diagnosis and Treatment of Adenomyosis. Biomed Res Int. 2017;2017:2518396.
Di Spiezio Sardo A, Campo R. State-of-the-Art Hysteroscopic Approaches to Pathologies of the Genital Tract. EndoPress. Version: 2.0 04-2022.
Di Spiezio Sardo A, De Angelis MC, Della Corte L et al. Should endometrial biopsy under direct hysteroscopic visualization using the grasp technique become the new gold standard for the preoperative evaluation of the patient with endometrial cancer? Gynecol Oncol. 2020;158:347-53.
Di Spiezio Sardo A, Gallo A. Tissue Removal Systems for Biopsy. Hysteroscopic Newsletter, Jul-Sep 2022, Vol. 8, Issue 3. https://www.isge.org/wp-content/uploads/2022/09/20220903_Hysteroscopy_newsletter_vol_8_issue_3_english.pdf.
Finco A, Centini G, Lazzeri L et al. Surgical management of abnormal uterine bleeding in fertile age women. Womens Health (Lond). 2015;11:513-25.
Fraser IS. Bleeding arising from use of exogenous steroids. Baillieres Best Pract Res Clin Obstet Gynaecol. 1999;13:203–22.
Fraser IS, Mansour D, Breymann C et al. Prevalence of heavy menstrual bleeding and experiences of affected women in a European patient survey. Int J Gynaecol Obstet. 2015;128:196–200.
Frick KD, Clark MA, Steinwachs DM et al. Financial and quality-of-life burden of dysfunctional uterine bleeding among women agreeing to obtain surgical treatment. Womens Health Issues 2009;19:70e8.
Heavy menstrual bleeding: assessment and management. London: National Institute for Health and Care Excellence (NICE); 2018. https://www.nice.org.uk/guidance/ng88
Jensen JT, Lefebvre P, Laliberté F et al. Cost burden and treatment patterns associated with management of heavy menstrual bleeding. J Womens Health (Larchmt). 2012;21:539-47.
Karlsson TS, Marions LB, Edlund MG. Heavy menstrual bleeding significantly affects quality of life. Acta Obstet Gynecol Scand. 2014;93:52-7.
Kouides PA, Conard J, Peyvandi F et al. Hemostasis and menstruation: appropriate investigation for underlying disorders of hemostasis in women with excessive menstrual bleeding. Fertil Steril. 2005;84:1345e51.
Kadir RA, Economides DL, Sabin CA et al. Frequency of inherited bleeding disorders in women with menorrhagia. Lancet. 1998;351:485–9.
Lieng M, Istre O, Qvigstad E. Treatment of endometrial polyps: a systematic review. Acta Obstet Gynecol Scand. 2010;89:992-1002.
Liu Z, Doan QV, Blumenthal P et al. A systematic review evaluating health-related quality of life, work impairment, and health-care costs and utilization in abnormal uterine bleeding. Value Health. 2007;10:183-94.
Lu KH, Broaddus RR. Gynecological tumors in hereditary nonpolypo- sis colorectal cancer: We know they are common–now what? Gynecol Oncol. 2001;82:221–2.
Lu KH, Dinh M, Kohlmann W et al. Gynecologic cancer as a "sentinel cancer" for women with hereditary nonpolyposis colorectal cancer syndrome. Obstet Gynecol. 2005;105:569–74.
Munro MG, Critchley HO, Broder MS et al. FIGO Working Group on Menstrual Disorders. FIGO classification system (PALM-COEIN) for causes of abnormal uterine bleeding in nongravid women of reproductive age. Int J Gynaecol Obstet. 2011;113:3-13.
Munro MG, Critchley HOD, Fraser IS. FIGO Menstrual Disorders Committee. The two FIGO systems for normal and abnormal uterine bleeding symptoms and classification of causes of abnormal uterine bleeding in the reproductive years: 2018 revisions. Int J Gynaecol Obstet. 2018;143:393-408.
Murji A, Sanders AP, Monteiro I et al. International Federation of Gynecology and Obstetrics (FIGO) Committee on Menstrual Disorders and Related Health Impacts. Cesarean scar defects and abnormal uterine bleeding: a systematic review and meta-analysis. Fertil Steril. 2022;118:758-66.
Nathani F, Clark TJ. Uterine polypectomy in the management of abnormal uterine bleeding: A systematic review. J Minim Invasive Gynecol. 2006;13:260-8.
Nazaryan H, Watson M, Ellingham D et al. Impact of iron supplementation on patient outcomes for women with abnormal uterine bleeding: a protocol for a systematic review and meta-analysis. Syst Rev. 2023;12:121.
Patel JP, Nzelu O, Roberts LN, Johns J, Ross J, Arya R. How do anticoagulants impact menstrual bleeding and quality of life? - The PERIOD study. Res Pract Thromb Haemost. 2023;7:100072.
Santer M, Wyke S, Warner P. What aspects of periods are most bothersome for women reporting heavy menstrual bleeding? Community survey and qualitative study. BMC Womens Health. 2007;7:8.
Taran FA, Stewart EA, Brucker S. Adenomyosis: epidemiology, risk factors, clinical phenotype and surgical and interventional alternatives to hysterectomy. Geburtshilfe Frauenheilkd. 2013;73:924-31.
Toth M, Patton DL, Esquenazi B et al. Association between Chlamydia trachomatis and abnormal uterine bleeding. Am J Reprod Immunol. 2007;57:361–6.
Tulandi T, Cohen A. Emerging manifestations of cesarean scar defect in reproductive-aged women. J Minim Invasive Gynecol. 2016;23:893–902.
Van den Bosch T, Dueholm M, Leone FP et al. Terms, definitions and measurements to describe sonographic features of myometrium and uterine masses: a consensus opinion from the Morphological Uterus Sonographic Assessment (MUSA) group. Ultrasound Obstet Gynecol. 2015;46:284-98.
Van den Brink M. Management of heavy menstrual bleeding: Towards a patient-centred approach. [Groningen]: University of Groningen, 2021. 230 p.
Vannuccini S, Rossi E, Cassioli E et al. Menstrual Distress Questionnaire (MEDI-Q): a new tool to assess menstruation-related distress. Reprod Biomed Online. 2021;43:1107-16.
Whitaker L, Critchley HO. Abnormal uterine bleeding. Best Pract Res Clin Obstet Gynaecol. 2016;34:54-65.
Woolcock JG, Critchley HO, Munro MG et al. Review of the confusion in current and historical terminology and definitions for disturbances of menstrual bleeding. Fertil Steril. 2008;90:2269-80.
Wouk N, Helton M. Abnormal Uterine Bleeding in Premenopausal Women. Am Fam Physician. 2019;99:435-43.

doi.org/10.52054/FVVO.15.M.092

Review

An overview of International AUB/HMB Guidelines*

E. Saridogan[1]

[1]*Professor of Gynaecological Surgery, Elizabeth Garrett Anderson Institute for Women's Health, University College London; Consultant in Reproductive Medicine and Minimal Access Surgery, Women's Health Division, University College London Hospital, 250 Euston Road, London NW1 2PG, United Kingdom.*
**This article was not peer reviewed by Facts, Views and Vision. The author was commissioned by Hologic.*

Correspondence at: Professor Ertan Saridogan. E-mail: ertan.saridogan@nhs.net

Abstract

Abnormal uterine bleeding (AUB) is estimated to affect approximately 3-30% of women in their reproductive years. There are a number of guidelines from national societies and organisations on this subject. Many aspects of the available guidelines are in agreement with each other, probably due to the use of same published evidence. However, this article demonstrates that there are also major differences on certain subjects. These are likely to be a reflection of variations in clinical practice in different countries, as the differences are difficult explain with emergence of new evidence. Guidelines aim to improve patient care by informing clinical practice, to reduce unwarranted variability and to expedite implementation of effective intervention. The similarities between the guidelines give an opportunity to create international guidelines which may be more influential globally. Such a document would be more widely accepted by the clinicians and women alike, potentially reduce variability of access to the best treatments available and improve the lives of sufferers.

Keywords: **Abnormal uterine bleeding, heavy menstrual bleeding, guidelines.**

Introduction

Abnormal uterine bleeding (AUB) is estimated to affect approximately 3-30% of women in their reproductive years. These figures mostly come from studies on heavy menstrual bleeding (HMB), hence the real prevalence may be higher (Munro et al., 2018). AUB is the leading reason for gynaecological consultations. As a result, a number of national societies and organisations have prepared guidance to clinicians on this subject. Guidelines for clinical practice are systematically developed statements to help healthcare professionals and affected people make decisions about appropriate care for specific clinical circumstances. Their purpose is to improve patient care by informing clinical practice, to reduce unwarranted variability and to expedite implementation of effective intervention.

Many aspects of the available guidelines are in agreement with each other although there are some differences. This similarity is not surprising as most guidelines use the same published evidence, and the differences may be a reflection of the variation in clinical practice in individual countries and new evidence which may have come up since publication of some of these guidelines. It is also possible that there may be differences amongst the underlying causes of AUB or women's preferences of treatment may vary reflecting cultural differences. A list of some of the major international guidelines is given in Table I.

Guidelines on AUB/HMB cover diagnosis and/or management. Older guidelines were mostly written by 'expert committees' in a narrative review style, whereas more recent guidelines have a structured methodology which include a systematic literature search to answer structured questions (PICO – patients, intervention, comparison, outcome) which have been determined by stakeholders, eventually leading to a number of evidence based statements after review of the relevant articles by the guideline development group (GDG). The GDG usually consists of a multidisciplinary team including patient representatives.

This article will give a comparative description of the most recent major guidelines on AUB or HMB

Table I. — List of some of the available guidelines on abnormal uterine or heavy menstrual bleeding.

- CNGOF (College National des Gynecologues et Obstetriciens Francais), Management of women with abnormal uterine bleeding: Clinical practice guidelines of the French National College of Gynaecologists and Obstetricians (CNGOF), 2023 (Brun et al., 2023)
- NICE (National Institute for Health and Care Excellence) Guideline, Heavy menstrual bleeding: assessment and management, 2018 (NICE, 2018)
- NHG – (Nederlands Huisartsen Genootshap - Dutch College of General Practitioners), NHG-Standaard Vaginaal bloedverlies, 2014, updated in 2023 (NHG, 2014)
- NVOG- (Nederlandse Vereniging voor Obstetrie en Gynaecologie – Dutch College of Obstetrics and Gynaecology) – Heavy menstrual bleeding, 2013, updated in 2023 (NVOG, 2013)
- Australian Commission on Safety and Quality in Health Care – Heavy menstrual bleeding Clinical Care Standard, 2017
- DGGG (Deutsche Gesellschaft für Gynäkologie und Geburtshilfe), Indikation und Methodik der Hysterektomie bei benignen Erkrankungen, 2015 (DGGG, 2015)
- SEGO (Sociedad Espaňola Ginecologica y Obsttetrica), Heavy menstrual bleeding, 2013 (SEGO, 2013)
- SIGO (Societá italiana di Ginecologica e Ostetricia) Recommendations on diagnostic and therapeutic approaches for heavy menstrual bleeding, 2006 (SIGO, 2006)
- SOGC (Society of Obstetricians and Gynaecologists of Canada), Abnormal uterine bleeding in premenopausal women, 2018 (Singh et al., 2018)
- ACOG (American College of Obstetricians and Gynecologists) Committee Opinion: Management of acute abnormal uterine bleeding in non-pregnant reproductive-aged women, 2013 (ACOG, 2013)

from Canada, France, the Netherlands and United Kingdom to highlight main points of agreements and differences in diagnostic and therapeutic approaches to AUB. The references for these guidelines can be found in Table I or when they are first mentioned in the text and the details are in the reference list.

Diagnosis

History

There is overall agreement in most evidence based guidelines that a detailed history should be taken to aid diagnosis. This should include duration and nature of AUB, details of menstrual cycles and presence or absence of associated symptoms such as pain, urinary symptoms. There is however disagreement on the use of assessment of menstrual blood loss. Whilst the Dutch general practitioners NHG (Nederlands Huisartsen Genootshap) guideline and French CNGOF (College National des Gynecologues et Obstetriciens Francais) guidelines (NHG, 2014; Brun et al., 2023) recommend use of pictorial blood loss assessment charts (PBAC) when there is diagnostic doubt, the United Kingdom NICE (National Institute for Health and Care Excellence) guideline (NICE, 2018) does not recommend their routine use. French CNGOF guidelines (Brun et al., 2023) also suggest that they should be used in adolescents. NICE guidelines suggest that the woman herself should decide if the menstrual blood loss is a problem and if it affects her quality of life. Canadian SOGC (Society of Obstetricians and Gynaecologists of Canada) guidelines do not make a recommendation on the use of PBAC (Singh et al., 2018).

Physical examination

SOGC and CNGOF guidelines recommend a general physical and a gynaecological examination with a speculum to rule out a lower genital tract pathology. NICE and NHG guidelines take a more a selective approach; the former recommend a physical examination when structural abnormalities are suspected, and before arranging further investigations or a levonorgestrel-IUS (LNG-IUS) is fitted, and the latter state that speculum and bimanual examinations can be omitted in low risk women for a genital pathology. NICE guidelines also indicate that pharmaceutical treatment can be started without an examination if a structural or histological abnormality is not suspected from the woman's history. There is overall agreement that physical examination is a useful tool for diagnosis and that vast majority of women, if not all, should be examined to establish diagnosis and guide treatment.

Ultrasound examination

Similar to the approach to physical examination, there are subtle differences between the French guidelines and the other three guidelines from

the Netherlands, Canada and United Kingdom. CNGOF guidelines imply that all women presenting with AUB have an ultrasound examination as the first line imaging investigation. NICE and SOGC guidelines advocate using ultrasound when the uterus is palpable abdominally, when examination reveals a structural abnormality or if pharmaceutical treatment fails. Dutch NHG guidelines also suggest arranging a transvaginal ultrasound examination if vaginal examination is abnormal. These differences imply that medical treatment can be initiated for AUB without an ultrasound examination according to the NICE and NHG guidelines, whilst French guidelines indicate that an ultrasound should be performed to rule out a structural abnormality.

Hysteroscopy and endometrial biopsy

There are significant differences amongst the guidelines evaluated in this article. The NICE HMB guideline advocate a 'fast track' approach to outpatient hysteroscopy and endometrial biopsy in women who have persistent intermenstrual or irregular bleeding, obesity or polycystic ovary syndrome, in women who are on tamoxifen or who have not responded to medical treatment for HMB and in women with suspected submucosal fibroids, endometrial polyps or other endometrial pathology. In their flowchart, this recommendation comes without an initial ultrasound examination.

In contrast the CNGOF guidelines take a more conservative approach towards hysteroscopy and advise that hysteroscopy should not be routinely used when the ultrasound examination enabled diagnosis of an intracavitary pathology and should only be used when the ultrasound diagnosis is doubtful. It also suggests sonohysterography as an alternative to hysteroscopy. In a separate recommendation, the French guidelines advise that endometrial biopsy should be taken in adult women when the endometrial thickness is over 15 mm, or in the presence of a risk factor for endometrial cancer such as perimenopause, high body mass index, diabetes, nulliparity or genetic risks.

The Canadian SOGC guidelines suggest hysteroscopy as an option in selected patients to visualise intracavitary pathology along with saline infusion sonohysterography and take direct biopsies when necessary. They recommend endometrial biopsy in women over age 40 years, in those with increased risk of endometrial cancer (age, obesity, nulliparity, PCOS, diabetes, HNPCC) and in the presence of intermenstrual bleeding, infrequent menses suggestive of anovulatory cycles or when medical treatment fails.

The Dutch NHG guidelines suggest considering hysteroscopy or transvaginal contrast sonography if there is no response to medical treatment or if the woman is on tamoxifen. Similarly the Dutch NVOG- (Nederlandse Vereniging voor Obstetrie en Gynaecologie) guidelines on heavy menstrual bleeding do not recommend routine hysteroscopy with normal saline or gel instillation sonography (NVOG, 2013).

The differences between the British and other guidelines may be a reflection variations in clinical practice in these countries. The majority of guidelines preserve hysteroscopy for specific situations and heavily rely on ultrasound and endometrial biopsy, whereas the British guidelines have a more liberal approach to outpatient hysteroscopy, even without an ultrasound examination.

Treatment

Treatment options have been outlined in the guidelines – except the SOGC guidelines- in two separate groups depending on presence or absence of an underlying pathology (structural abnormality). The NICE guidelines include women with small (<3 cm) non-cavity distorting fibroids and adenomyosis in the group without an underlying pathology. All four guidelines specify first and second line treatment options and make separate recommendations who have presence or absence of desire for pregnancy in the immediate or long term future (Table II and Table III).

AUB/HMB in the absence of a structural abnormality including those with small non-cavity distorting fibroids and adenomyosis

There is overall agreement that LNG-IUS should be offered as the first line treatment to this group of women when there is no immediate desire for pregnancy, except the Canadian SOGC guidelines which do not indicate a preference order for non-surgical treatments. The CNGOF guidelines make distinction between women age under and over 42 years when they no longer desire pregnancy; LNG-IUS 52 mg is the first line treatment but over the age 42 years they recommend endometrial ablation due to lower side effect rates.

When LNG-IUS is not acceptable or is unsuitable other first line treatment options include tranexamic acid and nonsteroid anti-inflammatory drugs (NSAIDs). In the NICE guidelines, combined hormonal contraceptives (CHC), progesterone only contraceptives and progestins are recommended alternative first line treatment options for women who do not wish to become pregnant. NHG guidelines also include CHC and progestins as alternatives to LNG-IUS, whereas

Table II. — Treatment options for AUB/HMB in the absence of an underlying pathology.

	United Kingdom	The Netherlands	France	Canada
First line	LNG-IUS	LNG-IUS	Age <42 years LNG-IUS Age > 42 years EA	Tranexamic acid, NSAIDs, CHC, DMPA, LNG-IUS
	Tranexamic acid, NSAIDs	Tranexamic acid, NSAIDs	Tranexamic acid, NSAIDs	
	CHC, Progestins	CHC, Progestins		
	Progesterone only contraceptives			
Second line	SEAT	SEAT	Endometrial resection or ablation	SEAT
	Hysterectomy	Hysterectomy	Laparoscopic or vaginal hysterectomy	Hysterectomy

LNG-IUS: Levonorgestrel intrauterine system, DMPA: Depot medroxyprogesterone acetate, EA: Endometrial ablation, NSAIDs: nonsteroid anti-inflammatory drugs, SEAT: second generation endometrial ablation therapies

these are not included in the CNGOF guidelines. SOGC guidelines advise against use of cyclical progestins due to lack of efficiency in the literature.

Second line treatment options for women who no longer have future fertility plans are endometrial resection/ablation or hysterectomy. Both the NICE and NVOG guideline specifically recommend second generation endometrial ablation therapies (SEAT), whereas CNGOF include both endometrial resection and ablation options. French guidelines specify that if hysterectomy is chosen, laparoscopic or vaginal route should be preferred, however, the NICE guidelines suggest that the woman's preferences should be taken into account on the type of hysterectomy. French guidelines make a strong recommendation that hysterectomy can be offered to women who are eligible to have surgical treatment if there is no desire to preserve the uterus, but in contrast NICE guideline suggests that hysterectomy should not be offered as a first line treatment.

AUB/HMB due to a structural uterine pathology

The guidelines cover a number of structural abnormalities which may cause AUB or HMB and include polyps, fibroids, hyperplasia and malignancy. These abnormalities are classified in the FIGO classification system as PALM-COEIN (Munro et al., 2018).

NVOG guidelines do not routinely recommend removal of polyps for HMB, although its benefit in treating intermenstrual bleeding is acknowledged. Same guidelines suggest that polyp removal should preferably be performed within an outpatient setting, depending on the size of polyp and experience of the clinician. Polyps do not feature amongst the treatment recommendations in the NICE HMB guidelines, their diagnosis by ultrasound and hysteroscopy is extensively covered in the diagnosis section. French CNGOF guidelines take a very different approach to endometrial polyps; whilst they recommend polyp resection as a sole procedure in women with current or future desire for pregnancy, first or second generation endometrial ablation in combination with polyp resection is recommended in women who have no desire for pregnancy.

There is overall agreement that submucosal fibroids should be removed at hysteroscopy. The NVOG guidelines suggest hysteroscopic myomectomy for submucosal fibroids of up to 4 cm. The CNGOF guidelines do not specify the size of fibroids but recommend fibroid resection for type 0-2 submucosal fibroids. The NICE guidelines include a recommendation of fibroid resection for fibroids smaller than 3 cm causing HMB, however there is no separate statement for larger submucosal fibroids.

For other fibroids the treatment option that have been considered in the guidelines include myomectomy, uterine artery embolisation (UAE) and hysterectomy, in addition to symptomatic hormonal or non-hormonal treatment options discussed in the previous section (LNG-IUS, Tranexamic acid, NSAIDs, CHCs and progestins). The Dutch NVOG guidelines advocate myomectomy instead of UAE in women with a wish to future pregnancy. Both the Dutch NVOG and French CNGOF guidelines indicate that UAE and hysterectomy have similar 5 year quality of life and satisfaction rates but higher re-interventions rates following UAE should be taken into account during the decision making process with the woman. The French CNGOF guidelines indicate

Table III. — Treatment options for AUB/HMB secondary to uterine pathology.

	United Kingdom	The Netherlands	France	Canada
Endometrial polyps	No recommendation	Do not routinely remove polyps for HMB, but remove for IMB Polyp removal preferably in outpatient setting	Polyp resection when pregnancy desired Polyp resection in combination with FEAT or SEAT when pregnancy not desired	Polyp removal
Submucosal fibroids	Fibroid resection when < 3 cm	Fibroid resection when < 4 cm	Fibroid resection for type 0-2 fibroids	Fibroid resection
Other fibroids	Tranexamic acid, NSAIDs, LNG-IUS, CHC, progestins SEAT when pregnancy not desired Myomectomy or UAE when pregnancy desired Hysterectomy	LNG-IUS when future pregnancy is desired SEAT when pregnancy not desired Myomectomy when pregnancy desired UAE when pregnancy not desired Hysterectomy	LNG-IUS when pregnancy desired EA when pregnancy not desired Myomectomy or UAE when pregnancy desired Hysterectomy	Myomectomy, UAE, hysterectomy
Adenomyosis	Tranexamic acid, NSAIDs, LNG-IUS, CHC, progestins, progesterone only contraceptives	No recommendation	LNG-IUS when pregnancy desired FEAT or SEAT when pregnancy not desired but wish to preserve uterus Hysterectomy	

LNG-IUS: Levonorgestrel intrauterine system, EA: Endometrial ablation, NSAIDs: nonsteroid anti-inflammatory drugs, SEAT: second generation endometrial ablation therapies, FEAT: first generation endometrial ablation/resection therapies.

that both myomectomy and UAE can be offered to women who desire pregnancy but they should be informed of uncertainties about the impact of UAE on subsequent fertility and risk of miscarriage. The NICE guidelines recommend that both myomectomy and UAE can be considered in these women without any warning on future fertility. Both the NICE and CNGOF guidelines indicate that endometrial ablation can also be considered before hysterectomy in women who no longer desires pregnancy when the uterus is smaller than a certain size (no larger than 10 weeks in NICE and when hysterometry is < 12 cm in CNGOF guidelines).

Treatment options for adenomyosis are included in the group with no underlying pathology in the NICE guidelines. The NVOG guidelines do not cover adenomyosis separately but state that UAE for adenomyosis should only be performed in research settings. The CNGOF guidelines recommend LNG-IUS as first line treatment when fertility or uterine preservation is desired, endometrial resection or ablation to those who do not want to become pregnant but wish to preserve their uterus and hysterectomy when there is no desire to preserve fertility/uterus. They did not make a specific recommendation on UAE for adenomyosis related AUB but indicated that it can be considered.

Conclusions

There are a number of available national guidelines on the assessment and/or management of AUB or HMB. The scope, length and details of these documents and the way they are structured vary considerably. Guidelines that have been prepared more recently tend to have a defined methodology in line with internationally agreed standards on evidence based guideline development. The guidelines use the same published evidence on most clinical questions or conditions, hence there is an overall agreement between the majority of the guidelines. However, as outlined in this article,

there are also major differences on certain subjects. These are likely to be a reflection of variations in clinical practice in different countries, as the differences are difficult explain with emergence of new evidence. The guidelines that have been summarised and compared in this article were mostly prepared in the last 10 years and were mostly updated in the last 5 years. Hence the evidence they looked at would have been very similar.

The similarities between the guidelines give an opportunity to create international guidelines which may be more influential globally. Such a document would be more widely accepted by the clinicians and women alike, potentially reduce variability of access to the best treatments available and improve the lives of sufferers. Benefits of such global documents can be seen in the example of the FIGO PALM-COEIN classification which are now widely used. A similar approach to management of AUB/HMB can have the same impact globally. However, as outlined in the current articles, there are a number of challenges in creating such a guideline including financial costs, logistical difficulties in arranging participation from all parts of the world and linguistic challenges. Major international societies and their collaborations may be able to find a way forward to achieve this task.

References

ACOG committee opinion no. 557: Management of acute abnormal uterine bleeding in nonpregnant reproductive-aged women. Obstet Gynecol. 2013;121:891-6.

Australian Commission on Safety and Quality in Health Care – Heavy menstrual bleeding Clinical Care Standard, 2017, https://www.safetyandquality.gov.au/sites/default/files/migrated/Heavy-Menstrual-Bleeding-Clinical-Care-Standard.pdf, accessed on 30 August 2023

Brun JL, Plu-Bureau G, Huchon C et al. Management of women with abnormal uterine bleeding: Clinical practice guidelines of the French National College of Gynaecologists and Obstetricians (CNGOF). Eur J Obstet Gynecol Reprod Biol. 2023;288:90-107.

DGGG (Deutsche Gesellschaft für Gynäkologie und Geburtshilfe), Indikation und Methodik der Hysterektomie bei benignen Erkrankungen, 2015. https://www.dggg.de/fileadmin/data/Presse/Pressemitteilungen/2015/Patientinnen_mit_Blutungsstoerungen_und_gutartigen_Gebaermuttererkrankungen_Mehr_Lebensqualitaet_dank_individualisierter__leitliniengerechter_Therapie/015-070l_S3_Indikation_und_Methodik_der_Hysterektomie_2015-08.pdf

Munro MG, Critchley HOD, Fraser IS. FIGO Menstrual Disorders Committee. The two FIGO systems for normal and abnormal uterine bleeding symptoms and classification of causes of abnormal uterine bleeding in the reproductive years: 2018 revisions. Int J Gynaecol Obstet. 2018;143:393-408.

NICE – National Institute for Health and Care Excellence. Heavy menstrual bleeding: assessment and management. https://www.nice.org.uk/guidance/ng88/chapter/Recommendations#investigations-for-the-cause-of-hmb, 2018, last updated May 2021, accessed on 30 August 2023

NHG – (Nederlands Huisartsen Genootshap), NHG-Standaard Vaginaal bloedverlies, 2014, https://richtlijnen.nhg.org/standaarden/vaginaal-bloedverlies, last updated April 2023, accessed 30 August 2023

NVOG-(Nederlandse Vereniging voor Obstetrie en Gynaecologie) – Heavy menstrual bleeding, 2013 https://richtlijnendatabase.nl/richtlijn/hevig_menstrueel_bloedverlies/startpagina_-_hevig_menstrueel_bloedverlies_hmb.html, last reviewed on 30 June 2023, accessed on 30 August 2023

SIGO - Societá italiana di Ginecologica e Ostetricia. Raccomandazioni per l'approccio diagnostico-terapeutico ai flussi menstruali abbondanti. 2006, https://www.sigo.it/linee-guida/sigo

Singh S, Best C, Dunn S, Leyland N, Wolfman WL. No. 292-Abnormal Uterine Bleeding in Pre-Menopausal Women. J Obstet Gynaecol Can. 2018;40:e391-e415.

Socieda Espanola de Ginecologica y Obstetricia. Sangrado menstrual abundante (SMA) (actualizado 2013). Prog Obstet Ginecol. 2013;56:535-46.

doi.org/10.52054/FVVO.15.M.095

Review

Nonsurgical treatment options for heavy menstrual bleeding*

M.Y. Bongers[1,2], T. Oderkerk[1,2], M. Herman[3], P.M.A.J. Geomini[1]

[1]Máxima Medical Centre, Department OB&GYN, Postbox 7777, 5500 MB, Veldhoven, The Netherlands; [2]Grow School for oncology and reproduction, Maastricht University, Universiteitssingel 40, 6229 ER Maastricht, The Netherlands; [3]Jeroen Bosch Hospital, Department OB&GYN, Henri Dunantstraat 1, 5223 GZ 's-Hertogenbosch, The Netherlands.
**This article was not peer reviewed by Facts, Views and Vision. The lead author was commissioned by Hologic.*

Correspondence at: Prof Dr M.Y. Bongers. E-mail: m.bongers@mmc.nl

Abstract

Treatment options for heavy menstrual bleeding depend on the uterine anatomy, the women's preferences and personal ideas, her age and her future child wish. If the uterus has a normal anatomy, treatment options include hormonal or non-hormonal drugs (including levonorgestrel releasing intra-uterine systems; LNG-IUS), endometrial ablation and hysterectomy. In general, the main advantage of pharmacological treatment is the reversibility and therefore the eligibility for women, independent of age and future child-wish. This article provides a literature review on the effectiveness of medical treatment (hormonal and non-hormonal) for heavy menstrual bleeding and to discuss the dilemmas experienced by women and doctors. A literature search was performed focusing on the effectiveness of hormonal and non-hormonal medical treatment of women suffering from heavy menstrual bleeding. For nonsteroidal anti-inflammatory drugs (NSAIDs) as well as tranexamic acid, direct evidence for comparison to placebo is available, for the other agents (oral progestins (luteal phase and long term); LNG-IUS; combined hormonal contraceptives (combined oral contraceptive pills, combined vaginal ring), evidence could be extracted from a recent network meta-analysis. Evidence on treatment effects on HMB of the progesterone only pill and the etonogestrel subdermal implant is lacking. LNG-IUS appears to be the best pharmacological treatment option for HMB in terms of reducing blood loss as well as improving symptoms. Professionals should be aware that a number of women want to avoid a hormone-containing treatment, this may be due to (expected) negative side effects. In conclusion, considering pharmacological treatment of HMB without underlying pathology, LNG-IUS seems to be the best option to reduce menstrual blood loss. However, it is advised to carefully listen what women want, think and believe and to make a shared tailor-made decision. Pharmacological treatment for HMB should be initiated as a surgical intervention can be avoided. However, women who are not receptive to first-line drug treatments should be given the opportunity to improve their quality of life by getting rid of disabling symptoms of heavy menstrual bleeding, by offering treatment with endometrial ablation or hysterectomy.

Introduction

Heavy menstrual bleeding (HMB) is excessive menstrual bleeding with a negative impact on a woman's life (NICE, 2018; Matteson Clark et al, 2010). Around 30% of women suffer from HMB at some time during their reproductive years making it a common reason for gynaecological consultations in both primary and secondary care (NICE, 2018; Fraser et al., 2015). Traditionally, HMB is objectively measured as blood loss of more than 80 mL per cycle (Hallberg et al., 1996). It is uncertain if women can judge their blood loss objectively enough. However, over time it seems that a woman's perception of blood loss seems to correlate with the objective amount of bleeding (Warner et al., 2004). Therefore, in clinical practice women's perception of their symptoms often leads to diagnosing and treating HMB. It is important to offer women an effective and tailor-made treatment for HMB. In order to make a well-informed and shared treatment decision, women's preferences, treatment effectiveness and differences in treatment characteristics must be considered.

The endometrium is a dynamic tissue regulated by ovarian steroid hormones, mainly oestrogen and progesterone (Jabbour et al., 2006). In response to fluctuations of the ovarian steroid concentrations, the endometrium undergoes cycles of proliferation, differentiation and breakdown of the superficial stratum functionalis (Henriet et al., 2012). This process leads to the monthly bleeding, the so-called menstrual period. Any process interfering with a part of the female reproductive tract can cause HMB (Hapangama Bulmer et al., 2016; Wouk Helton et al., 2019). According to the FIGO classification system, there are nine main categories which can cause abnormal uterine bleeding (Munro et al., 2011). These categories are arranged according to the acronym PALM-COEIN: polyp; adenomyosis; leiomyoma; malignancy and hyperplasia; coagulopathy; ovulatory dysfunction; endometrial; iatrogenic; not yet classified (Munro et al., 2011). The components of the PALM group are structural aetiologies which can be assessed with imaging techniques or histopathology. The COEIN group is related to non-structural aetiologies. In women with HMB, uterine fibroids and polyps are the most common pathology found. However, in the majority of women no underlying pathology is diagnosed (NICE, 2018). The options of treatment will depend on the anatomy of the uterus, women's preferences and her personal ideas, her age and her wish to conceive in future. In case of normal anatomy of the uterus, treatment options involve hormonal or non-hormonal drugs (including levonorgestrel releasing intra-uterine systems; LNG-IUS), endometrial ablation and hysterectomy. Hysterectomy seems to be most cost-effective treatment (Roberts et al., 2011; Spencer et al., 2017). Moreover, treatment of HMB starting with LNG-IUS seems to be cheaper but slightly less effective than endometrial ablation (van den Brink et al., 2021).

In this article we focus on pharmacological treatments to reduce menstrual bleeding. In general, the main advantage of pharmacological treatment is the reversibility and therefore the eligibility for women, independent of age and future child-wish. However, women seem to become more critical to take hormones for cycle regulation (van den Brink et al., 2018). From this perspective, following the scientific results of non-surgical treatment for HMB, the dilemmas experienced by women and doctors will be discussed.

Pharmacological treatment of HMB

In women without underlying pathology pharmacological treatment can be initiated both in general and gynaecological practices. Pharmacological treatments include non-hormonal therapies; tranexamic acid (TxA) or non-steroidal anti-inflammatory drugs (NSAIDs), and hormonal therapies: progestogens, the LNG-IUS and combined oral contraceptive pills (COCP).

Tranexamic Acid (TxA), Antifibrinolytics

When bleeding occurs somewhere in the body, a network of fibrin filaments is temporarily formed, creating a blood clot and stopping the bleeding. During fibrinolysis these fibrin filaments are broken down again. TxA is an antifibrinolytic agent and reversibly blocks lysine-binding sites on plasminogen molecules. Conversion of plasminogen to plasmin is inhibited, making a blood clot less likely to dissolve. The fibrinolytic activity of menstrual blood appears to be significantly higher than that of peripheral blood. Moreover, fibrinolytic activity is even higher in the menstrual blood of patients with HMB compared with the control subjects.

Non-steroidal anti-inflammatory drugs (NSAIDs)

The precise mechanism by which excessive blood loss occurs remains speculative, especially in women without underlying pathology diagnosed. Willman et al showed higher levels of prostaglandin E2 and prostaglandin F2a in the endometrium of women with excessive menstrual bleeding when compared with women with normal menses (Willman et al., 1976). NSAIDs reduce prostaglandin levels by inhibiting the cyclo-oxygenase enzymes and therefore NSAIDs are known to reduce menstrual blood loss.

Progestogens

In the human menstrual cycle, progesterone activity plays a major role in the secretory phase. Progesterone is produced by the corpus luteum and is required for the establishment and maintenance of a pregnancy. After 10-14 days regression of the corpus luteum occurs and consequently the level of progesterone diminishes sharply. The progesterone withdrawal induces the breakdown of the functional layer of the endometrium, resulting in a bleeding which we call the menstruation. In case of anovulatory cycles, the oestrogen dominated endometrium is not organised by progesterone (as a corpus luteum is lacking) and prolonged uncontrolled bleeding can happen. In such emergency cases, administering (oral) progestins will help to stop heavy uterine bleedings. Moreover, progesterone has a strong anti-inflammatory effect and therefore could help to control HMB. The term 'progesterone' refers to the natural hormone, whereas 'progestin' refers to a synthetic product; and 'progestogens' include both kinds, the natural hormone as well as the synthetic

products. Progestins are divided in four generations, pointing to the timing of introduction. Their progestogenic effects, androgenic and oestrogenic effects differ.
Progestin therapy for HMB can be divided in cyclical therapy (during the luteal phase only) and long cycle progestins (three to four weeks regimes).

The leading progesterone only pill (POP) on the European market is desogestrel which is administered in a dose of 75mcg each day, continuously (Benagiano Primiero, 2008). Desogestrel is a third-generation progestin and it is often prescribed during breastfeeding period due to the relative contraindication for oestrogens during breastfeeding. Another advantage of POPs is the favourable cardiovascular profile compared to combined contraceptive pills. However, irregular bleeding may occur, which may be a reason for women to stop taking POPs (Hooper et al., 2010).
Etonogestrel subdermal implant(ESI) is a safe long-acting reversible contraceptive during at least three years. Etonogestrel is an active metabolite of the third generation progestin desogestrel. Like all progestogens, also etonogestrel induces endometrial changes, and therefore changes bleeding patterns (Mansour et al., 2008; Funk et al., 2005).

LNG-IUS

Levonorgestrel-releasing intrauterine system 52 mg (LNG-IUS, Mirena®, Bayer HealthCare Pharmaceuticals, Germany or Levosert®, Gedeon Richter, Budapest, Hungary) is a hormonal contraceptive and is proven as an effective treatment for HMB (Health Quality Ontario 2016). The LNG-IUS decreases menstrual bleeding by the local release of levonorgestrel which suppresses endometrial growth, by which it effectively reduces menstrual blood loss and increases quality of life (Lethaby et al., 2015). Advantages of the LNG-IUS are the contraceptive effect, the reversibility and the possibility to be inserted by both the general practitioner and the gynaecologist. Despite the general efficacy and advantages, around 40% of women discontinue the LNG-IUS within two years (Beelen et al., 2021). The discontinuation is mostly because of a lack of effectiveness, irregular bleeding, abdominal pain, or progestogenic side effects (Beelen et al., 2021).

Combined hormonal contraceptives

Combined hormonal contraceptive methods contain oestrogen and progestin. Several schedules and routes of delivery are available, including oral, vaginal, transdermal and intramuscular. Not all routes of delivery have been assessed for the treatment of HMB, only the combined oral contraceptive pill (COCP) and the combined vaginal ring (CVR) (Lethaby et al., 2019). Combined hormonal contraceptives have been associated with a higher risk of thrombotic adverse events, although the oestrogen dose has been gradually reduced from 150 μg in the original preparations to 30 μg or less, significantly reducing the risk. The combined hormonal contraceptives are now only associated with a small increased risk of venous thromboembolism (De Bastos et al., 2014). Oestrogen provides negative feedback on follicle-stimulating hormone secretion and prevents the development of a dominant follicle (Bradley Guye., 2016), providing endometrial stability and growth, improving the progestational impact. At the same time, progestin impedes the rise of luteinising hormone and consequently prevents ovulation and creates an atrophic endometrial lining. This combination reduces overall menstrual blood loss. So, combined hormonal contraceptives have two beneficial effects, inducing a regular shedding of a thinner endometrium and inhibiting ovulation, thus having the effect of both treating HMB and providing contraception.

Effectiveness of pharmacological treatment options

All these medical treatment options have recently been evaluated in an extensive network meta-analysis based on Cochrane reviews evaluating first- and second line interventions for HMB (Bofill Rodriguez et al., 2022). Primary outcomes in this review are menstrual bleeding and satisfaction. Firstline treatment options are compared to placebo as well as compared to each other. For NSAID's as well as TxA, direct evidence for comparison to placebo is available, for the other agents (oral progestins (luteal phase and long term); LNG-IUS; combined hormonal contraceptives (COCP, CVR), evidence is extracted just from the network meta-analysis. The POP as well as the ESI are excluded from the meta-analysis network, however included in this review.

Comparison to placebo

Antifibrinolytics (TxA), NSAIDs, long cycle progestogens and LNG-IUS appeared to be linked to a decrease in average blood loss in comparison to placebo. See Table I (Bofill Rodriquez et al., 2022). Certainty of evidence was moderate to very low. For the POP (desogestrel) and the ESI, data on treatment effect in case of HMB appeared to be lacking.

Table II shows results for women's perception of heavy menstrual bleeding improvement (Bofill

Table I. — Reduction in menstrual blood loss with drug treatments compared to placebo.

	Mean difference of blood loss compared to placebo (ml per cycle)	95% CI
TxA	-80,32	-127,67 to -32,98
NSAIDs	-40,67	- 84,61 to 3,27
POP	NA	NA
Cyclic progesterone(luteal phase)	-19,1	- 87,81 to 49,61
Long cycle progesterone	-76,93	- 153,82 to -0.05
ESI	NA	NA
LNG-IUS	-105,71	-201,1 to -10,3
COCP	-56,08	-140,88 to 14,50
CVR	-81,53	-177,56 to 14,50

TxA: Tranexamic acid, NSAIDs: Nonsteroidal anti-inflammatory drugs, POP: Progesterone only pill, ESI: Etonogestrel subdermal implant, LNG-IUS: Levonorgestrel-Intrauterine system, COCP: Combined oral contraceptive pill, CVR: Combined vaginal ring, NA: Not available.

Rodriquez et al., 2022). TxA, NSAID's, LNG-IUS and COCPs appeared to improve women's perception of treatment in comparison to placebo.

Comparison to other treatment options

The network meta-analysis of Bofill Rodriquez et al. (Bofill Rodriquez et al., 2022) also presents the surface under the cumulative ranking curve (SUCRA), enabling comparison of several treatment options to each other. SUCRA is a numeric representation of the overall ranking. It has a single number associated with each treatment, and the values range from 0% to 100% (Bofill Rodriquez et al., 2022). The larger the SUCRA, the higher the chances a treatment is ranked highest among all the available treatments. On the contrary, the lower the SUCRA, the more likely the intervention is to be ranked near the bottom.

The best treatment for reducing menstrual bleeding was LNG-IUS (SUCRA 100%), second long-cycle progestogen (SUCRA 80%) and third, TxA (SUCRA 80%).

The best HMB treatment in terms of perception of improvement was LNG-IUS (SUCRA 80%), second best was danazol (SUCRA 70%) and on rank three, CVR (SUCRA 70%). On rank four and five they found TxA (SUCRA 70%) and NSAIDs (SUCRA 50%). The lowest ranking is for long-cycle progestogens (SUCRA 50%), COCP (SUCRA 40%) and luteal progestogen. Nowadays, danazol is not used anymore to reduce HMB because of the side-effects.

In conclusion, both from a perspective of reduction of blood loss and from a perspective of perception of improvement of symptoms, the LNG-IUS appears to be the best pharmacological treatment option for HMB. In line with this conclusion, the NICE guideline recommends LNG-IUS as first line treatment for women suffering from HMB without underlying pathology, or the use of other medical treatments if LNG-IUS is declined or not suitable (TxA, NSAIDs, combined hormonal contraception, oral progestogens).

Patient preference

Few studies have been performed on patient preference and the treatment for HMB. Van den Brink et al. evaluated patient preference for the LNG-IUS compared to the endometrial ablation (EA) (van den Brink et al., 2018). In a discrete choice experiment, a treatment without hormones had the most influence on women's decision. Possible reasons why women want to avoid a hormone-containing treatment may be due to (expected) negative side effects (Daud Ewies, 2008). Professionals should be aware of this and inform patients about hormone-related side effects (Dutton Kai, 2023). The treatment preferences of women in primary care seem to differ from those of women referred to the gynaecologist (van den Brink et al., 2018). The general practitioner (GP) is mostly the first professional with whom women share their complaints of HMB. At this point they may have other desires and expectations regarding a treatment as compared to their later visit with the gynaecologist.

A qualitative study in primary care has been published recently interviewing women suffering

Table II. — Women's perception of heavy menstrual bleeding improvement compared to placebo.

	Relative effect (Odds ratio)	95% CI
TxA	11.13	1,79 to 69,30
NSAIDs	7.24	1,19 to 44,01
POP	NA	NA
Cyclical progestogen(luteal phase)	3,30	0,44 to 24,68
Long cycle progestogen	5,78	0,43 to 77,71
ESI	NA	NA
LNG-IUS	20,73	1,60 to 267, 83
COCP	5,43	1,19 to 24,73
CVR	14,49	0,86 to 244,30

TxA: Tranexamic acid, NSAIDs: Nonsteroidal anti-inflammatory drugs, POP: Progesterone only pill, ESI: Etonogestrel subdermal implant, LNG-IUS: Levonorgestrel-Intrauterine system, COCP: Combined oral contraceptive pill, CVR: Combined vaginal ring, NA Not available.

from HMB. Women had often normalised their menstrual blood loss which underlines the societal taboos about HMB (Cooper et al., 2023). Women (for several years) delayed seeking for help. This probably reflects the relative low knowledge about treatment options for HMB. However, if they searched for help, they could be frustrated by lack of a medical explanation for the cause of HMB. Interestingly if pathology had been diagnosed, women felt better able to understand their HMB. Experiences of medical treatment varied considerably, but were strongly influenced by interactions with doctors. Other impacts on women's treatment included considerations regarding their fertility, health concerns, family and colleagues, and views on approaching menopause (Cooper et al., 2023).

Doctor's perspective

This article evaluates first-line non-surgical treatment which is mostly initiated by the GP. Data of the Registration Network Groningen (approximately 30 000 registered patients per year) can be used to investigate how many women consult their GP with symptoms of HMB. Between 2004 and 2013 a mean annual incidence of 9.3 per 1000 person years was found, most women aged 35-54 years (van den Brink et al., 2017). Most women received hormonal treatment (46%) within three months after diagnosis, but just as large a group (44%) received no medication at all. The LNG-IUS was prescribed only in 2.4% of the women (van den Brink et al., 2017).

In the ECLIPSE primary care trial, women with HMB were randomised between LNG-IUS versus other usual medical treatments (oral TxA, mefenamic acid, combined oestrogen–progestogen; or progesterone alone) (Gupta et al., 2013). Just over 50% of participating women reported to have turned postmenopausal at long-term follow-up, however 27.2% of women reported they were using LNG-IUS at the time of response to the 10-year follow-up (Kai et al., 2016). Moreover, data of ten year follow up showed sustained low rates of progression to surgical intervention (hysterectomy (16.5%) or endometrial ablation (12.6%)). This highlights the importance and value of initiating medical management of HMB in women in primary care.

Focus for future research

A perfect treatment is not only efficacy but contains also convenience, cost, adverse effects and women's preference and choices. The definition of success for HMB has been changed to quality of life (QOL) improvement. Therefore, this should be the primary outcome of the upcoming trials and studies dealing with HMB. However, until now QOL was reported with an enormous difference in lists and outcomes. The main goal should be to worldwide agree on the same QOL-list evaluating the impact of HMB and the improvement of treatment. This highlights the importance of developing a core outcome set (COS) for heavy menstrual bleeding trials that would facilitate more effective analysis and gives the opportunity to compare or augment data of different trials. The COMET initiative (Core Outcome Measures in Effectiveness Trial) has an ongoing project, defining core outcomes for clinical trials of heavy menstrual bleeding. Recently within this project two studies have been published (Cooper et al., 2023a; Cooper et al., 2023b). The final COS for HMB should include variables that

are feasible for use in clinical trials in all resource settings and apply to the PALM-COEIN causes of the symptom of HMB. These outcomes should be reported in all future trials of interventions, their systematic reviews, and clinical guidelines (Cooper et al., 2023a). Cooper et al. concluded in their article that the COS should consists of subjective blood loss; flooding; menstrual cycle metrics; severity of dysmenorrhoea; number of days with dysmenorrhoea; quality of life; adverse events; patient satisfaction; number of patients going on to have further treatment for HMB and haemoglobin level. It would be perfect if the same lists, the same graphs, the same tables and values were used when displaying all these results.

There is also a need to investigate the advantages and disadvantages comparing first line and second line treatment options for women suffering from HMB (Bergeron et al., 2020). The endometrial ablation (EA) has been compared to the LNG-IUS in a RCT (Beelen et al., 2021), showing a cost advantage for the LNG-IUS and a satisfaction rate of 76% and 84% for LNG-IUS and EA respectively (Beelen et al., 2021; van den Brink et al., 2021). In the end 24% of the women with an LNG-IUS after two years of follow-up had a reintervention, with a hysterectomy rate of 7% for the LNG-IUS group and 10% after EA (Beelen et al., 2021). However, the outcome of the EA can probably be improved by adding directly after ablation an LNG-IUS. A systematic review evaluating this combination shows a favourable outcome for the EA plus LNG-IUS (Oderkerk et al., 2021). A RCT needs to be done to elucidate the real advantages and outcome of this combination (Oderkerk et al., 2022).

Conclusion

Considering pharmacological treatment of HMB without underlying pathology, the results of this review suggests the LNG-IUS seems to be the best option to reduce menstrual blood loss. However, it is advised to carefully listen what the woman wants, thinks, believes and in the end make a shared decision. Pharmacological treatment should be initiated by GPs as a surgical intervention can be avoided. However, GPs should also have knowledge about the surgical (minimal) invasive solutions, in order to make a balanced personal decision. Women who prefer non-hormonal treatment for some reason and who are not receptive to other first line drug treatment should also be given the opportunity to improve their quality of life by getting rid of disabling symptoms of heavy menstrual bleeding, by offering treatment with endometrial ablation or hysterectomy.

References

Beelen P, van den Brink MJ, Herman MC et al. Levonorgestrel-releasing intrauterine system versus endometrial ablation for heavy menstrual bleeding. Am J Obstet Gynecol. 2021;224:187.e1–10.

Benagiano G, Primiero FM. Seventy-five microgram desogestrel minipill, a new perspective in estrogen-free contraception. Ann N Y Acad Sci. 2003;997:163-73.

Bergeron C, Laberge PY, Boutin A et al. Endometrial ablation or resection versus levonorgestrel intra-uterine system for the treatment of women with heavy menstrual bleeding and a normal uterine cavity: a systematic review with meta-analysis. Hum Reprod Update. 2020;26:302-11.

Bofill Rodriguez M, Lethaby A, Low C et al. Cyclical progestogens for heavy menstrual bleeding. Cochrane Database of Systematic Reviews. 2019;8:CD001016.

Bofill Rodriguez M, Lethaby A, Farquhar C. Non-steroidal anti-inflammatory drugs for heavy menstrual bleeding. Cochrane Database Syst Rev. 2019;9: CD000400.

Bofill Rodriguez M, Lethaby A, Jordan V. Progestogen-releasing intrauterine systems for heavy menstrual bleeding. Cochrane Database Syst Rev. 2020;6:CD002126.

Bofill Rodriguez M, Dias S, Jordan V, Lethaby A, Lensen SF, Wise MR, Wilkinson J, Brown J, Farquhar C. Interventions for heavy menstrual bleeding; overview of Cochrane reviews and network meta-analysis. Cochrane Database Syst Rev. 202231;5:CD013180.

Bradley LD, Gueye NA. The medical management of abnormal uterine bleeding in reproductive-aged women. Am J Obstet Gynecol. 2016;214:31-44.

Cooper NAM, Rivas C, Munro MG et al. Standardising outcome reporting for clinical trials of interventions for heavy menstrual bleeding: Development of a core outcome set. BJOG. 2023a;130-1337-45.

Cooper NAM, Yorke S, Tan A, Khan KS, Rivas C. Qualitative study exploring which research outcomes best reflect women's experiences of heavy menstrual bleeding: stakeholder involvement in development of a core outcome set. BMJ Open. 2023b;13:e063637.

Daud S, Ewies AA. Levonorgestrel-releasing intrauterine system: why do some women dislike it? Gynecol Endocrinol. 2008;24:686-90.

De Bastos M, Stegeman BH, Rosendaal FR, Van Hylckama Vlieg A, Helmerhorst FM, Stijnen T, Dekkers OM. Combined oral contraceptives: venous thrombosis. Cochrane Database Syst Rev. 2014 Mar 3;(3):CD010813.

De Vries CJ, Meijer LJ, Janssen CA et al. Dutch College of General Practitioners' practice guideline on 'Vaginal bleeding']. Ned Tijdschr Geneeskd. 2015;159:A8534.

Dutton B, Kai J. Women's experiences of heavy menstrual bleeding and medical treatment: a qualitative study in primary care. Br J Gen Pract. 2023;73:e294-e301.

Fraser IS, Mansour D, Breymann C et al. Prevalence of heavy menstrual bleeding and experiences of affected women in a European patient survey. Int J Gynaecol Obstet. 2015;128:196-200.

Funk S, Miller MM, Mishell DR Jr et al. Implanon US Study Group. Safety and efficacy of Implanon, a single-rod implantable contraceptive containing etonogestrel. Contraception. 2005;71:319-26.

Gupta J, Kai J, Middleton L, Pattison H et al. Levonorgestrel intrauterine system versus medical therapy for menorrhagia. N Engl J Med. 2013;368:128-37.

Hallberg L, Hogdahl AM, Nilsson L et al. Menstrual blood loss--a population study. Variation at different ages and attempts to define normality. Acta Obstet Gynecol Scand. 1966;45:320-51.

Hapangama DK, Bulmer JN. Pathophysiology of heavy menstrual bleeding. Womens Health (Lond). 2016;12:3-13.

Health Quality Ontario. Levonorgestrel-Releasing Intrauterine System (52 mg) for Idiopathic Heavy Menstrual Bleeding: A

Health Technology Assessment. Ont Health Technol Assess Ser. 2016;16:1-119
Henriet P, Gaide Chevronnay HP, Marbaix E. The endocrine and paracrine control of menstruation. Mol Cell Endocrinol. 2012;358:197-207.
Hooper DJ. Attitudes, awareness, compliance and preferences among hormonal contraception users: a global, cross-sectional, self-administered, online survey. Clin Drug Investig. 2010;30:749–63.
Jabbour HN, Kelly RW, Fraser HM et al. Endocrine regulation of menstruation. Endocr Rev. 2006;27:17-46.
Kai J, Middleton L, Daniels J et al. ECLIPSE trial collaborative group. Usual medical treatments or levonorgestrel-IUS for women with heavy menstrual bleeding: long-term randomised pragmatic trial in primary care. Br J Gen Pract. 2016;66:e861-e870.
Kai J, Dutton B, Vinogradova Y et al. Medical treatment for heavy menstrual bleeding in primary care: 10-year data from the ECLIPSE trial. Br J Gen Pract. 2022 Nov 24;72(725):e857-e864.
Lethaby A, Hussain M, Rishworth JR et al. Non-steroidal anti-inflammatory drugs for heavy menstrual bleeding. Cochrane Database Syst Rev. 2015;4:CD002126.
Lethaby A, Wise MR, Weterings MA et al. Combined hormonal contraceptives for heavy menstrual bleeding. Cochrane Database Syst Rev. 2019;2:CD000154.
Lethaby A, Hussain M, Rishworth JR et al. Progesterone or progestogen-releasing intrauterine systems for heavy menstrual bleeding. Cochrane Database Syst Rev. 2015;4:Cd002126.
Matteson KA, Clark MA. Questioning our questions: do frequently asked questions adequately cover the aspects of women's lives most affected by abnormal uterine bleeding? Opinions of women with abnormal uterine bleeding participating in focus group discussions. Women Health. 2010;50:195-211.
Mansour D, Korver T, Marintcheva-Petrova M et al. The effects of Implanon on menstrual bleeding patterns. Eur J Contracept Reprod Health Care. 2008;13 (Suppl 1):13-28).
Munro MG, Critchley HO, Broder MS et al. FIGO classification system (PALM-COEIN) for causes of abnormal uterine bleeding in nongravid women of reproductive age. Int J Gynaecol Obstet. 2011;113:3-13.
National Institute for Health and Care and Excellence .Heavy menstrual bleeding: assessment and management NG88 (NICE, London). 2018.https://wwwniceorguk/guidance/ng88
Ont Health Technol Assess Ser. Levonorgestrel-Releasing Intrauterine System (52 mg) for Idiopathic Heavy Menstrual Bleeding: A Health Technology Assessment. 2016;16:1-119.
Oderkerk TJ, van de Kar MMA, van der Zanden CHM et al. The combined use of endometrial ablation or resection and levonorgestrel-releasing intrauterine system in women with heavy menstrual bleeding: A systematic review. Acta Obstet Gynecol Scand. 2021;100:1779-87.
Oderkerk TJ, Beelen P, Geomini PMAJ et al. Endometrial ablation plus levonorgestrel releasing intrauterine system versus endometrial ablation alone in women with heavy menstrual bleeding: study protocol of a multicentre randomised controlled trial; MIRA2 trial. BMC Womens Health. 2022;22:257.
Richtlijn Hevig Menstrueel Bloedverlies. NVOG. https://richtlijnendatabase.nl/richtlijn/hevig_menstrueel_bloedverlies.
Roberts TE, Tsourapas A, Middleton LJ et al. Hysterectomy, endometrial ablation, and levonorgestrel releasing intrauterine system (Mirena) for treatment of heavy menstrual bleeding: cost effectiveness analysis. BMJ. 2011;342:d2202.
Spencer JC, Louie M, Moulder JK et al. Cost-effectiveness of treatments for heavy menstrual bleeding. Am J Obstet Gynecol. 2017;217:574 .e1-574.e9.
van den Brink MJ, Beelen P, Herman MC et al. Women's preferences for the levonorgestrel intrauterine system versus endometrial ablation for heavy menstrual bleeding. Eur J Obstet Gynecol Reprod Biol. 2018;228:143-7.
van den Brink MJ, Saaltink AL, Groenhof F et al. Incidence and treatment of heavy menstrual bleeding in general practice Fam Pract. 2017;34:673-8.
van den Brink MJ, Beelen P, Herman MC et al. The levonorgestrel intrauterine system versus endometrial ablation for heavy menstrual bleeding: a cost-effectiveness analysis. BJOG. 2021;128:2003-11.
Warner PE, Critchley HO, Lumsden MA et al. Menorrhagia I: measured blood loss, clinical features, and outcome in women with heavy periods: a survey with follow-up data. Am J Obstet Gynecol. 2004;190:1216-23.
Willman EA, Collins WP, Clayton SG. Studies in the involvement of prostaglandins in uterine symptomatology and pathology. Br J Obstet Gynaecol. 1976;83:337-41.
Wouk N, Helton M. Abnormal Uterine Bleeding in Premenopausal Women. Am Fam Physician. 2019;99:435-43.

doi.org/10.52054/FVVO.15.M.098

Review

Endometrial ablation in the Outpatient Setting*

S. Martinez[1], A. Megia[1], C. Alvarez[2]

[1]*Department of Obstetrics and Gynaecology, Hospital Universitario Torrecárdenas, Almería, Spain;* [2]*Department of Obstetrics and Gynaecology, Hospital Universitario La Paz, Madrid, Spain.*

This article was not peer reviewed by Facts, Views and Vision. The lead author was commissioned by Hologic.

Correspondence at: Sonia Martinez Morales. E-mail: smartinezm26@gmail.com

Abstract

Endometrial ablation techniques are a minimally invasive, safe and satisfying option for heavy menstrual bleeding (HMB) treatment. The development of new faster devices with smaller diameters has made it possible to perform these procedures in office and outpatient setting under local anaesthesia with high patient satisfaction, fewer complications, shorter hospital stays and quicker recovery time reducing costs. In this article we analyse the management protocols for endometrial ablation in the outpatient setting to provide the best treatment option. A bibliographic search from 2013 in the Medline, Embase, PubMed and Cochrane Library databases was carried out with the keywords: endometrial ablation, outpatient, local anaesthesia, fundal block.
Most studies reviewed show that 2nd generation endometrial ablation techniques are safer, faster, and equally effective for treatment of HMB than 1st generation ones and can be safe and feasible under local anaesthesia in office and outpatient setting. The combination of either intra- or paracervical anaesthesia with intrauterine cornual or fundal block is more effective at reducing pain. Levobupivacaine and Ropivacaine are the anaesthetics of choice due to their potency duration with low adverse effects.
Women should be encouraged to play an active role in selecting the type of surgery the setting and the model of care, based on a complete information, their personal preferences and expectations.
Some aspects such as age, intention to become pregnant, other symptoms or comorbidities and failure of previous treatments will help to make the best choice.

Keywords: **Endometrial ablation, local anaesthesia, fundal block, heavy menstrual bleeding, outpatient setting.**

Introduction

Heavy menstrual bleeding (HMB) is an important health problem for women of reproductive age because it can affect physical health and quality of life. It represents about 30% of total gynaecological visits and entails important costs and loss of productivity (Miller et al., 2015; Fraser et al., 2015))

First line treatment includes progestogen-releasing intrauterine systems (Pg-IUS or LNG-IUS) which is considered the best and secure option to reduce menstrual blood loss, followed by antifibrinolytics, non-steroidal anti-inflammatory drugs (NSAIDs), long-acting progestogens, and combined hormonal contraceptives. Surgery is recommended as a second-line treatment of heavy menstrual bleeding (HMB). Although hysterectomy is a definitive treatment for HMB with higher satisfaction rates, preferably minimally invasive hysterectomy, endometrial resection/ablation (ER/EA) techniques represent a less invasive alternative, especially for those patients who want to preserve their uterus. They require a shorter hospital stay, allow a quicker return to normal activity compared with hysterectomy and have fewer postoperative complications (Bofill Rodríguez et al., 2022; NICE, 2018).

Over the years, numerous devices have been developed for performing endometrial ablation that allow the procedure to be carried out under local anaesthesia since they do not require cervical dilation due to their smaller diameter. This has made it possible to safely perform in-office ablation, improving patient satisfaction and reducing costs.

Most of the publications that analyse endometrial ablation under local anaesthesia focus mainly on pain tolerance, patient satisfaction and adverse effects, however they do not describe the infiltration technique, or the anaesthetics used in detail.

Performing endometrial ablation under local anaesthesia using potent, long-acting drugs not only provide a good pain control during the procedure, but also effective analgesia during the immediate postoperative period that can last up to 8 hours, so that the need of oral analgesic medication is significantly reduced.

It is important to improve training in local anaesthesia for ablation so that we can offer this option to our patients safely and effectively.

Objectives

In this section we will summarise the outpatient management protocols for endometrial ablation in the outpatient setting, the premedication administered, the anaesthetic techniques, the drugs used and their differences and the medication in the postoperative period. In addition to knowing the most important aspects for the selection of patients, we must provide them with the relevant information so that they can choose the most appropriate type of treatment for their HMB.

Methods

A bibliographic search of publications on ambulatory endometrial ablation from 2013 onwards was carried out in the Medline, Embase, PubMed and Cochrane Library databases. The keywords used were endometrial ablation, outpatient setting, local anaesthesia, and fundal block.

The type of studies selected were Cochrane reviews, controlled clinical trials, systematic reviews, randomized controlled trials and metaanalyses. Articles were selected based on the content and the quality of the study.

Results

Selection of patients

Endometrial ablation is indicated in women of premenopausal age with heavy menstrual bleeding of benign aetiology, with normal cavity less than 10cm in length, without uterine abnormalities or fibroids greater than 3 cm in diameter in whom medical treatment has failed or is contraindicated. Prior classic caesarean scar or transmural myomectomy may increase the risk of damage to surrounding structures, so in these cases it may be best to perform resectoscopic endometrial ablation. Active pelvic infections should also be excluded.

The endometrium of all candidates for endometrial ablation must be sampled, and histopathologic results should be reviewed before the procedure. The possibility of pregnancy cannot be excluded after an endometrial ablation, therefore women undergoing this procedure should be counselled to use appropriate contraception (Vitale et al., 2023; Reinders et al., 2016). Patients should be given choice for endometrial ablation either with or without general anaesthesia in the office or in the operating room. For women with increased surgical risks or with contraindications for medical treatment due to pre-existing comorbidities, endometrial ablation may be a minimally invasive therapeutic option for the treatment of heavy menstrual bleeding (Vitale, 2023).

For outpatient/office procedures patient consent is essential, so we must inform about aspects such as pre-medication and type of anaesthesia that will be administered, they must know that a certain degree of discomfort is normal, for which the necessary medication will be administered. They must also be informed in advance about the estimated time of the procedure and the stay in the hospital until discharge as well as possible course of the postoperative period.

A thorough medical evaluation is also necessary. Patients with significant or poorly controlled pathologies such as heart disease, cerebrovascular disease, metabolic disease, uncontrolled hypertension, severe anaemia, respiratory disease, sepsis, gastrointestinal insufficiency, morbid obesity, toxic habits that may interfere with the medication administered and with a known or expected difficult airway should be excluded from "in office" procedures. Vital signs must be normal, and they must have a patent nasal airway and be free of respiratory tract infection. Patients with significant learning difficulties or severe mental illness are not candidates for procedures under local anaesthesia in an outpatient setting. Patients must be accompanied by a person who can ensure transport home and provide home care after discharge and can detect possible complications. The distance to the hospital should be less than an hour.

Surgical intervention

Type of procedure

Endometrial resection and endometrial ablation are effective, minimally invasive and safe procedures that destroy the endometrium by entering the uterine cavity directly through the cervix. They are usually classified into two groups:

1st generation techniques or resectoscopic endometrial ablation or endometrial resection

(REA/ER), require direct visualisation of the uterine cavity through a surgical hysteroscope and use different forms of energy such as monopolar or bipolar electrocoagulation with rollerball, transcervical endometrial resection (TCRE) with a loop or vaporisation with a specific device.

2nd generation techniques or non-resectoscopic endometrial ablation (NREA/EA) do not require direct visualisation or fluid distension of the uterine cavity. They can use different types of energy such as microwaves, hydrothermal ablation, bipolar energy or thermal balloon.

REA requires larger diameter instruments and is performed in the operating room under general or locoregional anaesthesia but can be done on ambulatory basis.

NREA uses thinner instruments, usually does not require cervical dilation and can be carried out either under general or loco-regional anaesthesia in the operating room or in office setting under local anaesthesia.

Ablation technologies are continuously improving with smaller and more rapid ablative devices (e.g., NovaSure V5, LiNA Librata, MiniTouch) (De Silva et al., 2021).

However, there are still many hospitals where new 2nd generation ablation techniques are not available.

Advantages and disadvantages of endometrial resection/ablation techniques

Second-generation techniques of EA are safer, quicker, and equally effective when compared with first-generation devices for treatment of HMB, furthermore, the potential for EA to be performed under local anaesthesia offers a considerable advantage. Satisfaction rates and reduction in HMB are similar with both approaches. Second-generation endometrial ablation should be considered for women with a normal uterus and HMB who are not planning a present or future pregnancy (Bofill et al., 2019).

When second generation technologies were compared, no significant differences were found in pain scores between radiofrequency ablation (with NovaSure) and thermal balloon ablation (with either Thermachoice III or Thermablate). Gupta et al reported lower anaesthetic requirements for cryoablation with Cerene compared with hyperthermic endometrial ablation (Gupta et al., 2022).

Time of ablation was shorter for NovaSure and Thermablate compared with Thermachoice III.

NovaSure also had better tolerance for the procedure, significantly higher rates of amenorrhoea after 12 months and more patients were completely satisfied when compared with Thermablate. The improvement of bleeding and dysmenorrhoea was higher although non-significant for NovaSure compared with Thermablate (De Silva et al., 2021).

Pretreatment is needed before non resectoscopic endometrial ablation except for bipolar radiofrequency. NovaSure has a built-in impedance system which calculates the endometrial thickness and the amount of energy to apply in each case.

The treatment usually applied is GnRH agonists, which entails an extra cost for procedures, although combined oral contraceptives, patch, ring, or progestogens can also be used. Another option for those patients who do not want hormonal treatment or have a contraindication for it, is to perform the procedure before the 10th day of the cycle.

Setting

First generation endometrial resection and ablation are usually performed in the operating room involving more need for staff and greater use of facilities, since after the procedure the patient will also require a stay in the recovery unit before discharge, however second-generation procedures can be done using local anaesthesia in many cases in an office setting, improving patient satisfaction, with less anaesthetic complications, shorter hospital stays and quicker recovery time. This increases efficiency and reduces overall healthcare costs (Ayesha et al., 2020).

A number of trials described the use of nonresectoscopic endometrial ablation devices with local anaesthesia and included the use of parenteral conscious sedation, which precludes these procedures in most office environments.

Analgesia pre- and post-procedure and follow up

Analgesia prior to the ablation and after the discharge is recommended because it reduces pain during the procedure and in the postoperative period due to the release of prostaglandins, mainly PGF2α, after cervical and endometrial manipulation. Published reports described administration of oral analgesics one hour before the procedure; NSAIDs (Diclofenac 50 mg or Naproxen 500mg) and Paracetamol 1g eventually associated to Dihydrocodeine 20-40mg and an antiemetic (cyclizine, 50 mg orally) (Kumar et al., 2016; Reinders et al., 2020). After the ablation patients were advised to use paracetamol 1000 mg every six hours and naproxen 500 mg every 12 hours for 1–2 days (depending on pain) or Tramadol 100mg and an antiemetic in case of contraindication for NSAIDs (Kumar et al., 2016; Reinders et al., 2020).

Pain experienced should be reported using a visual analogue scale. Specific questionnaires can be useful to evaluate acceptability of the procedures.

Local anaesthesia technique

Infiltration of the uterus with local anaesthesia reduces pain both during endometrial ablation and in the immediate postoperative period, therefore, this is the most valuable tool for pain control in outpatient procedures. Unlike general anaesthesia, the application of local anaesthesia has the advantage that the analgesic effect can remain for several hours depending on the drug used, this allows the patient to leave the hospital on her own and does not require oral analgesia in the immediate postoperative period. It also makes the procedure more satisfactory for the patient.

There is no standard protocol for the application of local anaesthesia and the type of anaesthetics used.

Direct cervical block (DCB) paracervical or intracervical are the most commonly used methods of local anaesthesia.

Paracervical block (PCB) involves several injections into the cervix at the level of the vaginal fornices, whereas intracervical block (ICB) involves injections directly into the cervix, but none of these techniques can provide anaesthesia to the upper part of the uterus because its innervation comes from a double pathway. The cervix and the lower half of the uterus is primarily innervated from inferior hypogastric plexus that forms the uterovaginal plexus, largely deriving from the parasympathetic sacral S2–4 nerve roots, whereas the upper half of the uterus is innervated from the thoracic nerves, deriving from the sympathetic fibres of the superior hypogastric plexus T8-T10 and L1 roots. These latter nerve fibres enter the uterus along the infundibulopelvic ligament and the path of the ovarian arteries.

The combination of either intra- or paracervical anaesthesia with intrauterine cornual block is more effective at reducing pain compared with intra- or paracervical anaesthesia alone and it is a safe approach to perform endometrial ablation under local anaesthesia (Figures 1,2 and 3) (Reinders et al., 2020; Kumar et al., 2016).

The guidelines for the application of local anaesthesia for endometrial ablation vary among different authors and, in many cases, the publications on endometrial ablation in patients without admission are difficult to compare because they talk about local anaesthesia but do not specify which drug was used or at what concentrations, which could lead to large variations in the assessment of pain during ablation, as well as in the first hours after the procedure, depending on the potency and duration of effect of the anaesthetic used (Table I).

Further paracervical and fundal block protocols for performing endometrial ablation can be found

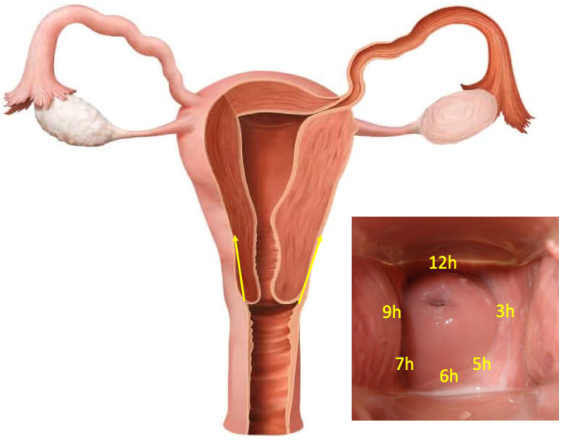

Figure 1: Paracervical block.

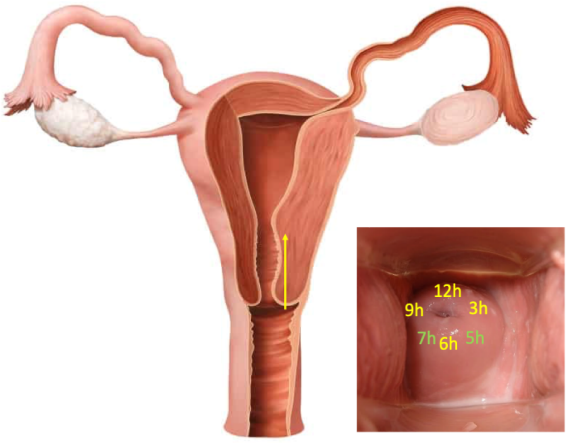

Figure 2: Intracervical block.

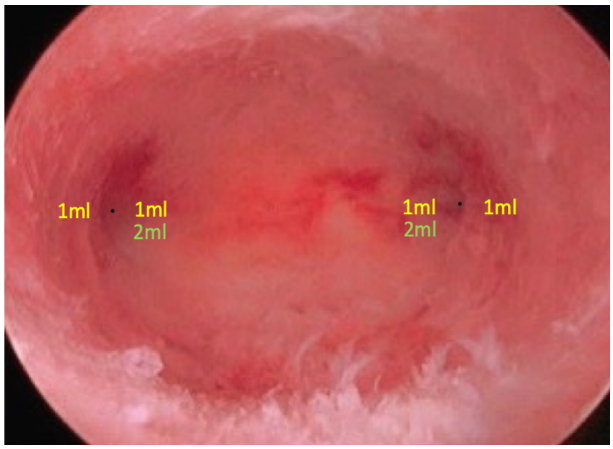

Figure 3: Intrauterine cornual (fundal) block.

using the following link: https://www.bsge.org.uk/wp-content/uploads/2021/06/NovaSure-LA-Protocol-Booklet.pdf. An education video of fundal block can be found via the following link:

https://hologic.box.com/s/
5m228ll86ew1igqtqs9adtij90igph80

Local anaesthetics can be classified in two groups:

1.- Ester linked: Procaine, Tetracaine, Benzocaine and Cocaine

They are hydrolysed by plasma cholinesterase (very short half-life), are less stable, and produce allergies more frequently. Their use is currently restricted to topical application, especially on mucous membranes.

2.- Amide linked: Lidocaine, Prilocaine, Mepivacaine, Bupivacaine, Ropivacaine, Articaine and Dibucaine.

They are more stable because they have hepatic metabolisation and cause fewer allergies. They have a stronger effect at low concentrations due to their greater lipid solubility and diffuse more rapidly.

Mepivacaine or Lidocaine are the most widely used amide-type anaesthetics for local infiltration, their effect lasts 2-3h for Mepivacaine and 1-2h for lidocaine, and their potency is strong enough to control cervical pain during diagnostic hysteroscopy or short surgeries.

For longer procedures or those that are expected to be more painful, the most recommended anaesthetics are Bupivacaine and Ropivacaine since, being more lipid soluble, they are more powerful, and their effect lasts 6-8h in the case of Bupivacaine and 4-6h for Ropivacaine.

Another important factor is toxicity that depends directly on the power of the anaesthetic.

Levo forms produce less toxicity than dextro forms.

There are two state-of-the-art anaesthetics marketed entirely in levo form: Levobupivacaine (levo form of bupivacaine) and Ropivacaine (which is 100% levo form). If we compare them, we can see that levobupivacaine has less neuro-cardiotoxicity than bupivacaine with identical potency.

Levobupivacaine has a higher potency than ropivacaine with equivalent safety as both are L-enantiomers.

Therefore, Levobupivacaine will be the anaesthetic of choice when we need power and duration of effect, as it also provides us with safety and less toxicity (Butterworth et al., 2020).

In the next table we can see the potency and duration of action of the different amide-type local anaesthetics (Table II).

Toxicity

It is important to be aware of the possible adverse effects of local anaesthetics, especially most potent drugs often used for endometrial ablation.

Local anaesthetics may cause both systemic and local toxicity. Most of the side effects are caused by overdosing, usually by accidental intravenous injection, toxicity occurs at two levels:

Central nervous system (CNS) toxicity

The CNS is more sensitive than the myocardium, therefore neurological symptoms will occur earlier. This is the most common feature of toxicity (68%–77%), primarily in the form of seizures.

Early manifestations are perioral paraesthesia, confusion, audio– visual disturbances, dysgeusia (metallic taste), agitation, or reduced level of consciousness.

Cardiovascular system (CVS) toxicity

Dysrhythmias, conduction deficits, hypotension, and eventually cardiac arrest – most commonly of an asystolic nature – may be seen. Toxicity events most frequently occur immediately following injection of local anaesthetic.

To prevent systemic toxicity, it is very important to take the following precautions:

- Never exceed the maximum recommended dose in mg/kg.

Table I. — Drugs and doses for paracervical and fundal block.

Authors	Drugs and doses		
Reinders et al., 2020	Paracervical block	Ropivacaine 0,2% 10ml x 4	3 and 9 o'clock and in both uterosacral ligaments (a total of 40 ml)
	Hysteroscopic intrauterine fundal block	Ropivacaine 0,2% 1ml x 4	in the myometrium of the fundus: 1 ml on either side of the midline and 1 ml medial to both tubal ostia
Chene et al., 2020	Paracervical block	Ropivacaine 0,2% 10ml x 4	2 , 4, 8 and 10 o'clock (a total of 40 ml)
	Hysteroscopic intrauterine fundal block	Ropivacaine 0,2% 2ml x 4	3-4 fundal injections separated 15-20mm
Kumar et al., 2016	Paracervical block	Mepivacaine 3% 6,6ml x 6	Infiltrating deep to the cervical isthmus level at 12, 3, 5, 6, 7, and 9 o'clock positions
	Hysteroscopic intrauterine fundal block	3% Mepivacaine (fast acting) 1ml + 0.5% Bupivacaine (long acting) 1ml	One injection medial to each tubal ostium
Skensved, 2011	Paracervical block	0.2% of Ropivacaine 10ml x 4	Injections at 3, 5, 7 and 9 o′clock
	Hysteroscopic intrauterine fundal block	Prilocaine 30mg / Felypressin 0.54 µg per ml x2	Medial to each of the tubal ostia, and 1 ml on either side of the midline of the fundus

Table II. — Potency and duration of action for amide local anaesthetics.

Anaesthetic	Relative potency	Onset of action	Toxicity	Duration (h)	Maximum dose mg/kg	
					without Epinephrine	With Epinephrine
L-Bupivacaine	6	8 min	3	6-8	3	4
Bupivacaine	6	8 min	4	6-8	2	2.5
Ropivacaine	5	8 min	4	4-6	3	3.5
Lidocaine	1	5 min	1	1-2	4.5	7
Mepivacaine	1	3 min	1	2-3	5	7

- Avoid intravenous administration, always aspirate before injecting the local anaesthetic, verifying that a vessel has not been punctured (which would be evidenced by the presence of blood in the syringe, in this case go back and aspirate again).
- Ask about allergies to any medication.
- Expect latency time of 10-15 minutes
- Always have cardiopulmonary resuscitation material and medication available to treat eventual seizures, hypotension, bradycardia, arrhythmias and cardiorespiratory arrest (El-Boghdadly et al., 2018).

Counselling

Women should be encouraged to play an active role in selecting the type of surgery, the setting and model of care for the endometrial ablation, based on a complete information.

Many women may prefer a surgical option as first-line management, as they decline hormonal treatment. The best treatment will depend on the woman's age, her intention to become pregnant, the presence of other symp-toms or comorbidities, failure of previous treatments and her personal views and preferences (Bofill et al., 2022; NICE, 2018)

Some of the questions that may be raised during the preoperative counselling and may influence the outcomes, differences among devices or recovery time are listed in the table below (Table III).

Conclusion

- Non resectoscopic endometrial ablation is a less invasive option than hysterectomy for HMB treatment and should be offered as an alternative for uterus sparing.
- Endometrial ablation is a feasible procedure that can be performed safely under local anaesthesia with high acceptability and effectiveness.
- Second generation procedures can be done in the office setting improving patients' satisfaction,

Table III. — Factors to consider when advising the best procedure (Daniels et al., 2012; Bofill et al., 2022; Reinders et al., 2022).

FACTOR	IMPACT
Age	Better results in reduction of bleeding after age 45 years
Satisfaction	Rates over 80% NREA may have higher satisfaction rates than LNG-IUS
Outcome of menstrual blood loss	Amenorrhoea rate depends on device used, most likely normalisation of menstrual flow, not necessarily amenorrhoea
Type of NREA	* REA and NREA may be better than LNG-IUS at reducing blood loss * Microwave NREA is better than REA for reducing blood loss * Bipolar radiofrequency and microwave ablation devices are more effective than thermal balloon and free fluid ablation for treating HMB * Bipolar radiofrequency is probably the best option for achieving amenorrhea * Bipolar radiofrequency has lower rates of requirement of further surgery
Predictors of endometrial ablation failure	Multiparity, obesity, and previous dysmenorrhoea
Returning to normal activities (time estimated)	5-7 days
Necessity of pain medication (time estimated)	2 days
Patients with increased surgical risks	Minimally invasive therapeutic option with lower risks than hysterectomy

LNG-IUS: Levonorgestrel – Intrauterine system, NREA: Non-resectoscopic endometrial ablation, REA: Resectoscopic endometrial ablation, HMB: Heavy menstrual bleeding.

with fewer anaesthetic complications, shorter hospital stay and quicker recovery time so patients should be given the choice for this option when choosing the procedure.

• The election of the type of device used depends on the availability and the decision agreed with the patient based on her expectations and needs after complete information on the available options and pro and drawbacks of each one.

• Long acting and potent anaesthetics like Bupivacaine or Ropivacaine are preferred for uterine infiltration because they provide good pain control also during the first postoperative hours with low toxicity.

• The most effective infiltration technique for local anaesthesia is the combination of paracervical and fundal block.

• Women's/Patient safety must be our main objective, therefore endometrial ablation procedures must be performed in an office setting where we have available all the security measures in place to guarantee care in the event of adverse effects that, although infrequent, can be life-threatening for patients.

References

Ajmi A, Das S. Outpatient endometrial ablation: audit of outcomes and patient satisfaction. J Obstet Gynaecol. 2020;40:1145-7.

Bofill Rodriguez M, Dias S, Jordan V et al. Interventions for heavy menstrual bleeding; overview of Cochrane reviews and network meta-analysis. Cochrane Database of Systematic Reviews. 2022;5: CD013180.

Bofill Rodriguez M, Lethaby A, Grigore M et al. Endometrial resection and ablation techniques for heavy menstrual bleeding. Cochrane Database of Systematic Reviews. 2019;1: CD001501.

Butterworth JF, Lahaye L. Clinical use of local anesthetics in anesthesia. Available at: https://www.uptodate.com/contents/clinical-use-of-local-anesthetics-in-anesthesia#:~:text=Mechanism%20of%20action%20 of%20 local%20 anesthetics%20%E2%80%94%20LAs%20 reversibly%20inhibit%20nerve,anchored%20in%20the%20 plasma%20membrane

Chene G, Piana F, Cerruto E et al. Comment je fais… simplement une thermodestruction endométriale sous bloc anesthésique associé à la réalité virtuelle immersive. Gynecol Obstet Fertil Senol. 2020;48:703-6.

Cooper N, Ireland N. Analgesia and Anaesthesia for Hysteroscopy. In Connor M, Clark T. (Eds). Diagnostic and Operative Hysteroscopy. Cambridge University Press, Cambridge, United Kingdom 2020, 72-82.

Daniels JP, Middleton LJ, Champaneria R et al. (International Heavy Menstrual Bleeding IPD Meta-analysis Collaborative Group). Second generation endometrial ablation techniques for heavy menstrual bleeding: network meta-analysis. BMJ. 2012;344:e2564.

De Silva PM, Stevenson H, Smith PP et al. Pain and operative technologies used in office hysteroscopy: a systematic review of randomized controlled trials. J Minim Invasive Gynecol. 2021;28:1699-711.

El-Boghdadly K, Pawa A, Chin KJ. Local anesthetic systemic toxicity: current perspectives. Local Reg Anesth. 2018;8:35-44.

Fraser IS, Mansour D, Breymann C et al. Prevalence of heavy menstrual bleeding and experiences of affected women in a European patient survey. Int J Gynecol Obstet. 2015;128:196–200.

Gupta S, Greenberg JA, Smith SE et al. 8580 Comparison of anesthetic usage with different endometrial ablation devices. J Minim Invasive Gynecol. 2022;29(S135).

Kumar V, Tryposkiadis K, Gupta JK. Hysteroscopic local anesthetic intrauterine cornual block in office endometrial ablation: a randomized controlled trial. Fertil Steril. 2016;105:474-80.

Miller JD, Lenhart GM, Bonafede MM et al. Cost effectiveness of endometrial ablation with the NovaSure® system versus other global ablation modalities and hysterectomy for treatment of abnormal uterine bleeding: US commercial and Medicaid payer perspectives. Int J Womens Health. 2015;7:59-73.

NICE Guideline [NG88]. Heavy Menstrual bleeding: assessment and management. Published 2007, updated 2018, last updated May 2021.

Reinders IMA, Geomini PMAJ, Leemans JC et al. Intrauterine fundal anaesthesia during endometrial ablation in the office: A randomised double-blind, non-inferiority trial. Eur J Obstet Gynecol Reprod Biol. 2020;254:206-11.

Skensved H. Global-local anaesthesia: combining paracervical block with intramyometrial prilocaine in the fundus significantly reduces patients' perception of pain during radio-frequency endometrial ablation (NovaSure1) in an office setting. Gynecol Surg. 2012;9:207-12.

Vitale SG, Della Corte L, Ciebiera M et al. Hysteroscopic endometrial ablation: from indications to instrumentation and techniques-a call to action. Diagnostics. 2023;13:339.

Video scan (read QR)

https://hologic.box.com/s/5m228ll86ew1igqtqs9adtij90igph80

doi.org/10.52054/FVVO.15.M.099

Review

Hysteroscopic removal of polyps and fibroids in the outpatient setting*

L. Antoun[1,3], L.E. Clark[2], T. J. Clark[1,3]

[1]*Birmingham Women's and Children's Hospital, Birmingham, UK;* [2]*Sanger Institute, Wellcome Genome Campus, Hinxton, Cambridge;* [3]*University of Birmingham, Birmingham, UK.*

**This article was not peer reviewed by Facts, Views and Vision. The lead author was commissioned by Hologic.*

Correspondence at: Professor T Justin Clark, Birmingham Women's and Children's Hospital, Birmingham B15 2TG, United Kingdom. E-mail: t.j.clark@doctors.org.uk

Abstract

Technological advances have facilitated the removal of endometrial polyps and submucous fibroids in an outpatient setting. This narrative review summarises the role, technologies and techniques, feasibility and effectiveness relating to outpatient hysteroscopic removal of uterine polyps and fibroids. A systematic electronic literature search of PubMed, Europe PMC, and Google Scholar in July 2023 was performed. The main outcome measures described were indications, patient selection and counselling, control of pain, modern definitions of treatment setting, available technologies, appropriate techniques and the evidence-base and future research directions. The results show that attention to patient counselling and the use of miniature instruments allowing vaginoscopy, and the judicious use of local anaesthesia with good technique are associated with improved patient experience and complete excision of uterine polyps and fibroids. Outpatient polypectomy is safe, feasible, acceptable, effective and cost-effective. Mechanical hysteroscopic tissue removal systems (mHTR) should be preferred to conventional mechanical instruments and electrosurgery because they are quicker, less painful, more acceptable and more successful. Outpatient hysteroscopic myomectomy is feasible using electrosurgery and mHTRs but appears more successful with smaller, more accessible fibroids. More research is needed surrounding case selection, identification of the best technologies and techniques and clinical effectiveness for hysteroscopic myomectomy in the outpatient setting.

Keywords: **Endometrial polyp, fibroid, myoma, hysteroscopy, outpatient, office, tissue removal system, electrosurgery.**

Introduction

Endometrial polyps and submucous fibroids are the most commonly encountered intrauterine pathologies encountered at hysteroscopy. Endometrial polyps are localised overgrowths of endometrial tissue that can occur anywhere in the uterine cavity. They contain variable amounts of glands, stroma and blood vessels that are covered by a layer of endometrium. Endometrial polyps vary in prevalence with a reported range between 20% - 40% and occur in women of reproductive and post-reproductive age (Lasmar et al., 2008; Nagele et al., 1996; Clevenger et al., 1999; van Dongen et al., 2007; Coloma et al., 1998). Uterine fibroids or leiomyomas ("myomas") on the other hand are solid, invariably benign tumours of uterine smooth muscle and connective tissue. Fibroids that encroach beyond the myometrium into the uterine cavity are called submucous or submucosal or intra-cavity fibroids and may account for up to 10% of all fibroids (Coloma et al., 1998).

Whilst these focal pathologies may be associated with reproductive failure (subfertility and miscarriage) (ARSM., 2008; Russo et al., 2016), the most frequently reported associated symptom is abnormal uterine bleeding (AUB); heavy menstrual bleeding (HMB), intermenstrual bleeding (IMB) and postmenopausal bleeding (PMB) with or without the use of hormone replacement therapy (HRT) (Lasmar et al., 2008; Lieng et al., 2009; Clark and Connor, 2020; Emmanuel et al., 1995).

Thus, hysteroscopic surgical removal can help improve fertility and alleviate AUB symptoms. In addition, obtaining a tissue sample for analysis can help diagnose premalignant and malignant pathology. The potential for (pre) malignancy inside endometrial polyps is reported to be up to 12% in patients with predisposing factors such as menopause, age over 60, diabetes, obesity, or the use of tamoxifen (van Dongen et al., 2007; Sasaki et al., 2018), and such oncogenic change is thought be even lower in submucous fibroids (Baranov et al., 2019). However, the current guidelines state that although hysteroscopic morcellation occurs in the uterus compared to laparoscopic morcellation which occurs in the abdomen, it still carries a theoretical risk of disseminating occult malignant tissues through retrograde flow via the fallopian tubes or perforation. Similar to intraperitoneal morcellation, hyseroscopic morcellation should be avoided if malignancy was suspected, however, it remains an appropriate method of managing submucosal fibroid in symptomatic women (NICE, 2021; ESGE, 2014; AAGL, 2014; ACOG, 2014).

Hysteroscopy is considered the gold standard technique for the diagnosis and treatment of endometrial polyps (Russo et al., 2016; Coloma et al 1998; RCOG GTG 59, 2020; ACOG, 2020; Cooper et al., 2015), and submucous fibroids (Farquhar et al., 2003; van Dongen et al., 2007; NICE, 2021; AAGL, 2012; Loddo et al., 2022). Conventional practice is to undertake these procedures under general anaesthesia in a hospital operating theatre. However, with advances in endoscopic technology, especially imaging quality, miniaturisation / portability of endoscopes and novel ancillary instrumentation, it is now possible to perform hysteroscopic polypectomy and myomectomy in an outpatient setting without the need for hospital admission and general or regional anaesthesia or deep intravenous sedation (Clark and Gupta, 2005; Clark and O'Donovan, 2015; Clark and Connor, 2020). Whilst treatment in this setting is convenient, the limitations of operating in the genital tract using miniature equipment in a conscious patient may offset any apparent benefits.

This paper will review the hysteroscopic treatment of endometrial polyps and submucous fibroids in a contemporary outpatient setting. Modern terminology defining treatment setting will be presented along with indications, patient selection, patient counselling and pain control. Moreover, the available technologies and surgical techniques will be evaluated with a focus on practical approaches, and optimising feasibility and clinical outcomes, namely effectiveness in alleviating clinical symptoms, safety and patient experience. Finally, quality assurance and future research opportunities will be discussed.

Search strategy and identification of studies

Our review covers several relevant aspects pertaining to the hysteroscopic removal of polyps and fibroids in an outpatient setting. Important terminology relating to the definitions of procedural setting is discussed using the recent joint consensus document from the European Society of Gynecological Endoscopy (ESGE), the Global Congress of Hysteroscopy (GCH) and the American Association of Gynecologic Laparoscopy (AAGL) (Carugno et al., 2021; Carugno et al., 2022). One of the authors (TJC) is an author on an extensively revised, updated version of the joint Royal College of Obstetricians and Gynaecologists (RCOG) and British Society for Gynaecological Endoscopy (BSGE) document, which is currently under peer review (Clark and Connor, 2020). This evidence-based guideline comprehensively covers pain control measures in the outpatient setting for diagnostic and operative hysteroscopy and we have used these collated data to inform this narrative review with a focus on removing polyps and fibroids. The guidance along with an RCOG Good Practice Paper (GPP) in outpatient hysteroscopy covers patient selection and counselling and this has been our main source to cover these aspects of care (RCOG GPP, 2023).

As regards identification of the available methods for removing polyps and fibroids and their feasibility and efficacy in an outpatient setting, we used relevant data from the aforementioned extensively revised and updated RCOG/BSGE outpatient hysteroscopy guidance. In addition, we conducted electronic searches between Oct 1990 and June 2023 of the PubMed database, Europe PMC, the Cochrane Central Register of Controlled Trials (CENTRAL) and Google Scholar. Potentially relevant studies were identified using a combination of the keywords "hysteroscopy*", "outpatient", "ambulatory", "office" and their associated medical subject headings (MeSH). In order to capture as many studies as possible, restrictions were not placed on the search and the reference lists of all included papers were reviewed and further studies were included if considered relevant. Our inclusion criteria were any systematic reviews, randomised controlled studies, prospective and retrospective cohort studies that provided data on the feasibility and / or clinical outcomes of hysteroscopic polypectomy and / or myomectomy. Initially, all the potentially eligible papers were independently evaluated by reading the title and abstract. When it was not possible to assess the eligibility of the

article by only reading title and abstract, the authors read the full text.

Definitions and classifications

Endometrial polyps

Endometrial polyps are focal endometrial outgrowths that can occur anywhere within the uterine cavity. They contain a variable amount of glands, stroma and blood vessels, the relative amounts of which influence their visual appearance at hysteroscopy. Polyps may be soft and cystic or firm and fibrous; they may be pedunculated or sessile, single or multiple, and vary in size from small (a few millimetres with minimal uterine cavity distortion), to large (several centimetres), filling the whole cavity.

There are no standard classification systems for endometrial polyps based upon hysteroscopy, although one of the authors (TJC) is leading on such a system on behalf of the International Federation of Gynecology and Obstetrics FIGO) to help predict the feasibility of removal and the nature of endometrial polyps. Hysteroscopic identification of polyps and submucosal fibroids (myomas) is generally easy. Figure 1 provides useful clinical (hysteroscopic) definitions of these two focal lesions (Clark and Gupta, 2005; Cooper et al., 2015). However, where endometrial polyps contain much fibrous stromal tissue then differentiation between the two common types of acquired focal pathology may only be definitively determined by histological examination. Submucous fibroids may be difficult to delineate from adenomyomas and smooth muscle tumours of uncertain malignant potential (STUMP). Folds of secretory endometrium may be mistaken for sessile endometrial polyps.

Submucous fibroids

Uterine fibroids or leiomyomas or 'myomas', are smooth muscle tumours and are the commonest benign tumours in females. They originate within the myometrium and can expand to deviate the mucosal layer (submucous) so that they are visible within the uterine cavity. These solid tumours are well demarcated by a pseudocapsule and their growth is dependent upon stimulation by oestrogen. They are usually solitary but can be multiple and vary in size.

There are two classification systems for fibroids, one adopted by the International Federation of Gynaecology and Obstetrics (FIGO), and one by the European Society of Gynaecological Endoscopy (ESGE). Both FIGO and ESGE (Munro et al., 2011; Wamsteker et al., 1993) classification of uterine fibroids are shown in (Table I).

The "STEPW or Lasmar" hysteroscopic myoma classification was developed in 2005 (Lasmar et al., 2012). It evaluates five parameters which allows better planning and preparation for surgery (Table II). The STEPW classification identifies the group of submucous fibroids in which incomplete myomectomy will be the outcome and the group in which complete removal will occur based on scores (Table II). This allows the surgeon to provide better counselling prior to consenting the patient for the procedure. Whilst the Lasmar classification does not specifically address the feasibility of hysteroscopic myomectomy in an outpatient setting, it is intuitive that Group 1 (low complexity) procedures should be

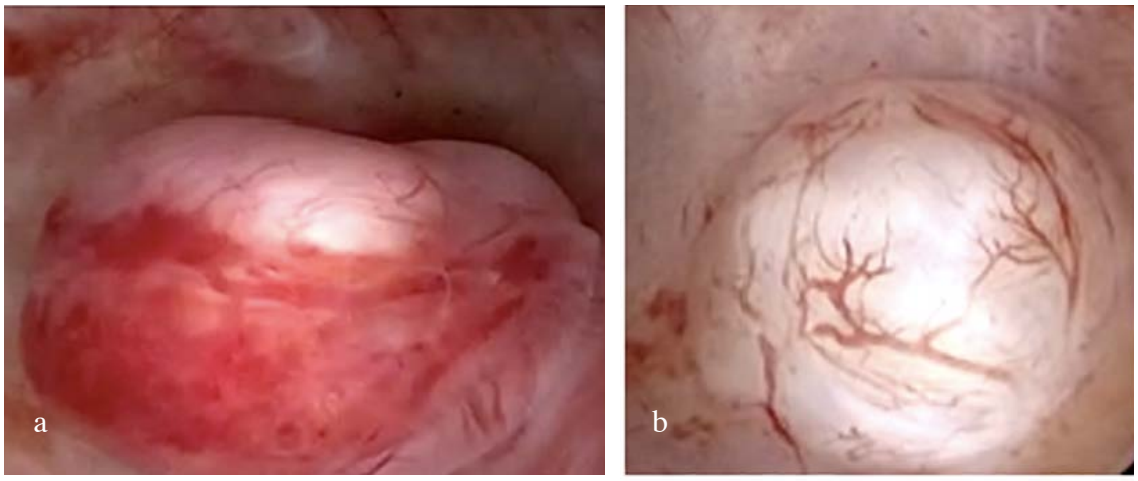

Figure 1: (a) Hysteroscogic definitions of endometrial polyps and submucous fibroids (Clark and Gupta, 2005). Endometrial polyp: a discrete outgrowth of endometrium, attached by a pedicle, which moves with the flow of the distension medium. Polyps may be pedunculated or sessile, single or multiple and vary in size (the variable amount of glands, stroma and blood vessels that constitute the polyp will influence their macroscopie appearance [i.e. glandulocystic polyps or firmer, more fibrous polyps (indistinguishable in some instances from grade 0 submucous fibroids)]. (b) Submucous fibroid: a firm, smooth and irregular sessile or pedunculated, intracavitx formation, covered by a thin, pale and transparent layer of endometrium revealing superficially large blood vessels, distorting the regular contour of an otherwise normal endometrial cavity.

Table I. — FIGO and ESGE classification of uterine fibroids.

ESGE	Fibroid type	FIGO	Fibroid type	Location
No myometrial involvement – pedunculated	0	Submucosal	0	Pedunculated in the cavity
<50% myometrial involvement	1		1	<50% intramural
			2	≥50% intramural
		Intramural	3	Contacts endometrium, 100% intramural
			4	100% Intramural
		Subserosal	5	Subserous and ≥50% intramural
≥ 50%myometrial involvement	2		6	Subserous and <50% intramural
		Pendunculated	7	Subserous pedunculated
		Other	8	Cervical/parasitic
		Hybrid leiomyoma	2-5	Submucous and subserous, each with less than half the diameter in the endometrial and peritoneal cavities

selected as prolonged procedures are less likely to be achievable or tolerated by the patient.

Standardising terminology for procedural setting

Pain associated with such hysteroscopic procedures limits their feasibility and can adversely affect patient experience (Mahmud et al., 2021; Clark and O'Donovan, 2015). Thus, pain management during operative hysteroscopy is of fundamental importance. However, reporting of the treatment setting and pain control measures lacks consistency. This non-uniformity of reporting limits the interpretation of research and generalisability of findings to individual practice, which in turn can impede the production of evidence-based guidance.

To try and provide consistency in reporting of hysteroscopic interventions, an international group of expert hysteroscopists was convened to produce a consensus statement for recommended terminology describing hysteroscopic procedures (Carugno el al., 2021; Carugno et al., 2022). A key component of this consensus was describing the treatment setting; it was decided that this should be defined according to the type of facility where the hysteroscopy was undertaken in conjunction with the highest level of pain control used.

To this end, a consensus was reached about a hierarchy of pain control measures relevant to hysteroscopy (Carugno el al., 2021; Carugno et al., 2022):

1. No medication or the use of oral non-sedative medication
2. Local anaesthetic to the genital tract
3. Conscious sedation
    a. Oral or inhalational medications with a sedative effect
    b. Parenteral medications with a sedative effect
4. Regional anaesthesia
5. General anaesthesia

Table II. — STEPW classification of uterine fibroids.

	Size (cm)	Topography	Extension of the base	Penetration	Lateral wall	Total
0	< 2	Low	< 1/3	0	+1	
1	2 to 5	Middle	1/3 to 2/3	<50%		
2	> 5	Upper	>2/3	>50%		

Score	Group	Complexity and therapeutic options
0 to 4	I	Less complexity hysteroscopic myomectomy
5 to 6	II	High complexity hysteroscopic myomectomy Consider GnRHa use Consider two steps hysteroscopic myomectomy
7 to 9	III	Consider alternatives to the hysteroscopic techniques

Moreover, it was agreed that the type of facility (office, outpatient clinic, community clinic, surgical centre, hospital) should be defined in alignment with the "International Association for Ambulatory (Day) Surgery (IAAS) Suggested International Terminology and Definitions" (Castoro et al., 2006). To provide greater clarity, the group agreed that the length of stay and plan for admission to a specific health care facility should not be used to inform the definition of treatment setting, but rather should be kept distinct and reported within a separate "model of care" category comprising the following: office, outpatient, ambulatory, extended recovery, inpatient.

In summary, treatment settings are defined thus (Carugno el al., 2021; Carugno et al., 2022): In summary, treatment settings are defined thus (Carugno el al., 2021; Carugno et al., 2022):

Office setting

- The hysteroscopic procedure is performed in a medical practitioner's professional premises where pain control up to level 3(a) can be administered.

Outpatient clinic setting

- The hysteroscopic procedure is performed in a health care facility for the management of outpatients e.g. hospital, community clinic or a freestanding surgical centre where pain control up to level 3(a) can be administered.

Operating Room setting

- The hysteroscopic procedure is performed in a fully equipped operating theatre where pain control up to level 5 can be administered

In exceptional circumstances, it was agreed that the treatment setting could be described as 'office' or 'outpatient' where pain management up to level 3(b) is administered. This was allowed to recognise the fact that local legislation permits the use of such pain control measure in some countries in an office / outpatient facility. However, it was emphasised that if the setting is defined as an office or outpatient clinic then it should be reported that level 3(b) pain management was used with details of type of pain management administered and route of administration.

It is hoped that this standardised nomenclature is adopted by the gynaecological community and that research papers and conference submissions relating to hysteroscopic surgery define the treatment setting in compliance with the international consensus statement (Carugno el al., 2021; Carugno et al., 2022): In addition, these clinical and academic documents and presentations should describe the pain control measures used in accordance with the agreed pain control hierarchy used and the model of care (defined according to need for admission / planned length of stay and type of facility).

Pain control

Outpatient or office hysteroscopic polypectomy or myomectomy relates to procedures in a setting where pain control up to level 3a (i.e. oral and / or inhalational analgesics / sedatives with or without local genital tract anaesthesia) (Carugno et al., 2021; Carugno et al., 2022). It is of paramount importance to manage pain to make operative hysteroscopy as painless as possible for the patient, enhance their experience and reduce the likelihood of a failed hysteroscopy due to unacceptable discomfort.

The joint British Society for Gynaecological Endoscopy (BSGE) and Royal College of Obstetricians and Gynaecologists (RCOG) evidence-based "Green Top Guideline 59" on "Best Practice in Outpatient Hysteroscopy" identified good technique, especially the use of miniature hysteroscopes, a vaginoscopic approach and minimising distension pressures, as of key importance (RCOG, 2022). Although not covered by this guidance, when operating on or within the myometrium the operator needs to be aware that sensory innervation inside the uterine cavity is mainly found in the myometrium (Tommaso et al., 2016). It is therefore important technically if removing polyps to be precise and avoid unnecessary painful trauma to the underlying myometrium. Similarly, when removing fibroids precision is necessary to ensure cutting and manipulation of the intracavitary fibrous tissue, which are not reached by nerve fibres, rather than adjacent myometrium to minimise pain.

In addition, the BSGE / RCOG evidence-based guidance recommended the use of pre-procedural, simple oral analgesics. This recommendation was based upon a metanalysis of 22 randomised control trials that analysed the effects of analgesia on pain both during and after hysteroscopy compared with a placebo (De Silva et al., 2020; Souza et al., 2020; De Silva et al., 2021; De Angelics et al., 2003; Lisón et al., 2017; Clark et al., 2002). Oral NSAIDs such as ibuprofen were proven effective in reducing pain intra-procedure and post-procedure when taken one hour prior to hysteroscopy. Moreover, no increase in adverse events was reported. Therefore, oral NSAIDs are an effective, low-risk option for reducing pain in an outpatient hysteroscopy setting and in the absence of contraindications should be taken pre-operatively. Paracetamol can be utilised for pain-relief since it is safe and well tolerated,

however, evidence regarding its efficacy in reducing pain in an outpatient hysteroscopy setting is limited.

Inhaled nitrous oxide gas is another form of analgesia which has been demonstrated to be more effective than a control in reducing pain associated with hysteroscopy although 5% of women did report dizziness with nitrous oxide (De Silva et al., 2021). Inhaled methoxyflurane (Penthrox®) is being trialled in our Unit because it has been shown to be effective in both emergency (Smith et al., 2022) and also elective (Hayne et al., 2021) settings, although data relating to gynaecological interventions are lacking (Stewart et al., 2023).

Local anaesthesia can be applied on, in, adjacent or through the cervix (RCOG, 2020). As such approaches cannot provide effective anaesthesia to the uterine body, the use of local anaesthesia is restricted to cases where cervical manipulation or dilation is required. There are a range of anaesthetic agents that can be delivered through various routes of administration, all of which have been shown to confer pain relief in the outpatient hysteroscopy setting (Clark and Gupta, 2005). Mepivacaine and bupivacaine have been reported to reduce pain both during and after hysteroscopy. Other agents including lidocaine and prilocaine significantly reduced pain during the hysteroscopy procedure. There has been recent interest in administration of local anaesthesia into the intrauterine fundus / cornua. This requires the hysteroscopic administration of local anaesthetic using a 5Fr needle and has been demonstrated to significantly decrease pain in a randomised control trial of outpatient endometrial ablation (Reinders et al., 2020). More RCTs are needed to see if this route of administration has effectiveness for outpatient hysteroscopic polypectomy and myomectomy.

Oral or vaginal prostaglandins can be considered to aid cervical dilatation and for pain control in addition to local anaesthesia. Prostaglandins have been shown to reduce pain, particularly when administered 12 hours prior to the procedure (Abdelhakim et al., 2019). However, prostaglandins are associated with side effects including genital tract bleeding, abdominal pain and gastrointestinal side effects which may lead to failure to complete the hysteroscopy (Abdelhakim et al., 2019).

Patient counselling

For any outpatient hysteroscopy procedure, it is important to adequately inform and counsel patients. The Royal College of Obstetricians and Gynaecologists (RCOG) have recently published a Good Practice Paper for outpatient hysteroscopy that includes practical approaches to patient counselling and consent (RCOG, 2023).

Women should ideally have been sent written information and / or access to online resources prior to attending. The local information provided should include any recommendations relating to taking simple analgesics prior to the appointment. The information provided should cover 'see and treat' if this approach is offered (i.e. polypectomy or myomectomy may be performed immediately following hysteroscopic diagnosis). Women should understand the rationale for removing polyps and fibroids and what to expect and the likely clinical outcomes. These include the likelihood of a failed or second stage procedure, and possible adverse effects and complications

The clinician should explore and address any concerns the patient might have about the procedure, especially regarding questions about pain management. The hysteroscopist must be reassured that the woman has had sufficient information to give informed verbal and/or written consent. The woman should be made aware of other settings and modes of anaesthesia for hysteroscopy as well as alternative care options available to her, and on the day of the procedure be given enough time to discuss any concerns or to change options. Importantly, the hysteroscopist must remind the woman that she is likely to experience period-like cramping and lower abdominal pain during and after the procedure and that should she find the procedure too painful or distressing she should notify her clinical team who will stop the procedure immediately.

Equipment

Hysteroscopes and fluid management

The development of small diameter hysteroscopic systems with outer diameters of 5.5mm or less, have driven the development of outpatient hysteroscopy because painful dilatation of the cervix can be avoided. Small diameter hysteroscopes with an integral working channel, typically 5Fr (1.8mm) or 7Fr (2.1mm) in diameter, allow for operative procedures to be performed in the outpatient setting (Bettochi et al., 2004; Vasiljević et al., 2019). Rigid reusable, rod lens systems (Figure 2a) and semi-rigid fibreoptic systems with a disposable outer sheath containing an expandable working channel (Figure 2b) are available. Recent advances in technology include the use of fully portable and disposable hysteroscopic diagnostic and operative systems (The EndoSee® device (CooperSurgical, Trumbull, CT, USA; LiNA OperåScope™ (LiNA Medical ApS, Glostrup, Denmark), and the Omni™ hysteroscope

(Hologic™, Marlborough, MA USA) (Figure 3a) that can be used with three sheath options.

Mechanical hysteroscopic tissue removal systems (mHTR) have been developed to remove tissue from within the uterine cavity. These systems necessitate the use of a bespoke hysteroscope with an offset proximal eyepiece to allow for a straight working channel large enough to accommodate a tissue removal blade. The TruClear™ 5.0 (Medtronic, Minneapolis, USA) and the MyoSure™ (Hologic™, Marlborough, MA USA) mHTR systems use a 0° hysteroscope and the IBS® - Integrated Bigatti Shaver (Karl Storz, Tuttlingen, USA) a 6° optic. The systems come in several sizes but those most suitable for use in an outpatient setting are between 5mm and 6.25mm (Figure 3).

The conventional resectoscope with typical outer diameters of 26-27Fr (8-9mm) has been miniaturised with 16 Fr mini-resectoscopes now available (e.g. Karl Storz SE & Co.KG, Tuttlingen, Germany) (Figure 4) suitable for removal of intrauterine pathologies in the office setting.

Fluid management

Complex hysteroscopic surgery, such as dense adhesiolysis or removal of large and / or FIGO type 2 fibroids, where optimal vision is required and prolonged procedures are likely mandates for the use of an automated fluid management system. Such procedures are not suitable for the outpatient setting. Furthermore, the risk of fluid overload complications, especially when using physiological saline is low. Thus, adequate fluid management can be achieved by simple gravity or pressurised inflow as opposed to automated fluid management systems in the outpatient setting (Umranikar et al., 2016; Clark and Connor, 2020). This is especially true for simple procedures like polypectomy. However, if myomectomy is frequently performed in an outpatient setting then investment in an automated fluid management system is to be encouraged to optimise visualisation and accurately monitor fluid inflow and outflow. Such automated systems include the Fluent fluid control system (Hologic), the Hysteromat (KARL STORZ –Endoskope,



Figure 2: Small diameter operative hysteroscopes suitable /or operative outpatient hysteroscopy . (A) Bettocchi rigid operarive hysteroscope (Karl Storz SE & Co.KG, Tuttlingen, Germany). (B) Alphascope® with Versapoint® bipolor electrodes and generator (Gynecare, Ethicon, Somerville, NU, USA).



Figure 3: Mechanical hysteroscopic tissue removal systems for use in the outpatient setting.
(A) The MyoSure Omni hysteroscope [6.25 mrr. (19 Fr) sheath and 0° optic] (Hologic, Marlborough, Massachusetts, USA); (B) The TruClear™ 5.0 [5-5.6mm sheath and 0° optic] (Medtronic, Minneapolis, USA) system; (C) The lntegrated Bigatti Shaver® [8mm and 6° optic) (Karl Storz, Tuttlingen, USA).

Germany), the Hysterolux fluid management system (Medtronic, USA) and HysteroBalance (Olympus GmbH, Hamburg, Germany).

Instrumentation

Conventional mechanical instruments

A range of finely engineered mechanical instruments designed to pass down 5Fr or larger 7Fr operating channels of rigid operative hysteroscopes, typically </=5.5mm in outer diameter are available. These include scissors, loops, biopsy cups, grasping forceps and snares (Figure 5a). One drawback of these fine mechanical instruments is that skill is required to manipulate them and they lack the strength to remove large and more dense, fibrous pathology and occasionally there can be problems with bleeding (Clark and Gupta, 2005; Garuti et al., 2008; Bettocchi et al., 2004), However, they are simple, safe and effective (Clark and Gupta, 2005; Garuti et al., 2008; Bettocchi et al., 2004) for removing soft polyps in an outpatient setting.

They are reusable but have a limited life due to their fragility.

These conventional, fine mechanical instruments are generally ill-suited to removing denser, submucous fibroids, lacking the necessary strength and cutting power. However, scissors can be successfully used to delineate the fibroid capsule and separate the connective tissue bridges, mobilising the fibroid and removing small fibroids en-bloc. Larger fibroids are less suitable for such an approach because of the risk of bleeding obscuring visualisation.

Mechanical tissue removal systems

Mechanical hysteroscopic tissue removal systems (mHTR) have largely superseded conventional mechanical and miniature electrosurgical technologies for the removal of endometrial polyps in an outpatient setting (Smith et al., 2014; Li et al., 2017). This is because they are extremely effective and easy to use (van Dongen et al., 2008). In contrast, the removal of submucous fibroids in the outpatient setting remains challenging regardless of which technology is adopted (see later) and so no technology is currently considered superior for outpatient hysteroscopic myomectomy.

Mechanical hysteroscopic tissue removal systems (mHTR) avoid the need for electricity and can simultaneously cut and aspirate tissue. The cutting blades or 'shavers' consist of two

hollow metal cylinders with a distal opening or 'cutting window'. The pathology enters the cutting window when negative pressure (suction) is applied. The inner cylinder moves under the operator's control (foot pedal or integral hand-held pump, depending upon the system) to shave away the tissue. A clear view within the uterine cavity is achieved by eradicating tissue debris and blood and the suction provides tissue for histological examination. Repeated insertions of the hysteroscope are not required reducing procedural time, which is of particular importance in the outpatient setting when operating on a conscious patient, as well as reducing the risk of pain, vaso-vagal reactions and air embolus. Three mHTR systems are widely used in the outpatient setting: MyoSure™ (Hologic™, Marlborough, MA USA) (Figure 3a), TruClear™ 5.0 (Medtronic, Minneapolis, USA) (Figure 3b) and the IBS® - Integrated Bigatti Shaver (Karl Storz, Tuttlingen, USA) (Figure 3c). The SYMPHIONTM system (Boston Scientific, Natick, MA) combines a tissue removal system with bipolar radiofrequency energy within an integrated tissue management system but is less widely used outside of the US.

The TruClear™ 5C office system (5-5.6mm) has a bevelled tip easing the use of vaginoscopy and insertion of the hysteroscope in an outpatient setting through which the rotating TruClear™ Soft Tissue Shaver and reciprocating Dense Tissue Shaver can be used. The MyoSure™ system now includes a 'Three-in-One' Omni™ hysteroscope (Figure 3a) that can be used with any of the three new sheaths. The smallest of these is 3.7mm diameter and suitable for diagnostic hysteroscopy. The two operative sheaths are 5.5 mm and 6 mm in diameter. The smaller of the operating scopes can accommodate the MyoSure™ MANUAL, LITE and REACH devices; these can also be used down the larger 6 mm Omni™ scope, as well as the MyoSure™ XL device. The IBS® is larger at 8mm in out the IBS® in outer diameter but the shaving blade is reusable for a finite amount of procedures. A smaller diameter IBS® system suitable for use in an outpatient setting has been developed.

All the available systems consist of an electrical generator that drives the mechanical cutting blades which aspirate fluid and tissue upon attachment to external suction apparatus. The MyoSure™ suite of mHTR systems also includes a manually operated system that avoids the need for an electrical generator, the blades being rotated by repeated squeezing and release of an integrated hand held pump to completely remove polyps (Smith and Clark, 2020).

Electrosurgical equipment

A variety of miniature electrosurgical instruments are available for use in an outpatient setting. These instruments described include miniature 5Fr bipolar electrodes (Clark and Connor, 2005; Cooper et al., 2015; Clark and O'Donovan, 2015) (Figure 2b), 16Fr (5mm) bipolar resecting loops (Papalampros et al., 2009) (Figure 4) and monopolar electrosurgical snares (van Germet et al., 2022) (Figure 5b). The use of electrical energy provides more efficient cutting than the conventional mechanical instruments and also allows for control of bleeding by coagulation of bleeding points. However, the risk of thermal injury to viscera is greater than with mechanical instruments if a uterine perforation is sustained. Complications from fluid overload are however unlikely when operating with electrical energy in an outpatient setting because procedures are shorter, fibroids smaller and more superficial (FIGO types 0 and 1), and normal saline used with the bipolar energy systems (Umranikar et al., 2016; Clark and Connor, 2020).

The successful use of miniature diode lasers has been reported in the outpatient setting (e.g. the Leonardo VR laser system (D.w.L.S.; LeonardoVR , Biolitec, Jena, Germany) to conduct polypectomies, myomectomies and metroplasty (Vitale et al., 2023;



Figure 4: The 16 Fr mini-resectoscope (Karl Storz SE & Co. KG, Tuttlingen, Germany)

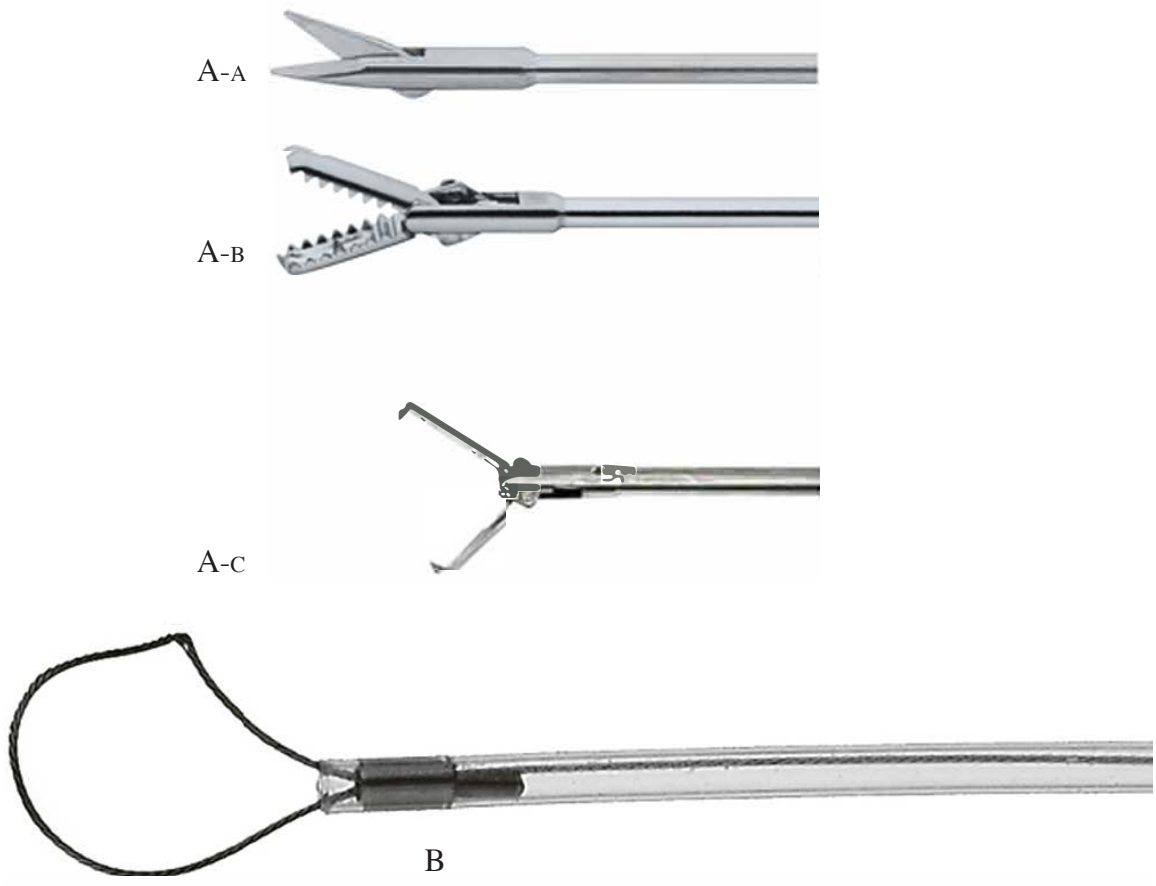

Figure 5: (A) 5Fr mechanical instruments (Karl Storz SE & Co. KG, Tuttlingen, Germany) - (A) Scissors; (B) Grasper; (C) Grasping forceps.
(B) Snare (can cut electrosurgically or be used solely mechanically to excise and retrieve endometrial polyps).

Haimovich et al., 2015; Haimovich et al., 2013; Nappi et al., 2017). However, this technology is not considered further as it is not widely employed.

Techniques

Outpatient polypectomy

Conventional mechanical approach

5Fr and 7Fr 'cold' scissors and / or grasping forceps / biopsy cups passed down the working channel of 4-5.5mm operating hysteroscopes. They can be used to detach and retrieve endometrial polyps. The scissors can be used at the base of the polyp to remove 'en bloc' or to cut larger polyps into pieces. Where grasping forceps are used to avulse the attached polyp rather than to retrieve polyp tissue cut away with scissors or snares, it is important to grasp the polyp at its base under high magnification such that the fine instrument is stabilised by the hysteroscope. The polyp is then squeezed and twisted with the forceps to detach and removed from the uterus by withdrawing the entire hysteroscope with the graspers just exterior holding the polyp tissue. Unlike electrosurgical and most mHTR approaches, the scissors / graspers have the advantage of being reusable. However, movements can be limited and they are relatively fragile so they

are most appropriate for small, soft, solitary polyps. Repeated instrument insertions are often required to remove the entire lesion.

Mechanical tissue removal systems

On accessing the uterus, brief activation of the mHTR within the central cavity will clear the view because suction will remove both turbid fluid, blood and free endometrial tissue fragments. The cutting window should be aligned against the end of the polyp and the tissue will be sucked into the window on activation of the mHTR. In the outpatient setting where patients are conscious, efficient operating is of paramount importance. The operator should avoid a 'stop : start' approach aiming for almost continuous device activation unless adequate visualisation is lost. Furthermore, the operator must ensure that the cutting window is contacted within the polyp tissue at all times such that it cannot be seen rotating. As the polyp is gradually removed, fine rotatory adjustments of the blade handle will facilitate this. Movements should be kept to a minimum to minimise patient discomfort. If the soft polyp is seen to be 'dancing' i.e. vigorously moving within the cutting window, then this indicates an optimal cutting position of the TRS relative to the polyp. Accessing the base of the polyp can be aided by levering the mHTR thereby applying gently to the uterine wall so that the polyp is completely removed (Smith et al., 2014; Smith and Clark, 2020).

Electrosurgery

Electrical resection of endometrial polyps can be achieved using 5Fr miniature bipolar electrodes, bipolar mini-resectoscopes and monopolar snares. Polyps of all sizes can be detached with these technologies although larger polyps over 2cm can be more challenging (Lieng et al., 2009). This is due to the need of longer operating times because of restricted access within the cavity and to the polyp attachment (base), in addition to difficulties manoeuvring the miniature electrodes, and maintaining good visual field.

Miniature bipolar 5Fr electrodes:

The 'en-bloc' technique, detaching the polyp at its base so it can be removed efficiently in one piece, is most commonly used (Clark and Connor, 2020; Smith and Clark, 2020; Cravello et al., 2000). However, whilst polyps are usually soft and compressible, removal with fine 5 or 7Fr grasping forceps / biopsy cups can be difficult through the relatively narrow and fibrous cervical canal. Cervical dilatation is required for larger or more fibrous polyps to facilitate retrieval. The alternative approach is to adopt a 'slicing technique'. This involves cutting the polyps into pieces and using grasping forceps to retrieve the fragments. This technique has the advantage of allowing removal of smaller diameter tissue through the narrow endocervical canal. However, the procedure is prolonged, requiring multiple instrument passes through the cervix. Maintaining an optimal view may be difficult because of endometrial congestion associated with protracted fluid instillation, the creation of tissue debris and the intermittent loss of uterine tamponade.

Mini-resectoscopes:

The electrosurgical cutting loop visualised with an offset distal lens, allows much more manoeuvrability to remove focal pathologies regardless of their location within the uterine cavity than small, straight miniature electrodes. The mini-resectoscope should be used in the same way as conventional larger diameter resectoscopes. The resectoscope controls the resecting loop which is activated in a retrograde fashion, from fundus to isthmus, to minimise the risk of uterine perforation and thermal injury to intra-abdominal visceral structures. The polyp is removed in slices; the cutting loop is placed beyond the distal border of the polyp and repeated, systematic, retrograde electrosurgical cutting movements, facilitated by movement of the hysteroscope or withdrawal of the cutting loop or a combination of both methods, are undertaken until the polyp is removed entirely. The soft, small polyp tissue fragments are either removed spontaneously, with 'blind' polyp forceps after cervical dilatation or a bridge modification to the 16 Fr mini-resectoscope can allow the insertion of 5Fr grasping forceps.

Snares (loops):

Loops can either be used as a simple mechanical snare to retrieve polyps previously detached by other means or as a stand-alone technology with monopolar electrical energy applied via a generator in a non-conducting fluid medium to cut the polyp which is then ensnared and removed (Timmermans et al., 2005; van Gemert et al., 2022). They have the advantage over graspers of providing better traction, so that larger polyps can be negotiated through the cervical canal. However, limited manoeuvrability can make accessing polyps, especially sessile lesion difficult.

Outpatient myomectomy

Conventional mechanical approach

Dense fibroid tissue is too strong for these finely engineered mechanical instruments. However, 5/ 7 Fr scissors can successfully incise the endometrium and delineate the fibroid capsule, separating the

connective tissue bridges thereby mobilising the fibroid. `fine instruments including tiny myomectomy 'screws' and grasping forceps with integral spikes to aid contact with the fibrous tissue have been developed but only very small fibroids can be removed with such instruments, either en-bloc or in pieces. Larger fibroids are less suitable for such an approach, not only because of fragility of the instruments but also because of the risk of bleeding obscuring visualisation.

Mechanical tissue removal systems

The instrument tip must be placed firmly in contact with the submucous fibroid prior to activation. The cutting window is placed within the central portion of the fibroid to create a 'bite' (likened to eating an apple), followed by lateral rotations of the cutting window (likened to spreading butter on toast) (Emmaneul et al., 2005; van Dongen et al., 2008). These manoeuvres are repeated until the fibroid removed. Minimal anterograde or retrograde movements of the mHTR are required and these are only to ensure that the cutting window is placed within fibroid tissue at all times to ensure efficient removal. Once the fibroid capsule has been opened using mHTR, any myometrial component of the fibroid is free to protrude further into the uterine cavity facilitated by uterine contractions. The mHTR system can then be used to mechanically 'lever up' ('spade technique') the fibroid in order to separate the myometrial component of the fibroid from the underlying myometrium along the cleavage plane thereby delineating the capsule. These manoeuvres have some similarities with the 'cold loop' technique described by Mazzon for conventional operating room removal of submucous fibroids (Mazzon., 2015), because the cutting blades of the mHTR are robust in contrast to more delicate electrosurgical cutting loops that are prone to bending / fracturing. These manoeuvres help distinguish the fibroid from the underlying myometrium so that mechanical cutting can be safely continued by ensuring the cutting window is placed within residual fibroid tissue, minimising the risk of inadvertent uterine perforation. An alternative technique that can be used when the cleavage plane is entered with the mHTR device, is to rotate the cutting window 180° which enables the fibroid to be removed from 'below' i.e. from within the myometrium in an 'upwards' direction i.e. towards the uterine cavity.

Electrosurgery

Miniature bipolar 5Fr electrodes:

As with polyps, the fibroid can be detached in one piece 'en-bloc' or in slices. For en bloc removal, the electrode (and in the case of fully intracavity FIGO type 0 fibroids) or resectoscopic cutting loop is placed at the level of attachment of the fibroid to the myometrium and beyond its distal border (Clark et al, 2002; Varma et al., 2009; Bettocchi et al., 2004). Repeated retrograde electrosurgical cutting is then performed by movement of the hysteroscope or withdrawal of the electrode or a combination of both methods. Motions are continued in a systematic way until the fibroid is detached. The inactivated electrode can be used periodically to probe the fibroid to help identify the basal attachment to the myometrium.

For FIGO type 1 and 2 fibroids the 5Fr straight electrode is used to wholly, or partially, circumscribe the endometrium overlying the visible margins of the fibroid, where possible moving the activated electrode in a retrograde direction. Once the fibroid capsule has been opened in this way, the myometrial component of the fibroid is free to protrude further into the uterine cavity facilitated by uterine contractions. The inactivated electrode or a 5Fr grasping forceps can be used to mechanically identify the cleavage plane, separating the intramural component of the fibroid from within the underlying myometrium, by breaking the connecting bridges of fascicular myometrial tissue. In this way, the intramural component of the submucous fibroid becomes increasingly visible as it migrates further into the uterine cavity and becomes more accessible (Istre and Clark, 2020; Varma et al., 2009; Munro et al., 2016). These cutting and mechanical steps are systematically repeated until the fibroid is completely enucleated. Removal of tissue from the uterine cavity is as described for endometrial polyps above using miniature 5Fr bipolar electrodes.

The electrode can then be used to slice the fully or partially detached fibroid into smaller pieces to aid removal from the cavity (Bettocchi et al., 2002) using hysteroscopic or blind instruments like polyp forceps although in reality it is difficult to debulk a fibroid that has been partially or fully detached from the myometrium due to its mobility. Alternatively, the fibroid can be retrieved from the uterine cavity in one piece. This usually necessitates variable degrees of cervical dilatation and blind insertion of instruments such as polyp forceps. Wherever possible, blind instrumentation of the uterus should be avoided to minimise the risk of genital tract trauma. Another option to blind removal or when blind removal is not easily achieved, is to leave the detached fibroid in situ to degenerate and pass spontaneously post-operatively and often during the first menstruation after surgery (Varma et al., 2009; Haimovich et al., 2015). A 'hybrid' procedure can also be performed where a mHTR is used to

remove under direct vision after complete or partial detachment of the fibroid (Munro et al., 2016).

The alternative 'slicing' technique involves placing a straight 5Fr electrode at the distal extremity of the fibroid and a retrograde surgical cut is made to the proximal extremity. Repeated cuts are made in the same furrow so that the fibroid is sliced vertically until the basal attachment with the myometrium is reached (Clark et al., 2002; Varma et al., 2009; Bettocchi et al., 2004). Depending on the shape and size of the fibroid, it can be divided in half or quarters or as many fragments as necessary to debulk using systematic vertical and /or horizontal slices. The cut pieces should be small enough to remove with hysteroscopic grasping forceps.

Mini-resectoscopes:

The cutting loop is placed beyond the distal border of the fibroid and repeated, systematic, retrograde electrosurgical cutting movements, facilitated by movement of the hysteroscope or withdrawal of the cutting loop or a combination of both methods, are undertaken until the fibroid is removed. Resection normally is initiated at the free margin of the myoma, then proceeding in a uniform manner towards its base of implantation within the myometrium. As soon as the visible intracavity portion of the myoma has been removed, the inactivated cutting loop can be gently used to undermine and identify more clearly the myometrial component of the fibroid, separating it from the underlying capsular attachment (Emmanuel and Wamsteker, 2005; Hart et al., 1999; Vercellini et al., 1999; AAGL, 2012; Di Spiezio et al., 2008; Istre and Clark, 2020). To ensure complete enucleation, pink, softer myometrial tissue should be identified; the inactivated cutting loop can be used to help judge the tissue density and delineate the base of the fibroid capsule. The activated electrode is then used to remove any residual fibroid tissue from the base, carefully judging the depth of insertion of the cutting loop.

Attempts may be made during the procedure to coagulate specific bleeding points using the loop if the bleeding persists and is compromising visualisation. Removal of tissue can be achieved in the following ways: (i) the small size of the resected 'chips' allow for spontaneous passage down the cervical canal; (ii) removal by trapping them in the end of the hysteroscope by retracting the inactivated cutting loop and removing the resectoscope; (iii) removal with 5/7Fr grasping forceps passed along an adapted bridge or using an additional operating hysteroscope; (iv) using blind polyp forceps. Some surgeons avoid the formation of free flowing 'chips' of tissue that can obscure vision by removing each resected strip of tissue by immediate removal of the resectoscope followed by re-insertions which can be painful in an outpatient environment.

Feasibility and clinical outcomes

So far we have discussed the practical aspects around removing polyps and fibroids hysteroscopically in the outpatient setting; pain control, equipment and techniques, However, if we are not to cause harm and waste scarce health care resources we need to evaluate the acceptability, feasibility and effectiveness of our interventions. By understanding the impact of our surgery, we can better counsel our patients and optimise clinical care.

Outpatient polypectomy

The evidence-base supporting outpatient hysteroscopic removal of endometrial polyps is more extensive and clearer than for fibroid removal. A systematic review of randomised controlled trials (RCTs) evaluating the effect of hysteroscopic devices on pain experienced by women undergoing operative office hysteroscopy identified seven trials that evaluated technologies for endometrial polypectomy; four compared energy modalities; miniature bipolar electrode resection against resectoscopy (n=1), mHTR (n=2) and diode laser resection (n=1) (De Silva et al., 2020). Two studies compared hysteroscope diameter and one study compared methods of polyp retrieval.

A significant reduction in pain was found using mHTRs rather than miniature bipolar electrosurgical devices ($p<0.001$), smaller diameter resectoscopes ($p<0.001$) and 3.5mm fibreoptic hysteroscopes with 7Fr forceps rather than 5mm lens-based hysteroscopes with 5Fr forceps. In the two studies comparing mHTR with miniature bipolar electrosurgical resection using 5Fr miniature bipolar electrodes (Smith et al., 2014; Pampalona et al., 2015), the earlier study showed a significant reduction in pain when using a mHTR (Smith et al., 2014), whereas the latter one did not (Pampalona et al., 2015). However, the earlier study compared a 5mm diameter hysteroscopic morcellator against either a 3.5mm or 5mm hysteroscope (Smith et al., 2014), whereas the latter one compared the same hysteroscopic morcellation system device against a slightly larger 5.5mm hysteroscope (Pampalona et al., 2015). Both trials were consistent in showing that mHTR was significantly quicker and associated with lower rates of failure (Smith et al., 2014; Pampalona et al., 2015). More than 99% of women found outpatient polypectomy acceptable (Smith et al., 2014). Novel, miniature bipolar mini-resectoscopes have been shown to be feasible and safe in an outpatient setting to remove endometrial polyps

(Dealberti et al., 2016), However comparative data between mHTR and miniature bipolar resectoscopes to guide practice is lacking.

Similarly, the superiority of mHTR was demonstrated in a recent RCT that found that outpatient polypectomy was more successful using a mHTR (Truclear™, Medtronic) compared to an electrosurgical polyp snare (DPS) (Duckbill®, Cook) (95% vs. 59%). Removal using a mHTR was shorter (6 vs. 12 minutes). Pain scores and rates of acceptability were comparable between technologies although it should be noted that 23/66 (35%) were not outpatient procedures as level 3B (Carugno et al., 2021; Carugno et al., 2022) pain control was used (iv propofol administered by a trained sedationist) (van Gemert et al., 2022).

The use of a dual wavelength laser system has been shown to be feasible and safe in an outpatient setting (Nappi et al., 2017). One RCT has compared outpatient polypectomy using miniature bipolar electrosurgery against diode laser, there was no significant difference in pain experienced by women and the rate of adverse events was the same between the two modalities. Polyp resection, however, was quicker with the laser (Lara-Domínguez et al., 2015). Polyp relapse was more common in women randomised to miniature bipolar electrosurgery when compared to diode laser resection at second-look hysteroscopy three months' post-procedure (Lara-Domínguez et al., 2015).

Another systematic review and meta-analysis of RCTs comparing mHTR with conventional resectoscopy for removal of endometrial lesions also identified the same four trials including 392 patients found that successful removal of polyps was more frequent with mHTR than conventional resectoscopy (odds ratio 4.49, 95% confidence interval [CI] 1.94–10.41) and total operative time was shorter with mHTR (mean difference −4.94 minutes, 95% CI −7.20 to −2.68;) (Li et al., 2017). No significant differences in complications were found. Thus it is clear that mHTR is superior to electrical resection of polyps in terms of feasibility and patient experience in an outpatient setting.

A large, multicentre RCT (the OPT trial) comparing outpatient to inpatient polypectomy for abnormal uterine bleeding showed that there was no difference in effectiveness but that the outpatient setting was significantly more cost-effective (Cooper et al., 2015; Clark and O'Donovan, 2015).

Outpatient myomectomy

There is less evidence to guide clinical practice regarding hysteroscopic myomectomy in an outpatient setting compared to hysteroscopic polypectomy. A systematic review failed to identify any RCTs evaluating mHTR for myomectomy but did find eight observational studies (208 used MyoSure and 75 Truclear). The review showed that mHTRs were associated with similar or reduced operative time compared to traditional electrical resectoscopy. However, only two articles reported data about procedures performed in outpatient/office setting both using the MyoSure (FIGO types 0-2) technology (Rajesh and Guyer, 2015; Rubino and Lukes, 2015; Haimovich et al., 2015; D'Alterio et al., 2020). One was an RCT of 42 fibroids (FIGO types 0-1; 1.6-2.9cm) of which 28 were removed in an outpatient setting (Rubino and Lukes, 2015). The office procedures used the following pain management protocol: 800 mg of ibuprofen administered the night before the procedure, and 10 mg diazepam, 10 mg hydrocodone/acetaminophen, and 25 mg phenergan. Topical 2% lidocaine gel was applied to the cervix and a cotton swab coated with 2% lidocaine gel was inserted into the cervical os for 10 min. Two millilitres of 1% lidocaine and 0.25% bupivacaine were injected superficially at the 12:00 position. Ten millilitres of 1% lidocaine and 0.25% bupivacaine were injected approximately 1 to 2 cm deep at the 4 and 8 o'clock positions. Rates of successful fibroid removal were similar regardless of treatment setting and in excess of 97%. Clinical outcomes in terms of improvement in health-related quality of life was similar regardless of treatment setting (outpatient or ambulatory) but the data presentation precluded an evaluation of feasibility and acceptability in an outpatient setting. The other primary study was a small retrospective study published as a conference abstract that reported the successful removal of 14/17 (82%) fibroids in an outpatient setting (FIGO types 0-2) (Rajesh and Guyer, 2015).

One observational study of 28 myomectomies showed the feasibility of outpatient myomectomy using the MyoSure system and quicker post-operative recovery compared to inpatient treatment. However, according to new accepted terminology for treatment setting these were not outpatient procedures as 61% had iv sedation and 7% general anaesthesia (Schieber and Chen, 2016). A series of 124 patients (135 pathologies) from the UK evaluated the use of MyoSure in the outpatient setting using an intracervical local anaesthetic block to remove polyps (109), fibroids (19) and retained products of conception (Georgiou et al., 2018). The MyoSure Classic and Lite devices were used for small fibroids and MyoSure XL for larger fibroids. Complete excision was achieved in 14/19 (73%) of cases. As one would expect, logistic regression analysis showed that incomplete excision was associated with predominantly intramural (FIGO type II)

and larger (maximal diameter > 4 cm) submucous fibroids. Importantly, rates of acceptability were high (>99%) and severe pain reported by only 7% of women from the whole series although pain and acceptability data were not stratified by pathology.

One RCT has been conducted comparing mHTR and bipolar resectoscopy for FIGO type 0 and 1 fibroids and showed that complete resection was comparable (89 % vs. 95%) but 2/45 mHTRs (4%) had to be converted to resection due to the hardness (calcification) of the fibroid (van Wessel et al., 2021). Total procedure time between mHTR and bipolar was similar but set up time was longer for mHTR. This study was conducted in the operating room with pain control level 4 and 5 (Carugno et al., 2021; Carugno et al., 2022) (i.e. spinal and general anaesthesia). Similar randomised studies comparing mHTR and mini-resectoscopy for submucous fibroids in an outpatient setting are required to build upon available comparative observational series to remove selection bias inherent is such study designs. Valero et al (Valero et al., 2022) performed a prospective, cross-sectional, observational study of 80 patients comparing the mini-bipolar resectoscopy with a 5.8 mm (17.5 Fr) thick loop tip and a 30°optic (Invidia-Medical GmbH & Co. KG, Tuttlingen, Germany) and mHTR using the MyoSure Omni hysteroscope (Hologic, Marlborough, Massachusetts, USA) with a 6.25 mm (19 Fr) sheath and 0° optic for outpatient hysteroscopic myomectomy. The pain control protocol was as follows: all patients received 200mcg of Misoprostol for cervical ripening 12 h prior, as well as 10 mg of diazepam and 600 mg of ibuprofen (or some other painkiller in case of allergies) one hour before the procedure. Paracervical block using 1.8 ml of 3% mepivacaine injected in the posterior fornix, at the limit between vaginal and cervical mucosa and in each utero-sacral ligament, at 5 and 7 o'clock. They found clinical outcomes to be comparable between mini resectoscopy and mHTR. These included mean treatment times (13 vs. 17 minutes), rates of complete resection (82% vs. 83%), pain scores >7 (13% vs. 7%) and high levels of patient satisfaction (50% vs. 70%) with both technologies (Valero et al., 2022).

A prospective series of 92 hysteroscopic myomectomies of which 35 were conducted in an outpatient setting using the Gynecare VersascopeTM bipolar system showed complete excision in 19 (54%) cases. Successful removal did not appear to be related to treatment setting (Varma et al., 2009).

The use of the LeonardoVR diode laser system (D.w.L.S.; LeonardoVR , Biolitec, Jena, Germany) is not widely used but small series have shown the feasibility of the technology in an outpatient setting to treat fibroids (Vitale et al., 2023). One series of 43 women described a two-step hysteroscopic procedure, which included preparation of partially intramural myomas with incision of the endometrial mucosa and the pseudocapsule covering the fibroid followed by subsequent excision of the fibroid using the diode laser four weeks later. 79% of fibroids were successfully removed and success rates were higher for fibroids <2cm in diameter. Another outpatient series of 20 patients described vaporisation of the fibroid core using a 980-1470 nm wavelength diode laser inserted through the hysteroscope's working channel. A reduction in fibroid volume and vascularity was observed in most patients at two months after the procedure (Vitale et al., 2023).

Future research

Advances in technologies have facilitated the move to outpatient 'office' operating. However, the main limitation now is feasibility and most of these procedural challenges relate to patient experience, especially pain and acceptability. Thus, more quantitative and qualitative research is needed in this area and evaluation of pain control interventions / protocols. There is a still an urgent need to assess the effectiveness of removing polyps and fibroids on patient outcomes regardless of treatment setting. The efficacy on alleviating abnormal bleeding symptoms seems clear (Cooper et al., 2015; Di Spiezio et al., 2008) but the impact on reproductive outcomes, namely infertility and miscarriage, is lacking. Once we know the answers to these questions then trials can compare the relative merits of outpatient versus operating room setting. It is important that such trials (van der Meulen et al., 2019) clearly define the treatment setting including level of pain control according to the standardised nomenclature produced on behalf of the European Society of Gynaecological Endoscopy (ESGE), Global Congress of Hysteroscopy (GCH) and American Association of Gynecological Laparoscopy (AAGL, 2020; Carugno et al., 2021; Carugno et al.,2022).

Conclusion

The available evidence supports the hysteroscopic removal of endometrial polyps in an outpatient setting. The procedure is safe, feasible, acceptable, effective and cost-effective. Clinical outcomes are not compromised compared to conventional hospital, operating room settings. Mechanical hysteroscopic tissue removal systems should be preferred to conventional mechanical instruments and electrosurgery because the evidence shows that mHTRs are quicker, less painful, more acceptable

and more successful. Proficiency in the various techniques and modalities for performing outpatient hysteroscopic polypectomy can be acquired relatively quickly, especially for acquisition of the requisite skills for successful use of an mHTR.

The situation for removal of submucous fibroids in an outpatient setting is less clear. There is a lack of randomised clinical trials to inform clinical practice. Small, observational series show that outpatient hysteroscopic myomectomy is feasible and acceptable but rates of failure are higher compared to outpatient polypectomy. There is no data to support any particular modality or technique as being superior to another. It seems that the main limitation for outpatient hysteroscopic myomectomy is the size and accessibility of the fibroid. Smaller, mostly intracavity and no-fundal fibroids appear to be most suitable for outpatient hysteroscopic removal. More data are needed to better understand which technologies, method of fluid management, pain control measures etc. are best for outpatient myomectomy. Head to head trials comparing such interventions are needed and also comparing treatment settings. It is of key importance that the recent, internationally agreed nomenclature to define treatment setting and pain control is used to aid appropriate clinical inferences being drawn to inform practice and to enhance generalisability.

Conflicts of Interest: Lina Antoun - None; Laura E. Clark - None; T. Justin Clark - Honoraria for education / training / consultancy from the hysteroscopic instrument manufacturers Hologic and Medtronic.

References

AAGL practice report: Morcellation during uterine tissue extraction. J Minim Invasive Gynecol. 2014;21:517–30.

Abdelhakim AM, Gadallah AH, Abbas AM. Efficacy and safety of oral vs vaginal misoprostol for cervical priming before hysteroscopy: A systematic review and meta-analysis. Eur J Obstet Gynecol Reprod Biol. 2019;243:111-9.

ACOG statement on power morcellation. ACOG statement on power morcellation. 2014 Available at: https://www.acog.org/About-ACOG/News-Room/Statements/2014/ACOG-Statement-on-Power-Morcellation? (Accessed July 26, 2023).

American Association of Gynecologic Laparoscopists (AAGL): Advancing Minimally Invasive Gynecology Worldwide. AAGL practice report: practice guidelines for the diagnosis and management of submucous leiomyomas. J Minim Invasive Gynecol. 2012;19:152-71.

Baranov VS, Osinovskaya NS, Yarmolinskaya MI. Pathogenomics of Uterine Fibroids Development. Int J Mol Sci. 2019;20:6151.

Bettocchi S, Ceci O, Di Venere R et al. Advanced operative office hysteroscopy without anaesthesia: analysis of 501 cases treated with a 5 Fr. bipolar electrode. Hum Reprod. 2002;17:2435-8.

Bettocchi S, Nappi L, Ceci O et al. Treatment of submucosal and partially intramural myomas using the bipolar Versapoint system. J Am Assoc Gynecol Laparosc. 2004;11:s-17–s-18 (II).

Bettocchi S, Nappi L, Ceci O et al. What does 'diagnostic hysteroscopy' mean

today? The role of the new techniques. Curr Opin Obstet Gynecol.. 2003;15:303–8.

Carugno J, Grimbizis G, Franchini M et al. International Consensus Statement for recommended terminology describing hysteroscopic procedures. Facts Views Vis Obgyn. 2021;13:287-94.

Carugno J, Grimbizis G, Franchini M et al. International Consensus Statement for Recommended Terminology Describing Hysteroscopic Procedures. J Minim Invasive Gynecol. 2022;29:385-91.

Castoro C, Drace C, Baccaglini U. Patient information, assessment, and preparation of day cases. In: Lemos P, Jarret PEM, Philip B, editors. Day-surgery – development and practice. London: International Association for Ambulatory Surgery (IAAS); 2006. 157–84.

Clark TJ and Connor ME. (Eds). Diagnostic & Operative Hysteroscopy. Cambridge University Press, Cambridge, United Kingdom, 2020.

Clark TJ and Gupta JK (Eds). Handbook of outpatient hysteroscopy: A complete guide to diagnosis and therapy. Hodder Arnold, London, United Kingdom, 2005.

Clark TJ and O'Donovan P (Eds). Hysteroscopy. Best Practice & Research: Clinical Obstetrics & Gynaecology. Elsevier Best Practice & Research Clinical Obstetrics & Gynaecology, United Kingdom, 2015.

Clark TJ, Cooper NAM, Kremer C. Best Practice in Outpatient Hysteroscopy: Green Top Guideline 59. Update 2nd Edition RCOG/ BSGE Joint Green Top Guideline. RCOG 2020 http://https://www.rcog.org.uk/media/5llizces/gtg59hysteroscopy.pdf.

Clark TJ, Mahajan D, Sunder P et al. Hysteroscopic treatment of symptomatic submucous fibroids using a bipolar intrauterine system: a feasibility study. Eur J Obstet Gynecol Reprod Biol. 2002;100:237–42.

Clark TJ, Middleton LJ, Cooper NA et al. A randomised controlled trial of Outpatient versus inpatient Polyp Treatment (OPT) for abnormal uterine bleeding. Health Technol Assess. 2015;19:1-194.

Clark TJ, Voit D, Gupta JK et al. Accuracy of hysteroscopy in the diagnosis of endometrial cancer and hyperplasia: a systematic quantitative review. JAMA. 2002;288:1610–21.

Clevenger-Hoeft M, Syrop CH, Stovall DW et al. Sonohysterography in premenopausal women with and without abnormal bleeding. Obstet Gynecol 1999;94:516–20.

Coloma CF, Paya A, V, Diago Almela VJ et al. 2,000 outpatient diagnostic hyteroscopies: 8 years of experience. [In Spanish.] Dos mil histeroscopias diagnosticas ambulatorias: experiencia de echo anos. Prog Obstet Ginecol 1998;41:347–52.

Cooper NA, Clark TJ, Middleton L et al. OPT Trial Collaborative Group. Outpatient versus inpatient uterine polyp treatment for abnormal uterine bleeding: randomised controlled non-inferiority study. BMJ. 2015;350:h1398.

Cravello L, Stolla V, Bretelle F et al. Hysteroscopic resection of endometrial polyps: a study of 195 cases. Eur J Obstet Gynecol Reprod Biol. 2000;93:131-4.

D'Alterio MN, Scicchitano F, Fanni D et al. Ex vivo myolysis with dual wavelengths diode laser system: macroscopic and histopathological examination. CEOG. 2021;48:875–82.

Dealberti D, Riboni F, Cosma S et al. Feasibility and acceptability of office-based Polypectomy with a 16F mini-Resectoscope: A multicenter clinical study. J Minim Invasive Gynecol. 2016;23:418–24.

De Angelis C, Perrone G, Santoro G et al. Suppression of pelvic pain during hysteroscopy with a transcutaneous electrical nerve stimulation device. Fertil Steril. 2003;79:1422-7.

De Silva PM, Carnegy A, Smith PP et al. Vaginoscopy for office hysteroscopy: A systematic review & meta-analysis. Eur J Obstet Gynecol Reprod Biol. 2020;252:278–85.

De Silva PM, Stevenson H, Smith PP et al. Pain and Operative Technologies Used in Office Hysteroscopy: A Systematic

Review of Randomized Controlled Trials. J Minim Invasive Gynecol. 2021;28:1699-711.
Di Spiezio Sardo A, Mazzon I, Bramante S et al. Hysteroscopic myomectomy: a comprehensive review of surgical techniques. Hum Reprod Update. 2008;14:101–19.
Emanuel MH, Verdel MJC, Stas H et al. An audit of true prevalence of intra-uterine pathology: the hysteroscopical findings controlled for patient selection in 1202 patients with abnormal uterine bleeding. Gynaecol Endosc 1995;4:237–41
Emanuel MH, Wamsteker K. The Intra Uterine Morcellator: a new hysteroscopic operating technique to remove intrauterine polyps and fibroids. J Minim Invasive Gynecol 2005;12:62–6.
European Society of Gynaecological Endoscopy (ESGE). Statement on morcellation (of presumed fibroids appearing to be sarcomas). ESGE executive board. 2014. Ref Type: Internet Communication.
Farquhar C, Ekeroma A, Furness S et al. A systematic review of transvaginal ultrasonography, sonohysterography and hysteroscopy for the investigation of abnormal uterine bleeding in premenopausal women. Acta Obstet Gynecol Scand. 2003;82:493-504.
Georgiou D, Tranoulis A, Jackson TL. Hysteroscopic tissue removal system (MyoSure) for the resection of polyps, submucosal leiomyomas and retained products of conception in an out-patient setting: A single UK institution experience. Eur J Obstet Gynecol Reprod Biol. 2018;231:147-51
Garuti G, Centinaio G, Luerti M. Outpatient hysteroscopic polypectomy in postmenopausal women: a comparison between mechanical and electrosurgical resection. J Minim Invasive Gynecol. 2008;15:595–600.
Haimovich S, López-Yarto M, Urresta Ávila J et al. Office Hysteroscopic Laser Enucleation of Submucous Myomas without Mass Extraction: A Case Series Study. Biomed Res Int. 2015;2015:905204.
Haimovich S, Mancebo G, Alameda F et al. Feasibility of a new two-step procedure for office hysteroscopic resection of submucous myomas: results of a pilot study. Eur J Obstet Gynecol Reprod Biol. 2013;168:191–4.
Hart R, Molnar BG, Magos A. Long term follow up of hysteroscopic myomectomy assessed by survival analysis. Br J Obstet Gynaecol 1999;106:700–5.
Hayne D, Grummet J, Espinoza D et al. Australian and New Zealand Urogenital and Prostate Cancer Trials Group (ANZUP). 'Pain-free TRUS B': a phase 3 double-blind placebo-controlled randomized trial of methoxyflurane with periprostatic local anaesthesia to reduce the discomfort of transrectal ultrasonography-guided prostate biopsy (ANZUP 1501). BJU Int. 2022;129:591-600.
Istre O, Clark TJ. Chapter 12: Hysteroscopic management of fibroids in Clark TJ and Connor ME. (Eds). Diagnostic & Operative Hysteroscopy Cambridge University Press August 2020: 180-93. ISBN 9781107111608.
Lara-Domínguez Maria D, Arjona-Berral Jose E, Dios-Palomares Rafaela et al. Outpatient hysteroscopic polypectomy: Bipolar energy system (Versapoint®) versus diode laser - Randomized clinical trial. Gynecological Endocrinology. 2016;32:196–200.
Lasmar RB, Dias R, Barrozo PR et al. Prevalence of hysteroscopic findings and histologic diagnoses in patients with abnormal uterine bleeding. Fertil Steril 2008;89:1803–7.
Li C, Dai Z, Gong Y et al. A systematic review and meta-analysis of randomized controlled trials comparing hysteroscopic morcellation with resectoscopy for patients with endometrial lesions. Int J Gynaecol Obstet. 2017;136:6-12.
Lieng M, Istre O, Sandvik L et al. Prevalence, 1-year regression rate, and clinical significance of asymptomatic endometrial polyps: cross-sectional study. J Minim Invasive Gynecol. 2009;16:465-71.
Lisón JF, Amer-Cuenca JJ, Piquer-Martí S et al. Transcutaneous Nerve Stimulation for Pain Relief During Office Hysteroscopy: A Randomized Controlled Trial. Obstet Gynecol. 2017;129:363-370
Loddo A, Djokovic D, Drizi A et al. Hysteroscopic myomectomy: The guidelines of the International Society for Gynecologic Endoscopy (ISGE). Eur J Obstet Gynecol Reprod Biol. 2022;268:121-8.
Mahmud A, Smith PP, Clark TJ. Benchmarking services in Outpatient hysteroscopy (OPH): a quality improvement project. Eur J Obstet Gynecol Reprod Biol. 2021;259:211-21.
Mazzon I, Favilli, A, Grasso M et al. Is Cold Loop Hysteroscopic Myomectomy a Safe and Effective Technique for the Treatment of Submucous Myomas With Intramural Development? A Series of 1434 Surgical Procedures Journal of Minimally Invasive Gynecology. 2015;22:792–8.
Munro MG. Hysteroscopic Myomectomy of FIGO Type 2 Leiomyomas Under Local Anesthesia: Bipolar Radiofrequency Needle-Based Release Followed By Electromechanical Morcellation. J Minim Invasive Gynecol. 2016;23:12-3.
Munro MG, Critchley HO, Broder MS et al. FIGO Working Group on Menstrual Disorders. FIGO classification system (PALM-COEIN) for causes of abnormal uterine bleeding in nongravid women of reproductive age. Int J Gynaecol Obstet. 201;113:3-13.
Nagele F, O'Connor H, Davies A et al. 2500 Outpatient diagnostic hysteroscopies. Obstet Gynecol. 1996;88:87–92.
National Institute for Health and Care Excellence (NICE). Heavy menstrual bleeding: assessment and management. London; 2021 May 24. (NICE Guideline, No. 88.) Available from: https://www.ncbi.nlm.nih.gov/books/NBK493300/
National Institute for Health and Care Excellence (NICE). Hysteroscopic mechanical tissue removal (hysteroscopic morcellation) for uterine fibroids. 2021a. https://www.nice.org.uk/guidance/IPG704/chapter/1-Recommendations
Nappi L, Sorrentino F, Angioni S et al. Feasibility of hysteroscopic endometrial polypectomy using a new dual wavelengths laser system (DWLS): preliminary results of a pilot study. Arch Gynecol Obstet. 2017; 295:3–7.
Pampalona JR, Bastos MD, Moreno GM et al. A comparison of hysteroscopic mechanical tissue removal with bipolar electrical resection for the management of endometrial polyps in an ambulatory care setting: preliminary results. J Minim Invasive Gynecol. 2015;22:439-45.
Papalampros P, Gambadauro P, Papadopoulos N et al. The mini-resectoscope: a new instrument for office hysteroscopic surgery. Acta Obstet Gynecol Scand. 2009;88:227-30.
Practice Committee of American Society for Reproductive Medicine in collaboration with Society of Reproductive Surgeons. Myomas and reproductive function. Fertil Steril. 2008;90:S125–S130.
Rajesh SK, Guyer C. Myosure Hysteroscopic Morcellation for the Management of Submucous Fibroids in an Out-Patient Hysteroscopy Setting. J Minim Invasive Gynecol. 2015;22:S102-3.
Reinders IMA, Geomini PMAJ, Leemans JC et al. Intrauterine fundal anaesthesia during endometrial ablation in the office: A randomised double-blind, non-inferiority trial. Eur J Obstet Gynecol Reprod Biol. 2020;254:206-11.
Royal College of Obstetricians and Gynaecologists (RCOG). Good practice paper No 16. Pain Relief and Informed Decision Making for Outpatient Hysteroscopy. London: RCOG; 2023 [https://www.rcog.org.uk/media/ymvha2n3/gpp16-final-publication-proof.pdf].
Royal College of Obstetricians and Gynaecologists (RCOG): Morcellation for myomectomy or hysterectomy. https://www.rcog.org.uk/en/patients/patient-leaflets/morcellation-myomectomy-hysterectomy/ (Accessed July 26, 2023).
Rubino RJ, Lukes AS. Twelve-month outcomes for patients undergoing hysteroscopic morcellation of uterine polyps and myomas in an office or ambulatory surgical center. J Minim Invasive Gynecol. 2015;22:285-90.
Russo M, Suen M, Bedaiwy M, Chen I. Prevalence of Uterine Myomas Among Women with 2 or More Recurrent Pregnancy Losses: A Systematic Review. J Minim Invasive Gynecol. 2016;23:702-6.

Sasaki LMP, Andrade KRC, Figuereido ACMG et al. Factors Associated with Malignancy in Histeroscopically Resected Endometrial Polyps: A Systematic Review and MetaAnalysis. J Minim Invasive Gynecol. 2018;25:777-85.
Scheiber MD, Chen SH. A Prospective Multicenter Registry of Patients Undergoing Hysteroscopic Morcellation of Uterine Polyps and Myomas. J Gynecol Surg. 2016;32:318-23.
Smith MD, Rowan E, Spaight R et al. Evaluation of the effectiveness and costs of inhaled methoxyflurane versus usual analgesia for prehospital injury and trauma: non-randomised clinical study. BMC Emerg Med. 2022;22:122.
Smith PP, Clark TJ. Chapter 10: Hysteroscopic endometrial polypectomy in Clark TJ and Connor ME. (Eds). Diagnostic & Operative Hysteroscopy Cambridge University Press August 2020: 180-193.
Smith PP, Middleton LJ, Connor M et al. Hysteroscopic morcellation compared with electrical resection of endometrial polyps: a randomized controlled trial. Obstet Gynecol. 2014;123:745–51.
Stewart AJ, Brooker C, Vose G et al. Pain and symptom relief using inhaled methoxyflurane for gynecologic brachytherapy applicator removal. J Contemp Brachytherapy. 2023;15:37-42.
The Use of Hysteroscopy for the Diagnosis and Treatment of Intrauterine Pathology. Obstet. Gynecol. 2020;135:754–6.
Timmermans A, Veersema S. Ambulatory transcervical resection of polyps with the Duckbill polyp snare: a modality for treatment of endometrial polyps. J Minim Invasive Gynecol. 2005;12:37–9.
Tommaso S, Cavallotti C, Malvasi A et al. A qualitative and quantitative study of the innervation of the human non pregnant uterus. Curr Protein Pept Sci. 2016;18:140–8.
Umranikar S, Clark TJ, Saridogan E et al. British Society for Gynaecological Endoscopy /European Society for Gynaecological Endoscopy Guideline Development Group for Management of Fluid Distension Media in Operative Hysteroscopy. BSGE/ESGE guideline on management of fluid distension media in operative hysteroscopy. Gynecol Surg. 2016;13:289-303.
Valero I, García-Jiménez R, Florez N et al. Mini-resectoscope vs morcellator for in-office hysteroscopic myomectomy: Evaluation of results and patient satisfaction. Eur J Obstet Gynecol Reprod Biol. 2022;270:95-9.
van der Meulen JF, Bongers MY, Coppus SFPJ et al. The (cost) effectiveness of procedural sedation and analgesia versus general anaesthesia for hysteroscopic myomectomy, a multicentre randomised controlled trial: PROSECCO trial, a study protocol. BMC Womens Health. 2019;19:46.
van Dongen H, de Kroon CD, Jacobi CE et al. Diagnostic hysteroscopy in abnormal uterine bleeding: a systematic review and meta-analysis. BJOG 2007;114:664–75.
van Dongen H, Emanuel MH, Wolterbeek R et al. Hysteroscopic morcellator for removal of intrauterine polyps and myomas: a randomized controlled pilot study among residents in training. J Minim Invasive Gynecol. 2008;15:466–71.
van Gemert J, Herman MC, Beelen P et al. Endometrial polypectomy using tissue removal device or electrosurgical snare: a randomised controlled trial. Facts Views Vis Obgyn. 2022;14:235-43.
van Wessel S, van Vliet HAAM, Schoot BC et al. Hysteroscopic morcellation versus bipolar resection for removal of type 0 and 1 submucous myomas: A randomized trial. Eur J Obstet Gynecol Reprod Biol. 2021;259:32-7.
Varma R, Soneja H, Clark TJ et al. Hysteroscopic myomectomy for menorrhagia using VersascopeTM bipolar system: Efficacy and prognostic factors at a minimum of one year follow up. Eur J Obstet Gynecol Reprod Biol 2009;142:154-9.
Vasiljević M, Rakić S, Mihajlović S et al. Hysteroscopy: History and development. Srpski arhiv za celokupno lekarstvo. 2019;147:375-9.
Vercellini P, Zaina B, Yaylayan L et al. Hysteroscopic myomectomy: long-term effects on menstrual pattern and fertility. Obstet Gynecol 1999;94:341–7.
Vitale SG, Moore O, Riemma G et al. Hysteroscopic laser ablation of symptomatic uterine fibroids: insights from a prospective study. Climacteric. 2023;11:1-6.
Wamsteker K, Emanuel MH, de Kruif JH. Transcervical hysteroscopic resection of submucous fibroids for abnormal uterine bleeding: results regarding the degree of intramural extension. Obstet Gynecol. 1993;82:736-40.

doi.org/10.52054/FVVO.15.M.100

Review

Hysteroscopic removal of retained products of conception in the outpatient setting*

N. Smorgick[1], Y. Melcer[1], O. Levinsohn-Tavor[1], S. Haimovich[2]

[1]Department of Obstetrics and Gynecology; The Yitzhak Shamir Medical Center (formerly Assaf Harofeh Medical Center), affiliated to the Sackler Faculty of Medicine, Tel Aviv University, Tel Aviv, Israel; [2]Department of Obstetrics and Gynecology, Laniado University Hospital, Netanya, Israel. Adelson School of Medicine, Ariel University, Ariel, Israel.
**This article was not peer reviewed by Facts, Views and Vision. The lead author was commissioned by Hologic.*

Correspondence at: Sergio Haimovich, Department of Obstetrics and Gynecology, Laniado University Hospital, Netanya, Israel. Adelson School of Medicine, Ariel University, Ariel, Israel. E-mail: sergio.haimovich@gmail.com

Abstract

This article presents an overview of the diagnosis and classification of retained products of conception (RPOC) as well as removal techniques and discusses the associated complications, advantages and disadvantages of these procedures. RPOC occur when tissue from the placenta or the fetus remain in the uterus after all types of termination of pregnancy and deliveries, including vaginal or cesarean delivery, spontaneous miscarriage, or induced medical or surgical abortion. The diagnosis is based on the combination of clinical findings and ultrasound (US) evaluation (gray-scale and Doppler flow). Hysteroscopy has emerged as the preferred treatment for women with RPOC largely due to its demonstrated safety, feasibility, low incidence of postoperative intrauterine adhesions (IUAs) and high rates of subsequent fertility. Furthermore, thanks to the availability of hysteroscopic tissue removal systems (HTRs) and the miniresectoscope, many hysteroscopic procedures can now be performed without anaesthesia or cervical dilation in an ambulatory setting. Further studies are required to provide a more comprehensive understanding of the reproductive outcomes in patients with pregnancies complicated by RPOC.

Keywords: **Retained products of conception, hysteroscopy, intrauterine adhesions, hysteroscopic tissue removal system, reroductive outcomes.**

Introduction

Retained products of conception (RPOC) occur when tissue from the placenta or the fetus remain in the uterus after all types of termination of pregnancy and deliveries, including vaginal or cesarean delivery, spontaneous miscarriage, or induced medical or surgical abortion. This complication is also termed "placental polyp," "retained placental fragment" or "residual trophoblastic tissue."

The incidence of RPOC varies as a function of the type of pregnancy; i.e., full-term delivery, miscarriage, or induced abortion. The incidence of RPOC following full-term vaginal or cesarean delivery is low, around 1% (Weissbach et al., 2015; Capmas et al., 2019). The rate is significantly higher for miscarriages and for medical abortions, with a prevalence of 6% and 15% respectively (Smorgick et al., 2014). However, these figures are likely to vary widely depending on the population and the definition of RPOC used in the study.

The signs and symptoms of RPOC include abnormal uterine bleeding, abdominal pain, fever and signs of infection, and a persisting dilated cervix. However, RPOC are also frequently diagnosed incidentally during an ultrasound (US) examination. In the long term, RPOC can cause severe complications, such as endometritis and intrauterine adhesions formation (IUAs), and may potentially lead to secondary infertility (Smorgick et al., 2014). A number of risk factors are associated with RPOC, including second trimester demise, morbidly adherent placenta, history of RPOC in a previous pregnancy, presence of IUAs, and uterne anomalies such as uterine septum. More recent works have suggested that ART-related pregnancies may be a risk factor for RPOC (Baba et al., 2013).

The diagnosis and management of RPOC is challenging because there are no universally accepted diagnostic criteria or treatment protocols

(Hooker et al., 2016). The diagnosis is usually based on ultrasound findings indicative of a heterogeneous intracavitary hyperechoic focal mass, with a poorly defined endometrium-myometrium interface, a fluid layer, and/or increased and irregular endometrial thickness. A color Doppler examination can improve diagnostic accuracy and help differentiate between different types of RPOC (Kamaya et al., 2009).

In outpatient settings today, several strategies are used to manage RPOC, ranging from expectant or medical management to surgical evacuation of the uterine cavity. Goldenberg was the first to report the use of hysteroscopy for the removal of residual trophoblastic tissue using a cutting loop as a curette for selective removal (Goldenberg et al., 1997). Since then, additional hysteroscopic techniques such as the tossuetissue removal devices have been introduced to deal with this pathology.

This article presents an overview of the diagnosis and classification of RPOC as well as hysteroscopic removal techniques and discusses the associated complications, advantages and disadvantages of these procedures.

Diagnosis and classification

The diagnosis of RPOC presents a major clinical challenge, since overdiagnosis may lead to unnecessary interventions and possible complications, while underdiagnosis may cause long term sequela such as IUAs. Since the first report by Robinson in 1972, US has been used as the first-line diagnostic tool for suspected RPOC, thanks to its wide availability, high reproducibility and non-invasiveness (Robinson, 1972). Older studies did report high rates of false positive results for the diagnosis of RPOC by US, reaching 17-51% (Shen et al., 2003; DeVries et al., 2000; Malvern et al., 1973; Sadan et al., 2004). However, these fndings have been attributed to the incorrect interpretation of the variable appearance of the normal post-pregnancy uterus, and more recent studies found significantly higher rates of accurate diagnosis.

During the postpartum period 6-8 weeks after delivery, the uterus undergoes involution and returns to its original state and the endometrium resumes its normal thickness (Mulic-Lutvica et al., 2001; Steinkeler et al., 2012). RPOC can only be successfully diagnosed if the clinician has a clear understanding of what to expect in a normal, uncomplicated recovery. Uterine cavity contents such as fluid, debris, and blood clots appear as echogenic findings on US. In most cases, these findings are a normal part of the postpartum recovery process, should not be diagnosed as RPOC per se and usually disappear by the end of the puerperal period (Mulic-Lutvica et al., 2001; Steinkeler et al., 2012; Edwards and Ellwood, 2000). The patient's history should always be elicited and related to the clinical symptoms.

The timing of the examination during puerperium is crucial. Sokol et al. (2004) conducted a prospective observational study on normal transabdominal US findings after uncomplicated vaginal delivery in 40 women within 48h after delivery (Sokol et al., 2004). In 40% of these women, there was echogenic material in the endometrial cavity. No association with heavier or prolonged bleeding was found and none of the women needed medical care. Edwards and Ellwood (2000) performed transabdominal US in 40 women at days 7, 14 and 21 after a normal vaginal delivery. The mean duration of postpartum bleeding was 24.5 days. They showed that 51% had an echogenic mass within the uterine cavity at seven days postpartum, which then dropped sharply to 6% at day 21. This US finding was likely blood clots, which raises questions as to the significance of finding an echogenic mass when diagnosing RPOC, which has a positive predictive value (PPV) of 59% (Edwards and Ellwood, 2000). This suggests that it may be worthwhile postponing the US evaluation until the end of the puerperal period.

The key finding of RPOC on a gray-scale US is a thickened endometrial echo complex (EEC), with a cut-off value of 10 mm (ranging from 8 to 13 mm) or an intracavitary mass with a thickened EEC (Sellmyer et al., 2013). By contrast, specificity is rather low. If no endometrial mass is detected or the endometrium thickness is less than 10 mm, RPOC are rare. In clinical settings, however, the diagnosis of RPOC is not made solely on the basis of gray-scale US findings.

Recent studies have shown that colour Doppler US enhances RPOC diagnostic accuracy. For example, detection of vascularity in a thickened endometrium or endometrial mass was reported to increase the PPV for the diagnosis of RPOC to 65% or even 100% (Van den Bosch et al., 2008; Atri et al., 2011). However, even if there is no hypervascularity in the intracavitary mass or thickened EEC, this does not exclude RPOC (Durfee et al., 2005; Sellmyer et al., 2013). The presence of intrinsic vascularity helps distinguish simple clots which may resemble RPOC on gray-scale imaging from true RPOC. When utilising Doppler sonography, signals arising from tissue within the endometrial cavity need to be differentiated from signals within the adjacent myometrium, which may represent the implantation site, as in

cases of subinvolution. Other potential pitfalls in this diagnosis are rare but can include enhanced myometrial vascularity (EMV), preexisting endometrial polyps, submucosal fibroid and invasive moles.

One possible explanation for the wide range of percentage margin for the diagnosis of RPOC on colour Doppler US is when retained products expulsed spontaneously during the period of time between the US scan and the surgical procedure or follow-up examination. Another possibility is the subinvolution of the placental site. Specifically, if a blood clot is adjacent to the involution site, the colour Doppler flow may appear to be within the endometrium. Thus Doppler signals arising from tissue within the endometrial cavity need to be differentiated from signals occurring within the adjacent myometrium.

The degree of vascularisation into the thickened EEC or mass is also important. Kamaya et al. (2009) were the first to categorise suspected RPOC on the basis of Doppler vascularity (Kamaya et al., 2009). They divided them into four types ranging from Type 0 (avascular) to type 3 (marked vascularity). This Doppler characterisation was later adapted to create the Gutenberg RPOC classification which incorporates the vascularity and the echogenicity of ultrasound findings (Figure 1) (Tinelli and Haimovich, 2017). This classification is designed to predict the risk of intraoperative bleeding during the hysteroscopic removal of RPOC (Figure 2) (Alonso Pacheco et al., 2019).

Studies over the last 30 years have explored the relationship between RPOC and clinical and sonographic parameters (Ben-Ami et al., 2005; Neill et al., 2002). The results suggest that combining ultrasound and clinical assessment improves diagnostic accuracy when they are both positive or negative, but provides little clarification when the clinical and ultrasound findings do not coincide. Thus a combination of clinical and sonographic evaluations should be carried out before the decision to proceed with surgery, to help avoid unnecessary invasive procedures.

There is no consensus in the literature on a standardised postpartum US protocol or the interpretation of US findings in the uterine cavity. In a recent study (Levinsohn-Tavor et

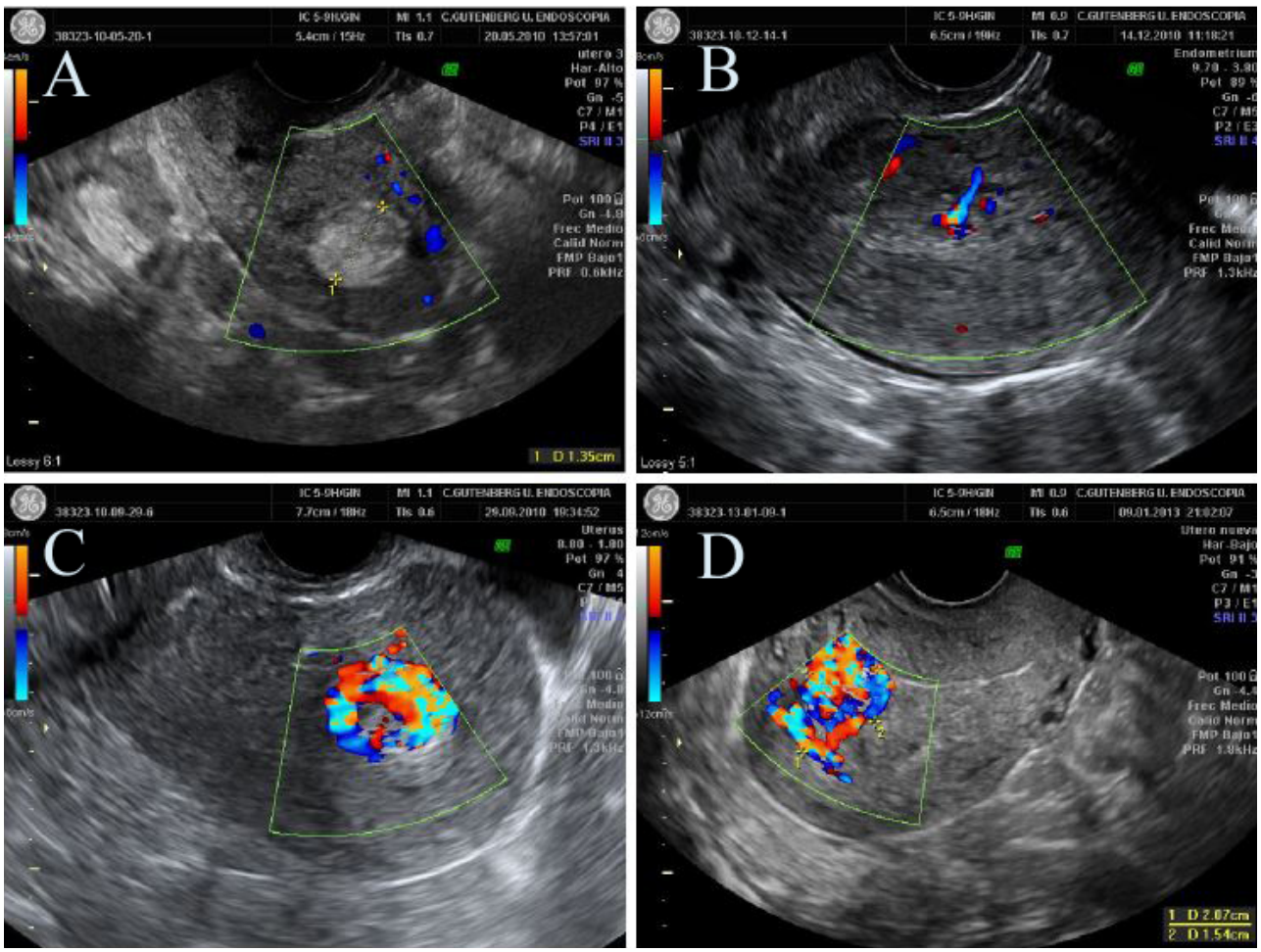

Figure 1: Ultrasonographic patterns of RPOC. Gutenberg Classification. A- Type 0: hyperechogenic avascular mass. B-Type 1: Different echoes with minimal or no vascularisation. C- Type 2: Highly vascularised mass confined to the cavity. D- Type 3: Highly vascularised mass with highly vascularised endometrium (Reproduced with permission from Alonso Pacheco et al., 2019).

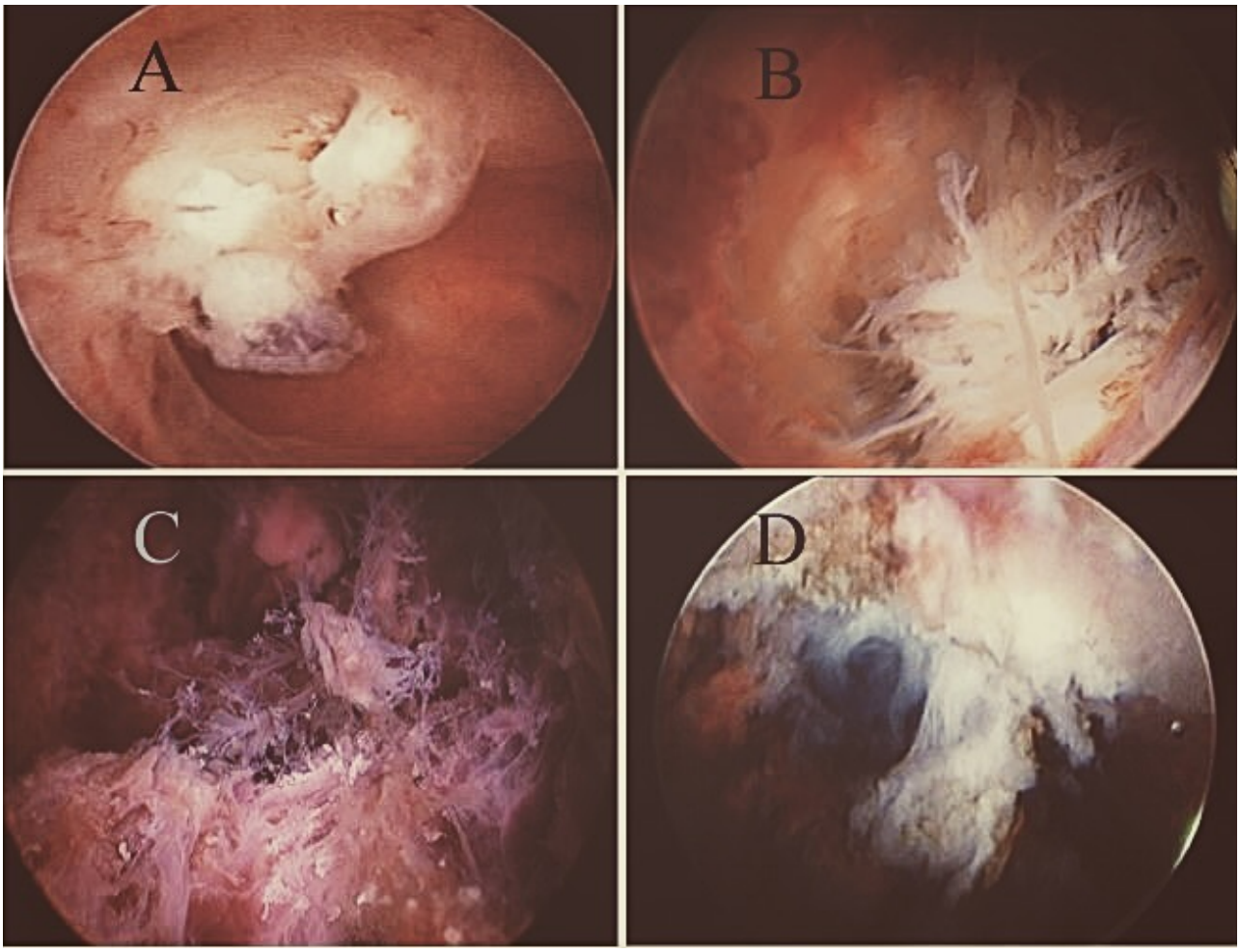

Figure 2: Hysteroscopic patterns of RPOC. Gutenberg classification. A- Type 0: white mass in with no clear structures. B- Type 1: well-defined avascular chorionic villi. C- Type 2: Well vascularised chorionic villi. D- Fig 4: Aneurism over myometrium in the implantation area (Reproduced with permission from Alonso Pacheco et al., 2019).

al., 2020), we presented our clinical approach to managing patients with suspected RPOC based on a classification of US findings in the uterine cavity into high, moderate , and low probability of RPOC (Figure 3A-C). The findings confirmed the presence of RPOC in 62%, 32%, and 0% of the high, moderate, and low probability groups, respectively. In the low probability group with normal sonographic findings, no surgical intervention is recommended. In the high probability group, surgical evacuation of the uterine content is indicated and we recommend operative hysteroscopy. When sonographic findings are within the moderate probability category, and the patient is clinically stable, expectant management with a follow-up scan at the end of the puerperal period is recommended. This approach may increase the positive predictive value of the US examination and avoid unnecessary interventions. Very recently, we conducted a larger prospective study that confirmed our results (Levinsohn-Tavor et al., 2022). This 3-group approach is now included in the Israeli professional guidelines for the diagnosis and treatment of RPOC (Israeli Society of Obstetrics and Gynecology, position paper 122, https://www.ima.org.il/main/EditClinicalInstruction.aspx?ClinicalInstructionId=2499).

Hysteroscopy for removal of retained products of conception

The surgical management of retained products of conception (RPOC) by hysteroscopy was first proposed by Goldenberg et al. in 1997 using the 10 mm resectoscope as an outpatient procedure under general anesthesia (Goldenberg et al., 1997). Subsequently, multiple studies have described the surgical technique and its short and long-term outcomes using different types of hysteroscopes, with and without general anesthesia (Smorgick et al., 2014; Hooker et al., 2016; Cohen et al., 2001; Golan et al., 2011; Barel et al., 2015). All hysteroscopic techniques rely on the direct visualisation of the uterine cavity, which enables targeted, focused removal of the RPOC rather than blind, global curettage, avoiding unnecesssary trauma to the unaffected parts of the cavity. In addition,

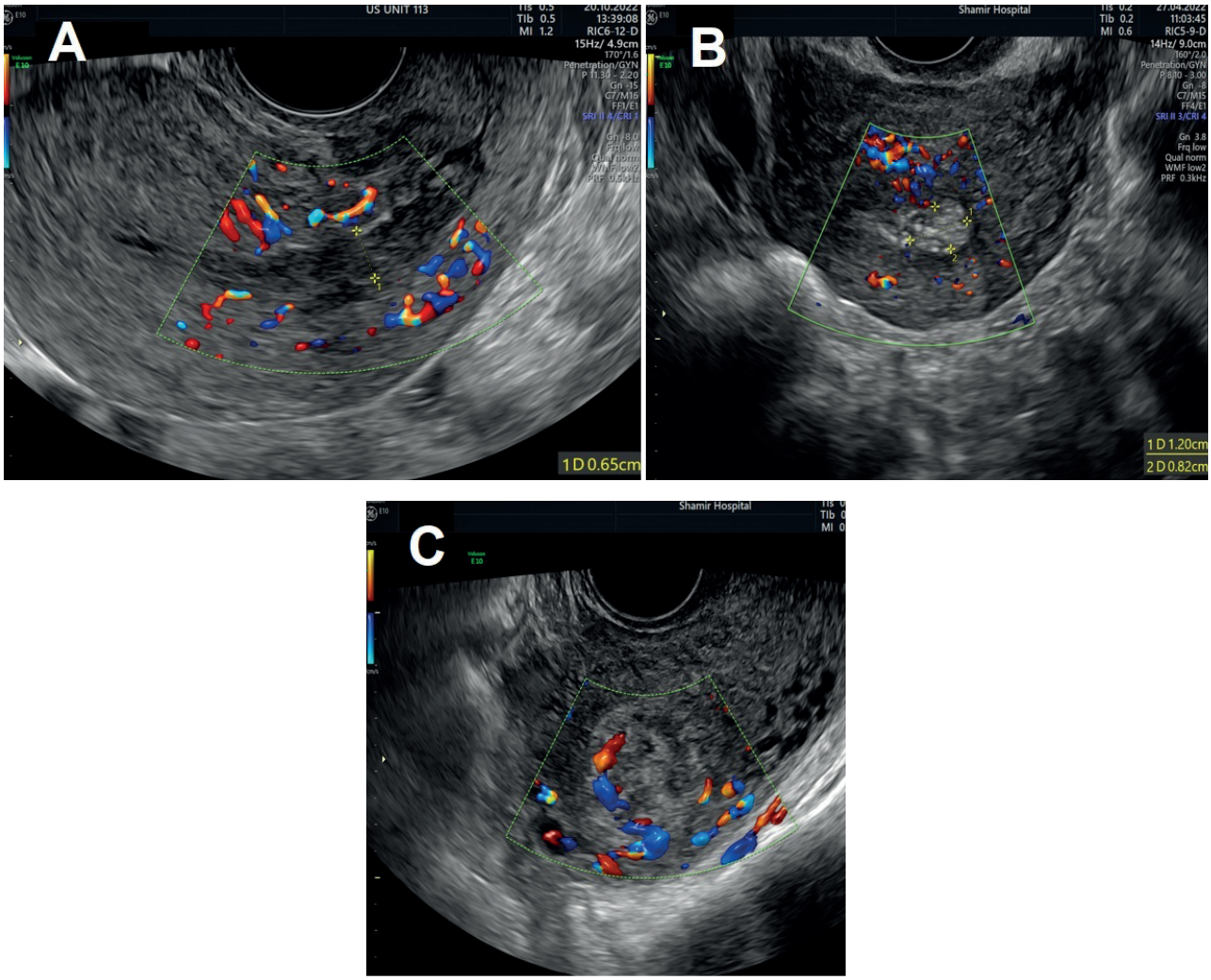

Figure 3: Images of the uterine cavity in patients with suspected retained products of conception after delivery. (A) Low probability: no echogenic mass, endometrial thickness<10 mm, no vascularity. (B) Moderate probability: endometrial thickness >10 mm without vascularity; (C) High probability: an echogenic mass or endometrial thickness >10mm with vascularity.

hysteroscopy has the advantage of complete visualisation of the uterine cavity, which makes it possible to confirm that all the retained products have been removed, in addition to the identification and treatment of uterine anomalies. To minimise the risk of postoperative intrauterine adhesions and their fertility sequelae, the hysteroscopic procedure is performed using a non-traumatic technique with limited or no electrosurgery. Other strategies for the prevention of intrauterine adhesions include the use of barrier intrauterine gel, oral oestrogen, and diagnostic office hysteroscopy performed about 6 weeks after surgery (AAGL/ESGE guidelines) (AAGL/ESGE guidelines, 2017).

1. Resectoscopy

In this technique, the loop of the resectoscope is used for blunt separation of the RPOC from the uterine walls along the surgical plane between the endometrium and the RPOC. In cases of large,vascular RPOC when the surgical plane cannot be clearly observed, the resectoscope loop may be used to resect the superficial areas of the RPOC, followed by blunt separation of the deeper areas adjacent to the endometrium. When a large bore resectoscope is used (e.g., 10 mm), cervical dilation is performed, which requires general anaesthesia or sedation. However, unless heavy bleeding has occurred, most of these procedures are performed in the outpatient setting. The recent development of a small diameter “mini-resectoscope” (5-6 mm) now permits some procedures without anaesthesia. Because of its smaller loop, the mini resectoscope is typically used to remove smaller RPOC (<2 cm).

2. Mechanical instruments (hysteroscopic shears and graspers)

Mechanical instruments can be introduced through the working channel of the small diameter (4-5 mm) hysteroscope using a vaginoscopic approach without cervical dilation or anaesthesia (Raz et al., 2022). The grasper and/or scissors are used to separate the RPOC from the uterine wall, and the subsequent grasping and removal of the RPOC mass. These

instruments are appropriate for the removal of small non-vascular RPOC, usually <2 cm (Mohr-Sasson et al., 2022).

Overall, favourable outcomes have been reported for hysteroscopic removal of RPOC, with low rates of complications and postoperative adhesions and high rates of subsequent pregnancies (Smorgick et al., 2014; Hooker et al., 2016). The rare reported intra- and postoperative complications include uterine perforation, bleeding requiring transfusion, and re-admission for fever (all in less than 1% of the cases). Postoperative adhesions were reported in 5% to 20% and were classified as mild in most cases (Smorgick et al., 2014; Hooker et al., 2016). The postoperative fertility rate was >80%, although subsequent pregnancies were complicated by adherent placenta and recurrent RPOC (Capmas et al., 2019; Smorgick et al., 2018).

3. Hysteroscopic tissue removal systems and retained products of conception

In 1999, Dr. Mark Hans Emanuel, a Dutch gynaecologist, designed the first generation of hysteroscopic mechanical shavers with the support of Smith and Nephew Ltd. (Andover, MA, USA). Since then, several hysteroscopic tissue removal systems (HTRS) have become available (Emanuel and Wamsteker, 2005). TruClear® (Medtronic, Dublin, Ireland) was the first to receive FDA approval in 2005, followed by MyoSure® (Hologic, Marlborough, MA, USA) and the Integrated Bigatti Shaver® (Karl Storz, Tüttlingen, Germany). The innovative hybrid Symphion™ (Minerva Surgical Inc, Santa Clara, CA, USA) system enables automatic aspiration of tissue fragments resected with a bipolar radiofrequency through a self-contained, recirculating fluid management system. Aveta® (Meditrina, Inc., San José, CA, USA) is a disposable system with high-speed mechanical oscillation mechanism.

When using HTRS for the management of RPOC, the blade of the device is introduced into the uterine cavity through the working channel of a rigid hysteroscope. For optimal uterine cavity distension, irrigation, and visibility, a continuous flow system is used (Georgiou et al., 2018; Hamerlynck et al., 2013). At the tip of the device, through a lateral window opening, the cutting blades cut the target tissue and the sample is aspirated by a vacuum source. Aspiration of blood clots and direct removal of intrauterine pathology result in good visualization, which permits satisfactory imaging throughout the procedure. The tissue can also be approached laterally, so that it can be scooped out of the myometrium when necessary.

HTRS are becoming an increasingly popular choice for the management of polyps and fibroids. They are also attracting interest for RPOC, given their precision, safety, and effectiveness (Georgiou et al., 2018). Hamerlynck et al. first described the use of hysteroscopic morcellation in the management of placental remnants in 2013 (Hamerlynck et al., 2013). This retrospective case series covered 105 procedures performed between January 2005 and May 2013. The RPOCs had a mean diameter of 26 mm and the success rate of removal for a single approach of 94%.

When using manual HTRS, the operator is able to selectively remove products of conception under direct visualisation, thus causing minimal damage to the endometrium and reducing the risk of post-operative adhesion formation. Ansari et al. conducted a 5-year retrospective series that reported on 52 cases of RPOC treated by a HTRS, which were confirmed histologically. They found that the shaver technique enabled a faster procedure with minimal damage to the healthy endometrium. They also found that the later the surgical procedure was performed after a miscarriage, the less bleeding was observed as a consequence of the devascularisation of the placental remnants. The authors did not report any complications (Ansari et al., 2018).

The advantages of manual HTRS with complete and fast removal of RPOC have been confirmed in several case series (Georgiou et al., 2018; Mallick and Middleton, 2017; Sutherland and Rajesh, 2018; Capote et al., 2018; Arnold et al., 2016). Hamerlynck et al. (2016) conducted a randomised controlled trial which showed that HTRS constitute a faster alternative to loop resection (Hamerlynck et al., 2016). She compared 37 cases treated by HTRS to 36 cases treated by loop resection. Both techniques are considered safe and show high rates of complete removal and tissue availability with 3% de novo intrauterine adhesion formation. In the HTRS group, the procedure was significantly faster (median operating time, 10.0 minutes [interquartile range (IQR), 5.8 − 16.4 minutes] vs. 6.2 minutes [IQR, 4−11.2 minutes]; p = 0.023).

Van Wessel et al. (2020) recently reported findings on reproductive and obstetric outcomes after HTRs and resection. In this cohort study, the authors randomised 46 patients with RPOC in the morcellation group and compared the outcomes to 40 patients in the loop resection group. The mean time from procedure to conception after removal of RPOC was similar, at 14 weeks with HTRS and 15 weeks with loop resection. The live birth rate was higher in HTRS (88.9%) than for resection (68.2%), although the difference was not statistically significant (Van Wessel et al., 2020).

Another comparative analysis of clinical efficacy and reproductive outcome was recently published by Yong et al. (Yong et al., 2023). This cohort retrospective comparative study included 361 patients diagnosed with RPOC in the morcellation group who were compared to 261 patients in the hysteroscopy electrosurgery group. Bipolar energy was used in the hysteroscopy group. The operative time was shorter in the HTRS group (21vs. 31min., p=0.039), whereas in terms of efficacy, in HTRs group a complete resection rate of 94% was achieved compared to 93% in the hysteroscopy group. In 24 of the 25 failures in the morcellator group, placenta accreta was found. The mean follow-up was 3 years, and the conception rate was higher in the mechanical removal group. Postpartum placenta abnormalities were found in 3.8% of the cases in the HTRS group compared to 10.5% in the other (p=0.017), probably due to the energy damage caused to the uterine wall. Although these data are promising, it is clear that more randomised comparative studies are needed to assess the relative value of HTRS in the treatment of RPOC.

Note that although these systems are considered safe and require a short learning curve, complications have been described, as with any other surgical tool. Safety is not only based on the device itself but also on training and prior experience.

Discussion

The diagnosis and management of RPOC have evolved considerably in the last 15 years. Previously, the diagnosis was based primarily on the clinical presentation of heavy vaginal bleeding and the management primarily by curettage, which may cause severe IUAs and Asherman's syndrome in up to 40% of women (Westendorp et al., 1998). Currently, the diagnosis is based on the combination of clinical findings and US evaluation (which includes gray-scale and Doppler flow scans), and the management is preferably by hysteroscopy, with low rates of postoperative IUAs and high rates of subsequent fertility (Capmas et al., 2019; Smorgick et al., 2014; Hooker et al., 2016). Indeed, a recent study comparing the management of postpartum RPOC between two periods has showed that most cases of RPOC are currently managed by hysteroscopy rather than curettage and that the rates of postoperative IUAs have concurrently decreased (Nir et al., 2022). Furthermore, thanks to the availability of HTRS and the miniresectoscope, many hysteroscopic procedure can now be performed without anaesthesia or cervical dilation in an ambulatory setting.

The timing of surgical inervention for RPOC has remained an important clinical question. In cases of postabortion RPOC (either medical or surgical, spontaneous or induced), expectant management can be offered to asymptomatic or mildly symptomatic patients since up to 60% of cases will resolve by spontaneous expulsion of the RPOC(Takahashi et al, 2019). An expectant management period of 2 menstrual cycles is usually considered acceptable. Obviously, significant symptoms such as bleeding or infection require early surgical intervention. Interestingly, Tzur et al found that medical treatment with misoprostol does not increase the rates of spontaneous expulsion of RPOC in this setting (Tzur et al., 2022).

In cases of postpartum RPOC, menstruation can be delayed due to lactation. Thus, the timing of surgical intervention is more difficut to ascertain, and the decision is individualised according to the patient's symptoms, ultrasound findings and classification (i.e., high or medium probability for RPOC, Figure 1) and the patient's desire for prolonged lactation (Levinsohn-Tavor et al., 2020; 2022). Unless surgical intervention is urgently required becase of significant symptoms, the hysteroscopy is usually offered after 6 to 8 weeks from delivery. Of note, delaying the surgical intervetion for >6 weeks after delivery has also the advantage of improved visualisation of the uterine cavity during hysteroscopy, since early intervention may be hindered by blood clots, decidua and debris in the cavity, and by difficuly in maintaining the intrauterine pressure due to cervical dilation.

Several hysteroscopic instruments are currently available for removal of RPOC, including mechanical instruments (grasper/scissors), HTRS , traditional large-bore resectoscopes, and the newer mini-resectoscopes. All these instruments have the advantages provided by hysteroscopy, namely a focused and non-traumatic procedure in the cavity, and all appear to have low rates of complications and IUAs and high rates of subsequent fertility, as opposed to curettage. The resusable mechanical instruments have the advantage of low cost, require minimal or no cervical dilation, and can be used in the see and treat setting without anaesthesia (Raz et al., 2022; Mohr-Sasson et al., 2022). However, they are mostly used for small and non-vascular RPOC, and require surgical expertise and relativey longer learning curve. The HTRS can also be used in the see and treat setting with no or minimal cervical dilation, appear to have a relatively shorter learning curve, and may be used for larger, albeit non-vascular RPOC. Nevertheless, cost is higher for the non-reusable blades. The traditional large-bore resectoscope remains the most appropriate

tool for removing large and vascular RPOC in the operative room, although surgical expertise is certainly required to minimise complications such as uterine perforation, and its learning curve is probably the longest of all hysteroscopic techniques.

Conclusion

Operative hysteroscopy has emerged as the preferred treatment for women with retained products of conception (RPOC), largely due to its demonstrated safety, feasibility, and low incidence of postoperative intrauterine adhesions (IUAs). The procedure may also offer potential benefits in terms of future conception rates. However, further studies are required to provide a more comprehensive understanding of the reproductive outcomes in patients with pregnancies complicated by RPOC. This includes investigating whether different hysteroscopic approaches, such as the utilisation of HTRS, enhance future fertility rates. Existing literature indicates the superiority of hysteroscopy over traditional dilatation and curettage for the treatment of RPOC, but additional research will help solidify these findings.

References

AAGL Elevating Gynecologic Surgery. AAGL practice report: practice guidelines on intrauterine adhesions developed in collaboration with the European Society of Gynaecological Endoscopy (ESGE). Gynecol Surg. 2017;14:6.

Alonso Pacheco L, Timmons D, Saad Naguib M et al. Hysteroscopic management of retained products of conception: A single center observational study. Facts Views Vis Obgyn. 2019;11:217-22.

Ansari SH, Bigatti G, Aghssa MM. Operative hysteroscopy with the Bigatti shaver (IBS®) for the removal of placental remnants. Facts Views Vis Obgyn. 2018;10:153-9.

Arnold A, Ketheeswaran A, Bhatti M et al. A Prospective Analysis of Hysteroscopic Morcellation in the Management of Intrauterine Pathologies. J Minim Invasive Gynecol. 2016;23:435-41.

Atri M, Rao A, Boylan C et al. Best predictors of grayscale ultrasound combined with color Doppler in the diagnosis of retained products of conception. J Clin Ultrasound. 2011;39:122-7.

Baba T, Endo T, Ikeda K et al. Assisted reproductive technique increases the risk of placental polyp. Gynecol Endocrinol. 2013;29:611–4.

Barel O, Krakov A, Pansky M et al. Intrauterine adhesions after hysteroscopic treatment for retained products of conception: what are the risk factors? Fertil Steril. 2015;103:775-9.

Ben-Ami I, Schneider D, Maymon R et al. Sonographic versus clinical evaluation as predictors of residual trophoblastic tissue. Hum Reprod. 2005;20:1107-11.

Capmas P, Lobersztajn A, Duminil L et al. Operative hysteroscopy for retained products of conception: Efficacy and subsequent fertility. J Gynecol Obstet Hum Reprod. 2019;48:151-4.

Capote S, Cubo-Abert M, Casellas-Caro M et al. Role of office hysteroscopic morcellation and 3-dimensional transvaginal ultrasound in conservative management of retained placenta accreta. Eur J Obstet Gynecol Reprod Biol. 2018;230:199-200.

Cohen SB, Kalter-Ferber A, Weisz BS et al. Hysteroscopy may be the method of choice for management of residual trophoblastic tissue. J Am Assoc Gynecol Laparosc. 2001;8:199-202.

DeVries JIP, van der Linden RM, van der Linden HC. Predictive values of sonographic examination to visualize retained placenta directly after birth at 16 to 28 weeks. J Ultrasound Med. 2000;19:7–12.

Durfee SM, Frates MC, Luong A et al. The sonographic and color Doppler features of retained products of conception. J Ultrasound Med. 2005;24:1181-6.

Edwards A, Ellwood DA. Ultrasonographic evaluation of the postpartum uterus. Ultrasound Obstet Gynecol. 2000;16:640-3.

Emanuel MH, Wamsteker K. The Intra Uterine Morcellator: a new hysteroscopic operating technique to remove intrauterine polyps and myomas. J Minim Invasive Gynecol. 2005;12:62-6.

Georgiou D, Tranoulis A, Jackson TL. Hysteroscopic tissue removal system (MyoSure) for the resection of polyps, sub-mucosal leiomyomas and retained products of conception in an out-patient setting: A single UK institution experience. Eur J Obstet Gynecol Reprod Biol. 2018;231:147-51.

Golan A, Dishi M, Shalev A et al. Operative hysteroscopy to remove retained products of conception: novel treatment of an old problem. J Minim Invasive Gynecol. 2011; 18:100-3.

Goldenberg M, Schiff E, Achiron R et al. Managing residual trophoblastic tissue. Hysteroscopy for directing curettage. J Reprod Med. 1997;42:26–8.

Hamerlynck TW, Blikkendaal MD, Schoot BC et al. An alternative approach for removal of placental remnants: Hysteroscopic morcellation. J Minim Invasive Gynecol. 2013;20:796-802.

Hamerlynck TW, van Vliet HA, Beerens AS et al. Hysteroscopic morcellation versus loop resection for removal of placental remnants: A randomized trial. J Minim Invasive Gynecol. 2016;23:1172-80.

Hooker AB, Aydin H, Brölmann HA et al. Long-term complications and reproductive outcome after the management of retained products of conception: A systematic review. Fertil Steril. 2016;105:156-64.e1-2.

Kamaya A, Petrovitch I, Chen B et al. Retained products of conception: Spectrum of color Doppler findings. J Ultrasound Med. 2009;28:1031-41.

Levinsohn-Tavor O, Feldman N, Svirsky R et al. Ultrasound criteria for managing postpartum patients with suspicion of retention of conception products. Acta Radiol. 2020;61:276–81.

Levinsohn-Tavor O, Zilberman Sharon N, Feldman F et al. Managing patients with suspected postpartum retained products of conception using a novel sonographic classification. Acta Radiol. 2022;63:410-5.

Mallick R, Middleton B. The use of hysteroscopic morcellation in the outpatient management of retained products of conception. Res Rep Gynaecol Obstet. 2017;1:17-15.

Malvern J, Campbell S, May P. Ultrasonic scanning of the puerperal uterus following secondary postpartum haemorrhage. J Obstet Gynecol. 1973;80:320-4.

Mohr-Sasson A, Gur T, Meyer R et al. Office Operative Hysteroscopy for the Management of Retained Products of Conception. Reprod Sci. 2022;29:761-7.

Mulic-Lutvica A, Bekuretsion M, Bakos O et al. Ultrasonic evaluation of the uterus and uterine cavity after normal, vaginal delivery. Ultrasound Obstet Gynecol. 2001;18:491-8.

Neill AC, Nixon RM, Thornton S. A comparison of clinical assessment with ultrasound in the management of secondary postpartum haemorrhage. Eur J Obstet Gynecol Reprod Biol. 2002;104;113-5.

Nir A, Mor M, Yekutiel M et al. Postpartum retained products of conception: Is it possible to avoid postpartum curettage? Int J Gynaecol Obstet. 2022;156:231-5.

Raz N, Sigal E, Gonzalez Arjona F et al. See-and-treat in-office hysteroscopy versus operative hysteroscopy for the treatment of retained products of conception: A retrospective study. J Obstet Gynaecol Res. 2022;48:2459-65.
Robinson HP. Sonar in the puerperium. A means of diagnosing retained products of conception. Scot Med J. 1972;1:364-6.
Sadan O, Golan A, Girtler O et al. Role of sonography in the diagnosis of retained products of conception. J Ultrasound Med. 2004;23:371-4.
Sellmyer MA, Desser TS, Maturen KE et al. Physiologic, histologic, and imaging features of retained products of conception. Radiographics. 2013;33:781-96.
Shen O, Rabinowitz R, Eisenberg VH et al. Transabdominal sonography before uterine exploration as a predictor of retained placental fragments. J Ultrasound Med. 2003;22:561-4.
Smorgick N, Barel O, Fuchs N et al. Hysteroscopic management of retained products of conception: Meta-analysis and literature review. Eur J Obstet Gynecol Reprod Biol. 2014;173:19-22.
Smorgick N, Mittler A, Ben-Ami I et al. Retained products of conception: What is the risk for recurrence on subsequent pregnancies? Eur J Obstet Gynecol Reprod Biol. 2018;224:1-5.
Sokol ER, Casele H, Haney EI. Ultrasound examination of the postpartum uterus: what is normal? J Matern Fetal Neonatal Med. 2004;15:95-9.
Steinkeler J, Coldwell B J, Warner M A. Ultrasound of the postpartum uterus. Ultrasound Q. 2012;28:97-103.
Sutherland NSV, Rajesh H. The Intrauterine Bigatti Shaver System: An Alternative Option for Focal Retained Products of Conception. Case Rep Obstet Gynecol. 2018;2018:1536801.
Tinelli AP, Haimovich S. Hysteroscopy. New York, NY, Springer Berlin Heidelberg, 2017.
Tzur Y, Berkovitz-Shperling R, Goitein Inbar T et al. Expectant vs medical management for retained products of conception after medical termination of pregnancy: a randomized controlled study. Am J Obstet Gynecol. 2022;227:599.e1-599.e9.
Takahashi H, Ohhashi M, Baba Y et al. Conservative management of retained products of conception in the normal placental position: A retrospective observational study. Eur J Obstet Gynecol Reprod Biol. 2019;240:87-92.
Van den Bosch T, Daemen A, Van Schoubroeck D et al. Occurrence and outcome of residual trophoblastic tissue: a prospective study. J Ultrasound Med. 2008;27:357–61.
van Wessel S, Coryn N, van Vliet H et al. Reproductive and Obstetric Outcomes After Hysteroscopic Removal of Retained Products of Conception. J Minim Invasive Gynecol. 2020;27:840-6.
Weissbach T, Haikin-Herzberger E et al. Immediate postpartum ultrasound evaluation for suspected retained placental tissue in patients undergoing manual removal of placenta. Eur J Obstet Gynecol Reprod Biol. 2015 Sep;192:37-40.
Westendorp IC, Ankum WM, Mol BW et al. Prevalence of Asherman's syndrome after secondary removal of placental remnants or a repeat curettage for incomplete abortion. Hum Reprod. 1998;13:3347-50.
Yong J, Wan Y, Ye M et al. Comparative analysis of the clinical efficacy and reproductive outcomes of the hysteroscopic tissue removal system (MyoSure) and hysteroscopic electroresection in the treatment of benign intrauterine lesions. Int J Gynaecol Obstet. 2023 May 21.

doi.org/10.52054/FVVO.15.M.093

Review

Fluid management in hysteroscopy*

D.P. van der Ham[1]

[1]*MD PhD, Department of Obstetrics and Gynaecology, Martini Hospital Groningen, Postbus 30033, 9700 RM Groningen.*
**This article was not peer reviewed by Facts, Views and Vision. The lead author was commissioned by Hologic.*

Correspondence at: D.P. van der Ham, MD PhD, Department of Obstetrics and Gynaecology, Martini Hospital Groningen, Postbus 30033, 9700 RM Groningen. E-mail: D.vanderHam@mzh.nl

Abstract

Nowadays many hysteroscopic procedures can be done in the outpatient or office setting. With the introduction of tissue removal systems with a smaller diameter than a resectoscope, operative hysteroscopy is well tolerated and preferred by patients in the office setting. These procedures can be done with normal saline with seemingly limited risk of complications. However, as more operative hysteroscopic procedures are done outside the OR facility with limited surveillance of the patient, one should always be aware of the risks. Fortunately, potential life-threatening complications especially those related to fluid overload are hardly being reported anymore. However, if unnoticed, these complications can still occur.
This review gives an overview of the potential (life-threatening) risks and how, based on guidelines, fluid deficit should be monitored during operative hysteroscopic surgery. The use of an automated fluid management system makes monitoring easier and should be considered a standard of care in operative hysteroscopy in both in- and outpatient setting.

Keywords: **Fluid management, fluid overload, management, risk reduction.**

Introduction

Both diagnostic and increasingly therapeutic hysteroscopic procedures are progressively performed in an outpatient or office setting. This is due to the fact that over the last decades diameters of hysteroscopes as well as therapeutic instruments has decreased to an extend that is well tolerated by the patient in an office setting. Furthermore, the introduction of tissue removal systems has decreased operative risks (Noventa et al., 2015) and therefore office hysteroscopy seems to be easy and nearly complication free. Nevertheless, past has shown that severe complications can occur, especially in patients with unnoticed fluid overload. As office hysteroscopy will become more and more the standard for diagnostic as well as therapeutic procedures, this article describes the added value of fluid management in hysteroscopy.

Guidelines

In 2016 British and European Societies for Gynaecological Endoscopy (BSGE/ESGE) published a guideline on management of fluid distention media in operative hysteroscopy. (Umranikar et al., 2016) This guideline together with the guideline of the American Association of Gynecologic Laparoscopists (AAGL) (AAGL, 2013) can be considered as the backbone of guidelines on fluid management. There is no reason to believe that the advice in these guidelines regarding fluid management will be different around the globe. Therefore, in the absence of national guidelines, these guidelines could/should be taken into account in the development of local protocols on fluid management.

Review of literature

A repeated literature search was done on the combination of MeSH (Medical subject Headings) and relevant index terms as was used in the BSGE/

ESGE guideline on management of fluid distension media in operative surgery (Umranikar et al., 2016) in order to identify additional evidence on this guideline. The used MeSH or index terms were: "operative hysteroscopy", "TCRE", "hysteroscopy" AND "glycine", "resectoscope", "hysteroscopy" AND "fluid overload", "hysteroscopy" AND "management". The search was limited to humans and articles in the English language. The search was done from 2015 until 01-06-2023. The additional 18 papers included the BSGE/ESGE guideline and the practical guideline of the Society of Obstetricians and Gynaecologists of Canada (Laberge et al., 2015), besides book chapters, review articles and a case report (Lee et al., 2020). There was one retrospective comparative study comparing volumetric and biochemical assessment of intravasation which showed that there was significant differences and poor agreement between volumetric and biochemically assessed intravasation (Haude et al., 2020). A prospective single centre trial showed that spinal anaesthesia is associated with less glycine absorption, less thoracic fluid load, better control of haemodynamics and better patient satisfaction in operative hysteroscopy (Moharram et al., 2017).

History

Since the first described hysteroscopy in 1869 (Tarneja and Duggal, 2002) it took forty-five years before Heinenberg in 1914 introduced the first irrigation system to distend the uterine cavity (Manchanda et al., 2022). In the 1930s it became clear that an intrauterine pressure of a least 25-30 mmHg was needed for adequate visualisation and the intraperitoneal spill over the fallopian tubes occurred at a pressure > 55mmHg (Manchanda et al., 2022; Schroeder, 1934). Decades followed in which one gained more understanding in intrauterine pressure, ways to rinse the uterine cavity and maintain intrauterine vision. A manometer to measure intrauterine pressure was first described in the early 1960s (Manchanda et al., 2022; Gribb, 1960).

The infusion of high-viscosity media in the 1970s made it possible to have a better visualisation of the uterine cavity as these liquids did not mix with blood, and only slowly flowed over the fallopian tubes. Hysteroscopy was mainly performed for diagnostic reasons in those days.

In the late 1970s and early 1980s different techniques were described to remove or destroy intrauterine pathology, such as Nd:YAG laser and the first use of a resectoscope (Manchanda et al., 2022; Neuwirth, 1978). As for the use of monopolar radiofrequency electrical circuits, which was used in the first resectoscopes, an electrolyte free distension media was necessary. As sterile water led to haemolysis, hypotonic media such as glucose, sorbitol or glycine were used (AAGL, 2013). When absorbed in a certain volume, patients could suffer from nausea, vomiting, neurological symptoms including muscular twitching, grand-mal seizure and coma. As it was first described in urological use of a resectoscope this phenomenon was also known as TURP (Transurethral resection of the prostate) syndrome (Arieff, 1987).

It became apparent that there was a need to calculate fluid deficit, because manual calculation was either inaccurate as well as determined afterwards (AAGL, 2013). In the 1990s the first more or less closed loop systems were developed in which the inflow channel was connected to a pump for continuous intrauterine pressure and the outflow was connected to a collecting jar. However, the fluid deficit was not calculated automatically. At the end of the 1990s the Dolphin® fluid delivery system (Gyrus ACMI Inc. Maple Grove, MN, USA) was one of the first to have an alarm activated when a fluid deficit of 1000 mL was reached (Corson, 1997).

It is only since the last decade and a half that we have fluid delivery systems which are able to display real time fluid deficit (Manchanda et al., 2022).

Alongside the development of better fluid delivery systems, the operative instruments which were used in hysteroscopy also changed. Where procedures under general anaesthesia and after blind cervical dilatation with a monopolar resectoscope with an outer diameter of 26-27 Fr (8.7-9.0mm) were once first choice of treatment in case of intrauterine pathology. Bipolar resectoscopes were introduced reducing the complications of fluid overload as these could be used with isotonic normal saline. The development of smaller diameter hysteroscopes and instruments over the last two decades, together with a new (vaginoscopic) approach of the uterine cavity, made it possible to perform more complex procedures in a less complex (outpatient or office) setting (Bettocchi and Selvaggi, 1997; di Spiezio Sardo, 2020; Papalampros et al., 2009).

Types of distending media

In order to visualise the uterine cavity, one needs to distend the cavity. Different distending media have been used, which can be divided in three groups carbon dioxide, high-viscosity media and low-viscosity media. Due to the risks of complications as described below, currently only low-viscosity media are used. From these, isotonic media are the safest to use (Umranikar et al., 2016).

Carbon Dioxide

Carbon dioxide was first described in the 1920s (Manchanda et al., 2022). Because catastrophic cardiorespiratory collapse can occur if in therapeutic hysteroscopy large volumes of CO2 reaches the systemic circulation, CO2 should only be used in diagnostic hysteroscopy only with a low-pressure hysteroscopic insufflator (AAGL, 2013; Umranikar et al., 2016). As carbon dioxide is only used for diagnostic reasons, its use and management of complications is outside the scope of this article.

High-Viscosity Distending Media

Although high-viscosity distending media, such as dextran 70 (32% dextran 70 in 10% dextrose) have the advantage of preserving a better view as they are insoluble with blood, the high risk of adverse outcome even with small fluid deficits, makes these media nearly unsuitable for operative hysteroscopic procedures and should therefore be avoided, as there are safer media available (AAGL, 2013).

Low-Viscosity Distending Media

In the past commingle of blood with low-viscosity distending media was a challenge to overcome. The introduction of hysteroscopes with an outflow channel made it possible to rinse the uterine cavity and made a safer low-viscosity distending media could be used instead of high-viscosity distending media (Manchanda et al., 2022).

There are different low-viscosity distending media which vary in osmolarity (iso- or hypotonic) and presence or absence of electrolytes. In order to use a monopolar radiofrequency (RF) electosurgery device an electrolyte free solution is needed. Except from Mannitol all electrolyte free solutions are hypotonic (AAGL, 2013).

The development of bipolar electrical instruments and later tissue removal systems made it possible to perform operative procedures with isotonic electrolyte-containing media such as normal saline and Ringer's lactate (AAGL, 2013).

The absorption of large amounts of distending media may lead to fluid overload, which depending on the media used (hypo- or isotonic) will sooner or later lead to major complications.

Fluid overload

Fluid overload has been defined by the BSGE/ESGE as a fluid deficit more than 1000 mL in healthy women when using a hypotonic solution and more than 2500 mL in healthy women using normal saline, an isotonic solution (Umranikar et al., 2016). However in elderly women and those who have cardiovascular or renal diseases a threshold of 750 mL (for hypotonic) and 1000 mL for isotonic solutions is recommended (Table 1) (AAGL, 2013; Umranikar et al., 2016).

Absorption of distending media is inevitable, nevertheless understanding the mechanisms which lead to fluid absorption is a minimal requirement for all of us who perform hysteroscopic surgery.

First of all, there is retrograde passage of fluid over the fallopian tubes. The risk of leakage over the fallopian tubes increases when the intrauterine pressure exceeds 70-75mmHg (Umranikar et al., 2016; Hasham et al., 1992), but it may already occur when intrauterine pressure exceeds 55 mmHg (Manchanda et al., 2022).

The second mechanism is absorption through the endometrium itself. If the mean arterial pressure (MAP) is exceeded by the intrauterine pressure, absorption of fluid into the systemic circulation will occur. To prevent this, one can quickly estimate the maximum intrauterine pressure by calculating the MAP = diastolic pressure + 1/3 (difference between systolic and diastolic pressure) (DeMers and Wachs, 2023). Another risk of absorption through the endometrium is in case of a large uterine cavity, as one needs more fluid to distend and in general a higher pressure to achieve adequate visualisation (Umranikar et al., 2016).

Finally, absorption takes place through open vessels during surgery. Where in general a polypectomy has one vascular pedicle with a small number of open vessels, a myomectomy or a thermal resection of the endometrium will lead to multiple open vessels (Umranikar et al., 2016).

Table I. — BSGE/ESGE Guideline recommendations on maximum fluid overload.

	Maximum fluid overload	
Patient	Hypotonic media	Isotonic media
Healthy of reproductive age	1000 mL	2500 mL
Elderly women	750 mL	1500 mL
With cardiovascular diseases		
With renal disease		
With multiple co-morbidity		
Adapted from the BSGE/ESGE guideline (Umranikar et al., 2016).		

The use of a hypotonic electrolyte free solution, such as Glycine 1.5% (200 mOsm/L) of sorbitol 3% (165 mOsm/L), which are needed for monopolar electrosurgery, have the disadvantage of creating electrolyte disturbances. Headache, nausea, vomiting and muscle weakness occur when the sodium levels drop below 125 mmol/l. If not recognised further fluid loss will lead to brain oedema and increased intracranial pressure, brain stem herniation, coma and even death (Istre et al., 1994; Baggish et al., 1993). In contrast to men and postmenopausal women, premenopausal women have a 25 times higher risk to develop permanent brain damage because female sex hormones inhibit Na+/K+-ATPase pump which helps the brain to compensate in case of an osmotic imbalance (Ayus et al., 1997).

With the introduction of bipolar electrosurgery an electrolyte containing isotonic solution as normal saline the risks of complications due to fluid overload decreases, however if absorbed in large amounts electrolyte disturbances such as hyperchloremic acidosis (Schäfer et al., 2005) as well as pulmonary oedema (Grove et al., 2004) can still occur.

Therefore, careful monitoring of the fluid loss has been advocated ever since the first guidelines in hysteroscopy were published (AAGL, 2013; Umranikar et al., 2016; Loffer et al., 2000) Nevertheless, if not carefully monitored, major complications could result from fluid overload (Lee et al., 2020). Not only should we monitor fluid loss carefully, but an automated real time calculation is needed. This is because, as Boyd and Stanley had shown, many non-automated factors can and will contribute to an incorrect fluid loss (Boyd and Stanley, 2000). For example, 3-litre fluid bags were on average 2.8% overfilled, estimated fluid in remaining bags was miscalculated by 4-50%, collection of fluid by 10-39% and remaining fluid on the operating floor was over- or underestimated by 56-67%. This makes manual calculating fluid loss nearly impossible (Boyd and Stanley, 2000).

Incidence of fluid overload

The incidence of fluid overload is related to the type of surgery performed. In a prospective multicentre study by Jansen et al, 11,085 diagnostic and 2,515 operative procedures were reviewed. Fluid overload which was defined as a loss of > 1500 mL was only seen in operative procedures in 5 cases (0.2%) and never in diagnostic procedures. Four of these five cases were during myomectomy (Jansen et al., 2000). Another multicentre survey in 21,676 operative hysteroscopies fluid overload syndrome was recorded in 13 patients (0.06%). Ten patients had a myomectomy and three an endometrial ablation (Aydeniz et al., 2002).

Based on these studies in operative hysteroscopy the incidence of fluid overload is approximately 0.1-0.2% in which myomectomy and endometrial ablation have the highest risks and this incidence is very low in polypectomy (Aydeniz et al., 2002; Jansen et al., 2000). It is so far unknown if tissue removal with a tissue removal system will increase or decrease these risks, but the use of these instruments seems relatively safe (Noventa et al., 2015). Furthermore, increased use of normal saline has probably reduced the incidence of fluid overload. Besides that, the risk of fluid overload in diagnostic procedures is nearly non existing. Nevertheless, if unrecognised fluid overload can lead to severe outcomes (Arieff, 1987; Baggish et al., 1993; Ayus et al., 1997; Schäfer et al., 2005; Grove et al., 2004; Lee et al., 2020).

Prevention of fluid overload

As prevention is better than cure, the preoperative administration of GnRH agonists in premenopausal women before hysteroscopic resection of myoma, Intracervical injection with dilute Vasopressin and maintaining the intrauterine pressure as low as possible are recommended approaches to reduce risk of fluid overload (Umranikar et al., 2016). In many cases an intrauterine pressure of 60-70 mmHg will be sufficient.

Fluid management system

All current fluid management systems are closed systems. This means that they have an automated pump to control intrauterine pressure and a collection system which measures the returned amount of fluid (Manchanda et al., 2022). The displayed fluid deficit is calculated by the difference between inflow and collected outflow. Even in closed systems there is possibility of overestimating fluid loss, because there can be fluid loss in blankets or on the floor, which falsely increase the calculated loss. This may result in premature abortion and incomplete resection during surgery (Marshburn et al., 2021). Conversely, if the procedure is continued after an alarm the loss might be underestimated by the team (Boyd and Stanley, 2000).

A fluid-collection drape with a reservoir can be applied underneath the bottom of the patient, preventing leakage in blankets or alongside regular drapes on the floor (Marshburn et al., 2021). In

office setting a fluid-collection drape can easily be positioned in the proper way as the patient is awake and can lift her bottom herself.

The first automated closed systems which displayed fluid deficit and equipped with an alarm system was the Hysteroflow II® (Olympus Winter & Ibe GmbH, Hamburg, Germany), (Olympus - Hysteroflow II n.d.) introduced in 2013, followed by Aquilex® (WOM, Berlin, Germany) in 2014 which calculated fluid deficit volume. (Hologic - Aquilex n.d.) The first fluid management system with a user friendly touchscreen and which calculated fluid deficit based on a weight difference was Hysterolux® (Medtronic INC, Minneapolis, MN, USA) introduced in 2018. (Medtronics - Hysterolux n.d.) Another worldwide used "smart" pump is the Hysteromat E.A.S.I® (Karl Storz Endoscopy GmbH, Tuttlingen, Germany). (Karl Storz - Hysteromat n.d.) The latest development in fluid management system is Fluent® (Hologic Inc., Marlborough, MA, USA.) which was introduced in 2020. (Hologic - Fluent n.d.) Compared to its predecessor (Hologic - Aquilex n.d.) the Fluent® is easier to set-up and is therefore very suitable in office setting use. Furthermore, Fluent® has a peristaltic in- and outflow, this reduces the amount of fluid which is used during the procedure and leads to more stable and better vision even at low intrauterine pressures (Figure 1).



Figure 1

If there is no possibility to use a modern automated pump in therapeutic procedures, fluid deficit should be measured at a minimum of a 10 minutes interval (Umranikar et al., 2016). As the use of a fluid management system is costly and also produces waste, a fluid management system it is not always needed in every procedure. As in diagnostic settings fluid overload is very low, (Jansen et al., 2000) a diagnostic hysteroscopy can be performed with normal saline in a pressure bag. The same applies for the removal of small polyps with forceps and scissors or with a manual tissue removal system (e.g. MyoSure Manual®, Hologic Inc., Marlborough, MA, USA). If a 1L normal saline bag, which in the majority of cases is sufficient in diagnostic and small operative procedures, is used in all procedure without the use of a fluid management system, a fluid overload of > 1500mL is impossible. By doing so a hysteroscopy without the use of a fluid management system is safe in all patients including those with renal impairment or cardiovascular diseases (Umranikar et al., 2016).

Conclusion

In the last two decades there has been a major improvement in hysteroscopic surgery. The use of bipolar electrical current made it possible to use normal saline and reducing the risks of electrolyse disturbances caused by hypotonic solutions which were used before. Reducing the diameter of hysteroscopes, vaginoscopic approach and the introduction of small diameter instruments lead to a shift from the operating room (OR) to an outpatient or office setting for not only diagnostic but also operative hysteroscopy. Moving from the OR towards an outpatient or office setting reduces costs, shorten hospital stay. It is efficient, well accepted by patients and often preferred over a hysteroscopy in the OR (Ma et al., 2017). Although the complication rates are considered as negligible by some (Ma et al., 2017) there is still a risk of fluid overload. Although the risks of complications due to fluid overload maybe smaller than reported before, the consequences if it happened can be devastating.

In aviation we expect that aircraft personnel will take all safety measurements prescribed in order to prevent accidents to happen. In 2022 the risk of an individual person to die on a flight was 0.11/million flights. (IATA n.d.) Bearing these figures in mind, may our patients expect from us to measure fluid loss, as we expect from the aircraft personnel on safety issues in aviation? There is no excuse not to use a fluid management system or measure fluid loss manually every 10 minutes in operative hysteroscopic surgery, if we cannot end

the procedure within the use of 1L of normal saline as guidelines advise (AAGL, 2013; Umranikar et al., 2016)

Acknowledgements: I would like to thank Rachel Williams and Willianne Blé for their support and comments on the manuscript.

Conflict of interest: D.P. van der Ham is a consultant for Hologic, Inc.

References

AAGL. Practice Report: Practice Guideline for the Management of Hysteroscopic Distenting Media. J Minim Invasive Gynecol. 2013;13:137-48.

Arieff AI. Hyponatremia associated with permanent brain damage. Adv Intern Med. 1987;32:325-44.

Aydeniz B, Gruber IV, Schauf B et al. A multicenter survey of complications associated with 21 676 operative hysteroscopies. Eur J Obstet Gynecol Reprod Biol. 2002:104:160-4.

Ayus JC, Wheeler JM, Arieff AI. Postoperative hyponatremic encephalopathy in menstruant women. Ann Intern Med. 1997;157:223-6.

Baggish M, Brill A, Rosenweig B et al. Fatal Acute Glycine and Sorbitol Toxicity During Operative Hysteroscopy. J Gynecol Surg. 1993;9:137-43.

Bettocchi S, Selvaggi L. A vaginoscopic approach to reduce the pain of office hysteroscopy. J Am Assoc Gynecol Laparosc. 1997;4:255-8.

Boyd HR, Stanley C. Sources of error when tracking irrigation fluids during hysteroscopic procedures. J Am Assoc Gynecol Laparosc. 2000;7:472-6.

Corson SL. Hysteroscopic fluid management. J Am Assoc gynecol Laparosc. 1997;4:375-9.

DeMers D, Wachs D. Physiology, Mean Arterial Pressure. In StatPearls. Treasure Island (FL): StatPearls Publishing. 2023.

di Spiezio Sardo A. The legend of modern hysteroscopic surgery. Facts Views Vis Obgyn. 2020;12:71-3.

Gribb JJ. Hysteroscopy: an aid in gynecologic diagnosis. Obstet Gynecol. 1960;15:593-601.

Grove JJ, Shinaman RC, Drover DR. Noncardiogenic Pulmonary Edema and Venous Air Embolus as Complications of Operative Hysteroscopy. J Clin Anesth. 2004;16:48-50.

Hasham F, Garry R, Kokri MS et al. Fluid absorption during laser ablation of the endometrium in treatment of menorrhagia. Br J Anaesth. 1992;68:151-4.

Haude O, Overdijk LE, van Kesteren PJM et al. Comparing volumetric and biochemical assessment of intravasation caused by hysteroscopic surgery. Acta Anaesthesiol Scand. 2020;64:232-7.

Hologic - Aquilex. (website) Accessed 7 13, 2023. https://www.hologic.com/hologic-products/gynecologic-health/aquilex-fluid-management-system.

Hologic - Fluent. (website) Accessed 7 13, 2023. https://www.hologic.com/hologic-products/gynecologic-health/fluent-fluid-management-system.

Hologic - MyoSure. (website) Accessed 7 13, 2023. https://www.hologic.com/hologic-products/gynecologic-health/myosure-tissue-removal-suite.

IATA. (website) Accessed 7 13, 2023. https://www.iata.org/en/pressroom/2023-releases/2023-03-07-01/.

Istre O, Bjoenne J , Naess R et al. Postoperative cerebral oedema after transcervical endometrial resection and uterine irrigation with 1.5% glycine. Lancet. 1994;344:1187-9.

Jansen FW, Vredevoogd CB, van Ulzen K et al. Complications of hysteroscopy: A prospective multicentre study. Obstet Gynecol. 2000;96:266-70.

Karl Storz – Hysteromat. (website). Accessed 7 23, 2023. https://www.karlstorz.com/in/en/gynecology.htm.

Laberge P, Leyland N, Murji A et al. Endometrial ablation in the management of abnormal uterine bleeding. J Obstet Gynaecol Can. 2015;37:362-79.

Lee J, Park EB, Kim YI et al. Complications of fluid overload during hysteroscopic surgery: cardiomyopathy and epistaxis. Anesth Pain Med. 2020;15:61-5.

Loffer FD, Bradley LD, Brill AI et al. Hysteroscopic Fluid Monitioring Guidelines. The ad hoc committee on hysteroscopic fluid guidelines of the American associationf of gynecologic laparoscopists. J Am Assoc Gynecol Laparosc. 2000;7:167-8.

Ma T, Readman E, Hicks L et al. Is outpatient hysteroscopy the new gold standard? Result from an 11 year prospective observational study. Aust NZ J Obs Gynaecol. 2017;57:74-80.

Manchanda R, Valenti G, Rathore A et al. Distension media delivery systems in hysteroscopy: past present and future. Minim Invasive Ther Allied Technol. 2022;31:1-12.

Marshburn PB, Anderson-Montoy BL, Baek S et al. A fluid-management drape for hysteroscopy. Innovation for improved patient safety and surgical care. Obstet Gynecol. 2021;138:905-10.

Medtronics - Hysterolux. (website) Accessed 7 13, 2023. https://www.medtronic.com/covidien/en-gb/products/hysteroscopy-systems/hysterolux-fluid-management-system.html#.

Moharram , EE, AM el Attar, MA Kamel. The impact of anesthesia on hemodynamic and volume changes in operative hysteroscopy: a bioimpedance randomized study. J of Clinical Anesth. 2017;38:59-67.

Neuwirth RS. A new technique for and additional experience with hysteroscopic resection of submucous fibroids. Am J Obstet Gynecol. 1978;131:91-4.

Noventa M, Ancona E, Quaranta M et al. Intrauterine morcellator devices: The icon of hysteroscopic future or merely a marketing image? A systematic review regarding safety, efficacy, advantages, and contraindications. Reprod Sci. 2015;22:1289-96.

Olympus - Hysteroflow II. (website) Accessed 7 13, 2023. https://www.olympus-europa.com/medical/en/Products-and-Solutions/Products/Product/HysteroFlow-HysteroBalance-II.html.

Papalampros P, Gambaduaro P, Papadopoulos N et al. The mini-resectoscope: A new intrument for office hysteroscopic surgery. Acta Obstet Gynecol. 2009;88:227-30.

Schäfer M, Britta S, von Ungem-Sternberg MD et al. Isotonic Fluid Absorption during Hysteroscopy Resulting in Severe Hyperchloremic Acidosis. Anesthesiology. 2005;103:203-4.

Schroeder C. Über den Ausbau und die Leistungen der Hysteroskopie. Arch Gynak. 1934;156:407-19.

Tarneja P, Duggal BS. Hysteroscopy: Past, Present and Future. Med J Armed Forces India. 2002;58:293-4.

Umranikar S, Clark TJ, Saridogan E et al. BSGE/ESGE guideline on management of fluid distension media in operative hysteroscopy. Gynecol Surg. 2016;13:289-303.

doi.org/10.52054/FVVO.15.M.096