

The Posterior Intravaginal Slingplasty treatment for apical prolapse: 3 years experience in a single centre setting

Piet HINOUL¹, Ruben VANSPAUWEN², Stéfan SMAJDA³, Jan-Paul ROOVERS⁴

¹Ziekenhuis Oost Limburg, Schiepsse Bos 6, 3600 Genk, Belgium, piet.hinoul@skynet.be

²A.Z. Turnhout, Steenweg op Merksplas 44, 2300 Turnhout, Ruben.Vanspauwen@azstjozef-turnhout.be

³Clinique Ste Anne-St Rémi, Bd Graindor 66, 1070 Brussels, Belgium, dr.smajda@skynet.be

⁴Academic Medical Center, Meibergdreef 9, 1105 AZ Amsterdam, The Netherlands, j.p.roovers@amc.uva.nl

Correspondence at: piet.hinoul@skynet.be

Abstract

Aim: To assess the anatomic effectiveness and complications of the Posterior IVS technique for the treatment of pelvic organ prolapse over a period of 3 years.

Methods: A retrospective, single-arm, non-comparative study involving routine, standardised, pre-operative assessment, surgery and follow-up care using the Pelvic Organ Prolapse Quantifications score at 1, 2 and 3 years was performed. The Posterior IVS technique was performed in patients with a symptomatic grade 2 or greater prolapse of the apical compartment (i.e. point C and/or D \geq -1). Concomitant prolapse procedures were allowed.

Results: Twenty-nine consecutive patients underwent a Posterior IVS suspension over a period of 2 years. Ninety percent (26/29) of patients required a concomitant prolapse procedure (79% an anterior and 55% a posterior vaginal wall repair).

No serious perioperative complications, bladder injuries or rectal perforations were encountered. Overall anatomical success rates (<Stage 2, International Continence Society criteria) declined from 86% to 58% and 50% after 1, 2 and 3 years, respectively. In 14% (4/29) of patients the site of anatomic recurrence was located in the apical compartment, in 31% (9/29) at the level of the anterior compartment and 14% (4/29) at the level of the posterior vaginal wall. Erosion of the Posterior IVS tape was encountered in 14% (4/29) of patients; 2 of which presented as gluteo-vaginal fistula's.

Conclusion: Three years follow-up of the Posterior IVS yields a high anatomical failure and substantial surgical reintervention rate.

Key words: Pelvic organ prolapse, apical prolapse, surgery, mesh, Posterior IVS, infracoccygeal sacropexy.

Introduction

Providing adequate support for the vaginal apex is essential to provide a durable surgical repair for women with pelvic organ prolapse (POP) (Brubaker *et al.*, 2005; Hsu *et al.*, 2008; Rooney *et al.*, 2006; Summers *et al.*, 2006; Lowder *et al.*, 2008). The “gold standard” to restore the anatomy of the vaginal apex is still considered to be the sacral colpopexy (Maher *et al.*, 2007). Sacral colpopexy has been shown in randomized controlled trials to offer lower recurrence rates and less dyspareunia than sacrospinous fixation, but at the expense of a longer operating and recovery time. Whether the surgeon

selects a vaginal or abdominal approach does depend on several factors: general medical condition of the patient, vaginal caliber, sexual activity, dominant site of the prolapse and the surgeon's experience with either technique.

In 1997, P. Petros conceived the “infracoccygeal colpopexy”, commercially known as the “Posterior IVS” (IVS Tunneler, Tyco Healthcare Group, Norwalk, Conn, USA), combining a vaginal approach and a mesh prosthesis using a needle suspension technique (Petros, 2001). The posterior intravaginal slingplasty (IVS) aimed to be a minimally invasive, standardized operation to treat vaginal vault prolapse; hoping to combine the advantages of the

reduced invasiveness of the vaginal route with the durability of a permanent synthetic graft as used in sacral colpopexies. Intuitively it makes sense to replace or reinforce damaged endogeneous vaginal supportive tissues, however, when consulting the available literature there exists a paucity of information on the long-term efficacy of this innovative procedure. Until now, only one PubMed publication reports on patients with a follow-up exceeding one year after the Posterior IVS procedure (Deffieux *et al.*, 2009). Multiple articles have reported upon the associated morbidity that could possibly explain the disuse of the "Posterior IVS" as a procedure to treat apical prolapse (Hefni *et al.*, 2007; Baessler *et al.*, 2005; Luck *et al.*; Luck *et al.*, 2008). However, as far as we are aware, there is only one manuscript (Mattox *et al.*, 2006) that critically reviewed both anatomical and subjective cure rates.

The primary aim of this study was to report 3 year objective and subjective results of IVS posterior in patients treated for stage 2 or more (POP-Q classification (Bump *et al.*, 1996)) middle compartment prolapse. This study also reports on the procedure's morbidity.

Materials and Methods

Study Design

The objective of the study was to assess the anatomic effectiveness and complications of the Posterior IVS technique for the treatment of pelvic organ prolapse. It was a retrospective, single-arm, non-comparative design involving standardised pre-operative assessment, surgery and follow-up visits at 1, 2 and 3 years after the intervention.

The Posterior IVS technique was performed when patients presented with a symptomatic stage 2 or greater prolapse of the middle compartment (i.e. point C and/or D \geq -1). A concomitant hysterectomy and/or prolapse correction were not considered to be an exclusion criterion as apical prolapse is often associated with prolapse in different compartments. The Posterior IVS Tunneler used in this series refers to the first generation of the device available on the market and consisted of 0.8 cm wide tape made of a woven, multifilament, microporous polypropylene mesh (IVS Tunneler, Tyco Healthcare Group, Norwalk, Conn, USA).

Intervention

The procedures were performed according to a standardized protocol. After vaginal cleansing with a watery Isobetadine solution and intravenous administration of 2 grams Cefazoline, a lubricated

gauze was placed inside the rectum to allow peroperative palpation of the rectum during placement of the IVS tunneler. The needle insertion technique was performed as originally described (Petros). The dissection was initiated with a full thickness, longitudinal incision at the posterior vaginal wall 1-2 cm inferior to the cervix or to the vault after aqua-dissection of the ischio-rectal space with approximately 20-40 mL of a 0.9% NaCl solution. On both sides of this incision a blunt pararectal dissection was performed, similar to the dissection performed during a sacrospinous ligament fixation, until the pelvic side of the levator plate was reached. The IVS suspension needle was inserted bilaterally through a small skin incision 3 cm lateral and 3 cm below the anus. The needle perforated the skin, the subcutaneous adipose tissue and entered the ischio-rectal fossa. To avoid inadvertent, excessive forward travel of the needle, the shaft of the IVS tunneler was gripped at the level of the curvature (approximately 5 cm from the tip). The needle was then pushed forward parallel to the rectum in the direction of the ischial spine and was guided by a finger placed in the vagina. At the most cranial part of the ischio-rectal fossa, the ischiococcygeal muscle was perforated medially to the ischial spine. Once the levator plate was perforated, the IVS tunneler was directed medially. The tape was anchored to the apex of the vaginal vault or to the posterior side of the supravaginal portion of the cervix using a non-resorbable, multifilament 2-0 Ethibond suture. Finally, the tape was gently pulled upon until adequate elevation of the vault or uterus was achieved. Skin incisions were closed using a resorbable suture, the perineal ends of the tape remained unfixed. A rectal examination was systematically carried out to exclude rectal perforation but equally important to possibly loosen the the sling when excessive tensioning around the rectum could be palpated. A vaginal packing lubricated with Isobetadine cream was left in situ for 18 to 24 hours and a 14 gauge Folley catheter for 24 hours postoperatively, and for 48 hours in patients who had also undergone an anterior vaginal wall repair. Low molecular weight heparin thromboprophylaxis was administered to all patients for a period of 10 days.

Primary Outcome Measure

Prolapse assessment was performed according to the POP-Q scoring system (Bump). The primary effectiveness endpoint was prolapse recurrence, defined as a POP-Q stage 2 or more (i.e. leading edge of the prolapse \geq -1 cm) or surgical intervention to repair recurrence of vaginal prolapse in any compartment.

Secondary Outcome Measures

Additional analyses were performed that assumed women lost to follow-up were either treatment failures or successes. An alternate definition of success was defined as women with the leading edge above the hymen (i.e. < 0 cm). Pre-operatively, patients' demographic details, medical and surgical history were recorded. Other outcome parameters that were prospectively recorded were: peroperative complications, the impact of the prolapse on urinary and defecatory symptoms, the erosion rate and any vaginal pain reported by the patient. The surgeon's assessment of the impact of the prolapse on urinary and defecatory symptoms was mainly based on questions from the King's College - Prolapse quality of life questionnaire (P-QOL), which had not been validated and published at the time of the study (Digesu *et al.*, 2005). The questions related to: presence of vaginal bulge, heaviness or dragging feeling from the vagina, urinary frequency, urinary urgency, urge urinary incontinence, stress urinary incontinence, poor urinary stream, straining to empty the bladder, constipation, straining to open the bowels, vaginal discharge and vaginal discomfort.

Analysis

Variables were described as mean (standard deviation) or as frequency (percentage). The study's endpoint was the recurrence of 2nd degree prolapse (in any compartment) at the end of the follow up period. The outcome was carried forward from the first visit when a recurrence was observed, or recorded at the last scheduled follow up visit at 1, 2 or 3 years. Statistical analyses were performed using the Wilcoxon matched paired test. This was done for the available paired data at each timepoint. The level of significance was set at 5%. Statistical analysis was performed using Statistica Software.

Results

Twenty-nine patients underwent a Posterior IVS suspension between May 2002 and June 2004 at a teaching hospital in Genk, Belgium. All procedures were performed by the same surgeon (PH). No other prolapse repairs involving mesh material were included in this study. All patients from the first IVS procedure onwards were included in the series.

Baseline characteristics and surgical parameters are summarised in table 1. The average age of the treated patients was 66 years old (range 52-85 y). Median follow up was 36 months (range 15-60 m). Patients were not contacted when they did not attend their yearly follow up visit; however, hospital notes

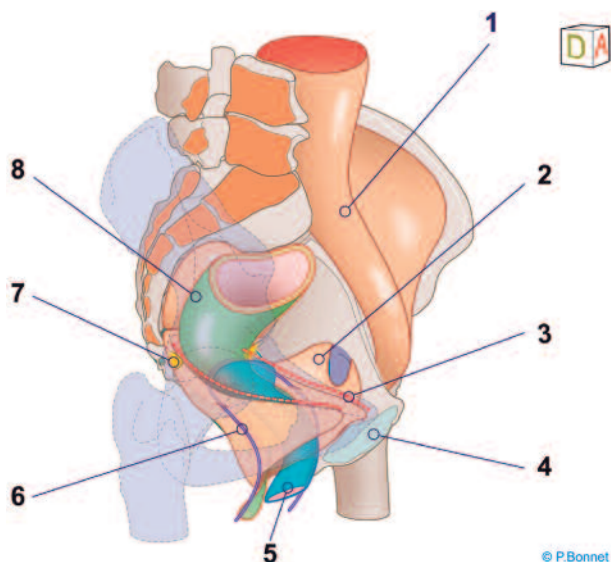
Table 1. — Baseline demographics and surgical parameters.

	N = 29
Mean age in years (SD)	66 (8)
Median parity (range)	3 (1-7)
Mean BMI kg/m ² (SD)	26 (4)
Previous prolapse repair	6 (21%)
Prior hysterectomy	6 (21%)
Concomitant vaginal hysterectomy	16 (55%)
Concomitant anterior colporrhaphy	23 (79%)
Concomitant posterior colporrhaphy	16 (55%)
Concomitant continence surgery (TOT)	2 (7%)
Postmenopausal patients	29 (100%)
Hormonal treatment (postmenopausal)	21 (23%)

Data are expressed as n (%) except where otherwise indicated; Standard Deviation (SD); Body Mass Index (BMI).

for any surgical, gynaecological or urological consultations or interventions were searched. The average operating time for the Posterior IVS procedure excluding any concomitant surgery was 25 minutes (range 20-60 min). Ninety percent of patients were indicated to have a concomitant prolapse procedure (26/29). The majority (79%) of them underwent an anterior and 55% a posterior vaginal wall repair. A diagram depicts the anatomical aspiration of a successful posterior intra vaginal sling procedure (Fig. 1).

No serious peroperative complications, bladder injuries or rectal perforations were encountered in relation to the Posterior IVS procedure. No blood transfusions were indicated. Five patients required antibiotic treatment for either cystitis or a wound infection. Two patients without recurrent prolapse developed recurrent urinary tract infections. Erosion of the Posterior IVS tape was encountered in 14% (4/29) of patients. In one patient it concerned a classical mesh exposure of the multifilamentary polypropylene tape at the vaginal apex that was removed during a treatment of recurrence of the prolapse after 14 months. One erosion presented as a mere granuloma immediately post operatively and was treated by topical oestrogen administration. Two other erosions presented themselves as gluteo-vaginal fistulas after 6 and 13 months (Fig. 2a-b). The fistulas required complete extraction of the tape which led to complete resolution of this complication. One patient reported transient paraesthesia in the buttock region for approximately 6 months. One patient continued to complain of tenesmus; rectal examination could not reveal any excessive tensioning of the mesh. The patient was minimally bothered by these symptoms and no further investigations or treatment options were deemed necessary.



Legend to figure 1:

1. Psoas muscle
2. Obturator internus muscle
3. Arcus tendineus levator ani
4. Symphysis
5. Vagina
6. Posterior Intra Vaginal Sling
7. Ischial spine
8. Rectum

Fig. 1. — Anatomical diagram depicting the Posterior Intra Vaginal Sling procedure.

The overall ICS POP-Q stages observed pre-operatively and at each post operative follow up visit are reported in Table 2. Alternative failure rates were calculated based on different approaches to handling missing data; these rates are also presented in Table 2. Table 3 summarizes the mean POP-Q scores for the anterior, posterior and apical compartment. Over a mean of 36 months a progressive recurrence of prolapse (stage 2, ICS) was observed in 50% of those patients who returned for follow up.

In 14% (4/29) of patients the site of anatomic recurrence was located in the apical compartment, in 31% (9/29) at the level of the anterior compartment and 14% (4/29) at the posterior vaginal wall (carrying the last observation or the observation before reintervention forward for the full analysis set of 29 patients). One recurrence in the apical compartment presented after 1 year, 3 others were recorded after 2 years. Similarly 3 anterior recurrences presented after 1 year and 6 after 2 years. Two recurrences in the posterior compartment were noted both after one and two years of follow up. Eight patients (28%) actually experienced recurrence of prolapse symptoms. Five of them underwent surgical reinterventions for symptomatic recurrence of pelvic organ prolapse: one sacrospinous ligament fixation,

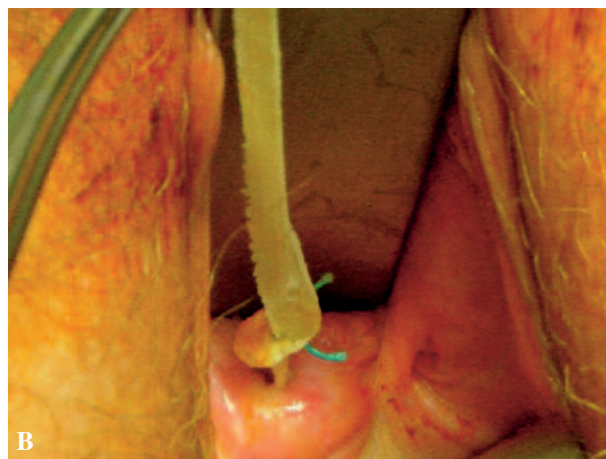
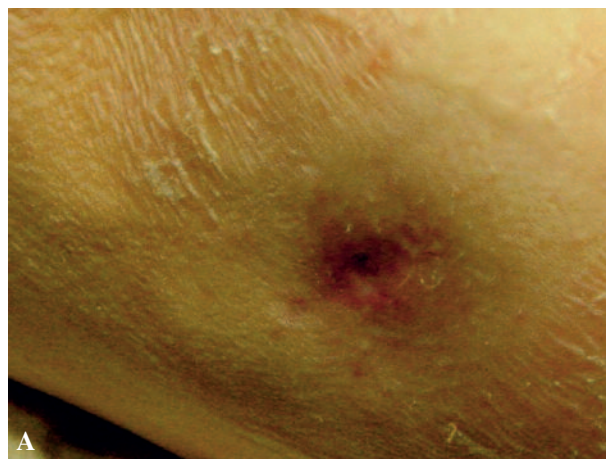

Fig. 2a&b. — Patient presenting with a gluteo-vaginal fistula

1 sacrocolpopexy that subsequently failed too, 2 anterior mesh kits and 1 posterior colporrhaphy. In two patients a pessary was placed and one patient declined further treatment. Of note is that the 8 patients with recurrence of symptoms represented all patients who had a prolapse beyond the level of the hymen (i.e. leading edge ≥ 0).

Overactive bladder symptoms (urgency, frequency, nocturia) improved in all 13 out of 29 (45%) patients who reported these symptoms before surgery. De novo overactive bladder symptoms were reported by 14% (4/28) of the patients who answered the standard check-list after one year. One patient complained of worsened pre-existent dyspareunia.

A literature review was conducted using PUBMED and all conference proceedings of the International Urogynecology Society (IUGA) from 2001 to 2009. Tables 4 and 5 summarise all identified studies listing the number of patients in the study, the follow up period, the success- and the erosion rate.

Table 2. — Overall ICS POP-Q Stages and Failure Rates.

	Baseline N = 29*	1 year N = 28/29	2 years N = 26/29	3 years N = 18/29
Stage 0	–	14 (50%)	9 (35%)	2 (11%)
Stage I	–	10(36%)	6 (23%)	7 (39%)
Stage II	14 (48%)	3 (11%)	10 (39%)	7 (39%)
Stage III	11 (38%)	1 (4%)	1 (4%)	2 (11%)
Stage IV	4 (14%)	–	–	–
Re-intervention ^a	–	1	4	7
Rate of anatomic failure (90% CI), assuming:		1 year	2 years	3 years
Patients returning for examinations ^b		4/ 28 14%	11/26 42%	9/18 50%
Missing data as failures		5/29 17%	14/29 48%	20/29 69%
LOCF for missing data		4/29 14%	11/29 38%	11/29 38%

Data are expressed as n (%).

^aReintervention rate for prolapse recurrence only (includes pessary placement), cumulative rate.

^bFor patients who had undergone a reintervention, the last observation prior to surgery was carried forward.

LOCF: Last Observation Carried Forward.

Discussion

This retrospective single-centre study reports the three-year follow-up results of a vaginal apical prolapse repair that uses a tension-free, synthetic tape fixed to the level of the cervix or vaginal vault in combination with traditional vaginal repairs. Our results confirm a satisfactory intra-operative safety profile. Short term satisfactory anatomical cure results appeared to decline to unacceptably low anatomical cure rates at 3 years follow-up. These results are lower than reported on the Posterior IVS in the peer reviewed literature.

There are several limitations of our studies that need to be addressed. The major shortcoming is that it only constitutes a small study population (with a high dropout rate at the 3 year endpoint) in a single

centre setting without a comparative group. The high concomitant surgery rate also makes it difficult to draw any sound conclusions regarding the effects of the Posterior IVS alone. Finally, we regret the lack of prospectively using validated symptom and quality of life questionnaires. However, it wasn't until 2004 that the International Consultation on Incontinence stressed the importance of the systematic use of such instruments when assessing POP repairs (Brubaker *et al.*, 2005). Our study derives its strength from the three year follow-up it provides. We are convinced that only longer term follow can guide surgeons appropriately whether they should or should not embrace new surgical technologies and help them in the counseling of their patients. The use of the validated POP-Q scores to assess anatomical outcome also adds to the study's value (Bump *et al.*, 1996).

Table 3. — Comparison of mean pre-operative and post-operative POP-Q scores.

POP-Q point	Baseline	1 year		2 years		3 years	
		Mean (SD)	Δ	Mean (SD)	Δ	Mean (SD)	Δ
Ba	1.6	-2.3 (1.1)	3.9 ^s	-1.5 (1.5)	3.1 ^s	-0.6 (1.9)	2.2 ^{NS}
Bp	-0.8	-2.7 (1.0)	1.9 ^s	-2.5 (1.2)	1.7 ^s	-2.0 (1.3)	1.2 ^s
C	0.2	-6.1 (2.9)	6.3 ^s	-5.2 (3.7)	5.4 ^s	-5.2 (4.1)	5.4 ^s

Ba = Most distal point anterior vaginal wall, C = Most distal point of cervix or vaginal cuff, Bp = Most distal point posterior vaginal wall. All points are measured in cm during maximal Valsalva.

Δ: Mean change from baseline

^s: Statistically significant difference compared to baseline

^{NS}: Not statistically significant difference compared to baseline.

Table 4. — PubMed published data regarding Posterior IVS.

Author	n	Follow up (m)	Success (%)	Erosion (%)
Petros, 2001	75	55	94	5.3
Farnsworth, 2002	93	12	91	5.4
Jordaan <i>et al.</i> , 2006	42	13	75	0
Luck <i>et al.</i> , 2007	90	7	88	17.8
Hefni <i>et al.</i> , 2007	127	14	88	17
Von Theobald <i>et al.</i> , 2007	108	19	99	2.8
Biertho <i>et al.</i> , 2004	34	NR (<12)	91.2	2.2
Sivaslioglu <i>et al.</i> , 2005	30	16	96.7	0
Kolusari <i>et al.</i> , 2010	33	12	97.1	0
Deffieux <i>et al.</i> , 2009	53	32	84	9
Mattox <i>et al.</i> , 2006	19	4	74	NR
Neuman <i>et al.</i> , 2008	140	19	97.9	8.6

The failure rate – specifically for the apical compartment – was 14% (4/29). With an overall anatomic success rate of 58% at 2 years and 50% at 3 years, however, it does not seem that the posterior IVS’s apical support has improved the outcome of traditional repairs in the anterior and/or posterior compartment when compared to published data (Whiteside *et al.*, 2004; Webber *et al.*, 2001). This was an effect we had hoped to observe, as it is now well accepted that adequate apical support is essential to provide a durable correction of the anterior and posterior vaginal wall (Brubaker *et al.*, 2005).

We had predefined an alternate definition of success as women with the leading edge above the hymen (i.e. < 0 cm), in light of the correlation between symptoms and the leading edge beyond the hymen (Swift *et al.*, 2003). The fact that all 8 patients who met this criterion had recurrence of symptoms, and 7 of them actually underwent a further intervention to alleviate these symptoms, underscores the importance of the level of the hymen as a better indicator to determine subjective success as opposed to the ICS criteria. Future studies are likely to define success as a composite of the absence of bulge symptoms, the leading edge of the vagina at or above the hymen and no re-intervention for prolapse (Barber *et al.*, 2009).

The reason why we encountered such a high overall failure rate warrants further analysis. There exists the real possibility that we are reporting a significant learning effect effect, as a learning curve is inherent to all new surgical techniques (Schraffordt Koops *et al.*, 2005). This learning curve may apply to the novel technique itself; alternately, it may also be the case that the traditional repairs were performed suboptimally because the surgeon relied too much on the assumption that the adjunct of a synthetic

apical support would constitute the essence of the POP-repair.

The failure rates may also be attributable to the technique itself. The trocars and mesh tape perforate the levator muscle rather than the sacrospinous ligament. It has been demonstrated that the perforation of the ligament generates a stronger pull out force, which can hypothetically add to the durability of a POP repair (Boukerrou *et al.*, 2006). Concurrently, we have previously reported in an anatomical study that it seems more appropriate to state that the Posterior IVS procedure suspends the vagina at the upper border of level II in contrast to the level I anatomical support claimed by Petros in his original paper (Smajda *et al.*, 2005). By definition, level I support is limited to the cardinal-uterosacral ligament (deLancey, 1992). Jelovsek *et al.* came to the same conclusion in another anatomical study (Jelovsek *et al.*, 2005).

Finally, the added morbidity caused by mesh erosion and fistulisation in 14% (4/29) raises concern. The mechanism of erosion can most likely be explained by the intrinsic properties of its woven, multifilament, microporous polypropylene mesh tape. We – very easily – removed the two tapes that presented as gluteo-vaginal fistulas. A biofilm formed around the mesh had possibly induced the fistula formation and had subsequently prevented fibrosis and ingrowth of the tape. This has been reported upon previously in the literature (Mikos *et al.*, 2007). Since the initial introduction of the posterior IVS it has become apparent that the use of microporous mesh (as used in the Posterior IVS in our series) is more prone to the development of erosion in comparison to macroporous prostheses (Klosterhalfen *et al.*, 2005). The Posterior IVS currently on the market (IVS02™), changed its initial mesh tape to a macroporous polypropylene tape to alleviate this problem.

Table 5. — Posterior IVS results as published in abstracts of the annual International Urogynecology Association (IUGA): 2001-2009.

Author ^a	Meeting	n	FU (m)	succes%	erosion(n)
Farnsworth	2001	93	NR	91	NR
Vellayan	2003	15	3	100	NR
Meschia	2005	66	24	58	2
Riva	2005	172	12	87	6
Choi	2005	28	5	76	NR
Gunasekaran	2005	10	8	100	0
Vardi	2005	98	NR	99	2
Riva	2006	172	24	77	6
Hinouul	2006	92	21	90	6
de Tayrac	2006	21	10	95	NR
Bjelic-Radusic	2006	420	2	87	26
Snaaijer	2006	32	NR	NR	8
Rondini	2006	51	12	82	3
Bhal	2006	20	NR	95	1
Deffieux	2007	53	15	98	5
Geo	2007	46	25	91	1
Bergmans	2007	150	11	86	4
Iliev	2007	22	26	100	NR
Deffieux	2008	53	32	82	5

^aReferences: Abstract Books of the International Urogynaecology Society Annual meetings, 2001-2009 (Note: no references to posterior IVS found in 2002 and 2009).

Conclusion

In view of the erosion rate and the high symptomatic recurrence of POP in our study, we cannot advice the use of Posterior IVS to treat patients suffering from POP with apical involvement. We feel that the poor anatomical results can be partially attributed to the fact that the posterior IVS does not provide level I support and that the narrow mesh tape does not adequately address the lateral, level II, attachment. The intrinsic mesh properties were the likely cause of the high erosion rate, but they may also have contributed to insufficient tissue ingrowth, leading to a lack of durable support.

Acknowledgements

The authors would like to thank Professor Pierre Bonnet (Institute of Human Anatomy and the Department of Urology, University of Liège, Belgium) for supplying the anatomical illustration.

References

- Abstract Book of the International Urogynaecology Society Annual meeting, Melbourne, supplement to the Int Urogynecol J Pelvic Floor Dysfunct. 2001.
- Abstract Book of the International Urogynaecology Society Annual meeting, Buenos Aires, supplement to the Int Urogynecol J Pelvic Floor Dysfunct. 2003.
- Abstract Book of the joint International Urogynaecology Society Annual meeting and the International Continence Society, Paris, supplement to NeuroUrol and Urodyn. 2004.

- Abstract Book of the International Urogynaecology Society Annual meeting, Copenhagen, Int Urogynecol J. (2005) 16 (Suppl 2).
- Abstract Book of the International Urogynaecology Society Annual meeting, Athens, Int Urogynecol J. (2006) 17 (Suppl 2).
- Abstract Book of the International Urogynaecology Society Annual meeting, Cancun, Int Urogynecol J. (2007) 18 (Suppl 1).
- Abstract Book of the International Urogynaecology Society Annual meeting, Tai Pei, Int Urogynecol J. (2008) 19 (Suppl 1):S1-S166.
- Baessler K, Hewson AD, Tunn R *et al*. Severe mesh complications following intravaginal slingplasty. *Obstet Gynecol*. 2005;106(4):713-6.
- Barber MD, Brubaker L, Nygaard I *et al*. Defining success after surgery for pelvic organ prolapse. *Obstet Gynecol*. 2009;114:600-9.
- Biertho I, Dallemagne B, Dewandre JM *et al*. Intravaginal slingplasty: short term results. *Acta Chir Belg*. 2004;104(6):700-4.
- Boukerrou M, Lambaudie E, Collinet P *et al*. Objective analysis of mechanical resistance of tension-free devices. *Eur J Obstet Gynecol Reprod Biol*. 2006;124(2):240-5.
- Brubaker L, Bump RC, Fynes M *et al*. Surgery for pelvic organ prolapse. In: Abrams P, Cordozo L, Koury S, Wein A, editors. 3rd International Consultation on Incontinence. Paris: Health Publication Ltd;2005.
- Bump RC, Mattiasson A, Bø K *et al*. The standardization of terminology of female pelvic organ prolapse and pelvic floor dysfunction. *Am J Obstet Gynecol*. 1996;175(1):10-7.
- Deffieux X, Desseaux K, de Tayrac R *et al*. Infracoccygeal sacropexy for uterovaginal prolapse. *Int J Gynaecol Obstet*. 2009;104(1):56-9.
- deLancey J. Anatomic aspects of vaginal eversion after hysterectomy. *Am J Obstet Gynecol*. 1992;166:1717-28.
- Digesu GA, Khullar V, Cardozo L *et al*. P-QOL: a validated questionnaire to assess the symptoms and quality of life of women with urogenital prolapse. *Int Urogynecol J Pelvic Floor Dysfunct*. 2005;16(3):176-81.

- Farnsworth BN. Posterior intravaginal slingplasty (infracoccygeal sacropexy) for severe posthysterectomy vaginal vault prolapse—a preliminary report on efficacy and safety. *Int Urogynecol J*. 2002;13(1):4-8.
- Feiner B, Jelovsek JE, Maher C. Efficacy and safety of transvaginal mesh kits in the treatment of prolapse of the vaginal apex: a systematic review. *BJOG*. 2009;116(1):15-24.
- Hefni M, Yousri N, El-Toukhy T *et al*. Morbidity associated with posterior intravaginal slingplasty for uterovaginal and vault prolapse. *Arch Gynecol Obstet*. 2007;276(5):499-504.
- Hsu Y, Chen L, Summers A *et al*. Anterior vaginal wall length and degree of anterior compartment prolapse seen on dynamic MRI. *Int Urogynecol J Pelvic Floor Dysfunct* 2008;19:137-42.
- Jelovsek JE, Sokol AI, Barber MD *et al*. Anatomic relationships of infracoccygeal sacropexy (posterior intravaginal slingplasty) trocar insertion. *Am J Obstet Gynecol*. 2005;193(6):2099-104.
- Jordaan DJ, Prollius A, Cronje HS *et al*. Posterior intravaginal slingplasty for vaginal prolapse. *Int Urogynecol J*. 2006;17(4):326-9.
- Klosterhalfen B, Junge K, Klinge U. The lightweight and large porous mesh concept for hernia repair. *Expert Rev Med Devices*. 2005;2(1):103-17.
- Kolusari A, Yildizhan R, Adali E *et al*. A. Short-term results of posterior intravaginal slingplasty in grade 4 uterine prolapse. *Arch Gynecol Obstet*. 2010;281:55-8.
- Lowder JL, Park AJ, Ellison R *et al*. The role of apical vaginal support in the appearance of anterior and posterior vaginal prolapse. *Obstet Gynecol*. 2008;111(1):152-7.
- Luck AM, Steele AC, Leong FC *et al*. Short-term efficacy and complications of posterior intravaginal slingplasty. *Int Urogynecol J Pelvic Floor Dysfunct*. 2008;19(6):795-9.
- Maher C, Baessler K, Glazener CMA *et al*. Surgical management of pelvic organ prolapse in women. *Cochrane Database Syst Rev*. 2007:CD004014.
- Mattox TF, Moore S, Stanford EJ *et al*. Posterior vaginal sling experience in elderly patients yields poor results. *Am J Obstet Gynecol*. 2006;194(5):1462-6.
- Mikos T, Tsalikis T, Papanikolaou A *et al*. Gluteo-vaginal sinus formation complicating posterior intravaginal slingplasty followed by successful IVS removal. A case report and review of the literature. *Int Urogynecol J Pelvic Floor Dysfunct*. 2008;19(3):449-52.
- Neuman M, Lavy Y. Posterior intra-vaginal slingplasty for the treatment of vaginal apex prolapse: Medium-term results of 140 operations with a novel procedure. *Eur J Obstet Gynecol Reprod Biol*. 2008;140(2):230-3.
- Petros P. Vault prolapse II: restoration of dynamic vaginal supports by infracoccygeal sacropexy, an axial day-case vaginal procedure. *Int Urogynecol J*. 2001;12:296-303.
- Rooney K, Kenton K, Mueller ER *et al*. Advanced anterior vaginal wall prolapse is highly correlated with apical prolapse. *Am J Obstet Gynecol*. 2006;195:1837-40.
- Schraffordt Koops SE, Bisseling TM, Heintz AP *et al*. Prospective analysis of complications of tension-free vaginal tape from The Netherlands Tension-free Vaginal Tape study. *Am J Obstet Gynecol*. 2005;193:45-52.
- Smajda S, Vanormelingen L, Vandewalle G *et al*. Translevator posterior intravaginal slingplasty: anatomical landmarks and safety margins. *Int Urogynecol J Pelvic Floor Dysfunct*. 2005;16(5):364-8.
- Sivaslioglu AA, Gelisen O, Dolen I *et al*. Posterior sling (infracoccygeal sacropexy): an alternative procedure for vaginal vault prolapse. *Aust N Z J Obstet Gynaecol*. 2005;45(2):159-60.
- Summers A, Winkel LA, Hussain HK *et al*. The relationship between anterior and apical compartment support. *Am J Obstet Gynecol*. 2006;194:1438-43.
- Swift SE, Tate S, Nicholas J. Correlation of symptoms with degree of pelvic organ support in a general population of women: What is pelvic organ prolapse? *Am J Obstet Gynecol*. 2003;189:372-9.
- von Theobald P, Labbé E. [Posterior IVS: feasibility and preliminary results in a continuous series of 108 cases] [Article in French]. *Gynecol Obstet Fertil*. 2007;35(10):968-74.
- Weber AM, Walters MD, Piedmonte MR *et al*. Anterior colporrhaphy: a randomized trial of three surgical techniques. *Am J Obstet Gynecol*. 2001;185(6):1299-304.
- Whiteside JL, Weber AM, Meyn LA *et al*. Risk factors for prolapse recurrence after vaginal repair. *Am J Obstet Gynecol*. 2004;191(5):1533-8.