

Ultrasound features in trisomy 13 (Patau syndrome) and trisomy 18 (Edwards syndrome) in a consecutive series of 47 cases

I. KROES¹, S. JANSSENS², P. DEFOORT¹

¹Department of Obstetrics and Gynaecology, Ghent University Hospital, De Pintelaan 185, 9000 Gent, Belgium.

²Center for Medical Genetics Ghent, Ghent University Hospital, De Pintelaan 185, 9000 Gent, Belgium.

Correspondence at: kroes.ivo@gmail.com

Abstract

Objective: To determine and list the variety of the predominant appeal signs leading to referral and their accompanying features found during specialized ultrasound evaluation in fetuses with trisomy 13 and trisomy 18.

Materials and Methods: In a period of thirty years, 1110 cases of foetal malformations were detected during specialized echographic evaluation. 47 Of these cases were fetuses with trisomy 13 or trisomy 18. We evaluated the predominant signs leading to referral, the difference and overlap in presenting signs between both syndromes and when the data were available, we also compared the echographic signs with the foetal pathology.

Results: In fetuses with trisomy 13 the most common malformations were craniofacial defects, cerebral malformations and genitourinary tract anomalies. The most common malformations associated with trisomy 18 were limb abnormalities and intrauterine growth restriction. Most malformations were predominant in trisomy 18, except for genitourinary tract anomalies. In most cases the sonographic signs correlated with the pathology findings.

Conclusion: Trisomy 13 as well as trisomy 18 are characterized by a number of various malformations in the foetus. Most of the ultrasound features were predominant in fetuses with trisomy 18. Mostly the foetal pathology correlated with the sonographic evaluation.

Key words: Antenatal diagnosis, congenital abnormalities, sonographic signs, trisomy 13, trisomy 18, ultrasound.

Introduction

Trisomy 13 as well as trisomy 18 are typified by various foetal malformations. Although less prevalent than trisomy 21 (1 per 800 births), they are by no means extremely rare (Bundy et al., 1986; Shields et al., 1998; Fleischer et al., 2011).

Trisomy 18, also known as Edwards syndrome, is the second most common autosomal trisomy with a prevalence ranging between 1:3500 and 1:8000 births. Approximately 68% of fetuses with trisomy 18 die in utero, only 10% survive the first year of life (Dicke and Crane, 1991).

Trisomy 13, or Patau syndrome, has a prevalence of 1 per 6500 births. Most fetuses with trisomy 13 die in utero or are stillborn. Of those who alive at birth, only 20% will survive the first month of life and only 5% will survive the first six months (Fleischer et al., 2011).

The relationship of trisomy 13 and 18 with maternal aging is, contrary to trisomy 21, less outspoken. Overall 80% of children with a chromosomal abnormality are born to women under age 35 (Savva et al., 2010). This underlines the importance of ultrasound as a noninvasive screening tool for foetal abnormalities and associated underlying trisomies in younger women (Dicke and Crane, 1991).

Trisomy 13 fetuses may show various brain anomalies including holoprosencephaly – sometimes enabling the diagnosis made at 12 weeks of pregnancy – all or not with midfacial hypoplasia (cyclopia and proboscis), ventriculomegaly, enlarged cistern magna, microcephaly, agenesis of the corpus callosum, cleft lip and palate, microphthalmia, hypotelorism, nuchal thickening or hydrocephalus, neural tube defects (NTD), omphalocele, kidney and urogenital anomalies,

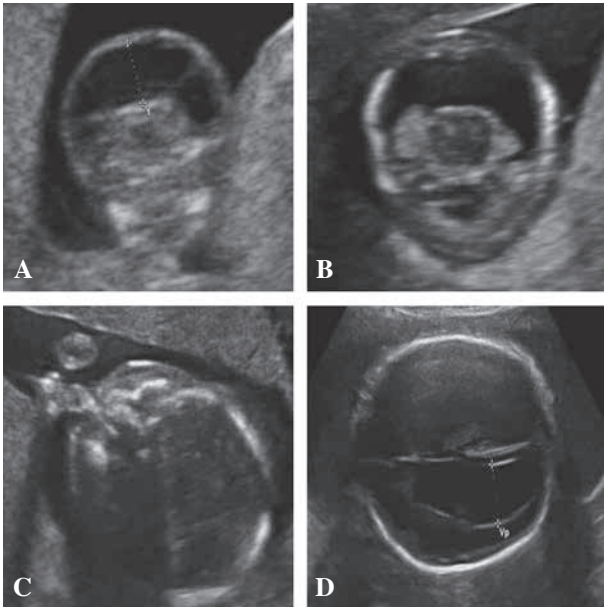


Fig. 1. — Trisomie 13: hygroma colli at gestational age (GA) of 11 weeks (A), holoprosencephaly at GA of 12 weeks (B), bilateral cleft lip palate or parrot beak at GA of 20 weeks (C), hydrocephaly at GA of 20 weeks.

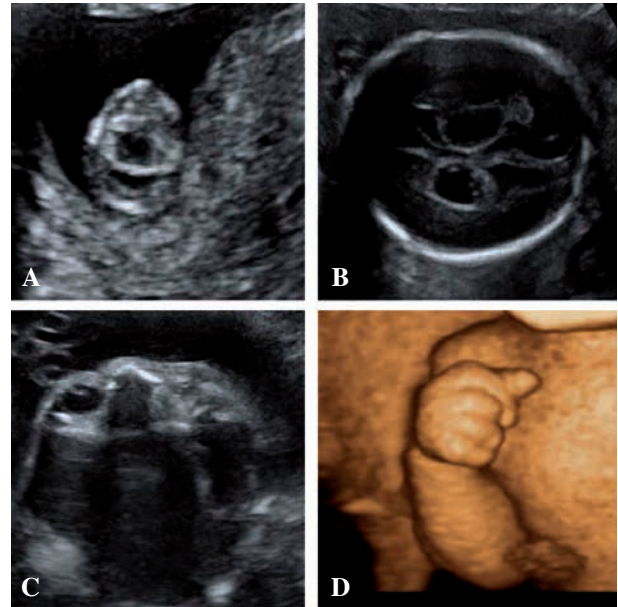


Fig. 2. — Trisomie 18: holoprosencephaly at gestational age (GA) of 11 weeks (A), Chorioid plexus cysts at GA of 20 weeks (B), microphthalmia unilateral at GA of 30 weeks (C), clenched hands with overriding index fingers at GA of 32 weeks.

hyperechogenic bowel, cardiac echogenic foci (resulting from echogenic chordae tendineae), cardiac defects, single umbilical artery (SUA), radial aplasia, polydactyly and flexion deformity of the fingers (Fig. 1).

Sonographic detection in trisomy 13 is reported to have a sensitivity of 90 to 100% by Benacerraf when a complete survey of the foetus, including the heart, was performed. She also reported that the detection rate by sonography in trisomy 18 is 80%. Still, fetuses with trisomy 13 without any anomaly being observed in the second trimester have been described (Benacerraf, 2008).

In trisomy 18 the features may include agenesis of the corpus callosum, meningomyelocele, ventriculomegaly, chorioid plexus cysts, posterior fossa anomalies, cleft lip and palate, micrognathia, low-set ears, microphthalmia, hypertelorism, short radial ray, clenched hands with overriding index fingers, club or rocker bottom feet, omphalocele, diaphragmatic hernia, renal anomalies, cardiac defects, SUA, polyhydramnios, nuchal thickening or hygroma and cryptorchidism (Fig. 2).

Intra-uterine growth restriction (IUGR) based on birth weight was observed as a feature both in trisomy 13 and 18 (Polani, 1974). Kirkinen et al. (1984) reported IUGR as a feature in trisomy 18 only in a series of neonates dying from the malformation.

The purpose of the present paper is to analyse which was or were the predominant appeal sign(s)

leading to referral to our centre and what were the accompanying features found during specialized echographic evaluation. If the data were available, we also compared the echographic signs with the foetal pathology. It appears that both trisomy 13 and 18 are picked up by a variety of predominant echographic features. We also evaluated what was the degree of commonality in predominant signs between both syndromes and what features remained particular to either trisomy 13 or 18.

Material and Methods

The study population consisted of all consecutive patients referred to the University Hospital of Gent for specialized prenatal echographic evaluation between 1980 and 2011. One of us (PD) observed 1110 cases of foetal malformations during these echographic consultations. 47 Of these cases with echographic malformations were fetuses with either trisomy 13 (15 cases) or trisomy 18 (32 cases).

Echographic evaluation included standard biometry measurements of biparietal diameter, head circumference, transcerebellar diameter, abdominal circumference and femur length as well as foetal anatomic evaluation of the total foetal head, thorax, abdomen and extremities in accordance with the criteria for structural echoscopic evaluation of the Flemish Society of Obstetrics and Gynaecology (www.vvog.be). Where applicable we also attempted to evaluate the nuchal skin fold.

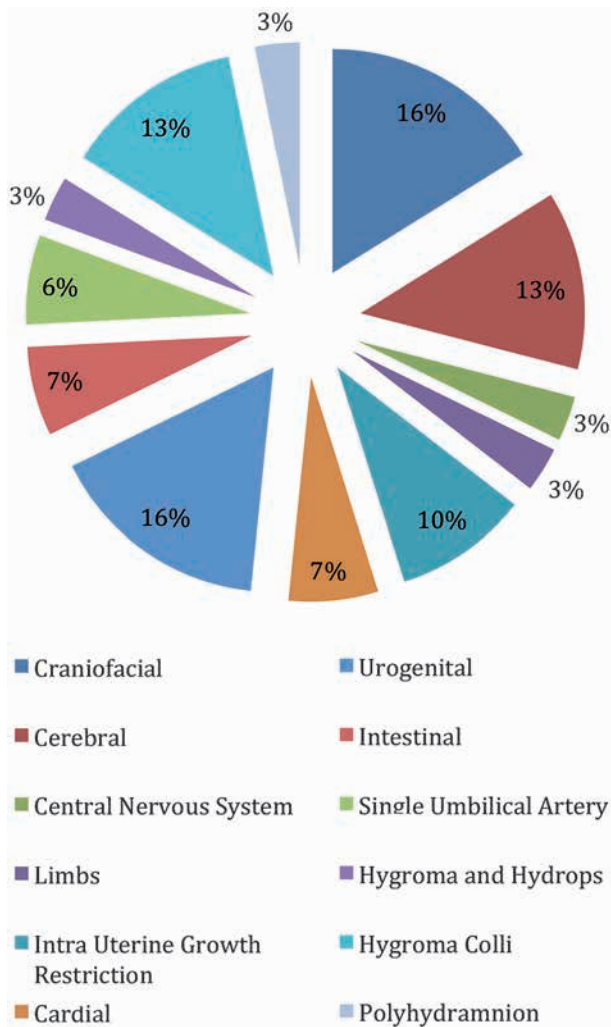


Fig. 3. — Ultrasound findings in Trisomy 13

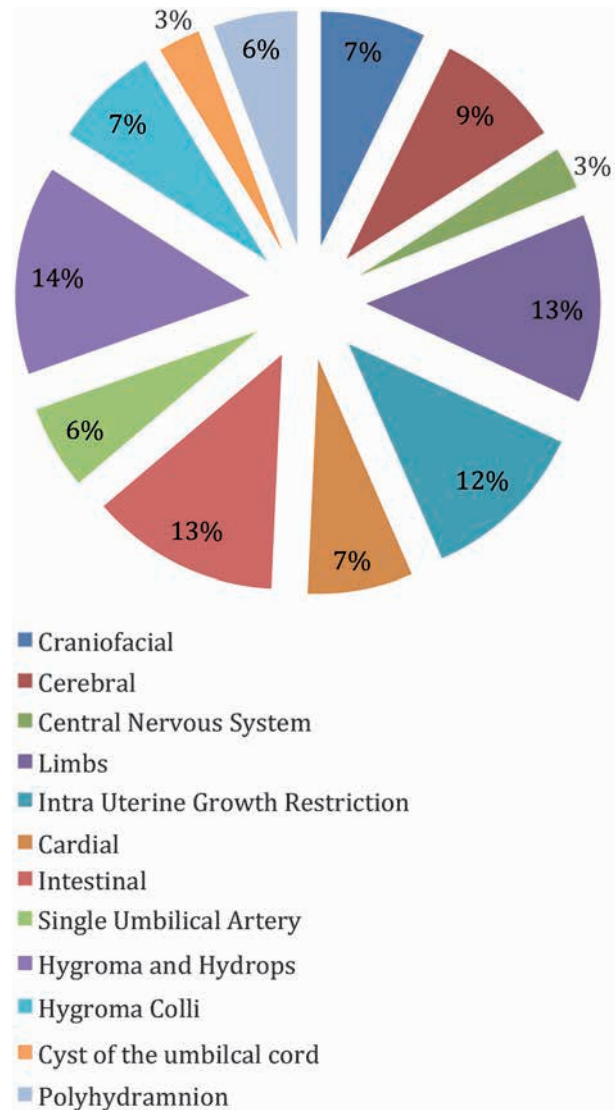


Fig. 4. — Ultrasound findings in Trisomy 18

Results

Characteristics of the study population

Of the 1110 detected cases of foetal malformations, 47 were foetuses with trisomy 13 (15 cases) or trisomy 18 (32 cases). The overall mean maternal age found was 31,0 years with a range from 22 to 42 years. For trisomy 13 the mean maternal age was 30,3 years with a range from 27 to 42 years. For trisomy 18 this was 31.6 years with a range from 22 to 42 years. In our study population, 69% of the women with trisomic foetuses were younger than 35 years of age.

The overall mean gestational age found at detection was 19,5 weeks, with a range from 11 to 36 weeks. For trisomy 13 the mean gestational age was 22,8 weeks, with a range from 11 to 36 weeks. For trisomy 18 this was 17,4 weeks, with a range from 11 to 33 weeks. Due to the recruitment by

referral of these cases, we lack a quantitative background population and cannot make any guess as to prevalence or incidence of the syndromes in our material.

Ultrasound findings

In the group of foetuses diagnosed with trisomy 13 a total of 31 various malformations were observed by ultrasound. Three of a total of 15 ultrasounds were done in the first trimester, all the foetuses in this group were diagnosed with hygroma colli. In the other foetuses with trisomy 13 the most common malformations were craniofacial defects, cerebral malformations and problems with the urogenital tract (Fig. 3).

In the group diagnosed with trisomy 18 the total number of detected malformations was 69. Nine of the 32 patients were in their first trimester at ultrasound evaluation. Seven of these 9 cases were

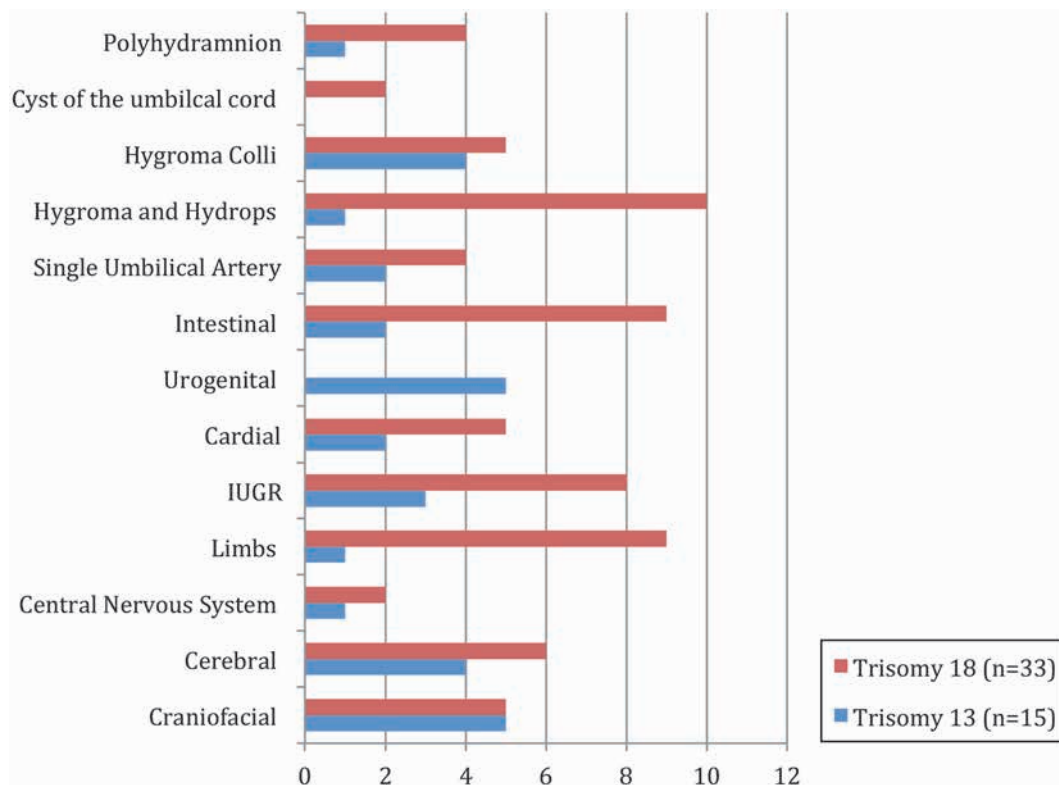


Fig. 5. — Overlap and difference in ultrasound findings Trisomy 13 and Trisomy 18

diagnosed with hygroma colli. In the patients evaluated after the first trimester of pregnancy the most common ultrasound findings were intestinal tract defects, malformation of the limbs and intra uterine growth restriction (IUGR) (Fig. 4).

Figure 5 shows the overlap and difference between the predominant signs found with trisomy 13 and trisomy 18. The number of craniofacial defects found, were equal for trisomy 13 as well as trisomy 18.

Most ultrasound findings seem to be equally predominant in trisomy 18 or 13, with the exception of defects in the urogenital tract, which we only found in foetuses with trisomy 13. The most spectacular case was a 28-year-old Turkish Gravida 4 who showed up very late in pregnancy. The foetus, a cryptorchidic boy, showed an enormous multicystic mass consisting of a mega-ureter and hypertrophic bladder with prune-belly sequence in the left hemi-abdomen. The left kidney, adrenal and spleen were dislocated into the thorax through a diaphragmatic hernia. There were hypoplastic lungs with a bilateral left lobulation, an accessory left liver lobe and Fallot's tetralogy. The 3320-gram baby died just after delivery (Apgar score 3/1/0).

Due to the recruitment by referral, we cannot say anything about missed cases during echographic evaluation.

Pathology findings

If the data were available, we also compared the echographic signs with the foetal pathological situation. In the group of foetuses with trisomy 13 the most common malformations found by the pathologist correlated well with the malformations found during ultrasound evaluation, namely craniofacial defects, cerebral malformations and problems with the urogenital tract (Fig. 6).

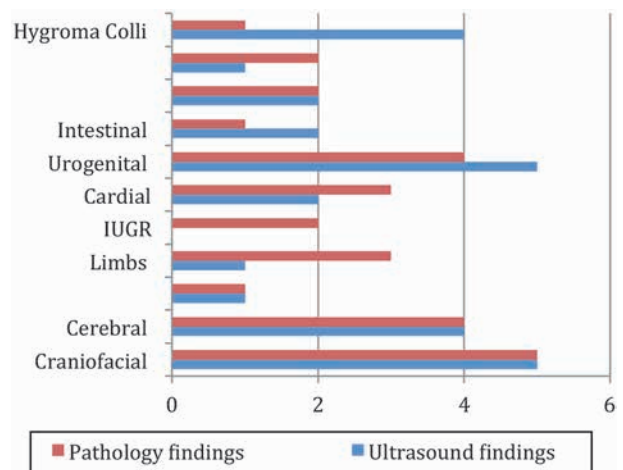


Fig. 6. — Overlap and difference in ultrasound findings and pathology findings Trisomy 13.

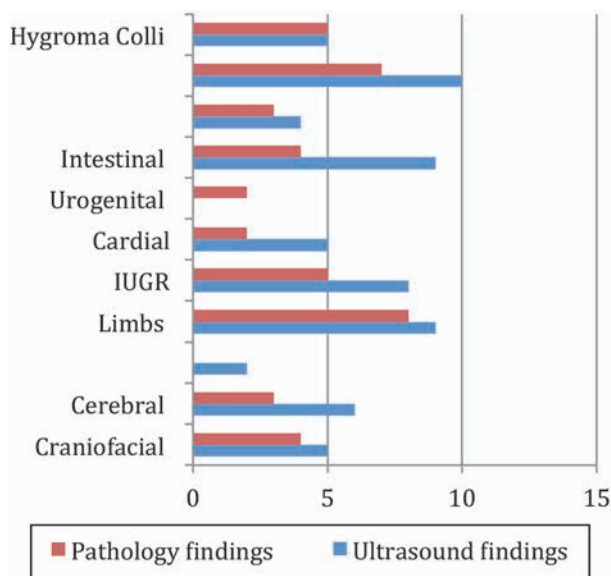


Fig. 7. — Overlap and difference in ultrasound findings and pathology findings Trisomy 18.

In the group diagnosed with trisomy 18, the pathology findings also correlated with the malformations found during ultrasound evaluation. The most common malformations in foetuses with trisomy 18 were hygroma colli and hydrops, problems with the intestinal tract and malformations of the limbs (Fig. 7).

Discussion

Trisomy 13 as well as trisomy 18 are typified by a number of various malformations in the foetus. In our study population 69% of women with trisomic foetuses were younger than 35 years of age. Most referrals were made during the first or second trimester of pregnancy. A small amount of malformations were discovered later in pregnancy.

The most common ultrasound features in our study population were predominant in foetuses diagnosed with trisomy 18. In this group we mostly saw intestinal tract defects, malformation of the limbs including clenched fists, and intra uterine growth restriction. In case of trisomy 13 we observed that all the foetuses presented with hygroma colli when referred in the first trimester. In foetuses diagnosed after the first trimester of pregnancy the predominant ultrasound features leading to referral to our centre were craniofacial defects, cerebral malformations and problems with the urogenital

tract. Urogenital tract malformations were only found on foetuses with trisomy 13. Overall the ultrasound features correlated well with the pathology findings in both trisomy 13 and trisomy 18 cases.

Our data also confirm that IUGR is a specific feature of trisomy 18 and not of trisomy 13 as reported before (Kirkinen et al., 1983; Polani, 1974).

As expected and due to the progress of early ultrasound diagnosis in pregnancy, we observed in our chronological series a tendency to detect trisomy 13 and 18 on the occasion of chorionic villus sampling (CVS) with hygroma colli as the most important feature and no longer from more outspoken anatomic abnormalities later in pregnancy. However this secular trend was not significant, meaning that there is clearly still a field for more active exploration of early sonomarkers.

Our results once more confirm the need for genetic testing to further explore foetal anatomical anomalies, especially when presenting in a cluster.

Acknowledgement

We owe a debt of gratitude to Dr. Ellen Roets, Department of Obstetrics and Gynaecology Ghent University Hospital, to have given us an extensive database of sonographic pictures to invliven our article.

References

- Benacerraf B. Ultrasound of foetal syndromes. 2nd Ed. P. 483-496. Philadelphia, Churchill-Livingstone-Elsevier, 2008.
- Bundy AL, Slatzman DH, Pober B et al. Antenatal Sonographic findings in Trisomy 18. *J Ultrasound Med.* 1986;5:361-4.
- Dicke JM, Crane JP. Sonographic recognition of major malformations and aberrant foetal growth in trisomic foetuses. *J Ultrasound Med.* 1991;10:433-8.
- Fleischer AC, Toy EC, Lee W et al. Sonography in obstetrics and gynecology, principles and practice, 7th Ed.P. 670-4. McGraw-Hill Companies, 2011.
- Kirkinen P, Joupilla P, Herva R. Intra-uterine growth and fatal foetal abnormality. *Acta Obstet Gynecol Scand.* 1983;62:43-7.
- Polani EP. Chromosomal and other genetic influences on birthweight variation. P. 127-135. CIBA Symposium (New Series) Amsterdam-NY, Excerpta Medica, 1974.
- Savva GM, Walker K, Morris JK. The maternal age-specific live birth prevalence of trisomies 13 and 18 compared to trisomy 21 (Down syndrome). *Prenat Diagn.* 2010;30:57-64.
- Shields LE, Carpenter LA, Smith KM et al. Ultrasonographic diagnosis of trisomy 18: is it practical in the early second trimester? *J Ultrasound Med.* 1998;17:327-31.