

Reproductive outcome after IVF following hysteroscopic division of incomplete uterine septum/arcuate uterine anomaly in women with primary infertility

M. ABUZEID^{1,2}, G. GHOURAB², O. ABUZEID², M. MITWALLY³, M. ASHRAF^{1,2}, M. DIAMOND⁴

¹*Division of Reproductive Endocrinology and Infertility, Department of OB/GYN, Hurley Medical Center, Two Hurley Plaza, Suite 209, Flint, Michigan 48503, USA.*

Michigan State University College of Human Medicine, Flint Campus, USA.

²*IVF Michigan PC, 3950 Rochester Road, Suite 2300, Rochester Hills, Michigan 48307, USA.*

³*Odessa Reproductive Medicine Center, 520 E. 6th Street, Odessa, TX 79761, USA.*

⁴*Georgia Regents University, Chairman of the Department of OB/GYN, 1120 15th Street BA 7300, Augusta, Georgia 30909, USA.*

Correspondence at: reprod1@hurleymc.com

Abstract

Objective: To determine reproductive outcome after in-vitro fertilization/embryo transfer (IVF-ET) in women with primary infertility following hysteroscopic septoplasty of incomplete uterine septum or arcuate uterine anomaly.

Methods: This is a historical cohort study. The study group consisted of 156 consecutive patients who underwent a total of 221 cycles of IVF/ET following hysteroscopic septoplasty of an incomplete uterine septum or arcuate anomaly (Group 1). The control group included 196 consecutive patients with normal endometrial cavity on hysteroscopy who underwent a total of 369 cycles of IVF/ET (Group 2). The reproductive outcome after the first cycle of IVF-ET and the best reproductive outcome of all the cycles the patient underwent were calculated. In addition, we compared the reproductive outcome in the study group based on the type of the anomalies (septum versus arcuate).

Results: In the first fresh cycle, following septoplasty, there were significantly higher clinical pregnancy and delivery rates in Group 1 (60.3% and 51.3% respectively) compared to Group 2 (38.8% and 33.2% respectively). However, there was no significant difference between the two groups in the clinical pregnancy (74.4% vs. 67.3%) or in the delivery (65.4% vs. 60.2%) rates per patient, respectively. There was no significant difference in the reproductive outcome after IVF-ET between patients who previously had arcuate uterine anomaly versus incomplete uterine septum.

Conclusion: Reproductive outcome of IVF-ET after hysteroscopic correction of incomplete uterine septum/arcuate uterine anomaly in women with primary infertility is no different from women with normal uterine cavity.

Key words: IVF, primary infertility, hysteroscopy, incomplete uterine septum, arcuate anomaly, septate uterus.

Introduction

Septate uterus accounts for over half of all cases of congenital Müllerian anomalies (Grimbizis et al., 2001). It is associated with a very high pregnancy wastage rate, as high as 70% (Buttram and Gibbons, 1979). It has also been shown to be an important risk variable for preterm birth (Tomazavic et al., 2007). In addition, septate uterus is associated with a high prevalence of both repeated assisted

reproductive technology (ART) failure (18.2%) (Raga et al., 1997) and early pregnancy loss after ART (9.7%) (Dicker et al., 1996).

The issue of uterine septum and infertility remains controversial, with both limited and conflicting data in the literature (Grimbizis et al., 2001; Rackow and Arici, 2007; Heinonen et al., 2006; Pabuccu et al., 2004; Shokeir et al., 2011). More recently, some reports suggested that hysteroscopic septoplasty in patients with unexplained infertility increases

natural conception rates as well as live birth rates, and decreases the risk of miscarriage (Mollo et al., 2009; Tonguc et al., 2011).

The association between uterine septum and the reproductive outcome after ART has not been adequately studied. Many studies reported the reproductive outcome after ART as part of the population studied (Shokeir et al., 2011; Grimbizis et al., 1998; Blanc et al., 1998; Doridot et al., 2003; Bendifallah et al., 2013). To this date only two retrospective studies addressing this issue have been published (Ozgun et al., 2007; Ban-Franchez et al., 2009). Data from these studies suggest that patients who underwent hysteroscopic septoplasty before in-vitro fertilization (IVF) have similar pregnancy and miscarriage rates when compared to those who have a normal uterine cavity (Ozgun et al., 2007; Ban-Franchez et al., 2009).

In addition, the literature is not clear on a definition of arcuate uterine anomaly based on the American Fertility Society classification (AFS Class VI) (AFS, 1988), or its effects on reproductive outcome (Mucowski et al., 2010). Only a few studies addressed this topic with conflicting results (Rackow and Arici, 2007; Bendifallah et al., 2013; Troiano and McCarthy, 2004; Woelfer et al., 2001; Giacomucci et al., 2011).

The aim of our study was to investigate the suggested beneficial effect that hysteroscopic septoplasty has on the reproductive outcome after IVF-ET in women with primary infertility and a subseptate uteri or arcuate uterine anomaly. The primary outcome measure was the reproductive outcome of the first fresh cycle. The secondary outcome measure was the best reproductive outcome of all the cycles the patient underwent. In addition, we compared the reproductive outcome in such patients based on the type of the anomalies (septum versus arcuate).

Material and Methods

This historical cohort study included all patients with primary infertility that underwent basic infertility workup and had hysteroscopy, laparoscopy and tubal perfusion between January 1992 and December 2011. Information was retrieved from the surgery and IVF database at our unit. This study was approved by the Institutional Review Board at Hurley Medical Centre, Flint, Michigan. All patients underwent basic infertility work up including a hysterosalpingogram (HSG), day 3 serum FSH and LH levels, serum prolactin and TSH levels, trans-vaginal 2D ultrasound scan (US) and mid-luteal progesterone levels. Semen analysis was performed on all male partners. During the last 8

years of the study, all patients underwent saline infusion hysterosonogram (SIH) with 2D US and 3D US. All patients underwent diagnostic hysteroscopy and diagnostic laparoscopy and tubal perfusion as part of their infertility work up. Operative laparoscopy was performed whenever endometriosis or tubal pathology was detected after staging endometriosis and tubal disease by the modified classification of AFS, and later, by the American Society of Reproductive Medicine (ASRM) classifications (AFS, 1988; ASRM, 1997). Whenever uterine septum was detected, it was classified according to AFS (1988) classification (AFS, 1988). For the purpose of this study the patient was considered to have arcuate anomaly if she satisfied AFS description of Class VI Müllerian anomaly (wide based and a convex apex) and the endocavitary length of the midline depression was ≥ 1 cm (Mitwally and Abuzeid, 2008). The endocavitary length of the midline depression was measured by comparing the length of the cutting wire and yellow tip of the straight resectoscope loop electrode to the length of the resected arcuate fundal anomaly.

There were a total of 871 patients enrolled in the study. Five hundred and fifty patients were found to have no uterine anomaly, of which 196 patients underwent IVF-ET. The remaining 321 patients had a hysteroscopic correction of uterine anomaly (uterine septum or arcuate uterine anomaly) of which 156 patients subsequently went on to have IVF-ET. Only 3 out of the 156 patients who underwent IVF-ET (1.9%) had a complete septum (Class Va), while the remaining either had an incomplete septum (Class Vb) ($n = 74$) or an arcuate uterine anomaly (Class VI) ($n = 79$).

All operations were performed under general anaesthesia during the mid follicular phase of the menstrual cycle or while the patient was on oral contraceptives. Diagnostic hysteroscopy was initially performed. If a uterine septum or arcuate uterus was found, hysteroscopic division of such pathology was performed at the same setting. In the first 6 years of the series, solid hysteroscopic scissors and operative hysteroscope were used, with normal saline used as a distension medium. During the last 13 years the septum was divided using monopolar cautery and straight resectoscope loop with a Gyrus ACMI hysteroscopic resectoscope (Division of Olympus; Maple Grove, MN, USA). A zero degree or 12 degree hysteroscope was used. Glycine 1.5% was used as a distension medium. A cutting current of 70 watts and a coagulation current of 50 watts were used. The procedure was considered complete upon achieving a triangular and symmetrical uterine cavity. Post-

operative care included placing a paediatric Foley catheter (size 8 French) inside the endometrial cavity, and inflating its balloon with 3 cc of normal saline for 6 days. No antibiotic was administered. All patients were placed on estrogen treatment for 6 weeks, adding Progesterone during the last 10 days of the estrogen course. Postoperative evaluation of the endometrial cavity after 7-8 weeks was performed, initially by HSG, and more recently, using trans-vaginal saline infusion sonohysterogram (SIH) with 2D and 3D US.

Patients were divided into two groups. The study group (Group 1) included 156 consecutive patients who underwent a total of 221 cycles of IVF/ET after having had hysteroscopic septoplasty. The control group (Group 2) consisted of 196 consecutive patients with no uterine anomalies (as determined by hysteroscopy), who underwent a total of 369 cycles of IVF/ET. The total number of IVF cycles per patient included both fresh and frozen attempts.

Between 1992-2002 controlled ovarian stimulation (COS) was achieved using mid luteal GnRH-a protocol and mixed gonadotropin protocol. While in the period between 2003-2011 both mid luteal GnRH-a protocol and GnRH antagonist protocol were used during COS where appropriate. Pure FSH was used in PCOS patients whenever possible. For the fertilization procedure IVF was used in the period between 1992-1994. Both IVF and intracytoplasmic sperm injection (ICSI) procedures were used where appropriate in the period between April 1994-2000. Since 2001, ICSI was used for all indications for IVF-ET procedures. Embryos were graded based on morphologic criteria (Khan et al., 1991) on day 3 in the period between 1992-2005. Subsequently, in the period between 2005-2011 embryos were graded on both day 2 by blastomere nuclear scoring (Van Royen et al., 2003) and day 3 by morphologic criteria. In the period between 2001-2011 blastocysts were graded according to Gardner's criteria (Gardner et al., 2004). Between 1992-2000 ET was performed on day 3, while between 2001-2011, if 6-8 embryos were of good quality on day 3, the transfer was delayed until day 5 (blastocyst transfer). ET was performed under trans-abdominal US-guidance starting in 1997. Since 2007 only 2 top quality embryos / blastocysts were transferred. Extra good quality zygote/cleavage stage embryos/ blastocysts were routinely frozen.

Luteal phase support protocol changed over the years, but always included vaginal Progesterone daily and Progesterone in oil, 100 mg IM every other day. In addition, Estradiol (2mg) B.I.D. was utilized for luteal phase support since 2007. Luteal phase support was discontinued with a negative

pregnancy test; otherwise, it was continued until 12-week gestation. Progesterone in oil and Estradiol were discontinued at six weeks gestation.

Pregnancy was confirmed by measurement of β HCG twelve days after blastocyst transfer, or fourteen days if ET was done on day 3. Clinical pregnancy rate was defined as the presence of a gestational sac on trans-vaginal 2D US scan at six weeks gestation. Miscarriage was defined as a clinical pregnancy that ended in pregnancy loss prior to twenty weeks gestation. Preterm birth rate was defined as any birth before 37 weeks gestation, while severe preterm birth was defined as any birth before 32 weeks gestation.

The primary outcome measure was the reproductive outcome of the first fresh IVF cycle. The secondary outcome measure was the best reproductive outcome of all the cycles, fresh and frozen, that the patient underwent. In other words for the secondary outcome measure, if a patient conceived more than once, the best outcome was the one chosen for the cumulative pregnancy outcome analysis. In addition, we compared the best reproductive outcome in such patients based on the type of the anomalies (septum versus arcuate).

Statistical analysis was performed with independent Student's t-test for comparison of continuous variables and Chi-squared analysis for comparison of categorical data. Binary logistical regression was used to assess the impact of group, duration of infertility, tubal factor, and endometriosis on clinical pregnancy rate and on delivery rate. A p-value < 0.05 was considered statistically significant.

Results

There was no significant difference in age, BMI, day 3 FSH or in the incidence of male factors infertility or ovulatory disorders between the two groups (Table I). The duration of infertility was significantly shorter and the incidence of endometriosis and tubal factors infertility was significantly lower in Group 1 compared to Group 2, $p = 0.006$ and $p = 0.000$ respectively (Table I).

The primary outcome measures (the reproductive outcome of the first fresh IVF cycle) are shown in Table II. There was significantly higher clinical pregnancy and delivery rates in Group 1 (60.3% and 51.3% respectively) compared to Group 2 (38.8% and 33.2% respectively) ($p = 0.000$ and $p = 0.001$ respectively). There was no significant difference in the miscarriage or ectopic pregnancy rates between the two groups (Table II).

The secondary outcome measures (the best reproductive outcome of all the cycles, fresh and

Table I. — Demographic Data.

	Group 1 (n = 156)	Group 2 (n = 196)
Age (years)	31.8 ± 4.4	31.3 ± 3.8
BMI (kg/m ²)	27.3 ± 7.5	25.8 ± 6.3
Day 3 FSH (miu/ml)	6.2 ± 3.5	6.0 ± 2.6
Duration of infertility (years)*	2.8 ± 2.2	3.5 ± 2.8
Male factor infertility	47.4%	37.1%
Tubal factor infertility**	24.0%	77.7%
Ovulatory factor infertility	38.3%	33.0%
Endometriosis**	52.6%	77.2%
History of uterine factors	100%	21.8%***
*p = 0.005		
**p = 0.000		
***Such as submucous fibroid or endometrial polyp. Such uterine factors were corrected via hysteroscopy once the pathology was found at diagnostic hysteroscopy, and prior to the initial IVF treatment.		

frozen, that the patient underwent) are shown in Table III. There was significantly higher cumulative clinical pregnancy (52.5% vs. 35.8%, $p = 0.0001$) and delivery (46.2% vs. 32%, $p = 0.0006$) rates per cycle in Group 1 compared to Group 2, respectively (Table III). However, there was no significant difference between Group 1 and Group 2 in the cumulative clinical pregnancy (74.4% vs. 67.3%) or in the cumulative delivery (65.4% vs. 60.2%) rates per patient (Table III). In a multiple binary logistical regression of the best outcome of fresh and / or frozen cycle neither tubal factor (95% CI of 0.74 – 2.26), endometriosis (95% CI of 0.58 – 1.66), nor group status (95% CI of 0.38 – 1.21) had a statistically significant effect on the clinical pregnancy rate per patient, but increasing duration of infertility was inversely related to pregnancy outcome (95% CI of 0.83 – 0.99). Also in a multiple binary logistical regression of the best outcome of fresh and / or frozen cycle neither tubal factor (95% CI of 0.77 – 2.20), endometriosis (95% CI of 0.63 – 1.68), nor group status (95% CI of 0.44 – 1.31) had a statistically significant effect on the delivery

rate per patient, but again duration of infertility negatively impacted delivery outcome (95% CI of 0.81 – 0.97). There was no significant difference in the miscarriage, ectopic pregnancy, and multiple pregnancy rates between the two groups (Table III). In singleton pregnancies, the rates of full term birth (83.9% vs. 78.6%), preterm birth (16.1% vs. 21.4%), and severe preterm birth i.e. ≤ 32 -week gestation (7.2% vs. 1.4%) were not different between Group 1 and Group 2 respectively. There was also no significant difference in mean gestational age at delivery in Group 1 (37.9 ± 1.0) compared to Group 2 (38.3 ± 0.7). In twins and higher order multiple pregnancies, there was no significant difference in the rates of full term birth, severe preterm birth or mean gestational age between the two groups (Fig. 1). However, the preterm birth rate was significantly higher in Group 1 (75.8%) compared to Group 2 (52.6%) ($p = 0.004$) (Fig. 1).

When the pregnancy outcome in patients who previously had an arcuate uterus (79) was compared to those who previously had an incomplete uterine septum (74), there was no significant difference in

Table II. — Reproductive Outcome after the First Fresh Cycle.

	Group 1 n = 156	Group 2 n = 196
Number clinical pregnancy (%) *	94 (60.3%)	76 (38.8%)
Number Delivered (%) **	80 (51.3%)	65 (33.2%)
Number Miscarried (%)	14 (14.9%)	11 (14.9%)
Number Ectopic (%)	0 (0%)	6 (7.9%)
*p = 0.000.		
**p = 0.001.		

Table III. — Comparison of the best reproductive outcome among all the cycles (fresh and frozen) between group 1 and group 2.

	Group 1	Group 2
Number of patients	156	196
Number of cycles	221	369
Cumulative clinical pregnancy rate per cycle*	52.5%	35.8%
Cumulative delivery rate per cycle**	46.2%	32.0%
Cumulative clinical pregnancy per patient	74.4%	67.3%
Cumulative delivery Rate per patient	65.4%	60.2%
Miscarriage rate	12.1%	12.9%
Multiple pregnancy rate	36.6%	36.4%
Ectopic pregnancy rate	0%	6.1%

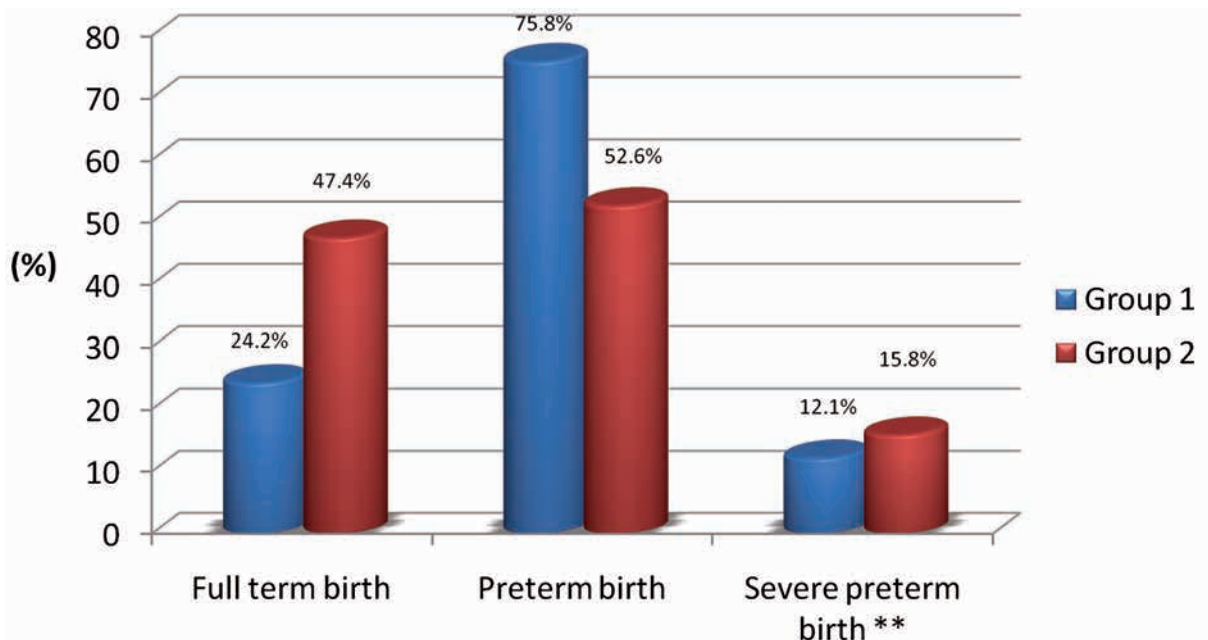
*p = 0.0001
**p = 0.0006.

the clinical pregnancy (74.7% vs. 75.0%) and the delivery (68.4% vs. 63.2%) rates per patient, as well as the miscarriage rate (8% vs. 14%) between the two populations studied. In addition, there was no significant difference in full term (86.7 vs. 80.8%), preterm (13.3% vs. 19.2%), or severe preterm (3.3% vs. 11.5%) birth rates, and mean gestational age (38.1 ± 2.3 vs. 37.6 ± 4.5) in singleton pregnancies in patients with arcuate and septate uterus respectively. Furthermore, there was also no significant difference when the rates of full term (21.4% vs. 26.3%), preterm (78.6 vs. 73.7%) and

severe preterm (28.6% vs. 0%) birth rate and mean gestational age (34.2 ± 3.7 vs. 35.8 ± 1.4) in twins and higher order pregnancies in patients with arcuate and subseptate uterus respectively.

Discussion

Uterine septum accounts for 34%-48% of structural uterine anomaly (Pabuccu et al., 2004; Tonguc et al., 2011; Homer et al., 2000). It is also the Müllerian anomaly associated with the highest rate of adverse pregnancy outcomes (Pabuccu et al., 2004; Tonguc



Mean gestational age, group 1: 35.1 ± 2.7 .
 Mean gestational age, group 2: 35.2 ± 3.8 .
 *P-value = 0.004.
 ** ≤ 32 week gestation.

Fig. 1. — Incidence of preterm, severe preterm and mean gestational age in twin birth.

et al., 2011; Grimbizis et al., 1998; Homer et al., 2000). Hysteroscopic septoplasty has been shown to be associated with marked improvement in reproductive outcome in patients with history of RPL, although there are no prospective randomized trials to confirm such findings.

The issue of uterine septum and infertility remains controversial and the data available on this topic is limited. Although some investigators advocate hysteroscopic septoplasty for treatment of infertility patients with uterine septum (Mencaglia and Tantini, 1996; Pabuccu et al., 1995), others do not (Grimbizis et al., 1998; Corson, 1992). In addition, the role of hysteroscopic septoplasty in patients with primary infertility remains controversial. Some investigators recommend treatment (Tonguc et al., 2011; Doridot et al., 2003), while others do not (Homer et al., 2000). Some authors argue that the treatment is worth considering, especially in patients undergoing ART (Mollo et al., 2009; Bendifallah et al., 2013; Ozgur et al., 2007; Ban-Franchez et al., 2009; Homer et al., 2000), because of possible beneficial effects on fecundity and the potential benefits of reduced rates of miscarriage and preterm labour if these women conceive. For the same reasons some authorities recommend hysteroscopic septoplasty in patients with long duration of infertility (Fedele et al., 1993), advanced female reproductive age (Choe and Baggish, 1992), and if the patient is undergoing laparoscopy and hysteroscopy as a part of her infertility work up (Homer et al., 2000; Valle and Sciarra, 1986). Currently there is no published prospective randomized, controlled trial on this topic.

For the last 20 years we advocated the use of hysteroscopic septoplasty for uterine septum and arcuate uterine anomaly in patients with both primary and secondary infertility prior to any infertility treatment in general and IVF-ET in particular because of the above mentioned potential benefits. In this study we report the reproductive outcome in a large group of patients with primary infertility who underwent hysteroscopic septoplasty prior to IVF-ET and compared the results to those of patients who had normal endometrial cavity. The data in our study suggest that hysteroscopic septoplasty in patients with primary infertility is beneficial prior to IVF-ET. In addition, based on the results of full term, preterm and severe preterm birth rates and mean gestational age in singleton pregnancy, again, it appears that the surgery is of benefit with respect obstetric outcome. The situation was different in multiple pregnancies which appear to increase the risk of preterm birth in these patients. Multiple pregnancies may have a negative impact on the likelihood of full term birth. Therefore, every

effort should be made to achieve a singleton pregnancy in these patients. In addition, if multiple pregnancies occur in such patients, they may benefit from referral and joint care with a high-risk pregnancy specialist.

Few earlier studies reported on pregnancy, delivery, and miscarriage rates after hysteroscopic septoplasty in women with primary infertility (Pabuccu et al., 2004; Homer et al., 2000). Grimbizis et al. (1998) found that patients with primary infertility and untreated uterine malformations had similar chances of conception to the general infertile population, but had poorer pregnancy outcomes (Grimbizis et al., 1998). They suggested that hysteroscopic metroplasty should not be indicated for the enhancement of the fertility potential of infertile patients, but rather to improve their pregnancy outcomes (Grimbizis et al., 1998). Recently, some reports challenged the above-mentioned opinion by Grimbizis et al. (1998). Mollo et al. (2009), Tonguc et al. (2011) and other investigators reported favourable reproductive outcomes in infertile patients after hysteroscopic septoplasty (Shokeir et al., 2011; Mollo et al., 2009; Tonguc et al., 2011; Saygili-Yilmaz et al., 2002; Nouri et al., 2010).

Earlier literature provides conflicting opinions regarding the value of septoplasty in infertile patients prior to IVF treatment. Marcus et al. (1996) reported no difference in pregnancy results between patients with uterine septum and general sterile population undergoing IVF treatment (Marcus et al., 1996). In contrast, Lavergne et al. (1996) reported poor implantation and pregnancy rates after IVF treatment in infertile patients with untreated uterine malformation compared to the general infertile population (Lavergne et al., 1996). A few recent studies addressed the effect of hysteroscopic septoplasty on ART results. In a retrospective matched-control study to evaluate the effect of uterine anomalies on pregnancy and delivery rates after 2481 embryo transfers in IVF/ICSI cycles, Tomazevic et al. (2010) concluded that pregnancy and delivery rates after embryo transfer before hysteroscopic metroplasty were significantly lower, both in women with subseptate/septate uterus (12.4% and 2.7%) and in women with arcuate uterus (13.6% and 2.8%) compared with controls (29.2% and 21.7%) and (25.6% and 21.3%) respectively. After hysteroscopic metroplasty, the differences in pregnancy and delivery rates disappeared being 22.9% and 15.6% in women with history of subseptate/septate uterus compared to 26.6% and 20.9% for the controls and 25.9% and 18.6% in women with history of arcuate uterus compared with 27.6% and 21.9% for controls (Tomazevic et

al., 2010). In a retrospective matched control study, Ban-Frangez et al. (2009) compared the miscarriage rate after IVF/ICSI in a study group of 31 patients who conceived before hysteroscopic resection and 106 patients who conceived after hysteroscopic resection to a control group of 274 patients (Ban-Frangez et al., 2009). They concluded that, similar to a large uterine septum, a small partial uterine septum is an important and hysteroscopically preventable risk factor for spontaneous abortion in pregnancies after IVF and ICSI. Ozgur et al. (2007), in a retrospective matched control study, reported a clinical pregnancy (47.8 vs. 46.3%) and a pregnancy loss (10.5 vs. 20.3%) in the study and control groups respectively (Ozgur et al., 2007). The authors concluded that hysteroscopic septoplasty improves reproductive outcome after ART. The design and conclusion of this study are similar to our study except for the fact that the patients in the control group of Ozgur et al. were determined to have normal endometrial cavity on the basis of sonohysterogram and not on hysteroscopy as in our study. Many other studies reported ART results as part of reporting on reproductive outcomes after different infertility treatment or for treatment of recurrent pregnancy loss. Abuzeid et al. (2007) in a retrospective observational study of 54 patients, who underwent ART, reported a pregnancy rate of 85%, delivery rate of 67%, and miscarriage rate of 20% (Abuzeid et al., 2007). Bendifallah et al. (2013) reported that of 47 patients with primary infertility, 25 had full term birth, 27.7% conceived after ART, with no miscarriages (Bendifallah et al., 2013). These authors and others (Shokeir et al., 2011; Grimbizis et al., 1998; Blanc et al., 1998; Doridot et al., 2003) proposed prophylactic hysteroscopic resection in patients in whom IVF was indicated.

The current classification of Müllerian anomalies (ASRM, 1988; Oppelt et al., 2005) does not provide a specific and clear diagnostic criteria, description, or parameters to distinguish arcuate uterine anomaly (ASF Class VI) from an incomplete uterine septum (ASF Class Vb). Lin (2004) considered the uterine anomaly as arcuate if the endocavitary length of the midline depression was < 1 cm, while it was considered an incomplete uterine septum if the endocavitary length of the midline depression involved one third of the uterine cavity (Lin, 2004). More recently, a new classification for Müllerian anomalies has been proposed by the European Society of Human Reproduction and Embryology (ESHRE) and the European Society of Gynecologic Endoscopy (ESGE), in which arcuate uterine anomaly as a separate entity was eliminated (Grimbizis et al., 2013). As mentioned in the

materials and methods section, for the purpose of this study we defined arcuate anomaly according to AFS description (wide based and a convex apex) if the endocavitary length of the midline depression was ≥ 1 cm (Abuzeid et al., 2007). In our study we found no difference in the reproductive outcome after hysteroscopic septoplasty in patients with incomplete uterine septum and arcuate anomaly who underwent ART treatment. However, the effects of arcuate anomaly on reproductive outcome are not adequately evaluated. The majority of the available data suggest no effect on reproductive outcome (Grimbizis et al., 2001; Raga et al., 1997; Rackow and Arici, 2007; Troiano and McCarthy, 2004; Woelfer et al., 2001; Lin, 2004; Lin et al., 2002; Tulandi et al., 1980). Only a few studies have suggested an association of the arcuate anomaly to poor reproductive outcomes, such as higher pregnancy loss rate and lower term delivery rate (Grimbizis et al., 2001; Woelfer et al., 2001; Zlopasa et al., 2007). In a recent study, Giacomucci et al. (2011) reported marked improvement in term delivery rate (from 6% to 55.6%) after hysteroscopic surgical correction of arcuate anomaly in 81 patients presenting with recurrent pregnancy loss (Giacomucci et al., 2011). Similarly, Bendifallah et al. (2013) reported marked improvement in full term birth (11.5% to 59.6%) and reduction of miscarriage rate (46.1% to 9.6%) after hysteroscopic septoplasty in 52 patients with arcuate anomaly (Bendifallah et al., 2013). Lin (2004) and Mucowski et al. (2010) suggested that the lack of standardized diagnostic criteria distinguishing the arcuate uterus from incomplete septum may have accounted for the discrepancies in the effect of arcuate anomaly on reproductive outcome.

Our study has some limitations. The study is retrospective in nature. In addition, the role of confounders and risk of bias as an alternative explanation for the study results and conclusion should be taken in consideration. There were some statistically significant differences between the two groups studied in the duration of infertility and incidence of some of the underlying aetiology, namely a higher incidence of endometriosis and tubal factor in Group 2. Based on logistic regression, the underlying aetiology appears not to have an effect on clinical pregnancy rate or delivery rate per patient but the duration of infertility was significant. Also, the study represents the experience in one unit. On the other hand, our study has some strength. It is the largest study so far addressing the topic of reproductive outcome in patients with primary infertility who underwent hysteroscopic septoplasty before IVF-ET treatment. Furthermore, the study was conducted in one practice and one IVF

laboratory, thus reducing possible confounding factors.

Conclusion

Reproductive outcome of IVF-ET after hysteroscopic correction of incomplete uterine septum/arcuate uterine anomaly in women with primary infertility is not different from women with normal uterine cavity. Multiple pregnancies may have a negative impact on the likelihood of a full term pregnancy; therefore, every effort should be made to achieve a singleton pregnancy in these patients. The reproductive outcome after IVF-ET was similar after hysteroscopic surgical correction, irrespective of the type of the uterine anomaly (septum versus arcuate). However, a prospective randomized trial is needed to compare IVF outcome in patients with such uterine anomaly after surgical correction versus those without surgical correction. We believe that such prospective randomized trial should be multicentre in nature in order to have the required number of patients in a short period of time.

Acknowledgements

The authors would like to thank Cheryl Anderson (Administrative assistant secretary), for her assistance in the preparation of this manuscript, and Jenny LaChance (Master of Science) for her assistance with statistical analyses for this manuscript.

References

- Abuzeid MI, Imam M, Sakel K, Mitwally M et al. Reproductive Outcome after hysteroscopic metroplasty in women with primary infertility. *Fertil Steril.* 2007;88:Suppl. 1, S108-109.
- American Fertility Society. The American Fertility Society classifications of adnexal adhesions, distal tubal occlusion, tubal occlusion secondary to tubal ligation, tubal pregnancies, müllerian anomalies and intrauterine adhesions. *Fertil Steril.* 1988;49:944-55.
- American Society for Reproductive Medicine, 1996. Revised American Society for Reproductive Medicine classification of endometriosis. *Fertil Steril.* 1997;67:817-21.
- Ban-Frangez H, Tomazevic T, Virant-Klun I et al. The outcome of singleton pregnancies after IVF/ICSI in women before and after hysteroscopic resection of a uterine septum compared to normal controls. *Eur J Obstet Gynecol Reprod Biol.* 2009;146(2):184-7.
- Bendifallah S, Faivre E, Legendre G et al. Metroplasty for AFS Class V and VI Septate Uterus in Patients With Infertility or Miscarriage: Reproductive Outcomes Study. *J Minim Invasive Gynecol.* 2013;20:178-84.
- Blanc B, Cravello L, Porcu G et al. Surgical hysteroscopy in the treatment of septate uterus: systemic treatment or selective indications. *Bull Acad Natl Med.* 1998;182:251-61.
- Buttram VC Jr, Gibbons WE. Mullerian anomalies: a proposed classification (an analysis of 144 cases). *Fertil Steril.* 1979;32:40-8.
- Choe KJ, Baggish SM. Hysteroscopic treatment of septate uterus with Neodymium-YAG laser. *Fertil Steril.* 1992; 57:81-4.
- Corson SL. Operative hysteroscopy for infertility. *Clin Obstet Gynecol.* 1992;35(2):229-41.
- Dicker D, Ashkenazi J, Dekel A et al. The value of hysteroscopic evaluation in patients with preclinical in-vitro fertilization abortions. *Hum Reprod.* 1996;11:730-1.
- Doridot V, Gervaise A, Taylor S et al. Obstetric outcome after endoscopic transection of the uterine septum. *J Am Assoc Gynecol Laparosc.* 2003;10:271-5.
- Fedele L, Arcaini L, Parazzini F et al. Reproductive prognosis after hysteroscopic metroplasty in 102 women: life-table analysis. *Fertil Steril.* 1993;59:768-72.
- Gardner D, Surrey E, Minjarez D et al. Single blastocyst transfer: a prospective randomized trial. *Fertil Steril.* 2004;81:551-5.
- Giacomucci E, Bellavia E, Sandri F et al. Term delivery rate after hysteroscopic metroplasty in patients with recurrent spontaneous abortion and T-shaped, arcuate and septate uterus. *Gynecol Obstet Invest.* 2011;71:183-8.
- Grimbizis GF, Gordts S, Di Spiezo Sardo A et al. The ESHRE/ESGE consensus on the classification of female genital tract congenital anomalies. *Hum Reprod.* 2013; 28:2032-44.
- Grimbizis GF, Camus M, Tarlatzis BC et al. Clinical implications of uterine malformations and hysteroscopic treatment results. *Hum Reprod Update.* 2001;7:161-74.
- Grimbizis G, Camus M, Clasen K et al. Hysteroscopic septum resection in patients with recurrent abortions or infertility. *Hum Reprod.* 1998;13:1188-93.
- Heinonen PK. Complete septate uterus with longitudinal vaginal septum. *Fertil Steril.* 2006;85:700-5.
- Homer HA, Li TC, Cooke I. The septate uterus: a review of management and reproductive outcome. *Fertil Steril.* 2000; 73:1-14.
- Khan I, Staessen C, Devroey P et al. Human serum albumin versus serum: a comparative study on embryo transfer medium. *Fertil Steril.* 1991;56:98-101.
- Lavergne N, Aristizabal J, Zarka V et al. Uterine anomalies and in vitro fertilization: what are the results? *Eur J Obstet Gynecol Reprod Biol.* 1996;68:29-34.
- Lin P. Reproductive Outcomes in Women with Uterine Anomalies. *J Womens Health (Larchmt).* 2004;13: 33-9.
- Lin PC, Bhatnagar KP, Nettleton GS et al. Female genital anomalies affecting reproduction. *Fertil Steril.* 2002;78:899-915.
- Marcus S, al-Shawaf T, Brinsden P. The obstetric outcome of in vitro fertilization and embryo transfer in women with congenital uterine malformation. *Am J Obstet Gynecol.* 1996;175:85-9.
- Mencaglia L, Tantini C. Hysteroscopic treatment of septate and arcuate uterus. *Gynaecol Endosc.* 1996; 5:151-4.
- Mitwally MFM, Abuzeid M. Operative Hysteroscopy for Uterine Septum. In: Rizk BRM, Garcia-Velasco JA, Sallam HN, Nakrigiannakis A. eds. *Textbook of Infertility and Assisted Reproduction. Infertility Evaluation and Treatment. Part II.* Cambridge: Cambridge University Press, 2008: Chapter 13, 115-31.
- Mollo A, De Franciscis P, Colacurci N et al. Hysteroscopic resection of the septum improves the pregnancy rate of women with unexplained infertility: a prospective controlled trial. *Fertil Steril.* 2009;91:2628-31.
- Mucowski SJ, Herndon CN, Rosen MP. The Arcuate Uterine Anomaly: A Critical Appraisal of Its Diagnostic and Clinical Relevance. *Obstet Gynecol Surv.* 2010; 65:449-54.
- Nouri K, Ott J, Huber JC et al. Reproductive outcome after hysteroscopic septoplasty in patients with septate uterus: a retrospective cohort study and systematic review of the literature. *Reprod Biol Endocrinol.* 2010;8:52.
- Oppelt P, Renner SP, Brucker S et al. The VCUAM (Vagina Cervix Uterus Adnex-associated Malformation) classifica-

- tion: a new classification for genital malformations. *Fertil Steril*. 2005;84:1493-7.
- Ozgun K, Isikoglu M, Donmez L et al. Is hysteroscopic correction of an incomplete uterine septum justified prior to IVF? *Reprod Biomed Online*. 2007;14:335-40.
- Pabuccu R, Gomel V. Reproductive outcome after hysteroscopic metroplasty in women with septate uterus and otherwise unexplained infertility. *Fertil Steril*. 2004;81:1675-8.
- Pabuccu R, Atay V, Urman B et al. Hysteroscopic treatment of septate uterus. *Gynaecol Endosc*. 1995;4:213-5.
- Rackow BW, Arici A. Reproductive performance of women with mullerian anomalies. *Curr Opin Obstet Gynecol*. 2007;19:229-37.
- Raga F, Bauset C, Remohi J et al. Reproductive impact of congenital Mullerian anomalies. *Hum Reprod*. 1997;12(10):2277-81.
- Saygili-Yilmaz ES, Erman-Akar M, Yilmaz Z. A retrospective study on the reproductive outcome of the septate uterus corrected by hysteroscopic metroplasty. *Int J Gynecol Obstet*. 2002;78:59-60.
- Shokeir T, Abdelshaheed M, El-Shafie M et al. Determinants of fertility and reproductive success after hysteroscopic septoplasty for women with unexplained primary infertility: a prospective analysis of 88 cases. *Eur J Obstet Gynecol Reprod Biol*. 2011;155:54-7.
- Tomazevic T, Ban-Frangez H, Ribic-Pucelj M et al. Small uterine septum is an important risk variable for preterm birth. *Eur J Obstet Gynecol Reprod Biol*. 2007;135:154-7.
- Tomazevic T, Ban-Frangez H, Virant-Klun I et al. Septate, subseptate and arcuate uterus decrease pregnancy and live birth rates in IVF/ICSI. *Reprod BioMed Online*. 2010;21:700-5.
- Tonguc EA, Var T, Batioglu S. Hysteroscopic metroplasty in patients with a uterine septum and otherwise unexplained infertility. *Int J Gynecol Obstet*. 2011;113:128-30.
- Troiano RN, McCarthy SM. Mullerian duct anomalies: Imaging and clinical issues. *Radiology*. 2004;233:19-34.
- Tulandi T, Arronet GH, McInnes RA. Arcuate and bicornuate uterine anomalies and infertility. *Fertil Steril*. 1980;34:362-4.
- Valle RF, Sciarra JJ. Hysteroscopic treatment of the septate uterus. *Obstet Gynecol*. 1986; 67:253-7.
- Van Royen E, Mangelschots K, Vercruyssen M et al. Multinucleation in cleavage stage embryos. *Hum Reprod*. 2003;18:1062-9.
- Woelfer B, Salim R, Banerjee S et al. Reproductive outcomes in women with congenital uterine anomalies detected by three-dimensional ultrasound screening. *Obstet Gynecol*. 2001;98:1099-1103.
- Zlopasa G, Skrablin S, Kalafatic D et al. Uterine anomalies and pregnancy outcome following resectoscope metroplasty. *Int J Gynaecol Obstet*. 2007;98:129-33.