

Laparoscopic Sacrocolpopexy

S. MANODORO^{1,2}, E. WERBROUCK^{1,+}, J. VELDMAN¹, K. HAEST^{1,3}, R. CORONA¹, F. CLAERHOUT^{1,*}, G. COREMANS¹, D. DE RIDDER¹, F. SPELZINI², J. DEPREST¹

¹ Pelvic Floor Unit, University Hospitals, Katholieke Universiteit Leuven, Leuven, Belgium;

² Department of Obstetrics and Gynecology, San Gerardo Hospital, Monza, University of Milan-Bicocca, Milan, Italy;

³ Vie Curie, Venlo, The Netherlands;

⁺ Currently at the Department of Obstetrics and Gynaecology, AZ Sint Jozef, Izegem, Belgium;

^{*} Currently at the Bekkenbodemklinik, AZ Sint Lucas, Brugge, Belgium.

Correspondence at: Jan Deprest, Pelvic Floor Unit, UZ Gasthuisberg, Herestraat 49, Leuven 3000, Belgium.
Email: jan.deprest@uzleuven.be; Tel: +3216344215; Fax: +3216344205

Abstract

Laparoscopy offers great exposure and surgical detail, reduces blood loss and the need for excessive abdominal packing and bowel manipulation making it an excellent modality to perform pelvic floor surgery. Laparoscopic repair of level I or apical vaginal prolapse may be challenging, due to the need for extensive dissection and advanced suturing skills. However, it offers the efficacy of open abdominal sacrocolpopexy, such as lower recurrence rates and less dyspareunia than sacrospinous fixation, as well as the reduced morbidity of a laparoscopic approach.

Key words: Colposuspension, sacrocolpopexy, laparoscopy, mesh, graft related complications, learning curve.

Introduction

Laparoscopy may yield better exposure and surgical detail, reduce blood loss and the need for excessive abdominal packing and bowel manipulation, which all may lead to a lesser morbidity (Garry, 2004). Laparoscopy has gradually found its way in the field of urogynaecology, but scientific validation of this approach has long-time been poor. Recently laparoscopic colposuspension was shown to be equally effective as an open procedure at 2 years follow-up (Tan *et al.*, 2007). Today, the procedure may be less practiced since the transvaginal tension free tape (TVT) procedure was shown to be equally effective as open colposuspension and being even lesser invasive and less expensive. It has therefore become the gold standard for treating stress urinary incontinence, leaving laparoscopic colposuspension in our unit a procedure being offered only to patients that undergo simultaneously other procedures by laparoscopy.

Nevertheless, other urogynaecologic procedures may still benefit from an abdominal approach. Sur-

gical repair of level I or apical vaginal defects, that also preserves vaginal function, can be performed either vaginally or through abdominal approach (De Lancey, 1992). Randomized trials, however, have shown that sacrocolpopexy offers lower recurrence rates and less dyspareunia than sacrospinous fixation, but at the expense of a longer recovery time (Maher *et al.*, 2007). Logically, a laparoscopic modification towards sacrocolpopexy (LSC) may reduce the morbidity of the latter. However, LSC was embraced later than colposuspension, probably because vault prolapse occurs more rarely and LSC needs extensive dissection and advanced suturing skills, limiting this as a procedure within reach of the general gynaecologist or urologist (Nezhat, 1994).

Level I defects

The support of the cervix, and in its absence, the apex of the vagina is provided by vertical orientated fibres that have a broad origin at the sacrum and lateral pelvic wall. These structures are better known as the utero-sacral and cardinal ligaments, described

by DeLancey as Level I support (1992). When these fail, uterine or vaginal vault prolapse occurs. Loss of apical support is associated with concomitant defects of the anterior or posterior wall in 67-100% of cases (DeLancey, 1992; Shull, 1999).

The leading risk factor to develop post-hysterectomy vault prolapse is the prior presence of uterine prolapse at the time of hysterectomy. The prevalence of vault prolapse in women with prior hysterectomy because of prolapse is as high as 11.6%, whereas it is only 1.8% when the hysterectomy was done for another reason (Marchionni *et al.*, 1999); overall incidence 4.4%. Other risk factors for vaginal vault prolapse include more generic causes, such as chronic pulmonary disease, but not obesity (Dällenbach *et al.*, 2008; Blandon *et al.*, 2009). Adequate prophylactic suspension of the vault by a proper culdoplasty at the time of hysterectomy prevents the occurrence of post-hysterectomy vault prolapse (Cruikshank *et al.*, 1988).

The clinical presentation of apical prolapse can vary from being asymptomatic to causing a multitude of symptoms. The common denominator is the feeling or seeing of a vaginal lump. Frequently urinary, defaecatory or sexual symptoms may coexist. The prevalence of symptoms of stress urinary incontinence, overactive bladder and voiding dysfunction

vary around 30% for each of them (Maher *et al.*, 2004). One in three patients has constipation and around one in five experiences dyspareunia, although a causal relationship remaining is difficult to explain.

Vault prolapse can be treated by pessaries, however, with limited success. A variety of abdominal and vaginal operations restoring level I support have been described. Vaginal repairs include utero-sacral ligament suspension, ileococcygeal suspension, sacrospinous fixation and infracoccygeal sacropexy. Suspension at the uterosacral ligaments involves suturing of the vaginal vault to the remnants of the utero-sacral ligaments as high as possible (Shull *et al.*, 2000). Abdominal techniques involve utero-sacral ligament suspension (Karram *et al.*, 1999), sacrospinous fixation (Hale *et al.*, 1999) and sacrocolpopexy (Adisson *et al.*, 1985). Historically, these techniques were first described via laparotomy, and only recently laparoscopic modifications were described. In the uterosacral ligament fixation, the apex is suspended by shortening the ligaments with helical sutures. Abdominal sacrocolpopexy involves fixation of the vault to the anterior longitudinal ligament by the interposition of a graft, and historically reports go back as far as the late 19th century, by Freund in 1889 and Kustner in 1890. Cutaneous

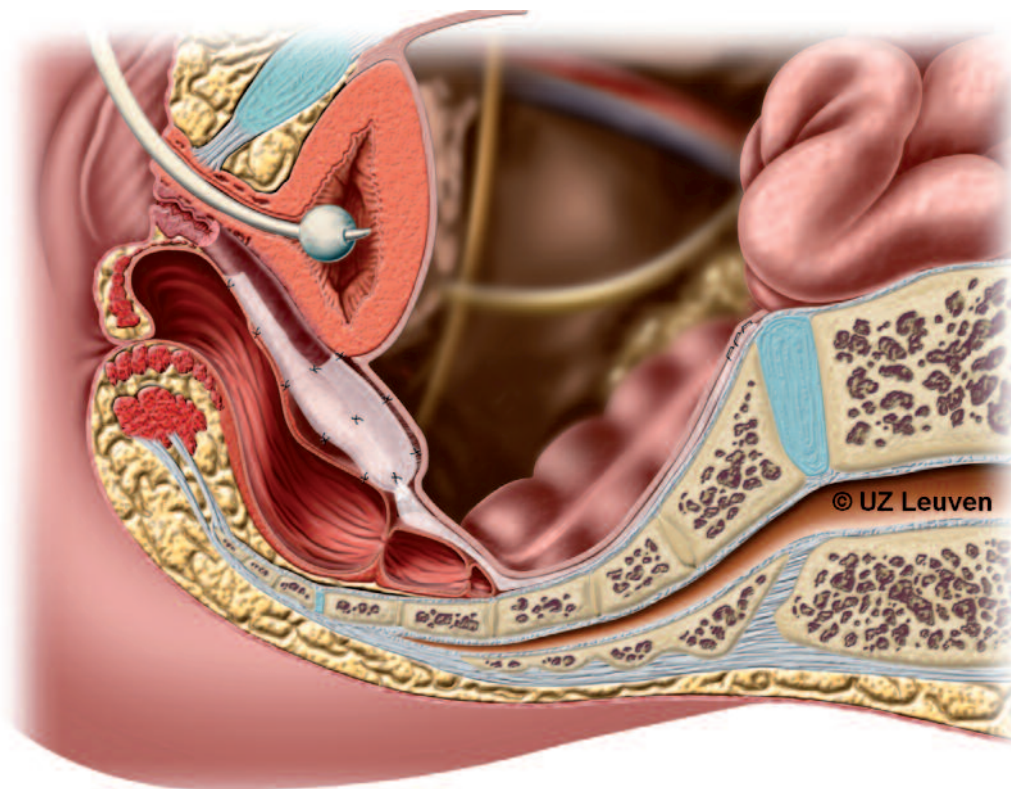


Fig. 1. — Schematic drawing of a sacrocolpoperineopexy. In this case, the posterior implant is extended over the entire posterior wall and sutured at the level of the sphincteric complex. (Courtesy of UZ Leuven and Leuven Academic Press— From: Claerhout F, 2010)⁽¹⁾.

⁽¹⁾ Claerhout F (2010). The introduction of laparoscopy and novel biomatrices for surgical repair of vaginal vault prolapse by sacral colpopexy. Thesis Manuscript. Leuven, Leuven Academic Press, 185 pp, ISBN: 978 90 5867 806 5.

flaps were initially used by Huguier and Scali (1958), and a synthetic graft was first described by Scali (1974).

A Cochrane systematic review concluded that abdominal SC is associated with less recurrence at the vaginal vault (RR 0.23, 95% CI 0.07-0.77) and less dyspareunia (RR 0.39, 95 CI 0.18-0.86) than vaginal sacrospinous fixation (Maher *et al.*, 2007). Conversely, open abdominal sacrocolpopexy was associated with a longer operating time, longer hospital stay and higher cost than vaginal suspension. Logically, laparoscopic sacrocolpopexy (LSC) may reduce these unfavourable aspects.

Technique of laparoscopic sacrocolpopexy

We operate only symptomatic vault prolapse, minimally presenting as stage II prolapse of the apex or upper posterior wall of the vagina according to the Pelvic Organ Prolapse-Quantification system (POP-Q; Bump 1996). In case of associated rectal prolapse, a rectopexy may be performed (Fig. 1). Patient preparation is as for laparoscopic colposuspension, but bowel preparation may be even more important. Good exposure of the promontory is easier with adequate bowel preparation. For this procedure we have been giving both cefazolin (2 g) and metronidazole (1500 mg) prophylaxis. After induction of general anesthesia, the patient is positioned in a modified lithotomy position with access to the vagina and rectum. After disinfection and sterile draping a 3-way Foley catheter is inserted to empty the bladder. The additional channels allow for bladder filling with dyed saline, to detect bladder lesions and/or identify the bladder margins. At least four trocars are necessary: one primary subumbilical 10 mm cannula, two lateral 5 mm trocars and one trocar halfway between the symphysis and the umbilicus. The latter one is used for suturing, and should have leak proof seals; we use Excel trocars for that purpose (Johnson & Johnson).

After careful identification of L5-S1, the inferior limit of the left common iliac vein and the right ureter, the dissection of the promontory is started. First the prevertebral parietal peritoneum is incised with 5-mm monopolar scissors vertically (Ethicon). Retroperitoneal fat is dissected to allow exposure of the anterior vertebral ligament. An area as large as required for fixing the mesh needs to be dissected on the promontory just right from the midline. Pitfalls are the median sacral vessels, or when moving too much laterally of the ureter or to the left the main vessels. Occasionally bipolar forceps is used for that purpose.

The peritoneal incision at the promontory is then extended along the rectosigmoid to continue over the

deepest part of the cul-de-sac, opening the recto- and vesicovaginal space. Some prefer to create a tunnel under the peritoneum, avoiding later suturing. The lateral incision as well as the dissection downward towards the perineal body can be extended as far as required. This is the case when there is a large rectocele or when a concomitant rectopexy is required for rectal prolapse.

At this point in time we change gloves to prevent contamination of the mesh. Two separate meshes are sutured to the posterior and anterior wall of the vagina, using a knot pusher, needle holder and assistant needle holder. As much as possible we try to avoid perforating the vagina while suturing. Because this might not always be avoided, we moved away from braided sutures such as Ethibond, and now use PDS sutures which were made on purpose (Ethicon, 120 cm). Today there are double legged meshes commercially available, such as Y-mesh (AMS) and Alyte (Bard). If not available, one can easily cut a larger mesh to the appropriate size, e.g. Gynaemesh M implants (Ethicon). The posterior mesh can be fixed as laterally as the levator muscle. There is neither agreement on the size of the meshes used nor on the number of sutures required for this operation, but usually we place between 9 and 16 sutures. One may need to palpate the rectum and vagina to define their borders. Once this is finished, the vault is positioned by the rectal pusher (placed in the vagina) at the level of the ischial spines and then fixed in a tension-free position. We use either staples or tackers to fix the mesh to the promontory; however, sutures can be used as well. It is at this time that one needs to be alert to avoid haemorrhage from the presacral vessels. We then close the peritoneum with both a running suture and the staples left over from the sacral fixation. This will avoid adhesions to the mesh. At the end of the procedure we pack the vagina.

We remove the vaginal packing and urinary catheter after 48 hours. Postoperatively, low molecular weight heparin injections as well as a stool softener macrogol 3.350 13.25 g (Movicol, Norgine) are continued for 6 postoperative weeks to prevent heavy pushing. Also sexual inactivity is recommended until the 3 month postop visit. All these measures were empirically determined.

In patients with uterine prolapse a laparoscopic supracervical hysterectomy can be performed. This avoids opening of the vagina and might decrease the risk of erosion (Visco *et al.*, 2001). In patients choosing to conserve the uterus, a hysteropexy is performed instead (Krause *et al.*, 2006). One method is to place a mesh both anteriorly and posteriorly, and connect at the posterior aspect of the cervix, after passing it through the ligamentum latum.

At the promontory, large vessel or venous injury should be avoided. During dissection of the vesicovaginal space haemorrhage or a bladder lesion can occur. Ureteric lesions are uncommon, but may occur when the dissection is performed too laterally.

Dissection of the rectovaginal space may lead to haemorrhage and rectal injury. Appropriate traction and dissection close to the vagina may reduce the risk. Also the use of a rectal probe helps identifying these structures.

Postoperative wound infections are rare. De novo stress incontinence may be the result of excessive correction and traction backwards, opening the urethrovesical angle. De novo urge and urge incontinence may occur but its course is relatively unpredictable.

The use of a mesh, which is a foreign body, can lead to graft related complications (GRC). Pain or dyspareunia related to the mesh can occur. Exposure of suture material or mesh erosions (< 6%) may occur and may require re-intervention. Infections of the mesh, leading to sepsis or spondylodiscitis are rare but feared complications. Intravenous antibiotics are started and re-intervention with removal of the infected mesh may be required. Constipation may be due to extensive dissection or damage of the sacral plexus, but the majority of patients suffer from constipation already before the operation.

Experience with laparoscopic sacrocolpopexy

We recently reported our prospective experience with all consecutive LSC beyond our learning curve (Claerhout *et al.*, 2009) (Table 1, Table 2). LSC was introduced in our unit in 1996. Since then, laparoscopy was used as the primary access route. In order to avoid an effect on outcome of the inherent learning process we used the cumulative sum analysis (CUSUM) method to determine the learning curve (Ramsay *et al.*, 2002). Based on a 90% rate of avoiding conversion to laparotomy or occurrence of perioperative complications, our prior learning curve was set at 60 cases. Later cases (> 61) were included in a prospective consecutive series of 132 women.

Table 1. — Perioperative characteristics and complications in a prospective series of 132 LSC (Claerhout *et al.*, 2009).

	Mean or n	SD or %
Operation time (min)	180.5	(46)
Blood loss (mL)	185	(124)
Inpatient days (days)	5.7	(1.9)
Conversion	1	(0.7)
Completely by laparoscopy	131	(99)
<i>Per-operative complications</i>	0	(0)
<i>Complications in the early post-operative (<6w) period</i>		
Bleeding	1	(0.75)
Nerve lesions	3	(2.3)
Local problems	2	(1.5)
<i>Complications in the late postoperative period (6 wks to 59 months)</i>		
Reintervention related to the mesh	9	(6.8)
Mesh erosion	6	(4.5)
Pain related to mesh	3	(2.3)
Reintervention for genital prolapse	0	(0)

They all had vaginal vault prolapse, presenting as stage II apical prolapse. They underwent LSC using a Amid type I polypropylene implant over a 5 year-period and were prospectively followed up by a standardized protocol to determine anatomical cure (\leq POP-Q Stage I), subjective cure and impact on quality of life, as measured by a standardized interview and a prolapse-specific questionnaire (P-QOL) before and after the operation (Digesu *et al.*, 2005; Claerhout *et al.*, 2010). The standardized interview consists of 28 questions related to prolapse, bladder, bowel and sexual function. P-QOL assesses the impact of prolapse on 9 different quality of life domains with scores for each domain, ranging between 0 and 100. Postoperative assessment was done after 3, 6 and 12 months and annually thereafter by a single independent assessor. De novo symptoms were defined as symptoms that were not present before surgery but that were present at the 3 months visit. At study-closure all patients were asked to complete the P-QOL. If patients did not attend their planned

Table 2. — Anatomical findings prior to, 3 months after surgery and at study closure in a prospective series of 132 LSC (Claerhout *et al.*, 2009).

<i>POP-Q</i> ¹	Preoperative		3m		Study closure	
Number of patients at each time point	132		132		99	
POPQ \geq -1 at any compartment	132	(100)	7	(5.3)	22	(22)
POPQ point Ba \geq -1	72	(54.5)	1	(0.8)	3	(3)
POPQ point C \geq -1	87	(66)	0	(0)	2	(2)
POPQ point Bp \geq -1	124	(94)	6	(4.5)	18	(18)

follow-up visits, they were phoned to come for clinical assessment and if that was not possible, a telephone interview was undertaken to document the functional outcome. Women reporting “never” or “rarely” prolapse symptoms (questions 1,2 or 3 of the standardized interview) were classified as subjectively cured.

Our operation time was over 180 min (including other procedures), 20 min longer than in the literature review of Ganatra *et al.* (2009). Our reoperation rate for prolapse was 2.3% (vs. 6.2%), while the erosion rate was 2.3%, similar to what Ganatra *et al.* reported in their review (2009). Hospital stay was relatively long for a laparoscopic procedure, but to us this has several reasons. First, we do offer this procedure without any upper age limit, and the elder population is reluctant to be discharged too early. Second, patients are admitted a day prior to the procedure. Third, there is no financial incentive in Belgium for an early discharge, because of the public health system.

Literature on laparoscopic sacrocolpopexy.

Data on LSC initially were limited to retrospective studies of variable size (Cosson *et al.*, 2002; Elliot *et al.*, 2005; Antiphon *et al.*, 2004; Gadonneix *et al.*, 2004; Rozet *et al.*, 2005; Higgs, 2005; Paraiso *et al.*, 2005; Rivoire *et al.*, 2007; Argawala, 2007). They covered issues such as peri-operative parameters, reported short term results and were usually retrospective in design. In the largest retrospective study (n = 363) anatomical cure rate was 96% at a mean follow up of 14.6 months (Rozet *et al.*, 2005). Higgs observed on a longer term 8% recurrences at the level of the vault, but over one in three recurrences in the anterior or posterior compartment. The overall re-operation rate for prolapse was 16% (Higgs, 2005).

The number of prospective studies is limited. North *et al.* reported on the 2-year outcome in 22 women. Although excellent vault support was reported, recurrence in the anterior (n = 5) and posterior (n = 12) were unacceptably high. There was one case of exposure of the mesh at the level of the vault. Price *et al.* reported on the effects of laparoscopic sacrocolpopexy on female sexual function (n = 84). Overall sexual function was improved with a low rate of de novo postoperative dyspareunia (8%) despite 5 exposures (1 of the mesh and 4 suture material) (Price *et al.*, 2010).

In the more recent literature, a number of studies have looked at larger numbers and longer term outcomes. Granese *et al.* reported results on 165 procedures with a mean follow up of 43 months. The success rate was 94.9%. Sabbagh *et al.* analyzed

anatomical and functional outcomes of 186 women at a mean follow up of 60 months. Anatomical success rate was 92.4% and functional cure rate was 95%. Of note is that in both series morbidities were comparable to what was earlier published. In the latter study the vaginal mesh exposure rate was 3.8%.

Finally, Ganatra *et al.* (2009) analyzed 11 series with a mean follow-up of 24.6 months (range: 11.4-66 months). Mean operative time was 158 min (range: 96-286 min) with a 2.7% conversion rate (range: 0-11%) and a 1.6% early reoperation rate (range: 0-3.9%). Overall satisfaction rate was 94.4%, the reoperation rate for prolapse was 6.2% and mesh erosion rate was 2.7%. The objective success rate was 92%. Postoperative urinary dysfunction (urinary urgency, urinary retention or stress incontinence) was as frequent as 17.8% (range: 2.4-44%) and stress incontinence requiring surgery (suburethral sling, bulking-agent injections, bladder-neck procedures) in 42% of cases. Postoperative sexual dysfunction was present in 7.8% of patients (range: 0-47%) but only few series reported sexual function. Bowel postoperative dysfunction occurred in 9.8% (range: 0-25%) of patients, presenting with constipation, anal pain, and one case of fecal incontinence. Most of the bowel symptoms resolved within 6 months.

Overall these studies confirm that laparoscopic sacrocolpopexy is a safe and effective substitute for open sacropexy, with excellent apical support and good functional outcome and limited morbidity.

Choice of the mesh material.

Different types of mesh have been suggested, either xenografts or synthetics. A comprehensive review reported an overall rate of mesh erosion of 3.4% when synthetic permanent materials are used (Nygaard *et al.*, 2004). The nature of the material used has been identified as a risk factor for the occurrence of GRC. For that reason, surgeons have moved away from Type II (microporous – e.g. Expanded PTFE [Gore-tex]) and Type III (macroporous with microporous or multifilamentous components – e.g. Polyethylene tetraphthalate [Mersilene]) because of their increased risk for infection and erosion, and their poor integration into the host. Therefore, type I macroporous polypropylene (PP) grafts are nowadays most frequently used and provide excellent long term anatomical results.

There is also some evidence that synthetic grafts are superior to xenografts. They do not reduce the number of GRC neither are they equally effective in terms of recurrence for this type of prolapse. We conducted a controlled study on a consecutive number of patients that was implanted with xenografts

(Deprest *et al.*, 2009). Anatomical and subjective outcomes were compared to outcomes from consecutive controls operated with a polypropylene mesh either prior to the xenograft cohort, or after (to allow an overall comparable follow up period). After a mean follow up of 33 months, the anatomical failure rate at the level of the vault was significantly higher (21% vs 3%, $p < 0.01$). There were also significantly more posterior compartment (36% vs 19%, $p < 0.05$) prolapses. There was a trend for an increased recurrence at any stage as well. There were also significantly more reoperations for recurrence. Functional outcomes were equal. Though a cross linked (resistant to collagenase) as well as a non-cross linked graft were used, the recurrence rates were similar. We concluded that substitution of polypropylene grafts by xenografts did not yield equally good objective outcomes, neither did they reduce the number of GRC. Though functional outcomes are comparable we moved away from the routine use of xenografts for this operation and hope a more ideal “biological” mesh will be designed.

Learning process

We studied the feasibility and the learning process of LSC by documenting our entire experience, i.e. from the first laparoscopic case onwards (Claerhout *et al.*, 2009). As outcome measures we used a variety of relevant indicators of surgical performance, including the number of laparotomies, complication rate, operation time and anatomical failure. We analysed these by different statistical methods, including “moving average” (MOA) and “cumulative sum” analysis (CUSUM). We demonstrated that LSC can be implemented without increasing the complication rate. We defined the endpoint for the learning curve as the moment that the surgeon was able to complete the procedure by laparoscopy, without complications and with good anatomical outcome in at least 90% of patients. With this as an endpoint the surgeon required 60 cases. This is fairly high and can be explained by the high number of laparotomies in our series. The majority of laparotomies were, however, performed out of precaution: only 2 (6%) were converted for complications. It is possible that this would be less today, since we now have far more background laparoscopy experience than at that time, in 1996.

Operation time can also be used as a sole endpoint. Operation time declined rapidly over the first 30 procedures, declining slower thereafter, to reach a steady state after 90 cases (175 min). This rather long learning curve tickled us to get better insight into the limiting factors or challenging steps of the procedure. To investigate this we studied the

learning curve of a fellow who was familiar with advanced laparoscopic surgery but not LSC. Instead of only focusing on total operation time and complication rate we split the operation empirically into 5 steps: (1) dissection of the promontory, (2) dissection of the right parasigmoidal, para-rectal gutter and the vaginal vault, (3) fixation of the implant to the vault, which involves the placement of several sutures; (4) fixation of the implant to the promontory, (5) reperitonealisation. We analysed for each step the operation time, performance and complication rate. Taking operation time as outcome measure, we found an apparent learning curve for all steps of the procedure, except for the dissection of and fixation to the promontory. The most challenging step was the dissection of the vault. It took the trainee 31 procedures to achieve an operation time that was comparable to that of an experienced surgeon. After a skills lab for suturing, the trainee could suture the implant as fast to the vault as the teacher.

Since then, Akladios *et al.* have analysed the learning curve of a senior urogynecologic surgeon who was initiated into laparoscopic sacrocolpopexy. The mean operative time was of 236.9 minutes, which decreased with a turning point after 18-24 procedures. Anatomical cure rate was 95.8% after a mean of 15.8 months. The authors concluded that despite the learning process they obtained outcomes that were comparable to what is reported in the literature.

Robotic Surgery

Robotic surgery is increasingly being used in gynaecology and urology, and many hospitals have invested into the required hardware. It can also be used to perform LSC (Mottrie *et al.*, 2005). It is possible that, for surgeons not familiar with endoscopic suturing, robotic surgery cuts on their learning process. The associated cost to robotic surgery, however, remains an obstacle for the wider implementation of the operation.

The surgical technique involves 4 to 5 laparoscopic ports: 3 to 4 for the da Vinci robot and 2 for the assistant. Suturing is intra-corporeal. Elliot *et al.* (2006) published an experience in 30 patients. In their initial experience they docked the robot only for the suturing of the mesh, which helped them overcome problems with endoscopic suturing (Di Marco *et al.*, 2004). On average the operation took over 3 hours (range 2.15 to 4.75 hrs). Recurrent grade 3 rectocele developed in 1 patient, 1 had recurrent vault prolapse and 2 had vaginal extrusion of mesh. A smaller series from Kramer (2009) showed similar operation times, also one recurrence on 21 patients, and over half of the patients had

recurrent surgery for prolapse in other compartments. Akl *et al.* published the largest case series to date. Robotic-assisted sacrocolpopexy (RAS) was performed on 80 patients with a mean follow-up of only 4.8 months. The mean operative time was 197 min, but after the first 10 cases, it decreased by 25%. There were 4 conversions (5%). Their results show a short learning curve. Intra-operative complications were comparable to what was earlier reported in open series (5%; 2 cystotomies, 1 bowel lesion and 1 ureter injury). Postoperatively, five (6%) patients developed vaginal mesh exposure, one (1.2%) patient developed a pelvic abscess, and one (1.2%) patient had a postoperative ileus. The follow up period was too short to say something about the anatomical outcome.

Costs of procedures

The cost associated with the use of the daVinci surgical system is a concern. In a small study Patel *et al.* in 2009 demonstrated that the estimated direct cost for RAS was significantly higher than that for the open route, but not different from the laparoscopic one. Judd did a cost-minimization study based on a systematic review of medical literature performed in February 2009, comparing robotic-assisted, laparoscopic and abdominal sacrocolpopexy in 2008 US\$. He used a microcosting approach based on actual costs at Duke University Medical Center, Durham, North Carolina. Without including the purchasing and maintenance costs of the daVinci abdominal sacrocolpopexy was cheapest. RA-sacrocolpopexy was more expensive than either laparoscopic or abdominal sacrocolpopexy. Robotic and laparoscopic sacrocolpopexy become cost-equivalent when robotic operative time would be reduced to 149 min, or if the disposable costs would be reduced from \$3293 to \$2132. Laparoscopic sacrocolpopexy becomes as expensive as abdominal sacrocolpopexy if the length of stay after the abdominal operation would exceed 5.6 days, or if the disposables used would cost less than \$668. Limitations of cost-minimization studies are that the results cannot be extrapolated to other hospitals or health systems, neither does it take into account the effects or benefits to the patient of the different access routes.

Conclusion

Laparoscopic sacrocolpopexy yields equally good objective and subjective cure rates as open surgery. At present there is no randomized controlled trial proving this, but one is under way. Observational

data are however reassuring. Patients benefit from the low peri-operative complications and quick recovery. However, extensive laparoscopic skills are necessary for this type of surgery and the turnover required to become proficient may be a limiting factor to make this operation a reasonable goal for the average gynecologist or urologist. The place for robotic sacrocolpopexy remains to be established.

References

- Addison WA, Livengood CH 3rd, Sutton GP, Parker RT. Abdominal sacral colpopexy with Mersilene mesh in the retroperitoneal position in the management of posthysterectomy vaginal vault prolapse and enterocele. *Am J Obstet Gynecol.* 1985;153(2):140-6.
- Agarwala N, Hasiak N, Shade M. Laparoscopic sacral colpopexy with Gynemesh as graft material – experience and results. *J Minim Invasive Gynecol.* 2007;14:577-83.
- Akl MN, Long JB, Giles AL *et al.* Robotic-assisted sacrocolpopexy: technique and learning curve. *Surg Endosc.* 2009;23:2390-4.
- Akladios CY, Dautun D, Saussine A *et al.* Laparoscopic sacrocolpopexy for female genital organ prolapse: establishment of a learning curve. *Eur J Obst Gyn Reprod Biol.* 2010; 149:218-21.
- Antiphon P, Elard S, Benyoussef A *et al.* Laparoscopic promontory sacral colpopexy: Is the posterior recto-vaginal mesh mandatory. *Eur Urol.* 2004;45:655-61.
- Blandon RE, Bharucha AE, Melton LJ 3rd *et al.* Risk factors for pelvic floor repair after hysterectomy. *Obstet Gynecol.* 2009;113(3):601-8.
- Bump R, Mattiasson A, Bø K *et al.* The standardization of terminology of female pelvic organ prolapse and pelvic dysfunction. *Am J Obstet Gynecol.* 1996;175:10-7.
- Claerhout F. The introduction of laparoscopy and novel biomaterials for surgical repair of vaginal vault prolapse by sacral colpopexy. Thesis Manuscript. Leuven, Leuven Academic Press, ISBN: 978 90 5867 806 5, 2010.
- Claerhout F, De Ridder D, Roovers JP *et al.* Medium-Term Anatomic and Functional Results of Laparoscopic Sacrocolpopexy Beyond the Learning Curve. *Eur Urol.* 2009; 55:1459-67.
- Claerhout F, Lewi P, Verguts J *et al.* Analysis of the learning curve for laparoscopic sacrocolpopexy: identification of challenging steps. *Int Urogynecol J.* 2009;20 (suppl 2): S202-S203 (153).
- Claerhout F, Moons P, Ghesquiere S *et al.* Validity, reliability and responsiveness of a Dutch version of the prolapse quality-of-life questionnaire. *Int Urogynaecol J.* 2010;21:569-78.
- Cosson M, Rajabally R, Bogaert E *et al.* Laparoscopic sacrocolpopexy, hysterectomy and Burch colposuspension: feasibility and short-term complications of 77 procedures. *J Soc Lap Surg.* 2002;6:115-9.
- Cruikshank SH. Preventing posthysterectomy vaginal vault prolapse and enterocele during vaginal hysterectomy. *Am J Obstet Gynecol.* 1987;156(6):1433-40.
- Dällenbach P, Kaelin-Gambirasio I, Jacob S *et al.* Incidence rate and risk factors for vaginal vault prolapse repair after hysterectomy. *Int Urogynecol J Pelvic Floor Dysfunct.* 2008; 19(12):1623-9.
- Dean N, Herbison P, Ellis G *et al.* Laparoscopic colposuspension and tension-free vaginal tape: a systematic review. *BJOG* 2006;113(12):1345-53.
- DeLancey JOL. Anatomic aspects of vaginal eversion after hysterectomy. *Am J Obstet Gynecol.* 1992;166:1717-28.
- Deprest J, De Ridder D, Roovers JP *et al.* Medium term outcome of laparoscopic sacrocolpopexy with xenografts compared to synthetic grafts. *J Urol.* 2009;182(5):2362-8.

- Di Marco DS, Chow GK, Gettman MT *et al.* Robotic-assisted laparoscopic sacrocolpopexy for treatment of vaginal vault prolapse. *Urology*. 2004;63(2):373-6.
- Digesu GA, Khullar V, Cardozo L *et al.* P-QOL: a validated questionnaire to assess the symptoms and quality of life of women with urogenital prolapse. *Int Urogynecol J*. 2005; 6:176-81.
- Elliott DS, Frank I, DiMarco DS *et al.* Gynecologic use of robotically assisted laparoscopy: sacrocolpopexy for the treatment of high-grade vaginal vault prolapse. *Am J Surg*. 2004;188:52S-56S.
- Elliott DS, Krambeck AE, Chow GK. Long-term results of robotic assisted laparoscopic sacrocolpopexy for the treatment of high grade vaginal vault prolapse. *J Urol*. 2006; 176(2):655-9.
- Gadonneix P, Ercoli A, Salet-Lizée D *et al.* Laparoscopic sacrocolpopexy with two separate meshes along the anterior and posterior vaginal walls for multicompartiment pelvic organ prolapse. *J Am Assoc Gynecol Laparosc*. 2004;11:29-35.
- Ganatra AM, Rozet F, Sanchez-Salas R *et al.* The current status of laparoscopic sacrocolpopexy: a review. *Eur Urol*. 2009; 55:1089-105.
- Garry R, Fountain J, Mason S *et al.* The eVALuate study: two parallel randomised trials, one comparing laparoscopic with abdominal hysterectomy, the other comparing laparoscopic with vaginal hysterectomy. *BMJ*. 2004;328:129-36.
- Granese R, Candiani M, Perino A *et al.* Laparoscopic sacrocolpopexy in the treatment of vaginal vault prolapse: 8 years experience. *Eur J Obs Gyn and Reprod Biol* 2009;146:227-31.
- Hale DS, Rogers RM Jr. Abdominal sacrospinous ligament colposuspension. *Obstet Gynecol*. 1999;94(6):1039-41.
- Higgs PJ, Chua HL, Smith ARB. Long term review of laparoscopic sacrocolpopexy. *BJOG*. 2005;112:1134-8.
- Jelovsek JE, Barber MD, Karram MM *et al.* Randomized trial of laparoscopic Burch colposuspension versus tension-free vaginal tape: long term follow up. *BJOG*. 2008;115:219-25.
- Karram MM, Sze EH, Walters MD. Surgical treatment of vaginal vault prolapse. In: Walters MD, Karram MM, editors. *Urogynecology and reconstructive pelvic surgery*; 2nd ed. St. Louis: Mosby; 1999. pp. 235-256.
- Kramer BA, Whelan CM, Powell TM *et al.* Robot-assisted laparoscopic sacrocolpopexy as management for pelvic organ prolapse. *J Endourol*. 2009;23(4):655-8.
- Krause HG, Goh JT, Sloane K *et al.* Laparoscopic sacral suture hysteropexy for uterine prolapse. *Int Urogynecol J Pelvic Floor Dysfunct*. 2006;17(4):378-81.
- Maher C, Baessler K, Glazener CMA *et al.* Surgical management of pelvic organ prolapse in women. *Cochrane Database of Systematic Reviews* 2007, Issue 3. Art. No.: CD004014. DOI: 10.1002/14651858.CD004014.pub3.
- Maher C, Qatawneh A, Baessler K *et al.* Laparoscopic colposuspension or tension-free vaginal tape for recurrent stress urinary incontinence and/or intrinsic sphincter deficiency: a randomized controlled trial. *Neurourol Urodyn*. 2004; 23(5/6):433-4.
- Maher CF, Qatawneh AM, Dwyer PL *et al.* Abdominal sacral colpopexy or vaginal sacrospinous colpopexy for vaginal vault prolapse: a prospective randomized study. *Am J Obstet Gynecol*. 2004;190(1):20-6.
- Marchionni M, Bracco GL, Checcucci V *et al.* True incidence of vaginal vault prolapse. Thirteen years of experience. *J Reprod Med*. 1999;44(8):679-84.
- Mottrie A, Martens P, Bollens R *et al.* Laparoscopic colpopromotofixation. *Aktuelle Urol*. 2005;36(2):157-65.
- Nezhat CH, Nezhat F, Nezhat C. Laparoscopic sacral colpopexy for vaginal vault prolapse. *Obstet Gynecol*. 1994;84: 885-8.
- North CE, Ali-Ross NS, Smith ARB *et al.* A prospective study of laparoscopic sacrocolpopexy for the management of pelvic organ prolapse. *BJOG* 2009;116:1251-1257.
- Nygaard IE, McCreery R, Brubaker L *et al.* for the Pelvic Floor Disorders Network. Abdominal sacrocolpopexy : a comprehensive review. *Obstet Gynecol*. 2004;104:805-23.
- Paraiso MF, Walters M, Karram M *et al.* Laparoscopic Burch colposuspension versus the tension-free vaginal tape procedure: a randomised controlled trial. *Neurourol and Urodyn*. 2004;22(5):487-8.
- Paraiso MF, Walters MD, Rackley RR *et al.* Laparoscopic and abdominal sacral colpopexies: a comparative cohort study. *Am J Obstet Gynecol*. 2005;192:1752-8.
- Patel M, O'Sullivan D, Tulikangas PK. A comparison of costs for abdominal, laparoscopic and robot-assisted sacral colpopexy. *Int Urogynecol J Pelvic Floor Dysfunct*. 2009; 20:223-8.
- Price N, Slack A, Jackson SR. Laparoscopic sacrocolpopexy: an observational study of functional and anatomical outcomes. *Int Urogynecol J Pelvic Floor Dysfunct*. 2011;Jan;22(1):77-82.
- Ramsay CR, Wallace SA, Garthwaite PH *et al.* Assessing the learning curve effect in health technologies. Lessons from the nonclinical literature. *Int J Technol Assess Health Care* 2002;18(1):1-10.
- Rivoire C, Botchorishvili, Canis M *et al.* Complete laparoscopic treatment of genital prolapse with meshes including vaginal promotofixation and anterior repair: a series of 138 patients. *J Minim Invasive Gynecol*. 2007;14:712-8.
- Rozet F, Mandron E, Arroyo C *et al.* Laparoscopic sacral colpopexy approach for genito-urinary prolapse: experience with 363 cases. *Eur Urology*. 2005;47:230-6.
- Sabbagh R, Mandron E, Piussan J *et al.* Long-term anatomical and functional results of laparoscopic promotofixation for pelvic organ prolapse. *BJUI*. 2010;106:861-6.
- Shull BL. Pelvic organ prolapse: Anterior, superior and posterior vaginal segment defects. *Am J Obstet Gynecol*. 1999;181:6-11.
- Shull BL, Bachofen C, Coates KW *et al.* A transvaginal approach to repair of apical and other associated sites of pelvic organ prolapse with uterosacral ligaments. *Am J Obstet Gynecol*. 2000;183(6):1365-73.
- Tan E, Tekkis PP, Cornish J *et al.* Laparoscopic versus open colposuspension for urodynamic stress incontinence. *Neurourol Urodyn*. 2007;26:158-69.
- Visco AJ, Weidner AC, Barber MD *et al.* Vaginal mesh erosion after abdominal sacral colpopexy. *Am J Obstet Gynecol*. 2001;184:297-302.