BEST SELECTED ABSTRACTS ORAL

ESGE35-0588 -
Best Selected Oral 1

Impact of Morphological Characteristics and Severity of Adenomyosis on IVF/ICSI Outcomes: A Systematic Review and Meta-analysis

Anna Ottone[1], Vasileios Sevas[2], Dimitrios Rafail Kalaitzopoulos[3], Michelle Soares[3], Grigoris Grimbizis[4], Nicola Pluchino[2]
[1]Cantonal Hospital of Aarau, Department of Obstetrics & Gynaecology, Aarau, Switzerland
[2]Geneva University Hospitals HUG, Department of Paediatrics- Gynaecology and Obstetrics, Geneva, Switzerland
[3]Universitair Ziekenhuis Brussel, Centre for Reproductive Medicine, Brussels, Belgium
[4]Aristotle University of Thessaloniki, Department of Obstetrics & Gynaecology, Thessaloniki, Greece

Background

Adenomyosis has been associated with impaired reproductive outcomes following assisted reproductive techniques (ART), but its heterogeneous character and presentation limit prognostic assessment. Advances in imaging nowadays allow more detailed phenotyping of adenomyosis. However, the impact of specific phenotypes on IVF/ICSI outcomes remains unclear.

Methods

A systematic review and meta-analysis was conducted following PRISMA guidelines and prospectively registered in PROSPERO (CRD420251163085). PubMed and Cochrane databases were searched up to December 1, 2025. Studies reporting IVF/ICSI outcomes according to imaging characteristics of adenomyosis were included, whereas studies were excluded if they did not specifically involve patients diagnosed with adenomyosis. The primary outcome was live birth rate (LBR); secondary outcomes included clinical pregnancy rate (CPR) and miscarriage rate. Risk of bias was assessed using the QUIPS tool. Random-effects meta-analyses were performed.

Results

10 studies were included in the systematic review. Increased uterine volume was associated with significantly lower LBR (OR 0.66, 95% CI 0.49–0.91) and higher miscarriage rates (OR 2.36, 95% CI 1.38–4.05), with comparable CPR. Diffuse and focal adenomyosis showed comparable outcomes when directly compared. Inner myometrial localisation was associated with significantly lower LBR (OR 0.47, 95% CI 0.34–0.64) and CPR (OR 0.56, 95% CI 0.42–0.74), while miscarriage rates were comparable to outer myometrial disease. The evidence of MRI studies is limited. Sensitivity analysis was performed after excluding high-risk-of-bias studies and confirmed the consistency of findings.

Conclusions

Imaging-defined characteristics of adenomyosis may enable clinically relevant prognostic stratification in women with adenomyosis undergoing IVF/ICSI**.** Importantly, uterine volume, diffuse disease, and inner myometrial involvement are associated with poorer IVF/ICSI outcomes, whereas focal and outer myometrial disease appear to confer a more favourable prognosis. Diagnostic heterogeneity and observer variability limit current evidence, underscoring the need for a standardised, prognostically meaningful classification system to improve research quality and clinical applicability.

ESGE35-0586 -
Best Selected Oral 1

The impact of unilateral endometriomas on ovarian response to stimulation: a systematic review and meta-analysis

Dimitrios Rafail Kalaitzopoulos[1], Maria Zografou[2], Paola Vigano[3], Edgardo Somigliana[3], Noemi Salmeri[4], Nicolas Samartzis[5]
[1]Cantonal Hospital of Schaffhausen, Gynaecology, Schaffhausen, Switzerland
[2]St. Augustinus Krankenhaus- Germany, Gynaecology and Obstetrics, Duren, Germany
[3]Fondazione IRCCS Ca' Granda Ospedale Maggiore Policlinico, Infertility Unit, Milano, Italy
[4]Infertility Unit, Fondazione IRCCS Ca' Granda Ospedale Maggiore Policlinico, Milano, Italy
[5]Cantonal Hospital of Schaffhausen, Gynecology and Obstetrics, Schaffhausen, Switzerland

Background

The impact of ovarian endometrioma on assisted reproductive techniques (ART) remains controversial. The aim of this study was to assess ovarian responsiveness and the reproductive outcomes after IVF/ICSI by comparing the affected and contralateral intact gonads in women with unilateral unoperated endometrioma.

Methods

A systematic search for all eligible studies in the PubMed and Cochrane databases until 1st. of May 2025 was conducted. The main outcome of our study was the number of oocytes retrieved per ovary, while for secondary outcomes we compared the number of MII oocytes, fertilisation rate, the number of embryos formed, the number of good quality embryos and implantation rates between the affected and contralateral ovaries.

Results

2903 studies were identified after the search in PubMed and Cochrane databases, and thirteen observational studies met the inclusion criteria and were included in this systematic review and meta-analysis. The meta-analysis of the number of oocytes retrieved showed comparable results between affected and unaffected ovaries in women with unilateral ovarian endometrioma (MD -0.51, 95% CI -1.20 to 0.18; I^2 = 97%; 12 studies, 644 patients). Similarly, the number of MII oocytes and good quality embryos were comparable between affected and unaffected ovaries (MD -0.60, 95% CI -1.86 to 0.66; I^2 = 81%; 6 studies, 149 patients and MD -0.18, 95% CI -0.53 to 0.18; I^2 = 0%; 3 studies, 74 affected vs. 74 unaffected ovaries, respectively). The implantation rate according to the ovary from which the oocyte was retrieved was also comparable (OR 1.49, 95% CI 0.60 to 3.65; I^2 = 0%; 3 studies, 38 affected vs. 51 unaffected ovaries). Conversely, the number of co-dominant follicles and embryos formed were significantly lower in affected ovaries (MD -0.77, 95% CI -1.50 to -0.04; I^2 = 74%; 6 studies, 319 patients and MD -0.72, 95% CI -1.39 to -0.05; I^2 = 68%; 4 studies, 192 affected vs. 193 unaffected ovaries, respectively). A subgroup analysis revealed that endometriomas larger than 4 cm are associated with a significantly lower number of oocytes retrieved (MD -2.17, 95% CI -2.90 to -1.44; I^2 = 77%; 2 studies, 47 affected vs. 47 unaffected ovaries).

Conclusions

Ovaries affected by unoperated ovarian endometriomas show similar outcomes to unaffected ovaries following controlled ovarian stimulation. However, the size of the endometrioma appears to influence these outcomes. These findings suggest that gynaecologists should carefully consider whether to recommend surgery prior to IVF/ICSI, particularly for small endometriomas, which may not adversely impact ovarian stimulation outcomes.

ESGE35-0581 -
Best Selected Oral 1

Minimally invasive fertility-sparing surgery for paediatric adnexal masses, including adnexal torsion and malignant tumours: a retrospective tertiary-centre cohort study

Agnieszka Kotlarz[1,2,3], *Olga Szymon*[4], *Malgorzata Fryczek*[4], *Joanna Zielinska*[2], *Wojciech Gorecki*[4,5]
[1]*Jagiellonian University- Medical College, Department of Gynaecology and Oncology, Krakow, Poland*
[2]*University Children's Hospital of Krakow, Radiology Department, Krakow, Poland*
[3]*University Hospital in Krakow, Department of Gynaecology and Oncological Gynaecology, Krakow, Poland*
[4]*University Children's Hospital of Krakow, Department of Paediatric Surgery, Krakow, Poland*
[5]*Jagiellonian University Medical College, Clinic of Paediatric Surgery, Krakow, Poland*

Background

The optimal surgical management of paediatric adnexal masses requires balancing oncological safety with preservation of future reproductive potential. This study aimed to evaluate the feasibility, perioperative outcomes and ovarian preservation rates of minimally invasive fertility-sparing surgery in paediatric and adolescent patients with adnexal masses, including complex cases with adnexal torsion or borderline and malignant ovarian tumours.

Methods

This retrospective single-centre cohort study included 232 paediatric and adolescent patients treated surgically for adnexal masses at a tertiary referral centre. Evaluated variables included lesion type and size, histopathological diagnosis, adnexal torsion, recurrence, preoperative imaging, surgical approach, extent of gonadal preservation, operative and anaesthesia time, perioperative and postoperative complications, and length of hospital stay. The cohort included laparoscopic procedures, laparotomies, conversions from laparoscopy to laparotomy, and selected mixed or staged procedures. Comparative perioperative analysis was performed between pure laparoscopic and pure open surgical approaches.

Results

Median patient age was 14.4 years, and median lesion size was 65 mm. Surgical management included 83 laparoscopies, 76 laparotomies and 18 conversions from laparoscopy to laparotomy, with additional mixed or staged procedures analysed descriptively. Adnexal torsion was confirmed in 40/190 evaluable patients (21.1%). Borderline or malignant pathology was identified in 26/156 patients with evaluable histopathological classification (16.7%), including epithelial, germ-cell and sex cord-stromal tumours. Gonad-sparing surgery was achieved in 131/148 evaluable patients (88.5%). Compared with laparotomy, laparoscopy was associated with significantly smaller lesion size (48.5 vs 83.0 mm, $p<0.001$) and shorter postoperative hospitalisation (3 vs 4 days, $p<0.001$). Median operative time was 80 vs 90 minutes, while median anaesthesia time was 120 vs 132.5 minutes for laparoscopy and laparotomy, respectively.

Conclusions

Minimally invasive fertility-sparing surgery is feasible and safe in the majority of paediatric and adolescent patients with adnexal masses, including selected patients presenting with adnexal torsion and borderline or malignant ovarian tumours. Adnexal torsion alone should not automatically mandate gonad removal. Careful preoperative imaging assessment and individualised surgical planning remain essential to optimise oncological safety while preserving future reproductive potential.

ESGE35-0562 -
Best Selected Oral 1

Does the Ultrasound Morphology of Rectosigmoid Endometriotic Nodules Influence the Type of Surgery? Results from a Retrospective Cohort Study

Manuela Maletta[1,2], Federica Tegazi[1,2], Cristian Forastiere[1,2], Antonio Raffone[2,3], Renato Seracchioli[1,2], Diego Raimondo[1]
[1]IRCCS Azienda Ospedaliero-Universitaria di Bologna- Bologna- Italy,
Division of Gynaecology and Human Reproduction Physiopathology, Bologna, Italy
[2]University of Bologna, Department of Medical and Surgical Sciences DIMEC, Bologna, Italy
[3]University of Campania "Luigi Vanvitelli",
Department of Woman- Child and General Specialised Surgery, Napoli, Italy

Background

To investigate the association between the ultrasound morphology of rectosigmoid endometriosis (RSE) nodules, according to the International Deep Endometriosis Analysis (IDEA) consensus, and the type of surgery performed for RSE.

Methods

This was a single-centre, observational, cross-sectional study based on a prospectively collected database and conducted at a tertiary referral centre for endometriosis. All consecutive patients aged 18–52 years who underwent surgery for RSE between January 2020 and March 2026 were included. Exclusion criteria were previous RSE surgery, gynaecological malignancy, absence of preoperative ultrasound evaluation, or multiple RSE localisations. Demographic, clinical, and surgical data were collected. Ultrasound morphology of RSE nodules was reviewed by two expert sonographers and classified as regular profile outlines, “moose antler” sign, “comet” sign, “mushroom cap” sign, or “pulling sleeve” sign. For study purposes, patients with RSE were classified into two groups: full-thickness resection (including discoid or segmental resection) and non–full-thickness resection (including shaving). Statistical analysis included χ^2 test, Fisher’s exact test, and the Kruskal–Wallis test. Logistic regression models were used to evaluate the association between nodule morphology and surgical approach, adjusting for bowel stenosis and lesion size. Statistical significance was set at $p<0.05$.

Results

A total of 219 patients were included in the study. Regular profiles were observed in 55/219 patients (25.1%), comet sign in 51/219 (23.3%), Indian headdress sign in 49/219 (22.4%), pulling sleeve sign in 29/219 (13.2%), and mushroom cap sign in 35/219 patients (16.0%). 126 (57.5%) women underwent a full-thickness resection, and 93 (42.5%) women underwent shaving. At univariable logistic regression analysis, the “mushroom cap” morphology (OR 3.222, 95% CI 1.312–8.452, p=0.013), bowel stenosis >50% (OR 17.358, 95% CI 3.512–>100, p=0.006), and greater longitudinal nodule size (OR 1.134, 95% CI 1.095–1.181, p<0.001) were significantly associated with full-thickness resection. However, in the multivariable analysis, only longitudinal nodule size remained independently associated with the surgical approach (OR 1.127, 95% CI 1.086–1.176, p<0.001). In the subgroup of

patients undergoing full-thickness resection (n=126), at multivariable analysis, only greater longitudinal nodule size was independently associated with a higher likelihood of segmental resection (OR 1.10, 95% 1.055- 1.161, p<0.001).

Conclusions

No association was observed between the ultrasound morphology of RSE nodules, according to the IDEA consensus, and the type of surgery performed. Therefore, the morphology of endometriotic nodules does not appear to be a relevant factor to consider when planning the surgical approach for RSE. However, future larger studies are needed to confirm our findings.

ESGE35-0484 -
Best Selected Oral 1

Fertility-sparing treatment for endometrial cancer: when remission is not enough — the unmet reproductive journey

Simona Palladino[1], Diletta Costeniero[2], Maria Chiara Guarino[3], Aurora Perelli[4], Ludovica Vitale[5], Valentina Chiappa[1]
[1]Fondazione IRCCS Istituto Nazionale Dei Tumori, Gynecologic Oncology, Milan, Italy
[2]University of Padua, Gynaecology and Obstetrics, Padua, Italy
[3]University of Naples Federico II, Gynaecology and Obstetrics, Naples, Italy
[4]University of Verona, Surgery- Dentistry- Paediatrics and Gynaecology, Verona, Italy
[5]Careggi University Hospital- University of Florence,
Experimental- Clinical- and Biomedical Sciences "Mario Serio", Florence, Italy

Background

To evaluate oncological and reproductive outcomes of fertility-sparing treatment in young women with endometrial neoplastic and pre-neoplastic lesions, with particular focus on the gap between achieving histological remission and actually pursuing pregnancy.

Methods

A retrospective observational study included all women aged 18–43 years who underwent fertility-sparing treatment for endometrial pathology at the Fondazione IRCCS Istituto Nazionale Dei Tumori in Milan between 2005 and 2025. Eligible diagnoses were endometrioid carcinoma G1 or G2, atypical endometrial hyperplasia (AEH), atypical polypoid adenomyoma (APA), or adenosarcoma, with disease confined to the endometrium (2018 FIGO stage IA). Treatment consisted of a levonorgestrel-releasing intrauterine device (LNG-IUD), oral progestogens, or a combination, with or without metformin. Histological response was assessed by hysteroscopy every 3 months; complete remission required two consecutive negative biopsies.

Results

Of 68 patients enrolled, 52 (76.5%) achieved complete histological remission; after excluding 10 lost to follow-up, 42 patients formed the final analysis cohort (mean age 34.4 years). Histological diagnoses included G1 endometrioid carcinoma (40.5%), AEH (35.7%), APA (16.7%), and G2 endometrioid carcinoma (7.1%). No statistically significant difference in response rate was observed across histological subgroups ($p > 0.05$). Disease recurrence occurred in 17/42 patients (40.5%), with a mean time to recurrence of 31.4 months. Notably, despite having been cleared for conception, only 25 of 42 patients (59.5%) actually attempted pregnancy — meaning that 4 in 10 women who achieved remission did not pursue their reproductive goal. The overall pregnancy rate was 28.6% (12/42); among those who attempted conception, the rate reached 48%. Use of assisted reproductive technologies (ART) was associated with higher pregnancy rates compared to spontaneous conception attempts.

Conclusions

Fertility-sparing treatment is oncologically effective in selected patients, but oncological remission alone does not guarantee reproductive success. A striking 40% of women who achieved histological remission did not attempt pregnancy, suggesting that barriers beyond oncological control — including psychological factors, age-related concerns, comorbidities, and access to ART — play a major role in reproductive outcomes. These findings highlight the need for early multidisciplinary counselling integrating oncological, reproductive, and psychological support from the outset of treatment, and prompt referral to ART upon remission to maximise both reproductive success and oncological safety.

ESGE35-0442 -
Best Selected Oral 1

Ultrasound-based #ENZIAN classification predicts surgical complexity in deep endometriosis: a prospective cohort study

Daria Pashkunova[1], *Ezgi Darici Kurt*[2,3], *Jörg Keckstein*[4], *Johannes Ott*[5], *Attila Bokor*[3], *Gernot Hudelist*[6,7]
[1]*Floridsdorf Hospital, Department of Obstetrics and Gynaecology, Vienna, Austria*
[2]*Bahceci IVF Centre, Department of Gynaecology, Istanbul, Türkiye*
[3]*Semmelweis University, Department of Obstetrics and Gynaecology, Budapest, Hungary*
[4]*Gynecological Clinic Drs Keckstein, Gynaecological Clinic, Villach, Austria*
[5]*Medical University of Vienna, Department of Obstetrics and Gynaecology, Vienna, Austria*
[6]*Hospital St. John of God, Department of Gynaecology, Vienna, Austria*
[7]*Jagiellonian University Hospital, Department of Gynaecology, Krakow, Poland*

Background

Surgical treatment of endometriosis can be technically demanding, particularly in ovarian and deep endometriosis, where lesion size and anatomical location strongly influence operative complexity. High-quality preoperative transvaginal ultrasound enables systematic mapping of affected compartments and may support surgical planning. The #ENZIAN classification provides a standardised framework for the non-invasive description of endometriotic lesions. This prospective cohort study evaluated whether preoperative ultrasound findings classified according to #ENZIAN can predict the surgical steps required during laparoscopic surgery for complete resection of ovarian and deep endometriosis.

Methods

Premenopausal women undergoing laparoscopic surgery for suspected endometriosis at two referral centres in Vienna, Austria, were prospectively included. All patients underwent standardised preoperative transvaginal ultrasound, and the extent and anatomical localisation of endometriotic lesions were documented according to the #ENZIAN classification. During surgery, all procedures required for complete excision of endometriotic tissue were prospectively recorded as predefined surgical steps, including left- and right-sided ureterolysis, left- and right-sided endometrioma resection, resection of the left and right uterosacral ligaments, dissection of the pouch of Douglas, and bowel surgery. Preoperative #ENZIAN findings were correlated with the surgical steps performed intraoperatively.

Results

Overall, 291 patients were included. The need for bowel surgery was significantly predicted by compartment C involvement, with an overall prediction accuracy of 92.8% ($\chi^2 = 221.76$, $p < .001$). Pouch of Douglas dissection was associated with compartments A and C, T left, and left-sided compartment B involvement, correctly classifying 79.4% of cases ($\chi^2 = 150.03$, $p < .001$). Excision of left- and right-sided ovarian endometriomas was significantly associated with ovarian involvement, classified as compartment O, and ipsilateral tubo-ovarian involvement, classified as compartment T, with correct classification rates of 88.0% and 89.7%, respectively ($\chi^2 = 182.72$ and 166.96; both $p <$

.001). Left- and right-sided ureterolysis were associated with ipsilateral compartment T involvement and compartments A and C (χ^2 = 107.84 and 88.28; both $p < .001$). Left-sided ureterolysis was additionally associated with left-sided compartment B and ovarian involvement, achieving a prediction accuracy of 76.3%. Prediction models for uterosacral ligament resection showed lower predictive performance. Left-sided resection was associated with left ovarian and bilateral compartment B involvement, whereas right-sided resection was associated with right-sided compartment B and T left involvement, with correct classification rates of 67.4% and 72.4%, respectively.

Conclusions

Preoperative ultrasound assessment using the #ENZIAN classification provides clinically relevant information for predicting surgical complexity in ovarian and deep endometriosis. Standardised #ENZIAN mapping may improve surgical planning, interdisciplinary coordination, and patient counselling regarding the extent and risks of laparoscopic endometriosis surgery.

ESGE35-0130 -
Best Selected Oral 1

Long-term clinical results of High Intensity Focused Ultrasound (HIFU) treatment of rectal endometriosis

Gil Dubernard[1], *Alexia Mazard*[2], *Manon Basso*[2], *Charles Jayyosi*[2]
[1]*Croix-Rousse University Hospital- Hospices Civils de Lyon. Université Claude Bernard Lyon 1, Gynaecology Obstetrics, Lyon, France*
[2]*Croix-Rousse University Hospital- Hospices Civils de Lyon. Université Claude Bernard Lyon 1, Gynaecology Obstetrics, Lyon, France*

Background

To assess the evolution of gynaecological and digestive symptoms and health status after High Intensity Focused Ultrasound (HIFU) treatment of rectal endometriosis.

Methods

Patients who received HIFU treatment for rectal endometriosis were enrolled in the EndoFollow-up study. Patients' symptoms were assessed before treatment, then 1 and 2 years later using several questionnaires exploring gynaecological and digestive symptoms (Visual Analogue Scale) and health status (MOSSF-36 questionnaire). In addition, a clinical interview was performed, recording pregnancy attempts, infertility, use of hormonal treatment and additional surgery related to endometriosis.

Results

At 1 year post-treatment compared to baseline, we observed a significant improvement in dysmenorrhea or acute pelvic pain ($p<0.01$), dyspareunia ($p<0.01$), pain on defecation ($p<0.01$), diarrhoea ($p<0.01$), constipation ($p<0.01$), false urge ($p<0.01$), tenesmus ($p<0.01$) and asthenia ($p<0.01$).

When compared to baseline, all the gynecologic and digestive symptoms were still significantly improved ($p<0.01$) 2 years after the procedure. Physical and mental components of the MOSSF-36 score were significantly improved from baseline and respectively at 1 ($p<0.01$ and $p<0.01$)and 2 years ($p<0.04$ and $p<0.01$) after the treatment, excepted for physical functioning at 2 years ($p=0.06$). These clinical outcomes were achieved with 57% of the patients receiving hormonal treatment at one year and 53% at 2 years. During the 2 -year follow-up period, 6 patients had surgical management of rectal endometriosis by rectal shaving, except one segmental resection. Among the patients, 12 (10%) were pregnant.

Conclusions

HIFU management of rectal endometriosis provides a significant improvement of gynecological and digestive complaints as well as the health status up to 2 years after the treatment. For eligible patients, HIFU may be proposed as a first-line treatment of rectal endometriosis due to the lack of complications related to this procedure.

ESGE35-0053 -
Best Selected Oral 1

Vaginal Natural Orifice Transluminal Endoscopic Surgery vs. Conventional Laparoscopy for Pelvic Lymphadenectomy in Endometrial Cancer: A Comparative Analysis of Surgical Outcomes and Quality of Recovery

Kemal Güngördük[1], Serkan Ustuntas[2], Berican Sahin Uyar[2], Berke Nur Ergu[2], Furkan Karaoz[2], Emre Biton[2]
[1]Muğla Sıtkı Koçman University, Gynecological Oncology, Muğla, Türkiye
[2]Mugla Sıtkı Koçman University, Department of Obstetrics and Gynaecology, Muğla, Türkiye

Background

We compared the outcomes of complete pelvic lymph node dissection performed via multiport conventional laparoscopy (MCL) versus vaginal natural orifice transluminal endoscopic surgery (vNOTES) in patients with endometrial cancer in whom sentinel lymph node (SLN) mapping was unsuccessful.

Methods

This retrospective cohort study included 42 patients with grade I or II endometrioid endometrial cancer who underwent hysterectomy with bilateral salpingo-oophorectomy, followed by comprehensive retroperitoneal pelvic lymphadenectomy after failed bilateral SLN mapping. Patients underwent either vNOTES (n = 21) or MCL (n = 21). Demographic characteristics, operative times, perioperative and postoperative complications, pain scores, and quality of recovery-15 (QoR-15) scores were collected and compared between the two groups.

Results

Demographic and clinical characteristics were comparable between the two groups, with no statistically significant differences. Operative times were significantly longer in the vNOTES group (53.8 ± 7.4 min) compared to the MCL group (46.9 ± 9.2 min; P = 0.01), whereas blood loss (17.7 ± 5.6 mL vs. 18.8 ± 5.0 mL; P = 0.50) and the numbers of retrieved lymph nodes (32.1 ± 6.6 vs. 35.0 ± 8.1; P = 0.21) did not differ significantly. Postoperative pain, assessed using a visual analogue scale, was lower in the vNOTES group at 6 h (4.3 ± 1.1 vs. 5.5 ± 1.0; P = 0.01), 12 h (3.5 ± 0.8 vs. 4.8 ± 1.1; P < 0.001), and 24 h (2.1 ± 0.6 vs. 3.1 ± 0.9; P < 0.001). These findings were corroborated by the Faces Pain Scale-Revised, which demonstrated significantly reduced pain in the vNOTES group at 6 h (P = 0.002), 12 h (P < 0.001), and 24 h (P = 0.04). QoR-15 scores at 48 h postoperatively were higher in the vNOTES group compared to the MCL group (109.3 ± 4.7 vs. 104.9 ± 4.1; P = 0.002), indicating improved postoperative recovery.

Conclusions

vNOTES for complete pelvic lymphadenectomy offers reduced postoperative pain, scar-free surgery, and enhanced recovery, while maintaining oncologic outcomes comparable to those of MCL.

ESGE35-0017 -
Best Selected Oral 1

Mid-term oncologic outcomes of vaginal natural orifice transluminal endoscopic surgery compared with total laparoscopic hysterectomy for early-stage endometrial cancer: a single-centre retrospective study

Junya Abe[1], Kenro Chikazawa[1], Ken Imai[1], Miyuki Taniguchi[1], Nanami Suzuki[1], Mina Hasegawa[1]
[1]Saitama Medical Centre- Jichi Medical University, Department of Obstetrics and Gynaecology, Saitama, Japan

Background

Vaginal natural orifice transluminal endoscopic surgery (vNOTES) is increasingly being used to avoid abdominal incisions, but mid-term oncological safety in endometrial cancer is unclear.

Methods

This single-centre retrospective study was conducted from January 2014 to February 2026. Patients with International Federation of Gynaecology and Obstetrics (FIGO) clinical stage IA endometrioid endometrial carcinoma who underwent simple hysterectomy were enrolled. We compared mid-term oncologic outcomes of vNOTES and total laparoscopic hysterectomy (TLH). Recurrence-free survival (RFS) was evaluated using the Kaplan–Meier method and compared between the TLH and vNOTES groups. Cox proportional hazards models were used to identify the prognostic factors for RFS.

Results

In total, 130 patients were included: 109 underwent TLH, and 21 underwent vNOTES. The median follow-up period was 48 and 33 months in the TLH and vNOTES groups, respectively. Postoperative adjuvant therapy was more frequent in the vNOTES group. The operative time was significantly shorter with vNOTES. Incidence of postoperative complications was low and similar between the groups. The 3-year RFS was 92.8% and 94.4% in the TLH and vNOTES groups, respectively, without a significant difference (P = 0.874). Lymphovascular invasion predicted RFS, whereas surgical approach did not.

Conclusions

vNOTES hysterectomy demonstrated mid-term oncologic outcomes comparable to TLH in patients with FIGO stage IA endometrial cancer, suggesting that vNOTES does not compromise oncological safety in appropriately selected patients with early-stage endometrial cancer.

ESGE35-0453 -
Best Selected Oral 2

Impact of gaming on endoscopic skill acquisition: a prospective cohort study

Daria Adamska[1], Karolina Kęsik[1], Julia Traczyk[1], Łucja Zaborowska[1], Artur Ludwin[1]
[1]Medical University of Warsaw, 1st Department of Obstetrics and Gynaecology, Warsaw, Poland

Background

As endoscopy increasingly replaces traditional surgery in diagnostic and therapeutic procedures, there is a growing need for effective methods to facilitate the acquisition of endoscopic skills. One such approach involves computer games, which are highly popular among students and may potentially improve hand-eye coordination, visual-spatial abilities and concentration required in laparoscopic surgery. The aim of the prospective observational cohort study was to assess the impact of prior gaming experience on the rate of acquisition of endoscopic skills in medical students using laparoscopic trainers.

Methods

This prospective cohort study was conducted at the Medical University of Warsaw in 2025. Participants were recruited among medical university students via an online application form and divided into two groups: gamers (study group, people who regularly play computer games) and non-gamers (control group, participants with no prior gaming experience). The study consisted of three 30-minute sessions during which participants performed two timed tasks on laparoscopic trainers. All tasks were performed bimanually. The first task involved placing beads on eight pegs. The second task required passing a string through eight metal loops in a specified order. We measured the time of completion of both tasks at every session.

Results

The study included 65 participants with no prior experience in laparoscopic training (34 gamers, 31 non-gamers). Gamers completed the first task on average approximately 8 seconds faster (6.4%) than non-gamers (117.26 s ± 44.10 vs 125.22 s ± 44.25, respectively; p= 0.549), and the second task about 41 seconds faster (16.4%) than non-gamers (208.49 s ± 72.27 vs 249.35 s ± 118.03, respectively; p = 0.314). Gamers outperformed non-gamers during the initial session (first task: p = 0.133; second task: p = 0.237); however, this advantage diminished with repeated simulator training. Both groups demonstrated a significant improvement in task completion time across consecutive sessions. Personal computer gamers completed both tasks an average of 53 seconds (11%) faster than console gamers (481.59 s ± 166.25 vs 534.63 s ± 174.71, respectively), although the difference did not reach statistical significance (p = 0.216). Gamers reporting 1–3 hours of gameplay per week achieved the shortest mean completion time, followed by those playing more than 7 hours weekly and those playing 4–6 hours weekly (477.12 s ± 162.03 vs 478.61 s ± 119.03 vs 518.56 s ± 190.05, respectively; p = 0.6).

Conclusions

Prior gaming experience was associated with a trend toward faster laparoscopic performance, although the observed difference did not reach statistical significance. The potential advantage associated with gaming diminished with repeated simulator training. Weekly gaming duration did not significantly influence performance outcomes. Both groups demonstrated significant improvement across consecutive training sessions, suggesting that even short-term simulator training effectively enhances basic laparoscopic skills. Larger studies are needed to confirm these findings.

ESGE35-0337 -
Best Selected Oral 2

Laparoscopic implantation of bioengineered uterine scaffolds enables tissue regeneration and immune modulation in a sheep model

Francisco Miguel Sánchez-Margallo[1], Soledad Sánchez-Mateos[2], Joaquín Gómez-Abellán[3], Ester Párraga-Ros[4], Juan Alberto Sánchez-Margallo[3], Alba Mangas Losada[5]
[1]Minimally Invasive Surgery Centre Jesús Usón, Scientific Director, Cáceres, Spain
[2]Minimally Invasive Surgery Centre Jesús Usón, Assisted Reproduction, Cáceres, Spain
[3]Minimally Invasive Surgery Centre Jesús Usón, Robotics- Bioprinting- and Image-Guided Surgery, Cáceres, Spain
[4]Faculty of Veterinary Medicine- University of Murcia, Comparative Anatomy and Pathological Anatomy, Murcia, Spain
[5]Minimally Invasive Surgery Centre Jesus Uson, Assisted Reproduction, Cáceres, Spain

Background

The objectives of the study are to evaluate the feasibility and safety of laparoscopic uterine scaffold implantation in a large animal model and to characterise the regenerative and immunological responses associated with biological and biosynthetic scaffolds for uterine reconstruction.

Methods

An experimental pilot study was conducted in ten sheep, selected because of their anatomical and physiological similarity to the human female reproductive tract. A full-thickness defect involving all uterine wall layers was surgically created in one uterine horn and reconstructed laparoscopically using scaffold implantation secured with continuous sutures.

Three scaffold types were evaluated: decellularised uterine tissue, decellularised uterine tissue recellularized with endometrial-derived stem cells, and polycaprolactone (PCL) synthetic scaffolds.

Peripheral blood samples were collected longitudinally for immune cell isolation and flow cytometry analysis. After 11 weeks, animals underwent robot-assisted laparoscopic hysterectomy for tissue retrieval and histological assessment. Regenerative remodelling was evaluated using hematoxylin-eosin staining and semi-quantitative histological analysis.

Results

All scaffold types were successfully implanted laparoscopically without intraoperative complications, enabling a fully minimally invasive approach. Animals showed uneventful postoperative recovery, with no clinical or laboratory evidence of rejection or severe inflammatory response.

Histological analysis demonstrated partial uterine tissue regeneration in all experimental groups, including the presence of endometrial structures and glandular organisation, although myometrial regeneration remained incomplete. Biological scaffolds demonstrated superior regenerative integration compared with PCL scaffolds, which showed limited tissue remodelling and poorer structural organisation. Decellularised uterine scaffolds achieved the most balanced regenerative

response, with reduced lesion severity and improved tissue architecture compared with decellularised scaffolds alone.

Immunological analysis identified scaffold-dependent peripheral immune signatures. Significant differences were observed between biological and synthetic scaffolds, particularly involving CD4 and CD8 T-cell subsets and monocyte populations. Multivariate analysis revealed distinct distributions of naïve, central memory, and effector memory CD8 populations among groups. Correlation analysis demonstrated positive associations between regenerative outcomes and early CD45+CD14+CD163+ cell populations, whereas increased total leukocyte counts and CD4−CD8−CD62L+ populations were associated with poorer histological regeneration.

Conclusions

Laparoscopic implantation of bioengineered uterine scaffolds is feasible and safe in a large animal model and enables partial uterine tissue regeneration following full-thickness uterine repair. Tissue-derived scaffolds demonstrated superior regenerative integration compared with synthetic biomaterials and generated distinct immune signatures associated with tissue remodelling.

These findings support the translational potential of combining minimally invasive gynecologic surgery with regenerative bioengineering strategies for future uterine reconstruction and fertility-preserving applications. Peripheral immune profiling may represent a valuable tool for identifying biomarkers associated with regenerative success. Further studies are required to validate these findings and support clinical translation.

ESGE35-0285 -
Best Selected Oral 2

Three Distinct Bladder Nerve Pathways from the Pelvic Plexus and Their Surgical Implications for Nerve-Sparing Radical Hysterectomy

Kenro Chikazawa[1], *Ken Imai*[2], *Tomoyuki Kuwata*[2]
[1]*Jichi Medical University- Saitama Medical Centre, Obstetrics and Gynaecology, Saitama, Japan*
[2]*Jichi Medical University-Saitama Medical Centre, Obstetrics and Gynaecology, Saitama, Japan*

Background

To clarify the anatomical courses of bladder branches arising from the pelvic plexus and to demonstrate their surgical significance during nerve-sparing radical hysterectomy (NSRH), particularly in relation to dissection of the posterior layer of the vesicouterine ligament.

Methods

Anatomical dissections were performed on three cadavers (six pelvic sides). The bladder branches arising from the pelvic plexus were identified, and their relationships to the ureter, vesical veins, vaginal veins, and rectovaginal ligament were evaluated. Surgical findings were correlated with anatomical observations using intraoperative video analysis during NSRH.

Results

Three distinct bladder nerve pathways were identified. Type I coursed along the ureter. Type II coursed along the vesical veins within the posterior layer of the vesicouterine ligament. Type III ran between the vesical and vaginal veins and shared a common trunk with the uterine branch. This common trunk travelled adjacent to the ventrolateral aspect of the rectovaginal ligament before extending branches to the bladder. Type II nerves mainly projected toward the bladder body, whereas Type III nerves extended toward the dorsal aspect of the bladder. During Okabayashi-style NSRH, the posterior layer of the vesicouterine ligament is divided, resulting in transection of Type II nerves while preserving Type III nerves. Surgical traction of the bladder ventrally and the ureter laterally widened the vector between Types II and III, thereby emphasising the avascular space recognised intraoperatively as the paravaginal space and facilitating its dissection. In contrast, radical hysterectomy performed without opening this space and with division of the vesical veins along the deep uterine vein preserved Type II nerves. Although NSRH is classified as type C1 in the Querleu-Morrow classification, these findings suggest the existence of anatomically distinct subtypes based on differential preservation of bladder nerve pathways.

Conclusions

Bladder branches from the pelvic plexus consist of three anatomically distinct pathways with different spatial orientations and surgical implications. Recognition of these nerve vectors and the paravaginal space may improve anatomical understanding and refinement of NSRH techniques. These findings also suggest that current classifications of NSRH may require further anatomical subclassification.

ESGE35-0158 -
Best Selected Oral 2

Procedural sedation versus general anaesthesia for laparoscopic sterilisation; a randomised controlled trial

Hilde Sluijter[1], *Huib van Vliet*[1], *Dana Huppelschoten*[1], *Loes Braam*[2], *Kim Bijleveld*[2]
[1]*Catharina Hospital, Obstetrics and gynaecology, Eindhoven, The Netherlands*
[2]*Catharina Hospital, Anaesthesiology, Eindhoven, The Netherlands*

Background

Gynaecological procedures are increasingly performed under procedural sedation instead of general anaesthesia. Advantages are a quicker recovery, higher patient satisfaction and lower costs. A number of studies have reported on the safety of procedural sedation during laparoscopic sterilisation; however, these were generally small, outdated, and patient recovery was not assessed. The objective of this study is to evaluate whether the postoperative recovery differs between patients receiving procedural sedation for a laparoscopic sterilisation or general anaesthesia.

Methods

This study is a single-centre, single-blinded randomised controlled trial. Patients who were scheduled for a laparoscopic sterilisation were allocated to either receive procedural sedation with propofol and alfentanil or general anaesthesia during the procedure. The primary outcome measure was recovery 24 hours postoperatively, which was assessed using the Quality of Recovery 40 (QoR-40) questionnaire (range 40-200, higher score indicating superior recovery). The required sample size was calculated to be 46 inclusions, based on a ten-point difference per scale of the QoR-40, with an alpha of 0.05 and a beta of 80%. In addition, peri-operative data were measured, including vital parameters, complications and conversions, the necessity for additional medication and the times of induction, operation, total time in the operating room and total time in the recovery room. Use of analgesics directly postoperatively and in the subsequent week was also assessed.

Results

The study comprised a total of 46 patients, with 23 patients in each arm. No significant difference was found in the main outcome, QoR-40, with 170 pts in the procedural sedation and 167 pts in the general anaesthesia group (p=0.471). The mean total operating room time was eighteen minutes shorter in the procedural sedation group compared to those receiving general anaesthesia (43 vs 61 minutes, p=0.001). There was no difference in use of analgesics either after the surgery or in the first week postoperative. There were no anaesthesia-related complications or conversions in either group.

Conclusions

Laparoscopic sterilisation with procedural sedation shows shorter total operating room time than laparoscopic sterilisation with general anaesthesia. No difference was found in recovery after 24 hours. The shorter total operating room times and less trained personnel being required, most likely make procedural sedation more cost-effective.

We therefore advise that procedural sedation should be the first choice for laparoscopic sterilisation in a select group of low-risk patients. However, more research should be done into the safety of procedural sedation for larger groups, higher-risk patients, and for the use of procedural sedation for other minimally invasive gynaecological procedures.

ESGE35-0097 -
Best Selected Oral 2

Does robotic surgery influence post-operative pain in patients undergoing sacrocolpopexy?

Ramona Osswald[1], *Katrin Breitling*[1]
[1]*Cantonal Hospital of Schaffhausen, Gynaecology and Obstetrics, Schaffhausen, Switzerland*

Background

In the past decades, robotics have increasingly been introduced into gynecologic surgery. Better dexterity and visualisation, as well as surgeons' ergonomics, have led to this development. For sacrocolpopexy, different studies have shown the non-inferiority of the robot. The aim of our analysis was to investigate if post-operative pain after sacrocolpopexy is dependent on the type of minimal invasive surgery applied.

Methods

Twenty-eight patients were included in this retrospective quality control analysis. Fifteen had undergone laparoscopic (LSC) sacrocolpopexy, 13 had undergone robotic (ROB) sacrocolpopexy. All procedures were performed at the Cantonal Hospital of Schaffhausen between 2023 and 2026. Basic postoperative analgesics (non-opioids) were applied according to WHO pain scale. For both groups, the application of reserve medication (opiates) was assessed and compared. Moreover, VAS-scores were measured for the operation day and every following day during the hospital stay. Operation time, BMI, hospital stay, age and re-hospitalisation for adverse events were recorded. Student's t-test was used to compare the groups, p-values <0,05 were considered statistically significant.

Results

There were no significant differences in the age of the patients (LSC 60 years, ROB 63years, p=0,41) length of hospital stay (LSC 2,2 days vs. ROB 2,0 days, p=0,36), the BMI (LSC 27kg/m2 vs. ROB 25kg/m2, p=0,25) and the use of NSAID, metamizole and paracetamol between the groups. No patient was re-hospitalised. Operation time was significantly longer in the robot group (LSC 226 min vs ROB 271 min, p=0,046). The VAS score was higher in the LSC group on the operation day (LSC VAS 2,24= vs. ROB VAS 1,51, p=0,15) and the first post-operative day (LSC VAS 2,3= vs. ROB VAS 1,61 p=0,20), but differences were not significant. On the second post-operative day, the VAS score was higher in the robot group (LSC VAS 0,49 vs. ROB VAS 0,75, p=0,44). In the robot group, 5 doses of reserve analgesics were applied for all patients during all days, while in the LSC group, 24 doses were applied (p=0,008).

Conclusions

The post-operative VAS score in laparoscopic and robotic sacrocolpopexy is low. Although the operation time is longer in the robotic group, the amount of analgesics needed to reach an adequately low pain level appears to be higher in the laparoscopic sacrocolpopexy group. Since this analysis was carried out on a small sample size, it surely needs further investigations and studies to confirm our results.

ESGE35-0096 -
Best Selected Oral 2

Update on clinical classification system of Obstructed Hemivagina and Ipsilateral Renal Anomaly (OHVIRA) syndrome: a nationwide multicentre retrospective study

Lan Zhu[1], *Shuang Song*[2]
[1]*Peking Union Medical College Hospital- Beijing, Department of Obstetrics and Gynaecology, Beijing, China*
[2]*Peking Union Medical College Hospital, Department of Obstetrics and Gynecology, Beijing, China*

Background

Obstructed Hemivagina and Ipsilateral Renal Anomaly (OHVIRA) syndrome is a rare female urogenital tract malformation disease. A 4-subtype clinical classification system was proposed previously based on a single-center study with a relatively small sample size. Here we aim to propose the update version of clinical classification system of OHVIRA syndrome by this nationwide multicentre retrospective study, enrolling in the largest cohort of patients with OHVIRA syndrome to date.

Methods

This is a nationwide multicentric retrospective study enrolling patients diagnosed with OHVIRA syndrome from January 2015 to July 2024 in 30 tertiary medical centres across China. We searched the Chinese Female Reproductive Tract Malformation registry platform and retrospectively identified OHVIRA cases. After excluding incomplete or duplicated data, the anatomical features of enrolled cases were summarized and the clinical characteristics including onset age, symptoms, complications as well as clinical management procedures were analysed to display various features of different subtypes.

Results

A total of 517 cases were identified in the database, and 420 patients were enrolled. Based on their anatomical features, we identified the new subtype (classification V) characterised by unilateral cervical atresia with communicating uteri. Therefore, we expanded the previous 4-subtype classification system to an updated 5-subtype classification system. Among the patients, 175 (46.7%) cases were assigned to classification I, 167 (39.8%) as classification II, 35 (8.3%) as classification III, 38 (9.0%) as classification IV, and 5 (1.2%) as classification V. Compared to classification II and III, patients with classification I, IV and V presented with more severe dysmenorrhea, less irregular vaginal bleeding, and had significantly higher risk of endometriosis and lower risk of pelvic inflammatory disease (Bonferroni-adjusted P <0.005). Moreover, most patients with classification IV and V received hemi-hysterectomy, while a majority of patients with classification I, II and III received excision of vaginal septum.

Conclusions

The updated 5-subtype clinical classification system can elucidate various anatomical variations of OHVIRA syndrome, further guiding the diagnosis process and clinical management. Though rare, newly proposed classification V is noteworthy. It's an incomplete obstructed subtype anatomically, with a lot of clinical features more similar to the complete obstructed subtypes, such as more severe dysmenorrhea and increased risk of secondary endometriosis, which is prone to misdiagnosis or delayed intervention.

ESGE35-0044 -
Best Selected Oral 2

Association between diffuse inner myometrial adenomyosis and chronic endometritis in women with adverse reproductive outcomes

Yannick Hurni[1], *Nuria Barbany-Freixa*[1], *Susana Tovar*[2], *Laura Vilar*[2], *Pere Nolasc Barri-Soldevila*[1], *Alicia Ubeda*[1]
[1]*Dexeus University Hospital Dexeus Mujer, Obstetrics- Gynaecology and Reproductive Medicine, Barcelona, Spain*
[2]*University Hospital General de Catalunya Dexeus Mujer, Obstetrics- Gynaecology and Reproductive Medicine, Sant Cugat, Spain*

Background

Chronic endometritis (CE) is a subtle inflammatory condition of the endometrium associated with impaired endometrial receptivity and adverse reproductive outcomes, including infertility, recurrent pregnancy loss (RPL), and repeated implantation failure (RIF). Adenomyosis, particularly when involving the inner myometrial layer, is characterised by local inflammatory and immune dysregulation and may contribute to a proinflammatory endometrial environment. However, the association between adenomyosis and CE remains insufficiently investigated.

Methods

This was a retrospective cohort study conducted at two tertiary referral centres between January 2023 and June 2025. Women aged 18–45 years undergoing evaluation for infertility, recurrent pregnancy loss (RPL), or repeated implantation failure (RIF) underwent transvaginal 2D and 3D ultrasound, hysteroscopy, and endometrial biopsy. Adenomyosis was defined according to standardised MUSA criteria and restricted to diffuse disease involving the inner myometrial layer. CE was diagnosed histologically using CD138 immunohistochemistry. Multivariable logistic regression was used to adjust for predefined confounders, with sensitivity analyses performed to assess robustness.

Results

A total of 332 women were included; 48 (14.5%) had diffuse adenomyosis, and 284 (85.5%) had no adenomyosis. CE was significantly more prevalent in women with adenomyosis than in those without (41.7% vs. 13.7%, $p<0.001$). After adjustment for age, uterine fibroids, prior uterine surgery, and parity, adenomyosis remained independently associated with CE (OR 4.33, 95% CI 2.16–8.70). Sensitivity analyses yielded consistent results. Subgroup analyses showed a higher prevalence of CE in women with adenomyosis across infertility, RPL, and RIF indications. Statistical significance was not reached in the RIF subgroup, likely due to the small sample size.

Conclusions

Diffuse adenomyosis involving the inner myometrial layer is associated with CE in women with adverse reproductive outcomes. These findings support the concept that endometrial inflammation

may represent a relevant biological component of adenomyosis-associated reproductive dysfunction and warrant further investigation into its pathophysiologic and clinical implications.

ESGE35-0001 -
Best Selected Oral 2

Risk factors for non-satisfaction after benign hysterectomy - a population-based nationwide register study

Lollo Makdessi Björkström[1], Mats Fredrikson[2], Ninnie Borendal Wodlin[3], Lena Nilsson[4], Christer Borgfeldt[3], Preben Kjølhede[3]
[1]Region Östergötland, Clinical Department of Obstetrics and Gynaecology, Norrköping, Sweden
[2]Linköping University, Department of Biomedical and Clinical Sciences, Linköping, Sweden
[3]Region Östergötland, Clinical Department of Obstetrics and Gynaecology, Linköping, Sweden
[4]Region Östergötland, Clinical Department of Anaesthesiology and Intensive Care, Linköping, Sweden

Background

The main goal of hysterectomy for benign conditions is to improve health-related quality of life. This study aimed to determine preoperative risk factors for non-satisfaction one year after hysterectomy for benign indication and to analyze whether multiple co-occurring preoperative risk factors increase the rate of non-satisfaction.

Methods

A historical register study was conducted using data from the Swedish National Register for Gynaecological Surgery of women aged 18-56 years who underwent hysterectomy for benign conditions between 2004 and 2023. One year postoperatively, satisfaction was dichotomised into satisfaction or non-satisfaction. Multiple logistic regression was used to evaluate preoperative risk factors, with results presented as adjusted odds ratios (aORs) and 95% confidence intervals (CIs). Nagelkerke's coefficient of determination (R^2) assessed the explanatory power of the models.

Results

Among the 38,044 participating women, 3335 (8.8%) were not satisfied after one year. Preoperative risk factors for non-satisfaction were smoking (aOR 1.34, 95%CI 1.18-1.53), not being gainfully employed (aOR 1.60, 95%CI 1.40-1.82), and the main symptoms leading to hysterectomy (pain (aOR 1.91, (95%CI 1.70-2.15), pressure/heaviness (aOR1.90, 95%CI 1.53-2.21), other symptoms (aOR 2.24, 95%CI 1.95-2.59), or several main symptoms (aOR 1.92, 95%CI 1.53-2.41)). Protective factors for non-satisfaction were age 46-50 years (aOR 0.87, 95%CI 0.76-1.00) and minimally invasive hysterectomy (vaginal (aOR 0.69, 95%CI 0.59-0.81), laparoscopic (aOR 0.79, 95%CI 0.68-0.91), and robot assisted laparoscopic (aOR 0.82, 95%CI 0.71-0.95)).

The likelihood of being non-satisfied rose with the accumulation of preoperative risk factors, as reflected by the full model's explanatory power (R^2 =0.141). Among individual predictors, the main symptom leading to hysterectomy contributed most to the explained variance (R^2 =0.029), followed by employment status (R^2 =0.009), while other factors such as surgical route, age, and smoking only marginally contributed to the variance.

Conclusions

Nearly 9% of the women were dissatisfied with the outcome of the hysterectomy after one year. Lack of satisfaction appeared predictable from preoperative factors, notably smoking, not being gainfully employed, and non-bleeding symptoms leading to hysterectomy. These findings emphasise the need for individualised counselling before surgery. Given that most preoperative risk factors are resistant to immediate modification, more research is needed to develop targeted interventions that can reduce non-satisfaction and enhance patient outcomes.

BEST SELECTED VIDEO ABSTRACTS

ESGE35-0316 -
Best Selected Videos 1

V-Notes right sentinel lymph node excision and left pelvic lymphadenectomy

Oguzhan Kayim[1], Duygu Güzel[1], Ghanim Khatib[1]
[1]Cukurova University Balcali Hospital, Gynaecologic Oncology, Adana, Türkiye

Background

Vaginal natural orifice transluminal endoscopic surgery (V-NOTES) has increasingly been preferred in recent years due to its ability to reduce postoperative morbidity and provide favourable cosmetic outcomes. In this video, we aimed to demonstrate the feasibility and safety of performing right sentinel lymph node excision combined with left pelvic lymphadenectomy using the V-NOTES approach in gynaecologic oncology.

Methods

This video presents the surgical steps of the V-NOTES procedure performed in a patient requiring lymphatic assessment. Following transvaginal access, pelvic anatomy was systematically identified. Right-sided sentinel lymph node excision was performed, followed by left pelvic lymphadenectomy. Key anatomic landmarks, dissection planes, and technical tips facilitating adequate exposure and safe lymph node removal are highlighted.

Results

The procedure was successfully completed via the V-NOTES approach without intraoperative complications. Adequate exposure of the pelvic spaces allowed precise identification and excision of the sentinel lymph node on the right side. On the left side, there was no sentinel lymph node staining with indocyanine green. Therefore, systemic pelvic lymphadenectomy was performed on the left side.

Conclusions

The technique provided effective lymphatic staging while preserving the benefits of minimally invasive surgery. V-NOTES enables pelvic lymphadenectomy with efficacious exposure and surgical safety. This approach could be a valuable minimally invasive alternative for patients requiring lymph node assessment in gynaecologic oncology.

https://player.vimeo.com/video/1191118010?autoplay=1

ESGE35-0174 -
Best Selected Videos 1

Inside the Obturator Canal: Robotic Ganglion Cyst Decompression

Oscar BARNICK[1], Florence Britton[1], Shaheen Khazali[1]
[1]HCA, The Lister Hospital, London, United Kingdom

Background

Obturator nerve compression is an uncommon cause of groin and medial thigh pain. Ganglion cysts extending into the obturator foramen are rare and usually managed via open or orthopaedic approaches. Robotic Neuropelveology offers high-definition access to pelvic neurovascular structures and may facilitate nerve-preserving excision.

Objectives

To demonstrate a robotic pelvic approach to the obturator foramen for excision of a ganglion cyst inseparable from the obturator nerve, and to highlight multidisciplinary planning in atypical neuropathic pelvic pain.

Participant

A 47-year-old woman with left groin/medial thigh pain and impaired leg function. MRI showed a 16-mm lobulated ganglion cyst arising from the undersurface of the left hip joint and extending into the left obturator foramen, inseparable from the obturator nerve with neurogenic oedema in obturator externus/adductor muscles.

Methods

After multidisciplinary (MDT) planning with radiology, a neurosurgeon and Neuropelveology gynaecology surgeon, a joint robotic procedure was performed. Key steps: develop an avascular pelvic sidewall plane via the lumbosacral space; dissect caudally to the obturator canal with minimal traction; identify the obturator nerve and vein and perform nerve-sparing neurolysis; perform controlled cystotomy and evacuate gelatinous contents for decompression; deroof the ganglion and remove the cyst wall to reduce recurrence.

Results

This operation was an excellent success, as shown by the patient's leg movement and control on day 2 post op. To date, she remains well.

Conclusion

Robotic access to the obturator foramen can enable minimally invasive, nerve-preserving decompression and excision of selected pelvic nerve compression lesions, supported by MDT planning, with symptomatic and motor improvement.

https://player.vimeo.com/video/1191168559?autoplay=1

ESGE35-0216 -
Best Selected Videos 1

Transvaginal single-port robotic surgical staging for early-stage endometrial cancer: a video article

Federica Anzelmo Sciarra[1], Carlo Ronsini[2], Mariano Catello Di Donna[3], Maria Cristina Solazzo[2], Cono Scaffa[2], Vito Chiantera[4]
[1]University of Campania "Luigi Vanvitelli",
Department of Woman- Child and General and Specialized Surgery-, Naples, Italy
[2]Istituto Nazionale Tumori IRCCS "Fondazione G. Pascale"-, Gynaecology Oncology Unit, Naples, Italy
[3]Istituto Nazionale Tumori IRCCS "Fondazione G. Pascale", Gynaecology Oncology Unit, Naples, Italy
[4]Istituto Nazionale Tumori IRCCS "Fondazione G. Pascale" and University of Campania "Luigi Vanvitelli ", Gynaecology Oncology Unit and Department of Woman- Child and General and Specialized Surgery- , Naples, Italy

Background

Minimally invasive surgery represents the standard approach for early-stage endometrial cancer. Recently, transvaginal endoscopic surgery is an emerging ultra-minimally invasive scarless technique. The transvaginal single-port robotic approach potentially combines robotic technology with scarless surgery; however, data on staging procedures remain limited. The aim of this video article is to demonstrate the feasibility and to show the surgical steps of transvaginal single-port robotic staging surgery of endometrial cancer, including bilateral sentinel lymph node mapping.

Methods

We present the case of a 46-year-old woman with low-grade endometrioid endometrial carcinoma. Preoperative imaging showed no evidence of extrauterine disease or abdominal lymphadenopathy. The patient underwent transvaginal single-port robotic surgery using the Da Vinci SP platform (Intuitive Surgical Inc., Sunnyvale, CA, USA) at the National Cancer Institute of Naples, Italy.

Results

After posterior colpotomy and transvaginal access to the pouch of Douglas, indocyanine green was injected into the uterine cervix, and the single-port robotic device was introduced. Subsequently, the Da Vinci SP platform was docked. Bilateral pelvic retroperitoneal spaces were developed, and Firefly® fluorescence imaging allowed bilateral identification of sentinel lymph nodes along the external iliac vessels. Sentinel lymph nodes were safely dissected, preserving surrounding vascular and nervous structures. The robotic platform was repositioned circumferentially around the cervix, and circumferential colpotomy was completed. Radical type A colpohysterectomy with bilateral salpingo-oophorectomy was performed. The procedure was successfully completed through a transvaginal single-port robotic approach without any other surgical access. Estimated blood loss was 20 mL, and no intra- or postoperative complications occurred. Final histology confirmed FIGO stage IA low-grade endometrioid endometrial carcinoma with negative bilateral sentinel lymph nodes.

Conclusions

This video demonstrates the feasibility and safety of transvaginal single-port robotic surgery for staging of early-stage endometrial cancer, allowing adequate retroperitoneal dissection and bilateral sentinel lymph node mapping through a scarless natural orifice approach.

https://player.vimeo.com/video/1191290150?autoplay=1

ESGE35-0230 -
Best Selected Videos 1

Robotics Redefining Secondary Cytoreduction in Ovarian Cancer: Tailored Approach to Deep Pelvis Recurrence

Luca Palmieri[1], Francesco Santullo[2], Camilla Certelli[1], Riccardo Oliva[1], Anna Fagotti[1], Valerio Gallotta[1]
[1]Fondazione Policlinico Universitario A. Gemelli IRCCS, Gynecologic Oncology Unit, Rome, Italy
[2]Fondazione Policlinico Universitario A. Gemelli IRCCS,
Surgical Unit of Peritoneum and Retroperitoneum, Rome, Italy

Background

Secondary cytoreductive surgery for isolated platinum-sensitive pelvic recurrence of high-grade serous ovarian cancer (HGSOC) requires complete oncologic resection within a distorted and fibrotic pelvis. Prior radical surgery transforms the operative field into a hostile environment where conventional laparoscopy is limited by reduced dexterity and unstable visualisation. Robotic technology - with high-definition three-dimensional optics, tremor filtration, and wristed instrumentation - may enhance precision in deep pelvic compartments. We present a robotic-assisted secondary cytoreduction for isolated mesorectal recurrence in a BRCA1-mutated patient after a long disease-free interval.

Methods

A 48-year-old BRCA1-mutated woman previously treated for FIGO IIA high-grade serous ovarian cancer (radical hysterectomy type A, bilateral salpingo-oophorectomy, pelvic and para-aortic lymphadenectomy, infracolic omentectomy, adjuvant carboplatin/paclitaxel, maintenance immunotherapy) developed imaging-confirmed isolated deep pelvic recurrence 9 years and 5 months later. Tumour markers were normal. PET-CT revealed an isolated hypermetabolic mesorectal lesion. MRI localised recurrence along the anterior mesorectal fascia. Ultrasound demonstrated a fixed right pararectal mass (40 × 21 × 30 mm). After multidisciplinary tumour board evaluation and confirmation of resectable isolated disease, robotic secondary cytoreduction was undertaken. The robotic system provided stable magnified 3D visualisation of the deep pelvis. Instrument articulation enabled controlled dissection within the pararectal and mesorectal planes, overcoming fibrosis from prior surgery. Tremor filtration and instrument stability allowed meticulous separation of tumour from the mesorectal fascia, iliac vessels, ureter, and autonomic nerve fibres. En bloc rectosigmoid resection was completed robotically, as well as a tension-free end-to-end colorectal anastomosis.

Results

Complete macroscopic cytoreduction was achieved. The robotic platform enhanced exposure of narrow lateral pelvic compartments and facilitated precise dissection in proximity to critical vascular, neural, and urinary structures. Articulated instrumentation allowed safe execution of mesorectal mobilisation in a confined, previously operated field. No intraoperative complications occurred. Postoperative recovery was uneventful, with restoration of bowel function and the patient was discharged on postoperative day 4. Final pathology confirmed isolated pelvic recurrence of high-grade serous ovarian cancer with negative margins.

Conclusions

In accurately selected patients with isolated ovarian cancer recurrence, secondary cytoreductive surgery can be considered when complete macroscopic resection can be achieved. Robotic technology enhances precision in a hostile pelvic field. Augmented depth perception, tremor elimination, and articulated instrument control provide distinct technical advantages for deep dissection and rectosigmoid resection. Preoperative 3D reconstruction transforms technical complexity into a tailored and structured surgical approach. Advanced robotic platforms may expand the boundaries of secondary cytoreductive surgery in recurrent ovarian cancer when performed in high-volume tertiary centres.

https://player.vimeo.com/video/1191306672?autoplay=1

ESGE35-0439 -
Best Selected Videos 1

ICG-guided nerve-sparing pelvic and para-aortic lymphadenectomy for early-stage ovarian cancer staging with a RAS platform

Davide Arrigo[1], Andrea Rosati[2], Riccardo Oliva[2], Sara Mastrovito[2], Francesco Fanfani[1], Anna Fagotti[1]
[1]Fondazione Policlinico Universitario A. Gemelli IRCCS - Università Cattolica del Sacro Cuore, Department of Woman- Child and Public Health, Rome, Italy
[2]Fondazione Policlinico Universitario Agostino Gemelli IRCCS, Department of Woman- Child and Public Health, Rome, Italy

Background

Comprehensive surgical staging is central to the management of early-stage epithelial ovarian cancer (EOC), with systematic pelvic and para-aortic lymphadenectomy supporting accurate FIGO classification and adjuvant treatment planning. Minimally invasive staging has expanded, offering reduced morbidity and faster recovery while maintaining oncological safety. Robotic platforms further facilitate complex retroperitoneal dissection through three-dimensional visualisation and articulated instruments. The HUGO™ RAS system (Medtronic), with modular arm configuration and multi-quadrant accessibility, may support staging procedures. Indocyanine green (ICG) fluorescence provides real-time anatomical guidance and may assist nerve-sparing lymphadenectomy by improving visualisation of lymphatic, vascular, and neural structures. We report a case of ICG-guided nerve-sparing pelvic and para-aortic lymphadenectomy using the HUGO™ RAS platform for early-stage EOC staging.

Methods

A 45-year-old patient (BMI 27 kg/m²) presented with bilateral adnexal masses suspicious for malignancy. Diagnostic laparoscopy with bilateral adnexectomy was performed, and frozen section suggested a possible secondary metastatic tumour. Gastroscopy and colonoscopy excluded a non-gynaecological primary, while final histology confirmed ovarian grade 2 endometrioid adenocarcinoma. Robotic radical staging surgery was planned. After four-arm docking of the HUGO™ RAS system, ICG was injected cervically to map lymphatic drainage. Systematic pelvic and para-aortic lymphadenectomy was performed using an ICG-assisted nerve-sparing technique, with en-bloc nodal removal and continuous fluorescence guidance to identify and preserve adjacent vascular and neural structures.

Results

Total operative time was 205 minutes, and estimated blood loss was 150 mL. No intraoperative or postoperative complications occurred, and the patient was discharged on postoperative day 3. ICG fluorescence enabled real-time visualisation of lymphatic channels and nodal tissue boundaries, supporting precise nodal dissection and selective preservation of adjacent vascular and neural structures.

Conclusions

ICG-guided nerve-sparing pelvic and para-aortic lymphadenectomy using the HUGO™ RAS platform was safe and feasible for early-stage EOC staging. Larger series are needed to confirm reproducibility and assess oncological and functional outcomes.

https://player.vimeo.com/video/1191629442?autoplay=1

ESGE35-0841 -
Best Selected Videos 1

Laparoscopic Interval Debulking Surgery for Advanced Ovarian Cancer: Surgical Technique within the LANCE Trial Protocol

Luca Palmieri[1], Camilla Certelli[1], Claudio Lodoli[2], Riccardo Oliva[1], Anna Fagotti[1], Valerio Gallotta[1]
[1]Fondazione Policlinico Universitario Agostino Gemelli IRCCS- Rome- Italy,
Department of Women and Children- Gynecologic Oncology Unit, Roma, Italy
[2]Fondazione Policlinico Universitario Agostino Gemelli IRCCS- Rome- Italy,
Surgical Unit of Peritoneum and Retroperitoneum, Roma, Italy

Background

Primary cytoreductive surgery followed by chemotherapy is the standard for advanced epithelial ovarian cancer (EOC). However, randomised trials show that neoadjuvant chemotherapy (NACT) before surgery reduces morbidity and improves quality of life without compromising survival. In patients with complete or near-complete response to NACT, minimally invasive surgery (MIS) achieves comparable cytoreduction and survival outcomes to laparotomy, with reduced morbidity. The ongoing international LANCE trial aims to confirm the noninferiority of MIS versus laparotomy in the interval debulking surgery (IDS) setting. However, there are few video articles providing a detailed step-by-step demonstration of the surgical technique.

Methods

We report the case of a 52-year-old woman with FIGO stage IIIC high-grade serous EOC who received three cycles of platinum-based NACT. Following multidisciplinary tumour board discussion, interval debulking surgery was recommended, and the patient was enrolled in the LANCE trial protocol. She was randomised to the experimental arm and underwent MIS. A minimally invasive cytoreduction was performed and systematically documented, providing a stepwise description of the laparoscopic approach.

Results

Complete cytoreduction was achieved with no intraoperative or postoperative complications. Estimated blood loss was negligible, and postoperative recovery was uneventful. Histopathological analysis confirmed FIGO stage IIIC HGSOC, BRCA wild-type, and HRD negative. The patient subsequently received platinum-based adjuvant chemotherapy and is currently on maintenance therapy with niraparib.

Conclusions

This video demonstrates the use of MIS for interval debulking surgery in selected patients with advanced EOC treated within a clinical trial. Compared with open surgery, MIS offers reduced morbidity, shorter hospitalisation, and faster recovery. However, long-term oncologic comparability to laparotomy is still under evaluation.

https://player.vimeo.com/video/1195686390?autoplay=1

ESGE35-0848 -
Best Selected Videos 1

Robotic-assisted ICG-Guided Sentinel Lymph Node Biopsy for Vulvar Cancer: a step-by step surgical technique

Angelica Naldini[1], Giacomo Guidi[1], Francesca Romana Scanu[1], Stefano Di Berardino[1], Matteo Pavone[1], Anna Fagotti[1]
[1]Fondazione Policlinico Universitario A. Gemelli- IRCCS,
Dipartimento di Scienze per la salute della Donna e del Bambino, Rome, Italy

Background

Sentinel lymph node (SLN) biopsy represents the standard nodal assessment for patients with early-stage vulvar carcinoma measuring <4 cm and without clinical or radiological evidence of nodal metastasis. Minimally invasive video-endoscopic and robotic approaches may reduce surgical morbidity while maintaining accurate nodal mapping. This study aimed to demonstrate the surgical technique and feasibility of bilateral robotic-assisted video-endoscopic inguinal sentinel lymph node biopsy using indocyanine green (ICG) fluorescence in early-stage vulvar carcinoma

Methods

A step-by-step educational surgical video was developed at a tertiary referral centre for gynecologic oncology. The procedure was performed in a 78-year-old woman with a 3.5 cm midline vulvar cancer. Bilateral robotic-assisted video-endoscopic inguinal sentinel lymph node biopsy was performed using the da Vinci Xi Surgical System, combining ICG fluorescence and radioactive tracer mapping. The video demonstrates trocar placement, robotic docking, development of the inguinal working space, fluorescence-guided SLN identification with Firefly® imaging, and gamma probe confirmation of node retrieval.

Results

On the day of surgery, 99mTc radiocolloid was injected in the peritumoral area, followed by intraoperative administration of ICG (2.5 mg/mL) around the tumour. Three 8-mm robotic trocars were positioned, including one at the apex of the femoral triangle and two bilateral trocars. After robotic docking, the working space was developed, and bilateral blunt dissection was performed to expose the inguinal nodal basin. SLNs were successfully identified bilaterally using Firefly® imaging and gamma probe detection and safely removed without vascular or lymphatic injuries. No intraoperative or postoperative complications occurred.

Conclusions

Robotic-assisted video-endoscopic bilateral inguinal sentinel lymph node biopsy using ICG fluorescence appears to be a feasible and safe minimally invasive approach in selected patients with early-stage vulvar carcinoma. Enhanced visualisation and precise lymphatic dissection provided by the robotic platform may optimise sentinel lymph node detection while potentially reducing postoperative morbidity compared with conventional open surgery.
https://player.vimeo.com/video/1195700804?autoplay=1

ESGE35-0872 -
Best Selected Videos 1

LAPAROSCOPIC APPROACH TO PARA-AORTIC LYMPH NODE RECURRENCE: EN BLOC NERVE-SPARING RESECTION WITH VIRTUAL REALITY SUPPORT

Andrea Rosati[1], Vincenzo Pio Maria Penza[1], Guido Lancellotti[1], Matteo Figà[1], Virginia Vargiu[1], Anna Fagotti[1]
[1]Fondazione Policlinico Universitario A. Gemelli- IRCCS- Roma- Italy.,
Woman- Child and Public Health Department, Rome, Italy

Background

Tertiary cytoreductive surgery (TCS) for recurrent ovarian cancer may be a valid option in highly selected cases of single or oligometastatic relapse. The aim of this video is to demonstrate the feasibility of TCS supported by preoperative 3D reconstruction and intraoperative ultrasound (US) guidance.

Methods

We present the case of a woman in her 70s with a single platinum-sensitive ovarian cancer recurrence. Preoperative positron emission tomography identified a solitary left para-aortic lymph node recurrence. After 3D reconstruction, a minimally invasive TCS with intraoperative US guidance was performed.

Results

Complete cytoreduction was achieved. The operative time was 280 minutes, and the estimated blood loss was 100 mL. No intraoperative complications occurred. Histopathological examination confirmed metastatic involvement of the resected lesion.

Conclusions

A minimally invasive approach can be considered for tertiary ovarian cancer recurrence in carefully selected patients treated in high-volume oncologic centres with multidisciplinary expertise. Patient selection, meticulous preoperative planning using 3D reconstruction, and intraoperative ultrasound guidance should be integrated to optimise surgical precision and oncologic safety.

https://player.vimeo.com/video/1195724165?autoplay=1

ESGE35-0047 -
Best Selected Videos 2

NOSE technique for double bowel nodule with double bowel anastomosis in deep endometriosis case.

Ewa Milnerowicz-Nabzdyk[1], Mariusz Kasperski[2], Krzysztof Nowak[3], Aneta Machnicka-Rusek[4]
[1]Opole Oncology Centre- Medical Faculty Opole University,
Gynaecological Oncology Department and Referral Endometriosis Centre, Opole, Poland
[2]Opole Oncology Centre- Medical Faculty- Opole University,
Gynaecological Oncology Department- Referral Endometriosis Centre, Opole, Poland
[3]Opole Oncology Centre- Medical Faculty- Opole University,
Gynaecological Oncology Department- Referral Endometriosis Centre, Opole, Poland
[4]Opole Oncology Centre- Medical Faculty- Opole University,
Gynaecological Oncology Department - Referral Endometriosis Centre, Opole, Poland

Background

Debate continues over the optimal surgical approach for rectal and sigmoid endometriosis. The NOSE technique is widely used by many endometriosis surgeons, but evidence on its application in multisegmented resections of bowel remains limited.
This video presents a step-by-step description of the total laparoscopic procedure of double segmental resection due to an endometriosis recto-sigmoid nodule and ceco-intestinal nodule with simultaneous hysterectomy due to adenomyosis, using natural orifice specimen extraction.

Methods

Setting: Of 425 patients with bowel endometriosis operated at the Referral Endometriosis Centre in Opole, Poland, we identified 57 such cases which needed simultaneous multisegmented bowel resections with two bowel anastomoses. This video presents the most useful, in our opinion, technique for ceco-ileal and recto-sigmal double location of nodules, for women who no longer desire future pregnancies. All presented technique were performed by qualified team of gynaecologists specialised in endometriosis surgery with subspeciality in gynecological oncology who performed in this the same team 500 resections of a bowel in deep infiltrated endometriosis during last 6 years. We used a laparoscopic towel STORZ Rubina with ICG . All procedures were performed using only two 5-mm, one 10-mm, and one 12-mm trocars. All specimens were extracted through the vagina which was later closed with two layers of suture. We used a linear 60 mm stapler and a circular stapler for low sigmo-rectal anastomosis, and only 60 mm linear stapler with 3 shots for ileo-colic anastomosis after removal of ceco-ileal segment of bowel. All staplers were from Medtronic brand.

Results

Intervention: A 36-year-old woman suffering from dyschezia 9/10, dysmenorrhea 9/10, dysuria 3/10, dyspareunia 2/10, with critical stenosis of the bowel and colic pain in the right middle abdomen, was admitted for planned surgery. She had a 7-cm endometriotic nodule involving the rectum and sigmoid colon, causing 80% stenosis and located 97 mm from the anorectal junction, along with an

adenomyotic uterus and two additional stenotic nodules on the cecum and ileum. The procedure included a stepwise end-to-end anastomosis using a 33-mm circular stapler, a total hysterectomy, and a resection of the ileocecal segment with the same trocars, followed by a fully intracorporeal side-to-side anastomosis. All procedures used ICG to assess vascularity. The anastomosis was covered with fibrin glue. The operating time of this multiorgan surgery was 3h15min. The patient was discharged on postoperative day 3 after passing stool, without complications.

Conclusions

Conclusion: A laparoscopic approach performed by an experienced, skilled team is highly effective for multiorgan surgery. The NOSE technique further enhances outcomes by providing a tailored and beneficial method across multiple surgical aspects, even for more than one resection and anastomosis on a bowel.

https://player.vimeo.com/video/1187778087?autoplay=1

ESGE35-0061 -
Best Selected Videos 2

Sacrospinous ligament suspension via vNOTES for the management of pelvic organ prolapse

Emre Biton[1], Serkan Ustuntas[2], Kemal Gungorduk[3]
[1]Mugla Sitki Kocman University, Department of Obstetrics and Gynaecology, Mugla, Türkiye
[2]Mugla Sıtkı Koçman University, Department of Obstetrics and Gynaecology, Muğla, Türkiye
[3]Mugla Sıtkı Koçman University,
Department of Obstetrics and Gynaecology, Division of Gynaecologic Oncology, Muğla, Türkiye

Background

Pelvic organ prolapse (POP) can result in urinary and faecal incontinence, among other symptoms that greatly diminish quality of life, often leading to anxiety, depression, and emotional distress for many patients. The trans-vaginal sacrospinous ligament suspension (VSSLS) procedure involves attaching the apex of the prolapsed vagina to the sacrospinous ligament. This technique works to reestablish the natural alignment of the vaginal axis, repair defects in the pelvic floor, and restore its normal function, contributing to a reduction in patients' anxiety and depressive symptoms. While VSSLS offers certain benefits, such as avoiding the need for an abdominal approach, eliminating the use of mesh or grafts, and preserving vaginal anatomy, it also has limitations, including restricted visualisation and the potential for risks associated with blind dissection. On the other hand, transvaginal natural orifice transluminal endoscopic surgery (vNOTES) provides a minimally invasive technique with improved anatomical visualisation.

Methods

A comprehensive case report supplemented by a video demonstration showcasing a step-by-step approach to performing a surgical technique for treating POP. The patient has given her consent for her images and other clinical information to be reported in the abstract.

A 67-year-old postmenopausal woman, G2P2(SVD), was referred to our clinic with progressive pelvic pressure, a sensation of vaginal fullness, and a palpable vaginal bulge. On examination in the dorsal lithotomy position and during a sustained Valsalva manoeuvre, she had a procidentia (Stage 4) uterovaginal prolapse (Figure 1a). The relevant surgical anatomy of the sacrospinous ligament and adjacent neurovascular structures (sacral plexus, internal pudendal vessels, and ischial spine) was used pre-operatively to plan the placement of the apical anchoring suture 1.5–2 cm medial to the ischial spine, away from the pudendal neurovascular bundle.

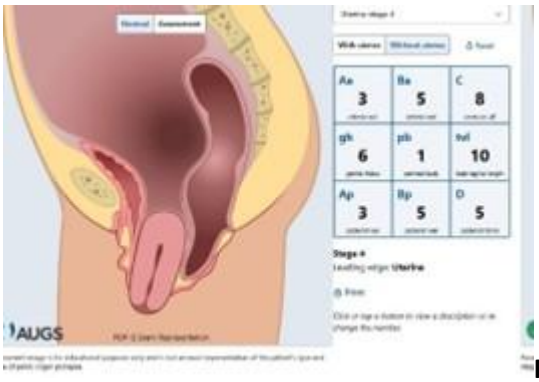

Results

Steps:

1-Patient positioning and preparation

2-Posterior colpotomy and access to the right pararectal space

3-GelPOINT placement

4-Endoscopic dissection of the pararectal space and exposure of the sacrospinous ligament

5-Sacrospinous ligament suture placement

6-Vaginal hysterectomy.

7-vNOTES bilateral salpingo-oophorectomy.

8-Anterior compartment repair.

9-Vaginal cuff closure with apical anchoring.

The post-operative course was uneventful. The patient was mobilised on the day of surgery; the Foley catheter was removed on post-operative day 1, and she was discharged in satisfactory condition without rectal pain, gluteal pain, or new-onset urinary symptoms; at the six-week follow-up, examination showed an anatomically restored vaginal axis with no recurrent prolapse and no apical or posterior dehiscence.

Conclusions

vNOTES sacrospinous ligament suspension performed at the time of vaginal hysterectomy and bilateral salpingo-oophorectomy is a feasible, mesh-free, and anatomically precise approach to apical pelvic-organ-prolapse repair. Compared with conventional blind transvaginal SSLS, the vNOTES route allows the sacrospinous ligament and the surrounding pudendal and gluteal neurovascular to be exposed under direct endoscopic vision, supporting safer needle placement.

https://player.vimeo.com/video/1188846134?autoplay=1

ESGE35-0120 -
Best Selected Videos 2

Single port robotic management of severe endometriosis

Masaaki Andou[1], Yoshifumi Ochi[1], Yoshiko Kurose[1], Mari Sawada[1], Kiyoshi Kannno[1], Tsutomu Hoshiba[1]
[1]Kurashiki Medical Centre, Gynaecology, Kurashiki-shi, Japan

Background

This presentation aims to show the potential of robotic surgery in the management of severe endometriosis such as rectal endometriosis and ureteral endometriosis. The robotic techniques shown were developed through the experience of 200 laparoscopic low anterior resection (LAR) surgeries and 55 ureteral reconstructions.

Methods

Techniques for the management of severe endometriosis using a single-port surgery robot will be shown. One case report is shown. The case presented suffered from ureteral and rectal endometriosis, deep endometriosis, as well as adenomyosis and bilateral ovarian cysts. The case underwent LAR, ureteroneocystostomy, and deep endometrial resection. As the patient (aged 33) wished to preserve their fertility, they did not undergo a hysterectomy.

The surgery required just two abdominal incisions: a 3cm incision in the umbilicus for the DaVinci SP system, and a 1cm incision in the right iliac port used for retraction of the bowel, cutting using a linear stapler, suction and irrigation of the peritoneal cavity, and introduction of suture and needles.

Cutting methods specific to our technique will be shown. For cutting, we do not use monopolar cutting current. Instead, we use the double bipolar method. In this method, the right Maryland forceps are used as the cutting device while the left forceps are used as a coagulator for hemostasis. This allows for small and precise cutting of tissue and can prevent capacitive coupling or current diversion. The minimal thermal spread facilitates fine and safe dissection of the ureter and the bowel. As for the surgical robot, we applied the DaVinci SP (single port) surgical robot.

For the rectal endometriosis, after extensive dissection and mobilisation of the rectum, we resected the pathological segment of the rectum and reconstructed it using a double-stapling technique. For the ureteral endometriosis, after extensive mobilisation of the pelvic ureter, the pathological segment was resected, and ureteral reimplantation was performed via simple ureteroneocystostomy. None of the cases shown in this presentation can be identified and gave their consent for the videos to be used for educational purposes.

Results

Operative time for the presented case was 277 mins and estimated blood loss was 50mL. Only two abdominal incisions were required and the patient recovered without sequel.

Conclusions

Single port robotic surgery is feasible for selected cases of severe endometriosis. These techniques are successful in minimizing the number of abdominal wounds, resulting in an optimal cosmetic result and quick recovery. It is possible to achieve ultra-minimally invasive resection of extensive endometriosis and preserve fertility with the single port robotic approach.

https://player.vimeo.com/video/1190880222?autoplay=1

ESGE35-0167 -
Best Selected Videos 2

Combined robotic excision and suction curettage for a highly vascularized caesarean scar pregnancy presenting as an extra-uterine mass.

Kobe Dewilde[1], Wouter Froyman[1], Thierry Van den Bosch[2]
[1]University Hospitals UZ Leuven, Gynaecology and Obstetrics, Leuven, Belgium
[2]University Hospitals KU Leuven, Gynaecology and Obstetrics, Leuven, Belgium

Background

Caesarean Scar Pregnancy (CSP) is a form of ectopic pregnancy implanted in a uterine scar niche following caesarean delivery. CSP is associated with a higher risk of miscarriage, uterine rupture and progression to placenta accreta spectrum. Management is guided by clinical presentation, patient preference and sonographic features. We present a case of a 31-year-old G2P1 with one previous caesarean delivery, referred to a tertiary university hospital because of a non-vital CSP with a growing extra-uterine highly vascularized mass. Given the extensive vascularity and volume of the mass, the risk of acute torrential bleeding was deemed high and surgical resection was performed.

Methods

In this video we demonstrate a stepwise, combined surgical approach including robotic CSP resection and laparoscopic sonographically guided suction curettage. Informed consent was obtained from the patient. Pre-operative sonography demonstrated a CSP with an intra-uterine gestation sac (25x11x31mm) and amniotic sac, with prominent extra-uterine extension of trophoblastic tissue through the caesarean scar into the right pelvic sidewall (54x44x46mm) close to the uterine artery, internal iliac artery and ureter.

Following placement of a supra-renal Resuscitative Endovascular Balloon Occlusion of the Aorta (REBOA) and bilateral double-J ureteral stents, a robotic assisted laparoscopic temporary clipping of both uterine arteries and utero-ovarian ligaments was performed. After a complete mobilisation of the retro-peritoneal part of the CSP and adhesiolysis from the bladder, the REBOA catheter was inflated. Under direct laparoscopic ultrasound guidance using a flexible drop-in probe, suction curettage of the intra-uterine gestational sac was performed and carboprost (0.25mg) was injected into the myometrium of the uterine fundus. The trophoblastic tissue within the niche could not be aspirated. A Foley catheter was inserted through the cervix and the balloon was inflated within the niche as a visual landmark for the subsequent robotic excision the extra-uterine component of the CSP. After complete resection, uterine reconstruction was completed with multilayer barbed suturing, all within the 20-minute REBOA occlusion window. Haemostasis remained excellent after REBOA deflation and temporary clip removal.

Results

This combined approach enabled controlled resection despite marked vascularization and distorted anatomy. Intraoperative blood loss was minimal (estimated blood loss 150 mL). No intra- or immediate postoperative complications occurred. Intraoperative ultrasound did not demonstrate any residual niche. The patient was discharged 3 days postoperatively.

Conclusions

This video demonstrates a multidisciplinary, stepwise approach integrating vascular control, image-guided curettage, and robotic excision for complex, highly vascular CSP resulting in effective bleeding control, complete and safe resection with single-stage uterine reconstruction.

https://player.vimeo.com/video/1191131876?autoplay=1

ESGE35-0193 -
Best Selected Videos 2

Beyond the laparoscope; A combined robotic-assisted laparoscopic and thoracoscopic approach for the mapping and excision of diaphragmatic endometriosis.

Christina Neophytou[1], *Ismini Panayotidis*[1], *Milena Petrovic*[1], *Kunal Bhakhri*[2], *Ertan Saridogan*[3], *Arvind Vashisht*[1]
[1]*University College London Hospital, Endometriosis & Minimal Access Surgery, London, United Kingdom*
[2]*University College London Hospital, Thoracic Surgery, London, United Kingdom*
[3]*University College London Hospital, Reproductive Medicine- Endometriosis & Minimal Access Surgery, London, United Kingdom*

Background

Thoracic endometriosis is the most common extra-pelvic manifestation of the disease(1). In spite of this, the condition remains under-diagnosed and challenging to manage.

Methods

Here, we present a surgical video demonstrating the combined robotic-assisted laparoscopic and thoracoscopic approach for the mapping and excision of diaphragmatic and pelvic endometriosis. Upon completion of the robotic-assisted laparoscopic excision of all visible pelvic disease, anaesthesia was converted to double-lumen intubation and the patient was repositioned to left lateral decubitus for the thoracoscopic excision of a large full thickness diaphragmatic nodule.

Results

A 33-year-old patient with history of three previous laparoscopies and high anterior resection was referred to our tertiary centre following identification of a 3mm right subdiaphragmatic endometriotic deposit on laparoscopy. She reported cyclical right shoulder tip pain, often excruciating and affecting her breathing. Magnetic resonance imaging demonstrated a 12mm lesion on the posterolateral inner aspect of the liver. On laparoscopy, there was evidence of deep endometriosis in the posterior compartment (right pararectal fossa, right pelvic side wall and right uterosacral ligament) and the left ovary was densely adherent to the left ovarian fossa. Upon mobilisation of the ovaries and visualisation of the ureters with the help of intra-ureteric ICG, all visible pelvic endometriosis was excised. Laparoscopic assessment of the upper abdomen, demonstrated evidence of superficial diaphragmatic deposits on the right hemidiaphragm, following deflection of the liver lobe. Thoracoscopy revealed a large full-thickness diaphragmatic endometriotic lesion, associated with dense adhesions to the liver. This was excised using a permanent cautery spatula. The diaphragmatic defect was repaired with interrupted Ethibond 2/0 sutures with Teflon interposition. A 28F chest drain was placed and removed on postoperative day one, following a normal chest x-ray. Recovery was uncomplicated and the patient was discharged home on day four.

Conclusions

This case demonstrates how laparoscopic assessment alone may underestimate the extent and potentially be deceptive in concealing significant diaphragmatic disease. Cyclical chest symptoms should prompt investigation and possible referral to a thoracic endometriosis surgeon. A multidisciplinary combined minimally invasive surgical approach enables comprehensive evaluation and treatment of symptomatic disease within a single operative setting.

References

1. Andres MP, Arcoverde FVL, Souza CCC, et al. Extrapelvic Endometriosis: A Systematic Review. J Minim Invasive Gynecol. 2020. 27(2):373-389. doi: 10.1016/j.jmig.2019.10.004.

https://player.vimeo.com/video/1191256119?autoplay=1

ESGE35-0207 -
Best Selected Videos 2

Intravenous ICG-Guided Laparoscopic Endometrioma Dissection for Fertility Preservation

Ahkam Göksel Kanmaz[1], Emrah Töz[2], Yaşam Kemal Akpak[2], Eda Güner Özen[3], Özgün Akbaş[4]
[1]İzmir City Hospital, Department of Obstetrics and Gynaecology, İzmir TR-MİGS, Türkiye
[2]İzmir City Hospital, Obstetrics and Gynaecology, İzmir, Türkiye
[3]İzmir City Hospital, Obstetrics and Gynaecology, İzmir, Türkiye
[4]İzmir City Hosptial, Obstetrics and Gynaecology, İzmir, Türkiye

Background

The aim of this video presentation is to demonstrate the surgical applicability and potential fertility-preserving role of intravenous indocyanine green (ICG)-guided fluorescence imaging during laparoscopic dissection of bilateral ovarian endometriomas in an infertile patient.

Methods

A 34-year-old nulliparous woman with primary infertility and bilateral ovarian endometriomas was referred to our tertiary endometriosis unit by the infertility clinic for fertility-preserving surgical management. Following laparoscopic pelvic exploration and adhesiolysis, for fluorescence imaging, 25 mg of ICG was diluted in 10 mL of sterile water, and an intravenous bolus dose of 0.25 mg/kg was administered intraoperatively, and then bilateral endometrioma cystectomy was performed. Near-infrared fluorescence imaging was utilized to assess ovarian perfusion and facilitate identification of the cleavage plane between the endometrioma capsule and healthy ovarian cortex. The entire procedure was recorded in a stepwise surgical video format.

Results

ICG-enhanced fluorescence imaging enabled real-time evaluation of ovarian vascularization and improved delineation of dissection planes during bilateral endometrioma surgery. The technique facilitated complete excision of the cyst wall while supporting maximal preservation of healthy ovarian tissue. No intraoperative complications were observed. Four months postoperatively, the patient underwent oocyte pick-up followed by embryo transfer, resulting in a successful pregnancy and subsequent delivery of a healthy infant.

Conclusions

Intravenous ICG-guided fluorescence imaging may represent a valuable adjunct in fertility-preserving laparoscopic endometrioma surgery by enhancing intraoperative visualisation and optimising ovarian tissue preservation. This approach may contribute to improved reproductive outcomes in infertile patients with advanced endometriosis.

https://player.vimeo.com/video/1191277766?autoplay=1

ESGE35-0412 -
Best Selected Videos 2

Navigating the obstacle: hysteroscopic management of voluntary termination of pregnancy behind a giant previa isthmic myoma

Vito Antonio Quartulli[1], Erika Catania[2], Fabiola Nardelli[1], Cinzia Ferrara[3], Gabriella Sglavo[3], Brunella Zizolfi[1]
[1]University of Naples Federico II, Department of Public Health, Naples, Italy
[2]University of Palermo, Department of Obstetrics and Gynaecology, Palermo, Italy
[3]University of Naples Federico II, Gynaecology and Obstetrics Department, Naples, Italy

Background

The aim of this video-article is to present a minimally invasive, two-step strategy for a complex first-trimester termination of pregnancy (TOP) obstructed by a massive previa isthmic myoma.

Methods

A 41-year-old patient (10+3 weeks of gestation) requested a termination of pregnancy (TOP). Imaging revealed a 10 cm FIGO type 1 previa isthmic myoma completely obstructing the lower uterine segment. Traditional medical management or blind suction carried a high risk of catastrophic hemorrhage and incomplete evacuation. A two-step approach was adopted. First, Uterine Artery Embolization (UAE) was performed to induce foetal demise and reduce vascularity. Second, a sequential ultrasound-guided hysteroscopic approach was utilized. A miniaturized 15 Fr bipolar resectoscope bypassed the myoma to selectively resect the umbilical cord and gestational sac. After careful cervical dilation, a 27 Fr resectoscope completed the mechanical evacuation without suction.

Results

The procedure successfully cleared the uterine cavity under direct visual control. The fluid deficit remained within safety thresholds, with no intraoperative complications reported. A 60-day follow-up, utilising both ultrasound and diagnostic hysteroscopy, confirmed a regularly restored endometrium. Notably, the myoma's size was dramatically reduced to approximately 2.5 cm.

Conclusions

Combining UAE with sequential ultrasound-guided hysteroscopy offers a safe, reproducible, and effective alternative for early pregnancy terminations facing severe anatomical obstacles, drastically reducing surgical risks while preserving long-term fertility.

https://player.vimeo.com/video/1191613593?autoplay=1

ESGE35-0465 -
Best Selected Videos 2

Resection of Diffuse Adenomyosis: Using a Robotic Double-Flap Technique

Taina Rocha[1], Gabriela Asenjo Seoanes Wright[1],
Paula Medina Poeta Fermino[2], Fernanda Dishchekenian[3], Edvaldo Cavalcante[2],
Mariano Tamura Vieira Gomes[3]
[1]Universidade Federal de São Paulo, Gynaecology, São Paulo, Brazil
[2]Hospital Moriah, Gynaecology, São Paulo, Brazil
[3]Einstein Hospital Israelita, Gynaecology, São Paulo, Brazil

Background

Diffuse adenomyosis remains a major therapeutic challenge in patients seeking fertility preservation. This video demonstrates a robotic double-flap resection technique as a uterus-sparing alternative to hysterectomy in a patient with severe symptomatic diffuse adenomyosis.

Methods

A 44-year-old nulligravid patient with severe dysmenorrhea and infertility underwent a three-step approach. Initial hysteroscopy identified focal adenomyosis, and biopsy was performed. Robotic surgery was then carried out using three robotic ports and one hybrid assistant port. Intraoperative laparoscopic ultrasound guided precise localisation and excision of adenomyotic tissue. Bilateral uterine artery clamping, vasopressin infiltration, and tranexamic acid administration were used to minimize blood loss. Following complete resection of the area affected by adenomyosis, uterine reconstruction was performed using a robotic double-flap technique with layered barbed sutures to restore uterine anatomy. Final hysteroscopy confirmed complete removal of the intracavitary lesion.

Results

Total operative time was 5 hours, with estimated blood loss of 750 mL. No intraoperative complications occurred. The patient was discharged on postoperative day two. Thirty-day postoperative magnetic resonance imaging demonstrated reduction in uterine volume, restoration of uterine symmetry, and significant improvement in the adenomyosis pattern.

Conclusions

Robotic double-flap adenomyosis resection appears to be a feasible fertility-preserving alternative for selected patients with diffuse adenomyosis. The combination of robotic surgery and intraoperative ultrasound may facilitate precise excision and satisfactory uterine reconstruction with favourable short-term anatomical outcomes.

https://player.vimeo.com/video/1191651600?autoplay=1

ESGE35-0540 -
Best Selected Videos 2

Navigating the Pelvic Sidewall: Functional and Radical Anatomical Perspectives

Dogan Vatansever[1], Oytun Turkkan[2], Muhterem Melis Canturk[1], Emin Erhan Donmez[1], Burak Giray[1], Cagatay Taskiran[1]
[1]Koc University, Gynaecologic Oncology, Istanbul, Türkiye
[2]Koc University, Gynaecologic Oncology, İstanbul, Türkiye

Background

Navigating the pelvic sidewall requires a mastery of neurovascular corridors, particularly when anatomy is distorted by severe disease or prior surgery. The objective of this educational compilation is to demonstrate the systematic identification of deep pelvic structures using two distinct surgical models: deep endometriosis excision and Laterally Extended Endopelvic Resection (LEER).

Methods

The video is divided into two instructional segments.

The first segment focuses on a 50-year-old patient with somatic leg pain. Viewers should observe the demonstration of **three surgical corridors** to the pelvic floor:

1. 1. Lateral to the external iliac vessels.
2. 2. Between the external and internal iliac systems.
3. 3. Medial to the internal iliac artery and hypogastric nerves. Key highlights include the skeletonisation of the pudendal neurovascular bundle and the identification of the sacrospinous and sacrotuberous ligaments.

The second segment features a 32-year-old patient with recurrent cervical cancer. It demonstrates the anatomical landscape after a LEER procedure, where the internal iliac system has been entirely resected. This segment highlights the radical exposure of the **sacral nerve roots and the ischiadic nerve** deep to the external iliac vessels.

Results

This compilation successfully maps the complex anatomy of the pelvic sidewall from functional preservation to radical oncologic resection.

Conclusions

By understanding these corridors and neurovascular relationships, surgeons can safely approach the pelvic floor, address somatic nerve involvement in benign disease, and achieve clear margins in advanced pelvic malignancies.

https://player.vimeo.com/video/1191685540?autoplay=1

ESGE35-0876 -
Best Selected Videos 2

Anatomy-driven laparoscopic excision of a retroperitoneal hemiuterus between the external iliac vessels in a complete bicorporeal uterus

Camilla Riccetti[1], Sara Mastrovito[1], Davide Arrigo[1], Francesco Fanfani[1], Anna Fagotti[1], Giovanni Panico[1]
[1]Fondazione Policlinico Universitario Agostino Gemelli IRCCS - Università Cattolica del Sacro Cuore, Department of Woman- Child and Public Health, Rome, Italy

Background

Complete bicorporeal uterus results from failed fusion of the Müllerian ducts and may present with surgically relevant pelvic anatomical distortion. This video case report illustrates laparoscopic management of a complete bicorporeal uterus (ESHRE/ESGE U3b), in which the left hemiuterus developed retroperitoneally between the external iliac vessels and was associated with a benign cystic lesion arising from its medial wall.

Methods

A 48-year-old premenopausal woman, with previous caesarean section and left adnexectomy for ovarian cyst, underwent laparoscopic excision of a pelvic cystic lesion. Preoperative 2D/3D transvaginal ultrasound showed a U3b complete bicorporeal uterus and a 6-cm bilocular, avascular, low-level cystic lesion medial to the left hemiuterus, consistent with an adhesional pseudocyst. The retroperitoneal position of the left hemiuterus and its relationship with the external iliac vessels were not identified preoperatively.

Results

At laparoscopy, the right hemiuterus was seen in a median position, with normal adnexa. A cystic lesion arose from the medial aspect of the left hemiuterus, with dense adhesions to the cyst, hemiuterus, and sigmoid colon. Retroperitoneal dissection revealed the key anatomy: the left external iliac vein remained lateral to the hemiuterus, while the left external iliac artery crossed over its anterior surface. The left ureter coursed posteriorly and laterally and was adherent to the hemiuterus, requiring ureterolysis. After adhesiolysis, clipping of feeding branches, cyst detachment, and mobilisation beneath the arterial arch, the left hemiuterus was removed through circumferential colpotomy, followed by colporrhaphy. Operative time was 230 minutes, estimated blood loss was negligible, and discharge occurred on postoperative day 2. Final histology confirmed an endometriotic cyst adherent to the left hemiuterus.

Conclusions

This case demonstrates that Müllerian anomalies may be associated with unexpected, surgically relevant retroperitoneal anatomy. When anatomical distortion is encountered, safe laparoscopic excision requires a stepwise anatomy-driven strategy, with progressive definition of surgical planes before definitive removal.

https://player.vimeo.com/video/1195730022?autoplay=1

BEST SELECTED PhD

ESGE35-0870 -
Best Selected PhD Abstracts

Robotic Management of Advanced Deep Endometriosis: Utility of Near-Infrared Fluorescence Imaging with Intraureteral ICG

Cihan Yuksel[1], *Fatih Sendag*[2], *Kubra Bagci*[3]
[1]*Cihan Yuksel Clinic, Obstetrics and Gynaecology, Izmir, Türkiye*
[2]*Ege University, Obstetrics and Gynaecology, Izmir, Türkiye*
[3]*Kubra Bagci Clinic, Obstetrics and Gynaecology, Izmir, Türkiye*

Aim

In this video presentation, we demonstrate the clinical utility of indocyanine green (ICG) fluorescence imaging in optimising robotic precision for the management of deep endometriosis. In deep endometriosis, anatomical planes are so distorted that even the most experienced surgeon can lose sight of the ureter; however, this technology lifts the fog exactly where the enemy is hiding.

Background

A 44-year-old patient with a history of one caesarean section and laparoscopic appendectomy presented with pelvic pain, including a one-night hospitalisation three days prior due to an acute exacerbation. Ultrasonography revealed a 10 cm right ovarian cyst. It can be noted that the cyst is compatible with an endometrioma and exhibits benign criteria on ultrasound. The patient's pre-operative Enzian score was recorded as A2, B3, C2. Additionally, deep endometriosis was detected during both ultrasonography and clinical examination.

Materials / Patients

Preoperatively, cystoscopy was performed for bilateral ureteral catheterisation using 6 Fr catheters, followed by the administration of 5 cc of indocyanine green.

Methods / Results

This video abstract demonstrates that intraureteral ICG administration provides critical ureteral fluorescence, serving as effective guidance during complex endometriosis surgery. Real-time visualisation of the ureter significantly facilitates tissue dissection, enhancing both procedural efficiency and patient safety.

Complete excision of all detected deep infiltrating endometriosis lesions was performed, along with a right salpingo-oophorectomy due to adnexal involvement, a left salpingectomy due to hydrosalpinx, and a left ovarian cystectomy for a cyst compatible with an endometrioma.

Discussion

Intraoperative ureteral injury is a preventable complication in complex gynaecological procedures.

Real-time near-infrared fluorescence imaging with intraureteral ICG significantly enhances anatomical visualisation.

This approach optimises dissection safety, minimises iatrogenic risks, and potentially reduces postoperative complications.

Conclusion

Incorporating ICG technology into robotic systems represents a substantial advancement for managing challenging pelvic disease.

Prospective multi-centre studies are warranted to further substantiate its long-term clinical efficacy.

Impact on Patients' Health

Although preoperative cystoscopy and ureteral catheterisation add an extra 5 to 10 minutes to the operative time, the enhanced safety and anatomical reassurance they provide far outweigh this minimal burden.
At her 2-month follow-up, the patient reported complete resolution of pelvic pain and dysmenorrhea. The patient reported a significant improvement in her quality of life. Ultrasonography revealed no residual endometriotic lesions.

https://player.vimeo.com/video/1195718460?autoplay=1

ESGE35-0200 -
Best Selected PhD Abstracts

Endoscopic Management of Vesicovaginal Fistulae Following Gynecologic Oncology Surgery: A Contemporary Single-Center Analysis of Surgical Outcomes and Evidence-Based Treatment Strategies

Fidan Novruzova[1], Akbar Ibrahimov[1], Ahliman Amiraslanov[1], Abuzar Gaziyev[1], Malakkhanim Behbudova[1], Zaur Maharramov[1]
[1]Azerbaijan Medical University, Department of Oncology, Baku, Azerbaijan

Aim

To evaluate the clinical characteristics, management strategies, and surgical outcomes of vesicovaginal fistulae (VVF) following complex gynaecologic and oncologic procedures, and to provide evidence-based recommendations for optimal patient care.

Background

Vesicovaginal fistula is a severe and debilitating complication following gynecologic oncology and complex pelvic surgeries. While minimally invasive and endoscopic approaches are gaining prominence in modern pelvic surgery, the optimal management strategy for VVF remains highly dependent on fistula characteristics, prior radiation, and surgical expertise.

Materials / Patients

A retrospective single-centre analysis was conducted on 10 patients diagnosed with post-surgical VVF between 2017 and 2021. Primary surgeries leading to VVF included radical hysterectomy for cervical cancer (n=6), primary cytoreductive surgery for advanced ovarian cancer (n=3), and total laparoscopic hysterectomy for a benign condition (n=1). The mean age of the cohort was 51.2 years.

Methods / Results

Clinical findings, diagnostic methods, treatment approaches, and postoperative outcomes were meticulously evaluated. Initial conservative management with continuous Foley catheterisation was attempted for all patients. When conservative measures failed, surgical repair was performed. Outcomes were assessed using standardised criteria, including anatomical success, functional outcomes, and complication rates.
The mean time from primary surgery to VVF diagnosis was 16.8 days. Conservative management achieved success in 2 out of 10 patients. The remaining 8 patients required surgical intervention. Successful repair was achieved in all surgical cases using individualised approaches: abdominal repair (n=5), vaginal repair via the Latzko procedure (n=2), and laparoscopic repair (n=1). The overall surgical success rate was 100% for the intervention group, with minimal complications. The mean postoperative hospital stay was 6.8 days, and catheterisation duration averaged 14 days.

Discussion

Although endoscopic techniques are the future of gynecologic surgery, the majority of cases in this oncology-heavy cohort required open abdominal or vaginal routes, reflecting the complexity and tissue compromise associated with radical oncologic resections. The high success rate underscores the critical importance of an individualised surgical approach-whether open, vaginal, or laparoscopic-tailored to the specific anatomical defect and the patient's surgical history.

Conclusion

VVF following complex gynecologic procedures can be successfully managed with excellent outcomes by experienced specialists. While conservative management demonstrates limited success, individualised surgical repair achieves high success rates with minimal morbidity.

Impact on Patients' Health

Effective and individualised surgical management of VVF significantly restores urinary continence, eliminates the profound social stigma associated with the condition, and dramatically improves the overall quality of life and psychological well-being of patients recovering from complex gynecologic surgeries.

ESGE35-0204 -
Best Selected PhD Abstracts

Integrating Preoperative Risk Stratification (IOTA ADNEX) with Endoscopic Assessment for Personalised Adnexal Mass Management

Akbar Ibrahimov[1], *Ahliman Amiraslanov*[1], *Abuzar Gaziyev*[1], *Fidan Novruzova*[1]
[1]*Azerbaijan Medical University, Department of Oncology, Baku, Azerbaijan*

Aim

This study aimed to evaluate the diagnostic performance of preoperative ultrasonographic (USG) markers and biochemical parameters in distinguishing between malignant and benign adnexal masses.

Background

Accurate preoperative differentiation of adnexal masses is crucial for appropriate patient management. Nowadays, some researchers have discovered integrating advanced risk stratification tools like IOTA ADNEX with endoscopic assessment to be much more practical and feasible step for approach to adnexal mass.

Materials / Patients

A retrospective cohort study analysed data from 141 patients who underwent surgery for adnexal masses at the Department of Oncology, Azerbaijan Medical University. Data collected included demographics, clinical features, preoperative serum levels of biochemical markers (CA125, CA15-3, CA19-9, AFP, and CEA), and specific ultrasound (USG) findings.

Methods / Results

Postoperative histopathology served as the gold standard, identifying 91 benign and 50 malignant cases. Statistical analyses included the Independent Samples t-test, the Mann-Whitney U test, the Chi-square test, and multivariate backward stepwise logistic regression. The utility of various Risk of Malignancy Indexes (RMI) was also compared.
Malignancy was significantly associated with older patient age ($p = 0.04$), bilateral tumour presentation (44% in malignant vs. 9.9% in benign, $p < 0.05$), and elevated preoperative serum levels of CA125 and CA15-3 ($p < 0.05$ for both). Specific USG features significantly associated with malignancy included the presence of septations, irregular tumour surface, and ascites ($p < 0.05$ for all). Ascites demonstrated the highest predictive value, being present in 94% of malignant cases compared to 2.2% of benign cases ($p < 0.05$). RMI-4 exhibited slightly higher sensitivity (74%) and specificity (84.6%) for malignancy detection compared to RMI-3 (sensitivity 72%, specificity 83.5%). These findings underscore the value of comprehensive preoperative assessment in guiding management decisions.

Discussion

Our findings underscore the value of a multimodal approach, confirming that advanced patient age, bilateral tumour presentation, specific USG markers (notably ascites, septations, and irregular

surfaces), and elevated levels of CA125 and CA15-3 are significantly associated with malignancy. The substantial predictive value of certain USG features identified in our logistic regression analysis aligns well with established knowledge. The presence of ascites yielded the highest odds ratio (OR = 23.22), consistent with numerous studies linking ascites to advanced-stage ovarian cancer and peritoneal involvement.

Conclusion

The integration of patient age, tumour laterality, specific USG characteristics, and selected serum biomarkers significantly enhances the preoperative prediction of malignancy in women presenting with adnexal masses.

Impact on Patients' Health

While acknowledging the superior performance of modern advanced diagnostic modalities, our findings demonstrate that in resource-constrained settings, RMI-based approaches maintain clinical utility where implementation barriers limit access to more sophisticated tools.

ESGE35-0212 -
Best Selected PhD Abstracts

The Impact of Uterine Manipulators in Endoscopic Hysterectomy for Uterine Cancer: Balancing Surgical Efficacy and Oncological Safety

Aygun Hasanova[1], Ahliman Amiraslanov[1], Akbar Ibrahimov[1], Abuzar Gaziyev[1], Fidan Novruzova[1]
[1]Azerbaijan Medical University, Department of Oncology, Baku, Azerbaijan

Aim

This study aimed to compare the surgical and oncological results of total laparoscopic hysterectomy with or without the use of uterine manipulators (UM) in patients with endometrial cancer (EC).

Background

The objective was to assess the impact of UM on lymphovascular space invasion (LVSI) and overall oncological outcomes, thereby balancing surgical efficacy with oncological safety.

Materials / Patients

One hundred seventeen EC patients who underwent total laparoscopic hysterectomy between 2018 and 2024 were retrospectively evaluated. The cohort included patients who received UM during surgery and those who did not.

Methods / Results

Methods*:* Data collected included patient demographics, pathological factors such as myometrial invasion, cervical involvement, adnexal involvement, lymph node metastases, and the presence of LVSI. Recurrence rates and patient mortality were also analysed to assess long-term oncological outcomes. Statistical comparisons were made between the groups with and without UM.
Results: One hundred five (89.7%) of the patients were over 50 years of age, and 102 (87.2%) were in the postmenopausal period. A BMI >30 was observed in 79 (67.5%) patients. Tumour size was larger than 2 cm in 70 (59.8%) of the patients, and FIGO stage I was present in 105 (89.7%) patients. Myometrial invasion >50% was found in 58 (49.6%) patients, cervical involvement in 77 (65.8%) patients, adnexal involvement in 4 (3.4%) patients, and lymph node metastases in 9 (7.7%) patients. LVSI was determined in 77 (65.8%) of the 117 EC patients. LVSI was observed in 81.0% of patients without UM and in 62.1% of patients with UM, but there was no statistically significant difference between the groups. Recurrence was observed in 15 patients, and 12 patients died. No significant relationship was found between the use of UM and an increase in LVSI or adverse oncological outcomes.

Discussion

In this study, we examined the effects of UM on surgical and oncological outcomes in patients with EC. UM was used more frequently in patients with BMI>30, patients with FIGO stage I, and patients who underwent TH BSO+BPLND, and the duration of surgery was shorter in patients using UM. However, no association of UM use with LVSI, recurrence, and survival was observed.

Conclusion

The use of uterine manipulators during laparoscopic hysterectomy for endometrial cancer does not appear to be associated with an increased rate of lymphovascular space invasion or compromised oncological outcomes.

Impact on Patients' Health

Since no statistically significant difference was observed between the groups in terms of pathohistological criteria, the UM can be safely utilised without negatively impacting oncological safety. Before inserting the UM, it is advisable to seal both fallopian tubes proximal to the uterus to prevent transtubal dissemination. Furthermore, placement of the uterine manipulator under laparoscopic visualisation is recommended in all patients.

ESGE35-0525 -
Best Selected PhD Abstracts

Efficacy of Desogestrel in retained products of conception: validation by hysteroscopy and factors associated with treatment failure

Claudia Menchero Sánchez-Migallón[1], José Carlos Vilches[2], Juan Luis Alcázar[3], Luis Alonso[4], Rodrigo Orozco[5]
[1]Quironsalud Málaga, Hysteroscopy, Malaga, Spain
[2]Quironsalud Málaga, Gynaecological oncology, Málaga, Spain
[3]Quironsalud Málaga, Gynaecological ultrasound, Málaga, Spain
[4]Quironsalud Málaga, Hysteroscopy, Málaga, Spain
[5]Quironsalud Málaga, Gynaecology, Málaga, Spain

Aim
To evaluate the efficacy of Desogestrel and identify predictors of treatment failure.

Background

There is no standardised treatment protocol for retained products of conception

Materials / Patients

A total of 47 patients were included, of whom 43 (91.5%) completed the 120-day follow-up.

Methods / Results

An observational study involving 47 patients with retained products of conception (RPOC) treated with Desogestrel and followed up for 120 days. Resolution was assessed by final hysteroscopy. Univariate and multivariate analyses were performed.

Discussion

A total of 47 patients were included, of whom 43 (91.5%) completed the 120-day follow-up.

No clinically relevant attrition bias.

Among the patients who completed the follow-up, the distribution of the Gutenberg classification was: type 0 (18.6%), type 1 (41.9%), type 2 (18.6%) and type 3 (20.9%), with approximately 40% of complex cases (types 2–3). The median size of the placental remnants was 2.3 cm.

At the final hysteroscopy, 28 patients (65.1%) showed complete resolution of the RPOCs, whilst 15 (34.9%) showed persistence.

When analysing treatment efficacy according to the size of the RPOC, patients with remnants ≤3 cm had a higher rate of complete resolution compared with those with remnants >3 cm (75.9% vs 42.9%). A size >3 cm was associated with a higher risk of treatment failure (OR 4.19; 95% CI 1.10–15.9; p=0.034).

Regarding the Gutenberg classification, patients with types 0–1 showed a significantly higher resolution rate compared with types 2–3 (80.8% vs 41.2%). The Gutenberg classification 2–3 was associated with a higher risk of persistent RPOC (OR 6.0; 95% CI 1.55–23.2; p=0.008).

In the multivariate analysis using logistic regression, the Gutenberg classification 2–3 remained an independent predictor of treatment failure (OR 4.72; 95% CI 1.10–20.2; p=0.036). In contrast, the size of the remnants >3 cm did not reach statistical significance after adjustment (OR 2.85; 95% CI 0.65–12.4; p=0.16).

Among patients with persistent RPOC, a reduction in the Gutenberg classification was observed in 12 of the 14 patients analysed (85.7%); the other two already had Gutenberg 0 at baseline, so no worsening was recorded in any case. Notably, all patients with an initial Gutenberg classification of 2–3 showed ultrasound downstaging, reaching a final classification of 0 following treatment. Paired analysis using the Wilcoxon test demonstrated a significant reduction in the Gutenberg classification following treatment with desogestrel ($p<0.001$). These findings suggest that medical treatment could induce a significant reduction in the vascularisation and ultrasound complexity of PCOCs, even in cases with residual persistence.

Conclusion

Desogestrel shows a resolution rate of 65%. The Gutenberg classification is the main predictor of treatment failure, which could help in selecting candidates for medical treatment.

Impact on Patients' Health

The implementation of the Gutenberg classification enables the precise selection of candidates for medical treatment, avoiding unnecessary surgical procedures and optimising surgical safety through vascular downstaging in patients with residual disease.

ABSTRACTS IN PLENARY

ESGE35-0197 -
Artificial Intelligence in Gynaecology

Free Communication: EndoVe: Personalised LLM -Assisted Patient Education for Endometriosis Using MRI and Symptom-Linked Visualisation

Amr Magdi Mohamed Moneib[1]
[1]*London Northwest Healthcare NHS Trust, Obstetrics and Gynaecology, London, United Kingdom*

Background

Effective communication of endometriosis imaging findings remains challenging in routine clinical practice. MRI reports are often highly technical and may not adequately convey disease extent, symptom correlation, or implications for treatment to patients. Variability in patient understanding can negatively affect shared decision-making, informed consent, and engagement with management plans.

Digital technologies and AI-assisted systems offer opportunities to improve personalised patient education by integrating imaging data, symptom profiles, and visual explanatory tools. However, most existing resources remain generic and are not tailored to individual disease patterns.

Methods

To evaluate the feasibility of using a personalised digital platform, EndoVe, to generate individualised educational explanations of endometriosis MRI findings by linking symptom profiles and imaging data to adaptive anatomical models, procedural animations, and curated educational resources.

Results

EndoVe was developed as a computer-based educational platform capable of integrating MRI findings and patient-reported symptoms into a structured visual explanation pathway. MRI-derived disease distribution, including ENZIAN-based compartment involvement, was mapped onto pre-configured anatomical models and explanatory video content.

The platform generated personalised outputs including:

- patient-specific anatomical visualisations,
- symptom-to-disease correlation explanations,
- procedure-specific educational animations,
- and links to validated patient information resources.

Pilot testing assessed technical feasibility, clinician usability, and perceived patient communication value during endometriosis consultations.

Conclusions

EndoVe demonstrates the potential of AI-assisted personalised education tools within gynaecology. Linking MRI findings and symptom profiles to adaptive visual models and targeted educational resources may enhance patient understanding, engagement, and informed decision-making in endometriosis care. Further studies are required to evaluate patient-reported outcomes, comprehension retention, and impact on clinical pathways.

ESGE35-0569 -
Hysteroscopy I GCH I ESGE Session

Free Communication: Outpatient hysteroscopic management of missed abortion: safety, reproductive outcomes and cytogenetic analysis via embryofetoscopy

Enrico Maria Rispoli[1], Danilo Borrelli[1], Federica Cinque[1], Marcello Muzi[1], Alfonso Manzi[1], Maria Chiara De Angelis[2]
[1]University of Naples Federico II, Department of Public Health, Naples, Italy
[2]University of Naples Federico II,
Department of Neuroscience- Reproductive Sciences and Dentistry- School of Medicine, Naples, Italy

Background

To evaluate the safety, feasibility and reproductive outcomes of hysteroscopic evacuation of missed abortion using a mechanical tissue removal device (TRD) and to report outcomes of parallel embryoscopic sampling for cytogenetic analysis.

Methods

This retrospective observational study included women with ultrasound-confirmed missed abortion diagnosed up to 9w+6d who desired fertility preservation, treated hysteroscopically between June 2023 and February 2026. All procedures were performed in an outpatient setting via vaginoscopic approach, without cervical dilation, awake or under sedation. Complete uterine evacuation was achieved with a mechanical TRD, avoiding electrosurgical energy. Prior to evacuation, embryofetoscopy was performed using a 5-mm continuous-flow hysteroscope with a 30-degree–grade optic and 5 Fr working channel. After opening the gestational sac, targeted sampling of embryonic tissue and chorionic villi was performed under direct visualisation, enabling cytogenetic analysis without maternal tissue contamination. All patients underwent ultrasound and outpatient hysteroscopy at 1 and 3 months to assess the uterine cavity. The primary outcome was procedural safety, defined as intra- and postoperative complications, including intravasation, retained tissue and intrauterine adhesions. Secondary outcomes included subsequent pregnancy rate and time to conception. Reproductive follow-up was obtained from clinical records and telephone interviews. Cytogenetic informative rate was recorded as an additional outcome.

Results

Fifty patients (mean age 36,6 ± 4,3 years; with mean gestational age of 7w+6d ± 1w+1d) were enrolled. Forty-one (82%) patients underwent the procedure under sedation, nine (18%) were awake. Mean operative time was 12.8 ± 3.8 minutes. Two minor intraoperative complications occurred (4%; one anaesthesiologic event, one fluid intravasation) with no major surgical complications. Three cases of uterine malformation were identified and further evaluated during follow-up. One and three-month follow-up showed no retained products of conception and no intrauterine adhesions, corresponding to a 100% procedural success rate. Reproductive follow-up was available for 41 women; among 29 actively attempting conception, 79% (23/29) achieved pregnancy, with mean time to conception of 5.7 ± 3.0 months. Cytogenetic analysis was informative in 83.7% of tested cases.

Conclusions

These preliminary data indicate that hysteroscopic evacuation of missed abortion up to 9w+6d using TRD is associated with minimal complication rates and excellent reproductive outcomes. Parallel embryofetoscopy allows reliable and accurate cytogenetic analysis without maternal tissue contamination. Complete uterine evacuation with preserved endometrial integrity at follow up, demonstrated 100% technical success, supporting this approach as an innovative, fertility-sparing and reliable alternative to blind D&C.

ESGE35-0037 -
vNOTES

Free Communication: Extraperitoneal versus Transperitoneal Approach in vNOTES Sacrocolpopexy: A Comparative Pilot Study

Kemal Güngördük[1], Emre Biton[2], Berican Sahin UYAR[2], Serkan Ustuntas[2]
[1]Muğla Sıtkı Koçman University, Gynelogical Oncology, Muğla, Türkiye
[2]Muğla Sıtkı Koçman University, Faculty of Medicine- Department of Obstetrics and Gynaecology, Muğla, Türkiye

Background

Sacrocolpopexy (SC) is the gold standard for treating apical compartment prolapse, consistently yielding superior long-term anatomical and functional results compared to native tissue repair. Determining the optimal sacrocolpopexy approach remains a key discussion in modern pelvic reconstructive surgery. This requires balancing the open abdominal technique's proven anatomical reliability against minimally invasive alternatives' lower morbidity. Current vNOTES sacrocolpopexy techniques primarily utilize a transperitoneal approach, mirroring the intraperitoneal dissection typical of conventional laparoscopic and robotic procedures. To address this critical data gap and inform future definitive trials, this pilot study provides what is, to our knowledge, among the first direct comparisons of extraperitoneal and transperitoneal vNOTES sacrocolpopexy, specifically in the context of simultaneous hysterectomy and bilateral salpingo-oophorectomy (BSO), assessing feasibility, perioperative safety, and short-term outcomes. Our primary objective is to establish crucial baseline data and generate testable hypotheses regarding potential perioperative advantages of the extraperitoneal method, particularly concerning patient positioning and early recovery.

Methods

This retrospective comparative study included 36 patients with advanced pelvic organ prolapse quantification (POP-Q) Stage III or higher who underwent simultaneous vNOTES hysterectomy, bilateral salpingo-oophorectomy (BSO), and SC. The participants were categorized into two groups based on the surgical approach: extraperitoneal (Group A, n=14) and transperitoneal (Group B, n=22). Metrics such as anatomical success, quality of life, and recovery quality were assessed using validated scales: POP-Q, P-QOL, ICIQ-UI SF, QoR-15, and MESH-R.

Results

Baseline demographic and clinical characteristics were similar across the groups. Short-term anatomical success rates at 6 months were comparable between approaches (extraperitoneal 90.8% vs. transperitoneal 91.6%), supporting feasibility rather than differential superiority. The only clear procedural differentiator was Trendelenburg positioning: the extraperitoneal group was maintained at 10°–15° throughout the entire procedure, whereas the transperitoneal group required 25°–30° during the sacrocolpopexy phase. Numerical trends toward shorter operative duration (99.6 vs. 110.4 min; P = 0.185) and earlier first stool (27.7 vs. 34.5 h; P = 0.552) were observed but did not reach statistical significance and must be considered hypothesis-generating only. Perioperative safety profiles were comparable, with no rectal injuries or intra-abdominal abscesses in either group.

Conclusions

This pilot study demonstrates that vNOTES extraperitoneal sacrocolpopexy is feasible and safe in the short term, with 6-month anatomical success rates equivalent to those of the transperitoneal approach. The technique's most substantiated and clinically meaningful distinction is its ability to be performed throughout at a modest Trendelenburg angle (10°–15°), avoiding the steep 25°–30° tilt required by the transperitoneal route—a potential advantage of particular relevance for patients with elevated BMI. Numerical trends favouring the extraperitoneal group in operative time, bowel recovery, and subjective recovery quality were observed but did not reach statistical significance in this underpowered series; these must be regarded strictly as hypothesis-generating and not as evidence of clinical superiority.

ESGE35-0188 -
Society Session I Chinese Session

Risk factors for sentinel lymph node metastasis and the value of molecular subtypes in the risk stratification of endometrial cancer

Yu Zhao[1], *Qiong Zhang*[1]
[1]*The Second Affiliated Hospital and Yuying Children's Hospital of Wenzhou Medical University, Department of Obstetrics and Gynaecology, Wenzhou, China*

Background

To investigate the risk factors associated with sentinel lymph node (SLN) metastasis in endometrial cancer (EC), evaluate the diagnostic performance of sentinel lymph node biopsy (SLNB), and analyze the value of molecular subtypes in risk stratification for SLN metastasis, thereby providing evidence for preoperative risk assessment and individualized treatment strategies.

Methods

Clinical data of 149 EC patients who underwent SLNB at the XX Hospital between January 2021 and December 2025 were retrospectively collected. The histopathological results from subsequent systematic lymphadenectomy or lymph node excision were used as the gold standard to evaluate the diagnostic performance of SLNB. Patients were categorized into SLN-positive and SLN-negative groups based on SLN pathology. Clinical characteristics, serum tumor markers, imaging findings, histopathological features, and molecular subtype data were collected. Fisher's exact test was used for univariate analysis to identify factors associated with SLN metastasis. Firth-corrected logistic regression, with NSMP as the reference, was applied to assess the relationship between molecular subtypes and SLN metastasis risk. Receiver operating characteristic (ROC) curves were plotted and the area under the curve (AUC) calculated to evaluate the discriminative ability of individual indicators and the preoperative risk stratification model.

Results

Among the 149 patients, 15 (10.1%) were SLN-positive. The diagnostic sensitivity, specificity, positive predictive value, negative predictive value, overall accuracy, and false-negative rate of SLNB were 88.24%, 100%, 100%, 98.51%, 98.66%, and 11.76%, respectively. Univariate analysis revealed that serum CA125 >35 U/mL, lymph node enlargement on MRI/CT, high-risk histology, myometrial invasion ≥1/2, cervical stromal invasion, lymphovascular space invasion (LVSI), and molecular subtype were significantly associated with SLN metastasis ($P < 0.05$). Molecular subtype comparison was statistically significant overall ($P = 0.028$). The p53abn subtype exhibited the highest SLN metastasis rate (36.4%), whereas no SLN metastases were observed in patients with the POLE mut subtype. Firth-corrected logistic regression demonstrated that p53abn was a high-risk subtype for SLN metastasis compared with NSMP (OR = 5.27, 95% CI: 1.29–20.22, $P = 0.022$). ROC analysis indicated that LVSI (AUC = 0.829) and myometrial invasion ≥1/2 (AUC = 0.762) were the strongest correlates of SLN metastasis. A preliminary preoperative risk stratification model incorporating p53abn, high-risk histology, and CA125 yielded an AUC of 0.748 (95% CI: 0.604–0.892).

Conclusions

SLNB demonstrates high diagnostic accuracy for assessing lymph node metastasis in EC. Elevated CA125, suspicious lymph nodes on imaging, high-risk histology, deep myometrial invasion, cervical stromal invasion, and LVSI are closely associated with SLN metastasis. Molecular subtype is significantly associated with SLN metastasis, with p53abn suggesting an increased risk. Combining molecular subtyping with clinicopathological and serum biomarkers may facilitate preoperative risk stratification for SLN metastasis and help optimize individualized treatment strategies.

ESGE35-0645 -
Fibroids

Free Communication: Transvaginal ultrasound-guided radiofrequency ablation of uterine fibroids: first Czech clinical experience and establishment of a national proctoring centre

Jan Kostun[1], *Jiri Presl*[1], *Katerina Keplova*[1], *Lucie Betincova*[1]
[1]*University Hospital and Faculty of Medicine in Pilsen- Charles University, Department of Obstetrics and Gynaecology, Pilsen, Czech Republic*

Background

Transvaginal ultrasound-guided radiofrequency ablation (RFA) is a minimally invasive, uterus-sparing treatment option for symptomatic uterine fibroids. We aimed to report the first clinical experience with this technique in the Czech Republic and to describe the establishment of a national proctoring centre.

Methods

Transvaginal ultrasound-guided RFA of uterine fibroids was introduced at the Department of Obstetrics and Gynaecology, University Hospital in Pilsen, on 31 October 2025. Symptomatic patients with fibroids suitable for RFA were evaluated through a dedicated outpatient pathway. Fibroids were classified according to the International Federation of Gynecology and Obstetrics classification. Follow-up was scheduled at 1, 3, 12 and 24 months and included assessment of clinical response, ultrasound-based fibroid regression, safety, postoperative recovery and quality of life using the Uterine Fibroid Symptom and Quality of Life questionnaire. Perioperative and postoperative complications were prospectively recorded.

Results

At the time of abstract submission, 61 patients had undergone transvaginal ultrasound-guided RFA for 71 fibroids, with approximately 40 additional patients scheduled for treatment. Mean patient age was 42.5 years and median age was 43 years. Treated fibroids included FIGO types 3, 4, 5, 6 and 2–5. Mean fibroid diameter was 45.5 mm and median diameter was 40 mm. At 3-month follow-up, mean relative fibroid volume reduction was 60.2% per fibroid and mean relative diameter reduction was 28.2%. No Clavien–Dindo grade II–V complications occurred. Minor postoperative events included transient pelvic pain, mild early postoperative bleeding, dysmenorrhoea and temporarily heavier menstruation. Median sick leave was 5 days.

Conclusions

This first Czech experience suggests that transvaginal ultrasound-guided RFA of uterine fibroids is feasible, safe and well tolerated in appropriately selected patients. Early ultrasound outcomes are encouraging and support continued prospective follow-up. University Hospital in Pilsen has established the first Czech fibroid RFA programme and national proctoring pathway to support wider implementation of this uterus-sparing technique in clinical practice.

ESGE35-0840 -
Bowel and Sexual Function and Dysfunction from a Neuropelveology Point of View

Free Communication: Neurovascular Abnormalities of the Lumbosacral Space and Their Surgical Management

Tamer Seckin[1], Hakan Kula[2], Serin Seckin[3], Pamoukian Vicken[4]
[1]Donald Barbara Zucker School of Medicine, Obstetrics and Gynecology, New York, USA
[2]Endometriosis Foundation of America, Endometriosis Scientific Research Group, New York, USA
[3]Seckin Endometriosis Center, Seckin Endometriosis Center, New York, USA
[4]Lenox Hill Hospital, Vascular Surgery, New York, USA

Background

Neurovascular abnormalities of the lumbosacral space may result from congenital vascular malformations, aberrant vascular anatomy, secondary fibrosis, endometriosis-related inflammatory distortion, prior surgery, or acquired venous collateralization. These abnormalities may alter the relationship between the lumbosacral trunk, sacral plexus, and pelvic vessels, creating significant challenges during advanced pelvic sidewall and neuropelveologic surgery. Accurate recognition of these patterns is essential for safe nerve exposure, vascular control, and nerve-sparing dissection.

Methods

A surgical series of 39 patients who underwent laparoscopic neuropelveologic procedures requiring exposure of the lumbosacral space was evaluated. Intraoperative findings, surgical videos, operative reports, and postoperative follow-up outcomes were reviewed. Vascular variations involving iliac vessels, gluteal vessels, sacral veins, collateral venous pathways, and their relationships with the lumbosacral trunk and sacral nerve roots were analysed. A standardized compartment-based retroperitoneal dissection approach was utilized in all cases to facilitate vascular identification, bleeding control, and preservation of neural structures.

Results

Multiple neurovascular variations and abnormalities were identified within the lumbosacral space, frequently modifying the anatomical relationship between pelvic vessels and the sacral plexus. Enlarged venous channels, aberrant vascular branches, fibrosis, and distorted retroperitoneal anatomy represented the most common intraoperative challenges. Systematic retroperitoneal exposure and early identification of vascular landmarks facilitated safe dissection and improved visualization of the lumbosacral trunk and sacral nerve roots. Tailored surgical strategies based on individual neurovascular anatomy appeared to reduce excessive traction and improve surgical exposure. Detailed surgical outcomes and follow-up analyses are currently in progress and will be presented at the meeting.

Conclusions

Neurovascular abnormalities of the lumbosacral space represent a critical surgical consideration during advanced pelvic sidewall and neuropelveologic procedures. Detailed understanding of

retroperitoneal vascular anatomy, congenital vascular malformations, secondary fibrosis, and acquired anatomical distortion is essential for safe nerve preservation and effective surgical management.

We will present our surgical experience, anatomical findings, management strategies, and follow-up outcomes from a 39-case series.

ESGE35-1008 -
Miscellaneous 1

Free Communication: High weight uteri: a comparative analysis of abdominal, laparoscopic, robotic and vNOTES approaches

Johanna Wagenius[1], Karin Källén[2], Jan Baekelandt[3], Andrea Stuart[4]
[1]Institute of clinical sciences, Department of Obstetrics and Gynaecology- Lund university, Lund, Sweden
[2]Institute of clinical sciences, Center of Reproduction and Epidemiology- Lund University, Lund, Sweden
[3]Institute of Obstetrics and Gynecology, Development and Regeneration- University of Leuven, Leuven, Belgium
[4]Institute of clinical sciences, Department of Obstetrics and Gynaecology- Lund University, Lund, Sweden

Background

The aim was to compare surgical outcome and length of hospital stay in hysterectomy for large uteri (≥500 g) performed using abdominal, laparoscopic, robot assisted and vNOTES techniques.

Methods

A population-based cohort study with prospectively collected data from the Swedish National Registry for Gynecological Surgery between 2021-2025. Inclusion criteria were benign hysterectomies with a uterus weight ≥500g. Surgical outcomes were quantified using crude (RR) and adjusted risk ratios (aRR).

Results

A total of 3763 patients were included, 2058 underwent abdominal, 401 laparoscopic, 1119 robot-assisted, and 185 vNOTES hysterectomies. Procedures lasting <1 hour occurred more frequently with vNOTES (14.6%) than with abdominal (6.8%), laparoscopic (0.5%) or robot-assisted surgery (1.3%). Postoperative complications occurred in 5.9% of vNOTES hysterectomies, compared with 17.7% in abdominal, 15.5% in laparoscopic and 14.0% in robot-assisted hysterectomies. Adjusted risk for postoperative complications was significantly lower with vNOTES compared with abdominal (aRR 0.32; 95%CI 0.18-0.58), laparoscopic (aRR 0.39; 95% CI 0.21–0.72) and robot-assisted surgery (aRR 0.40; 95% CI 0.22–0.72). Intraoperative complications were rare across all groups, with no significant differences. Same-day discharge was achieved in 45.9% of vNOTES cases, versus 0.7% after abdominal,16.0% after laparoscopic and 20.1% after robot-assisted hysterectomy.

Conclusions

In this nationwide Swedish cohort, vNOTES hysterectomy for large uteri (≥500 g) was associated with substantially shorter operative time, lower postoperative complication rates, and a markedly higher likelihood of same-day discharge compared to abdominal, laparoscopic and robot-assisted hysterectomy. These findings support vNOTES as an efficient minimally invasive option for hysterectomy in patients with large uteri.

ESGE35-0692 -
Imaging: Ultrasound Masterclass: Learn Everything About Pre-Surgical Assessment

Free Communication: Laparoscopic Ultrasonography for Radical Myomectomy: Assessing Its Clinical Value in Resecting Multiple Uterine Myomas: A Single-Center Cohort Study

Xiali Xiong[1], Ziyi Zhao[1], Di Zhang[1], Hua Li[1]
[1]Beijing Chao-Yang Hospital- Capital Medical University, Department of Obstetrics and Gynaecology, Beijing, China

Background

Multiple uterine myomas are common benign tumors in women of reproductive age, which can lead to abnormal bleeding, compression symptoms, and reduced fertility. It is difficult to completely remove all myomas under laparoscopy, and the high postoperative recurrence rate seriously affects the quality of life of patients. This study aimed to assess the short-term clinical value of laparoscopic ultrasonography in the minimally invasive surgical management of multiple uterine myomas through laparoscopy.

Methods

A retrospective cohort study included patients who underwent laparoscopic myomectomy for multiple uterine myomas at the Department of Gynecology, Beijing Chaoyang Hospital (October 2022–February 2026). Patients were divided into LUS-guided group (14 cases) and conventional laparoscopic group (control, 56 cases). Clinical data collected included age, surgical indication, obstetric history, myoma characteristics, pre-/postoperative haemoglobin, operative time, excised myoma number, intraoperative blood loss, complications, postoperative recovery indicators, hospitalization expenses, and residual myomas (assessed by transvaginal ultrasonography 1–3 months postoperatively). Myoma excision rate was calculated as (intraoperative excised number/preoperative MRI-detected number) × 100%. Statistical analyses were performed.

Results

The median operative time was longer in the LUS group than in the control group (232.5 [172.5-262.5] min vs. 160.0 [140.0-190.0] min). The number of lesions excised intraoperatively was higher than which in the control group (6 [range 2–23] vs. 4 [range 2–14]), and the surgical cost was correspondingly greater (1.86 [1.55–2.53] ×10,000 CNY vs. 1.46 [1.34–1.82] ×10,000 CNY). However, the median myoma excision rate was significantly higher in the LUS group [125% (range 66.67–188.89%) vs. 80.0% (range 37.5–166.67%)], while the median residual myoma rate was lower (35.71% vs. 78.57%). The maximum diameter of residual myomas was also smaller in the LUS group [10 mm (range 4–13 mm) vs. 16 mm (range 7–39 mm)]. Residual myomas in the LUS group were mainly attributable to clinical decision-making. No endometrial penetration or intraoperative complications occurred in either group. There were no significant differences between the two groups in terms of intraoperative blood loss and postoperative recovery.

Conclusions

Compared with conventional laparoscopic myomectomy for multiple uterine myomas, laparoscopic ultrasound–guided surgery significantly improves the myoma excision rate, reduces the residual myoma rate, and minimizes the size of residual lesions. When performed by experienced surgeons, this approach may enable more complete myoma removal and represents a promising new advancement in minimally invasive gynecologic surgery.

ESGE35-0176 -
Reproductive medicine: Non-Surgical Techniques

Free Communication: A PUMCH Dichotomous Classification and Long-Term Outcomes of Laparoscopically Assisted Uterovaginal Canalization for Congenital Cervical Atresia

Jia Kang[1], *Lan Zhu*[1]
[1]*Peking Union Medical College Hospital, Obstetrics and Gynaecology, Beijing, China*

Background

Congenital cervical atresia is a complex obstructive genital tract malformation associated with hematometra, endometriosis, pelvic adhesions, and infertility. To improve anatomical assessment and individualized management, Peking Union Medical College Hospital proposed a dichotomous classification based on imaging and intraoperative findings, categorizing patients into "gourd-shaped" and "apple-shaped" phenotypes. This study aimed to evaluate the clinical value of this classification and the long-term outcomes of laparoscopically assisted uterovaginal canalization.

Methods

This prospective cohort study included 46 patients with congenital cervical atresia who underwent fertility-preserving laparoscopically assisted uterovaginal canalization and vaginoplasty between 2016 and 2025 at a tertiary referral center. Patients were classified intraoperatively and radiologically into gourd-shaped type, characterized by cervical outlet obstruction with cervical dilatation, or apple-shaped type, characterized by cervical dysplasia or absence without a continuous cervical canal. Clinical characteristics, MRI findings, intraoperative pelvic pathology, perioperative outcomes, and long-term follow-up results were compared between groups.

Results

Among the 46 patients, 35 were classified as gourd-shaped and 11 as apple-shaped. Mean age at surgery was 13.9±3.0 years. Apple-shaped patients had significantly older surgical age and longer diagnostic delay than gourd-shaped patients (both $P<0.001$). MRI demonstrated cervical dilatation and longer cervical sagittal length predominantly in the gourd-shaped group, whereas apple-shaped patients lacked identifiable cervical canal structures. Ovarian endometriosis (63.6% vs 2.9%, $P<0.001$) and moderate-to-severe endometriosis (36.4% vs 8.6%, $P=0.046$) were significantly more common in apple-shaped patients, while hematosalpinx was more frequent in the gourd-shaped group (48.6% vs 9.1%, $P=0.032$). No intraoperative complications occurred. All patients resumed menstruation after surgery. During a mean follow-up of 44.6±31.2 months, long-term complication and reoperation rates were 17.4% and 21.7%, respectively, and only one patient ultimately required hysterectomy. Persistent dysmenorrhea was significantly more frequent in apple-shaped patients at the last follow-up (81.8% vs 32.4%, $P=0.006$).

Conclusions

The PUMCH dichotomous classification reflects distinct anatomical and clinical phenotypes of congenital cervical atresia and may facilitate individualized surgical planning and postoperative management. Laparoscopically assisted uterovaginal canalization is a safe and effective fertility-

preserving procedure that restores menstrual outflow and preserves the uterus in most patients. Apple-shaped patients appear more susceptible to severe endometriosis and persistent postoperative pain, whereas gourd-shaped patients more commonly develop obstructive sequelae such as hematosalpinx.

ESGE35-0290 -
Uterine Disorders

Free Communication: Diagnosis of Chronic Endometritis in infertile women by Hysteroscopy, Immunohistochemistry and Microbiome analysis, Therapy proposals and Fertility outcomes

Eirini Angelidou[1]
[1]*General Clinic Rhodes Greece Euromedica, Gynaecological Department, Rhodes, Greece*

Background

Chronic endometritis (CE) is a persistent inflammation of the endometrium caused by bacteria or other immunological, traumatic factors. CE can be asymptomatic and it is insufficiently investigated, although associated with implantation failure and pregnancy loss. Hysteroscopy and endometrial biopsy (EB) have favourable diagnostic and predictive values in infertile women with immunohistochemistry (IHC) being the golden standard for diagnosis. The therapy is mainly a combination of antibiotics, and protocols have been proposed. However, limited, underpowered studies have validated their effectiveness. This study aims to evaluate prospectively the prevalence of CE in infertile women by hysteroscopy, IHC and microbiome analysis (MA) and to investigate the fertility outcomes after CE therapy.

Methods

400 infertile women (mean age 37 years) underwent hysteroscopy on the 12-20th day of their cycle. Age, Anti-mullerian Hormone, Body Mass Index, diseases, sperm, infertility types were recorded. At the hysteroscopy CE was diagnosed when micro polyps, hyperaemia, stromal edema, strawberry aspect or hemorrhagic spots were seen. EB was taken from all patients and assessed using ICH CD56 for natural killer cells, CD138 for plasma cells, CD3 for T-lymph cells, CD20 for B-lymph cells. EB were also taken for MA. The prevalence of CE was evaluated through hysteroscopy and immunochemistry to be 164/400 (41%). MA real time polymerase chain reaction was positive for more cases than IHC 200/400(50%). After completing the therapy according to the MA and suggestions a control immunohistochemical and microbiome EB with pipelle was done. The patients were followed for at least 3 years for fertility results. Spontaneous pregnancies were reported after one year and then intrauterine insemination (IUI) or in vitro fertilization (IVF) were performed in the rest patients and fertility outcomes were reported. The primary end point of the study was pregnancy rate and secondary life birth rate (LPR) and pregnancy loss rate (PLR).

Results

The prevalence of CE was 45%(180/400), 41%(164/400), 50%(200/400) based on hysteroscopy, IHC and MA respectively. The sensitivity, specificity, positive and negative predictive values of hysteroscopy in diagnosing CE were 98%, 93%, 91%, 98% respectively. All patients diagnosed with CE immunohistochemically and MA164/400(41%) and the extra 36 with MA underwent specific antibiotic therapy and probiotics according to their MA for one month, as well as their sexual partners. After completing therapy in 100/164(60,9%) and 22/36(61%) patients CE was no more identified with IHC and /or MA. The rest 64/164(39%) and 14/36(38,8%) needed one or more courses of therapy. In difficult cases we used extra intrauterine antibiotic rinsing with soft insemination

catheters with significant results. 49/122(40%) patients became pregnant spontaneously, 18/73(24,6%) with IUI and 30/73(41%) with IVF. 83/97(85,5%) experienced life births, whereas 14/97(14,4%) miscarriage.

Conclusions

Hysteroscopy with IHC reliably diagnoses CE in infertile women and with MA can control their therapy and improve significantly their fertility.

ESGE35-0133 -
Caesarean section niches: the cutting-edge research

Free Communication: Technical Refinement of the Taurus T Method in Robotic-Assisted Laparoscopic Repair of Caesarean Scar Defect

Yusuke Sako[1]
[1]*St. Luke's International Hospital, Department of Obstetrics and Gynecology, Tokyo, Japan*

Background

The main technical challenges in laparoscopic repair of caesarean scar defect (CSD) include bladder dissection, accurate identification and excision of the scar lesion from the abdominal side, and myometrial closure. At our institution, the Taurus T method has been developed and standardized to enable precise localization and resection of the lesion. This report describes the robotic-assisted application of this technique and evaluates its potential technical advantages.

Methods

A 42-year-old woman, gravida 1 para 1, presented with secondary infertility and persistent brown discharge after menstruation. Transvaginal ultrasonography showed fluid retention within the CSD and uterine cavity, with a markedly thin residual myometrial thickness (RMT) of 1.1 mm. Robotic-assisted laparoscopic repair was performed using the Da Vinci Xi system. After bladder dissection, the scar lesion was provisionally identified from the abdominal side under hysteroscopic guidance using near-infrared fluorescence imaging. While confirming the lesion hysteroscopically, straight needles were inserted from the abdominal side at the cephalad and caudal margins of the defect as resection landmarks. After excision of the lesion, the myometrium was repaired by two-layer closure.

Results

The total operative time was 207 minutes, including 117 minutes of console time. Blood loss was 5 mL, and no perioperative complications occurred. Three months postoperatively, the RMT had increased to 10.9 mm, brown discharge had completely resolved, and the patient resumed infertility treatment.

Conclusions

Robotic-assisted application of the Taurus T method appeared to provide several technical advantages. The magnified close-up view facilitated bladder dissection. Near-infrared fluorescence imaging provided clearer scar visualization than conventional hysteroscopic transillumination. Articulated instruments enabled accurate needle marking, precise monopolar scissors angulation during scar excision, and meticulous myometrial suturing. Transvaginal suction through the cervical canal effectively evacuated surgical smoke and maintained a clear operative field. This approach may further improve the precision of CSD repair and reduce its technical difficulty.
https://player.vimeo.com/video/1190927428?autoplay=1

ESGE35-0448 -
Endometriosis 1

Free Communication: Robotic Sacrocolpopexy with RAS in Deep Endometriosis: Deep Uterosacral Ligament "Jumping" for Safe Access to the Rectovaginal Septum

Giovanni Panico[1], Sara Mastrovito[2], Davide Arrigo[3], Camilla Riccetti[4], Alfredo Ercoli[5], Francesco Fanfani[3]
[1]Fondazione Policlinico Universitario A. Gemelli IRCCS, UOC Uroginecologia e Chirurgia Ricostruttiva del Pavimento Pelvico- Dipartimento di Scienze della Sal ute della Donna- del Bambino e di Sanità Pubblica, Rome, Italy
[2]Fondazione Policlinico Universitario Agostino Gemelli IRCCS, Department of Woman- Child and Public Health, Rome, Italy
[3]Fondazione Policlinico Universitario A. Gemelli IRCCS - Università Cattolica del Sacro Cuore, Department of Woman- Child and Public Health, Rome, Italy
[4]Fondazione Policlinico Universitario Agostino Gemelli IRCCS - Università Cattolica del Sacro Cuore, Department of Woman- Child and Public Health, Rome, Italy
[5]Fondazione Policlinico Tor Vergata- Università degli Studi di Roma Tor Vergata, Department of Surgical Sciences- Unit of Gynecology, Rome, Italy

Background

Deep infiltrating endometriosis involving the rectovaginal septum (RVS) may cause severe fibrosis and distortion of posterior pelvic anatomy, increasing the risk of ureteral, rectal, and autonomic nerve injury. Its coexistence with pelvic organ prolapse is rare and surgically demanding, particularly when sacrocolpopexy requires safe access to the posterior compartment. The deep uterosacral ligament (DUSL), a retroperitoneal neurofascial condensation extending from the posterolateral cervix toward S2–S4, may provide a constant anatomical landmark. We present a robotic sacrocolpopexy performed with the Hugo™ RAS platform in a patient with multicompartment prolapse and deep rectovaginal endometriosis, using a standardized DUSL-guided cranial crossing technique for nerve-sparing access to the RVS.

Methods

A stepwise retroperitoneal approach was adopted: right pelvic sidewall opening and rectal mobilization; sacral promontory peritoneal incision; identification of the iliac vessels and ureter; preservation of the hypogastric nerve within Heald's space; identification of the DUSL as a dense band medial to the ureter and lateral to the presacral fascia; controlled cranial crossing of its upper margin to enter an avascular subperitoneal plane; exposure of the RVS; nerve-sparing excision of the rectovaginal nodule; and posterior mesh placement with completion of sacrocolpopexy.

Results

The DUSL was clearly identified and provided a reliable boundary between the presacral space and posterior compartment. Cranial crossing of its upper margin enabled controlled entry into the subperitoneal Douglas pouch despite cul-de-sac fibrosis. The RVS was safely exposed, allowing precise nodule excision with preservation of the ureter and hypogastric nerve. Posterior mesh

placement was completed without rectal injury, ureteral compromise, major bleeding, or other intraoperative complications.

Conclusions

This case suggests that a fascia-based, landmark-driven approach may facilitate safe posterior compartment dissection in complex anatomy. DUSL-guided cranial crossing provides a reproducible strategy for nerve-sparing access to the RVS during robotic sacrocolpopexy.

https://player.vimeo.com/video/1191636988?autoplay=1

ESGE35-0953 -
Oncology 1

Free Communication: Laparoscopic interval cytoreduction after emergency surgery for bowel obstruction in advanced ovarian cancer: an UltraLAP approach

Filippo Cucinella[1], Matteo Marchetti[1], Tommaso Vezzaro[1], Andrea Mura[1], Roberto Tozzi[1]
[1]Department of Gynaecology and Obstetrics- University of Padua,
Division of Women and Children's Health, Padua, Italy

Background

Emergency surgery for bowel obstruction in advanced ovarian cancer may create challenging conditions for subsequent minimally invasive interval debulking because of postoperative adhesions, distorted anatomy and extensive residual disease. This video demonstrates a stepwise laparoscopic interval cytoreductive approach within the UltraLAP protocol in a complex surgical scenario.

Methods

A 65-year-old woman with high-grade serous ovarian carcinoma initially presented with bowel obstruction at the rectosigmoid junction requiring emergency surgery with loop colostomy creation. Following six cycles of neoadjuvant chemotherapy and laparoscopic assessment demonstrating disease amenable to complete cytoreduction, interval debulking surgery was performed within the UltraLAP trial.

The video highlights the principal surgical steps including retroperitoneal access and bilateral ureterolysis, management of a frozen pelvis with rectosigmoid involvement and en bloc pelvic resection. Upper abdominal cytoreduction was subsequently performed with complete gastrocolic omentectomy and right diaphragmatic peritonectomy following liver mobilization and falciform ligament division. Surgical specimens were placed into an endoscopic retrieval bag and extracted through the previously reduced stoma site, avoiding an additional abdominal extraction incision.

Results

Complete macroscopic cytoreduction (R0) was successfully achieved through a fully laparoscopic approach. The previous stoma site was utilized both as a reconstructive access and as a specimen extraction site for the en bloc pelvic specimen and omentum. Final histology demonstrated high-grade serous carcinoma with Chemotherapy Response Score (CRS) 3.

Conclusions

This case illustrates the feasibility of the UltraLAP approach in achieving complete laparoscopic interval cytoreduction even in complex surgical scenarios following previous emergency surgery and temporary stoma creation. When feasible, a structured minimally invasive strategy may allow complete cytoreduction while preserving the potential advantages of laparoscopy.
https://player.vimeo.com/video/1195776501?autoplay=1

ESGE35-0535 -
YEP Session

Free Communication: Retroperitoneal laparoscopic paraaortic lymphadenectomy: step by-step technique

Stamatios Petousis[1], *Chrysoula Margioula-Siarkou*[1]
[1]*Aristotle University of Thessaloniki, 2nd Department of Obstetrics and Gynaecology, Thessaloniki, Greece*

Background

Paraaortic lymphadenectomy consists of a basic staging procedure for early-stage ovarian cancer. Intraperitoneal laparoscopic approach may present difficulties especially in overweight patients. Retro peritoneal approach might be an alternative surgical approach for certain cases. Main objective of this video is to present the step-by-step optimal technique of laparoscopic retroperitoneal paraaortic lymphadenectomy.

Methods

Video file of a 56-patient being restaged after an initial diagnosis of apparent early-stage high-grade ovarian carcinoma was used to perform this video presentation. Video was edited with Windows Movie Maker and voice narration was added to describe main surgical steps to perform the procedure.

Results

There are certain surgical steps that need to be followed to successfully perform method. Dissection of retroperitoneal plan in the left lower abdominal wall is the first and critical step to perform retro pneumoperitoneum. After insertion of trocars, recognition of psoas and left ureter are considered the basic surgical landmarks. Dissection and recognition of left common iliac artery, aorta bifurcation, right common iliac artery and inferior mesenteric artery is necessitated to resect left lower paraaortic, pre sacral and right lower paraaortic lymph nodes. Furthermore, dissection of upper paraaortic area along with extension of left paraaortic lymphadenectomy until recognition of left ovarian vein need to be performed with accuracy. Excision of upper paraaortic nodes with recognition of aorta and vena cava need represent the final surgical steps of the method. Even if retroperitoneal technique may present difficulties regarding the dissection of right lower and upper paraaortic nodal pathway, it is a method with potential superiority to dissect left paraaortic channel until the level of left renal vein.

Conclusions

Retroperitoneal approach of laparoscopic paraaortic lymphade nectomy might be a valuable alternative, especially in overweight patients, to avoid difficulties posed by intraperitoneal technique.

https://player.vimeo.com/video/1191679740?autoplay=1

ESGE35-0580 -
Society Session I SCGP Session

Free Communication: Deep Uterosacral Ligament "Jumping" as a Safe Anatomical Route to the Rectovaginal Septum: A Stepwise Surgical Description

Carolina Dolci[1], Davide Arrigo[2], Anna Fagotti[2], Alfredo Ercoli[2], Francesco Fanfani[2], Giovanni Panico[2]
[1]Jeanne de Flandre Hospital, Gynaecology/Obstetrics Department, Lille, France
[2]Fondazione Policlinico Universitario A. Gemelli- IRCCS, Woman- Child and Public Health Department, Rome, Italy

Background

Safe and reproducible access to the rectovaginal septum (RVS) remains challenging in posterior pelvic surgery, particularly when peritoneal landmarks are unreliable. The deep uterosacral ligament (DUSL), a retroperitoneal neurofascial condensation, may serve as a consistent anatomical landmark to guide entry into the subperitoneal Douglas pouch and RVS while maintaining a nerve-sparing dissection corridor.

Methods

This is a retrospective descriptive anatomical-surgical video analysis in a tertiary referral pelvic floor center including patients undergoing minimally invasive sacrocolpopexy, either robotic or laparoscopic between May and December 2025. Intraoperative video recordings were reviewed to assess DUSL identification and describe a standardized nine-step dissection sequence from lateral peritoneal entry to rectovaginal septum access. Two independent reviewers assessed DUSL identification after a calibration session and recorded the first unequivocal identification within a predefined time tolerance window. A third senior reviewers verified landmark identification and adjudicated disagreements. The key surgical step was DUSL "jumping" manoeuvre, defined as cranial dissection across the superior DUSL margin.

Results

Of 60 screened procedures, 20 met inclusion criteria (10 robotic, 10 laparoscopic). All procedures were completed uneventfully without conversion, and posterior-compartment retroperitoneal structures were exposed in a consistent sequence. DUSL appeared as a dense oblique retroperitoneal band with cranial continuity toward the prerectal fascia. Cranial dissection across the superior margin of DUSL ("jumping" manoeuvre) consistently provided entry into an avascular subperitoneal plane corresponding to the subperitoneal Douglas pouch, ultimately allowing safe access to RVS. DUSL was identified in all 20 cases by both independent reviewers (20/20; 100%).

Conclusions

DUSL represents a consistent anatomical landmark for safe, nerve-sparing access to the posterior pelvic compartment. The "jumping" manoeuvre delineates a protected avascular corridor to the subperitoneal Douglas pouch and RVS. This standardized stepwise approach may enhance surgical safety in complex posterior pelvic dissections; prospective validation in pathological conditions is warranted. https://player.vimeo.com/video/1191696211?autoplay=1

ESGE35-0810 -
Reproductive Medicine and Surgery

Free Communication: Toumai : a novel robotic technique for uterovaginal reconstruction in complex mullerian aplasia, first case

Angelica Naldini[1], Cecilia Angelucci[1,2], Ursula Catena[1], Federica Pozzati[1], Benedetta Gui[3], Francesco Fanfani[1]
[1]Fondazione Policlinico Universitario Agostino Gemelli IRCCS,
Department of Woman and Child Health and Public Health, Rome, Italy
[2]Gynaecological and Obstetrics Clinic, Department of Clinical and Experimental Medicine, Sassari, Italy
[3]Fondazione Policlinico Universitario A. Gemelli IRCCS,
General and Interventional Radiology Unit- Diagnostic Imaging Area- Diagnostic Imaging- Oncological Radiotherapy and Hematology Department, Rome, Italy

Background

We present the case of a 28-year-old woman with a strong desire for pregnancy, affected by a complex Müllerian malformation characterized by cervical aplasia associated with aplasia of the upper third of the vagina and asymmetric uterine anomalies. The patient was undergoing medical therapy with decapeptyl. Initial ultrasound evaluation revealed ovaries in situ, with the right ovary at the upper limit of normal size and showing a polycystic ovary pco-like appearance, while the left ovary appeared cranialized with reduced follicular activity. Imaging demonstrated two uterine buds: the left hemiuterus, larger in size, showed a hyperechoic endometrial signal (4.2 mm), confirming the presence of an endometrial cavity, whereas the right one was smaller and without a clear endometrial signal. No communication was identified between the uterine structures and the vagina, which appeared regular, patent, and approximately 8 cm long. Kidneys were normal.

Gynecological evaluation confirmed normal external genitalia and a regular, patent vagina, with no indication for dilation therapy. Further diagnostic assessment established the diagnosis of cervical aplasia with aplasia of the upper third of the vagina and a left aplastic uterus with a rudimentary cavity not communicating with the vagina (ESHRE/ESGE classification U5a), associated with a right uterine horn without endometrial signal.

Methods

Given the patient's symptoms, anatomical complexity, and reproductive desire, a robot-assisted surgical approach was planned. The procedure, performed under general anesthesia, included examination under anesthesia, hysteroscopy, and robotic surgery using the Toumai platform. Surgical steps consisted of removal of the rudimentary right uterine horn along with the ipsilateral fallopian tube, resection of the aplastic upper vaginal segment, and, as the key reconstructive step, a uterovaginal anastomosis between the functional left uterine cavity and the vagina. At the end of the procedure, a foley catheter (Ch 6) was placed to prevent collapse of the vaginal walls and to maintain patency of the anastomosis.

Results

The surgery was completed without intraoperative complications. The robotic approach enabled precise dissection, improved visualization of pelvic anatomy, and accurate suturing of the anastomosis, all crucial in such complex reconstructions. The postoperative course was uneventful. At the first hysteroscopic follow-up, the foley catheter was removed. A second hysteroscopic evaluation performed 10 days later showed no postoperative complications.

Conclusions

This case highlights the importance of a multidisciplinary approach in managing rare Müllerian anomalies and underscores the role of robot-assisted surgery in the reconstructive treatment of cervical aplasia. Uterovaginal anastomosis represents a conservative option that may restore menstrual outflow and potentially fertility in selected patients. The video illustrates the key surgical steps, providing an educational contribution to the management of these challenging congenital conditions.

https://player.vimeo.com/video/1195635683?autoplay=1

ESGE35-0945 -
Society Session I AGE Session

Free Communication: Single-Port robotic excision of advanced deep endometriosis with rectal and parametrial disease

Mihai Constantin[1], *Petya Tanovska*[1], *Petra Klein*[1], *Harald Krentel*[1]
[1]*Klinikum Aschaffenburg-Alzenau,*
Department of Gynaecology- Obstetrics and Gynaecological Oncology, Aschaffenburg, Germany

Background

Deep infiltrating endometriosis involving the rectum and parametrium represents one of the most technically demanding scenarios in minimally invasive gynaecologic surgery. The role of robotic Single-Port surgery in advanced multicompartment disease remains insufficiently explored. This video demonstrates a fertility-preserving pure single-incision robotic approach for advanced posterior compartment endometriosis with bowel and parametrial involvement.

Methods

We present the case of a 32-year-old infertile patient with advanced multicompartment deep infiltrating endometriosis involving the rectum, rectovaginal septum, posterior vaginal wall and left parametrium. Two previous laparoscopic procedures had described a frozen pelvis with severe posterior compartment disease. Preoperative transvaginal ultrasound demonstrated a 5-centimeter infiltration of the anterior rectal wall and the disease was classified as ENZIAN P2, T3/3, A2, B2/2 and C3.

A robotic Single-Port approach through a single 2.7-centimeter umbilical incision was performed. The video demonstrates adhesiolysis, bilateral ovariolysis, bilateral retroperitoneal nerve-sparing dissection with ureterolysis, excision of left parametrial and rectovaginal disease, partial posterior colpectomy with vaginal closure and segmental rectal resection with intracorporeal stapled end-to-end anastomosis approximately 9 centimetres from the anal verge. Special attention is given to preservation of the hypogastric nerves and uterine vascularization as well as technical adaptation of the Single-Port platform during rectal transection using the Signia stapling device without additional abdominal trocars.

Results

Complete excision of posterior compartment disease with restoration of pelvic anatomy was achieved through a pure single-incision approach. Anastomotic integrity and adequate vascular perfusion were confirmed intraoperatively. Both ureters, uterine vascularization and ovarian tissue were preserved. Estimated blood loss was below 100 millilitres.

Conclusions

Single-Port robotic surgery represents a feasible minimally invasive approach for selected patients with advanced multicompartment endometriosis, enabling complex surgery through a pure single-incision approach while potentially minimizing abdominal wall trauma. Retroperitoneal nerve-sparing

dissection remains essential for complete excision and fertility preservation.
https://player.vimeo.com/video/1195770969?autoplay=1

ESGE35-0952 -
Adhesions

Free Communication: When Surgical Planes Disappear: Advanced Laparoscopic Management In a multiply-operated pelvis with adenomyosis and deep endometriosis

Ercan Baştu[1], Tural Ismayilov[2], Mehmet Ceyhan[1], Emre Kar[3]
[1]Nesta Clinic, Endometriosis and IVF Center, İstanbul, Türkiye
[2]Bingöl State Hospital, Department of Obstetrics and Gynaecology, Bingöl, Türkiye
[3]Çam and Sakura City Hospital, Obstetrics and Gynaecology, Istanbul, Türkiye

Background

Persistent abnormal uterine bleeding accompanied by chronic pelvic pain in patients with multiple prior pelvic surgeries presents a substantial diagnostic and surgical challenge, particularly when distorted anatomy obscures the underlying pathology. We aimed to demonstrate the minimally invasive surgical management of severe endometriosis and adenomyosis in a patient with complex surgical history and treatment-resistant symptoms.

Methods

A 46-year-old woman with a history of in vitro fertilization pregnancy, one caesarean delivery, one prior laparotomy, and multiple previous laparoscopic procedures presented with ongoing heavy uterine bleeding despite two unsuccessful dilatation and curettage procedures, in addition to dyspareunia and severe menstrual pain. Preoperative assessment raised concern for possible pelvic malignancy. Multiport laparoscopy was undertaken under general anesthesia. After abdominal entry, extensive adhesiolysis was performed to release omental and bowel adhesions. Bilateral retroperitoneal dissection with complete ureterolysis to the vesical level was carried out because of severe pelvic fibrosis. Definitive surgical treatment consisted of total laparoscopic hysterectomy with bilateral salpingo-oophorectomy.

Results

Intraoperative assessment revealed advanced pelvic disease with dense adhesive distortion of normal anatomy. The rectosigmoid colon was adherent to the left adnexal region and pelvic sidewall. A 5–6 cm right ovarian cyst was identified, while the left ovary was obscured by adhesions. The uterus appeared globally enlarged and consistent with adenomyosis. Dense bladder adhesions involving the prior caesarean scar required meticulous dissection before hysterectomy could be safely completed. Bilateral uterine vascular pedicles were secured after ureteral identification, allowing safe completion of the procedure without intraoperative complications. Histopathological examination demonstrated adenomyosis, bilateral tubo-ovarian endometriosis, hydrosalpinx, chronic cervicitis, and hypoestrogenic endometrial changes, confirming extensive benign gynecologic disease rather than malignancy.

Conclusions

Complex pelvic symptoms refractory to conservative management may conceal extensive endometriosis even in heavily operated patients with concern for alternative diagnoses. In

experienced hands, advanced laparoscopic surgery with retroperitoneal dissection and ureterolysis enables safe definitive treatment despite severe anatomical distortion. Comprehensive minimally invasive management remains a valuable option in selected complex cases.

https://player.vimeo.com/video/1195776734?autoplay=1

ESGE35-0409 -
Urogynaecology 2

Free Communication: Robotic single-port repair of vesicovaginal fistula

Leonardo Nelva Stelio[1], Luca Calzolari[1], Carmela Quatrale[1], Federica Ottolini[1], Antonio Galfano[2], Federico Spelzini[1]
[1]ASST Grande Ospedale Metropolitano Niguarda, OB/GYN, Milan, Italy
[2]ASST Grande Ospedale Metropolitano Niguarda, Urology, Milan, Italy

Background

Vesicovaginal fistula (VVF) is a distressing condition characterized by continuous urinary leakage due to an abnormal communication between the bladder and vagina. While several surgical approaches achieve favourable outcomes, robotic surgery has emerged as a preferred minimally invasive option. Evidence regarding single-port (SP) robotic repair remains limited. This study aims to evaluate the feasibility and safety of robotic SP VVF repair in a complex clinical setting

Methods

A 37-year-old woman with bilateral nephrostomies was referred for management of VVF and right ureteral obstruction following prior laparotomy-assisted hysterosalpingectomy for uterine fibromatosis and subsequent repair of a ureteroperitoneal fistula performed at another institution.

Preoperative assessment included Urogynaecological, anaesthesiologic, and radiological evaluation. Cystoscopy, CT cystography, and bilateral pyelography identified a 2 mm vesicovaginal fistula located at the left paramedian posterior bladder wall and obstruction of the right nephrostomy.

After replacement of the right nephrostomy and placement of an 18 Fr Foley catheter, a combined urological and gynaecological robotic procedure was performed using the Da Vinci SP system. The patient was placed in Lloyd-Davies position. VVF repair was achieved with layered closure and interposition of a pedicled omental flap. Bilateral double-J ureteral stents were placed.

Results

Total operative time was 110 minutes. Blood loss was negligible. No intraoperative or postoperative complications occurred. During the postoperative course, nephrostomies were kept closed with adequate urinary drainage via Foley catheter. Both nephrostomies and ureteral stents were removed on postoperative day nine after retrograde cystography confirmed fistula closure and absence of vesicoureteral reflux.

The patient was discharged on postoperative day nine in good clinical condition; total hospital stay was 18 days. At one-month follow-up, urological and gynaecological evaluation confirmed.

Conclusions

Robotic single-port repair of vesicovaginal fistula is a safe and effective option in selected complex cases. The SP platform enables precise dissection and suturing in confined spaces while maintaining minimal invasiveness.

This case highlights the importance of a multidisciplinary approach and careful preoperative planning. Although current evidence is limited, single-port robotic surgery may represent an important evolution in the management of complex Urogynaecological fistulas, warranting further investigation in larger cohorts with long-term follow-up.

https://player.vimeo.com/video/1191610400?autoplay=1

ESGE35-0591 -
EEL I ESGE Endometriosis Session

Free Communication: From Frozen Pelvis to Functional Recovery: Robotic Management of Ureterovaginal Fistula Following Single Port Deep Endometriosis Surgery

Saima Farooq[1], *Amer Raza*[1]
[1]*Cromwell Hospital, Gynaecology, LONDON, United Kingdom*

Background

Deep infiltrating endometriosis (DIE) involving the rectovaginal septum and pararectal spaces represents one of the most technically demanding forms of benign pelvic surgery. Delayed ureteric complications following radical excision are uncommon but may require complex multidisciplinary reconstruction.

Methods

Case Presentation and Surgical Technique: A 46-year-old woman with severe stage IV endometriosis presented with chronic pelvic pain, dysmenorrhoea, dyspareunia, and bowel symptoms refractory to previous medical management. MRI demonstrated diffuse adenomyosis, rectovaginal disease, bilateral adnexal adhesions, and complete obliteration of the pouch of Douglas consistent with a frozen pelvis. The patient underwent robotic hysterectomy with extensive excision of endometriosis, bilateral ureterolysis, opening of pararectal spaces, rectovaginal dissection, bowel shaving, and excision of deep posterior compartment disease. Postoperatively, she developed persistent urinary leakage. Imaging confirmed a distal ureteric injury with ureterovaginal fistula and associated hydronephrosis requiring nephrostomy insertion. A multidisciplinary robotic reconstructive procedure was subsequently undertaken. Dense postoperative fibrosis was encountered. The diseased distal ureteric segment communicating with the vagina was identified and excised. Robotic ureteroneocystostomy was performed with tension-free ureteric reimplantation and omental interposition flap placement. Intraoperative indocyanine green assessment confirmed satisfactory vascularity and anastomotic integrity.

Results

The reconstruction was completed successfully without intraoperative complications. Postoperative recovery was uneventful with complete resolution of urinary leakage and preservation of urinary drainage. Follow-up imaging and cystoscopic stent removal confirmed satisfactory recovery.

Conclusions

This video demonstrates the feasibility of robotic ureteric reconstruction following complex endometriosis surgery and highlights the importance of multidisciplinary collaboration, early recognition, and advanced robotic reconstructive skills in managing delayed ureteric complications.

https://player.vimeo.com/video/1199566424?autoplay=1

ESGE35-0896 -
New trends in hysteroscopy

Free Communication: Fully Vaginoscopic Hysteroscopy-Guided Paracervical Block: A Novel Speculum-Free Technique for Office Hysteroscopy

Federica Campolo[1], DiBiasi Jasmine[2], Matteo Tamagnini[3], Giulia Pellecchia[4], Fatilba Skoku[5], Manuel Maria Ianieri[6]
[1]UNIVERSITA' CATTOLICA DEL SACRO CUORE- ROMA,
Dipartimento per la Tutela della Salute della Donna e della Vita Nascente- Ginecologia e Ostetricia- Po liclinico di Abano Terme, ABANO TERME, Italy
[2]Università Cattolica del Sacro Cuore di Roma, Policlinico Gemelli, Roma, Italy
[3]Policlinico di Abano Terme,
Dipartimento per la Tutela della Salute della Donna e della Vita Nascente- Ginecologia e Ostetricia, Abano Terme- Padova, Italy
[4]Policlinico di Abano Terme,
Dipartimento per la Tutela della Salute della Donna e della Vita Nascente- Ginecologia e Ostetricia, Abano Termeo, Italy
[5]Policlinico di Abano Terme,
Dipartimento per la Tutela della Salute della Donna e della Vita Nascente- Ginecologia e Ostetricia, Abano Terme, Italy
[6]Saint Camillus International University of Health Sciences,
Dipartimento per la Tutela della Salute della Donna e della Vita Nascente- Ginecologia e Ostetricia- Po liclinico di Abano Terme, Abano Terme, Italy

Background

Pain remains one of the main limitations of office hysteroscopy, particularly in patients requiring cervical manipulation or operative procedures. Conventional paracervical block usually requires vaginal instrumentation, including speculum placement, cervical exposure, and blind landmark identification, which may increase patient discomfort and compromise the minimally invasive nature of office hysteroscopy.

Methods

We describe a novel hysteroscopy-guided fully vaginoscopic paracervical block performed under direct endoscopic visualization. The procedure is carried out using standard office hysteroscopy equipment, including a continuous-flow office hysteroscope, a long retractable injection needle, and a diluted lidocaine solution. Following atraumatic vaginoscopic access with high-flow saline distension, progressive vaginal expansion enables visualization of the cervicovaginal junction and identification of paracervical anatomical landmarks. Bilateral paracervical infiltration is then performed under direct hysteroscopic guidance after negative aspiration testing, allowing precise local anaesthetic administration without blind injection.

Main Outcome Measures: Technical feasibility, preservation of continuous office workflow, and potential improvement in patient tolerability.

Results

This technique eliminates the need for speculum placement and cervical traction while maintaining direct visualization throughout the anaesthetic procedure. Potential advantages include reduced procedural discomfort, improved tolerability, preservation of the vaginoscopic approach, and applicability in selected challenging patients, such as virginal patients, women with obesity, patients with contraindications to deep sedation, and highly anxious patients

Conclusions

Fully vaginoscopic hysteroscopy-guided paracervical block represents a simple, reproducible, and minimally invasive innovation in outpatient hysteroscopic anesthesia. This technique may expand the feasibility of office hysteroscopy in selected patients requiring improved pain management while preserving the principles of patient-centered minimally invasive care.

https://player.vimeo.com/video/1195746067?autoplay=1

FREE COMMUNICATION

ESGE35-0921 -
Free Communication

Can MRI Reliably Map Endometriosis? A Surgical Correlation Using #ENZIAN Classification System

Elie Finianos[1], *Panayiotis Tanos*[1], *Dominique Badr*[1], *Jacques Jani*[1], *Stavros Karampelas*[1]
[1]*CHU Brugmann, Gynecology, Brussels, Belgium*

Background

Accurate preoperative mapping of endometriosis is essential for surgical planning. This study aimed to evaluate the diagnostic performance of pelvic magnetic resonance imaging (MRI) for detecting and anatomically classifying endometriosis using surgical findings as the reference standard, with particular emphasis on the #ENZIAN classification system.

Methods

This retrospective observational study included operated patients for suspected endometriosis between October 2020 and October 2025. Patients without preoperative MRI examinations were excluded. MRI findings were compared with intraoperative findings, which served as the reference standard. Diagnostic performance was assessed for the #ENZIAN classification.

Overall agreement between MRI and surgical findings was evaluated using Cohen's κ coefficient for binary variables and quadratic weighted κ for ordinal #ENZIAN classifications (0–3). Sensitivity, specificity, positive predictive value (PPV), negative predictive value (NPV), and overall accuracy were calculated with exact 95% confidence intervals (CIs). For ordinal ENZIAN variables, class-specific diagnostic performance was calculated using a one-versus-all approach.

Results

Among 208 eligible patients, 39 were excluded because no MRI examination was available. Of the remaining 169 patients, 123 underwent MRI within our institution and 46 underwent external MRI examinations. One patient from the internal MRI group was excluded because of missing surgical documentation, resulting in a final cohort of 168 patients.

The median age of the study population was 34 years (21–54 years). The most common presenting symptom was pelvic pain (60.7%), followed by dysmenorrhea (19.6%) and infertility (15.5%). Transvaginal examination identified a palpable nodule in 76.5% of patients.

MRI demonstrated moderate diagnostic performance for deep endometriosis, with an overall accuracy of 83.3% (95% CI, 76.8–88.6), whereas the accuracy for superficial endometriosis was 60.1% (95% CI, 52.3–67.6) with a κ coefficient of 0.4 and 0.23, respectively.

For #ENZIAN classification, diagnostic performance varied according to anatomical compartment. The highest agreement between MRI and surgical findings was observed for ovarian involvement. Left ovarian lesions demonstrated an accuracy of 78.0% (95% CI, 70.9–84.0) while right ovarian lesions showed an accuracy of 84.5% (95% CI, 78.2–89.6), with a quadratic weighted κ of 0.65 and 0.74, respectively. Rectal involvement also showed substantial agreement, with an accuracy of 80.1% (95% CI, 73.2–85.9) and a quadratic weighted κ of 0.57.

In contrast, MRI performance for peritoneal involvement demonstrated the lowest agreement, with an accuracy of 53.6% (95% CI, 45.7–61.3) and a quadratic weighted κ of 0.24. Across most ENZIAN compartments, MRI demonstrated high specificity and high negative predictive value, whereas sensitivity for advanced disease stages remained limited and associated with wide confidence intervals because of the low prevalence of severe lesions.

Conclusions

Pelvic MRI demonstrated moderate-to-substantial agreement with surgical findings for the anatomical mapping of endometriosis, with the highest diagnostic performance observed for ovarian and rectal involvement. MRI showed high specificity across most anatomical compartments but limited sensitivity for advanced or low-prevalence lesions.

ESGE35-0843 -
Free Communication

Challenges in the Dual-Compartment Surgical Approach for Thoracic Endometriosis Syndrome

Tamer Seckin[1], Hakan Kula[2], Serin Seckin[3], Sabina Hajiyeva[4]
[1]Donald Barbara Zucker School of Medicine, Obstetrics and Gynecology, New York, USA
[2]Endometriosis Foundation of America, Endometriosis Research, New York, USA
[3]Seckin Endometriosis Center, Seckin Endometriosis Center, New York, USA
[4]Lenox Hill Hospital, Pathology Department, New York, USA

Background

Thoracic endometriosis syndrome (TES) represents one of the most complex manifestations of advanced endometriosis and frequently involves simultaneous pelvic, diaphragmatic, pleural, and pulmonary disease. Despite increasing recognition of TES, isolated thoracic or pelvic procedures remain common, potentially contributing to incomplete disease excision and recurrence. A coordinated dual-compartment surgical strategy combining thoracic and pelvic exploration may improve disease recognition and management; however, this approach presents unique anatomical, technical, and perioperative challenges.

Methods

A dual compartment surgery was performed of 53 patients, for TES over an 11-year period at a single tertiary referral center. All patients underwent combined video-assisted thoracoscopic surgery and laparoscopic pelvic exploration with excisional treatment of endometriosis. Operative findings, surgical staging, perioperative complications, diaphragmatic morphology, pathological findings, and follow-up outcomes were reviewed. Particular attention was directed toward technical and multidisciplinary challenges encountered during simultaneous thoracic and pelvic management.

Results

Among 53 patients undergoing dual-compartment surgery for thoracic endometriosis syndrome, advanced pelvic disease was common, with 46 patients (86.8%) classified as stage III–IV by AAGL criteria. Catamenial pneumothorax was reported in 37 patients (69.8%), and 52 patients (98.1%) demonstrated right-sided thoracic involvement. Dual-compartment surgery enabled simultaneous identification of pelvic, diaphragmatic, pleural, and pulmonary disease that would not be fully assessed from a single compartment alone. Major surgical challenges included distorted diaphragmatic anatomy, central tendon micro fenestrations, thoracic adhesions, severe retroperitoneal fibrosis, bowel and urinary tract involvement, and management of transdiaphragmatic communication during laparoscopy.

Intraoperative coordination between thoracic and gynecologic teams was essential for safe compartment transition and diaphragmatic repair. A total of 1,089 specimens were excised, with endometriosis confirmed in 672 specimens (62.3%). Stromal-predominant disease increased across compartments, representing 5.5% of pelvic, 19.4% of diaphragmatic, 31.3% of pleural, and 71.4% of

lung parenchymal endometriosis-positive specimens. Postoperative pneumothorax occurred in 3 patients (5.7%), and transient hypercarbia/acidosis occurred in 1 patient (1.8%).

Conclusions

TES should be approached as a progressive dual-compartment disease rather than an isolated thoracic entity. Successful management requires close collaboration between thoracic and endometriosis surgeons, detailed understanding of transdiaphragmatic disease spread, and meticulous compartment-based surgical planning. Dual-compartment surgery provides comprehensive disease assessment but introduces significant technical and perioperative challenges that must be recognized to optimize patient outcomes.

ESGE35-0709 -
Free Communication

Role of ICG (indocyanine green) in deep pelvic endometriosis surgery: evidence, experience and research.

Gourab Misra[1], *Justin Clarke*[2], *Lina Antoun*[2]
[1]*University Hospital North Midlands, Gynaecology, Stoke on Trent, United Kingdom*
[2]*Birmingham Women's Hospital, Gynaecology, Birmingham, United Kingdom*

Background

The ICE Trial

Full name: Ureteric identification using Indocyanine green dye versus Conventional ureteric stenting to reduce post-operative pain and surgical morbidity during Endometriosis surgery. NIHR Funded Randomized Feasibility Trial.

Deep endometriosis (DE) is a common condition affecting around one in ten women, causing severe pain. It occurs when cells similar to those lining the womb grow outside it, typically on surfaces and organs within the pelvic cavity, leading to bleeding, scarring, and inflammation. Unlike superficial endometriosis, in DE the cells grow deeper into tissues and organs such as the bowel, bladder, and vagina.

DE is treated using keyhole (laparoscopic or robotic-assisted) surgery to remove the areas of endometriosis.

Methods

What the Trial Compares

The central challenge in DE surgery is safely identifying and protecting the ureters (the tubes from the kidneys to the bladder), which are at risk of injury during excision. The ICE trial compares two techniques:

Group 1 — Traditional technique (stents): A small soft tube (stent) is temporarily placed in each ureter to identify and protect it during surgery. Stents are either removed at the end of the operation or left in place for 4–6 weeks. University Hospitals of North Midlands

Group 2 — New technique (ICG dye): Indocyanine green (ICG) dye is injected through a ureteric catheter into both ureters, allowing surgeons to visualise the ureters under a special light. University Hospitals of North Midlands

Results

The study is funded by the NIHR Research for Patient Benefit programme, runs over 24 months, and aims to recruit 70 participants aged 18–50 years undergoing minimal access surgery for deep endometriosis. Sites include University Hospital of North Midlands and Birmingham Women's and Children's NHS Foundation Trust. Participants are followed up for 12 weeks post-surgery via questionnaires, with an optional focus group component. University Hospitals of North Midlands

In short, the ICE trial is testing whether a modern fluorescence dye technique can replace conventional ureteric stenting in DE surgery, with the goal of reducing post-operative pain and surgical complications.

Data Collection:

Baseline demographic and clinical data, including age, BMI, previous history of excision of endometriosis and current pain level on a 0–10 numerical rating scale (VAS), will be collected following recruitment. The EQ-5D will be completed.

Laparoscopic (including robotic-assisted) excision vs excision and hysterectomy, surgical time, estimated blood loss, intraoperative visceral injury, conversion to laparotomy. We will also ask the surgeon at the end of the operation, to describe the severity, extent and location of DE using the structured, reproducible and validated ENZIAN classification system.

Conclusions

ICE trial was set up to there is lack of evidence in comparative studies comparing ureteric ICG compared to ureteric stenting in deep pelvic endometriosis surgery.

This randomised feasibility trial will help clinicians to identify specific areas for a larger multi-center RCT.

ESGE35-0546 -
Free Communication

Impact of bowel surgery for endometriosis on gastrointestinal symptoms: a clinically practice-changing surgical outcomes study

Milena Petrovic[1], Jonathan Lewin[1], Stavroula Kastora[1], Mohamed Mabrouk[1], Ertan Saridogan[1], Arvind Vashisht[1]
[1]University College London Hospital, Endometriosis, London, United Kingdom

Background

Bowel surgery for endometriosis frequently raises concern regarding postoperative bowel dysfunction. Evidence describing postoperative gastrointestinal (GI) symptom trajectories remains heterogeneous. This systematic review and meta-analysis aimed to quantitatively assess bowel symptom outcomes following treatment for endometriosis.

Methods

Six databases were searched from inception to June 2024 for studies reporting pre- and post-treatment bowel symptoms following surgery for endometriosis. Outcomes included constipation, diarrhoea, bloating, tenesmus, evacuation difficulty, and overall GI symptom burden. Meta-analysis was performed using arm-based pre-post comparisons, with subgroup analyses by bowel surgical modality.

Results

Sixty-one studies (n=5,279) met inclusion criteria, of which thirty-six evaluated bowel surgery. Overall, surgical intervention was associated with improvement rather than deterioration of bowel symptoms. Constipation prevalence significantly decreased following bowel surgery (OR 0.34, 95% CI 0.21-0.55), particularly following bowel resection or shave procedures. Bowel shave and disc resection were associated with reduced diarrhoea prevalence (OR 0.36, 95% CI 0.14-0.92). Segmental bowel resection demonstrated improvement in overall GI symptom burden and quality of life, including a clinically meaningful improvement in Gastrointestinal Quality of Life Index (GIQLI) scores (mean difference -17.7, 95% CI -22.38 to -13.02). Postoperative worsening of bowel symptoms was reported in eight treatment arms. Publication bias appeared minimal; overall risk of bias was high due to unblinded outcomes.

Conclusions

No evidence was identified for systematic postoperative deterioration in bowel function following surgical treatment of endometriosis, including segmental resection. Instead, pooled results consistently favoured improvement in gastrointestinal symptoms and quality of life. These findings provide important reassurance and support an individualised multidisciplinary surgical approach in advanced endometriosis.

ESGE35-0499 -
Free Communication

Conservative rectal surgery for deep infiltrating endometriosis: changing surgical trends and recurrence outcomes

Queralt Ampurdanés Noró[1], Sonia Monreal Clua[1], Laura Mañalich Barrachina[1], Anna Ruano Lopez[1], Eva Vila Escude[1], Elena Suarez Salvador[1]
[1]Hospital Universitari Vall d'Hebron, Gynecology, Barcelona, Spain

Background

The aim of this study is to evaluate if surgical management of rectal deep infiltrating endometriosis became progressively more conservative between 2017 and 2024 at our centre and to assess if this was achieved without an associated increase in postoperative recurrence rates.

Methods

A retrospective comparative study was conducted at our tertiary referral centre including patients who underwent surgery for deep infiltrating rectal endometriosis between January 2017 and December 2024.

Patients were classified according to the type of rectal surgical approach: conservative surgery (shaving or discoid excision) vs radical surgery (segmental resection) and according to the surgical access (robot-assisted laparoscopy vs conventional laparoscopy). Rectal nodule size was calculated using the available radiological dimensions (craniocaudal, transverse, and anteroposterior measurements). Clinical and/or radiological recurrence during follow-up was recorded.

Continuous variables were compared using Student's t-test or one-way ANOVA, while categorical variables were analysed using chi-square or Fisher's exact tests. Temporal trends were assessed using logistic regression analysis. Statistical significance was defined as $p<0.05$.

Results

Our preliminary study included 84 patients. Mean age at surgery was 39.8 ± 5.6 years. Robot-assisted laparoscopy was performed in 56.0% of patients (n=47), while 44.0% (n=37) underwent conventional laparoscopy. Surgical management included shaving in 45.2% (n=38), discoid excision in 13.1% (n=11), and segmental rectal resection in 41.7% (n=35). Mean rectal nodule size, defined as the mean of the available craniocaudal, transverse and anteroposterior measurements, was 22.9 ± 10.8 mm.

Clinical or radiological recurrence occurred in 29.8% of patients (n=25). Mean follow-up time was 30.2 ± 20.5 months, and mean time to recurrence was 25.6 ± 16.7 months. Larger nodules tended to be associated with more radical surgical approaches, although differences did not reach statistical significance (p=0.087).

The proportion of conservative rectal procedures increased progressively during the study period. Logistic regression analysis demonstrated a significant annual increase in the likelihood of performing conservative surgery (OR 1.46, 95% CI 1.10–1.93; p=0.008).

No significant differences in recurrence rates were observed between conservative and radical surgical approaches (p=0.632).

Conclusions

Between 2017 and 2024, surgical management of deep infiltrating rectal endometriosis at our centre progressively shifted towards more conservative approaches. This change was not associated with higher postoperative recurrence rates in this preliminary analysis. Further studies with longer follow-up are required to confirm these findings.

ESGE35-0368 -
Free Communication

Perception versus reality - improving documentation of endometriosis at diagnostic laparoscopy in NHS Lanarkshire

Suzie Gordon[1], *Inna Sokolova*[2], *Mihai Gherghe*[3], *Allam Mohammed*[3]
[1]*University Hospital Wishaw, Gynaecology Department, Larkhall, United Kingdom*
[2]*University Hospital Crosshouse, Gynaecology Department, NHS Ayrshire and Arran, United Kingdom*
[3]*University Hospital Wishaw, Gynaecology Department, NHS Lanarkshire, United Kingdom*

Background

Operative documentation of Endometriosis at diagnostic laparoscopy can shape years of treatment decisions for patients living with a complex and often underrecognized condition.

This audit aimed to compare clinicians' perception of their common practice with the realities of quantitative documentation. The intended outcome being an improved quality of documentation for diagnostic laparoscopies in our secondary care centre in NHS Lanarkshire (Scotland).

Methods

A four-year retrospective audit (February 2022–2026) of operation documentation was assessed against established gold standards, including the AAGL and #Enzian classification systems. Additionally, Gynaecologists within the health board were surveyed regarding their standard Endometriosis practices.

Results

19 survey responses and 72 operation notes were reviewed. 44% of consultants and 40% of registrars reported basing their documentation of Endometriosis on a classification system. Later in the survey, 52% of respondents could name a classification system used for Endometriosis, only 3 out of 19 respondents could name more than one.

Although 67% of consultants and 30% of registrars reported routinely documenting disease stage, only 11% of operation notes (8/72) included staging. All recorded as "stage 0." Similarly, 100% of consultants and 90% of registrars reported routinely documenting disease depth (superficial vs deep/infiltrating), yet this was recorded in only 30% (22/72) of cases.

In a free text question regarding anatomy at laparoscopy; 'ovarian fossae' and 'bladder/UV fold' (each 68%) were most commonly reported as visualised. Key structures such as the uterus, fallopian tubes, and ovaries were mentioned by fewer than half of respondents. In contrast, a review of operation notes showed fallopian tubes were most frequently documented (76%), with poor documentation rates for; peritoneum (10%), rectum (18%), ureters (19%), and liver edge/stomach (21%).

Using a 13-point gold standard checklist of anatomical sites, the mean documentation score was 5/13 (range 0–12), highlighting significant inconsistency and incompleteness.

Conclusions

This audit demonstrates a significant disparity between clinicians perceived and actual documentation practices in diagnostic laparoscopy for endometriosis. The findings identified clear gaps in knowledge with poor documentation practices and lack of thorough assessment of the abdomen and pelvis. In response, multiple quality improvement interventions were implemented – including the development of teaching, creation of an operation note template, development of visual displays in theatre to remind clinicians of 'complete' laparoscopic technique.

Results are promising from early re-audit data; Mean documentation scores have increased from 5/13 to 9/13, with improved rates of depth recording. Ongoing work is focused on improving confidence and consistency in disease staging.

ESGE35-0266 -
Free Communication

Robotic fertility-preserving surgery in advanced endometriosis: advanced adenomyomectomy techniques, nerve-sparing dissection and pelvic reconstruction

Saima Farooq[1], *Amer Raza*[1]
[1]*Cromwell Hospital, Gynaecology, LONDON, United Kingdom*

Background

Robotic adenomyomectomy remains surgically challenging due to distorted myometrial planes, heavy vascularity, and the need for precise uterine reconstruction. Advanced robotic techniques may facilitate fertility preservation in severe adenomyosis associated with multi-quadrant endometriosis.

Methods

A 40-year-old woman with longstanding infertility, multiple failed IVF attempts, and chronic pelvic pain presented with severe distortion of the endometrial cavity. MRI demonstrated diffuse adenomyosis with a 6 cm adenomyoma affecting the anterior uterine wall, associated rectovaginal endometriosis, right uterosacral ligament disease, and left ovarian endometrioma. Multiport robotic surgery was performed using four robotic ports. Operative findings demonstrated extensive superficial and deep infiltrating endometriosis involving bilateral pelvic sidewalls, bladder peritoneum, uterosacral ligaments, rectovaginal space, appendix, and left adnexa. Bilateral ureterolysis and retroperitoneal nerve-sparing dissection were undertaken to restore normal anatomy. The left endometrioma was mobilised and drained with extensive adhesiolysis. Vasopressin infiltration and temporary bilateral uterine artery clipping facilitated robotic adenomyomectomy with excision of a 6 cm adenomyoma followed by multilayer uterine reconstruction. Robotic bladder mobilisation, excision of uterovesical disease, appendicectomy, and rectovaginal shaving were completed during the same procedure. Indocyanine green was utilised intraoperatively to confirm tissue perfusion and preservation of critical anatomy.

Results

Complete excision of visible endometriosis and adenomyosis was achieved without conversion or intraoperative complications. Pelvic anatomy was successfully restored with preservation of the uterus and right fallopian tube. Excellent haemostasis was maintained throughout the procedure, and postoperative recovery was uncomplicated with early mobilisation and discharge.

Conclusions

Robotic adenomyomectomy combined with comprehensive endometriosis excision offers an effective fertility-preserving strategy in advanced pelvic disease. Precision robotic dissection, vascular control, nerve-sparing retroperitoneal surgery, and multilayer uterine reconstruction enable safe management of severe adenomyosis while restoring pelvic anatomy, minimising surgical morbidity, optimising reproductive potential, and maintaining the benefits of minimally invasive surgery.

https://player.vimeo.com/video/1199574195?autoplay=1

ESGE35-0255 -
Free Communication

#Enzian classification and infertility: which compartments are most involved?

Sara Valeriani[1,2], Federica Iacobini[1], Giuseppe Gabriele Iorio[3], Giulia Monaco[1], Alfredo Ercoli[4], Caterina Exacoustos[1]
[1]University of Rome "Tor Vergata", Department of Surgical Sciences- Gynecological Unit, Rome, Italy
[2]San Paolo Hospital, Obstetrics and Gynaecological Department, Civitavecchia, Italy
[3]University of Naples Federico II, Department of Public Health, Naples, Italy
[4]University of Rome "Tor Vergata", Department of Biomedicine and Prevention- Gynaecological Unit, Rome, Italy

Background

#Enzian classification represents a system to describe endometriotic lesions during surgery. Its use is well established in correlating ultrasound and surgical findings. This study aimed to assess the correlation between infertility and pelvic endometriosis described by using #Enzian classification through transvaginal ultrasound (TVS).

Methods

105 infertile women with ultrasound diagnosis of pelvic endometriosis, with no previous surgery and not taking any hormonal therapy for at least 6 months, were staged according to the #Enzian classification (compartments A, B, C, O, T, FA, FB, FI, FU, FO). A group of 105 patients with endometriosis and at least one pregnancy resulting in live birth was used as control group. Statistical analysis compared endometriosis location and symptoms (dysmenorrhea, dyspareunia, dysuria, dyschezia, bowel symptoms and heavy menstrual bleeding) between the two groups.

Results

We observed a statistically significant association between infertility and both compartment A (36.2% vs 21.9%, p = 0.02) and compartment C (33.3% vs 17.1%, p = 0.007) compared with the control group. Especially for the T and O compartments, infertile patients also exhibited a higher frequency of bilateral involvement compared with controls (28.6% vs 14.3% p=0.01; 21.0% vs 4.8% p<0.001). No significant differences in symptoms were observed between the two groups. Among the infertile patients, 39 out of 105 (37.1%) underwent artificial reproductive technology (ART). Of these, 6 out of 39 (15.4%) achieved pregnancy, while 33 out of 39 (84.6%) did not. The analysis of these two groups showed a higher prevalence of endometriosis in almost all #Enzian compartments among patients who did not achieve pregnancy, in particular FA was significantly more frequent in these patients (78.8% vs 33.3% p=0.02).

Conclusions

#ENZIAN classification could help in the evaluation of pelvic endometriosis and reproductive outcomes and should be used also in infertile center. An accurate evaluation of the compartments could guide the clinician to establish the best management for infertile patients.

ESGE35-0187 -
Free Communication

Follow-up in endometriosis: consistency and variability in international practice

Laurin Burla[1,2], Mauricio Simões Abrão[3], Sun-Wei Guo[4], Harald Krentel[5], Bernhard Kraemer[2], Patrick Imesch[6]
[1]University Hospital Zurich, Department of Gynecology, Zürich, Switzerland
[2]University Hospital Tuebingen, Department of Women's Health, Tuebingen, Germany
[3]University of São Paulo, Department of Obstetrics and Gynecology, São Paulo, Brazil
[4]Fudan University, Shanghai Obstetrics and Gynecology Hospital, Shanghai, China
[5]Klinikum Aschaffenburg-Alzenau, Department of Gynecology and Obstetrics, Aschaffenburg, Germany
[6]University Hospital Zurich, Department of Gynecology, Zurich, Switzerland

Background

Endometriosis is increasingly recognized as a chronic systemic condition requiring individualized long-term management. Despite growing awareness of the importance of longitudinal care, evidence-based follow-up strategies remain poorly established. This study aimed to characterize current international follow-up practices among endometriosis specialists and identify areas of consensus and variability across structured clinical scenarios.

Methods

An international cross-sectional survey was conducted among 120 endometriosis specialists from 33 countries. A structured 43-item questionnaire, developed by an international multidisciplinary expert panel, assessed general follow-up strategies and responses to five structured clinical scenarios representing different disease stages and treatment settings. Outcomes included follow-up provider, timing and duration of surveillance, criteria for extending intervalls or discontinuing follow-up, and diagnostic approaches. Inter-practice variability was quantified using normalized entropy analysis.

Results

Follow-up care was predominantly specialist-led, ranging from 65.0% to 78.3% across clinical scenarios. Surveillance intervals most commonly clustered around 3 and 6 months, with shorter intervals preferentially applied in patients with complex disease manifestations. Long-term follow-up was favoured by most participants and discontinuation of surveillance was uncommon, even in clinically stable patients. While 78% of respondents reported the use of routine follow-up protocols, standardized assessment instruments were inconsistently implemented. Areas of high agreement included renal surveillance after ureteral involvement (78.6%), whereas substantial heterogeneity was observed regarding functional assessment, duration of follow-up, and discontinuation criteria. Entropy analysis demonstrated marked variability in several domains of longitudinal care despite identifiable overarching practice patterns.

Conclusions

Current follow-up strategies in endometriosis demonstrate a combination of reproducible clinical patterns and considerable international variability. The absence of standardized long-term management pathways reflects a significant unmet need in endometriosis care. These findings support the development of evidence-based, structured, and patient-centered follow-up recommendations to improve continuity of care and long-term outcomes.

ESGE35-0858 -
Free Communication

Intraureteral ICG-guided robotic management of deep infiltrating ureteral endometriosis using a RAS system

Cristiano Rossitto[1], Giorgia Gaia[2], Alessandra De Cicco Nardone[2], Sara Mastrovito[2], Costanza Romeo[2], Anna Fagotti[2]
[1]Fondazione Policlinico Universitario A. Gemelli IRCCS, Department ow women's and children's health, Rome, Italy
[2]Fondazione Policlinico Universitario A. Gemelli IRCCS, Department of Women's and Children's Health, Rome, Italy

Background

To demonstrate the feasibility of fluorescence-guided robotic management of deep infiltrating ureteral endometriosis using intraureteral indocyanine green (ICG) administration integrated with the Hugo™ RAS system.

Methods

We present the case of a 21-year-old patient with preoperative right hydronephrosis caused by periureteral deep infiltrating endometriosis identified at transvaginal ultrasound. Before the robotic procedure, cystoscopy and intraureteral ICG injection were performed. A 4-F open-ended ureteral catheter was inserted into the right ureteral orifice, and 5–6 mL of ICG solution was injected into the mid-ureteral segment to obtain fluorescence-guided visualization of the ureter during surgery. Fluorescence imaging was achieved using the Karl Storz IMAGE1 S Rubina™ system integrated with the Hugo™ RAS platform, allowing superimposed fluorescence imaging over the standard surgical view to improve real-time ureteral identification during dissection. Robotic dissection included opening of the Okabayashi space with identification of the main vascular structures and ureteral course. Ureterolysis was performed up to the level of the endometriotic nodule, where significant ureteral stenosis was identified. The lesion was excised through careful blunt and sharp dissection guided by near-infrared fluorescence imaging, allowing progressive liberation of the ureter while preserving its integrity.

Results

Complete excision of the periureteral endometriotic nodule was achieved with restoration of ureteral continuity and preservation of the ureteral wall. Fluorescence guidance facilitated real-time identification of the ureter throughout the dissection, particularly in the stenotic segment surrounded by fibrosis. No evident ureteral injury was identified intraoperatively. Following multidisciplinary intraoperative evaluation, ureteral reimplantation was not considered necessary, and temporary ureteral stenting was performed.

Conclusions

Intraureteral ICG-guided robotic surgery using the Hugo™ RAS system appears to be a feasible approach for the management of ureteral endometriosis. Superimposed fluorescence imaging may

enhance ureteral visualization and support conservative ureter-sparing surgery during complex pelvic dissections.

https://player.vimeo.com/video/1195709351?autoplay=1

ESGE35-0577 -
Free Communication

Laparoscopic cervical stump excision after LASH for adenomyosis

Valentina Auletta[1], *Davit Bokhua*[1]
[1]*University of Jena, Gynecology Oncology and Endometriosis, Jena, Germany*

Background

To present laparoscopic cervical stump excision in a patient with cyclic bleeding and pain after supracervical hysterectomy for adenomyosis.

Methods

A 41-year-old patient presented with recurrent cyclic bleeding and pain arising from the residual cervix two years after laparoscopic supracervical hysterectomy for adenomyosis. Cervical cytology was normal, and there was no clinical suspicion of malignancy. Due to persistent symptoms and suspected hormonally active residual tissue, laparoscopic excision of the cervical stump was planned.

Results

The video demonstrates the key steps of laparoscopic cervical stump excision in a previously operated pelvis. After vaginal manipulation of the cervix and laparoscopic access, adhesions around the cervical stump were carefully divided. The vesicocervical space was opened, and the bladder was mobilised caudally to expose the cervicovaginal junction. The lateral aspects of the cervical stump were dissected with careful control of fibrotic tissue and vascular remnants. Circumferential colpotomy was then performed under laparoscopic vision, allowing complete removal of the portio and cervical stump through the vagina. The vaginal cuff was closed laparoscopically with a running suture. Final inspection confirmed haemostasis and no intraoperative complication. Histological examination confirmed adenomyosis / adenomyotic tissue within the resected cervical stump.

Conclusions

Persistent cyclic bleeding and pain after supracervical hysterectomy may be caused by hormonally active residual cervical tissue. In selected patients without suspicion of malignancy, laparoscopic cervical stump excision can provide definitive treatment. Careful vesicocervical dissection, controlled circumferential colpotomy and secure vaginal cuff closure are the central technical steps.

https://player.vimeo.com/video/1191691913?autoplay=1

ESGE35-0561 -
Free Communication

Minimally invasive management of sciatic nerve endometriosis: laparoscopic neurolysis and functional recovery

Necati Berk Kaplan[1], Salih Taşkın[1]
[1]Ankara University, Obstetrics and Gynecology, Ankara, Türkiye

Background

Sciatic nerve endometriosis is a rare manifestation of deep infiltrating endometriosis that may lead to progressive neuropathy if untreated. Patients typically present with cyclic sciatica, characterized by hip or buttock pain that exacerbates during menstruation. If left untreated, the condition can progress to constant neuropathic pain, motor deficits, muscle atrophy, and foot drop due to axonal destruction. Diagnosis is frequently delayed, as symptoms mimic orthopaedic or spinal pathologies; however, Magnetic Resonance Imaging (MRI) is the preferred modality for identifying these lesions. The gold standard for management is laparoscopic neurolysis and complete excision. This video demonstrates a neuropelveological laparoscopic approach for safe nerve decompression and excision.

Methods

A 29-year-old female (G1P1) presented with chronic, cyclic right-sided sciatica radiating from the lower back to the leg. While transvaginal ultrasonography revealed a normal uterus and bilateral ovaries, pelvic Magnetic Resonance Imaging (MRI) identified an 8 mm nodular lesion at the level of the right greater sciatic foramen. The nodule was located anterior to the piriformis muscle, involving the nerve fibres with associated oedematous signal changes and mild contrast enhancement, highly suggestive of sciatic nerve endometriosis. Given the failure of conservative symptoms and the risk of irreversible neurological damage, the patient was scheduled for elective laparoscopic exploration.

The procedure was performed in a stepwise manner to ensure safe identification and preservation of neural structures. A lateral retroperitoneal approach was used to access the lumbosacral plexus. Key anatomical landmarks were identified, and meticulous dissection allowed safe exposure of the sciatic nerve. Neurolysis and complete excision of the endometriotic nodule were performed while preserving nerve integrity.

Results

The procedure was completed without intraoperative complications. Postoperatively, the patient reported a significant reduction in neuropathic symptoms. The Visual Analog Scale (VAS) score for the radiating lower back and leg pain decreased from a preoperative 9 to 3. At the 6-month follow-up, the patient, who previously suffered from severe pain and gait limitations, demonstrated successful functional recovery and reported being completely pain-free during ambulation.

Conclusions

Laparoscopic neuropelveological techniques enable safe and effective management of sciatic nerve endometriosis. Early recognition and surgical intervention are critical to prevent irreversible neurological damage. This approach provides significant symptom relief and functional recovery and should be considered in patients with suspected sciatic nerve involvement.

https://player.vimeo.com/video/1191689897?autoplay=1

ESGE35-0560 -
Free Communication

Multi-compartment and pelvic floor endometriosis

Fernanda Dishchekenian[1], Marina Fulfaro[2], Rafaela Vincentin[2], Beatriz Oliveira[2], Adrielle Fernandes[2], Mariano Tamura[2]
[1]Einstein Hospital Israelita, Gynecology, Sao Paulo, Brazil
[2]Einstein Hospital Israelita, Gynecology, São Paulo, Brazil

Background

To demonstrate the challenges involved in the surgical treatment of multi-compartment deep infiltrating endometriosis associated with pelvic floor involvement, highlighting the importance of standardized surgical steps, detailed pelvic anatomical knowledge, and robotic-assisted laparoscopy to achieve safe and effective disease excision while preserving critical pelvic structures.

Methods

We present the case of a 45-year-old woman with a 10-year history of progressive dysmenorrhea, abnormal uterine bleeding, chronic pelvic pain with perianal radiation, dyschezia, dyspareunia, and faecal urgency incontinence. Her medical history included right breast carcinoma in situ treated with breast-conserving surgery, radiotherapy, and hormonal therapy. Physical examination revealed a posterior vaginal wall nodule, tenderness of the vaginal fornix, pain on cervical mobilization, and suspected left levator ani detachment. Pelvic MRI and transvaginal ultrasound demonstrated adenomyosis, bilateral endometriomas, obliteration of the posterior cul-de-sac, rectosigmoid retraction, lesions involving the uterosacral ligaments and inferior hypogastric plexus, and possible appendiceal involvement. Three-dimensional anorectal ultrasound demonstrated widening of the pelvic floor hiatus and puborectal muscle asymmetry suggestive of partial detachment. The patient underwent robotic-assisted laparoscopic excision of endometriosis in a multidisciplinary approach involving gynecologic and digestive surgery teams.

Results

Robotic surgery enabled comprehensive pelvic exploration, precise retroperitoneal dissection, and safe excision of deep infiltrating lesions involving the posterior compartment and pelvic floor. The procedure lasted approximately three hours, with minimal blood loss and no intraoperative complications. Postoperatively, the patient experienced abdominal distention and pain, requiring gradual diet progression. Bowel and urinary function were preserved. The patient was discharged on postoperative day eight with improvement of her preoperative symptoms.

Conclusions

This case highlights the complexity of multi-compartment endometriosis associated with pelvic floor distortion caused by chronic inflammation. A standardized stepwise surgical strategy combined with robotic-assisted laparoscopy provides excellent pelvic exposure, facilitates identification of distorted anatomy, and enables safe dissection near critical neurovascular structures. Detailed anatomical

knowledge and multidisciplinary management are essential to optimize surgical outcomes and minimize complications in complex endometriosis surgery.

https://player.vimeo.com/video/1191689026?autoplay=1

ESGE35-0531 -
Free Communication

Enhancing precision and fertility preservation: intraoperative ultrasound–guided robotic surgery for deep endometriosis with intestinal involvement

Adrielle Rodas Fernandes[1], Letícia Calazans[1], Thaís B. Pastana[2], Paula F. Medina[2], Tainá O. Rocha[2], Mariano Tamura[1]
[1]Einstein Hospital Israelita, Minimally Invasive Gynecologic Surgery, São Paulo, Brazil
[2]Hospital Moriah, Minimally Invasive Gynecologic Surgery, São Paulo, Brazil

Background

To demonstrate the role of intraoperative ultrasound as an adjunct to robotic-assisted surgery in the management of deep infiltrating endometriosis with rectosigmoid involvement, aiming to improve surgical precision, optimize resection margins, and preserve reproductive potential in complex recurrent disease.

Methods

We present a step-by-step surgical video of a 33-year-old nulligravid patient with a desire for future fertility, presenting with dysmenorrhea, menorrhagia, and dyspareunia refractory to medical therapy. She had a prior history of robotic excision of intestinal endometriosis and myomectomy two years earlier, with symptom recurrence.

Preoperative transvaginal ultrasound with bowel preparation demonstrated an anteverted uterus (67.4 cm^3) and a hypoechoic nodular lesion adjacent to anterior uterine serosa. Deep infiltrating endometriosis was identified in the posterior compartment, involving the anterior rectosigmoid wall. Two nodules were described: a 2.1 × 1.9 cm lesion located 13 cm from the anal verge, infiltrating the inner muscular layer and involving approximately 50% of bowel circumference; and a 0.6 × 0.3 cm lesion located 14.5 cm from the anal verge, involving the outer muscular layer and 25% of circumference. A right ovarian endometrioma (1.8 cm) and bilateral superficial ovarian implants were also identified.

Robotic-assisted laparoscopy was performed using the Da Vinci Xi platform with four ports. Intraoperative findings included dense pelvic adhesions, with rectal adherence to the posterior uterus and bilateral ovarian adhesions.

The procedure included adhesiolysis and restoration of pelvic anatomy through dissection of avascular spaces, particularly the pararectal spaces of Latzko and Okabayashi. A right ovarian cystectomy and temporary ovarian suspension were performed. A nodular lesion of the left round ligament was excised using a limited approach.

A 2.5 × 2.0 cm rectosigmoid lesion was identified approximately 10 cm from the anal verge. Intraoperative ultrasound was used to assess depth of infiltration and guide resection. Segmental rectosigmoid resection was performed with preservation of ureters and gonadal vessels, followed by transanal specimen extraction.

Colorectal end-to-end anastomosis was performed using a 28 mm circular stapler. Anastomotic integrity was confirmed with air leak and methylene blue tests, and perfusion was assessed using indocyanine green fluorescence.

Results

The procedure was completed without intraoperative complications. Postoperative recovery was uneventful, with early diet progression. The patient was discharged on postoperative day three.

Histopathology confirmed endometriosis in all resected specimens. Intraoperative ultrasound enabled accurate assessment of lesion extent, supporting complete excision while avoiding unnecessary bowel resection.

Conclusions

Intraoperative ultrasound is a valuable adjunct in the surgical management of rectosigmoid endometriosis, allowing real-time assessment of lesion extent and depth.

Combined with robotic-assisted surgery and standardized dissection of pelvic avascular spaces, this approach enhances precision, supports complete excision, and preserves critical structures. The use of indocyanine green further contributes to anastomotic safety.

This technique represents a reproducible strategy for complex endometriosis, with potential to reduce morbidity and optimize reproductive outcomes.

https://player.vimeo.com/video/1191683256?autoplay=1

ESGE35-0106 -
Free Communication

Impact of indentation angle of partial septate uterus on reproductive outcomes after septoplasty in infertile patients

Mostafa Abuzeid[1], *Salem Joseph*[1], *Panagiotis Cherouveim*[2], *Omar Abuzeid*[3], *Erdal Budak*[1], *Michael Fakih*[1]
[1]*Fakih IVF Fertility Center, Reproductive Medicine and Infertility, Abu Dhabi, United Arab Emirates*
[2]*Hurley Medical Center/Michigan State University, Department of OB/GYN, Flint, USA*
[3]*Franciscan Physician Network, Division of Maternal Fetal Medicine, Crown Point, USA*

Background

The definition of partial septate uterus (PSU) remains controversial, with the ESHRE/ESGE classification defines PSU as a mid-fundal indentation exceeding 50% of the fundal myometrial thickness, irrespective of the indentation angle, whereas the ASRM classification (2021) is incorporating both septum length (>10 mm) and angle (<90°). Despite these differing criteria, the clinical relevance of septum indentation angle in predicting reproductive outcomes after hysteroscopic septoplasty is unclear. Wider septal angles may influence surgical complexity, including bleeding risk and completeness of resection, potentially impacting fertility outcomes. This study aimed to evaluate whether septum indentation angle (<90° vs. ≥90°) affects reproductive outcomes following hysteroscopic septoplasty in infertile patients.

Methods

This single-center historical cohort study included 1,342 infertile patients who underwent hysteroscopic septoplasty for PSU between 1990 and 2023 after electing surgical management. All cases were reclassified according to ESHRE/ESGE criteria with respect to the septum angle. However, septum length in our study was defined as >10 mm according to Congenital Uterine Malformations by Experts criteria (CUME) [Ludwin A et al. 2018]. Patients were stratified into Group 1 (angle <90°, n=410) and Group 2 (angle ≥90°, n=932). Postoperative fertility management was individualized based on infertility etiology and included natural conception, ovulation induction, intrauterine insemination (IUI), and In-Vitro fertilization (IVF), as well as adjunctive procedures such as laparoscopy when indicated. Each patient's best reproductive outcome over a 2-year follow-up period was recorded. Statistical analyses were performed using Student's t-test and Chi-square test where appropriate, with generalized estimating equations regression used to adjust for potential confounders.

Results

Patients in Group 1 were significantly younger and had lower rates of hysteroscopic polypectomy compared to Group 2. However, Group 1 demonstrated a higher prevalence of prior delivery, tubal factor infertility, endometriosis, and male factor infertility. No other baseline characteristics differed significantly. Unadjusted analysis showed that Group 1 had significantly higher clinical pregnancy rates (65.9% vs. 59.4%, p=0.026) and live birth rates (58.8% vs. 52.6%, p=0.037), as well as higher preterm birth rates (29.9% vs. 22.9%, p=0.040). Miscarriage rates (10.0% vs. 10.9%, p=0.703) and

mean gestational age at delivery (36.6 ± 4.4 vs. 37.0 ± 3.5 weeks, p=0.972) were comparable between groups. A greater proportion of patients in Group 1 achieved pregnancy through non-IVF treatments, whereas IVF utilization was higher in Group 2. However, after adjustment for confounding factors, no statistically significant differences were observed between the groups in reproductive outcomes or method of conception (adjusted ORs with 95% CIs).

Conclusions

Hysteroscopic septoplasty in infertile patients with PSU yields favourable reproductive outcomes regardless of septum indentation angle.

ESGE35-0139 -
Free Communication

Beyond normal ultrasound: the additional value of office hysteroscopy in detecting occult intrauterine pathology before ivf and its impact on reproductive outcomes

Shahrzad Ansari[1]
[1]*Day General Hospital, OB & Gyn depart, Tehran, Iran*

Background

Successful embryo implantation depends on accurate assessment of the uterine cavity prior to in vitro fertilization (IVF). Although transvaginal ultrasound is routinely used as the primary diagnostic tool, subtle intrauterine abnormalities may remain undetected and potentially impair reproductive outcomes. Office hysteroscopy allows direct visualization of the endometrial cavity and may identify occult pathology not detected by ultrasound. This study aimed to evaluate the prevalence of unsuspected intrauterine abnormalities detected by office hysteroscopy in infertile women with normal ultrasound findings before IVF, and to assess their possible impact on reproductive outcomes.

Methods

This retrospective cohort study included infertile women undergoing IVF treatment between January 2024 and January 2026 at a tertiary reproductive medical center. All patients had normal transvaginal ultrasound examinations before undergoing office hysteroscopy as part of pre-IVF uterine cavity assessment. Patients with previously diagnosed uterine anomalies, submucosal fibroids, hydrosalpinx, or recurrent pregnancy loss were excluded.

Hysteroscopic findings including small endometrial polyps, micro polyps, subtle intrauterine adhesions, chronic endometritis-like changes, and focal endometrial irregularities were recorded. Patients with abnormal findings underwent hysteroscopic treatment or directed endometrial biopsy before embryo transfer. IVF outcomes including implantation rate, clinical pregnancy rate, and miscarriage rate were analysed and compared between patients with normal and abnormal hysteroscopic findings.

Results

A total of 236 infertile women were included in the analysis. Although all patients demonstrated normal ultrasound findings, office hysteroscopy identified occult intrauterine abnormalities in 84 patients (35.6%). The most frequent findings were small endometrial polyps (16.1%), chronic endometritis-like hysteroscopic features (10.2%), micro polyps (5.9%), and subtle adhesions (3.4%).

Following hysteroscopic management, patients with previously undetected pathology achieved reproductive outcomes comparable to those with initially normal hysteroscopy. Clinical pregnancy rates were significantly higher in treated patients compared with historical IVF outcomes prior to hysteroscopic correction (50.0% vs 38.5%, p=0.03). Implantation rates also improved after treatment, while miscarriage rates remained similar between groups.

Conclusions

More than one-third of infertile women with normal transvaginal ultrasound findings demonstrated occult intrauterine pathology on office hysteroscopy before IVF. These findings suggest that ultrasound alone may underestimate subtle endometrial abnormalities potentially affecting implantation. Office hysteroscopy may offer additional diagnostic and therapeutic value in selected IVF patients by enabling identification and treatment of lesions not detected by routine imaging.

ESGE35-0333 -
Free Communication

Automated classification of endometrial pathologies using artificial intelligence

Vasileios Bais[1], Fani Gkrozou[1], Panagiotis Kokkas[2], Dimitrios Lentzaris[1], Minas Paschopoulos[1]
[1]Faculty of Medicine- School of Health Sciences- University of Ioannina,
Department of Obstetrics and Gynecology, Ioannina, Greece
[2]School of Sciences- University of Ioannina, Department of Physics, Ioannina, Greece

Background

The primary goal of this study was to develop and evaluate an automated diagnostic framework for the objective classification of common uterine pathologies. Using the ConvNeXt-XLarge architecture, the study aimed to accurately differentiate between submucosal leiomyomas, functional polyps, and hyperplastic polyps, thereby reducing operator-dependent diagnostic variability and improving diagnostic consistency.

Methods

This study utilized a prospective dataset of 1,262 histopathologically confirmed hysteroscopic images collected between September 2024 and March 2026. The cohort consisted of 650 hyperplastic polyps, 439 functional polyps, and 173 leiomyomas. All images were distributed into training and validation sets using a standardized 80 to 20 percent split. Diagnostic models were developed using the ConvNeXt-XLarge through a dual-stage transfer learning strategy. This involved an initial feature extraction phase followed by selective fine-tuning of the final 20 layers to adapt the model to specific hysteroscopic morphological patterns. In addition to the primary multiclass model, three binary classification models were trained to evaluate pairwise pathological differentiation: model 1 (leiomyomas vs. functional polyps); model 2 (leiomyomas vs. hyperplastic polyps); and model 3 (functional polyps vs. hyperplastic polyps). Performance was assessed through accuracy, precision, sensitivity, specificity, and F1-score metrics, with 95 % confidence intervals (CIs) calculated using normal approximation and bootstrapping techniques.

Results

The multiclass model achieved an accuracy of 80.5% (95% CI: 75.6%–85.4%) and a precision of 82.3% (95% CI: 77.6%–87%). Among the binary classifiers, model 1 exhibited the highest diagnostic performance, achieving an accuracy of 96.7% (95% CI: 93.5%–99.9%) and a perfect precision of 100% (95% CI: 100%–100%). Model 3 followed with strong predictive capability, demonstrating an accuracy of 92.2% (95% CI: 88.6%–95.7%), and a precision of 97.3% (95% CI: 93.6%- 100%). In contrast, model 2 yielded the lowest comparative performance, with an accuracy of 87.2% (95% CI: 82.1%–92.3%) and a precision of 74.1% (95% CI: 57.6%-90.6%).

Conclusions

This study demonstrates that artificial intelligence frameworks can accurately automate the classification of hysteroscopic findings. By providing high-precision analysis, these models offer a robust tool to mitigate diagnostic subjectivity and optimize the management of uterine pathologies.

ESGE35-0390 -
Free Communication

Exploring patients' experience of pain and preferences for outpatient hysteroscopy: a quality improvement study.

Ines Goncalves[1], Isabel Lushbough[1], Ailsa Campbell[2], Marianne Watters[2]
[1]The University of Edinburgh, Gynaecology, Edinburgh, United Kingdom
[2]The University of Edinburgh, Obstetrics and Gynaecology, Edinburgh, United Kingdom

Background

To gain an understanding of patients' pain experience of outpatient hysteroscopy (OPH), to compare data to Royal College of Obstetricians and Gynaecologists (RCOG) Outpatient Hysteroscopy guideline standards and identify areas for improvement in local practice.

Methods

An anonymous patient questionnaire was designed based on the British Society Gynaecological Endoscopy Outpatient Hysteroscopy patient satisfaction survey. This was distributed to patients post-OPH procedure at a District General Hospital in the UK and collected via a questionnaire box over 6 months (October 2025 – March 2026). Pain was reported on a scale from 1-5, 1 being "not at all painful" and 5 being "extremely painful".

Results

The anonymous questionnaire was completed by 60 women who underwent OPH. 62% had had a hysteroscopy before. Among patients who had a smear test before (93%), 80% reported no problems tolerating their previous smears.

100% of patients attending OPH were given information about the procedure prior to appointment and 97% were given post-procedure care information. 80% of patients reported taking over-the-counter analgesia pre-OPH. 78% of patients were offered a recovery space post-OPH. The mean pain score for all respondents was 2.9 out of 5 (reported range 1-5). When prompted with future hysteroscopy setting preference, 80% indicated future preference for OPH and 15% preferred future procedures in theatre (5% indicated no preference). Among patients who indicated a preference for future hysteroscopy in theatre (15%) the mean pain score was 4.2, compared to 2.7 in those preferring OPH (80%) for future hysteroscopy procedures.

Conclusions

Data gathered over this period suggest that most patients received information regarding OPH, analgesia and post-procedure care in line with RCOG OPH Guidelines. Whilst most women experience some level of pain, hysteroscopy is generally well tolerated in the outpatient setting, with most patients indicating a preference to return to the outpatient setting for future procedures. This finding aligns with the RCOG OPH guidelines. Some patients, however, find this procedure difficult to tolerate. The data collected provides valuable insight into pain experiences of the local patient population and is a useful clinical resource. This data can be referenced during pre-procedure appointments, allowing patients to make informed decisions. Further studies exploring how to best

identify patients who will not tolerate OPH and direct them towards more suitable hysteroscopy settings and/or analgesia will be valuable for service provision and achieving greater patient satisfaction. In the future we plan to perform a detailed review of patient cases who express a preference for hysteroscopy in theatre. Ultimately, patient satisfaction of OPH will be improved by better understanding the patient experience and this project provides important local data to empower patients undergoing hysteroscopy.

ESGE35-0403 -
Free Communication

Hysteroscopic-guided anchoring of a frameless intrauterine device: technical feasibility, procedural safety and clinical outcomes in an outpatient setting.

Erika Catania[1], Vito Antonio Quartulli[2], Carmen Truono[2], MaryJo Troisi[2], Virginia De Santis[2], Brunella Zizolfi[2]
[1]University of Palermo, Department of Gynecology and Obstetrics, Palermo, Italy
[2]University of Naples Federico II, Department of Public Health, Naples, Italy

Background

Long-acting reversible contraception (LARC) systems frequently encounter complications (such as mispositioning, pain, or expulsion), often stemming from geometric incompatibility with the uterine cavity. The anchored frameless intrauterine device (IUD) was engineered to mitigate these issues. This prospective study, conducted at the Hysteroscopy Unit of the University Hospital Federico II of Naples, evaluates the surgical feasibility, safety, and clinical performance of hysteroscopic-guided insertion, highlighting the advantages of direct visualization over traditional blind techniques.

Methods

Initiated in October 2022, this ongoing prospective observational study enrolled62 patients for outpatient hysteroscopic insertion of a frameless copper IUD without any anesthesia. The clinical protocol integrated preoperative and longitudinal ultrasound (US)monitoring of specific topographical parameters: fundal thickness (FT), the distance from the anchor knot to the endometrium (KP), and the distance from the anchor to the serosa (SA).Primary endpoints included procedural duration, ease of insertion (Likert Scale 1-5), and mid-term clinical outcomes. Safety was assessed through expulsion rates and procedural or follow-up complications.

Results

Procedural efficiency was high, with a mean insertion time of 3.3 minutes and a difficulty score of 1.3/5. Hysteroscopic guidance facilitated precise anchoring by providing real-time visualization of myometrial penetration depth, effectively eliminating the risk of uterine perforation. Longitudinal US monitoring of FT, KP, and SA confirmed stable and correct device positioning. To date, 48 patients (77.4%) remain in active follow-up with the device in situ. The spontaneous expulsion rate was 9.7% (n=6), while medical removals (11.3%, n=7) were primarily due to heavy menstrual bleeding. Notably, no unintended pregnancies were recorded during the study period, confirming optimal contraceptive efficacy. Among patients continuing the method, the average satisfaction score was 4.3/5, indicating excellent tolerability.

Conclusions

Hysteroscopic-guided anchoring of a frameless IUD is a rapid, safe, and highly reproducible procedure. The synergy between direct endoscopic visualization and rigorous US monitoring of parameters such as FT, KP, and SA represents a significant advancement over blind insertion, ensuring

standardized fundal placement. These mid-term results support the anchored system as a highly reliable LARC option characterized by superior patient satisfaction and robust contraceptive safety.

ESGE35-0460 -
Free Communication

Effectiveness of Linzagolix in a clinical setting: preliminary data of an Italian real-life experience.

Sabrina Reppuccia[1], Carmen Truono[1], Fabiola Nardelli[1], Alfonso Manzi[1], Danilo Borrelli[1], Brunella Zizolfi[1]
[1]University Federico II, Public Health- School of Medicine, Naples, Italy

Background

Uterine fibroids are a common benign gynaecological condition in women of reproductive age and can often be symptomatic, causing heavy menstrual bleeding (HMB), infertility, and reduced quality of life. Effective medical treatments that can control symptoms and potentially avoid surgical intervention are of great clinical interest both for women seeking fertility and for those in perimenopausal period. Linzagolix, an oral GnRH antagonist, represents a promising non-surgical treatment option, particularly for women who are not eligible for combination hormonal therapy due to cardiovascular risk factors.

The objective of this study is to prospectively evaluate the short- and long-term clinical effectiveness of Linzagolix, as well as the surgical outcomes after at least 3 months of therapy, within routine clinical practice.

Methods

This is a prospective observational study conducted at the University of Naples Federico II. Eligible participants are women aged >18 years with a diagnosis of symptomatic uterine fibroids and a PBAC score >100. Enrolled women receive Linzagolix 200 mg once daily for at least 3 months. PBAC scores, haemoglobin levels, patient-reported satisfaction, ultrasound and surgical outcomes are systematically recorded.

Results

As of January 2025, 29 women were enrolled, with a mean age of 45.85 ± 6.61 years and a mean BMI of 26.7 ± 3.8 kg/m². All participants presented with HMB (mean PBAC 227.8 ± 53.4) and anaemia (mean haemoglobin 10.3 ± 1.2 g/dL).

After one month of treatment with Linzagolix 200 mg, 72.4% of the patients achieved a PBAC score below 100. After two months of therapy, all patients achieved a PBAC score <100.

At three months of treatment, mean PBAC score decreased to 92.4 ± 44.1 ($p<0.001$), and the mean haemoglobin level increased to 11.4 ± 1.0 g/dL ($p<0.01$).

At ultrasound assessment, a mean volumetric reduction of 43.5% in uterine volume and 48.6% in the largest fibroid was observed, according with findings already reported in the literature. No significant changes in echogenicity were detected, whereas a reduction in vascularization was documented according to the Colour Doppler score. No serious adverse events were reported during the treatment period.

Among the enrolled patients, 12 underwent hysteroscopic removal of fibroids. In all procedures, the cleavage plane was clearly visible and bleeding was minimal. No patients required a second step myomectomy, and they were all dismissed without complications.

Conclusions

Data from this real-world cohort suggest that Linzagolix is effective in significantly reducing menstrual blood loss and improving haemoglobin levels within one month of treatment. Moreover, the use of Linzagolix plays a relevant role as a pre-surgical treatment, allowing optimization of the patients' preoperative profile, reducing uterine fibroid volume, and showing no intraoperative or postoperative complications.

ESGE35-0855 -
Free Communication

Uterocervical angle and pain perception during office hysteroscopy in infertile women: a retrospective cohort study

Béla Bélteki[1], *Péter Török*[1], *Márton Lipták*[1]
[1]*University of Debrecen, Obstetrics and Gynecology, Debrecen, Hungary*

Background

To investigate whether the uterocervical angle (UCA), measured by transvaginal ultrasound using the UTEROMAP system, is associated with pain perception during diagnostic office hysteroscopy (OHSC) with endometrial biopsy performed without anesthesia. We also aimed to identify clinically relevant UCA thresholds associated with increased discomfort and to evaluate the influence of demographic factors such as age and body mass index (BMI).

Methods

This retrospective observational study included 141 nulligravid women undergoing OHSC for primary infertility evaluation. Preprocedural transvaginal ultrasound was used to determine uterine morphometry and calculate UCA from three anatomical parameters: uterine corpus length (co), cervical length (cx), and fundus–external os distance (u3). Pain perception was assessed immediately after the procedure using a 10-cm Visual Analogue Scale (VAS). Patients with anteflexed uterus (AFV, n=126) and retroflexed uterus (RFV, n=15) were analysed separately and comparatively. Non-parametric statistical methods were applied following Shapiro–Wilk normality testing. Data-driven threshold analysis using 5-degree UCA increments was performed to establish clinically relevant flexion categories.

Results

The overall mean VAS score in the combined cohort was 2.36 ± 1.69, indicating generally mild procedural discomfort. Continuous correlation analysis demonstrated no significant linear association between UCA and VAS ($p = 0.457$). However, threshold analysis identified three clinically relevant UCA categories in the AFV cohort: excessive low flexion (eLF, UCA <95°, n=17), normal flexion (NF, UCA 95–145°, n=80), and excessive high flexion (eHF, UCA >145°, n=29). Median VAS scores were 2.3, 1.9, and 2.5, respectively. Global comparison across the three groups using the Kruskal–Wallis test demonstrated a statistically significant difference ($H = 6.36$, $p = 0.0416$). Pairwise comparison revealed significantly higher pain scores in the eHF group compared with NF ($p = 0.0361$), while the eLF vs NF comparison approached significance ($p = 0.0705$). The boxplot distribution demonstrated a visually apparent U-shaped relationship between uterine flexion and pain perception. BMI showed a weak but statistically significant negative correlation with VAS (Spearman $\rho = -0.176$, $p = 0.036$), whereas age showed no significant association.

Conclusions

Extreme uterine flexion patterns, particularly excessive high flexion, were associated with increased discomfort during office hysteroscopy. These findings suggest that uterine geometry may represent a

clinically relevant anatomical factor influencing procedural tolerability. UCA assessment may contribute to individualized patient counselling and procedural planning in outpatient hysteroscopy. Larger prospective and randomized studies are warranted to validate these anatomical predictors of pain.

ESGE35-0115 -
Free Communication

Delayed adult presentation of obstructed hemivagina with suspected cervicovaginal atresia and ipsilateral renal agenesis.

Bassem Skaff[1], Omar Alameddine[2], Salwa Abouljoud[2], Sara El Lakiss[3]
[1]New Mazloum Hospital, Gynecology and Obstetrics, Tripoli, Lebanon
[2]American University of Beirut, Obstetrics and Gynecology, Beirut, Lebanon
[3]New Mazloum Hospital, Radiology, Tripoli, Lebanon

Background

Obstructed hemivagina and ipsilateral renal anomaly (OHVIRA) syndrome is a rare Müllerian anomaly usually diagnosed after menarche. We report a delayed adult presentation of an OHVIRA-spectrum anomaly with right-sided obstructed genital tract, suspected cervicovaginal atresia, ipsilateral renal agenesis, chronic pelvic pain, and preserved fertility through the contralateral uterus.

Methods

A 33-year-old G4P3A1 woman with three previous term caesarean deliveries and one spontaneous abortion presented with severe right-sided pelvic pain, back pain, dysmenorrhea requiring analgesia, bloating, dyspareunia, and almost daily dark spotting. Symptoms reportedly began after her second delivery. All pregnancies had occurred in the left uterus and were uncomplicated. Available previous operative reports were limited, including a prior laparotomy performed six months after the second delivery for removal of a right-sided 10 cm endometrioma. Pelvic magnetic resonance imaging demonstrated a duplicated uterus with two cervices and two vaginas joining distally, right sided hematocolpos, right renal agenesis, and a 4 cm anterior intramural fibroid in the right uterine horn. Preoperative haemoglobin and renal function were normal.

Results

Diagnostic laparoscopy demonstrated two uterine horns, with marked distension and engorgement of the right uterine cavity and an anterior intramural fibroid. Both ovaries appeared normal. Both fallopian tubes were identified without hematosalpinx; however, significant adhesions and endometriotic implants were noted. Diagnostic hysteroscopy was performed under direct visualization. Initial cold-scissor dissection was attempted, followed by conversion to operative hysteroscopy. Under transvaginal ultrasound guidance, a hysteroscopic hook was used to fenestrate and partially resect the obstructing septum/outflow tract by approximately 1.5 cm. Entry into the obstructed right cavity resulted in drainage of accumulated dark altered blood. Partial resection was completed to maintain drainage, with satisfactory hemostasis and no intraoperative complications.

Conclusions

This case highlights a diagnostically challenging delayed presentation of OHVIRA syndrome after multiple uncomplicated pregnancies in the contralateral uterus. Chronic dark spotting may suggest partial communication or intermittent drainage, potentially contributing to delayed diagnosis. Magnetic resonance imaging is essential for anatomical mapping, while combined laparoscopic and

ultrasound-guided hysteroscopic management may allow safe drainage and preservation of uterine anatomy in selected cases. Written informed consent was obtained for anonymous presentation and publication.

https://player.vimeo.com/video/1190818091?autoplay=1

ESGE35-0423 -
Free Communication

A novel hysteroscopic approach for FIGO type 3 fibroid

Ece Aksakal[1], *Irem Usta Korkut*[1], *Bulent Urman*[1]
[1]*American Hospital, Obstetrics and Gynecology, Istanbul, Türkiye*

Background

FIGO type 3 myomas are relatively uncommon submucosal leiomyomas characterized by complete intramural localization while maintaining direct contact with the endometrium. They are increasingly recognized in infertile patients due to their potential negative impact on implantation and reproductive outcomes. Unlike FIGO type 0, 1, and 2 submucosal myomas, which typically protrude into the uterine cavity and are readily accessible hysteroscopically, FIGO type 3 myomas are usually not visible within the cavity during standard hysteroscopic evaluation because they remain entirely embedded within the myometrium.

For this reason, conventional hysteroscopic myomectomy has historically been considered suitable mainly for FIGO type 0–2 lesions. Management of FIGO type 3 myomas remains technically challenging due to difficulties in localization, limited visualization, and the risk of excessive endometrial or myometrial damage.

Methods

A 43-year-old woman with a history of infertility presented with the desire for future pregnancy. She had previously undergone three IVF cycles, one resulting in a missed abortion, while the remaining attempts failed to achieve pregnancy. Preoperative evaluation demonstrated a 17 mm FIGO type 3 leiomyoma located within the right lateral uterine wall, confined to the junctional zone. A hysteroscopic approach was planned for surgical management.

Initially, office hysteroscopy was performed to evaluate the intrauterine cavity and localize the lesion. Concurrently, transrectal ultrasound guidance was utilized to identify the exact position of the myoma. An oocyte collection needle was advanced under ultrasound guidance, and methylene blue was injected to mark the corresponding intrauterine location of the lesion.
Subsequently, a bipolar hysteroscope was introduced into the uterine cavity. Using a loop electrode, endometrial incisions were initiated at the methylene blue–stained area to gain access to the myoma. The lesion was progressively dissected and excised in a slice-by-slice fashion down to the level of the pseudo capsule.

The operation was concluded without bleeding or complications. Hyalobarrier® gel was instilled into the uterine cavity to reduce postoperative adhesion formation.

Results

The present technique demonstrates a novel minimally invasive approach combining ultrasound-guided localization with hysteroscopic resection. By using real-time imaging guidance and intracavitary marking, precise access to deeply situated junctional zone myomas can be achieved

while preserving surrounding endometrial tissue. Although technically demanding, this approach may expand the role of hysteroscopic surgery in selected FIGO type 3 myomas and offers a fertility-preserving alternative to more invasive surgical techniques.

Conclusions

While it may be debatable whether IVF failures could be attributed to the type III fibroid given the patients age and the relatively low chances of transferring a euploid embryo, the case is an example for introducing a new approach for removing lesions that are not obvious to the naked eye during hysteroscopy. Besides fibroids, this approach also may be suitable for removing internal adenomyotic lesions disrupting the junctional zone.

https://player.vimeo.com/video/1191619212?autoplay=1

ESGE35-0445 -
Free Communication

Hysteroscopic removal of retained foetal bone fragments: a rare cause of secondary infertility.

Sabrina Sassone[1], Mary Jo Troisi[2], Flavia Peres[2], Laura Carmen Ciccarelli[2], Danilo Borrelli[2], Maria Chiara De Angelis[3]
[1]University of Rome "Tor Vergata" Rome- Italy., Department of Surgical Sciences- Gynecological Unit, Afragola, Italy
[2]University of Naples Federico II- Naples- Italy., Department of Public Health, Naples, Italy
[3]University of Naples Federico II- Naples- Italy.,
Department of Neuroscience- Reproductive Sciences and Dentistry- School of Medicine, Naples, Italy

Background

The aim of this video case report is to describe the hysteroscopic management of retained fetal bone fragments as a rare cause of secondary infertility and abnormal uterine symptoms, and to demonstrate a minimally invasive, fertility-preserving approach using modern office hysteroscopic instrumentation.

Methods

We present a video case report of a 36-year-old woman with a history of previous caesarean delivery and recent dilation and curettage for retained second-trimester miscarriage (two months before), with abnormal foul-smelling vaginal discharge. Diagnostic transvaginal ultrasound revealed a linear hyperechoic double-track structure consistent with retained foetal spinal ossification centres ("railroad sign"). Office hysteroscopy was performed using a 5-mm Bettocchi® continuous-flow hysteroscope with saline distension (Karl Storz SE & Co.-KG, Tuttlingen, Germany) without any anesthesia. Retained foetal spinal fragments and additional embryonic remnants were identified, along with early signs of endometritis. Initial removal attempts using 5-Fr grasping forceps were unsuccessful. Extraction was ultimately achieved following radial cervical incisions of the internal os using bipolar energy with a 5-Fr Twizzle™ bipolar electrode (VersaPoint™ system; Johnson & Johnson MedTech, Ethicon, Cincinnati-OH, USA), enabling successful removal with a 5-Fr tenaculum. Residual fragments were completely cleared using a 6-mm TruClear™ Tissue Removal System with a Dense Tissue Shaver (Medtronic, Minneapolis-MN, USA).

Results

Hysteroscopy confirmed retained foetal spinal bone fragments with early maceration two months after spontaneous abortion. Complete removal was achieved entirely hysteroscopically without complications or need for additional surgical approaches. At the conclusion of the procedure, the uterine cavity was empty. with no residual bone or foetal tissue visualized. Endometrial preservation was maintained throughout the intervention.

Conclusions

Retained foetal bone fragments, though rare, represent a clinically significant and likely underdiagnosed cause of secondary infertility and abnormal uterine symptoms. Transvaginal

ultrasound, particularly when characteristic signs are present, allows prompt diagnosis, while hysteroscopy remains the gold standard for definitive management. Advances in hysteroscopic techniques and miniaturized instruments permit complete, safe, and fertility-preserving removal of retained foetal bone fragments. This video-report represents, to our knowledge, the first documented hysteroscopic video demonstration of this condition and highlights the pivotal role of minimally invasive hysteroscopic surgery in restoring uterine health and reproductive potential.

https://player.vimeo.com/video/1191633067?autoplay=1

ESGE35-0868 -
Free Communication

Hymen-preserving vaginoscopic resection of obstructed hemivagina in OHVIRA Syndrome: a novel minimally invasive technique

Fatma Ezzahra Tekaya[1], Halouani Ahmed[2], Chaffei Olfa[2], Saidi Ezer[2], Halouani Lazhar[2], Triki Amel[2]
[1]Mongi Slim Hospital- La Marsa- Faculty of Medicine of Tunis- University of Tunis- El Manar- Tunis- Tunisia, Gynecology Departement of Mongi Slim Hospital- La Marsa-, Tunis, Tunisia
[2]Mongi Slim Hospital- La Marsa- Faculty of Medicine of Tunis- University of Tunis- El Manar- Tunis- Tunisia, Gynecology Departement of Mongi Slim Hospital- Tunis- Tunisia, Tunis, Tunisia

Background

OHVIRA syndrome is a rare Müllerian malformation characterized by uterine duplication, obstructed hemivagina, and ipsilateral renal anomaly. Standard surgical management typically involves vaginal septum incision using retractors, which may compromise hymenal integrity.

Methods

We report a case of a 22-year-old woman presenting with severe dysmenorrhea. Imaging (ultrasound and MRI) revealed a bicornuate bicervical uterus with obstructed hemivagina and hematocolpos (10 cm), classified as U3C2V3 (ESHRE classification), associated with right renal agenesis.

Surgical management was performed using a vaginoscopic approach with an 18 Fr bipolar resectoscope, avoiding the use of vaginal retractors.

Results

Complete resection of the blind hemivagina was achieved without intraoperative complications. Hymenal integrity was preserved. Postoperative ultrasound confirmed complete resolution of hematocolpos. The patient had favourable clinical outcomes.

Conclusions

Vaginoscopic resection using a bipolar resectoscope is a safe and effective minimally invasive alternative for managing OHVIRA syndrome, with the added benefit of preserving hymenal integrity. This technique may represent a valuable option, particularly in young patients.

https://player.vimeo.com/video/1195720994?autoplay=1

ESGE35-0041 -
Free Communication

How to reduce your CO_2 footprint in the operating room: from advice to a sustainable implementation

Frank Willem Jansen[1], *Kim van Nieuwenhuizen*[1], *Hans Friedericy*[2], *Anne van der Eijk*[3]
[1]*leiden University Medical Center, Gynaecology, Leiden, The Netherlands*
[2]*Leiden University Medical Center, Anaesthesiology, Leiden, The Netherlands*
[3]*Leiden University Medical Center, ICT, Leiden, The Netherlands*

Background

Healthcare accounts for approximately 7% of the national CO_2 footprint, with operating rooms (ORs) contributing disproportionately. Despite occupying only 6% of hospital floor space, ORs generate up to 30% of hospital waste and are highly energy intensive. In the Netherlands, surgical specialists have united in the national “Green OR” network to develop strategies for OR sustainability.

Methods

Key intervention themes were identified through a bottom-up approach combined with a review of the literature. Strategies were structured according to the R-ladder framework to prioritize high-impact reduction measures.

Results

Six principal domains for CO_2 reduction were identified:

1. Sustainability guidelines: Development of an evidence-based guideline using the GRADE methodology to incorporate sustainability into surgical decision-making (e.g., minimally invasive vs. robot-assisted techniques).

2. Anesthesia practices: Preference for intravenous anesthesia (propofol) over inhalational agents, achieving reductions of up to 76% (desflurane −100%, isoflurane −94%, sevoflurane −44%), corresponding to annual savings exceeding 3.4 million kg CO_2.

3. Circular use of materials: Implementation of reusable surgical gowns (−60%), optimization of instrument trays (−40%), transition to reusable instrument containers, and use of non-sterile gloves (−10%).

(4) Air handling optimization: Adjustments in ventilation during off-hours (−41%), reduced humidification (−33%), decreased outdoor air supply (−49%), and lowering air classification from class 1+ to 1 (−36%).

5. Barometer: Development of a benchmarking tool to assess OR sustainability performance and provide tailored recommendations on individual hospital bases.

6. Education: Implementation of structured training programs for all OR personnel.

Conclusions

Over a five-year period, the national Green OR network has developed practical, evidence-based recommendations for reducing the environmental impact of surgical care. While these measures are readily applicable, implementation remains complex due to supply chain constraints and required behavioural changes. Although many interventions offer cost savings, initial investments may be necessary. Sustainable transformation of the OR ultimately requires both systemic changes and reductions in overconsumption of medical resources

ESGE35-0154 -
Free Communication

Impact of FGM on endoscopic surgery

Mohamed Salama[1], Elakhras Sayed[2], Vasilios Tanos[3]
[1]Ain Shams University, Obstetrics and Gynaecology, Cairo, Egypt
[2]Omam Hospital, Minimally Invasive Gynecology, Cairo, Egypt
[3]Nicosia Medical School, Obstetrics and Gynecology, Nicosia, Cyprus

Background

FGM is a socio-cultural problem, deeply rooted, and widely practiced in some communities. The main adverse effects of these mutilative procedures on women's health include psychological, sexual and urinary side effects.
While urogynaecologists and urologists are met with the aftermath of these practices, the gynecological endoscopists are not far from being compromised by the abnormal anatomy met with in such cases

Methods

We discuss, through a case series, the impact of FGM practices on the feasibility and outcomes of gynecological endoscopic surgery, both hysteroscopic, endoscopic and cystoscopic.
We will discuss the different challenges and the proposed manoeuvres that the gynaecological endoscopists can use to navigate such challenges.

Results

Several challenges arise form FGM on the gynecological endoscopic interventions. However, there are some manoeuvres that can be implemented to navigate such challenges.
These are related to techniques to clarify the ambiguity of anatomical landmarks in such a setting of disturbed anatomy, as well as techniques to access these narrowed pathways.

Conclusions

FGM is a very harmful practice that should have no place in modern women's care and wellbeing. However, as it is still deeply rooted in some cultures, the gynecological endoscopists may encounter women suffering the aftermath of these procedures.
The endoscopic surgeons should be ready with some manoeuvres to navigate the challenges imposed by these practices.

ESGE35-0192 -
Free Communication

Clinical anatomy of Corona Mortis: an original study

Zuzana Marvanova[1], *David Kachlik*[2]
[1]*The Institute for Mother and Child Care, The Center for Endometriosis Care, Prague, Czech Republic*
[2]*2nd Faculty of Medicine- Charles University, Department of Anatomy, Prague, Czech Republic*

Background

The vascular supply of the lesser pelvis shows a high degree of anatomical variability. The aim of this study was to evaluate the incidence and morphology of variations in the obturator vessels and to propose a clear classification of “corona mortis” (CMOR) applicable in clinical practice as well as in scientific research.

Methods

A total of 587 hemipelves of Central European origin were examined, including 209 from anatomical dissections, 238 from clinical autopsies, and 140 from CT angiographies. The types of arterial and venous variations, their calibre, and their distance from a defined anatomical landmark (the midpoint of the pubic symphysis) were recorded.

Results

The normal course of the obturator artery (originating from the internal iliac artery) was observed in 72.57 % of cases. Arterial variations were identified in 27.43% of specimens, with the aberrant obturator artery being the most common type (22.53%). Variations of the obturator vein were found in 94.17% of hemipelves, most frequently in the form of the accessory aberrant obturator vein (82. 96%).

Conclusions

The high incidence of these vascular variations confirms the importance of detailed anatomical knowledge during surgical and interventional procedures within the pelvis. The risk of CMOR injury is notably increased during pelvic lymphadenectomy for gynaecological malignancies, Urogynaecological procedures, and advanced laparoscopic dissection for deep infiltrating endometriosis.

ESGE35-0279 -
Free Communication

Factors associated with surgeon pain and fatigue during gynaecologic laparoscopy: a national cross-sectional survey

Waldir Modotti[1], Gustavo Boas[2], Flávia Bueloni-Dias[2], Nilton Leite[2], Sarah Lobo[2], Daniel Dias[2]
[1]Instituto Modotti, Gynecology, Assis, Brazil
[2]Sao Paulo State University – FMB/Unesp, Department of Gynecology and Obstetrics, Botucatu, Brazil

Background

To identify factors associated with musculoskeletal pain and time to fatigue among gynaecologists performing laparoscopic surgery.

Methods

Cross-sectional observational study based on a structured nationwide survey conducted in Brazil. Participants were gynaecologists with experience in laparoscopic surgery. Data were collected through an online questionnaire assessing sociodemographic characteristics, ergonomic knowledge and application, surgical environment, and characteristics related to musculoskeletal pain and fatigue. Pain frequency and time to fatigue were defined as the primary outcomes. Univariate and multivariable logistic regression analyses were performed to identify independently associated factors, with adjustment for potential confounders. Statistical significance was set at 5%, adopting a 95% confidence interval (CI).

Results

A total of 193 gynecologic laparoscopic surgeons participated. Musculoskeletal pain was reported by the majority. Female participants reported a higher frequency of pain and greater involvement of multiple anatomical sites. In multivariable analysis, female gender remained independently associated with higher pain frequency (aOR = 3.643; 95% CI 1.364–9.725; p = 0.010), and greater weekly laparoscopic workload (aOR = 1.432; 95% CI 1.004–2.043; p = 0.047). Full application of ergonomic principles was associated with a lower frequency of pain (aOR = 0.186; 95% CI 0.036–0.949; p = 0.043). Regarding time to fatigue, regular physical activity was identified as an independent protective factor against early fatigue (aOR = 0.797; 95% CI 0.640–0.993; p = 0.043). Additionally, weekly workload, higher level of laparoscopic experience, and full application of ergonomic principles remained independently associated with the outcome.

Conclusions

Musculoskeletal pain and fatigue are highly prevalent among Brazilian gynecologic laparoscopic surgeons. Female gender and weekly workload are independent risk factors for pain frequency, whereas ergonomic principles protect occupational health and long-term career sustainability. Furthermore, physical activity, weekly workload, laparoscopic experience, and ergonomic practices were independently associated with longer time to fatigue.

ESGE35-0363 -
Free Communication

Learning curve of vNOTES adnexal surgery for benign indications: a CUSUM analysis of the first 100 cases in the Netherlands

Anouk Bus[1], Rebecca Henschen[1], Jean Daemen[2], Nicol Smeets[1], Erik de Loos[2], Martine Wassen[1]
[1]Zuyderland Medical Centre, Department of Obstetrics and Gynaecology, Heerlen, The Netherlands
[2]Zuyderland Medical Centre, Division of General Thoracic Surgery- Department of Surgery, Heerlen, The Netherlands

Background

The increasing adoption of Vaginal Natural Orifice Transluminal Endoscopic Surgery (vNOTES) in adnexal surgery reflects a gradual shift toward minimally invasive approaches with potential benefits in postoperative recovery and comparable surgical outcomes. However, the technique presents unique challenges due to limited workspace and altered surgical orientation, requiring specific skills and experience. While prior studies suggest a variable learning curve, data remain limited. This study aims to assess the learning curve of vNOTES for benign adnexal surgery on the first 100 bilateral salpingectomies and adnexectomies performed by two gynaecologists at Zuyderland Medical Centre in the Netherlands.

Methods

This retrospective cohort study included patients who underwent bilateral salpingectomy or adnexectomy via vNOTES between March 2020 and November 2025. Procedures were performed by two gynaecologists who had previously completed the learning curve for Vaginal Assisted NOTES Hysterectomy (VANH). Baseline characteristics, perioperative and postoperative outcomes were recorded. The learning curve was assessed per surgeon using a non–risk-adjusted cumulative sum (CUSUM) analysis of a composite outcome including intra-operative complications, operative time, and conversion to alternative surgical techniques. Based on earlier literature, acceptable and unacceptable performance rates were defined as 15% and 30%, respectively. Learning curve completion was defined as crossing the lower 95% limit of the CUSUM chart, indicating that the composite outcome failure rate had reached the predefined acceptable threshold (≤15%).

Results

Gynaecologist 1 performed 49 bilateral salpingectomies and 15 bilateral adnexectomies, with a median interval of 18 days between procedures (IQR 5–53.5). Gynaecologist 2 performed 25 salpingectomies and 11 adnexectomies, with a median interval of 37 days between procedures (IQR 2.5–63).The composite outcome was not achieved in 17 patients (17%). Reasons included exceeding the predefined maximum acceptable operating time (n=13), conversion to an alternative surgical approach due to major bleeding or abdominal adhesions (n=2), and intraoperative complications requiring repair of bowel lacerations (n=2). Non–risk-adjusted CUSUM charts remained within the predefined acceptable and unacceptable thresholds for both gynaecologists. The CUSUM chart for gynaecologist 1 crossed the lower 95% limit after 47 procedures, indicating a statistically significant

composite outcome failure rate of ≤15%. The CUSUM chart for gynaecologist 2 did not cross the lower 95% limit during the study period.

Conclusions

The learning curve of vNOTES adnexectomy and salpingectomy is safe and feasible after completing the learning curve of VANH. Based on the CUSUM analysis, surgical proficiency was achieved after approximately 47 cases, with a median interval between procedures of 18 days (IQR 5–53.5). However, the number of procedures required to achieve proficiency may differ depending on prior surgical experience.

ESGE35-0366 -
Free Communication

Correlation of psychomotor skills acquisition in pelvitrainers and virtual reality simulators with advanced operative performance in high-fidelity models

Dimitrios Balafoutas[1], Konstantinos Stavridis[2], Ralf Joukhadar[2], Nikos Vlahos[1], Alexandros Lazaridis[1], Emmanouil Kalampokas[1]
[1]University of Athens, Obstetrics and Gynecology, Athens, Greece
[2]Spital Männedorf, Obstetrics and Gynecology, Zürich, Switzerland

Background

Surgical education in gynecological endoscopy has decisively transitioned toward proficiency-based simulation curricula. While the pedagogical value of simulation is well established, the exact degree to which foundational psychomotor skills acquired in low-fidelity pelvitrainers and virtual reality (VR) platforms translate into holistic operative competence during in vivo surgery still requires validation. The primary objective of this study was to evaluate the construct and predictive validity of these multimodal simulation platforms, establishing their statistical correlation with standardized operative performance in high-fidelity biological models.

Methods

An intensive, proficiency-based training curriculum was completed by 32 participants presenting with varying baseline experience in minimally invasive gynecological surgery. The cohort was prospectively evaluated across three distinct simulation modalities: 1) standardized dry-lab tasks utilizing the Szabo-Berci Pelvic Trainer (navigation, star cutting, balance, string threading, and ring transfer), 2) a virtual reality simulator capturing automated kinematic metrics (time, path length, and specific error rates), 3) high-fidelity in vivo animal models (porcine). Operative performance in the biological models was blindly assessed using the validated Objective Structured Assessment of Technical Skills (OSATS) global rating scale across its standard seven domains (tissue handling, time and motion, instrument handling, knowledge of instruments, flow of operation, use of assistants, and knowledge of specific procedure). Statistical analyses incorporated Pearson correlations, independent t-tests, and Wilcoxon rank-sum tests to evaluate significance.

Results

Data analysis revealed strong correlations between pelvitrainer and VR simulator performance and in vivo operative competence. VR simulator time and error metrics demonstrated a strong inverse correlation with overall OSATS ratings ($r=-0.73$, $p<0.001$), accounting for 54% of the variance in actual surgical performance ($R2=0.54$). Within the pelvitrainer cohort, task completion times consistently predicted operative success; specifically, the time required for "star cutting" ($r=-0.64$,$p<0.001$) and "string threading" ($r=-0.61$,$p<0.001$) emerged as the most significant predictive indicators. Furthermore, participants with prior pelvitrainer experience achieved significantly higher overall OSATS scores compared to simulator-naïve novices (22.50 vs. 17.00,$p=0.037$), excelling particularly in respect for tissue handling ($p=0.013$) and flow of operation ($p=0.004$). Prior experience with in vivo animal models also correlated positively with improved operative flow ($p=0.048$).

Conclusions

Objective performance and kinematic metrics derived from both low-fidelity pelvitrainers and virtual reality platforms are strongly predictive of advanced surgical competence in high-fidelity in vivo models. While VR simulation provides unparalleled automated tracking of kinaesthetic economy, the physical pelvitrainer remains absolutely indispensable for developing true haptic feedback, safe tissue handling, and complex bimanual dexterity. These findings strongly support the implementation of standardized, multimodal simulation curricula to ensure safe, objective skills transfer in gynecological endoscopy.

ESGE35-0394 -
Free Communication

Building capacity in hysteroscopy: a tiered training system from a high-volume day surgery centre

Hong Zhan[1], Yue Wang[1]
[1]Women's Hospital School of Medicine Zhejiang University, Gynaecology, Hangzhou, China

Background

To describe the development and implementation of a tiered hysteroscopy training system established by a high-volume gynaecological day surgery centre, and to present a centre-based model for improving standardised hysteroscopic training and regional surgical capacity.

Methods

Since 2022, our centre has organised repeated hysteroscopy training programmes in different regions of China. The training system was built around four connected components: staged theoretical teaching, focused hands-on workshops, tailored clinical practice and faculty development. Participants were grouped into basic, intermediate and advanced levels according to previous experience, technical needs and expected clinical roles.

The basic level focused on safe entry, vaginoscopic hysteroscopy, systematic inspection of the uterine cavity, fluid management, instrument assembly, inflow and outflow control, and basic operative management of common causes of abnormal uterine bleeding (AUB). The intermediate level focused on operative progression, including mechanical instruments, energy-based techniques, lesion assessment, tissue removal, perioperative management and early recognition of complications. The advanced level addressed complex hysteroscopic practice, including severe intrauterine adhesions, reproductive tract malformations, pregnancy-related intrauterine conditions, complex cavity recognition, intrauterine suturing, ultrasound-assisted decision-making, crisis simulation and teaching skills.

Teaching methods included short lectures, stepwise demonstration, surgical video review, simulation or tissue-based practice, supervised hands-on training, structured feedback and case discussion.

Results

The programme converted high-volume hysteroscopic practice into a structured training pathway with defined levels, technical modules and safety points. The tiered design allowed beginners to establish basic procedural safety before moving to operative hysteroscopy, while experienced gynaecologists could focus on advanced skills, complication management and teaching capacity. The modular format also made it possible to teach difficult skills separately before integrating them into complete hysteroscopic procedures.

In repeated regional courses since 2022, the programme showed good training efficiency and favourable feedback from participants. It was particularly useful for improving first-line hysteroscopic management of AUB in less-resourced and remote areas. It also provided a route for selected gynaecologists to receive more specialised hysteroscopy training, supporting the use of hysteroscopy for more complex intrauterine conditions through less invasive approaches.

Conclusions

A high-volume day surgery centre can provide the clinical volume, case mix and teaching resources needed to build a structured hysteroscopy training system. A tiered model may improve training efficiency, support standardised AUB management and help hysteroscopy develop from a routine gynaecological tool into a specialised minimally invasive competence requiring professional training.

ESGE35-0593 -
Free Communication

Endometriosis care in Ireland: development of a national framework and supraregional services

Sarah Murphy[1]
[1]*CUMH, Obstetrics and Gynaecology, Roscommon, Ireland*

Background

Endometriosis affects approximately 10% of women of reproductive age and is associated with chronic pelvic pain, infertility and significant impairment in quality of life. Historically, endometriosis care in Ireland has been characterised by delayed diagnosis, fragmented referral pathways and limited access to advanced multidisciplinary surgical services. Increasing public awareness, patient advocacy and national media attention surrounding women travelling abroad for specialist treatment highlighted deficiencies within the Irish healthcare system. In response, Ireland has recently introduced major national reforms including publication of the Royal College of Physicians of Ireland (RCPI) National Clinical Guideline on Endometriosis and the launch of a National Framework for Endometriosis Care.

Methods

To describe the evolution of endometriosis care in Ireland and the implementation of a national specialist model of care. A narrative review and policy analysis of recent developments in Irish endometriosis care was undertaken. National clinical guidelines, governmental framework documents, publicly available health policy reports and specialist service developments were reviewed. Key themes including referral pathways, multidisciplinary care, specialist surgical services and national implementation strategies were analysed.

Results

The RCPI National Clinical Guideline on Endometriosis established standardised recommendations for diagnosis, imaging, medical management and surgical referral pathways. Subsequently, the Irish Health Service Executive introduced a National Framework for Endometriosis Care aimed at improving equity of access and centralising complex disease management. Two supraregional endometriosis centres were established in Cork and Tallaght University Hospital with a multidisciplinary model incorporating advanced minimally invasive gynaecological surgery, specialist radiology, pain management and fertility services. These developments represent a significant transition from historically localised and inconsistent care pathways toward a coordinated national specialist service. Ongoing challenges remain, including prolonged waiting times, regional inequity in access to specialist imaging and surgery, and the need for structured national training pathways in advanced endometriosis surgery.

Conclusions

Ireland is undergoing a major transformation in endometriosis care through implementation of national guidelines, establishment of specialist centres and development of a coordinated framework

of care. Continued investment in multidisciplinary services, surgical training and equitable access will be essential to ensure successful national implementation and improved patient outcomes.

ESGE35-0730 -
Free Communication

Implementation of a modular training approach to improve trainee autonomy during total laparoscopic hysterectomy: A quality improvement project

Hira Fatima[1], Muazzam Ali[2], Javeria Zahid[3], Remko Beukehnholdt[1], Ammara Sultan[4], Oluwasegun Akinyemi[5]
[1]Darlington Memorial Hospital, Gynaecology and Obstetrics, Darlington, United Kingdom
[2]Holy Family Hospital, Paediatrics, Islamabad, United Kingdom
[3]Independent University Hospital, Surgery, Faisalabad, United Kingdom
[4]University Hospital of North Durham, Gynaecology and Obstetrics, Durham, United Kingdom
[5]Howard University College of Medicine,
Department of Community Health and Medicine- Coordinator- Center for Innovation, Washington- DC, USA

Background

Training opportunities in advanced gynaecological laparoscopy can be variable particularly for trainees progressing towards independent total laparoscopic hysterectomy (TLH). In our unit trainee involvement during TLH was inconsistent and often influenced by case complexity service pressures and operating time constraints. The aim of this project was to assess whether introduction of a structured modular training approach could improve trainee autonomy during TLH without adversely affecting perioperative outcomes.

Methods

This quality improvement project was carried out in a district general gynaecology unit over two cycles between September 2025 and April 2026. Baseline data were collected retrospectively from 34 TLHs performed during the study period for indications including heavy menstrual bleeding fibroids adenomyosis endometriosis atypical endometrial hyperplasia and selected early-stage gynaecological malignancy cases.

Outcome measures included level of trainee involvement consultant takeover operative time estimated blood loss conversion to laparotomy perioperative complications and length of hospital stay.

Following review of baseline data a structured modular training approach was introduced. Procedures were divided into defined operative steps with preoperative allocation according to trainee competency and supervision requirements. Preoperative case discussions and routine postoperative debriefing were also incorporated into the pathway.

A second cycle was completed using the same outcome measures in a further 34 TLHs performed following implementation of the intervention.

Results

Following introduction of the modular training pathway trainee completion of more than 70% of operative steps increased from 26.5% (9/34) to 67.6% (23/34). Consultant takeover during key parts of the procedure reduced from 44.1% (15/34) to 20.6% (7/34).

Mean operative time increased slightly following implementation of the pathway (127 minutes vs 135 minutes) however there was no increase in estimated blood loss perioperative complications or length of hospital stay. One case in each cycle required overnight high dependency monitoring unrelated to surgical complications. No cases required conversion to laparotomy in either group.

The intervention also improved consistency of operative planning and allowed more focused intraoperative teaching and postoperative feedback within the unit.

Conclusions

Implementation of a structured modular approach to TLH training improved trainee autonomy without compromising patient safety or surgical outcomes including in selected pre-malignant and oncological cases. Dividing procedures into defined operative steps allowed training opportunities to be utilised more effectively within a busy district general hospital gynaecology unit. This approach may provide a practical framework for supporting advanced laparoscopic training in units facing increasing service pressures and reduced operative exposure.

ESGE35-0852 -
Free Communication

Extending the gynaecologist repertoire: the role of appendicectomy in complex benign pelvic pathology

Nadica Nikolova Nakev[1], Natasha Liou[2], Grigoria Gkova[2], Maria Eduarda Ferreira Bruco[2], Manikandan Kathirvel[1], Guldzhan Vorona[2]
[1]Whittington Hospital, General Surgery, London, United Kingdom
[2]Whittington Hospital, Gynaecology & Obstetrics, London, United Kingdom

Background

Appendiceal pathology and gynaecological pelvic disease share anatomical proximity and overlapping clinical presentations. This case series examines the spectrum of appendiceal involvement encountered during laparoscopic gynaecological surgery and makes the case for expanding advanced gynaecological surgical competence to include appendicectomy.

Methods

A retrospective case series of nine patients undergoing appendicectomy in the context of laparoscopic gynaecological surgery for complex benign pelvic pathology at a North London district general hospital between 2023-2026. Cases were identified via operative records. Clinical presentation, pre-operative imaging, operative findings, histopathology and postoperative outcomes were reviewed.

Results

Nine women aged 15-51 years were included. Primary gynaecological diagnoses were tubo-ovarian abscess (n=5), complex ovarian cyst or torsion (n=3), and chronic pelvic pain with incidental low-grade appendiceal mucinous neoplasm (LAMN) on histology (n=1).

Preoperative cross-sectional imaging failed to visualise or characterise the appendix in 4/9 cases (44%). Surgery was performed as a planned joint gynaecology–general surgery procedure in 3/9 cases; in 6/9 cases, appendiceal pathology was an intraoperative finding requiring urgent decision-making. Laparoscopy was converted to laparotomy in 2/9 cases due to complexity. One patient required ITU admission following emergency laparotomy for 4-quadrant peritonitis after a diagnostic delay exceeding 12 months.

Appendiceal involvement was identified across a broad spectrum of benign pelvic pathology. Intraoperative findings included appendiceal adherence to TOA, inflammatory pelvic phlegmon and ovarian dermoid cysts, appendiceal distortion within frozen pelvis, reactive appendiceal serositis associated with severe adnexal inflammation, and acute appendicitis. Extensive adhesions involving bowel, omentum and adnexal structures were frequently encountered, with several cases requiring multidisciplinary collaboration between gynaecology and general surgery teams.

Histopathology demonstrated acute appendicitis (n=1), acute-on-chronic serositis (n=2), inflammatory adhesions (n=3) and reactive appendiceal changes secondary to adjacent pelvic sepsis (2). One patient was unexpectedly diagnosed with low-grade appendiceal mucinous neoplasm

following surgery for chronic TOA, requiring referral to a tertiary peritoneal malignancy centre.

Additional associated findings included Fitz-Hugh–Curtis syndrome, hydrosalpinx, pelvic abscesses, torsion-related ischaemic change and bowel involvement.
Most patients had resolution of pelvic sepsis and symptoms following combined surgical and antimicrobial management.

Follow-up imaging demonstrated resolution or significant improvement of inflammatory pelvic disease in most of the cases.

Conclusions

Appendiceal involvement may coexist with complex benign gynaecological disease more frequently than recognised.

Preoperative imaging was unreliable for appendiceal assessment in nearly half of cases.
Gynaecologists must be equipped to recognise appendiceal involvement intraoperatively, exercise sound judgement regarding appendicectomy, and understand the histological differential including rare but clinically significant diagnoses such as LAMN.

Ongoing multidisciplinary collaboration between gynaecology and general surgery teams appears to improve surgical decision-making and patient outcomes in complex pelvic disease.

Expanded exposure to general surgical principles and bowel pathology should be incorporated into advanced gynaecological curricula to further support the safe management of increasingly complex benign pelvic pathology.

ESGE35-0927 -
Free Communication

Endometriosis knowledge and training gaps among early-career gynaecologists: a global survey

Sofia Tsiapakidou[1], Kubra Kubra[2], Evaggelia Deligeoroglou[3], Mary-Anne Zuolo[4], Duygy Ucar Kartal[5], Elif Goknur Topcu[6]
[1]1st Department of Obstetrics and Gyneacology General Hospital Papageorgiou Aristotle University of Thessaloniki,
1st Department of Obstetrics and Gynaecology- Medical School- Aristotle University of Thessaloniki- G reece, Thessaloniki, Greece
[2]Dogubeyazit State Hospital, Department of Obstetrics and Gynecology, Agri, Türkiye
[3]Faculty of Medicine- Aristotle University of Thessaloniki,
1st Department of Obstetrics and Gyneacology General Hospital Papageorgiou, Thessaloniki, Greece
[4]Korle Bu Teaching Hospital, Department of Obstetrics and Gynecology, Accra, Ghana
[5]Manisa Merkezefendi State Hospital, Department of Obstetrics and Gynecology, Manisa, Türkiye
[6]Sisli Kolan International Hospital, Department of Obstetrics and Gynecology- IVF Unit, Istanbul, Türkiye

Background

The clinical management of endometriosis remains challenging due to its complex and variable clinical presentation, often leading to significant worldwide delays in diagnosis. This study aimed to assess current awareness, daily clinical practices, and educational gaps concerning endometriosis classification systems, diagnostic imaging, and core symptomatology among young physicians globally.

Methods

A structured, anonymous cross-sectional online survey was distributed globally to young gynaecologists between November 2024 and May 2025 by the International Federation of Fertility Societies (IFFS) Next Generation team. The 21-item questionnaire evaluated demographics, theoretical and practical training experiences, and symptom recognition. Adequate knowledge was defined a priori as the correct identification of at least three out of four core symptoms: infertility, chronic pelvic pain, dyspareunia, and dyschezia. Data analysis and visualizations were performed using Stata©. Associations were assessed using Chi-square tests, with $p<0.05$ considered statistically significant.

Results

A total of 186 participants from Europe, Asia, Africa, and the Americas were included, primarily consisting of residents (39.7%) and specialists within five years of completing residency (38.6%). Specific theoretical training in endometriosis during residency was reported by only 27.3% of respondents, and a mere 15.1% had received structured training in endometriosis imaging. While the recognition of core classic symptoms such as chronic pelvic pain (98.4%) and infertility (96.2%) was exceptionally high, awareness dropped significantly for systemic or lower pelvic manifestations like

dyschezia (57.7%) and painful rectal bleeding (53.8%). Overall, 66.7% of participants demonstrated adequate knowledge levels, which varied significantly by continent of training ($p = 0.004$).

Conclusions

Substantial and persistent deficiencies exist in structured, standardized medical education and imaging training pathways for early-career gynaecologists worldwide. To bridge these clinical competency gaps, minimize global diagnostic delays, and optimize patient outcomes, the implementation of evidence-based educational initiatives during residency and the expansion of dedicated, specialized clinical training modules are heavily required.

ESGE35-0936 -
Free Communication

Postgraduate education and clinical competency disparities in chronic pelvic pain: a pan-European survey among European obstetrics and gynaecology trainees and young specialists

Sofia Tsiapakidou[1], Mei Yee Ng[2], Rafal Zadykowicz[3], Sara Vodopivec[4], Maia Susana[5], Helder Ferreira[6]
[1]1st Department of Obstetrics and Gyneacology General Hospital Papageorgiou Aristotle University of Thessaloniki,
1st Department of Obstetrics and Gynaecology- Medical School- Aristotle University of Thessaloniki- G reece, Thessaloniki, Greece
[2]The Coombe Hospital, Department of Obstetrics and Gynecology- IVF Unit, Dublin, Ireland
[3]Medical University of Warsaw,
Department of Obstetrics- Perinatology- Gynecology and Reproductive Medicine, Warsaw, Poland
[4]Medical Faculty- University of Ljubljana, Department of Obstetrics and Gynecology, Ljubljana, Slovenia
[5]Hospital Lusiadas Porto, Department of Obstetrics and Gynecology, Porto, Portugal
[6]Centro Materno Infantil do Norte., Department of Gynecology, Porto, Portugal

Background

Chronic pelvic pain (CPP) is a complex, multifactorial clinical condition requiring specialized, multidisciplinary clinical management. This study aimed to evaluate the current educational landscape, standardized training curriculum availability, clinical exposure levels, and diagnostic preparedness regarding CPP among obstetrics and gynaecology trainees and young specialists across Europe.

Methods

A voluntary, cross-sectional online pan-European survey comprising 17 structured questions was collaboratively launched in February 2026 by the European Network of Trainees in Obstetrics and Gynaecology (ENTOG) and the Minimally Invasive Surgery (MIS) Academy. The targeted questionnaire evaluated baseline demographics, existence of official national curricula, dedicated educational training modules, independent diagnostic confidence, and holistic clinical experiences regarding pelvic imaging and multi-specialty interventions. Data analysis aere performed using Stata©. Associations were assessed using Chi-square tests, with $p<0.05$ considered statistically significant.

Results

Final analysis included 116 respondents with a mean age of 30.2.7±6 years and a female-to-male ratio of 3:1. While 75% of participants confirmed the existence of an official national curriculum, CPP was explicitly included in only 49.1%, and a dedicated, structured training module was missing or unclear for 65% of respondents. Clinical hands-on encounters were low, with the largest group (n = 40) reporting only 1–5 supervised clinical cases. Self-reported confidence in diagnosing gynaecological etiologies clustered at mid-level scores (2–3 out of 5), with only 4 individuals reporting peak confidence. Significant educational deficiencies were identified in non-gynecological training (51.7% lacking formal gastrointestinal, urological, or psychological coursework), pelvic imaging training

(50.9% reporting no training at all), and structured multidisciplinary training pathways (75.9% lacking exposure). Conversely, 59.5% reported surgical exposure through laparoscopy.

Conclusions

Postgraduate medical training in CPP across Europe remains heavily fragmented and structurally inconsistent, leading to a profound mismatch between clinical complexity and trainee preparedness. To bridge these diagnostic gaps, there is an urgent demand to integrate comprehensive, multi-center pelvic imaging curricula and structured, holistic management frameworks within European core residency requirements.

ESGE35-0982 -
Free Communication

A pilot study of a novel scoring tool to support trainee decision-making in suspected ovarian torsion.

Prashanthi Swami Selvaraj[1], Maheen Anwar[2], Mona Sharma[3]
[1]Queens Hospital. Barking - Havering and Redbridge University Hospital & NHS Trust, Obstetrics and Gynaecology, London, United Kingdom
[2]Queens Hospital. Barking- Havering and Redbridge University Hospital and NHS Trust, Obstetrics and Gynaecology, London, United Kingdom
[3]Queens Hospital. Barking. Havering and Redbridge University Hospital and NHS Trust, Obstetrics and Gynaecology, London, United Kingdom

Background

Ovarian torsion accounts for approximately 2–3% of gynaecological emergencies and remains a diagnostic challenge due to its non-specific clinical presentation and variable ultrasound findings. Delayed diagnosis may result in ovarian loss, while over-triage can lead to unnecessary emergency surgery and increased pressure on emergency theatre services. Decision-making is particularly challenging for trainees during out of hours. To support clinical assessment and improve communication, we developed an objective 13-parameter scoring system to support risk stratification and enable structured SBAR communication in suspected ovarian torsion.

Methods

Our ovarian torsion scoring system was developed using demographic characteristics, presenting symptoms, and ultrasound findings identified in previous published studies as predictors of ovarian torsion. The selected variables represented common clinical and radiological features observed in patients with confirmed torsion and were incorporated into a weighted scoring tool to support risk stratification. To evaluate the performance of the scoring tool, a retrospective pilot study was conducted at a district general hospital between January 2023 and December 2024. Women who had emergency surgery for suspected ovarian torsion were identified, and relevant clinical and imaging data were extracted from electronic patient records. A total of 53 women were included in the analysis. The scoring system was applied retrospectively and blinded to surgical outcomes. Total scores were categorised as unlikely (≤5), indeterminate (6–10), likely (11–14), and highly likely (≥15) for torsion. Operative findings at laparoscopy were used as the reference standard to confirm or exclude ovarian torsion, and the diagnostic performance of the scoring system was assessed against these outcomes

Results

Fifty-three women underwent emergency surgery for suspected ovarian torsion during the study period. Ovarian torsion was confirmed at laparoscopy in 14 cases (26.4%), while 39 women (73.6%) had no torsion. When the scoring system was applied to demographic, clinical, and ultrasound features, women with confirmed torsion had higher average scores than those without (12.2 vs 8.6). Thirteen of the 14 women with torsion (92.9%) were classified as likely or highly likely to have torsion

(score ≥11), whereas 36 of the 39 women without torsion (92.3%) were categorised as indeterminate or unlikely (score ≤10). None of the women in the unlikely group with score ≤5 were found to have torsion at surgery.
The scoring system achieved a sensitivity of 92.9%, specificity of 87.2%, positive predictive value of 72.2%, and negative predictive value of 97.0%. Overall, the high negative predictive value indicates the tool may be particularly useful for supporting reliable exclusion of torsion.

Conclusions

When used alongside clinical assessment, this scoring system reliably identifies women at low risk of ovarian torsion, reducing unnecessary emergency surgical interventions. The use of a structured ultrasound reporting pro-forma, together with enhanced ultrasound training for trainees—moving beyond reliance on Doppler flow alone may support safer decision making.

ESGE35-0119 -
Free Communication

Escaping injury nightmares: Intraoperative repair for severe organ injuries

Masaaki Andou[1], Yoshifumi Ochi[1], Yoshiko Kurose[1], Mari Sawada[2], Kiyoshi Kannno[1], Tsutomu Hoshiba[3]
[1]Kurashiki Medical Center, Gynaecology, Kurashiki-shi, Japan
[2]Kurashiki Medical Cente, Gynaecology, Kurashiki-shi, Japan
[3]Kurashiki Medical Center, Gynaecology, Kurashiki-shi, Japan

Background

As minimally invasive surgery becomes more radical and indications expand, it is possible that the potential for organ injury can increase. To avoid the conversion to open surgery, and post-operative complications, it is necessary to be able to perform intraoperative minimally invasive injury repair. By learning and practicing techniques such as intracorporeal suturing, even severe organ repair can follow and meet the same goals as the original minimally invasive procedure.

Methods

The video will show three specific technique areas of bowel injury repair, urinary tract injury repair, and vessel injury repair. As organ-specific suturing management of injury repair is shown in a stepwise fashion so that techniques can be practiced, mastered, and reproduced.

Basic techniques for bowel injury repair include suturing in two layers- the first layer is full-thickness suturing followed by a second layer of seromuscular inverted suturing. For rectal injuries, end-to-end anastomosis will be shown.

Urinary tract injuries follow the same principles as bowel injury repair- full layer approximation followed by seromuscular approximation. Extensive bladder injury requiring laceration closure with multi-layer suturing will be shown. For ureteral injury repair, we applied ureteroneocystostomy and these techniques will be presented.

For vessel injuries, temporary bleeding control and suture repair of the vessels are presented. Vascular repair requires single-layer, full-thickness everted suturing.

The cases shown cannot be identified and gave their consent for the videos to be used for educational purposes.

Results

For bowel injury repair, of 20 rectal perforations during laparoscopic surgery, we applied intraoperative primary closure of the perforation without covering colostomy in every case. Only one of these cases suffered from fistula formation. This was managed conservatively. The other 19 cases recovered without sequel. 23 patients had urinary tract injuries occur during surgery. 15 cases were found intraoperatively and repaired in the same surgical session, laparoscopically. Eight cases were found post operatively as ureteral stricture or ureteral fistula. These cases required a second surgery. All cases were repaired using minimally invasive laparoscopy or robotic techniques. No cases underwent laparotomy. For vessel perforation, 25 complications occurred during pelvic or para-aortic

lymphadenectomy. All cases were repaired laparoscopically or robotically. No conversions to open surgery and no case underwent blood transfusion.

Conclusions

By following the basic tenets of intracorporeal suturing such as applying the appropriate tension to the suture, incorporating the appropriate amount of tissue in each suture, choosing inverted or extraverted suturing appropriately and selecting a high blood perfusion site for anastomosis, we can maintain the original minimally invasive goals of the surgery and avoid conversion to laparotomy as well as additional surgery.

https://player.vimeo.com/video/1190878097?autoplay=1

ESGE35-0051 -
Free Communication

Comparative analysis of vNOTES and conventional laparoscopic management of intra-abdominal bleeding following total hysterectomy: A 10-year retrospective case series

Berican Sahin Uyar[1], *Gungorduk Kemal*[2]
[1]*Faculty of Medicine- Muğla Sıtkı Koçman University, Department of Obstetrics and Gynaecology, Muğla, Türkiye*
[2]*Muğla Sıtkı Koçman University, Gynaecologic Oncologist:, Muğla, Türkiye*

Background

To compare surgical efficiency, haemostatic efficacy, and early postoperative recovery between vaginal natural orifice transluminal endoscopic surgery (vNOTES) and conventional multiport laparoscopy (CML) for emergency minimally invasive re-exploration of acute intra-abdominal haemorrhage after total hysterectomy in haemodynamically stable patients.

Methods

This 10-year, single-centre retrospective cohort study included 41 haemodynamically stable women undergoing minimally invasive emergency re-exploration for post-hysterectomy acute intra-abdominal haemorrhage (vNOTES, n = 12; CML, n = 29). Inverse probability of treatment weighting based on propensity scores adjusted for baseline confounding, and Firth's penalised logistic regression was used for sparse binary outcomes.

Results

After IPTW adjustment, vNOTES was associated with shorter operative time (Δ = -18.4 minutes; $p < 0.001$), reduced estimated blood loss (Δ = -59.8 mL; $p < 0.001$), and shorter postoperative hospital stay (Δ = -1.5 days; $p < 0.001$) than CML. Successful haemostasis within 30 days was achieved in all vNOTES cases (12/12) without conversion to laparotomy. Postoperative pain at 24 hours was lower after vNOTES (Δ = -1.5 on the visual analogue scale; $p < 0.001$), Quality of Recovery-15 scores at discharge were higher (130.5 ± 8.0 vs 114.7 ± 13.8; IPTW-adjusted Δ = +15.7; $p < 0.001$), and the overall complication rate (Clavien-Dindo grade ≥ I) was lower (Firth-adjusted odds ratio = 0.16; $p = 0.033$).

Conclusions

In this first comparative analysis of its kind, vNOTES showed statistically significant and clinically relevant advantages over CML, including greater operative efficiency, reduced blood loss, fewer complications, and superior early patient-reported recovery. These findings support vNOTES as a feasible first-line minimally invasive strategy for selected haemodynamically stable patients in the emergency setting.

ESGE35-0058 -
Free Communication

Transvaginal NOTES hysterectomy for large uterus weighing 1000 grams or more : a retrospective comparison with multiport laparoscopy

Kemal Güngördük[1], Emre Biton[2], Berican Sahin Uyar[3], Serkan Ustuntas[2]
[1]Muğla Sıtkı Koçman University, Gynaecological Oncology, Muğla, Türkiye
[2]Mugla Sıtkı Koçman University, Department of Obstetrics and Gynaecology, Muğla, Türkiye
[3]Mugla Sıtkı Koçman University, Department of Obstetrics and Gynaecology, Menteşe, Türkiye

Background

To compare the feasibility, perioperative outcomes, and early recovery of transvaginal natural orifice transluminal endoscopic surgery (vNOTES) hysterectomy versus conventional multi-portal laparoscopy (CMPL) for benign uteri weighing ≥1000 g.

Methods

This retrospective cohort study included consecutive women who underwent total hysterectomy with vNOTES or CMPL at two tertiary referral centres, with a final uterine weight of ≥1000 g on histopathology. The evaluated outcomes included operative time, estimated blood loss, conversion rates, intraoperative and postoperative complications (Clavien-Dindo classification), postoperative pain (VAS and FPS-R scores), and overall recovery using the Quality of Recovery-15 (QoR-15) questionnaire.

Results

Forty-two women met the inclusion criteria; 13 were in the vNOTES group and 29were in the CMPL group, with comparable baseline characteristics and uterine weights. The median operative time was shorter with vNOTES than with CMPL (115 vs. 145 minutes, P=0.02), and the median estimated blood loss was lower (160 vs. 260 mL, P=0.01). Early postoperative pain scores (VAS and FPS at 6, 12, and 24 hours) and QoR15 at discharge favoured vNOTES, whereas conversion to laparotomy and overall complication rates, including high-grade events, were low and similar between groups. Final pathology showed benign leiomyomas, with or without adenomyosis, in all cases.

Conclusions

vNOTES hysterectomy for uteri ≥ 1000 g is feasible and may offer benefits over CMPL, including reduced surgical duration, decreased blood loss, and expedited early recovery. Although complication rates were similar, the limited sample size precludes establishing definitive safety equivalence. Consequently, these findings remain exploratory, and larger prospective multicentre studies are necessary to validate comparative safety in massively enlarged uteri.

ESGE35-0454 -
Free Communication

Objective quantification of fluorescence-guided perfusion assessment in laparoscopic gynaecological surgery using a real-time ICG image analysis system

Samuel Mena Fernández[1], Juan Alberto Sanchez-Margallo[2], Carlos Plaza de Miguel[1], Antonio J. Plaza[1], Francisco M. Sánchez-Margallo[3]
[1]University of Extremadura, Technology of Computers and Communications, Cáceres, Spain
[2]Jesús Usón Minimally Invasive Surgery Centre, Robotics- image-guided surgery- and bioprinting, Cáceres, Spain
[3]Jesús Usón Minimally Invasive Surgery Centre, Scientific Direction, Cáceres, Spain

Background

Near-infrared fluorescence imaging using indocyanine green (ICG) has gained increasing relevance in laparoscopic gynaecological surgery for tissue perfusion assessment, vascular mapping, and anatomical identification. However, intraoperative interpretation of fluorescence imaging remains largely subjective and highly dependent on surgeon experience and image acquisition conditions. This limitation may affect the reproducibility of perfusion assessment during procedures such as hysterectomy, ovarian surgery, endometriosis resection, or fertility-preserving interventions. The aim of this study was to develop and preliminarily evaluate a real-time image-processing system capable of providing objective quantitative perfusion metrics during fluorescence-guided laparoscopic gynaecological surgery.

Methods

A dedicated software platform was developed in Python using computer vision and image-processing libraries for real-time fluorescence analysis. The system integrates live laparoscopic video acquisition with dynamic processing of fluorescence signals obtained from commercially available near-infrared imaging systems. The platform enables both interactive and automatic region-of-interest (ROI) selection, tissue segmentation, heatmap generation, and temporal fluorescence analysis. Quantitative parameters extracted from time-intensity curves include fluorescence onset (T0), maximum fluorescence intensity (Fmax), time-to-peak intensity (Tmax), perfusion and washout slopes, and dynamic enhancement patterns. To improve robustness under intraoperative conditions, the system incorporates ROI tracking algorithms with validation based on colour, texture, and shape descriptors, allowing tissue tracking to be maintained or recovered during camera motion or temporary loss of visualisation. The software architecture supports both CPU- and GPU-based processing and was designed to facilitate compatibility with different fluorescence laparoscopic platforms.

Results

Preliminary experimental and intraoperative evaluations demonstrated the technical feasibility of the platform in laparoscopic gynaecological surgery scenarios using different fluorescence imaging systems, including Olympus VISERA ELITE III and Richard Wolf green ICG imaging systems. Real-time visualisation of quantitative fluorescence information and perfusion dynamics was successfully

achieved without disrupting the surgical workflow. The system enabled simultaneous comparison of multiple ROIs and objective characterisation of tissue perfusion patterns through dynamic fluorescence curves and heatmap representations. Initial observations suggest potential utility for reducing variability associated with subjective interpretation during fluorescence-guided procedures. Additional experimental and validation studies are currently ongoing to evaluate measurement accuracy, reproducibility, and clinical applicability under different surgical conditions.

Conclusions

This work presents an interoperable real-time fluorescence quantification system designed to support objective perfusion assessment in laparoscopic gynaecological surgery. The proposed approach may contribute to improving the standardisation and reproducibility of fluorescence-guided surgery by providing quantitative intraoperative information beyond conventional visual interpretation. Further validation studies are required to determine its precision, robustness, and potential clinical impact in advanced minimally invasive gynaecological procedures.

ESGE35-0640 -
Free Communication

A novel uterine-sparing technology for adenomyosis uteri

Mohamed Salama[1], Elakhras Sayed[2], Mohamed Kandil[2], Vasilios Tanos[3]
[1]Ain Shams University, Obstetrics and Gynaecology, Cairo, Egypt
[2]Omam Hospital, Minimally Invasive Gynaecology, Cairo, Egypt
[3]University of Nicosia Medical School, Obstetrics and Gynaecology, Nicosia, Cyprus

Background

Uterine adenomyosis refers to the infiltration of endometrial glands into the myometrium, leading to diffuse or focal uterine enlargement. Diagnosing adenomyosis uteri is sometimes missed, however, implementing the recently published MUSA criteria, or resorting to MRI usually helps.
Adenomyosis is usually presented by heavy or irregular uterine bleeding, and/or pelvic pain. Another significant associated problem is infertility and poor reproductive outcomes. It is with these reproductive problems that the challenging problems of treating adenomyosis arise. Various medical treatment options have been studies, but with mostly sub-optimal outcomes.
Conservative surgical interventions have been compromised by technical difficulty, and the potential risk of uterine rupture with subsequent pregnancy.

Methods

A case series of women with adenomyosis is presented here. Those women's complaints were poor reproductive outcomes (infertility, recurrent miscarriage), pelvic pain, and/or abnormal uterine bleeding.

Microwave ablation of the adenomyotic tissues was performed on this case series, where the microwave needle was inserted during the laparoscopic procedures though the abdominal wall under vision. This was complemented by transvaginal ultrasound guidance to ensure proper targeting of the focal adenomyotic foci, and to avoid the proximity to the endometrium in those women seeking future fertility.

Certain protocols of energy and duration settings were implemented according to the specific conditions of each case.

Results

The preliminary results of this case series showed remarkable improvement of the gynecological complaints, primarily pelvic pain and abnormal uterine bleeding.

Detailed data about the reproductive performance of these ladies and their long-term follow up results are being collected and processed.

Post-operative recovery with microwave ablation seems to be much better in terms of post-operative pian and return to activity.

Conclusions

Microwave ablation of adenomyotic tissue seems to be a promising novel uterine-sparing approach. Although the use of microwave ablation of pathological tissues is not a recent concept in itself, the recently available machines and the validated protocols seem to offer hope for patients with adenomyosis uteri, especially those seeking future fertility.

ESGE35-0774 -
Free Communication

Initial experience with V-NOTES implementation in a secondary care hospital: a retrospective observational study.

Jesús Manuel Barreiro García[1], *María del Carmen Sánchez Sánchez*[1], *Rosana Elena González Suárez*[1], *María del Carmen Parada Millán*[1], *Luis Miguel González Seijas*[1]
[1]*Barbanza Hospital- SERGAS, Obstetrics and Gynaecology, Ribeira, Spain*

Background

V-NOTES (Vaginal Natural Orifice Transluminal Endoscopic Surgery) is an emerging minimally invasive surgical approach that uses the vaginal route as a natural access point. This technique has been associated with reduced postoperative pain, shorter hospital stays and absence of abdominal scars. However, evidence regarding its implementation in secondary care hospitals remains limited.

Methods

A retrospective descriptive study was conducted including all patients undergoing V-NOTES surgery at our secondary care hospital between December 2023 and February 2026. Demographic, surgical and postoperative data were collected from electronic medical records and analysed.

Results

A total of 17 V-NOTES procedures were performed during the study period. Mean patient age was 39.7 years (range 28–75) and mean body mass index was 26.3 kg/m² (range 21.08–38.28). Four patients (26.7%) were smokers. One patient (5.8%) was nulliparous and 16 (94.1%) were multiparous. Previous gynecological surgery was reported in 2 patients (11.7%), both with prior caesarean section.

Procedures performed included 2 bilateral adnexectomies (11.7%), 2 hysterectomies with bilateral adnexectomy (11.7%), 1 ovarian cystectomy (5.8%) and 12 prophylactic salpingectomies (70.5%). Median surgical time was 45 ± 29.2 minutes, calculated from operating room entry to discharge from the operating room. Most procedures were successfully completed using a minimally invasive transvaginal approach without the need for abdominal access.

Regarding postoperative outcomes, 13 patients (76.4%) were managed as ambulatory major surgery cases. Two patients developed postoperative inflammatory vaginal adhesions that were successfully released during gynecological examination. Conversion to conventional laparoscopy was required in 1 patient (5.8%) due to bleeding from the access port. One patient experienced an intraoperative rectal injury that was immediately repaired with satisfactory postoperative recovery.

Conclusions

V-NOTES appears to be a feasible minimally invasive approach for selected gynecological procedures, with high ambulatory management potential. Despite the initial learning curve, implementation of V-NOTES in a secondary care hospital was associated with acceptable surgical and postoperative outcomes.

ESGE35-0983 -
Free Communication

A simplified knotting technique to facilitate hysteroscopic suture fixation of a hormonal intrauterine system

Boping Yang[1], *Chi Yugang*[1]
[1]*Women and Children's Hospital of Chongqing Medical University, China*
Department of General Gynaecology, Chongqing, China

Background

Expulsion of a hormone-releasing intrauterine system may occur in patients with adenomyosis, uterine cavity enlargement or distorted uterine anatomy, compromising long-term symptom control for dysmenorrhoea and heavy menstrual bleeding. Hysteroscopic suture fixation is a potential strategy to maintain the intrauterine position of the device. However, conventional intrauterine knot delivery can be technically demanding, particularly when the knot cannot be advanced precisely to the fixation site or becomes loose during manipulation. This study describes a simplified extracorporeal knot-advancement technique designed to facilitate hysteroscopic suture fixation without the use of a conventional knot pusher.

Methods

A patient with adenomyosis, uterine cavity enlargement and repeated expulsion of a hormone-releasing intrauterine system underwent hysteroscopic suture fixation of the device. The operative technique was documented in a step-by-step surgical video for oral presentation. Written patient consent for presentation and publication of the surgical material was obtained.

After trimming the device tail, a non-absorbable suture was tied around one arm of the device, followed by a second knot approximately 0.3 cm from the first knot. One end of a double-armed 4-0 non-absorbable suture was passed through the interval between the two knots and introduced into the uterine cavity. Under hysteroscopic guidance, the needle was grasped with a needle holder, passed through the posterior myometrium and exteriorised through the vagina. The device was then delivered into the uterine cavity. After a simplified extracorporeal knot was created outside the body, traction on a single suture end advanced the knot to the intrauterine fixation site.

Results

The procedure was completed successfully. Hysteroscopic reassessment confirmed appropriate device position and accurate knot placement at the fixation site. This technique enabled controlled knot advancement without a knot pusher, thereby reducing the need for repeated intrauterine manipulation and minimising the risk of incomplete knot delivery or knot loosening. The key technical requirement was to obtain a sufficiently deep and wide myometrial bite to prevent suture detachment during traction. During follow-up, ultrasound confirmed that the device remained correctly positioned. Dysmenorrhoea and menstrual bleeding improved markedly, and no procedure-related adverse events were observed.

Conclusions

This simplified extracorporeal knot-advancement technique may provide a feasible and reproducible approach for hysteroscopic suture fixation of a hormone-releasing intrauterine system in selected patients at high risk of recurrent expulsion. By simplifying intrauterine knot delivery, the technique may reduce procedural complexity, minimise intrauterine manipulation and potentially improve fixation reliability. Adequate myometrial suture depth and width are essential to ensure fixation stability and procedural safety.

ESGE35-0135 -
Free Communication

Ten-step standardized vNOTES fimbriectomy

Grégoire Boubée[1], Camille Jauffret[1], Navid Mokarram[1], Susanna Delfrati[1], Céline Miguet[1], Eric Lambaudie[1]
[1]Institut Paoli Calmettes, Department of Gynaecologic Surgical Oncology, Marseille, France

Background

Fimbriectomy has emerged as a potential strategy for reducing the risk of epithelial ovarian cancer while preserving ovarian function in high-risk premenopausal women. The transvaginal natural orifice transluminal endoscopic surgery (vNOTES) approach provides direct access to the adnexa without abdominal scarring. However, standardization of the technique remains limited.

Methods

To describe a standardized 10-step vNOTES fimbriectomy technique and highlight key surgical tips to improve reproducibility, safety, and adnexal preservation.
This educational surgical video demonstrates a stepwise vNOTES fimbriectomy procedure. The technique includes posterior colpotomy and access to the pouch of Douglas, placement of the transvaginal single-port device, abdominal cavity exploration, peritoneal cytology, cold-scissor division of the ovarian fimbrial attachment, proximal tubal coagulation and transection, sequential coagulation and division of the mesosalpinx, specimen extraction with histopathological assessment, controlled exsufflation with recruitment manoeuvre, and vaginal closure.

Results

The standardized approach allowed precise fimbrial dissection while preserving ovarian vascularization and minimizing thermal spread. Technical tips are emphasized to optimize exposure, tissue handling, and haemostasis throughout the procedure.

Conclusions

Standardized vNOTES fimbriectomy is a reproducible minimally invasive procedure that combines the advantages of transvaginal endoscopy with ovarian preservation. This stepwise educational video may facilitate dissemination of the technique and support surgical training in minimally invasive gynecologic oncology and prophylactic surgery.

https://player.vimeo.com/video/1190927941?autoplay=1

ESGE35-0671 -
Free Communication

Utility of large language models in multidisciplinary tumor board decision-making for patients with endometrial cancer receiving sentinel lymph node biopsy (TRSGO-AI-002 SLN-015)

Ibrahim Yalcin[1], Oğuz Arslan[1], Çağatayhan Öztürk Ali Gökçe[2], Rümeysa Belen Gümüş Alparslan Serarslan[3], Sefa Kurt Faruk Köse[4], Fırat Ortaç Salih Taşkın[5]
[1]Dokuz Eylül University School of Medicine,
Division of Gynaecologic Oncology- Department of Obstetrics and Gynaecology, Izmir, Türkiye
[2]Ankara University School of Medicine,
Division of Gynecologic Oncology- Department of Obstetrics and Gynecology, Ankara, Türkiye
[3]Dokuz Eylül University School of Medicine- Ondokuz Mayis University School of Medicine,
Division of Gynaecologic Oncology- Department of Obstetrics and Gynaecology- Department of Radiation Oncology, Izmir, Türkiye
[4]Dokuz Eylül University School of Medicine- Acıbadem Mehmet Ali Aydinlar University,
Division of Gynaecologic Oncology- Department of Obstetrics and Gynaecology, Izmir, Türkiye
[5]Ankara University School of Medicine,
Division of Gynaecologic Oncology- Department of Obstetrics and Gynaecology, Ankara, Türkiye

Background

To evaluate the accuracy, consistency, and clinical applicability of large language models (LLMs) in multidisciplinary tumor board decision-making for patients with endometrial cancer who underwent sentinel lymph node (SLN) biopsy.

Methods

This two-center retrospective study included 120 patients with endometrial cancer who underwent SLN biopsy. Comprehensive clinicopathological data, including histological subtype, tumor grade, myometrial invasion, lymphovascular space invasion, cervical stromal involvement, SLN status, molecular profile and stage, were entered into ChatGPT-4o and ChatGPT-5 using a standardized prompt format. MTB decisions based on the ESGO/ESTRO/ESP 2021 guidelines served as the reference standard. All cases were entered into the models by a single investigator (OA). ChatGPT-generated responses were independently evaluated by two gynecologic oncologists with expertise (IY, ST) in SLN biopsy and endometrial cancer management. Discordant evaluations were adjudicated by a third senior gynecologic oncologist (FO). All evaluators were blinded to each other's assessments throughout the study. Patient data were anonymized prior to analysis, and written informed consent was obtained from all participants. Responses were categorized as comprehensive, correct but inadequate, some correct/incorrect, or completely incorrect. Reproducibility was assessed by re-entering all cases into new chat sessions two weeks after the initial analysis. Interobserver agreement was evaluated using Cohen's kappa analysis. In analysing the performance of ChatGPT-4 and ChatGPT-5, the Pearson chi-square and Fisher exact tests were applied for comparisons of categorical variables. $P<0.05$ was considered statistically significant.

Results

ChatGPT-5 demonstrated higher overall accuracy than ChatGPT-4o, with comprehensive responses observed in 68.3% and 65.0% of cases, respectively. Correct but inadequate responses were identified in 18.3% of ChatGPT-5 and 16.7% of ChatGPT-4o outputs. The proportion of some correct/incorrect responses was lower with ChatGPT-5 than ChatGPT-4o (7.5% vs. 9.2%). Completely incorrect responses were observed in 9.2% of ChatGPT-4o outputs and 5.8% of ChatGPT-5 outputs. Overall reproducibility rates were 89.2% for ChatGPT-5 and 85.0% for ChatGPT-4o. Performance varied significantly across risk groups for both models ($p<0.001$). Comprehensive response rates were highest for the low-risk group (ChatGPT-4o: 86.4%; ChatGPT-5: 91.5%) and lowest for the high-intermediate-risk group (ChatGPT-4o: 10.5%; ChatGPT-5: 15.8%), with no significant difference between the models in any risk stratum. Interobserver agreement between the two primary evaluators was substantial for both models, with kappa values of 0.63 (95% CI, 0.524–0.735) for ChatGPT-5 and 0.618 (95% CI, 0.498–0.737) for ChatGPT-4o. Despite promising performance, both models showed limitations in complex adjuvant treatment scenarios and occasionally generated recommendations inconsistent with current guideline-based management.

Conclusions

LLMs demonstrated promising accuracy and reproducibility in MTB decision-making for patients with endometrial cancer undergoing SLN biopsy. ChatGPT-5 showed modestly improved performance compared with ChatGPT-4o. However, limitations in complex risk stratification and adjuvant treatment planning indicate that LLMs should currently be considered supportive tools rather than independent clinical decision-makers in gynecologic oncology practice.

ESGE35-0641 -
Free Communication

Integrating 3D extended reality models to improve preoperative planning in multivisceral gynecologic oncology surgery

Martina Testiccioli[1], Andrea Rosati[1], Davide Arrigo[1], Giacomo Avesani[2], Shai Tejman-Yarden[3], Anna Fagotti[1]
[1]Fondazione Policlinico A. Gemelli IRCCS - Università Cattolica del Sacro Cuore, Department of Woman- Child and Public Health, Rome, Italy
[2]Fondazione Policlinico Universitario A. Gemelli IRCCS - Università Cattolica del Sacro Cuore, Department of Diagnostic Imaging and Oncologic Radiotherapy- UOC Abdominal and Pelvic Radiology , Rome, Italy
[3]Faculty of Medicine- Tel Aviv University, The Engineering Medical Research Lab- Sheba Medical Center, Tel Aviv, Israel

Background

The surgical management of gynecological tumors often challenges surgeons because of the limited spatial perception provided by conventional 2D imaging, particularly in cases requiring complex multivisceral resections. Three-dimensional extended reality tools may improve preoperative anatomical understanding by providing patient-specific visualization of tumor extent and relationships with surrounding organs. This study aims to assess the accuracy of 3D VR/AR-based preoperative reconstructions and their impact on anatomical perception, surgical planning, and operative decision-making in complex gynecologic oncology procedures.

Methods

This single-center prospective pilot study enrolled patients undergoing primary or recurrent complex multivisceral surgery for gynecologic malignancies. Patient-specific 3D reconstructions of tumors and surrounding organs were generated and reviewed by surgeons using Virtual and Augmented Reality with D2P® software (Figure 1c, 1d). Model accuracy was assessed by comparing preoperative 3D-based predictions with intraoperative findings through standardized correlation and agreement analyses. The impact of 3D surgical planning on anatomical understanding, workflow integration, surgical strategy, and decision-making was evaluated using surgeon-reported custom-designed questionnaires.

Results

Twenty-eight patients were included: 23 with recurrent gynecologic cancers and 5 with advanced-stage ovarian cancer. Surgery was performed by laparotomy in 19 patients, laparoscopy in 6, laparoscopy converted to laparotomy in 2, and a vaginal/perineal approach in 1. Median operative time was 255 minutes, and median estimated blood loss was 100 mL. Two intraoperative complications occurred (7.1%). Complete cytoreduction was achieved in 24 cases (85.7%). Two patients experienced minor postoperative complications, classified as Clavien–Dindo grade ≤2. The 3D models showed substantial agreement with intraoperative assessment in predicting tumour resectability (Cohen's $\kappa=0.65$, $p<0.001$; accuracy 96.4%) and the need for surgical consultants ($\kappa=0.72$,

p<0.001; accuracy 88.9%). The estimated number of disease sites showed excellent correlation with surgical findings (ρ=0.962), although with mild systematic overestimation (p<0.009). Estimates of infiltration sites also correlated strongly with intraoperative findings (ρ=0.863), without significant differences from surgical assessment (p=0.609) (Figure 1a). The surgical planning questionnaire showed high reliability and overall positive surgeon feedback (mean score 3.9 ± 0.5; 79% positive responses). The 3D models were considered easy to integrate into routine workflow, with strong intention for continued use. Their perceived usefulness in enhancing anatomical understanding, surgical strategy, and intraoperative sequence planning was moderately high, suggesting added value in anatomically complex cases (Figure 1b).

Role, N (%)	
Resident	4 (14.3)
Fellow/Early career	3 (10.7)
Gyn Onc Surgeon	21 (75)
Years of surgical experience, N (%)	
<5	11 (39.3)
5-10	14 (50)
<10	3 (10.7)

Questionnaire Domain	Cronbach's α	Mean (±SD)	Median (IQR)	% positive (≥3.5)
Perceived Usefulness	0.93	3.6 (±.7)	3.5 (3-4.3)	53%
Perceived Ease of Use	0.52	4.4 (±.5)	4.3 (4-4.7)	96%
Professional Influence	0.75	4.0 (±-6)	4 (3.4-4.7)	75%
Future Intention and Satisfaction	0.84	3.9 (±.7)	4 (3.7-4.3)	85%
Total score	**0.93**	**3.9 (±.5)**	**3.9 (3.5-4.3)**	**79%**

Figure 1b: Clinicians Surgical Planning Questionnaire.

Conclusions

3D surgical planning using VR/AR reconstructions provides an accurate representation of disease extent and supports more informed operative strategies in complex gynecologic oncology procedures. Surgeons valued the models for improving anatomical clarity, confidence in preoperative planning, and surgical sequence definition. These findings support the incorporation of 3D visualization tools into routine preoperative evaluation, particularly when complex multivisceral resections are being considered.

ESGE35-0922 -
Free Communication

Laparoscopic para-aortic sentinel lymph node mapping using indocyanine green in presumed early-stage ovarian cancer: a video case report – TR MIGS

Necati Berk Kaplan[1], Ali Gökçe[1], Gizem Çetinkaya Şendur[1], Çağatayhan Öztürk[1], Salih Taşkın[1]
[1]Ankara University, Obstetrics and Gynecology, Ankara, Türkiye

Background
A systematic pelvic and para-aortic lymphadenectomy is the traditional surgical standard for staging early-stage epithelial ovarian cancer, though it is associated with significant post-operative morbidity. Sentinel lymph node (SLN) mapping has emerged as a promising, less invasive alternative to balance diagnostic accuracy with surgical safety. This video presentation aims to demonstrate the technical feasibility and surgical steps of laparoscopic SLN mapping using indocyanine green (ICG) with a specific focus on the para-aortic region in a patient with presumed early-stage ovarian cancer.

Methods

A 43-year-old female was evaluated after a routine follow-up ultrasonography revealed an adnexal mass. Her pre-operative CA-125 level was 98 U/mL. Pre-operative imaging demonstrated bilateral complex adnexal masses without evidence of bulky lymphadenopathy or extra-ovarian disease. The patient underwent comprehensive laparoscopic staging surgery, including total laparoscopic hysterectomy, bilateral salpingo-oophorectomy, pelvic peritonectomy, and total omentectomy. For retroperitoneal assessment, SLN mapping was performed by injecting 4 mL of ICG specifically into the serosa of the right infundibulopelvic ligament. Real-time near-infrared fluorescence imaging was used to identify and dissect the para-aortic sentinel lymph nodes. Subsequently, a systematic bilateral pelvic and total para-aortic lymphadenectomy up to the left renal vein was performed as the reference standard.

Results

Fluorescence imaging successfully identified the sentinel lymph nodes along the para-aortic pathway. Final histopathological examination confirmed bilateral ovarian malignancy. Notably, the targeted para-aortic sentinel lymph node was positive for metastasis. Out of the 13 systematically harvested para-aortic lymph nodes, a total of 5 nodes were found to be metastatic. Post-operatively, the patient's CA-125 level successfully decreased to 13 U/mL.

Conclusions

Laparoscopic para-aortic sentinel lymph node mapping using ICG appears to be a feasible and clinically promising technique for detecting occult retroperitoneal metastasis in presumed early-stage ovarian cancer. This video highlights the surgical anatomy, injection technique, and fluorescence-guided dissection of para-aortic sentinel lymph nodes.

https://player.vimeo.com/video/1195760252?autoplay=1

ESGE35-0615 -
Free Communication

Laparoscopic pelvic lymph node debulking for advanced cervical cancer: technical feasibility and perioperative safety

Evgeni Baev[1]
[1]*Municipal Hospital, Department of Obstetrics and Gynaecology, Sofia, Bulgaria*

Background

Locally advanced cervical cancer with lymphatic dissemination is primarily managed with concurrent chemoradiotherapy, since radiation remains the most crucial modality for achieving local tumour control. Immune checkpoint inhibition, such as pembrolizumab, has recently been used to boost the efficacy of this multimodal approach by strengthening systemic disease response. In rare circumstances, a multidisciplinary tumour board may recommend surgical intervention beyond standard protocols, with the aim of achieving significant tumour reduction in cases of extensive bilateral pelvic nodal metastases, where masses can reach up to 8 cm on both sides. This video illustrates a technically demanding laparoscopic pelvic nodal debulking procedure with emphasis on operative feasibility, key anatomical steps, and perioperative safety.

Methods

A 43-year-old patient diagnosed with FIGO IIIC2 squamous cell carcinoma of the cervix presented with massive bilateral pelvic nodal metastases in close proximity to the external and internal iliac vessels and the obturator nerve. Following multidisciplinary tumour board recommendation, laparoscopic nodal debulking was performed. A high-definition 3D laparoscopic system enabled enhanced depth perception to safely navigate the confined pelvic compartments. Dissection focused on skeletonising the iliac vessels, preserving the obturator nerve, protecting the ureter, and maintaining the integrity of the metastatic node capsule during en bloc removal.

Results

The total operative time was 57 minutes with an estimated blood loss of 50-75 ml. No intraoperative complications occurred and no conversion was required. Complete laparoscopic removal of both large metastases was achieved without capsule rupture. The postoperative course was uneventful, and the patient was discharged on day three.

Conclusions

Even in exceptionally complex anatomical situations with massive pelvic nodal disease, laparoscopic debulking is technically feasible when meticulous surgical preparation and advanced mastery of pelvic neurovascular anatomy are ensured. This high-risk procedure should be reserved for highly selected patients and performed only in specialised oncological centres.

https://player.vimeo.com/video/1191686907?autoplay=1

ESGE35-0529 -
Free Communication

laparoscopic nerve-sparing paraaortic lymph node dissection with three gauze tented technique

Ali Abacı[1], *Oğuzhan Kayım*[1], *Ghanim Khatib*[1]
[1]*Cukurova University Balcali Hospital, Gynaecologic Oncology, Adana, Türkiye*

Background

Accurate nodal assessment is crucial in gynecologic cancers. Paraaortic lymph node dissection (PALND) provides essential staging information and guides adjuvant treatment. Minimally invasive techniques offer improved visualization and may reduce morbidity. This video demonstrates a standardized laparoscopic PALND focusing on key anatomical landmarks.

Methods

A patient with cervical cancer underwent laparoscopic sentinel lymph node dissection followed by paraaortic lymphadenectomy and subsequent open radical hysterectomy. The laparoscopic approach included retroperitoneal access, identification of the ureter, and exposure of the inferior vena cava and abdominal aorta. Systematic lymph node dissection was performed from the aortic bifurcation up to the level of the renal vessels.

Results

Emphasis is placed on anatomical orientation, meticulous dissection, and strategies to prevent vascular and ureteral injury. In this case, the three-gauze tented technique facilitated better visualization of the surgical field and more effective removal of nearby tissues and organs in the surgical field. It can be used as a facilitating method in such risky field surgeries to provide a clearer field of vision and comfortable working conditions.

Conclusions

Laparoscopic PALND is a feasible and effective technique for surgical staging in cervical, endometrial and ovarian cancers. A standardized, anatomy-based approach enhances safety and reproducibility. This video provides practical guidance for gynecologic oncologists aiming to refine minimally invasive surgical skills.

https://player.vimeo.com/video/1191682277?autoplay=1

ESGE35-0444 -
Free Communication

Minimally invasive anterior pelvic exenteration for endometrial cancer recurrence using a RAS platform

Davide Arrigo[1], Emanuele Perrone[2], Sara Mastrovito[2], Riccardo Oliva[2], Andrea Rosati[2], Francesco Fanfani[1]
[1]Fondazione Policlinico Universitario A. Gemelli IRCCS - Università Cattolica del Sacro Cuore, Department of Woman- Child and Public Health, Rome, Italy
[2]Fondazione Policlinico Universitario Agostino Gemelli IRCCS, Department of Woman- Child and Public Health, Rome, Italy

Background

Pelvic exenteration may offer curative treatment for carefully selected patients with primary or persistent/recurrent gynecologic malignancies, but it remains associated with substantial morbidity, prolonged recovery, and psychological impact. Although traditionally performed by laparotomy, minimally invasive approaches may reduce blood loss, complications, and hospital stay. Robotic surgery may further support feasibility through magnified three-dimensional vision and wristed instruments, facilitating precise dissection in the deep pelvis. Evidence in gynecologic pelvic exenteration remains limited. We report our first experience with minimally invasive anterior pelvic exenteration using the HUGO™ RAS® platform as salvage treatment for centrally recurrent endometrial cancer.

Methods

A 68-year-old woman with endometrioid endometrial carcinoma developed a central pelvic recurrence arising from the vaginal cuff, with persistent disease after multiple radiotherapy treatments, including brachytherapy and stereotactic body radiation therapy. Preoperative assessment showed localized central recurrence without distant disease. After multidisciplinary tumor board discussion and comprehensive counselling regarding morbidity, urinary diversion, and functional implications, robotic-assisted minimally invasive anterior pelvic exenteration was planned.

Results

The procedure was completed successfully without major vascular or nerve injury, intraoperative tumor disruption, or dissemination. Despite prior major abdominal surgery, dense adhesions, and pelvic irradiation, the HUGO™ RAS® platform enabled safe development of retroperitoneal pelvic spaces and effective vascular control. Complete resection with clear margins was achieved. Operative time was 245 minutes, and estimated blood loss was 200 ml. The postoperative course was complicated by fever requiring intravenous antibiotics, classified as 30-day Clavien-Dindo grade 2. The patient was discharged on postoperative day 12. Final histopathological examination showed vaginal/paracolpial and urethral disease localization with free margins. The patient was scheduled for adjuvant chemo-immunotherapy.

Conclusions

Robotic-assisted anterior pelvic exenteration with the HUGO™ RAS® platform was technically feasible and oncologically effective in a complex, previously irradiated field. Further experience and longer follow-up are required to confirm reproducibility, safety, and oncologic outcomes.

https://player.vimeo.com/video/1191633514?autoplay=1

ESGE35-0393 -
Free Communication

Minimally invasive approach to an extraordinary cervical cancer case with gastrointestinal stromal tumor and low grade appendiceal neoplasia mimicking metastatic disease

Ghanim Khatib[1], Ali Mesut Mısırlıoğlu[1], Oguzhan Kayim[1], Mehmet Ali Vardar[1]
[1]Cukurova University Balcali Hospital, Gynaecologic Oncology, Adana, Türkiye

Background

After LACC trail minimally invasive approach has lost its applicability in the arena of cervical cancer surgical therapy. To decrease morbidity of open surgery hybrid concepts, laparoscopic approach to lymph nodes with radical hysterectomy by low transverse incision is reasonable and feasible. Here we present an unusual cervical cancer patient both in presentation and as a case.

Methods

A patient with diagnosis of cervical squamous cancer with right adnexial mass and left morphologically malignant appearing implant on small bowel wall on MRI was discussed on tumor board. To make picture clearer and as a part of hybrid approach to lessen morbidity exploratory laparoscopy (+/- sentinel lymph node dissection) was planned. An appendiceal mucocele and small bowel GIST tumor were observed in exploration and had explained atypical imaging findings and presentation. Laparoscopically appendectomy segmental small bowel resection, sentinel node mapping and pelvic paraaortic lymphadenectomy then by Pfannenstiel incision type C1 hysterectomy were performed.

Results

Specimen pathologies stage IB2 for cervical squamous cancer, gastrointestinal stromal tumor for small bowel mass and low-grade mucinous neoplasia were reported. Approach by laparoscopy first and performing parts of the procedures endoscopically then carrying out radical hysterectomy by Pfannenstiel incision have made possible to complete surgical therapy in minimally invasive approach and had advantage in respect of morbidity.

Conclusions

Even though, minimal invasive surgery was significantly abandoned after the LACC trial, performing sentinel node biopsy, lymphadenectomies and various procedures endoscopically, and sequentially, carrying out the radical hysterectomy by Pfannenstiel incision, can be adopted as advantageous approach for cervical cancer patients.

https://player.vimeo.com/video/1191585366?autoplay=1

ESGE35-0083 -
Free Communication

Laparoscopic vNOTES Approach to Pelvic Sentinel Lymph Node

Giulio Ricotta[1], Charlotte Chollet[1], Giorgio Fiorenza[1], Enora Laas[2], Thomas Gaillard[2]
[1]Oncopole Claudius Regaud - IUCT, Surgery, Toulouse, France
[2]Institut Curie, Surgery, Paris, France

Background

Minimally invasive hysterectomy with bilateral adnexectomy and sentinel lymph node (SLN) biopsy is the current standard of care for patients with endometrial carcinoma.

Vaginal natural orifice transluminal endoscopic surgery (vNOTES) has demonstrated several advantages in benign gynecologic surgery, such as reduced postoperative pain and faster postoperative recovery. In obese patients, the vaginal approach may further facilitate surgical access and anaesthetic management by avoiding abdominal pressure and Trendelenburg positioning.

In gynecologic oncology, experience with vNOTES remains limited, particularly for retroperitoneal SLN dissection. A retroperitoneal vNOTES approach may provide additional theoretical benefits, including direct access to the paravesical space, absence of abdominal scars, and improved visualization of lymphatic drainage pathways through a caudal-to-cranial dissection.

Methods

We present a video demonstrating the main steps of retroperitoneal vNOTES dissection with sentinel lymph node biopsy for endometrial cancer.

The video aims to illustrate this approach and provide technical tips to facilitate standardization of this novel technique

Results

We present a case of a woman with an early-stage, low-grade endometrioid endometrial cancer.
Bilateral pelvic sentinel lymph-node biopsy and hysterectomy with bilateral adnexectomy were performed using a laparoscopic vNOTES approach.
Only bilateral pelvic sentinel lymph node biopsy is shown.
No intraoperative or postoperative complications occurred.
The patient was discharged on the same day of surgery.
Final pathological examination confirmed early-stage endometrial cancer with a low-risk ESGO 2025 classification.

Conclusions

The laparoscopic vNOTES approach is a feasible option for sentinel lymph node biopsy in endometrial cancer.

It offers several advantages, including no need for Trendelenburg positioning (which may be beneficial in obese patients), absence of abdominal scars, and direct access to the paravesical space with optimal visualization of anatomical landmarks and lymphatic drainage pathways.

However, its oncological safety requires further evaluation in prospective trials, and it should be performed in referral centres, in patient with low-risk disease and preferably in the context of clinical trials.

https://player.vimeo.com/video/1189695818?autoplay=1

ESGE35-0015 -
Free Communication

Gender disparities in management of gonadal torsion: a retrospective cohort study

Aya Abusheikha[1,2], Joycee Adebimpe[2,3], Dhillon Semreeta[2], Leezza Davidson[4], Obada Abusheikha[5], Rahul Gore[2]
[1]Frimley Health Foundation Trust, Obstetrics and Gynaecology, Frimley, United Kingdom
[2]Maidstone Tunbridge Wells NHS Trust, Obstetrics and Gynaecology, Tunbridge Wells, United Kingdom
[3]Medway NHS Foundation Trust, Obstetrics and Gynaecology, Medway, United Kingdom
[4]Kent and Medway Medical School, Medical School, Tunbridge Wells, United Kingdom
[5]University of Jordan, School of Medicine, Amman, Jordan

Background

Gonadal torsion is a time-critical surgical emergency in which delays beyond 6–8 hours markedly reduce organ salvage. Guidance advocates ovarian torsion as a diagnosis of inclusion, prioritising early endoscopic intervention over radiological certainty. Despite this, disparities in emergency care disadvantage women. This study examined gender-based differences in timeliness of management and surgical outcomes in suspected gonadal torsion.

Methods

A retrospective cohort study was conducted of adults undergoing emergency surgery for suspected ovarian or testicular torsion at Maidstone Tunbridge Wells NHS Trust between January 2022 and March 2025.

Results

110 patients were included (52 women, 58 men). Women experienced significantly longer delays at every stage. Median time from specialist review to knife-to-skin (KTS) was 41.5 hours (interquartile range (IQR) 22.1–68) in females compared with 1.5 hours (IQR 1.2–22.4) in males (p<0.0001). In women, median decision-to-incision time was 6.6 hours (IQR 3.6–22.1) versus 1.3 hours (IQR 1.0–2.1) in men (p<0.0001). Only 11.1% of women underwent surgery within six hours of review, compared with 95.8% of men. Torsion was confirmed in 52.1% of women and 33.3% of men. Necrotic gonads were identified in 29.2% of women and 5.3% of men (p=0.0012). Oophorectomy was performed in 46.2% of female patients, including 21.2% of women of reproductive age.

Table 1: Number of hours between significant clinical encounters in men and women with suspected gonadal torsion *45 female and 48 male patients had documented times ** 48 female and 57 male patients had a documented diagnosis *** 33 women who had surgery for suspected torsion were of reproductive age (<=43 years)

	Females (n = 52)	**Males (n = 58)**	**p- Value**
Time interval (hours) (median (IQR))			

	Females (n = 52)	**Males (n = 58)**	**p- Value**
Gynaecological/surgical review and decision for theatre	18.4 (6.2 – 38.1)	0.07 (0–0.35)	p < 0.0001
Decision for theatre and KTS	6.6 (3.6 – 22.1)	1.3 (1 – 2.1)	p < 0.0001
Gynaecological/surgical review and KTS	41.5 (22.1 – 68)	1.5 (1.2 – 22.4)	p < 0.0001
Proportion of patients (n (%))			
KTS <=6 hours from specialty review	5 (11.1) *	46 (95.8) *	p < 0.00001
KTS >48 hours from specialty review	18 (40) *	1 (2.1) *	p < 0.00001
Torsion diagnosis confirmed	25 (52.1) **	19 (33.3) **	p = 0.0524
Necrotic gonad	14 (29.2) **	3 (5.3) **	p = 0.00120
Gonadectomy performed	24 (46.2)	3 (5.2)	p < 0.00001
Necrotic gonad + gonadectomy in patients of reproductive age	7 (21.2) ***	3 (5.2)	p=0.0349

Conclusions

Women with suspected gonadal torsion experience profound delays resulting in disproportionate ovarian loss. In the absence of clear national guidance for ovarian torsion in England, emergency gynaecological care remains vulnerable to diagnostic uncertainty and pathway inefficiency. Standardised pathways are required to deliver equitable, time-critical care.

ESGE35-0076 -
Free Communication

Exploring predictive factors for spontaneous expulsion of retained products of conception.

Elke Pieters[1], Liselot Wagenaar[2], Steven Weyers[1,3], Jan Willem van der Steeg[4], Tjalina Hamerlynck[1,3], Hubertus A. van Vliet[1,2]
[1]Ghent University, Department of Human Structure and Repair, Ghent, Belgium
[2]Catharina Hospital, Department of Obstetrics and Gynecology, Eindhoven, The Netherlands
[3]Ghent University Hospital, Department of Gynaecology, Ghent, Belgium
[4]Jeroen Bosch Hospital, Department of Obstetrics and Gynaecology-, 's-Hertogenbosch, The Netherlands

Background

Retained products of conception (RPOC) are persistent placental tissues within the uterus after pregnancy. Management options include expectant, medical, or surgical approaches. Surgical treatment carries risks such as hemorrhage, infection, uterine perforation, and adhesion formation. Predictors of spontaneous expulsion (SE) during expectant management remain unclear. This study aimed to identify factors predicting successful expectant management to improve patient selection and individualised care.

Methods

This multicentre study combined data from a randomised trial and a cohort study (2015–2022) in three Dutch hospitals and the Ghent University Hospital. Women with ultrasonographically confirmed RPOC (1–4 cm) were included. Demographic, clinical, and ultrasound variables were prospectively collected. Variables with $p < 0.31$ in univariate analyses were entered into multivariable logistic regression models. Results were reported as odds ratios with 95% confidence intervals.

Results

Of 351 women with RPOC, 38 (10.83%) experienced SE. Multivariable analysis showed that a larger RPOC diameter was associated with a reduced likelihood of SE (OR 0.94; 95% CI 0.89-0.99; p = .02), whereas a history of miscarriage in previous pregnancies was associated with an increased likelihood of SE (OR 2.61; 95% CI 1.12–6.09; p = .03). In first-trimester cases, absence of embryonic cardiac activity increased the likelihood of SE of RPOC (OR 3.86; 95% CI 1.09–13.68; p = .04). No significant predictors were found in third-trimester cases.

Conclusions

RPOC size, prior miscarriage, and RPOC after first trimester losses with absence of embryonic cardiac activity play a role in SE of RPOC. These factors may guide patient counselling and individualised management. Larger studies in well-defined patient subgroups taking into account RPOC characteristics, obstetric history, type of pregnancy and pregnancy duration are needed to confirm and refine these predictive markers.

ESGE35-0113 -
Free Communication

Effect of hyaluronic acid anti-adhesion gel on intrauterine adhesion prevalence after second-trimester miscarriage curettage: a prospective randomized trial

Jiri Hanacek[1], *Michal Emingr*[2], *Jan Drahonovsky*[3], *Michal Mara*[4]
[1]*Institute of Care about Mother and Childe- 3- rd Medical Faculty- Charles University- Prague, Gynecology and Obstetrics, Prague, Czech Republic*
[2]*General Teaching Hospital-1-st Medical faculty- Charles University, Gynecology and Obstetric, Prague, Czech Republic*
[3]*Institute of Care about Mother and Childe- 3-rd Medical Faculty, Gynecology and Obstetric, Prague, Czech Republic*
[4]*General Teaching Hospital- 1-st Medical Faculty, Gynecology and Obstetric, Prague, Czech Republic*

Background

To evaluate whether intrauterine application of hyaluronic acid (HA) gel reduces de novo intrauterine adhesion formation after second-trimester uterine evacuation and to assess its impact on reproductive outcomes.

Methods

Two tertiary referral centres Patient(s)Women undergoing dilatation and curettage for second-trimester pregnancy loss. Intervention(s) Intrauterine application of hyaluronic acid gel following uterine evacuation. Main Outcome Measure(s)Primary outcome was de novo intrauterine adhesion formation at follow-up hysteroscopy, defined as an American Fertility Society (AFS) score >0. Secondary outcomes included adhesions detected by any diagnostic method, adhesion severity, diagnostic agreement between hysteroscopy and sonohysterography, and reproductive outcomes.

Results

A total of 124 women were randomized. Hysteroscopic evaluation was available in 78patients and constituted the primary analysis population. De novo intrauterine adhesions (AFS >0) were identified in 45.9% of women in the control group and 9.8% in the HA gel group (odds ratio [OR] 0.143, 95% confidence interval [CI] 0.042–0.494; p =0.002), corresponding to an absolute risk reduction of 36.1% and a number needed to treat of 3. Analyses including all diagnostic methods showed consistent results (29.3%vs. 6.4%; relative risk 0.22, 95% CI 0.07–0.72; p = 0.009). Agreement between hysteroscopy and sonohysterography was good (κ ≈ 0.75), although hysteroscopy remained the reference standard. Pregnancy was achieved in 68.4% of women. HA gel was not associated with a significant increase in pregnancy rates but was associated with a reduced risk of miscarriage (OR 0.216, 95% CI 0.049–0.955; p = 0.043).

Conclusions

Intrauterine application of hyaluronic acid gel significantly reduces de novo intrauterine adhesion formation after second-trimester uterine evacuation, a high-risk clinical setting. These findings support the use of anti-adhesion strategies in such patients. Potential benefits in reproductive outcomes require confirmation in adequately powered studies.

ESGE35-0161 -
Free Communication

Laparoscopic resection of large caesarean scar pregnancy

Özlem Yüksel Aybek[1], Tuğba Demirtaş[1], Gamze Taşkıran Özkebapçı[1], Merve Yastı Dayan[1], Özgür Aslan[1], Hakan Güraslan[1]
[1]Bagcilar Training and Research Hospital, Department of Obstetrics and Gynecology, Istanbul, Türkiye

Background

Caesarean scar pregnancy (CSP) is a rare form of ectopic pregnancy associated with significant maternal morbidity, including severe hemorrhage, placenta accreta spectrum disorders, and uterine rupture. Large and highly vascularized CSPs with thin residual myometrium present a particular surgical challenge and may be unsuitable for conservative treatment. We aimed to present laparoscopic resection as a surgical treatment option for large CSP.

Methods

A 33-year-old patient with a history of caesarean delivery was diagnosed with CSP. Transvaginal ultrasonography demonstrated a 5.8 × 5.2 cm highly vascularized gestational mass located in the anterior lower uterine segment at the site of the previous caesarean scar. Residual myometrial thickness was less than 3 mm, suggesting placenta accreta spectrum-like features. The serum β-human chorionic gonadotropin level was 7316 mIU/mL. Laparoscopic resection was performed. After filling the bladder with 300 mL isotonic fluid to delineate anatomical boundaries, the vesicouterine peritoneum was dissected. The gestational tissue and affected myometrial area were excised en bloc, followed by three-layer uterine reconstruction using absorbable sutures.

Results

The procedure was completed laparoscopically without intraoperative complications. Estimated blood loss was less than 100 mL, and no additional haemostatic procedures were required. The postoperative course was uneventful, and the patient was discharged in stable condition.

Conclusions

Management of CSP remains controversial, with options including medical therapy, aspiration techniques, and surgery. However, large CSPs with marked vascularity and thin residual myometrium carry an increased risk of hemorrhage and incomplete treatment with conservative approaches. Laparoscopic resection enables complete removal of trophoblastic tissue and affected myometrium while allowing simultaneous uterine reconstruction. This minimally invasive approach may reduce bleeding risk and preserve uterine integrity in selected patients with large CSP.

https://player.vimeo.com/video/1191105916?autoplay=1

ESGE35-0171 -
Free Communication

Reproductive outcomes after septoplasty in patients with combined infertility and recurrent pregnancy loss.

Michael Fakih[1], *Omar Abuzeid*[2], *Salem Joseph*[1], *Panagiotis Cherouveim*[3], *Erdal Budak*[1], *Mostafa Abuzeid*[1]
[1]*Fakih IVF Fertility Center, Reproductive Medicine and Infertility, Abu Dhabi, United Arab Emirates*
[2]*Franciscan Physician Network, Maternal Foetal Medicine, Indiana, USA*
[3]*Hurley Medical Center/Michigan State University, Obstetrics and Gynecology, Michigan, USA*

Background

Hysteroscopic septoplasty for partial septate uterus (PSU) in patients with recurrent pregnancy loss (RPL) may improve reproductive outcomes. However, the impact of septum resection in patients with combined RPL and infertility is not well evaluated. The aim of this study was to compare the reproductive outcomes after hysteroscopic septoplasty in infertile patients presenting with RPL to infertile patients with unexplained RPL and no Müllerin anomalies on hysteroscopy.

Methods

This is a single-center retrospective cohort study of 355 infertile patients with RPL that were evaluated and treated (1990-2023). Routine infertility and RPL work up were performed. RPL was defined as woman suffering from two or more consecutive pregnancy losses. Patients with RPL who had complete uterine septum, anti-phospholipid antibody syndrome or abnormal karyotype testing were excluded from this study. All patients underwent diagnostic, and if indicated, operative hysteroscopy during the same session. Patients were divided into two groups; Group 1 (285) included patients who underwent septoplasty for PSU and Group 2 (70) included patients with unexplained RPL and absent Müllerin uterine anomaly. Subsequent infertility treatment depended on the underlying etiology, and it included natural attempts, oral fertility medications, intrauterine insemination (IUI), in-vitro fertilization and embryo transfer (IVF-ET) as well as adjunctive procedures such as laparoscopy when indicated. The follow up period was two years. Background details and reproductive outcomes in the two groups were analysed. Student's t-test and Chi-squared test were used as appropriate, and generalized estimating equations regression analysis was used to adjust for potential confounders.

Results

Mean age and percentage of patients with prior deliveries were significantly lower in Group 1 compared to Group 2; 32.3 ± 4.0 vs. 33.6 ± 3.6 year; p=0.013 and 29.8% vs.42.9, p= 0.037 respectively. The percentage of patients with history of ovulatory disorders and hysteroscopic polypectomy were significantly higher in Group 1 compared to Group 2; 35.0% vs. 15.9%; p=0.004 and 67.2% vs.49.2%; p=0.012 respectively. There were no significant differences in other background details. There were no significant differences in clinical pregnancy (63.5% vs. 57.1%; p=0.325), live birth (53.7% vs. 44.3%, p=0.159) and miscarriage (13.9% vs. 22.5%, p=0.173) rates between Group 1 and group 2 respectively. In addition, there were no significant differences in

gestational age at delivery, pre-term delivery or twin pregnancy rates or method of conception between the two groups. When data was adjusted for confounding factors - Adjusted Odds Ratio (95%CI), the results did not change.

Conclusions

Reproductive outcomes after hysteroscopic septoplasty for PSU in infertile women with history of recurrent miscarriage are similar to those in infertile women with unexplained RPL and no Müllerian anomalies. Septoplasty, in experienced hands, is considered a safe and effective procedure that might improve reproductive outcomes in such patients.

ESGE35-0308 -
Free Communication

Reproductive outcomes in patients with arcuate uterus according to the most recent ASRM classification of uterine anomalies

Salem Joseph[1], Erdal Budak[1], Panagiotis Cherouveim[2], Omar Abuzeid[3], Michael Fakih[1], Mostafa Abuzeid[1]
[1]Fakih IVF Fertility Center, Reproductive Medicine and Infertility, Abu Dhabi, United Arab Emirates
[2]Hurley Medical Center/Michigan State University, Department of Obstetrics and Gynecology, Flint, USA
[3]Franciscan Physician Network, Division of Maternal Foetal Medicine, Crown Point, USA

Background

The 2021 ASRM classification of uterine anomalies defines an arcuate uterus as a fundal indentation <10 mm with an indentation angle >90° and considers it a normal variant. In contrast, the ESHRE/ESGE classification eliminated the term altogether. Literature prior to 2021 suggested no adverse effect of an arcuate uterus on reproductive outcomes; however, the definition was inconsistent. This study aimed to evaluate the impact of an arcuate uterus, as defined by the 2021 ASRM criteria, on reproductive outcomes in women undergoing fertility treatment.

Methods

This single-center retrospective cohort study included women who underwent diagnostic evaluation, including hysteroscopy, as part of their infertility work-up. Some patients also underwent concurrent diagnostic and/or operative laparoscopy. A total of 1,267 infertile women evaluated between 1990 and 2023 were included. The study group (Group 1) included 209 women who, on hysteroscopy, met the criteria of arcuate uterus according to the ASRM classification of uterine anomalies (2021), and were reclassified as such. The control group (Group 2) included 1,058 women with no uterine anomalies on hysteroscopy during the same period. The follow-up period was 2 years. Background details and reproductive outcome parameters for each group were compared. Student's t-test and Chi-square test were used as appropriate, and generalized estimating equations regression analysis was used to adjust for potential confounders.

Results

Mean infertility duration was significantly shorter in Group 1 vs. Group 2 (3.1±2.6 vs. 3.5±2.8 years, p=0.01), while the incidence of primary infertility (64.1% vs. 53.0%, p=0.003), prior delivery (21.4% vs. 11.5%, p<0.001), and prior miscarriage (14.6% vs. 8.0%, p=0.005) were significantly higher in Group 1. No other baseline characteristics differed significantly between the groups. Mean fundal indentation length was 7.0±1.7 mm in Group 1. Clinical pregnancy (58.4% vs. 30.6%, p<0.001), live birth (52.2% vs. 27.4%, p<0.001), and IVF pregnancy (79.6% vs. 61.1%, p=0.008) rates were significantly higher in Group 1. There were no significant differences in miscarriage rates (10.7% vs. 9.0%, p=0.589), preterm delivery rates (16.5% vs. 18.3%, p=0.671), or gestational age at delivery (37.1±4.0 vs. 37.4±2.9 weeks, p=0.94) between Group 1 and Group 2. After adjusting for confounding variables, clinical pregnancy (adjusted odds ratio 2.31, 95% CI 1.63–3.28, p<0.001) and live birth

(adjusted odds ratio 2.05, 95% CI 1.45–2.91, p<0.001) rates were the only outcomes that remained significantly higher in Group 1.

Conclusions

The presence of an arcuate uterus, as defined by the 2021 ASRM criteria, does not appear to impair fertility or otherwise adversely affect reproductive outcomes. Therefore, surgical correction of this condition is not indicated. To our knowledge, this is the first study to evaluate reproductive outcomes in patients diagnosed with an arcuate uterus on hysteroscopy based on the updated 2021 ASRM criteria.

ESGE35-0340 -
Free Communication

External validation of the Vizzielli score for advanced ovarian cancer patients undergoing primary debulking surgery, redefined for Clavien-Dindo classification.

Dimitrios Zouzoulas[1], Paraskevas Anagnostopoulos[1], Ioanna Vagioni[1], Vasilios Theodoulidis[1], Grigorios Grimbizis[1], Dimitrios Tsolakidis[1]
[1]General Papageorgiou Hospital, 1st Department of Obstetrics and Gynecology of Aristotle University, Thessaloniki, Greece

Background

Despite advances in surgical techniques and perioperative care, primary debulking surgery (PDS) for advanced ovarian cancer (AOC) is associated with substantial morbidity, which may delay initiation of adjuvant chemotherapy and negatively affect long-term outcomes. Identifying patients at high risk for severe postoperative complications is therefore crucial to guide treatment selection between upfront surgery and neoadjuvant chemotherapy. The aim of the study is to externally validate the Vizzielli score as a predictor of postoperative complications calculated by Clavien-Dindo classification.

Methods

We retrospectively analysed the records of patients with advanced ovarian cancer that underwent "Fagotti" diagnostic laparoscopy followed by PDS in the 1st Department of Obstetrics – Gynecology Clinic from 2017 – 2025. The Vizzielli score was reconstructed for each patient from prospectively collected preoperative and intraoperative data, according to the original description (composite of performance status, ascites, CA-125, and Fagotti score). Postoperative complications were graded according to the Clavien–Dindo classification and summarized as a continuous complication score (0–100), capturing the overall morbidity burden within 30 days after surgery.

Results

A total of 32 patients with advanced ovarian cancer underwent Fagotti diagnostic laparoscopy, followed by PDS. The population of the cohort had a mean age of 59 years old and a mean BMI of 27,6 kg/m^2. The majority of the patients had high-grade serous tumors and FIGO stage IIIC disease. Almost half of the patient underwent high surgical complexity surgery, with a median peritoneal cancer index (PCI) of 16. Moreover, the mean surgical duration and intraoperative blood-loss were 370 min and 630 cc, respectively, with a median hospital stay of 9 days. The Vizzielli score showed a strong positive association with the continuous complication score. In univariable linear regression, each one-point increase in the Vizzielli score was associated with an average 7.7-point increase in the continuous Clavien-Dindo complication score ($\beta = 7.66$; 95% CI 4.37–10.95; $p < 0.001$). The model explained 43% of the variability in postoperative morbidity ($R^2 = 0.43$), indicating moderate-to-good predictive ability. Higher Vizzielli scores were consistently observed in patients experiencing a greater overall burden of complications, including those requiring invasive interventions or intensive care admission.

Conclusions

In this single-center external validation cohort of patients with AOC undergoing PDS, the Vizzielli score demonstrated a clinically relevant, statistically significant association with the overall severity of postoperative complications quantified as a continuous variable based on the Clavien-Dindo classification. These findings suggest that the Vizzielli score may help identify patients at increased risk of all postoperative morbidity, not only major > grade III events, when treated with upfront cytoreductive surgery. However, larger, prospective studies are needed to confirm the above-mentioned results.

ESGE35-0630 -
Free Communication

Safe hysteroscopic restoration of septate uterus under 3D-sonographic versus laparoscopic guidance: a randomized controlled study

Eirini Angelidou[1]
[1]*General Clinic Rhodes Greece Euromedica, Gynaecological Department, Rhodes, Greece*

Background

Septate uterus is the most common congenital uterine anomaly and is associated with poor fertility and obstetrics outcomes. In patients with primary infertility or miscarriages the most effective treatment of this anomaly is the hysteroscopic metroplasty with the complete removal of the septum and restoration of a normal uterine cavity.

After hysteroscopic metroplasty, residual septal remnants or uterus peroration during the procedure could result in subsequent adhesions, reproductive failures and repeated surgeries.

The aim of this study is to evaluate intraoperatively, during the hysteroscopy of the uterine cavity, the morphology of the septate uteri by 3D transvaginal sonography (TVS) versus simultaneous diagnostic laparoscopy for the exact localization of the intracavitary instruments and estimation of the uterine wall thickness to achieve complete resection of the uterine septum and avoid perforation, adhesions and septal remnants, which could negatively influence the fertility of these patients.

Second end points of this trial are the pregnancy rates, the life birth rates and the pregnancy loss rates.

Methods

60 infertile patients, with a mean age of 35 years, diagnosed by 3D TVS with a septate uterus (U2 ESHRE-ESGE classification) were planned to undergo hysteroscopic metroplasty with a bipolar resectoscope and the goal of a complete and safe septum resection, without intraoperative complications. These patients were randomized prospectively in two groups: the first hysteroscopy under 3D TVS (30 patients) versus the second hysteroscopy under laparoscopic guidance (30 patients). The two groups were well matched according to their demographic, hormonal and fertility data.

Results

In the two groups the uterine septum was completely resected in (29/30) 96% and (28/30) 93% of the cases respectively (non-statistically significant difference). In the two groups there was no complication during the procedures. After 2 years of follow up 18/30 patients (60 %) of the first group and 24/30 (80%) of the second group became spontaneously pregnant with 15/18 (83%) and 21/24 (87%) of life birth rates and 3/18(16,6%) and 3/24(16,6%) pregnancy loss rates respectively. The higher pregnancy rate in the second group (laparoscopy) could be attributed to simultaneous laparoscopic correction of other infertility factors found at the time of the operation.

Conclusions

This randomised prospective study shows that 3D TVS is a useful non-invasive tool to diagnose and guide a complete and safe uterine septum resection and metroplasty. It also highlights the value of simultaneous laparoscopy to ensure the safe application of operative hysteroscopy to restore complex genital malformations and improve the fertility outcomes in challenging cases.

ESGE35-0678 -
Free Communication

The impact of deep endometriosis stratified by the #ENZIAN classification system on cumulative live birth rates following IVF; A retrospective cohort study of 346 patients.

Christina Neophytou[1], *Anoushka Bose*[2], *Ephia Yasmin*[3], *Ertan Saridogan*[4]
[1]*University College London Hospital, Endometriosis & Minimal Access Surgery, London, United Kingdom*
[2]*University College London, Medicine, London, United Kingdom*
[3]*University College London Hospital, Reproductive Medicine, London, United Kingdom*
[4]*University College London Hospital, Reproductive Medicine- Endometriosis & Minimal Access Surgery, London, United Kingdom*

Background

Patients with deep endometriosis and concurrent subfertility often require in vitro fertilisation (IVF), with a perceived need for multiple treatment cycles and frozen–thawed embryo transfers. This study aimed to evaluate the cumulative live birth rate (CLBR) in patients with deep endometriosis undergoing IVF and assess whether anatomical distribution of disease, classified using the #ENZIAN system, influences reproductive outcomes. Secondary aims included evaluating the impact of endometrioma size and prior surgical intervention on the CLBR.

Methods

A retrospective cohort study was conducted on patients with confirmed deep endometriosis, treated with IVF at a tertiary university hospital between 2014 and 2024. Patients were identified via institutional records and ultrasound databases. The primary outcome was CLBR, defined as the proportion of patients achieving at least one live birth, whether from the first transfer attempt or subsequent transfers of frozen–thawed supernumerary embryos. Patients were stratified by anatomical disease distribution defined by the #ENZIAN system, endometrioma size, and prior surgical history. CLBRs were calculated for each subgroup.

Results

The cohort included 346 patients. A total of 841 embryos were transferred over 615 embryo transfer episodes (389 single and 226 double embryo transfers). This resulted in 229 live birth episodes and 260 live births. The live birth rate per embryo transfer was 31% and the CLBR was 58% after consecutive embryo transfers.

The CLBR according to anatomical location was as follows: P - peritoneal disease = 58% (n=104); O (left or right) - unilateral endometrioma = 56% (n=138); O (left and right) - bilateral endometriomas = 63% (n=71); O1 - endometriomas of <3cm = 56% (n=89); O2 - endometriomas between 3-7cm = 64% (n=86); O3 - endometriomas of >7cm = 44% (n=27); A - rectovaginal/retro-cervical lesions = 54% (n=109); B - uterosacral ligament/cardinal ligament/pelvic side wall lesions = 53% (n=79); C - rectosigmoid lesions = 52% (n=62); F_A - adenomyosis = 58% (n=84); and obliteration of Pouch of Douglas = 58% (n=114).

The CLBR of patients with deep endometriosis according to previous surgical history was as follows: No previous surgical history = 55% (n=137); Previous surgery = 60% (n=209); Previous excisional surgery = 66% (n=50). Among patients with bilateral endometriomas, the CLBR was 59% (n=32) in those with no previous surgical history compared with 67% (n=39) in those with a history of prior surgery.

Conclusions

Despite the nature of the disease, patients with deep endometriosis can achieve favourable outcomes following IVF, with broadly comparable CLBRs across most #ENZIAN anatomical subtypes. In the context of the ongoing debate regarding surgical management prior to IVF, previous surgery does not appear to adversely affect outcomes, particularly in patients with bilateral endometriomas. Patients with large endometriomas >7cm should be counselled regarding the possibility of reduced success rates.

ESGE35-0295 -
Free Communication

Laparoscopic abdominal cerclage after failed transvaginal cerclage

Selçuk Yetkinel[1], Pınar Çağlar Aytaç[1], Tayfun Çok[1], Didem Alkaş Yağınç[1], Gülşen Doğan Durdağ[1], Erhan Şimşek[1]
[1]Başkent University Adana Dr. Turgut Noyan Research and Application Center, Division of Reproductive Endocrinology and IVF Unit- Department of Obstetrics and Gynecology- TR-MIGS, Adana, Türkiye

Background

Cervical insufficiency is an important cause of recurrent mid-trimester pregnancy loss and extreme preterm birth. In selected high-risk patients, transvaginal cerclage may fail to provide adequate cervical support. This study aimed to present the laparoscopic abdominal cerclage technique and evaluate the obstetric outcomes of our single-centre experience in women with severe cervical insufficiency.

Methods

This retrospective cohort study included women who underwent laparoscopic abdominal cerclage between January 2018 and December 2025 at a tertiary referral centre for high-risk obstetrics and minimally invasive surgery. Clinical and obstetric data were retrospectively analysed from a prospectively maintained institutional database. Ethical approval was obtained from the institutional ethics committee (KA26/143). The video demonstrates the standardised laparoscopic abdominal cerclage technique in a patient with severe cervical insufficiency after failed transvaginal cerclage.

Results

A total of 69 women underwent laparoscopic abdominal cerclage during the study period. Fifty women (72.5%) achieved at least one pregnancy following cerclage, resulting in 64 post-cerclage pregnancies. The live birth rate was 95.3%. Mean gestational age at delivery was 36.9 weeks, while delivery before 34 weeks occurred in 6.8% of pregnancies. Mean neonatal birthweight was 3016 g, and no very low birthweight infant (<1500 g) was observed. Additional vaginal cerclage was required in 7.8% of pregnancies.

Conclusions

Laparoscopic abdominal cerclage is a reproducible minimally invasive technique associated with favourable obstetric outcomes in carefully selected patients with severe cervical insufficiency after failed transvaginal cerclage.

https://player.vimeo.com/video/1191346103?autoplay=1

ESGE35-0300 -
Free Communication

Laparoscopic emergency cervicoisthmic cerclage during the second trimester of pregnancy: outcomes of a case series

Andreas Kavallaris[1,2], Dimitrios Grigoriou[2], Antonis Gkoutzioulis[1], Panagiotis Papandreou[1], Stergios Kopatsaris[3], Dimitrios Zygouris[1]
[1]St. Luke's Hospital- Thessaloniki- Greece,
Department of Gynecologic Oncology and Minimally invasive surgery, Thessaloniki, Greece
[2]Mother and child medical center- Nicosia- Cyprus,
Department of Gynecologic Oncology and Minimally invasive surgery, Nicosia, Cyprus
[3]Marienhospital Bottrop- Bottrop- Germany, Department of Gynecology and Obstetrics, Bottrop, Germany

Background

The aim of this study was to evaluate the feasibility and safety of Laparoscopic emergency cervicoisthmic cerclage in second trimester of pregnancy.

Methods

Between March 2015 and November 205 25 patients underwent Laparoscopic emergency cervicoisthmic cerclage. All women had showed cervical insufficiency with dilation in the second trimester. In 7 patients transvaginal cerclage failed due to a short vaginal cervix. Patients' characteristics were obtained from hospital's medical record and we evaluated surgical data, intra, postoperative complications, and perinatal outcome. All operations were performed by the same surgeon.

Results

The average operation time was 79 min (ranging from 72 to 97 minutes), the average estimated blood loss during the procedure was less than 100 mL and there were no perioperative or postoperative complications. The mean gestational age at surgery was 14.3 (ranging from 14.2 to 16) weeks. All women underwent an elective CS after 38 weeks of gestation. The overall pregnancy survival rate was 100 %, the mean gestational age at delivery was 38.1 weeks (ranging from 38.0 to 38.5 weeks) and the mean birth weight was 3190 g (g) (ranging from 2980 g to 3350 g).

Conclusions

Laparoscopic cervicoisthmic cerclage might be an alternative approach even in the early second trimester of pregnancy. Our study's success rates compare favourably to the laparotomy approach and the laparoscopic cervicoisthmic cerclage showed a relatively high success rate in women who are at risk of poor obstetric outcomes. Of course, the surgeon's experience and competence play a key role, and this approach should only be attempted in well-organized units.

https://player.vimeo.com/video/1191437664?autoplay=1

ESGE35-0570 -
Free Communication

Laparoscopic orthotopic ovarian tissue transplantation and peritoneal endometriosis excision : a video demonstration

Jeanne Dupont deguine[1], Maria Letailleur[1], Pascal Piver[2], Nathalie Rives[3], Aurelie Rives[3], Patrice Crochet[4]
[1]Rouen University Hospital, Obstetrics and Gynecology, Rouen, France
[2]Limoges University Hospital, Obstetrics and Gynecology, Limoges, France
[3]Univ Rouen Normandie-, INSERM- NORDIC UMR 1239- Team Adrenal and Gonadal Pathophysiology AGoPath, Rouen, France
[4]Rouen Normandie University, Gynecologic surgery, Rouen, France

Background

Ovarian tissue cryopreservation remains the only fertility preservation strategy for patients requiring urgent gonadotoxic treatment and presenting contraindications to ovarian stimulation. Orthotopic ovarian tissue transplantation aims to restore endocrine and reproductive function after treatment. We report a case of laparoscopic two-step ovarian tissue autotransplantation during which incidental superficial peritoneal endometriosis was identified and surgically managed.

Methods

This video demonstrates a stepwise laparoscopic orthotopic ovarian tissue transplantation technique. A 34-year-old patient previously underwent ovarian tissue cryopreservation by partial right ovariectomy before breast cancer treatment. Following completion of tamoxifen therapy and two unsuccessful IVF attempts, ovarian tissue transplantation was proposed.
The procedure was performed in two steps. During the first laparoscopy, superficial peritoneal windows were created bilaterally within the ovarian fossa without electrocautery in order to promote local neovascularization. Initial thawed ovarian cortical fragments were then positioned with the medullary side facing the pelvic wall. Pelvic exploration also revealed previously undiagnosed superficial endometriosis lesions involving the prevesical peritoneum and the pouch of Douglas. These lesions were excised during the same procedure.
A second laparoscopy was performed three days later. After thawing, the remaining ovarian cortical fragments were assembled into cortical patches using 5-0 Prolene sutures. The grafts were then positioned within the previously prepared peritoneal windows and secured bilaterally with interrupted sutures.

Results

Histopathological analysis confirmed superficial peritoneal endometriosis. The postoperative course was uneventful, and the patient was discharged on postoperative day one after each procedure. Menstrual cycles resumed three months after transplantation. A spontaneous pregnancy occurred seven months after surgery.

Conclusions

This video illustrates a reproducible two-step laparoscopic orthotopic ovarian tissue transplantation technique designed to optimize graft revascularization. It also demonstrates the feasibility of concomitant surgical management of incidentally diagnosed superficial endometriosis during transplantation surgery. This approach, currently evaluated in the French DATOR study, may represent an effective alternative to the one-step transplantation technique.

https://player.vimeo.com/video/1191690840?autoplay=1

ESGE35-0597 -
Free Communication

Robotic abdominal cerclage: a novel approach using cyanoacrylate glue for postoperative oligohydramnios management

Adrielle Rodas Fernandes[1], Mayara Andrade[1], Mariana Corinti[1], Mariano Tamura[1]
[1]Einstein Hospital Israelita, Gynecology, São Paulo, Brazil

Background

To demonstrate the feasibility of robotic-assisted abdominal cerclage during pregnancy following radical trachelectomy for cervical cancer and to describe a novel approach using cyanoacrylate glue for the management of postoperative oligohydramnios.

Methods

We present the case of a 37-year-old primigravida with a previous history of stage IB2 cervical adenocarcinoma treated with robotic-assisted radical trachelectomy and sentinel lymph node biopsy two years earlier. The patient declined hysterectomy in favour of fertility preservation and remained under strict oncologic surveillance. After spontaneous conception and a normal first-trimester ultrasound, robotic-assisted abdominal cerclage was performed at 13 weeks of gestation. The procedure was carried out under local anesthesia using three robotic arms and one camera arm, with an additional auxiliary trocar. Surgical steps included adhesiolysis, retroperitoneal dissection, bladder mobilization, development of vesicouterine and vesicovaginal spaces, and careful bilateral ureterolysis. Vaginal palpation by the assistant surgeon and use of a gauze-wrapped DeLee forceps facilitated anatomical orientation during dissection. A Mersilene tape was positioned at the uterine isthmus in a posterior-to-anterior direction medial to the uterine vessels and superior to the uterosacral ligaments. Four weeks later, repeat laparoscopy was required due to oligohydramnios. Cyanoacrylate glue was applied anteriorly and posteriorly at the identified tape exit sites after adhesiolysis and exposure of the cerclage knot.

Results

The abdominal cerclage was successfully completed without intraoperative complications. Transvaginal ultrasound at the end of the procedure confirmed foetal cardiac activity and appropriate tape positioning. Following the second procedure with cyanoacrylate application, restoration of amniotic fluid volume was observed, allowing continuation of the pregnancy. Gestation progressed until 32 weeks and 3 days, when an emergency caesarean section was performed due to preterm labour. A live male neonate weighing 1.85 kg was delivered, with Apgar scores of 8 and 9 at one and five minutes, respectively.

Conclusions

Robotic-assisted abdominal cerclage represents a feasible fertility-preserving strategy following radical trachelectomy. The robotic platform provides enhanced dexterity and precision during complex pelvic dissection in pregnancy. In this case, the experimental use of cyanoacrylate glue after

postoperative oligohydramnios was associated with restoration of amniotic fluid volume and favourable obstetric progression.

https://player.vimeo.com/video/1191700664?autoplay=1

ESGE35-0633 -
Free Communication

Insights and pearls for uterosacral suspension in vNOTES hysterectomy

Aya Mohr-Sasson[1], Alvaro Montealegre[1], Apurva Pancholy[1], Asha Bhalwal[1]
[1]McGovern Medical School at The University of Texas Health Science Center, Department of Obstetrics- Gynecology & Reproductive Sciences, Houston, USA

Background

Vaginal natural orifice transluminal endoscopic surgery (vNOTES) is an emerging minimally invasive technique that provides laparoscopic access via the transvaginal route. Unlike conventional laparoscopic or robotic hysterectomy, vNOTES involves routine early transection of the uterosacral ligaments—key structures in maintaining apical vaginal support. This raises concerns regarding future pelvic organ prolapse. The aim of this study is to describe a technique for prophylactic uterosacral suspension during vNOTES hysterectomy to preserve apical support and align with pelvic reconstructive principles and ACOG guidelines.

Methods

A detailed intraoperative video tutorial demonstrates the uterosacral suspension technique performed during a vNOTES hysterectomy in a 51-year-old woman (G4P2) with a history of cervical dysplasia and prior vaginal deliveries. Following completion of the standard vNOTES hysterectomy and bilateral salpingectomy, a prophylactic uterosacral ligament suspension was performed to mitigate the risk of future apical prolapse. The video highlights essential surgical steps, including identification of key anatomical landmarks, suture placement, and tissue handling techniques. Technical pearls and safety considerations are emphasized throughout to guide optimal execution and enhance procedural confidence.

Results

The uterosacral suspension technique was successfully implemented without intraoperative complications. The video demonstrates that the approach is both feasible and effective in preserving apical support following vNOTES hysterectomy. This intervention is consistent with ACOG guidelines, which recommend incorporating apical support at the time of hysterectomy to reduce the risk of future prolapse. While long-term outcome data are still pending, early experience supports its integration into standard surgical practice.

Conclusions

As adoption of vNOTES increases, attention to long-term outcomes, including pelvic organ support, becomes essential. Integrating uterosacral suspension as a routine component of vNOTES hysterectomy may mitigate the risk of future prolapse, uphold surgical best practices, and enhance long-term patient outcomes.

https://player.vimeo.com/video/1191779599?autoplay=1

ESGE35-0944 -
Free Communication

Laparoscopic Transabdominal Cerclage Following a Failed Transvaginal Cerclage: A Step-by-Step Approach

Atakan Sen[1], Necati Berk Kaplan[1], Batuhan Aslan[1], Gülşah Aynaoğlu[1], Yavuz Emre Şükür[1]
[1]Ankara University, Obstetrics and Gynecology, Ankara, Türkiye

Background

Cervical insufficiency is a recognized cause of painless cervical dilation leading to mid-trimester pregnancy loss and extreme premature delivery. Transvaginal cerclage is typically the first-line treatment for patients with a sonographically short cervix and a history of preterm birth. However, in patients with a prior failed vaginal cerclage resulting in a delivery before 28 weeks, a transabdominal cerclage (TAC) is strongly recommended to improve neonatal survival. The aim of this video is to demonstrate the step-by-step surgical technique of a laparoscopic TAC in a patient with a history of a failed McDonald cerclage.

Methods

We present the case of a 28-year-old woman (G1P0A1) who experienced a mid-trimester loss. During her previous pregnancy, transvaginal cervical length (TVU CL) screening at 15 weeks revealed a short cervix of 15 mm, and a McDonald transvaginal cerclage was subsequently placed. At 18 weeks and 3 days of gestation, she presented with preterm premature rupture of membranes (PPROM), and the TVU CL was 8 mm with evident funnelling. Due to rising acute-phase reactants and the high risk of impending chorioamnionitis, the pregnancy was terminated. Following this failed transvaginal cerclage, a preconceptional laparoscopic TAC was planned. The surgical steps demonstrated in the video include opening the vesicouterine peritoneum, displacing the bladder caudally, identifying the uterine vessels, creating an avascular window medial to the uterine vessels at the level of the cervicoisthmic junction (internal os), passing a Mersilene tape circumferentially, tying the knot anteriorly, and performing reperitonealization.

Results

The laparoscopic TAC was completed successfully without any intraoperative complications. Blood loss was minimal, and the patient had an uneventful postoperative recovery and was discharged on the first postoperative day. The patient was counselled that the cerclage will remain in situ indefinitely and that all future deliveries will necessitate a caesarean section.

Conclusions

Laparoscopic transabdominal cerclage is a safe, feasible, and highly effective fertility-preserving intervention for women with cervical insufficiency and a history of failed transvaginal cerclage. Adherence to meticulous surgical steps, careful dissection, and precise knowledge of retroperitoneal anatomy are essential to minimize surgical morbidity and optimize future obstetrical outcomes.

https://player.vimeo.com/video/1195769667?autoplay=1

ESGE35-0163 -
Free Communication

Does robotic surgery have a role in complex hysterectomy? a single-centre experience

Irem Herguner[1], Murat Cengiz[2], Utku Akgör[2], Murat Gultekin[2], Derman Basaran[2]
[1]Hacettepe University, Obstetrics and Gynecology, ANKARA, Türkiye
[2]Hacettepe University, Division of Gynecologic Oncology- Department of Obstetrics and Gynecology-, Ankara, Türkiye

Background

Complex hysterectomy is associated with increased intraoperative and postoperative risks due to patient-, disease-, and procedure-related factors. While robotic-assisted surgery offers technical advantages, its clinical superiority over conventional laparoscopy remains unclear. To evaluate the role of robotic-assisted hysterectomy in complex cases and assess perioperative outcomes in a tertiary center cohort.

Methods

We conducted a retrospective cohort study of 185 consecutive robotic-assisted gynecologic procedures performed at a tertiary referral center between May 2023 and December 2025. Patient complexity was defined by predefined criteria including obesity (BMI ≥30), advanced age (≥65 years), oncologic indication, and anticipated surgical difficulty.

Primary outcomes included conversion to laparotomy and major postoperative morbidity (Clavien-Dindo ≥III). Secondary outcomes included feasibility across high-risk subgroups.

Results

A total of 185 robotic-assisted gynaecologic procedures were analysed, representing a predominantly high-risk population. The mean body mass index was 30 (range 18–60), with 25.5% of patients aged ≥65 years and approximately 70% undergoing surgery for oncologic indications.

Despite the elevated baseline complexity, perioperative outcomes were favourable. The overall conversion rate to laparotomy was low at 1.5%, with no conversions observed among obese patients. Major postoperative complications (Clavien–Dindo grade ≥III) occurred in 1.1% of cases. Importantly, robotic-assisted surgery remained feasible across multiple high-risk subgroups, including patients with morbid obesity and advanced oncologic disease. These findings suggest that, within a complex surgical setting, robotic surgery can be implemented with low morbidity and minimal need for conversion, supporting its potential role in extending the applicability of minimally invasive surgery.

Table 1: Perioperative outcomes in robotic-assisted complex hysterectomy

Variable	***Value***
Total number of procedures	185
Mean BMI (range)	30 (18–60)
BMI ≥25 (%)	75%
Age ≥65 years (%)	25.5%
Oncologic indications (%)	~70%
Conversion to laparotomy (%)	1.5% (3/185)
Conversion in obese patients (%)	0%
Major complications (Clavien–Dindo ≥III)	1.1% (2/185)
Major complications in obese patients	1.6% (1/70)

Conclusions

While robotic-assisted hysterectomy does not demonstrate clear superiority over conventional laparoscopy in routine practice, our findings suggest that it may confer a selective advantage in complex surgical settings, particularly among obese and high-risk patients.

Rather than replacing conventional laparoscopy, robotic surgery may serve as a strategic adjunct, expanding the boundaries of minimally invasive surgery in challenging cases.

ESGE35-0271 -
Free Communication

Robotic identification and excision of occult vaginal endometriotic nodules: the added value of systematic intraoperative vaginal assessment beyond MRI

Saima Farooq[1], Amer Raza[1], Sarah Rami[2]
[1]Cromwell Hospital, Gynaecology, London, United Kingdom
[2]Chelsea and Westminster Hospital NHS Foundation Trust

Background

Vaginal endometriotic nodules remain an under-recognised manifestation of deep infiltrating endometriosis and are frequently associated with severe pelvic pain and deep dyspareunia. Despite advances in pelvic imaging, these lesions may remain occult preoperatively, contributing to incomplete excision and persistent symptoms. Careful intraoperative assessment and meticulous surgical planning are therefore essential to optimise disease detection and surgical outcomes.

Methods

We present a consecutive surgical series of ten patients undergoing robotic management of vaginal endometriotic nodules during 2025. All patients underwent detailed preoperative evaluation including symptom assessment, pelvic examination, and pelvic MRI. Preoperative imaging identified vaginal disease in six patients. At the start of surgery, a structured intraoperative speculum and rectovaginal examination under anaesthesia was systematically performed. This identified vaginal nodules in nine patients, including occult lesions not visualised on MRI. All lesions were managed using a robotic-assisted nerve-sparing approach with complete excision of visible disease.

Results

Concurrent rectal involvement was identified in six patients. Four patients underwent rectal shaving, while two required discoid excision. No intraoperative or postoperative complications occurred, and all patients were discharged within 24 hours following surgery. Clinical follow-up at three and six months demonstrated marked symptomatic improvement. Median pain scores improved from 9/10 preoperatively to 3/10 postoperatively, with significant improvement in deep dyspareunia and pelvic pain symptoms. All patients were referred for pelvic floor physiotherapy to optimise functional recovery.

Conclusions

This series demonstrates the limitations of MRI in detecting vaginal endometriotic disease and highlights the importance of systematic intraoperative vaginal assessment. Combining symptom correlation with meticulous robotic surgical exploration enables improved identification of occult disease, facilitates complete excision, and may contribute to superior long-term symptom control and patient recovery.

https://player.vimeo.com/video/1199582642?autoplay=1

ESGE35-0592 -
Free Communication

Robotic sentinel lymph node mapping with indocyanine green using a RAS system in endometrial cancer staging: outcomes of a prospective series.

Riccardo Oliva[1], Sara Mastrovito[2], Andrea Rosati[3], Emanuele Perrone[3], Anna Fagotti[4], Francesco Fanfani[3]
[1]Fondazione Policlinico Universitario A. Gemelli IRCSS- Università Cattolica del Sacro Cuore- Roma, Department of Women's and Children's Health- Complex Unit of Gynecologic Oncology, Rome, Italy
[2]Fondazione Policlinico Universitario A. Gemelli IRCCS- Università Cattolica del Sacro Cuore- Rome- Ital y, Department of Women's and Children's Health- Complex Unit of Gynecologic Oncology, Rome, Italy
[3]Fondazione Policlinico Universitario A. Gemelli IRCCS. Catholic University of Sacred Heart- Rome- Italy , Department of Women's and Children's Health- Complex Unit of Gynecologic Oncology, Rome, Italy
[4]Fondazione Policlinico Universitario A. Gemelli IRCCS. Catholic University of Sacred Heart- Rome- Italy , Department of Women's and Children's Health- Complex Unit of Gynecologic Oncology, Roma, Italy

Background

minimally invasive surgery represents the gold standard for presumed early-stage endometrial cancer. the HUGO™ robotic-assisted Surgery system is a modular platform with the newly integrated fluorescence. We aimed to evaluate perioperative outcomes and sentinel lymph node mapping rates using indocyanine green during surgery for endometrial cancer staging.

Methods

prospective cohort of patients undergoing total hysterectomy with or without adnexal surgery and sentinel lymph node biopsy using the HUGO™ RAS system in one single referral center. a four-arm compact configuration was used in all cases. sentinel lymph node mapping was performed with standard cervical indocyanine green injection. demographics, perioperative data, and postoperative complications were analysed.

Results

sixty patients were included. median age was 54 years (39–79), bmi 25 kg/m² (19–37). median operative time was 133.5 minutes (68–320) and docking time 5 minutes (3–12). bilateral sentinel lymph node detection was achieved in 51/60 (85%), unilateral in 1/60 (1.7%), while mapping failed in 7/60 (11.7%). conversion to laparotomy occurred in 2/60 (3.3%) for specimen extraction. estimated blood loss was low (median 20 ml), and median discharge was postoperative day 2 (1–6). one intraoperative and one postoperative grade I complication (1.7% each) were recorded. final pathology demonstrated endometrial atypical hyperplasia in 51.7%, and endometrial cancer in 48.3% of cases. among endometrial cancer, 93.1% were endometrioid; figo 2023 stages ranged from Ia to IIIa1. upstaging from atypical hyperplasia occurred in 11.6%. most patients (62.1%) were classified as low-

risk. median number of sentinel lymph node harvested was 2 (0-7).



Conclusions

The HUGO™ RAS system proved safe, ergonomically efficient, and oncologically reliable for surgical staging of endometrial disease, with high rates of successful sentinel lymph node mapping and minimal morbidity. these findings support its integration into contemporary gynaecologic oncologic practice and provide a robust rationale for comparative evaluation with established robotic platforms.

ESGE35-0605 -
Free Communication

Is robot-assisted surgery for endometrial cancer economically viable compared to laparoscopy in the Polish healthcare setting?

Anna Abacjew-Chmylko[1], *Dariusz G. Wydra*[1]
[1]*Medical University of Gdansk, Department of Gynecology and Obstetrics, Gdansk, Poland*

Background

Robot-assisted surgery (RAS) in gynaecological oncology has expanded rapidly in Poland since the National Health Fund (NFZ) reimbursement reform in 2022. Endometrial cancer is currently the main gynaecological indication reimbursed for robotic surgery by the NFZ. While clinical benefits of RAS over laparoscopy are well documented, comparative cost-effectiveness data in the Polish setting remain scarce, creating uncertainty for centres considering implementation.

Objectives

To compare the hospital treatment costs of patients with endometrial cancer operated on with robotic assistance versus conventional laparoscopy.

Methods

A retrospective cost analysis was performed on 50 patients with stage I endometrial cancer operated on between October 2023 and December 2024 at a tertiary academic centre. All procedures were performed by the same high-volume surgeon with extensive prior experience in advanced laparoscopy and in robotic surgery using an alternative robotic platform, ensuring comparable operator expertise across both groups. The robotic group (n=25) consisted of consecutive patients operated on with the da Vinci Xi system, starting from the 41st case to exclude the learning curve. The laparoscopic group (n=25) consisted of patients operated on immediately before the introduction of the da Vinci system. All procedures comprised total hysterectomy with bilateral salpingo-oophorectomy and sentinel lymph node biopsy. Cost components analysed represent direct hospitalisation costs and included bed-days, operating theatre use, diagnostics, consumables and equipment amortisation. Indirect costs — personnel salaries, fixed ward costs and, most importantly, the capital cost of acquiring the robotic system — were not included, which represents the main limitation of this analysis. Statistical analysis used Student's t-test, with $p<0.05$ considered significant.

Results

The mean direct hospitalisation cost was only marginally higher for robotic procedures than for laparoscopy, with the difference not reaching statistical significance ($p=0.29$). The robotic group showed a shorter mean hospital stay, significantly shorter operative time ($p=0.01$) and significantly lower operating theatre costs ($p<0.0001$). Resource consumption costs were significantly higher in the robotic group ($p<0.0001$), driven by disposable instruments and equipment amortisation. Conversion to laparotomy occurred in 0% of robotic versus 8.0% of laparoscopic cases ($p<0.05$); reoperation rates were 0% versus 4.0%, respectively ($p<0.05$). Cost variability was markedly lower in the robotic group, reflecting greater predictability of resource use.

Conclusions

With a single experienced operator and controlled for the learning curve, robot-assisted surgery for endometrial cancer generated only marginally higher direct hospitalisation costs than laparoscopy, with the difference not reaching statistical significance. Higher consumable and amortisation costs were largely offset by shorter stay, shorter theatre time and the absence of conversions and reoperations. The principal limitation of this analysis is the exclusion of indirect costs, particularly the capital cost of the robotic system, which remains the dominant barrier to implementation; nevertheless, operational cost-efficiency appears favourable and is expected to improve with growing surgical volume and market competition.

ESGE35-0949 -
Free Communication

Is single-port gynaecological surgery the final destination of robotic-assisted surgery? Early experience across multiple complex pelvic cases compared with multiport approaches

Saima Farooq[1], Amer Raza[1]
[1]Cromwell Hospital, Gynaecology, London, United Kingdom

Background

Single-port robotic surgery represents an evolving advancement in minimally invasive gynaecological surgery, aiming to reduce abdominal wall trauma while preserving surgical precision and reconstructive capability. Although conventional multiport robotics remains widely utilised in complex benign gynaecological surgery, increasing experience with single-port platforms suggests potential advantages in cosmetic outcomes, instrument articulation, confined-space surgery, and enhanced patient-centred minimally invasive care. However, evidence demonstrating its applicability across diverse complex pelvic pathologies remains limited.

Methods

This video abstract demonstrates the feasibility and versatility of robotic single-port surgery across multiple complex gynaecological scenarios. Four representative surgical procedures are presented. The first demonstrates robotic single-port management of complex fibroid disease with ureteric compression requiring advanced myomectomy and multilayer reconstruction. The second demonstrates fertility-preserving robotic adenomyomectomy for severe adenomyosis associated with advanced endometriosis. The third demonstrates robotic single-port segmental bowel resection for severe rectosigmoid endometriosis using a novel contained extraction strategy. The fourth demonstrates robotic management of advanced bladder and ureteric endometriosis requiring complex retroperitoneal dissection and reconstructive surgery. Surgical principles including retroperitoneal anatomy, vascular control, nerve-sparing dissection, fluorescence-guided surgery, and reconstructive techniques are highlighted throughout.

Results

All procedures were completed successfully using a single-port robotic platform without conversion to laparotomy or additional abdominal ports. The single-port platform provided stable visualisation, enhanced articulation, precise dissection, and effective reconstruction within confined pelvic anatomy. Excellent cosmetic outcomes and preservation of minimally invasive principles were achieved across all surgical scenarios. Complex dissection involving bowel, bladder, ureteric, and deep pelvic disease was safely performed with satisfactory postoperative recovery.

Conclusions

Single-port robotic surgery appears to be a safe and versatile minimally invasive platform for advanced gynaecological surgery across multiple complex pathologies. Beyond cosmetic benefits alone, the approach facilitates precision dissection, reconstructive surgery, and confined pelvic

operating while maintaining minimally invasive
principles. https://player.vimeo.com/video/1199580085?autoplay=1

ESGE35-0959 -
Free Communication

First clinical series of ten cases of single-port robotic disc excision for severe rectosigmoid endometriosis: a novel minimally invasive approach with comparable multiport outcomes

Saima Farooq[1], Amer Raza[1], Ana Mcdougall[2]
[1]Cromwell Hospital, Gynaecology, London, United Kingdom
[2]East and North Hertfordshire NHS Trust

Background

Disc excision represents an important fertility-preserving surgical option for selected patients with bowel endometriosis. However, the application of robotic single-port platforms for colorectal endometriosis surgery remains extremely limited, with very few reported series worldwide. Single-port robotic surgery may provide enhanced articulation, improved visualisation, reduced abdominal wall trauma, and superior cosmetic outcomes while preserving minimally invasive surgical principles. We present our initial experience from the first ten cases of robotic single-port disc excision performed for severe rectosigmoid endometriosis.

Methods

This video abstract demonstrates robotic single-port disc excision performed for advanced deep infiltrating rectosigmoid endometriosis. A retrospective review of the first ten consecutive patients undergoing robotic single-port disc excision was undertaken. Surgical steps included retroperitoneal dissection, ureterolysis, rectovaginal space development, discoid bowel excision, intracorporeal bowel repair, and contained specimen retrieval through the single-port access platform. Perioperative outcomes, postoperative recovery, and complications were evaluated. One patient developed a postoperative fistula requiring return to theatre and reconstructive management, with favourable long-term outcome following treatment.

Results

All procedures were completed successfully without conversion to laparotomy or requirement for additional abdominal ports. The single-port robotic platform provided enhanced dexterity and stable visualisation within confined pelvic anatomy. Preliminary outcomes demonstrated favourable postoperative recovery, minimal access-related morbidity, and satisfactory symptomatic improvement. Overall outcomes appeared comparable to published multiport robotic series while maintaining the advantages of single-port minimally invasive surgery.

Conclusions

This early experience demonstrates the technical feasibility and safety of robotic single-port disc excision for severe rectosigmoid endometriosis. To our knowledge, this represents one of the earliest reported series describing single-port robotic disc excision for bowel endometriosis. The technique may offer outcomes comparable to multiport robotic surgery while potentially reducing abdominal wall morbidity and improving cosmetic outcomes. Further prospective evaluation is required to

assess long-term reproducibility, safety, and patient-centred outcomes of this evolving minimally invasive approach.

https://player.vimeo.com/video/1199576605?autoplay=1

ESGE35-0100 -
Free Communication

Robot-assisted arterial sparing radical trachelectomy for early cervical cancer

Xiang Xue[1], *Pijun Gong*[2]
[1]*the Second Affiliated Hospital of Xian Jiao Tong University, Dept of Obstetrics and Gynaecology, Xi'an, China*
[2]*The Second Affiliated Hospital of Xi'an Jiao Tong University, Dept of Obstetrics and Gynaecology, Xi'an, China*

Background

Surgical demonstration by case. Show the advantages and characteristics of robot-assisted laparoscopic surgery in arterial sparing radical trachelectomy for early cervical cancer, and emphasize the key points that need to be paid attention to in the operation

Methods

Robot-assisted arterial sparing radical trachelectomy and pelvic lymphadenectomy in a 30-year-old, desire for fertility with stage IB1 squamous cell carcinoma of the cervix under the robotic surgical platform.

Results

1. The main purpose of radical trachelectomy is to preserve fertility and achieve pregnancy and delivery. therefore, postoperative preservation of the uterus with adequate blood supply is particularly critical to maintain normal function.
2. Preserving the uterine artery is a crucial step in performing arterial sparing radical trachelectomy with the aim of preserving the uterus and its blood supply.
3. The robotic surgical system provides a clearer surgical field and enables thorough excision of the paracervix and parametrial tissues.
4. Improving the stability of the surgical operation and reducing the risk of damaging the preserved uterine arteries
5. Makes the operation more flexible and suitable for precise dissection, suturing, and other surgeries in narrow spaces, which has great advantages for reconstructive surgery.

Conclusions

Robot-assisted laparoscopic uterine artery-sparing radical trachelectomy for early-stage cervical cancer is a reconstructive procedure. due to its high-definition naked-eye 3D field of view, flexible turning, fine and accurate separation, it ensures the precise anatomy of uterine artery preservation, significantly improves the chance of preserving uterine blood vessels, and thus ensures the postoperative blood supply and reproductive function of the uterus.

https://player.vimeo.com/video/1190709080?autoplay=1

ESGE35-0789 -
Free Communication

Robotic deep endometriosis resection with rectal nodule shaving using a RAS system and robotic ultrasound guidance: a video case report

Giorgia Gaia[1], Cristiano Rossitto[1], Greta Benvenga[1], Sara Mastrovito[1], Giulia Capanna[1], Francesco Fanfani[1]
[1]Fondazione Policlinico Universitario A. Gemelli IRCCS, Department of Women's and Children's Health, Rome, Italy

Background

To demonstrate the feasibility of conservative robotic-assisted management of deep infiltrating endometriosis involving the rectovaginal septum and anterior rectal wall using rectal shaving combined with intraoperative robotic ultrasound guidance.

Methods

We present the case of a 27-year-old patient complaining of dysmenorrhea and dyspareunia without relevant comorbidities. Preoperative transvaginal ultrasound identified a rectovaginal endometriotic nodule infiltrating the anterior rectal wall. Surgical treatment was performed using the Hugo™ RAS system. The procedure included bilateral pararectal dissection, isolation of the rectovaginal nodule and subsequent rectal shaving while preserving bowel integrity. The vaginal component of the lesion was subsequently excised. At the end of the procedure, robotic ultrasound guidance was used to evaluate residual rectal wall involvement and possible bowel stenosis

Results

Complete excision of the visible endometriotic disease was achieved using a nerve-sparing and bowel-sparing approach. Intraoperative ultrasound assessment confirmed preservation of the rectal lumen without evidence of stenosis and assessment of residual disease. No intraoperative complications occurred. Considering the absence of bowel symptoms and the intraoperative findings, conservative rectal shaving was considered appropriate, avoiding discoid or segmental bowel resection.

Conclusions

The Hugo™ RAS system combined with robotic ultrasound guidance appears to be a feasible approach for selected patients with deep infiltrating endometriosis. Intraoperative robotic ultrasound may represent a useful adjunct for real-time assessment of residual disease and bowel integrity during conservative rectal surgery.

https://player.vimeo.com/video/1195597044?autoplay=1

ESGE35-0956 -
Free Communication

Robotic surgical management of concurrent severe endometriosis and bulky uterine fibroids: intra-operative complication management in a complex case

Sharon Davidesko[1], *Jennifer Shallop*[2], *Prashant Purohit*[3], *Nitish Narvekar*[1]
[1]*King's College Hospital, Endometriosis and Complex Gynaecology- Women's Services, London, United Kingdom*
[2]*King's College Hospital, Women's Services, London, United Kingdom*
[3]*King's College Hospital, Complex Gynaecology- Women's Services, London, United Kingdom*

Background

To demonstrate the feasibility of robotic-assisted laparoscopic surgery for the simultaneous management of bulky uterine fibroids and severe endometriosis, and to illustrate a structured approach to intra-operative complication management within a single procedure.

Methods

A 33-year-old patient presented with a 16-week multi-fibroid uterus including a 25 cm FIGO type 6 fundal fibroid, bilateral endometriomas, and rectovaginal endometriosis with rectal involvement confirmed on MRI and examination. Pre-operative treatment with a gonadotropin-releasing hormone (GnRH) agonist was administered. Robotic-assisted surgery was performed using Palmer's point entry and a high semilunar port configuration. The procedure included robotic myomectomy with vasopressin injection for haemostasis, bilateral ureterolysis, pouch of Douglas dissection, rectal shave, bilateral endometrioma treatment, and management of an intraoperative rectal injury.

Results

Nine fibroids were removed through three uterine incisions without breach of the uterine cavity; total fibroid weight was 2 kg. Intraoperative spontaneous bilateral endometrioma rupture was managed with immediate suction to limit dissemination. A small rectal injury identified during rectovaginal dissection was repaired primarily with interrupted absorbable sutures; an initial air leak test demonstrated incomplete closure requiring a second suture layer, after which the repair was confirmed intact. Indocyanine green (ICG) fluorescence angiography confirmed adequate perfusion at the repair site. Specimens were retrieved via a 4 cm Pfannenstiel mini-laparotomy. The patient was discharged on day 2 without opioid analgesia and with no further complications.

Conclusions

This case demonstrates that complex combined pelvic pathology, historically requiring midline laparotomy, can be safely managed with robotic-assisted laparoscopy in a specialist centre. It illustrates a reproducible approach to intraoperative complications including rectal injury, with two-layer primary repair and ICG perfusion confirmation as integral steps. Robotic surgery offers precision and adaptability in cases where pathology and intraoperative findings evolve beyond the preoperative plan.

https://player.vimeo.com/video/1195777757?autoplay=1

ESGE35-0105 -
Free Communication

Real-time transvaginal ultrasound-guided microwave ablation of uterine fibroids: a retrospective single-center study on safety and effectiveness

Kyriakos Kakoullis[1], Thekla Achmet[1], Marianna Kakoulli[2], Polys Mitsingas[3], Stylianos Kakoullis[4], Nicolas Galazis[1]
[1]School of Medicine- European University Cyprus,
Department of Obstetrics and Gynecology- Nicosia Polyclinic, Nicosia, Cyprus
[2]School of Medicine- European University of Cyprus,
Department of Obstetrics and Gynecology- Nicosia Polyclinic, Nicosia, Cyprus
[3]Aretaeio Hospital, Department of Obstetrics and Gynecology- Aretaeio Hospital, Nicosia, Cyprus
[4]School of Medicine- European University Cyprus, Medicine, Nicosia, Cyprus

Background

Uterine fibroids (UFs) are the most common benign uterine tumors and may significantly impair quality of life (QoL) through bleeding, pain, anaemia, and fertility-related complications. While surgery remains the definitive treatment, minimally invasive uterus-sparing therapies are increasingly employed, one of these techniques is the microwave fibroid ablation (MWFA) procedure and we aimed to evaluate the safety and clinical effectiveness of real-time transvaginal ultrasound-guided microwave fibroid ablation (RT-TVUS-MWFA) for the treatment of symptomatic UFs using the low-energy multiple overlapping ablation (LEMOA) protocol.

Methods

A retrospective single-center study was conducted at Nicosia Polyclinic between July and December 2025 performed by senior gynaecologists. Thirty-eight symptomatic premenopausal women with a total of 46 FIGO type 2–5 fibroids were included. Procedures were performed under general anesthesia, with continuous transvaginal ultrasound guidance using a 2.45-GHz solid-state microwave system delivering energy at 20 W for 15–60 seconds per ablation cycle targeting approximately 70% of the UF volume. Fibroid volume and volume reduction ratio (VRR) were evaluated at the onset and at the end of the procedure. UF volumes and VRR were also reassessed at the 40-day and 3-month follow-up examinations. Symptom Severity Score (SSS), QoL using the UFS-QoL questionnaire were evaluated before the procedure and 3 months after the procedure. Peri and post-procedural complications were documented. Ablation times in seconds (s), ablation hits and cumulative energy delivery in kilojoules (kJ) were also recorded.

Results

100% technical success was achieved without peri or post procedural complications. Mean fibroid volume decreased from 30.4 mL pre-procedurally to 25.0 mL immediately post-procedurally, 17.9 mL at 40 days, and 14.0 mL at 3 months. VRR was 35.1% immediately post-procedure, 61.4% at 40 days, and 65.8% at 3 months. Both fibroid volume decrease and VRR showed statistical significance at all time point intervals ($p<0.001$). Significant clinical and statistical improvement was also observed in SSS (42.8 vs 13.3) and QoL scores (35.0 vs 9.06) at 3 months ($p<0.001$). Ablation time and energy

delivery correlated strongly with fibroid size (ρ=0.753), while VRR was inversely correlated with fibroid size and procedural parameters (ρ=-0.706, p<0.001).

Conclusions

RT-TVUS-MWFA using the LEMOA protocol appears to be a safe and effective minimally invasive, uterus-preserving treatment option for women with symptomatic uterine fibroids who decline or are unsuitable for surgery. Smaller fibroids responded more rapidly and required lower energy delivery, whereas larger fibroids showed a slower but sustained volume reduction, ultimately achieving comparable outcomes over time. These findings support the potential benefit of earlier intervention and warrant further prospective studies on treatment timing and long-term outcomes.

ESGE35-0185 -
Free Communication

Analysis of preoperative risk factors and development and validation of a predictive model for single-port trans-umbilical laparoscopic myomectomy in high-risk cases

Qiong Zhang[1], *Yu Zhao*[1]
[1]*The Second Affiliated Hospital and Yuying Children's Hospital of Wenzhou Medical University, Department of Obstetrics and Gynaecology, Wenzhou, China*

Background

To investigate the predictive value of MRI radiomics for evaluating the feasibility of trans- umbilical single-port laparoendoscopic myomectomy, and to construct and validate a combined predictive model incorporating MRI radiomics, imaging phenotypes and clinical characteristics.

Methods

This retrospective study enrolled 135 patients at the second affiliated hospital of Wenzhou medical university who planned for trans-umbilical single-port laparoendoscopic myomectomy from January 2023 to May 2025, all operated by the same surgeon (130 successfully completed as planned, 5 converted to traditional laparoscopic myomectomy). patients were categorized into conventional and difficult groups based on surgery duration and approach, then randomly divided into training (n=95) and test (n=40) cohorts using 7:3 stratified sampling. uterine fibroids were manually segmented on T2-weighted images (T2WI) for radiomics feature extraction. features highly correlated with surgical feasibility were selected using maximum relevance minimum redundancy (mRMR) algorithm and least absolute shrinkage and selection operator (LASSO) regression to build a radiomics (r) model. clinical data and imaging phenotypes were collected to construct a clinical-radiology (c-r) model via univariate and multivariate analysis. a combined clinical-radiology-radiomics (C-R-R) model was then developed. model performance was evaluated using area under the curve (AUC), calibration curves, and decision curve analysis.

Results

The training cohort included 35 difficult and 60 conventional cases; the test cohort included 15 difficult and 25 conventional cases. Independent predictors of surgical difficulty were number of fibroids (single or multiple) and location of the largest fibroid. the C-R model achieved an AUC of 0.722 (95% ci: 0.695-0.85) in training and 0.690 (0.523-0.848) in test. Fifteen radiomics features selected via mRMR and lasso formed the R model, which yielded AUCs of 0.844 (0.778-0.899) in training and 0.784 (0.642-0.91) in test. the C-R-R composite model showed superior performance with AUC of 0.905 (0.844-0.954) in training and 0.836 in test. Calibration curves indicated good predictive performance, and decision curve analysis demonstrated clinical utility.

Conclusions

The C-R-R composite model integrating MRI radiomics, imaging phenotypes and clinical characteristics demonstrated excellent predictive performance for assessing the feasibility of trans-umbilical single-port laparoendoscopic myomectomy, with good clinical applicability.

ESGE35-0307 -
Free Communication

Single port robotic-assisted myomectomy: surgical outcomes and early patient-reported satisfaction

Leonardo Nelva Stelio[1], Margherita Cei[2], Carmela Quatrale[1], Luca Calzolari[1], Federica Ottolini[1], Federico Spelzini[1]
[1]ASST Grande Ospedale Metropolitano Niguarda, OB/GYN, Milan, Italy
[2]University Milano-Bicocca, OB/GYN, Milan, Italy

Background

Myomectomy is the gold standard conservative surgical treatment for symptomatic uterine fibroids in women desiring fertility preservation. The introduction of next-generation robotic platforms has enabled complex procedures to be performed through a single incision. The Single Port (SP) robotic system combines the advantages of robotic surgery with enhanced minimally invasive access. The aim of this study was to evaluate feasibility, safety, perioperative outcomes, and patient-reported outcomes following SP robotic-assisted myomectomy.

Methods

A retrospective analysis was conducted on the first 19 consecutive patients undergoing SP robotic-assisted myomectomy at Grande Ospedale Metropolitano Niguarda between 2025 and 2026. Collected data included demographic characteristics, fibroid features (number, size, and location), operative time, estimated blood loss (EBL), haemoglobin variation, length of hospital stay, need for additional trocars, conversion rate, intra- and postoperative complications, surgical site infections (SSI), transfusion requirement, and patient-reported outcomes. Pre- and postoperative symptoms (pelvic pain and abnormal uterine bleeding) were compared. Patient satisfaction was assessed using a 5-point Likert scale (CSAT).

Results

Mean age was 36.8 ± 7.2 years and mean BMI was 21.4 ± 3.3 kg/m². Mean operative time was 162.6 ± 56.5 minutes, with mean EBL of 315.6 ± 408.1 mL. Fibroid size ranged from 4 to 12 cm (mean 7.2 ± 2.4 cm), predominantly intramural and subserosal, with selected cases of multiple fibroids.

Mean haemoglobin decreased from 12.9 g/dL preoperatively to 11.3 g/dL at discharge. Mean length of stay was 2.8 ± 0.8 days. An additional trocar was required in 47% of cases. No conversions to laparotomy were recorded. No intraoperative or major postoperative complications and no surgical site infections occurred; two patients required blood transfusion.

A significant postoperative improvement in pelvic pain and abnormal uterine bleeding was observed. Patient satisfaction was high, with a mean CSAT score of 4.7 ± 0.6.

Conclusions

SP robotic-assisted myomectomy appears to be a feasible and safe minimally invasive approach, even for large or complex fibroids. It is associated with favourable perioperative outcomes, low morbidity,

significant symptom improvement, and high patient satisfaction. Larger prospective studies with longer follow-up are warranted to confirm these findings and define its role in clinical practice.

ESGE35-0365 -
Free Communication

Transvaginal radiofrequency ablation of uterine fibroids: one-year outcomes in 96 patients

Martina Billeci[1], Gianfranco Morreale[1], Giulia Roberta Arcidiacono[1], Ilaria Marilli[1], Davide Calandra[1], Francesco Giuseppe Cannone[1]
[1]Lentini Hospital- Contrada Colle Roggio, Department of Gynaecology and Obstetrics, Lentini, Italy

Background

Uterine fibroids are a leading cause of menorrhagia and gynecologic morbidity in women of reproductive age. Transvaginal radiofrequency ablation (TV-RFA) offers a minimally invasive, uterus-sparing alternative to surgery. We aimed to evaluate the one-year clinical efficacy and safety of TV-RFA with the Myoblate system in an unselected real-world cohort.

Methods

We performed a retrospective analysis of patients who underwent TV-RFA at the Obstetrics and Gynecology Unit of Lentini Hospital (Lentini, Italy) and were followed up for up to 1 year for symptoms, complications and fibroid size. TV-RFA was performed with the Myoblate system, with energy delivery adjusted according to fibroid size and tissue response. A systematic slice-by-slice approach allows for coverage of the target volume of the myoma, while subsequent ablation of the vascular pedicle or main feeding vessel was intended to enhance tissue necrosis. Ablation continued until the treated area showed homogeneous hyperechogenicity on ultrasound. Doppler ultrasound was used to assess devascularization, with reduction or absence of intralesional flow considered a surrogate marker of procedural completeness. Symptoms and fibroid characteristics were recorded at baseline and at 1, 3, 6 and 12 months post-procedure.

Results

Ninety-six women underwent TV-RFA with treatment of 144 fibroids (procedures: June 2024–December 2025). Mean age was 43.0 ± 5.4 years (range 26–54) and mean BMI 26.4 ± 4.5 kg/m² (range 17.1–37.9). Patients had a mean 1.5 fibroid (range 1–3.): 61 (63.5%) had a single fibroid, 22 (22.9%) two and 13 (13.5%) three. The mean largest diameter of treated fibroids was 4.8 ± 2.2 cm (range 1.5–12.2). Size distribution was <3 cm 29/144 (20.1%); 3–<5 cm 52/144 (36.1%); 5–<7 cm 38/144 (26.4%); ≥7 cm 25/144 (17.4%). According to FIGO classification, treated lesions were predominantly intramural and subserosal (type 2, n=7; type 3, n=31; type 4, n=35; type 5, n=50; type 6, n=6; mixed 2–5, n=15). The most common anatomical locations were anterior (60/144) and posterior (55/144), followed by fundal (12), lateral (9) and isthmic (7). Baseline menorrhagia was reported by 66/96 patients (68.8%).
Peri-procedural complications were limited and managed conservatively (postoperative pain n=2; fever n=3). With staggered enrolment, follow-up data were available for 96 patients at 1 and 3 months, 88 at 6 months and 54 at 12 months. Among patients with baseline menorrhagia and an evaluable visit, the symptom resolved in 55/66 (83.3%) at 3 months, 51/60 (85%) at 6 months and 29/35 (82.9%) at 12 months.

Conclusions

TV-RFA with the Myoblate system produced a rapid and durable reduction in menorrhagia, and favourable safety profile, supporting its role as a uterus-sparing option for symptomatic uterine fibroids across a broad spectrum of sizes and FIGO types.

ESGE35-0544 -
Free Communication

Association between uterine fibroids and endometriosis: a retrospective cohort study

Plamena Kirova[1], Elitsa Valerieva[1], Aleksandar Boyadzhiev[1], Nadya Magunska[1]
[1]Shterev Hospital, Gynecologic endoscopy, Sofia, Bulgaria

Background

Endometriosis and uterine fibroids are the two most common gynecological conditions affecting quality of life and uterine function, and both share estrogen-related pathogenic pathways. Their symptoms may overlap, making diagnosis challenging and potentially delaying appropriate management. Additionally, both conditions may contribute to subfertility.

Methods

This retrospective cohort study included 345 patients who underwent laparoscopic conservative or radical surgery for symptomatic leiomyoma between January 2020 and December 2024 at the Department of Gynecologic Endoscopy. Surgical and histopathological records were analysed for the presence of endometriosis and histological confirmation.

Inclusion criteria were the presence of one or more leiomyomas associated with abnormal uterine bleeding, pelvic pain, or infertility. All patients underwent preoperative ultrasound examination performed by an experienced ultrasound specialist, including detailed mapping of leiomyomas and assessment for concomitant pelvic pathology.

Exclusion criteria included age over 50 years at the time of surgery, absence of a detailed preoperative pelvic ultrasound examination, and histopathological findings not confirming leiomyoma.

Results

The mean age of the cohort was 40.8 years, and 106 out of 345 patients presented with infertility. Intraoperative findings revealed the presence of endometriosis in 31.0% of patients (107/345), with histological confirmation in 98 cases. The prevalence of endometriosis in the infertility subgroup was similar to that of the overall cohort, accounting for 31.1% (33/106) of patients.

When patients were stratified according to the type of endometriosis, our data demonstrated sensitivity of 88% and specificity of 97% when the central compartment was involved. Similar results were found in case of adenomyosis. Involvement of the posterior compartments demonstrated high specificity but substantially lower sensitivity, with specificity rates of 97.9% for compartment A and 96.1% for compartment B, while sensitivity rates were 27.3% and 33.3%, respectively. Superficial endometriosis did not demonstrate significant diagnostic detectability in this cohort.

Age distribution analysis demonstrated a trend toward decreasing coexistence of both conditions with increasing age. A statistically significant difference was observed only between the 20–30 and 45–50 year age groups.

Conclusions

Patients with symptomatic uterine fibroids requiring surgery appear to have a high prevalence of concomitant endometriosis, particularly at younger age. During fibroid surgery, surgeons should actively inspect for endometriotic lesions and recognize that treatment of only one condition may not adequately address patient symptoms or fertility concerns. Particular attention should be paid to deep infiltrating endometriosis in the posterior compartments, as distortion of pelvic anatomy by fibroids may reduce preoperative diagnostic accuracy. Further research into the shared pathogenic mechanisms of these diseases may facilitate integrated and causative therapeutic approaches to improve women's health.

ESGE35-0582 -
Free Communication

Radiofrequency fibroid ablation: pilot study.

Ján Varga[1], Silvia Vernerová[2], Natalia Milczarska[2], Miroslava Vargová[2], Ladislav Rosocha[2]
[1]L. P. University Hospital and P.J.Š. University Medical Faculty, Dep. of Gynaecology and obstetrics, Košice, Slovakia
[2]L.P. University Hospital, Gynecology and obstetrics, Košice, Slovakia

Background

Uterine fibroids represent the most common benign tumours of the female reproductive system. the wide spectrum of therapeutic modalities in their treatment results in the need for individualized patient management. radiofrequency ablation is an innovative, minimally invasive method for the treatment of uterine fibroids. based on the principle of sonographically guided hyperthermic ablation, the tissue remodelling occurs resulting in its reduction.

Objective

The primary aim was to assess the effectiveness of radiofrequency fibroid ablation in symptoms reduction and improvement in quality of life. secondary objectives included assessment of vascularity and volume changes in fibroids after radiofrequency fibroid ablation. in addition, the safety of the method was also assessed.

Methods

118 patients with 145 treated leiomyomas were included into study. symptoms and quality of life were assessed by usage of uterine fibroid symptoms & health-related quality of life questionnaire. expertise ultrasonography was used for detection of changes in vascularisation as well as volume of fibroids. the parameters were assessed before radiofrequency fibroid ablation and in different time after ablation (1, 3, 6, 9, 12 months).

Results

Symptoms reduction was after procedure seen and significant improvement in quality of life was observed even 1 months after surgery. reduction in fibroid vascularity was followed by reduction in fibroids volume. there were no severe complications, and fast recovery time was observed.

Conclusions

Radiofrequency fibroid ablation is promising method for symptoms improvement in selected group of the patients.

ESGE35-0664 -
Free Communication

Selective Clamping of Uterine Arteries in Robot-Assisted Myomectomy: A prospective observational cohort study.

Perrine Capmas[1], *Saskia Venverloo*[2], *Celia Maheut*[3], *Camille Lemaire Tomczak*[4], *Constance Maudot*[4]
[1]*AP-HP- GHU-Paris Saclay- Hospital Bicêtre, Gynaecology and Obstetrics Department, Le Kremlin Bicetre, France*
[2]*AP-HP- GHU - Paris Saclay- Hospital Bicêtre, Department of Gynaecology and Obstetrics, Le Kremlin Bicêtre-, France*
[3]*APHP- CHU Bicetre- GHU - Paris Saclay, Department of Gynaecology and Obstetrics, Le Kremlin Bicêtre-, France*
[4]*APHP- CHU Bicetre- GHU Paris Saclay, Department of Gynaecology and Obstetrics, Le Kremlin Bicetre, France*

Background

Over the last decades, the advent of minimally invasive techniques has shifted practice toward laparoscopic myomectomy; more recently, robotic-assisted myomectomy has expanded the indications for minimally invasive management to include more and larger leiomyomas that were traditionally considered unsuitable for conventional laparoscopy. Intraoperative bleeding, however, remains a major technical challenge of myomectomy and represents the cornerstone of perioperative morbidity.
Aim of this study is to assess whether selective clamping of the uterine arteries with bulldog clamps during robotic-assisted laparoscopic myomectomy reduces intraoperative bleeding, transfusion rate and comparison of haemoglobin rate before and after surgery compared with procedures performed without clamping.

Methods

This prospective before/after observational cohort study included all consecutive women undergoing robotic assisted laparoscopic myomectomy for symptomatic leiomyomas (abnormal uterine bleeding, pelvic pain, or bulk symptoms) excluding type 7 in a teaching hospital between January 2021 and October 2025.Women who underwent surgery between January 2021 and February 2023 benefited of standard robotic assisted myomectomy (SRAM), while those who underwent surgery between March 2023 and October 2025 after implementation of artery clipping strategy were managed by robotic-assisted myomectomy using bulldogs clamps (RAM-B). Outcomes were compared between the two periods using a before–after comparative design. The study was approved by the national ethics committee for obstetrics and gynaecology (CEROG 2023-GYN-1110).For continuous variables, comparisons were performed using Student's t-test or the Mann–Whitney U test for non-parametric variables. For categorial variables, comparisons were performed using chi-square or Fisher's exact tests. A two-sided p-value < 0.05 was considered statistically significant. Statistical analysis was conducted using R-V2024.12.0.

Results

A total of 75 women were included between 2021 and 2025; 37 (50%) between Jan 2021 and Feb 2023 underwent standard robotic assisted myomectomy (SRAM) and 38 (50%) between March 2023 and Oct 2025 underwent robotic-assisted myomectomy using bulldogs clamps (RAM-B) Baseline characteristics were comparable between groups. Leiomyoma burden was slightly higher in the RAM-B group, with larger first leiomyoma (median 90 mm vs 74 mm), second leiomyoma (44 mm vs 40 mm), and third leiomyoma (50 mm vs 34 mm). Regarding the measured outcomes, estimated blood loss during surgery were comparable between groups while women in the RAM-B group lost a median of 1.4 g/dl haemoglobin [-2.48 ; -0.3] versus 2 [-2.9 ; -1.5] in the SRAM group with a significant difference (p=0.004). There were significantly more transfusions in the SRAM group (16/37 vs 1/38, p=0.003). Length of surgery was significantly longer in the RAM-B group (166 vs 130 min, p=0.017). The number and type of complications were comparable between groups.

Conclusions

This study highlights potential benefits of selective temporary vascular occlusion to prevent decrease in haemoglobin following robot-assisted myomectomy. Our results should be confirmed by a prospective randomized study.

ESGE35-0690 -
Free Communication

Clinical and sonographic features of atypical myometrial lesions in a five year surgical cohort: histopathological correlation between selectively performed core needle biopsy and final surgery

Michal Mara[1], Kristyna Hlinecka[1], Veronika Vaisova[1], Adela Kolek[1], Pavel Dundr[2], Zdenka Lisa[1]
[1]Department of Gynecology- Obstetrics and Neonatology- First Faculty of Medicine- Charles University - General University Hospital, Minimally Invasive Gynecology Surgery, Prague, Czech Republic
[2]First Faculty of Medicine- Charles University and General University Hospital, Department of Pathology, Prague, Czech Republic

Background

The objective of this work is to characterize the clinical and sonographic features of surgically treated myometrial lesions in a five-year cohort, to correlate ultrasound findings with final surgical histopathology, and to evaluate the role of selective ultrasound-guided core needle biopsy (CNB) in sonographically atypical cases.

Methods

This was a prospective single-center cohort study conducted between the years 2020 and 2024 and approved by IRB. All patients with uterus preserving surgery (myomectomy or adenomyosis resection) or hysterectomy for "myoma-like" myometrial lesions at a tertiary referral center, and signed informed consent with the study participation, were enrolled. Clinical characteristics and standardized preoperative ultrasound features were prospectively recorded and correlated with final surgical histopathology, which served as the reference standard. During the last study year, ultrasound-guided CNB was selectively performed in women with sonographically atypical myometrial lesions. In this nested biopsy subgroup, CNB findings were compared with final histopathology to assess histological concordance and diagnostic performance for malignancy. Ultrasound predictors associated with malignant histopathology were also evaluated. This work was supported by the Ministry of Health of the Czech Republic, grant number NW26-03-00271 (AZV), grant number NU23-06-00327 (AZV), and by Charles University in Prague (UNCE/24/MED/018).

Results

Out of 2367 uterine surgeries ten cases of myometrial malignancies were confirmed by final histopathology (0.4%). Among women who underwent CNB and subsequent surgery, 79 cases were available for histological comparison. Concordance between CNB and final surgical histopathology was achieved in 68 cases, corresponding to an overall concordance rate of 86.1%. For differentiating malignant from non-malignant lesions, CNB demonstrated a sensitivity of 66.7% and a specificity of 100%. Malignancy was confirmed in three women; CNB correctly identified two malignant cases, whereas one malignancy was not diagnosed preoperatively because of insufficient/non-representative sampling. In the analysis of ultrasound predictors, subjective sonographic suspicion of malignancy was the only independent predictor of malignant histopathology (OR, 41.16; 95 % CI, 1.14–1483.73; P = 0.042). These findings are currently being further evaluated in an ongoing

prospective multicentre validation study MYSTR enrolling 250 women with sonographically atypical myometrial lesions.

Conclusions

In this five-year surgical cohort, standardized ultrasound assessment enabled structured preoperative characterization of myometrial lesions and identification of cases with atypical features. In sonographically atypical lesions, selective ultrasound-guided CNB provided valuable additional preoperative histological information when interpreted together with expert ultrasound assessment. This combined approach may improve preoperative risk stratification and clinical decision-making in women undergoing surgery for myometrial lesions but needs further validation.

ESGE35-0705 -
Free Communication

Temporary uterine artery ligation in minimally invasive myomectomy: should it be routine?

Mehmet Tunç Canda[1]
[1]*Medicana International Izmir Hospital, Obstetrics & Gynecology, Izmir, Türkiye*

Background

Intraoperative bleeding control is a critical determinant of surgical outcomes in minimally invasive myomectomy. Although local infiltration of vasoconstrictors like vasopressin is widely utilized to reduce bleeding, it carries significant risks of severe systemic adverse effects, including profound bradycardia, cardiovascular collapse, and acute pulmonary edema. This study aims to evaluate the efficacy, safety, and surgical advantages of temporary uterine artery ligation (TUAL) using a mechanical approach with bulldog clamps during laparoscopic and robotic-assisted myomectomies.

Methods

A retrospective analysis was conducted on patients who underwent minimally invasive myomectomy with or without TUAL at our institution between January 2024 and January 2026. Thirty cases of myomectomy without TUAL were compared with thirty cases involving TUAL. In the intervention group, TUAL was performed bilaterally before myomectomy. Intraoperative blood loss, pre- and post-operative haemoglobin (Hb) and haematocrit (Hct) levels, total operative time associated with the TUAL procedure, postoperative discharge time, myoma weight, and any perioperative complications were evaluated. The results were also compared with current literature in relation to standard vasoconstrictor administration.

Results

A total of 60 patients were analysed (30 in the TUAL group and 30 in the control group). There was no significant difference between the groups regarding mean myoma weight (176.33 ± 46.50 g vs. 174.67 ± 47.90 g, respectively; p= 0.893). The mean postoperative haemoglobin (Hb) decline (1.00 ± 0.00 g/dL vs. 2.50 ± 0.51 g/dL) and haematocrit (Hct) decline (4.50 ± 0.51% vs. 8.90 ± 0.84 %) were significantly lower in the TUAL group compared to the control group (both p< 0.001). Additionally, the mean operative time was significantly shorter in the TUAL group than in the control group (101.67 ± 17.63 min. vs. 116.67 ±17.63 min, respectively; p = 0.002). No systemic hemodynamic instability, cardiovascular adverse events, or complications related to mechanical occlusion were observed in either group. All patients in both groups were successfully discharged on the first postoperative day.

Conclusions

Temporary uterine artery ligation is a highly effective, safe, and reproducible technique that provides excellent perioperative outcomes regardless of myoma weight in laparoscopic and robotic myomectomy. By providing a bloodless field, it optimizes surgical visualization and facilitates precise uterine suturing. Rather than prolonging the operative time, our data statistically confirms the TUAL procedure accelerates myoma dissection, enucleation, and suturing phases by effectively minimizing blood loss. Furthermore, it eliminates the unpredictable and potentially life-threatening systemic

risks associated with pharmacological vasoconstrictors. Given its significant clinical advantages in patient and surgeon safety, this mechanical approach warrants consideration as a routine step in minimally invasive myomectomy.

ESGE35-0764 -
Free Communication

Total laparoscopic hysterectomy for large uteri: perioperative outcomes, complications, and vaginal morcellation requirement (TR-MIGS study)

Elif Cetinkaya[1], Filiz Gokce Ikibudak[1], Asli Akdoner[1], Onur Yavuz[1], Mehmet Guney[1]
[1]Dokuz Eylul University Faculty of Medicine, Department of Obstetrics and Gynecology, Izmir, Türkiye

Background

Total laparoscopic hysterectomy (TLH) for large uteri is technically demanding due to restricted workspace and altered anatomy. This study aims to evaluate perioperative outcomes and the feasibility of vaginal morcellation in complex cases managed within a tertiary referral university hospital.

Methods

In this retrospective study, 49 high-difficulty cases were specifically selected from a total institutional cohort of 750 laparoscopic hysterectomies performed at Dokuz Eylul University. Inclusion criteria focused on uteri weighing ≥300g and patients with challenging clinical profiles, such as extensive previous surgical histories. Data regarding demographics, intraoperative findings, and complications were analysed using SPSS software.

Results

A total of 49 patients who underwent total laparoscopic hysterectomy for large uteri were included in the study. The median age was 50 years (40–68). Forty patients (81.6%) were premenopausal, while 9 patients (18.4%) were postmenopausal. Most patients were multiparous (95.9%), and 55.1% had a history of previous abdominopelvic surgery.

The median uterine weight was 434 g (307–1253). Vaginal morcellation was required in 43 patients (87.8%). Median operative time was 75 minutes (30–240). Median preoperative haemoglobin level was 12.4 g/dL (8.7–15), whereas postoperative haemoglobin level was 11.7 g/dL (7.9–14.5). Blood transfusion was required in 5 patients (10.2%). Median length of hospital stay was 2 days (1–8).

Regarding perioperative complications, vaginal/perineal laceration occurred in 6 patients (12.2%). Urinary tract injury was observed in 5 patients (10.2%), including 4 bladder injuries (8.2%) and 1

ureteral injury (2%).



Conclusions

TLH is a viable and efficient approach for large uteri, even in a high-risk patient population. While the complication rates, particularly urinary tract injuries, may appear higher than standard laparoscopic series in the literature, this must be interpreted within the context of our status as a tertiary referral center. Our cohort specifically represents "difficult-to-treat" cases, characterized by a very high prevalence of previous abdominopelvic surgeries (55.1%), which significantly distorts pelvic anatomy and increases surgical complexity. Despite these challenges, advanced laparoscopic expertise allows for favourable operative times and rapid recovery, with vaginal morcellation serving as a safe alternative to Mini laparotomy.

ESGE35-0992 -
Free Communication

Surgical management of necrotic uterine fibroids in early pregnancy for pregnancy preservation: two case reports

Shayman Gadimova[1], *Nargiz Shamsadinskaya*[1]
[1]*Azerbaijan Medical University, Obstetrics and Gynaecology, Baku, Azerbaijan*

Background

Uterine fibroids are the most common benign tumors of the female reproductive system and are detected in approximately 1–10% of pregnancies. Although most fibroids remain asymptomatic during gestation, degeneration and necrosis may occur due to impaired blood supply, resulting in severe abdominal pain and potential risks for pregnancy continuation. The optimal management of symptomatic necrotic fibroids during pregnancy remains controversial because of concerns regarding miscarriage, hemorrhage, and other obstetric complications.
To evaluate the effectiveness of surgical management for pregnancy preservation in two patients presenting with symptomatic necrotic uterine fibroids during the first trimester of pregnancy.

Methods

Two primigravid women were admitted with severe persistent lower abdominal and suprapubic pain during early pregnancy. The first patient was 29 years old at 12 weeks and 3 days of gestation. The second patient was 33 years old at 12 weeks and 4 days of gestation. Both had previously received conservative outpatient treatment consisting of antispasmodic and hormonal therapy without clinical improvement. Ultrasonography was performed to assess pregnancy viability and characterize the uterine masses.

Results

Ultrasound examination confirmed viable singleton intrauterine pregnancies in both patients. In the first case, a pedunculated fibroid measuring 50 × 45 mm with a subserosal–intramural component was identified and classified as FIGO type 5. Due to persistent severe pain and failure of conservative management, the patient underwent laparoscopic myomectomy under general anesthesia. In the second case, a necrotic subserosal–intramural fibroid measuring approximately 6 cm was detected and classified as FIGO type 5. Given the larger size of the lesion and ongoing symptoms refractory to conservative therapy, laparotomic myomectomy was performed under general anesthesia. Histopathological examination confirmed degenerative and necrotic leiomyoma. No intraoperative or postoperative complications occurred. Pregnancy was successfully preserved in both patients, and follow-up demonstrated continued foetal viability and normal pregnancy progression.

Conclusions

Myomectomy during the first trimester is rarely performed because of concerns regarding foetal loss and perioperative complications. These cases demonstrate that when conservative treatment fails, surgical intervention may be considered in carefully selected patients with symptomatic FIGO type 5

fibroids complicated by degeneration or necrosis. Both laparoscopic and laparotomic approaches can be successfully applied, resulting in symptom relief and preservation of pregnancy.

ESGE35-0380 -
Free Communication

Taming bleeding at the source: single-port myomectomy with uterine artery bulldog clamping

Leonardo Nelva Stelio[1], Carmela Quatrale[1], Luca Calzolari[1], Federica Ottolini[1], Federico Spelzini[1]
[1]ASST Grande Ospedale Metropolitano Niguarda, OB/GYN, Milan, Italy

Background

Minimally invasive surgery continues to evolve toward reducing surgical trauma while maintaining efficacy. Robotic single-port (SP) platforms represent the latest step in this progression. This study aims to evaluate the feasibility and safety of robotic SP myomectomy using the Da Vinci SP system for the treatment of multiple uterine fibroids.

Methods

A robotic single-port myomectomy was performed in a healthy woman with no prior surgical history, presenting with symptomatic uterine fibroids causing compressive symptoms. Surgery was conducted through a single 3 cm trans-umbilical incision using the Da Vinci SP system. Two FIGO type 6 fibroids measuring 7 cm and 5 cm were enucleated. Temporary vascular control was achieved by bilateral clamping of the uterine arteries at their origin and the utero-ovarian vessels using bulldog clamps. Operative time, estimated blood loss, perioperative outcomes, and length of hospital stay were recorded.

Results

Total operative time was 100 minutes. Estimated blood loss was less than 100 mL. No intraoperative or postoperative complications occurred. Both fibroids were successfully enucleated, and adequate myometrial reconstruction was achieved. The postoperative course was uneventful, and the patient was discharged on postoperative day two.

Conclusions

Robotic single-port myomectomy using the Da Vinci SP system is a safe and feasible technique for selected patients with multiple intramural-subserosal fibroids. Temporary vascular control may significantly reduce intraoperative blood loss. This approach combines surgical precision with minimal invasiveness, offering potential advantages in postoperative recovery and cosmetic outcomes, and represents a forward step in the evolution of gynecologic minimally invasive surgery.

https://player.vimeo.com/video/1191569903?autoplay=1

ESGE35-0909 -
Free Communication

Mini-laparotomic specimen extraction using a wound retractor system in minimally invasive gynecologic surgery: surgical technique and additional applications

Grzegorz Ziolkowski[1], Agata Mandes[2], Michal Kostrzanowski[2], Filip Karuga[2], Grzegorz Panek[2], Filip Dabrowski[2]
[1]Medical Centre of Postgraduate Medical Education CMKP- Bielanski Hospital Warsaw- Poland, Gynecology and Gynaecological Oncology, Warszawa, Poland
[2]Medical Centre of Postgraduate Medical Education CMKP- Bielanski Hospital Warsaw- Poland, Gynecology and Gynaecological Oncology, Warsaw, Poland

Background

Minimally invasive gynecologic surgery requires safe and effective techniques for extraction of large uterine fibroids and enlarged uteri while preserving the advantages of laparoscopy. Concerns regarding tissue dissemination during uncontained morcellation, particularly in cases of occult uterine sarcoma, have increased interest in contained extraction methods. Wound retractor systems may facilitate atraumatic specimen retrieval, improve wound protection, and potentially shorten extraction time for large specimens. The video additionally demonstrates the application of the same device during bowel stoma creation.

Methods

This surgical video presents step-by-step laparoscopic specimen extraction through a small abdominal incision using a wound retractor/protector system. Following laparoscopic hysterectomy or myomectomy, the specimen is placed into a containment bag and extracted through the mini-laparotomy incision. The wound retractor facilitates atraumatic dilation of the incision, improves visualization, protects wound edges, and enables controlled manual morcellation when required. The video additionally demonstrates the use of the device during bowel stoma formation. Relevant literature regarding the risk of occult uterine sarcoma dissemination during morcellation is reviewed.

Results

The wound retractor system enabled safe and reproducible extraction of large specimens while preserving the advantages of minimally invasive surgery. The technique provided stable exposure of the incision, circumferential wound protection, and facilitated controlled tissue extraction with reduced contamination of wound edges. When combined with contained morcellation, the approach may reduce the theoretical risk of intraperitoneal tissue dissemination associated with uncontained morcellation. Compared with conventional electromechanical morcellation, the described technique may additionally shorten extraction and morcellation time, particularly for large specimens. The additional use during bowel stoma creation demonstrated improved atraumatic exposure and abdominal wall protection.

Conclusions

Mini-laparotomic specimen extraction using a wound retractor system is a simple, versatile, and reproducible technique facilitating safe removal of large gynecologic specimens during laparoscopic surgery. The method combines wound protection, improved exposure, compatibility with contained morcellation, and potentially shorter extraction time while maintaining minimally invasive surgical principles. The wound retractor may also provide additional benefits in other abdominal procedures, including bowel stoma formation.

https://player.vimeo.com/video/1195750729?autoplay=1

ESGE35-0032 -
Free Communication

Antiadhesion gel versus no gel following operative hysteroscopy prior to subsequent fertility treatment or timed intercourse (AGNOHSTIC): a double blinded randomized controlled trial.

Steffi Van Wessel[1], *Valerie Schutyser*[2], *Jan Bosteels*[3], *Steven Weyers*[1]
[1]*Ghent University Hospital, Department of Gynaecology, Ghent, Belgium*
[2]*Heilig Hart Ziekenhuis, Leuven Institute for Fertility and Embryology, Leuven, Belgium*
[3]*Imelda Hospital, Department of Gynecology, Bonheiden, Belgium*

Background

Intrauterine adhesions (IUAs) after operative hysteroscopy can compromise fertility. While antiadhesion gels may reduce the formation of IUAs, current evidence for their impact on reproductive outcomes is limited. We aimed to investigate the effectiveness of auto-crosslinked hyaluronic acid (HA) gel following operative hysteroscopy on reproductive outcomes.

Methods

We performed a double-blind randomized controlled trial in nine canters in Belgium. Women of reproductive age (18–47 years) wishing to conceive and scheduled for operative hysteroscopy to treat intrauterine pathology were eligible. After informed consent, women were randomized in a 1:1 allocation ratio to receive auto-crosslinked HA gel or no gel. Randomization was performed by the study coordinator between 1 day and 1 hour prior to surgery using computer-generated random permuted blocks of variable sizes. Stratification was applied based on study center and type of pathology. Sterile ultrasound gel was inserted into the vagina to mask participants and outcome assessors in both groups. The primary outcome was conception within 30 weeks after randomization leading to live birth. Primary analyses were by intention to treat. The secondary outcomes were time to conception, clinical pregnancy rates, adverse pregnancy outcome (a composite outcome based on the individual outcomes miscarriage, ectopic pregnancy, pre-eclampsia, preterm birth, stillbirth, low/very low birth weight, caesarean section and neonatal complications) and intrauterine adhesion rate 30 weeks after receiving allocated treatment.
(Clinicaltrials.gov NCT03880435).

Results

From April 2019 to December 2023, 417 patients were randomized to either receive an auto-crosslinked HA gel or not. Conception within 30 weeks after randomization leading to live birth occurred in 33·0% (63/191) in the intervention group and 32·3% (64/198) in the control group (difference 0·6% [95%CI: -8·6% to 9·4%]).

The estimated average hazard ratio for time to conception leading to live birth since receiving treatment was 0·98 [95%CI: 0·68 to 1·42]. Clinical pregnancy rates within 30 weeks after receiving treatment were comparable: 47·7% (92/193) in the intervention group and 45·0% (90/200) in the control group with an estimated difference of 1·9% [95%CI -7·4% to 11·4%]. Adverse pregnancy outcome was observed in 44 out of 175 (25·1%) participants in the intervention group and 43 out of 188 participants (22·9%) in the control group with an estimated difference of 1·12% [95%CI: -7·14 to

9·3%]. The incidence of de novo intrauterine adhesions observed at 30 weeks second-look hysteroscopy in women who were known not to conceive a pregnancy resulting in live birth during the follow-up period was 12.7% (7 out of 55) in the intervention group and 7.7% (five out of 65) in the control group.

Conclusions

In women wishing to conceive undergoing operative hysteroscopy, auto-crosslinked HA gel does not increase live birth rates.

ESGE35-0411 -
Free Communication

Office hysteroscopic bipolar and mechanical polypectomy for obese patients with high ASA risk

Antonio Accardi[1]
[1]*Ospedale G. F. Ingrassia- ASP 6 Palermo, Obstetrics and Gynaecology, Palermo, Italy*

Background

To validate the safety, efficacy, and feasibility of office hysteroscopic polypectomy performing both mechanical and bipolar surgeries in high-risk patients with a BMI >30 and/or ASA score ≥3. Secondary endpoints include patient satisfaction, operating room (OR) admission rates, and surgical/anaesthesiologic risks.

Methods

This prospective observational study (January 2021–January 2026) enrolled 324 women with a BMI >30 scheduled for office hysteroscopy. The cohort included postmenopausal and reproductive-age women presenting with a single endometrial polyp (≤1.4 cm) and/or additional smaller endometrial/cervical polyps. Discomfort was measured via a validated Pain Rating Scale, and baseline ASA risk via anaesthesiologic consultation. Exclusion criteria included suspected malignancies, intrauterine adhesions, or outpatient procedure contraindications. Institutional board approval and written informed consent were obtained.
Procedures followed a "See and Treat" approach under direct vision, without cervical dilation or pharmacological analgesia. A 5-mm continuous-flow operative hysteroscope with saline distension media was used. The surgical technique combined a 5 Fr. office bipolar electrode with rotating mechanical scissors and forceps The core advantage of these mechanical instruments is their continuous 360-degree longitudinal rotation via a handle-integrated wheel, facilitating the complete, en-bloc excision of bulky polyps at their base (the 'Accardi's technique').

Results

Successful polyp removal during the initial office session was achieved in 280/324 patients (86.4%). Procedures were deferred in 26 patients (7.9%) due to suspected malignancy, while 18 patients (5.3%) required OR admission for pain management or challenging polyp localizations. Within the successfully treated cohort, 175 patients (62.5%) presented with a complex profile (BMI >35 and ASA 3 score), and 17 of these were virgo. Patients were discharged after approximately one hour without any major intraoperative or postoperative complications. The one-year recurrence rate was 2.9%, observed exclusively in the mechanically treated cohort.

Conclusions

Combining rotating mechanical instruments and bipolar energy makes office hysteroscopic polypectomy a safe, highly effective, and cost-efficient option for obese women with high ASA scores. By circumventing general anesthesia, this technique avoids the increased perioperative morbidity and mortality historically associated with this high-risk population. Demonstrating high feasibility, excellent patient satisfaction, and a negligible complication profile, this minimally invasive,

anesthesia-free approach optimizes healthcare accessibility and clinical outcomes amidst the rising global prevalence of obesity-associated endometrial pathology.

ESGE35-0526 -
Free Communication

Factors influencing pain perception in patients undergoing office hysteroscopy: a retrospective analysis

Gregor Prša[1], Branka Žegura Andrić[1]
[1]University Medical Centre Maribor,
Department of General Gynaecology and Urogynaecology- Clinic for Gynaecology and Perinatology, Maribor, Slovenia

Background

Office hysteroscopy is the gold standard for the diagnosis and treatment of intrauterine pathology. Although it is considered a safe and well-tolerated procedure, pain remains a significant limiting factor. The aim of this study was to determine the influence of patient age, previous deliveries, length of the procedure, and used instruments on subjective pain scores using the Visual Analogue Scale (VAS).

Methods

In this retrospective study, we included women who were treated with office hysteroscopy at our gynaecology clinic for diagnostic hysteroscopy or various intrauterine pathologies. We included patients from year 2004 to 2026. For each patient, the following data were obtained: age, postmenopausal status, satisfaction with procedure, VAS score, type of instrument, usage of analgesics, duration of procedure, parity, type of delivery, and indication for the procedure. IRB approval was obtained for this study.

Data were analysed using SPSS Statistics Programme. Descriptive statistics were calculated on basic patients' characteristics. Data were analysed using bivariate non-parametric tests (Spearman correlation, Mann-Whitney U test) and multiple linear regression to identify independent predictors of pain. Statistical significance was set at $p<0.05$.

Results

Three thousand ninety-two women were included in the study. The average age was 48 years (SD = 13,4). The procedure was well-tolerated with mean VAS score of 2.18 ± 1.9. Analysis showed significantly higher VAS scores in postmenopausal compared to premenopausal patients (2.53 vs. 1.83; $p < 0.001$). Nulliparous patients had also significantly higher VAS scores compared to those, who gave birth at least once in their lifetime (2.38 vs. 2.10; $p < 0.001$). Higher VAS scores significantly correlated with longer procedural duration ($p < 0.001$). Interestingly, patients who received analgesics reported higher VAS scores (3.15 vs. 2.07; $p < 0.001$). The presence of a uterine septum resulted in statistically significant higher pain scores ($p < 0.001$). The presence of endometrial polyp or myoma resulted in higher VAS scores, however not statistically significant. Polyp and myoma size have not contributed to higher VAS. The multivariate regression model ($F = 84.15$; $p < 0.001$) confirmed postmenopausal status, nulliparity, and longer procedural duration as key independent risk factors for higher pain levels. When controlling for these confounding variables, the use of modern instrumentation significantly and independently reduced VAS scores: the Truclear system by 0.77

points ($p < 0.001$) and the Bettochi system by 0.19 points ($p = 0.035$). Usage of bipolar needle during procedure also resulted in significantly higher VAS.

Conclusions

Office hysteroscopy is a well-tolerated procedure. Nulliparous and postmenopausal patients, particularly during longer procedures, represent a high-risk group for experiencing greater pain, necessitating a tailored approach. The use of optical systems such as Truclear and Bettochi significantly reduces pain levels under controlled conditions and substantially contributes to improved patient comfort.

ESGE35-0739 -
Free Communication

Hysteroscopic treatment as primary management of non-tubal ectopic pregnancy: a systematic review

Giulia Di Liello[1], *Valerio Alpini*[2], *Francesco Cecchieri*[2], *Eugenia Mantovani*[2], *Alessandro Arena*[2], *Paolo Casadio*[2]
[1]*IRCCS Azienda Ospedaliero-Universitaria di Bologna,*
Division of Gynaecology and Human Reproduction Physiopathology- Sant'orsola Hospital- University o f Bologna, Roma, Italy
[2]*IRCCS Azienda Ospedaliero-Universitaria di Bologna,*
Division of Gynaecology and Human Reproduction Physiopathology, Bologna, Italy

Background

To evaluate the efficacy and safety of hysteroscopic treatment as primary management for uterine non-tubal ectopic pregnancies, including caesarean scar, cervical, interstitial and intramural pregnancies.

Methods

A systematic review was conducted according to PRISMA guidelines and prospectively registered in PROSPERO. PubMed/MEDLINE, Scopus and CENTRAL were searched from database inception without date restrictions. Eligible studies included women with non-tubal ectopic pregnancy treated primarily with operative or resectoscopic hysteroscopy. Tubal ectopic pregnancies, hysteroscopy used only for diagnostic purposes and hysteroscopy performed after other primary treatments were excluded. Main outcomes included biochemical resolution, time to serum β-hCG negativization, perioperative complications and need for additional treatment.

Results

Twenty-one studies involving 380 patients were included in the qualitative synthesis. Caesarean scar pregnancy represented most cases (361/380; 95%), followed by interstitial (10/380 2.6%), cervical (8/380 2.1%), and intramural pregnancies (1/380 0.2%). Mean gestational age at diagnosis was 7.3 weeks, while mean initial serum β-hCG level was 33,214 IU/L, although substantial variability among studies was observed. Resectoscopic removal was the most frequently reported hysteroscopic technique and represented the primary approach in most caesarean scar and cervical pregnancies. Alternative hysteroscopic strategies included mechanical removal, hysteroscopic tissue removal systems and hysteroscopically guided methotrexate injection. In selected cases, adjunctive haemostatic measures such as intracervical vasopressin or pituitrin injection were used to reduce intraoperative bleeding risk. The mean time to β-hCG normalization was 29.1 days, with reported values ranging from 7 to 60 days according to pregnancy location, gestational age, and initial β-hCG levels. Mean intraoperative blood loss was 59 mL, ranging from 0 to 210 mL across studies. Overall, 24 complications were reported, corresponding to an estimated complication rate of 6.3%. The most frequently described complications were intraoperative bleeding and uterine perforation, while blood transfusion and reintervention were uncommon. Across the included studies, hysteroscopy allowed

direct visualization and targeted treatment of trophoblastic tissue while preserving uterine integrity. However, most available evidence derived from retrospective studies, case series and case reports, resulting in an overall moderate-to-high risk of bias and substantial heterogeneity in operative techniques and outcome reporting

Conclusions

Hysteroscopic management appears to be a feasible minimally invasive treatment option for carefully selected patients with uterine non-tubal ectopic pregnancy. Compared with blind evacuation procedures, hysteroscopy may offer improved procedural control through direct visualization of the implantation site, enabling targeted removal of trophoblastic tissue and selective hemostasis while minimizing uterine trauma. Nevertheless, hysteroscopic management should not be considered a single standardized procedure, as different operative techniques may present distinct advantages and limitations according to ectopic pregnancy location and characteristics. Further prospective and comparative studies are required to better define patient selection criteria, optimal hysteroscopic techniques and long-term reproductive outcomes.

ESGE35-0832 -
Free Communication

Mini-resectoscopy versus conventional hysteroscopic resectoscopy in congenital and acquired uterine anomalies: a systematic review

Francesca Bognanni[1], Erika Bettiol[2], Elisabetta D'Epifanio[2], Giulia Cristani[2], Paolo Casadio[3], Alessandro Arena[3]
[1]Department of Medical and Surgical Sciences DIMEC- University of Bologna / Gynaecology and Huma n Reproduction Physiopathology- IRCCS Azienda Ospedaliero-Universitaria di Bologna, Division of Gynaecology and Human Reproduction Physiopathology- IRCCS Azienda Ospedaliero-Universitaria di Bologna, Bologna, Italy
[2]Dipartimento di Scienze Mediche e Chirurgiche DIMEC - Università di Bologna / Ginecologia e Fisiopat ologia della Riproduzione Umana - IRCCS Azienda Ospedaliero-Universitaria di Bologna, Divisione di Ginecologia e Fisiopatologia della Riproduzione Umana - IRCCS Azienda Ospedaliero-Universitaria di Bologna, Bologna, Italy
[3]Ginecologia e Fisiopatologia della Riproduzione Umana - IRCCS Azienda Ospedaliero-Universitaria di Bologna, Divisione di Ginecologia e Fisiopatologia della Riproduzione Umana - IRCCS Azienda Ospedaliero-Universitaria di Bologna, Bologna, Italy

Background

Congenital and acquired uterine anomalies are important causes of infertility, recurrent pregnancy loss, abnormal uterine bleeding, chronic pelvic pain, and adverse obstetric outcomes. the most common of these affections are respectively the septate uterus and isthmocele. Hysteroscopic surgery is the gold standard for treating intrauterine anomalies, but conventional resectoscopes require significant cervical dilatation and operating-room settings, often leading to postoperative pain and increased risk of complications. recent technological advancements have introduced miniaturized resectoscopes (mini-resectoscopy) designed to reduce surgical trauma and improve patient tolerability, particularly in office-based settings. However, evidence comparing miniaturized systems with conventional resectoscopy remains heterogeneous and fragmented. The aim of this systematic review was therefore to evaluate the efficacy, safety, and reproductive outcomes of mini-resectoscopy compared with conventional hysteroscopic resectoscopy in women with congenital and acquired uterine anomalies.

Methods

This systematic review was conducted according to the preferred reporting Items for systematic reviews and meta-analyses (prisma 2020) guidelines. The review protocol was prospectively prepared for prosper registration before manuscript submission. A systematic literature search was conducted in PubMed, Scopus, Embase, and Cochrane Library from database inception to January 2026 using the following terms: “mini-resectoscopy,” “mini-resectoscope,” “office hysteroscopy,” “septate uterus,” “t-shaped uterus,” “isthmocele,” “metroplasty,” and “hysteroscopic resection.” Two reviewers independently screened titles, abstracts, and full-text studies for eligibility. only English-language studies involving human subjects were included. Furthermore, types of studies included were

comparative, retrospectives cohort and observational studies evaluating miniaturized hysteroscopic systems versus conventional resectoscopy for congenital or acquired uterine anomalies. On the contrary, narrative reviews, technical notes, video articles, and studies without extractable clinical outcomes were excluded. a total of 622 records were identified, 171 duplicates were removed using Rayyan software, and 81 full-text articles were assessed for eligibility. fourteen studies were included in the qualitative synthesis and seven in the quantitative comparative synthesis.

Results

Data extraction included efficacy and safety, perioperative complications, fluid absorption, postoperative pain, and reproductive outcomes. most studies focused on hysteroscopic treatment of septate uterus, whereas a smaller number evaluated hysteroscopic correction of isthmocele. the principal comparative evidence derived from studies evaluating mini-resectoscopy versus conventional hysteroscopic resectoscopy, bipolar versus monopolar systems, and small-diameter operative hysteroscopy versus standard resectoscopy. Mini-resectoscopy was consistently associated with shorter cervical dilatation time, lower postoperative pain, reduced fluid absorption, and fewer perioperative complications while maintaining comparable operative efficacy and reproductive outcomes relative to conventional resectoscopy. Bipolar systems additionally reduced electrolyte disturbances and hyponatremia risk. Formal pooled analysis was feasible, using random-effects models, for selected perioperative outcomes but limited for reproductive endpoints because of substantial heterogeneity among studies.

Conclusions

Mini-resectoscopy appears to be a safe and effective minimally invasive alternative to conventional hysteroscopic resectoscopy for congenital and acquired uterine anomalies, with improved perioperative outcomes and comparable reproductive efficacy.

ESGE35-0923 -
Free Communication

"The endometrial curtain": association between subtle hysteroscopic lesions and histologically confirmed adenomyosis in infertile women, a retrospective cohort study

Evy Gillet[1], Dounia El Khatiri[2], Helena Van Kerrebroeck[1], Stavros Karampelas[2], Marion Valkenburg[1], Rudi Campo[1]
[1]Life Expert Centre, Gynaecology, Leuven, Belgium
[2]CHU Brugmann, Gynaecology, Brussels, Belgium

Background

Adenomyosis is increasingly recognized as a contributor to infertility, recurrent implantation failure (RIF), and recurrent pregnancy loss (RPL). Although the Morphological Uterus Sonographic Assessment (MUSA) criteria have improved ultrasound-based diagnosis, correlations between hysteroscopic abnormalities, MUSA findings, and histologically confirmed adenomyosis remain insufficiently investigated. This study evaluated the association between subtle hysteroscopic abnormalities and histologically confirmed adenomyosis in infertile women.

Methods

This retrospective single-centre cohort study included infertile women evaluated at the Life Expert Centre (LEC), Leuven, Belgium, between January 2024 and December 2025. All patients underwent standardized multimodal uterine assessment including MUSA-based transvaginal ultrasound (TVUS), office hysteroscopy, and targeted endo-myometrial biopsy. Hysteroscopic abnormalities were classified into five phenotypic categories: cavity dysmorphism, endometrial surface changes, vascular changes, inflammatory changes, and adhesive changes. Histopathological confirmation served as the reference standard for adenomyosis diagnosis.

Results

Among 443 women assessed for eligibility, 408 met the inclusion criteria. Subtle hysteroscopic abnormalities were highly prevalent, with only 4.4% of patients demonstrating no abnormalities. Cavity dysmorphism represented the most prevalent hysteroscopic phenotype. Histologically confirmed adenomyosis was highly prevalent across all infertility subgroups. In women presenting direct MUSA signs, adenomyosis was histologically confirmed in 95% of cases. Endometrial surface changes demonstrated the highest prevalence of underlying adenomyosis, with histopathological confirmation in 98% of affected patients. Importantly, adenomyosis remained highly prevalent in women without direct MUSA signs (82%) and was still identified in 74% of patients without either direct or indirect sonographic signs.

Conclusions

Subtle hysteroscopic abnormalities are highly prevalent in infertile women and frequently associated with histologically confirmed adenomyosis. These findings support the concept that adenomyosis-associated reproductive dysfunction may manifest through a broader spectrum of endometrial–myometrial interface and junctional zone (JZ) remodelling. Hysteroscopy may provide complementary

information within a multimodal uterine assessment strategy, particularly in women without overt sonographic abnormalities.

ESGE35-0449 -
Free Communication

Interstitial pregnancy laparoscopic management

Berk Guzelbakan[1]
[1]*Darıca Farabi Research and Training Hospital, Gynecology and Obstetrics, Kocaeli, Türkiye*

Background

Interstitial pregnancies are uncommon, comprising approximately 1 to 3 percent of all ectopic pregnancies but potentially life-threatening form of ectopic pregnancies due to its high risk of severe hemorrhage. Early diagnosis and appropriate surgical management are critical to reduce morbidity and preserve fertility. This study aims to present the laparoscopic management of an interstitial pregnancy through a video case.

Methods

A patient diagnosed with interstitial pregnancy based on transvaginal, transabdominal ultrasonography and serum β-hCG levels underwent laparoscopic surgery. The procedure included identification of the ectopic gestational sac, salpingectomy wedge resection, and hemostasis using electrosurgical techniques. Key surgical steps and intraoperative findings were recorded and presented in a structured video format.

Results

Laparoscopic management was successfully completed without conversion to laparotomy. Effective hemostasis was achieved, and the patient had an uneventful postoperative recovery. No intraoperative or postoperative complications were observed.

Conclusions

Laparoscopic management of interstitial pregnancy is a safe and effective minimally invasive approach in selected patients, offering reduced blood loss and rapid recovery. However, due to disruption of the myometrial integrity at the uterine cornu, there remains a potential risk of uterine rupture in subsequent pregnancies. Therefore, careful patient counselling, close antenatal surveillance, and consideration of planned delivery strategies are essential.

https://player.vimeo.com/video/1191636999?autoplay=1

ESGE35-0807 -
Free Communication

A minimally invasive stepwise hysteroscopic myomectomy using the Collins loop of a 15 Fr bipolar mini resectoscope: the MiniLoop Enucleation Technique (MiLET)

Ilenia Imbergamo[1], Emma Bonetti Palermo[2], Eleonora La Fera[3], Federica Pozzati[3], Francesco Fanfani[3], Ursula Catena[3]
[1]Fondazione Policlinico Universitario Agostino Gemelli- IRCCS- Roma- Italia.,
Dipartimento Scienze della Salute della Donna- del Bambino e di Sanità Pubblica, Roma, Italy
[2]ASST Spedali Civili Brescia- Brescia- Italy, Department of Women and Mother and Child Health, Brescia, Italy
[3]Fondazione Policlinico Universitario A. Gemelli- IRCCS- Rome- Italy,
Department of Women's and Children's Health Sciences, Roma, Italy

Background

Hysteroscopic myomectomy remains the gold standard for the treatment of submucosal fibroids in women desiring uterine preservation. However, conventional techniques often require larger resectoscopes, cervical dilation, and extensive tissue resection, potentially increasing surgical trauma. We aimed to describe the MiniLoop Enucleation Technique (MiLET), a novel minimally invasive stepwise hysteroscopic myomectomy performed using the Collins loop of a 15 Fr mini-resectoscope.

Methods

A 40-year-old nulliparous woman with recurrent implantation failure and a FIGO type 2 submucosal fibroid measuring 14 mm underwent hysteroscopic myomectomy at the CLASS Hysteroscopy Digital Hysteroscopic Clinic, Fondazione Policlinico Universitario A. Gemelli IRCCS, Rome, Italy. Preoperative evaluation included two-dimensional and three-dimensional transvaginal ultrasound and diagnostic hysteroscopy. The procedure was performed using a 15 Fr bipolar mini-resectoscope without cervical dilation. MiLET was carried out using the Collins loop as the sole operative instrument. The cleavage plane between the myoma and surrounding myometrium was progressively developed while preserving the pseudo capsule. Fibroconnective bridges were selectively divided to achieve gradual enucleation of the intramural component and mobilization of the myoma into the uterine cavity. Once adequately mobilized, the same Collins loop was used to slice the fibroid into removable fragments, completing the procedure in a single operative session.

Results

Total operative time was 16 minutes. Hemostasis was satisfactory, and fluid balance was maintained throughout the procedure. No intraoperative or postoperative complications occurred. Follow-up office hysteroscopy performed 30 days after surgery confirmed normal healing and complete restoration of the uterine cavity.

Conclusions

MiLET combines miniaturized instrumentation, stepwise enucleation, and selective bipolar energy to achieve complete hysteroscopic myomectomy while preserving the surrounding myometrium. This technique may represent a feasible, minimally invasive, and uterine-sparing option for the management of submucosal fibroids, particularly in reproductive-age women requiring preservation of uterine integrity.

https://player.vimeo.com/video/1195616638?autoplay=1

ESGE35-0866 -
Free Communication

Video presentation of vaginoscopic resection of an oblique vaginal septum in an adolescent girl with OHVIRA syndrome presenting with pyocolpos

Şeyma Taştekin[1], Meryem Hocaoğlu[1], Nisan Helin Dönmez[1], Zühal Altıntaş Sakaoğlu[1], Abdulkadir Turgut[1]
[1]Istanbul Medeniyet University,
Department of Obstetrics and Gynaecology- Goztepe Prof. Dr. Suleyman Yalcin City Hospital, Istanbul, Türkiye

Background

Obstructed hemivagina and ipsilateral renal anomaly (OHVIRA) syndrome is a rare Müllerian duct anomaly characterized by uterus didelphys, obstructed hemivagina, and ipsilateral renal anomaly. Delayed diagnosis may result in hematocolpos, pyocolpos, pelvic infection, and endometriosis. We aimed to present vaginoscopic resection of the oblique vaginal septum in an adolescent girl with OHVIRA syndrome presenting with pyocolpos while preserving hymenal integrity.

Methods

A 16-year-old virgin adolescent was admitted with persistent vaginal bleeding and severe pelvic pain. Abdominal ultrasonography and magnetic resonance imaging (MRI) demonstrated uterus didelphys, obstructed right hemivagina with hematometrocolpos/pyocolpos, and ipsilateral renal anomaly, consistent with OHVIRA syndrome. Following preoperative evaluation and antibiotic treatment, vaginoscopic surgery was planned.

During surgical exploration, the cervix was visualized in the left superior aspect, while an obliquely oriented vaginal septum extending along the right lateral vaginal wall was identified. Abipolar resectoscope was used to perform partial septal incision, allowing drainage of the purulent collection. Complete vaginal septum resection was subsequently performed using bipolar resectoscope while preserving hymenal integrity. An anti-adhesion barrier and postoperative vaginal mold were applied for 30 days to reduce the risk of restenosis.

Results

Adequate drainage of pyocolpos was achieved and continuity between the obstructed hemivaginal cavity and the cervix was restored. No intraoperative complications or significant bleeding occurred. Hymenal integrity was preserved throughout the procedure. At the 4-month follow-up, the patient remained asymptomatic with no evidence of complications or recurrence.

Conclusions

OHVIRA syndrome should be considered in adolescent patients presenting with pelvic pain, persistent vaginal bleeding, or hematocolpos. MRI plays a critical role in diagnosis and surgical planning. Vaginoscopic vaginal septum resection is a minimally invasive and effective treatment option that enables adequate drainage and anatomical restoration while preserving hymenal integrity.

https://player.vimeo.com/video/1195720230?autoplay=1

ESGE35-0381 -
Free Communication

Safety and clinical significance of intraoperative CART during staging laparoscopy for advanced ovarian, fallopian tube, and primary peritoneal cancer with massive malignant ascites

Shingo Miyamoto[1], Koike Ryo[1], Nakayama Ken[1], Matusura Rei[1], Sasaki Yasushi[1], Morioka Miki[1]
[1]Showa Medical University Fujigaoka Hospital, Obstetrics and Gynecology, Yokohama, Japan

Background

Cell-free and concentrated ascites reinfusion therapy (CART) may support the initiation and continuation of chemotherapy not only through palliation of ascites-related symptoms, but also by preserving performance status (PS), serum albumin levels, and renal function. Because hypoalbuminemia and low prognostic nutritional index (PNI) are associated with poor treatment tolerance and unfavourable oncologic outcomes, the clinical significance of CART deserves further investigation. Staging laparoscopy plays an important role in intraperitoneal assessment and histological confirmation before treatment in advanced ovarian, fallopian tube, and primary peritoneal cancer. However, patients with massive malignant ascites are at high risk of hypoalbuminemia and low PNI even before treatment initiation. This study aimed to evaluate the safety and potential clinical significance of intraoperative CART during staging laparoscopy in patients with massive malignant ascites.

Methods

A retrospective cohort study was conducted in patients with advanced ovarian fallopian tube, or primary peritoneal cancer accompanied by massive malignant ascites who underwent ascites drainage at our institution during 2016-2022. During staging laparoscopy, ascites was aspirated under pneumoperitoneum through a balloon trocar inserted at the umbilicus, followed by laparoscopic drainage of the remaining ascites. We compared the volume of ascites collected during staging laparoscopy combined with CART and conventional paracentesis, the rate of serum albumin reduction according to CART, differences in albumin reduction among the CART combined with staging laparoscopy group, CART-only group, and non-CART group, as well as progression-free survival (PFS) and overall survival (OS) according to CART.

Results

Among 30 patients, CART was performed in 13 patients and was not performed in 17 patients. Of the 13 patients who underwent CART, 7 underwent CART combined with staging laparoscopy and 6 underwent CART alone. Staging laparoscopy combined with CART prolonged operative time by approximately 15 minutes; however, no perioperative complications were observed. Staging laparoscopy with CART enabled collection of a significantly larger volume of ascites than conventional paracentesis (3300 mL vs 2000 mL, $p<0.05$). CART tended to reduce the decline in serum albumin compared with non-CART management (0.25 vs 0.5 g/dL; 8% vs 18%). Furthermore, the staging laparoscopy with CART group showed a trend toward less albumin reduction than the CART-only and non-CART groups (0.25 vs 0.3 vs 0.5 g/dL; 9% vs 10% vs 18%). No significant differences were

observed in 3-year PFS (60% vs 24%, log-rank p=0.24) or 3-year OS (69% vs 63%, log-rank p=0.71), with a median follow-up period of 46 months (range, 23–54 months).

Conclusions

Intraoperative CART during staging laparoscopy for advanced ovarian, fallopian tube, and primary peritoneal cancer with massive malignant ascites appears to be safe and may facilitate collection of larger ascites volumes while minimizing pre-treatment albumin depletion. Pre-treatment CART may potentially contribute to improved oncologic outcomes through maintenance of nutritional status and treatment tolerability.

ESGE35-0296 -
Free Communication

Laparoscopic sentinel lymph node resection in endometrial cancer using ICG and NIR technology: nine years of experience and oncological outcomes

Andreas Kavallaris[1,2], Dimitrios Grigoriou[2], Panagiotis Papandreou[1],
Antonis Gkoutzioulis[1], Anna Sachpekidou[1], Dimitrios Zygouris[1]
[1]St. Luke's Hospital- Thessaloniki- Greece,
Department of Gynecologic Oncology and Minimally invasive surgery, Thessaloniki, Greece
[2]Mother and child medical center- Nicosia- Cyprus,
Department of Gynecologic Oncology and Minimally invasive surgery, Nicosia, Cyprus
[3]Marienhospital Bottrop- Bottrop- Germany, Department of Gynecology and Obstetrics, Bottrop, Germany

Background

In this retrospective study we present our oncological data on patients with Endometrial cancer, that underwent Laparoscopic Lymph node dissection.

Methods

Since 2017 we use the sentinel lymph node technique mapped with ICG dye for the treatment of endometrial cancer. For the first 40 cases between 02. 2017 until 10.2018 we performed always radical pelvic lymphadenectomy after the SLN mapping to evaluate the method and standardized our technique. However, obtaining sufficient and high surgeons experience (at least 20 cases per year) and standardized technique continues to be essential to preserving diagnostic accuracy. The data of the SLNs location were documented and evaluated.

Results

A total of 684 SLNs (range 1- 4 SLNs) were identified and removed. A total of 217 patients (98%) had a successful procedure, in 93%, bilateral mapping was successful. The most common area to find the SLN, were in the external iliac region (37.7%) the obturator region (34.4%,) the internal iliac region (11.9%), the common iliac region (8%,) presacral region (3%) and in 5.6% other areas. There were no differences in the SLN location on pelvic sides. In 3.7% positives SLNs were found and pelvic radical lymphadenectomy was performed. The overall survival rate in the SLN group after a median follow up of 38 months (range 4 – 64 months) was 100%, 169/169 pts. In 2 pts (1.1%) intraabdominal recurrence disease (peritoneal metastasis) occurred and the pts underwent chemotherapy treatment.

Conclusions

Sentinel lymph node (SLN) mapping in high-grade endometrial cancer has demonstrated detection rates and diagnostic accuracy comparable to those observed in low-grade disease. These findings support SLN mapping as a feasible and safe approach for surgical staging in patients with early-stage and high-risk endometrial cancer. Nevertheless, further studies are required to address remaining uncertainties and controversies, particularly in high-risk cases.

ESGE35-0476 -
Free Communication

Endometriosis-associated endometrioid adenocarcinoma with ovarian and extra-ovarian presentation - lessons from 2 cases.

Georgia Ilia[1], Tibor Zwimpfer[1], Fabienne Dominique Schwab[1], Viola Heinzelmann-Schwarz[1], Celine Montavon[1], Bich Doan Nguyen-Sträuli[1]
[1]University Hospital Basel, Gynaecological Cancer Centre, Basel, Switzerland

Background

Endometriosis-associated malignancy is rare, with malignant transformation reported in approximately 0.5–1% of women with endometriosis. The most frequently associated histological entities are endometrioid and clear cell carcinomas. Ovarian endometrioid carcinomas represent approximately 10% of epithelial ovarian cancers, whereas extra-ovarian malignant transformation is uncommon and may mimic gastrointestinal, urinary tract or pelvic sidewall malignancies. We report two cases of endometrioid adenocarcinomas with ovarian and extra-ovarian presentation, respectively.

Methods

We retrospectively reviewed clinicopathological data, biomarker status and tumor board recommendations of two patients treated for endometriosis-associated endometrioid adenocarcinoma at the University Hospital Basel, Switzerland, in 2026.

Results

Case 1: A 44-year-old woman, gravida 2 para 2, was referred for cytoreductive surgery following laparoscopy of a left-sided pelvic sidewall tumor. Biopsy revealed a PAX8-positive adenocarcinoma, most likely of female genital tract origin. She had undergone hysterectomy with bilateral salpingectomy in 2023 for uterine leiomyomas; no endometriosis was reported at that time. Preoperative imaging showed an extensive left-sided pelvic mass with bladder wall infiltration, grade III hydronephrosis and rectosigmoid involvement. Multivisceral cytoreductive surgery was performed, including en bloc tumor resection of the left pelvic sidewall with partial cystectomy and bladder reconstruction, extensive ureterolysis, resection of the left internal iliac artery anterior rectum resection, right-sided oophorectomy, omentectomy and peritoneal biopsies. Histology revealed a low-grade endometrioid adenocarcinoma infiltrating bladder, vagina and rectum, consistent with malignant transformation of deep infiltrating endometriosis. Immunohistochemistry showed PAX8 and CK7 positivity, ER/PR positivity, p53 wild-type pattern, PTEN and ARID1A loss, and deficient mismatch repair status (loss of MLH1/PMS2). No FIGO stage was assigned given the atypical presentation. Adjuvant Carboplatin, Caclitaxel and Dostarlimab were administrated.

Case 2: A 32-year-old nulligravida presented with a cystic-solid left ovarian mass containing a large, strongly vascularized papillary component , classified as O-RADS 5 (Ovarian-Adnexal Reporting and Data System) on ultrasound. Serum CA-125 and CA 19-9 levels were elevated (217 U/mL and 129.0 U/mL, respectively). Given her wish for future childbearing, fertility-sparing surgery was performed: left-sided salpingo-oophorectomy with staging (peritoneal biopsies, omentectomy, removal of two

grossy lymph nodes). Histology revealed a low-grade endometrioid ovarian carcinoma arising within an endometrioid borderline tumor with associated endometriotic cysts FIGO IA, R0, pT1a, pN0 (0/2), L0, V0, Pn0). Immunohistochemistry showed ER/PR positivity, p53 wild-type pattern, focal ARID1A loss and proficient mismatch repair. According to the interdisciplinary tumor board recommendation, no adjuvant chemotherapy was indicated, and the patient was subsequently referred to a reproductive endocrinologist for fertility counselling.

Conclusions

Endometriosis-associated endometrioid adenocarcinoma is a rare entity spanning ovarian and extra-ovarian malignant transformation. Management should be individualized, particularly when malignant transformation occurs in extra-ovarian sites. Oncologic surgical planning and multidisciplinary care are essential for timely diagnosis and appropriate treatment. Reproductive endocrinologists should be involved early in patients with a desire for future childbearing.

ESGE35-0488 -
Free Communication

Minimally invasive surgical staging in endometrial cancer: from laparoscopy to robotic sentinel lymph node mapping

Maria-Bianca Nitescu[1], Hashemi Anca-Mihaela[1], Manu Andrei[1], Coroleuca Bogdan-Catalin[1], Bratila Elvira[1]
[1]Clinical Hospital of Obstetrics and Gynaecology "Panait Sarbu", Obstetrics and Gynaecology, Bucharest, Romania

Background

To evaluate the transition from conventional surgical staging to minimally invasive precision staging in endometrial cancer, with particular emphasis on laparoscopic and robotic approaches combined with sentinel lymph node mapping.

Methods

We reviewed an institutional database of patients treated surgically for endometrial cancer or premalignant endometrial pathology. Surgical approach, type of nodal assessment, sentinel lymph node mapping technique, tumor grade and FIGO stage were analysed. Cases were grouped according to surgical access: open surgery, conventional laparoscopy and robotic-assisted surgery. Particular attention was given to the implementation of sentinel lymph node mapping using indocyanine green as part of a tailored staging strategy.

Results

The database included 154 patients. Surgical approach distribution reflected a progressive shift toward minimally invasive staging: 58 patients managed by open surgery, 77 by laparoscopy and 19 by robotic-assisted surgery. Most cases were early-stage disease: 84 patients classified as FIGO stage IA and 38 as stage IB. Tumour grade was predominantly low or intermediate, with 61 G1, 51 G2 and 16 G3 tumours recorded. Sentinel lymph node mapping was performed in 54 cases — 35 laparoscopic and 19 robotic — with indocyanine green used in 34 procedures. In the robotic group, sentinel lymph node mapping was consistently integrated into the staging strategy, supported by the platform's built-in fluorescence imaging, stable pelvic exposure and precise dissection of the paravesical, pararectal and obturator spaces.

Conclusions

The management of endometrial cancer is moving from systematic radical staging toward a more selective, minimally invasive and precision-based strategy. In our experience, laparoscopy and robotics enabled integration of sentinel lymph node mapping into surgical staging, while reducing reliance on open surgery. The value of robotic surgery in this setting lies not only in performing minimally invasive hysterectomy, but in supporting fluorescence-guided nodal assessment and tailored lymphadenectomy when indicated. This approach may contribute to accurate staging while limiting unnecessary lymphatic morbidity in selected patients.

ESGE35-0687 -
Free Communication

When endometriosis masquerades as ovarian malignancy: a triple-domain clinical–biochemical–mri predictive model in a two-week-wait cohort

Deepali Bhatte[1], *Shachi Mishra*[2], *Yemi Coker*[3], *Kunal Rathod*[4]
[1]*Barking- Havering and Redbridge University Hospitals- NHS Trust, Women's Health, Romford, United Kingdom*
[2]*Barking- Havering and Redbridge University Hospitals- NHS Trust, Womens' Health, Romford, United Kingdom*
[3]*Barking- Havering and Redbridge University Hospitals- NHS Trust, Women's Health, Romford, United Kingdom*
[4]*Barking- Havering and Redbridge University Hospitals- NHS Trust, Women's Health, Romford, United Kingdom*

Background

Advanced endometriosis frequently mimics ovarian malignancy due to complex adnexal masses, markedly elevated CA125, bowel tethering, pelvic nodularity, and deep infiltrating disease on MRI. Consequently, many women are referred through suspected ovarian cancer pathways and undergo oncology multidisciplinary review despite ultimately having benign disease. Distinguishing severe endometriosis from malignancy remains a major diagnostic and surgical challenge.

Objective

To evaluate clinical, biochemical and MRI predictors of histologically confirmed endometriosis in women referred through the suspected ovarian malignancy pathway, and to assess false-positive cancer referrals, unexpected malignancy rates, and development of a predictive scoring model.

Methods

A retrospective observational cohort study was performed in women referred with suspected ovarian malignancy. Demographic variables, symptoms, CA125, ultrasound findings, MRI characteristics, MDT discussion, operative management, and histopathological outcomes were analysed.

A triple-domain predictive analysis was undertaken using:

2. Clinical variables: age, BMI, parity, pelvic pain, bloating, and previous endometriosis
3. Biochemical variables: CA125 level and degree of elevation
4. MRI variables: deep infiltrating endometriosis, unilateral/bilateral endometrioma, kissing ovaries, haematosalpinx, pelvic plaque disease, bowel tethering and mushroom rectosigmoid lesions

Primary outcome was histologically confirmed endometriosis. Secondary outcomes included unexpected malignancy, conservative versus surgical management and development of a composite predictive score.

Results

A total of 61 patients were analysed, of whom 59/61 (96.7%) were referred through the two-week-wait ovarian cancer pathway. Raised CA125 was identified in 39/61 (63.9%), with values ranging from 6–1425 U/mL.

Histology and definitive clinical outcome data were available in 45 patients. Histologically confirmed endometriosis was identified in 31/45 (68.9%), while no unexpected malignancies were identified (0%) within the operated cohort.

MRI features most strongly associated with histologically confirmed endometriosis included:

4. bowel tethering,
5. bilateral endometrioma,
6. haematosalpinx,
7. kissing ovaries,
8. deep infiltrating endometriosis,
9. pelvic plaque disease,
10. and mushroom rectosigmoid lesions.

Among patients with bowel tethering on MRI, over three-quarters demonstrated histological endometriosis. Bilateral endometrioma and haematosalpinx also demonstrated high positive correlation with benign advanced endometriosis despite cancer-pathway referral.

Markedly elevated CA125 did not reliably predict malignancy. Multiple patients with CA125 levels >500 U/mL and one patient with CA125 >1400 U/mL had benign advanced endometriosis.

A composite clinical–biochemical–MRI predictive model demonstrated substantially higher probability of histological endometriosis in patients with combined MRI phenotype features compared with isolated CA125 elevation alone.

Complex surgical management included advanced laparoscopic, robotic and multidisciplinary procedures involving bowel and advanced pelvic sidewall disease. A substantial proportion of patients were managed conservatively, declined surgery or required fertility-preserving approaches.

Conclusions

Advanced endometriosis represents a major cause of false-positive ovarian cancer pathway referral. MRI phenotype appears significantly more predictive than CA125 elevation alone in differentiating benign endometriosis from malignancy.

A triple-domain approach integrating clinical presentation, biochemical markers and MRI characteristics may improve diagnostic stratification, reduce unnecessary oncology pathway utilisation and facilitate earlier referral into specialist endometriosis services.

Further multicentre validation of this predictive model is warranted.

ESGE35-0688 -
Free Communication

Sentinel lymph node mapping in endometrial cancer: does the minimally invasive surgical platform influence detection?

Giuseppe D'Angelo[1], Mario Ascione[1], Mario Palumbo[1], Attilio Di Spiezio Sardo[1], Luigi Della Corte[2], Giuseppe Bifulco[1]
[1]University of Naples Federico II, Department of Public Health, Naples, Italy
[2]University of Naples Federico II,
Department of Neuroscience- Reproductive Sciences and Dentistry- School of Medicine, Naples, Italy

Background

Sentinel lymph node mapping is a key component of surgical staging in apparent early-stage endometrial cancer. However, whether the minimally invasive surgical platform influences mapping performance remains unclear. This study aimed to compare sentinel lymph node detection between conventional laparoscopy and robot-assisted surgery within a standardized institutional mapping protocol.

Methods

This single-center retrospective cohort study included consecutive patients undergoing minimally invasive surgery with sentinel lymph node mapping for presumed early-stage endometrial cancer at the University of Naples Federico II between January 2023 and December 2024. Patients treated by conventional laparoscopy or robot-assisted surgery were compared. Mapping was performed using a standardized cervical near-infrared fluorescence tracer injection protocol. Reinjection and side-specific pelvic lymphadenectomy were performed in cases of persistent mapping failure. All sentinel lymph node specimens underwent pathological ultrastaging. The primary outcome was sentinel lymph node detection, assessed as bilateral, unilateral, absent, and any mapping. Multivariable logistic regression evaluated the association between surgical platform and any mapping success, adjusting for age, body mass index, and diabetes.

Results

A total of 185 patients were included: 70 underwent conventional laparoscopy and 115 robot-assisted surgery. Any sentinel lymph node mapping was achieved in 90.3% of laparoscopic cases and 91.6% of robotic cases. Bilateral mapping rates were 80.6% and 85.0%, respectively, while absent mapping occurred in 9.7% and 8.4% of cases. No significant difference was observed in overall mapping pattern between groups. The anatomical distribution of mapped nodes was also comparable. After adjustment for age, body mass index, and diabetes, robot-assisted surgery was not independently associated with any sentinel lymph node mapping success compared with laparoscopy. Operative time estimated blood loss, conversion rate, postoperative complications, and recurrence were similar between groups. However, length of hospital stay was significantly shorter after robot-assisted surgery compared with conventional laparoscopy, with a median stay of 30.0 hours [interquartile range 27.0–34.5] versus 49.0 hours [44.2–52.0], respectively ($p<0.001$). This difference remained significant after adjustment, with an adjusted median reduction of 19.4 hours in the robotic group.

Conclusions

In this retrospective cohort, sentinel lymph node mapping performance did not differ significantly between conventional laparoscopy and robot-assisted surgery when a standardized mapping protocol, ultrastaging, and predefined management of mapping failure were applied. These findings suggest that protocol standardization and surgical expertise may be more relevant to mapping success than the minimally invasive platform itself. Robot-assisted surgery was associated with a shorter hospital stay, although this result may also reflect institutional workflow and discharge practices.

ESGE35-0304 -
Free Communication

Sentinel lymph node mapping in endometrial cancer: most common nodal locations

Andreas Kavallaris[1,2], Antonis Gkoutzioulis[1], Panagiotis Papandreou[1], Dimitrios Grigoriou[2], Stergios Kopatsaris[3], Dimitrios Zygouris[1]
[1]St. Luke's Hospital- Thessaloniki- Greece,
Department of Gynecologic Oncology and Minimally invasive surgery, Thessaloniki, Greece
[2]Mother and child medical center- Nicosia- Cyprus,
Department of Gynecologic Oncology and Minimally invasive surgery, Nicosia, Cyprus
[3]Marienhospital Bottrop- Bottrop- Germany, Department of Gynecology and Obstetrics, Bottrop, Germany

Background

SLN mapping is based on the concept that the lymph drains in a specific pattern, away from the tumor and therefore, if the first lymph node (the SLN), is negative for metastasis, then the nodes after the SLN should also be negative.

Methods

Since 2017 we use the sentinel lymph node technique mapped with indocyanine green (ICG) dye for the treatment of endometrial cancer. For the first 40 cases between 02. 2017 until 10.2018 we performed always radical pelvic lymphadenectomy after the SLN mapping to evaluate the method and standardized our technique. However, obtaining sufficient and high surgeons experience (at least 20 cases per year) and standardized technique continues to be essential to preserving diagnostic accuracy. The data of the SLNs location were documented and evaluated. The following years between 11.2018 until 06.2026 we performed in 221cases (181 endometrioid G1 and G2 and 40 high grades endometrial cancer) ultra-staging SLN mapping, explore the pelvic, the presacral and the paraaortic areas.

Results

The overall detection rate (unilateral or bilateral mapping) of SLNs was for the low- and intermediate-risk patients 100%, and 91% for the high-risk patients, in 2 pts (8%) mapping had failed. A total of 684 SLNs (range 1- 4 SLNs) were identified and removed. A total of 217 patients (98%) had a successful procedure, in 93%, bilateral mapping was successful. The most common area to find the SLN, were in the external iliac region (37.7%) the obturator region (34.4%,) the internal iliac region (11.9%), the common iliac region (8%,) presacral region (3%) and in 5.6% other areas. There were no differences in the SLN location on pelvic sides. In 3.7% positives SLNs were found and pelvic radical lymphadenectomy was performed.

Conclusions

SLN mapping in high-grade endometrial cancer demonstrates similar high detection rates and diagnostic accuracy as seen in low-grade endometrial cancers. However, future studies are needed to support this suggestion by resolving potential areas of doubt and debate, especially for high-risk

endometrial cancer cases. With the standardization of the technique, we managed to reproduce the high total and bilateral SLN mapping using cervical ICG injection and NIR fluorescence.

https://player.vimeo.com/video/1191426875?autoplay=1

ESGE35-0477 -
Free Communication

When safe entry points become traps: laparoscopic entry in a hostile abdomen

Buket Kocak[1], Oguz Arslan[1], Rumeysa Belen Gumus[1], Mustafa Kemal Koksal[1], Onur Yavuz[1], Ibrahim Yalcin[1]
[1]Dokuz Eylul University, Department of Gynaecologic Oncology, IZMIR, Türkiye

Background

Safe laparoscopic entry can become challenging in patients with hostile abdomens and extensive postoperative adhesions. We present a case demonstrating alternative laparoscopic entry strategies in a patient undergoing minimally invasive surgical staging for endometrial carcinoma.

Methods

A 65-year-old G2P2 woman with postmenopausal bleeding and multiple prior abdominal surgeries, including sigmoidectomy via midline laparotomy, was diagnosed with FIGO grade 3 endometrioid endometrial carcinoma. Initial entry through Palmer's point failed to achieve pneumoperitoneum. Due to extensive adhesions involving the bowel and omentum beneath the anterior abdominal wall, an alternative left lateral Jain point entry was performed. Careful adhesiolysis allowed completion of total laparoscopic hysterectomy, bilateral salpingo-oophorectomy, sentinel lymph node mapping, left pelvic lymphadenectomy, and surgical staging.

Results

Successful right-sided sentinel lymphatic mapping was achieved, while no left-sided mapping was observed, requiring side-specific pelvic lymphadenectomy. No intraoperative complications occurred. Final pathology confirmed stage IA FIGO grade 3 endometrioid carcinoma without nodal metastasis.

Conclusions

Alternative laparoscopic entry strategies may allow safe completion of minimally invasive oncologic surgery in hostile abdomens when conventional safe entry points are not feasible.

https://player.vimeo.com/video/1191658284?autoplay=1

ESGE35-0553 -
Free Communication

Robotic Single-Port (SP) resection of a presacral oligometastatic ovarian cancer recurrence using ICG-guided ureteral visualization

Dogan Vatansever[1], Oytun Turkkan[2], Muhterem Melis Canturk[1], Emin Erhan Donmez[1], Burak Giray[1], Cagatay Taskiran[1]
[1]Koc University, Gynaecologic Oncology, Istanbul, Türkiye
[2]Koc University, Gynaecologic Oncology, İstanbul, Türkiye

Background

Surgical management of recurrent ovarian cancer is frequently complicated by altered anatomy and dense adhesions from prior interventions. The objective of this video is to demonstrate the safe and effective resection of a 1.5 cm presacral oligometastatic recurrence of high-grade serous ovarian carcinoma in a 67-year-old patient, utilizing the Da Vinci Single Port (SP) robotic platform.

Methods

Preoperative CT and PET imaging localized the presacral recurrence. The procedure began with a 3.7 cm umbilical incision for access and SP docking. Viewers should pay special attention to two major technical highlights demonstrated in the video:

- **Navigating the Frozen Pelvis:** Extensive and meticulous adhesiolysis was required to mobilize tissues and reach the deep pelvic area safely.
- **Real-Time Ureteral Mapping:** Due to the mass's proximity to the right ureter, cystoscopic injection of Indocyanine Green (ICG) into both ureters was performed. Utilizing the robotic Firefly (near-infrared) mode vividly illuminated the ureters. This technique was crucial for mapping the anatomy, preventing iatrogenic injury, and facilitating a much easier and safer dissection of the tumor bed. Furthermore, a Nelaton catheter was adapted for intraoperative aspiration.

Results

The presacral mass was successfully and completely resected.

Conclusions

The minimally invasive SP approach coupled with ICG mapping minimized surgical trauma, allowing the patient to bypass the intensive care unit. She was admitted directly to the standard ward and safely discharged on postoperative day 2.

https://player.vimeo.com/video/1191687673?autoplay=1

ESGE35-0940 -
Free Communication

Three-step approach to highly complex pelvic recurrence in ovarian cancer: vascular control, ICG ureteral staining, TICA

Andrea Rosati[1], Fausto Napolitano[1], Sofia Russo De Lucia[1], Francesca Romana Scanu[1], Claudio Lodoli[2], Anna Fagotti[1]
[1]Fondazione Policlinico Universitario A. Gemelli- IRCCS- Roma- Italy.,
Woman- Child and Public Health Department, Rome, Italy
[2]Fondazione Policlinico Universitario A. Gemelli- IRCCS- Roma- Italy.,
Medical and Surgical Science Department, Rome, Italy

Background

Secondary cytoreductive surgery (SCS) may be considered in carefully selected patients with recurrent ovarian cancer when complete gross resection is achievable. Oligo or multivisceral recurrence in a frozen pelvis remains technically challenging, especially when bowel, urinary tract, and parametrial/vaginal compartments are involved. The aim of this video is to demonstrate the feasibility of a robot-assisted SCS using en bloc multivisceral resection and totally intracorporeal termino-terminal colorectal anastomosis (TICA).

Methods

We present the case of a 54-year-old woman with a platinum-sensitive recurrence (PFI 40 months) of high-grade G3 clear-cell ovarian carcinoma. A pre-operative CT scan was performed. We selected a Da Vinci Xi robotic approach. The pelvis was characterized by dense adhesions and a frozen pelvis. Right ureteral catheterization with selective indocyanine-green injection enabled fluorescence-guided dissection using Firefly technology. The recurrence was resected en bloc with the upper third of the vagina, right lateral parametrium, bladder wall margin, and a segment of descending colon, followed by intracorporeal termino-terminal colorectal anastomosis.

Results

Complete cytoreduction was achieved (RT=0). The operative time was 420 minutes, and estimated blood loss was 300 mL. No intraoperative transfusion was required. Histopathological examination confirmed metastatic involvement of the resected lesion.

Conclusions

A fully robotic approach may be feasible for selected ovarian cancer recurrences requiring complex pelvic multivisceral resection, provided that surgery is performed in high-volume centres with gynaecologic oncology, urologic, and colorectal expertise. Robotic precision, fluorescence-guided ureteral navigation and TICA may support complete cytoreduction while maintaining a minimally invasive approach.

https://player.vimeo.com/video/1205318752?autoplay=1

ESGE35-0274 -
Free Communication

Quality of clinical assessments and interactions using telemedicine in the management of chronic pelvic and pudendal pain

Stesi Kambo[1], Danielle Tsirulnikov[1], Lacey Brennan[2], Sricherry Nannapaneni[1], Sara Hojabri[1], Nucelio Lemos[1]
[1]University of Toronto, Obstetrics and Gynaecology, Toronto, Canada
[2]Peter Lougheed Center, Obstetrics and Gynaecology, Calgary, Canada

Background

Chronic pelvic and pudendal pain (CPPP) is a common, debilitating condition affecting roughly 1 in 5 reproductive age women. Timely and accurate diagnosis is crucial, yet delays are well documented and can span years, leading to heavy use of emergency and specialist services, compounding their associated economic burden. As telemedicine becomes an established care modality, rigorous evidence on whether virtual consultations can match in-person care for complex gynecologic conditions remains scarce. The aim of this project is to evaluate the diagnostic accuracy and patient satisfaction of telemedicine in initial assessment of patients with CPPP compared to standard in-person consultations.

Methods

We conducted a descriptive retrospective-prospective observational cohort study of 447 patients (227 virtual, 220 in person) seen from 2018 to 2024 at a Complex Gynecology and Pelvic Pain Clinic at Mount Sinai Hospital in Toronto, Canada, tracking diagnoses at the initial visit, subsequent in-person follow-up, and final recorded appointment. Diagnostic stability, was defined as concordance of 11 diagnostic categories between first and last visit, assessed at both the overall level and among confirmed diagnoses (positive agreement). Patient composite satisfaction scores were calculated using survey responses on a 4-point Likert-type scale.

Results

Non-inferiority of virtual consultation was clearly established for overall diagnostic concordance (95% CI: -0.0192 to 0.0093; NI margin -0.10) and patient satisfaction (95% CI: -3.2 to 4.8; NI margin -0.10). Positive agreement, of diagnoses initially diagnosed and subsequently confirmed in follow up care, did not reach statistical significance to prove non-inferiority of virtual care (95% CI: -0.1373 to -0.0133; NI margin -0.10).

Conclusions

Telemedicine is non-inferior to standard in person consultation for diagnostic accuracy and patient satisfaction. More rigorous analysis of positive agreement and diagnostic revision demonstrated comparable diagnostic accuracy between care modalities. These findings support virtual care as a viable care and scalable model for specialized gynecologic assessment that can significantly expand equitable access to care and contribute to AI-assisted tools for diagnosis, triage, and management.

ESGE35-0658 -
Free Communication

Spatial neurovascular mapping of posterior deep endometriosis after butterfly peritoneal excision and its association with postoperative pain outcomes

Erberk Çimer[1], Kiper Aslan[2], Selen Mutlu[3], Cihan Cakir[3], Isıl Kasapoglu[2], Gurkan Uncu[2]
[1]Bursa Uludağ University, Obstetrics and Gynecology, Bursa, Türkiye
[2]Bursa Uludag University, Obstetrics and Gynecology, Bursa, Türkiye
[3]Bursa Uludag University, Histology and Embryology, Bursa, Türkiye

Background

Posterior deep endometriosis is associated with severe pain and complex neuroinflammatory remodelling, but the spatial distribution of neurovascular structures within the excised posterior peritoneal field remains poorly defined. This study evaluated the spatial neurovascular architecture of posterior deep endometriosis using standardized butterfly peritoneal excision and explored its association with postoperative pain outcomes.

Methods

This prospective exploratory pilot study included 15 women with advanced posterior deep endometriosis who underwent laparoscopic butterfly peritoneal excision at a tertiary referral center between December 2023 and April 2025. Each specimen was anatomically oriented and divided into 15 radial segments, including seven right-sided segments, seven left-sided segments, and a central torus uterinus segment, yielding 225 butterfly-derived samples and 15 normal peritoneal controls. Tissue concentrations of nerve growth factor, bradykinin, PGP9.5, and substance P were quantified by ELISA, and nerve-fibre and capillary density were assessed morphometrically on Masson trichrome-stained sections. Spatial gradients were analysed using generalized estimating equation models. Postoperative pain was assessed using visual analogue scale scores at 1, 3, and 6 months, and quality of life was evaluated with SF-12. Exploratory multivariable regression analyses assessed predictors of 6-month pain improvement.

Results

Nerve-fibre density demonstrated a significant center-to-periphery decline, corresponding to an approximately 27% reduction per radial segment ($\beta = -0.317$, $p < 0.001$). Capillary density showed a parallel but less pronounced decrease ($\beta = -0.100$, $p < 0.001$), with no right-left asymmetry. Tissue mediators showed heterogeneous spatial distributions rather than a uniform center-dominant pattern. Only bradykinin was significantly associated with nerve-fibre density ($p < 0.001$). Clinically, all pain domains improved significantly during follow-up. Dysmenorrhea decreased from 9 [7-10] preoperatively to 2 [0-4] at 6 months, and chronic pelvic pain decreased from 7 [7-9] to 0 [0-2], both $p < 0.001$. In exploratory adjusted analyses, central nerve growth factor concentration was associated with 6-month dysmenorrhea improvement ($\beta = 0.012$, $p = 0.043$), whereas morphometric nerve-fibre density was not ($p = 0.667$). For chronic pelvic pain, baseline pain severity was the only significant predictor of postoperative improvement ($\beta = 0.777$, $p = 0.030$).

Conclusions

Posterior deep endometriosis demonstrates a structured neurovascular gradient within butterfly peritoneal excision specimens, with dissociation between structural innervation and biochemical mediator distribution. Central neurotrophic activity, rather than morphometric nerve-fibre density alone, may be associated with postoperative dysmenorrhea improvement. These hypothesis-generating findings support the feasibility and biological relevance of systematic spatial neurovascular mapping and provide preliminary mechanistic support for field-based excision strategies in advanced posterior deep endometriosis.

ESGE35-0668 -
Free Communication

Perioperative dynamics of pelvic floor myofascial pain in women undergoing laparoscopy for endometriosis: a prospective cohort study

Lejla Samson[1], Alexandra Perricos-Hess[1], Jana Heine[1], Heinrich Husslein[1], Lorenz Kuessel[1]
[1]Medical University of Vienna, Department of Obstetrics and Gynaecology, Vienna, Austria

Background

Endometriosis, defined by the presence of endometrium-like tissue outside the uterine cavity, affects approximately 10–15% of women of reproductive age and is identified in nearly 70% of women with chronic pelvic pain. Pain severity does not correlate with the extent of lesions. Local neurogenic inflammation surrounding ectopic lesions is thought to contribute to central sensitisation, reflex pelvic floor hypertonia, and the development of myofascial trigger points—self-sustaining nociceptive foci that may persist even after surgical excision. However, the effect of laparoscopic excision on pelvic floor myofascial pain, as assessed using a standardised examination, remains unknown. We therefore investigated this relationship and its association with patient-reported pain, sexual function, and quality of life.

Methods

Prospective single-centre cohort study at a tertiary referral endometriosis unit in Vienna, Austria. Sixty-two premenopausal women aged 18–50 years scheduled for laparoscopy for suspected endometriosis underwent a standardised pelvic floor myofascial pain (MFPP) examination (Meister et al., 2019). Visual analogue scales (VAS) for dysmenorrhea, acyclic pelvic pain and dyspareunia, the validated German Female Sexual Function Index (FSFI-d) and the Endometriosis Health Profile-30 (EHP-30) were collected before surgery (V1) and 12–16 weeks after surgery (V2). Pre–post comparisons used the Wilcoxon signed-rank test; associations were assessed with Spearman correlations. A linear regression model with the preoperative MFPP score as covariate tested the independent effect of concomitant hysterectomy on the postoperative MFPP score.

Results

Endometriosis was histologically confirmed in 52 of 62 women (83.9 %); concomitant hysterectomy was performed in 18 women (29.0 %). The median internal MFPP score fell from 32.5 (IQR 21–44) at V1 to 14 (4–25.5) at V2 ($p < .001$). External MFPP score fell from 1 (0–2) to 0 (0–0). Dysmenorrhea (VAS 8 vs 2.5; $p < .001$), acyclic pelvic pain (VAS 6 vs 2; $p < .001$), dyspareunia (VAS 7 vs 0; $p < .001$), the EHP-30 total score (52 vs 27; $p < .001$) and the FSFI-d total score (22 vs 26; $p < .001$) all improved significantly. At baseline, the MFPP score did not correlate with any patient-reported outcome. After surgery, residual MFPP correlated weakly but significantly with residual dyspareunia ($\rho = 0.26$, $p = 0.013$) and with the EHP-30 total score ($\rho = 0.21$, $p = 0.025$). Concomitant hysterectomy did not independently influence the postoperative MFPP score after adjustment for the preoperative score (estimate 0.44; 95 % CI 0.16–1.23; $p = 0.117$).

Conclusions

Laparoscopic excision of endometriosis is associated with a marked reduction of pelvic floor myofascial pain that parallels improvements in pain symptoms, sexual function and disease-specific quality of life. Persistent postoperative myofascial pain identifies women who continue to experience dyspareunia and impaired quality of life and may represent a target for adjunctive pelvic floor physiotherapy.

ESGE35-0784 -
Free Communication

From pain to nerves: early surgical experience of a Neuropelveology program integrated into deep endometriosis surgery

Julie Alaert[1], Karampelas Stavros[2]
[1]Gynecology, CHU Brugmann, Laeken, Belgium
[2]Chu Brugmann, Gynecology, Bruxelles, Belgium

Background

Neuropelveology is an emerging multidisciplinary field focused on the diagnosis and treatment of pelvic nerve and neurovascular disorders contributing to chronic pelvic pain. In patients with deep infiltrating endometriosis (DIE), neurovascular entrapment involving the lumbosacral plexus and pelvic nerves remains frequently underdiagnosed, especially in cases of persistent pain despite standard treatment. In December 2025, a dedicated Neuropelveology program was established within a tertiary gynecologic referral center, integrating systematic pelvic nerve exploration into surgery for complex pelvic pain and DIE. This study reports the initial surgical experience and intraoperative findings of this program.

Methods

A prospective case series included 10 patients undergoing laparoscopic surgery between December 2025 and February 2026. The mean patient age was 30 years (range 25–44). All patients presented with severe refractory pelvic pain, including dysmenorrhea, dyspareunia, dyschezia, positional pain, and/or neuropathic lower-limb symptoms. Surgical management combined excision of deep infiltrating endometriosis with systematic neuropelveological exploration of the lumbosacral plexus, sacral roots, sciatic, hypogastric, and genitofemoral nerves using nerve-sparing retroperitoneal dissection techniques.

Results

Neurovascular entrapment was identified in all patients. Five neural structures were involved overall, with predominant sciatic nerve involvement (4/5 cases). Additional sites included sacral roots, lumbosacral plexus, genitofemoral nerve, left hypogastric nerve, and left internal iliac vein–related neurovascular compression. Neuropathic symptoms comprised sciatalgia (4 cases), chronic pelvic pain (5 cases), and positional sitting pain (1 case), all occurring in the context of deep infiltrating endometriosis associated with dysmenorrhea. Surgical treatment included sciatic and sacral neurolysis, genitofemoral and hypogastric nerve decompression, selective vascular coagulation or section, and complete excision of deep endometriotic disease involving the uterosacral ligaments, rectovaginal septum, parametria, and retroperitoneum. Postoperative morbidity was low, with two Clavien–Dindo I transient pain episodes and one Clavien–Dindo II urinary retention requiring 14 days of intermittent self-catheterization complicated by urinary tract infection. No intraoperative complications or reoperations occurred. Functional outcomes were marked, including major neurological and quality-of-life improvement. One patient previously wheelchair-dependent regained independent ambulation with the ability to walk several kilometres. Another patient achieved

complete discontinuation of analgesic therapy within two months postoperatively after long-term preoperative opioid/analgesic use. Urinary function normalized in all affected cases, and neuropathic symptoms showed substantial overall improvement or resolution. Median operative time was 240 minutes (150–420), median blood loss 0–350 mL, and median hospital stay 4 days (2–7).

Conclusions

The integration of Neuropelveology into complex laparoscopic pelvic pain surgery appears feasible and safe. Systematic pelvic nerve exploration enables identification of occult neurovascular entrapments frequently associated with refractory endometriosis-related pain. Early experience suggests that targeted neurolysis and vascular decompression can be effectively combined with endometriosis excision while maintaining low morbidity, offering a promising strategy to improve pain outcomes in complex patients.

ESGE35-0988 -
Free Communication

Laparoscopic removal of a large retroperitoneal mature teratoma located in the left obturator fossa.

Sadi Allahverdiyev[1], Namig Novruzov[2], Firangiz Azizova[3]
[1]Central Customs Hospital, Gynecology and Obstetrics, Baku, Azerbaijan
[2]Central Customs Hospital, General Surgery, Baku, Azerbaijan
[3]Central Customs Hospital, Obstetrics and Gynecology, Baku, Azerbaijan

Background

We present the case of 48-year-old patient, who had undergone open total abdominal hysterectomy and bilateral salpingo-oophorectomy with a Pfannenstiel incision 2 years ago, presented with complaints of tension and pain in the left groin area, pulling pain in the back of the left thigh during movement.

Methods

Examination (Pelvic MRI) revealed a solid fluid-filled cyst larger than 10 cm extending from the left retroperitoneal space to the obturator fossa.

Results

The patient underwent planned laparoscopic cyst removal. During laparoscopy, it was found that tumor was located in the retroperitoneal area, covered by the sigmoid colon mesentery and the left side wall of the urinary bladder.

The tumor was separated from the surrounding tissues and completely removed. Histological result: consistent with mature teratoma. No malignancy was detected. The patient was discharged home 2 days later with improvement. At the 2-month follow-up, the patient's complaints had completely resolved. No residual tumor was detected.

Conclusions

Retroperitoneal mature teratoma is a rare pathology. It is usually asymptomatic. This patient presented with symptoms of nerve compression due to its location close to the obturator nerve. Information about the characteristics and structure of the tumor is provided based on radiological imaging and histological opinion after removal.

ESGE35-0008 -
Free Communication

Laparoscopic demonstration of left hypogastric nerve, hypogastric fascia and sacral nerves

Baris Mulayim[1], *Sema Mulayim*[2]
[1]*Private Clinic, Obstetrics and Gynecology, Antalya, Türkiye*
[2]*vitale hospital, Obstetrics and Gynecology, Antalya, Türkiye*

Background

To demonstrate laparoscopic dissection of hypogastric nerve, hypogastric fascia and sacral nerves in case of pathologies of this so-called holly plane.

Methods

A 32-year-old virgin, 160cm/ 49kg woman admitted for dysmenorrhea, which was 10/8 according to visual analogue scale, who was diagnosed with bilateral endometrioma. She had regular menstruation, had no operation before, she was diagnosed with mild scoliosis. Her transabdominal ultrasound showed bilateral endometrioma; which was 5*3 cm on the left side and 2*3 cm on the right side. Her CA 125 level was within normal range, and AMH level was 3.18 ng/ml. Despite she had been on medical treatment, she suffered pelvic pain so laparoscopic endometrioma surgery was planned.

But our primary objective with this video presentation was to demonstrate how to dissect pelvic retroperitoneal so-called holly plane on the left side to the sacral nerves through medial to the infundibulopelvic ligament and iliac vessels, ureter, hypogastric nerve, hypogastric fascia and sacral nerves in a scenario of a patient who had diagnosed with endometriosis, vascular entrapment or tumor or any pathology. It is important to dissect iliac vessels first before excision of pathology over sacral nerves in order to prevent or manage bleeding.

The patient provided written informed consent for the publication of this case report and accompanying images.

Results

Patient was discharged on post-operative day 2 without any serious complaints or complications with medical treatment for secondary prevention of endometriosis.

Conclusions

Laparoscopic dissection of hypogastric nerve, hypogastric fascia and sacral nerves is feasible and reproducible after meticulous training.

https://player.vimeo.com/video/1172456835?autoplay=1

ESGE35-0190 -
Free Communication

Laparoscopic sacral plexus neuromodulation for chronic pelvic pain

Pornprom Ittiamornlert[1], Felix Zeppernick[2], Maryam En-Nosse[2], Sebastian Harth[3], Malgorzata Kolodziej[4], Ivo Meinhold-Heerlein[2]
[1]Faculty of medicine- Siriraj Hospital- Mahidol University- Thailand, Department of Obstetrics and Gynecology, Bangkok, Thailand
[2]Justus-Liebig-University Giessen, Department of obstetrics and Gynecology, Giessen, Germany
[3]Justus-Liebig-University Giessen, Department of Radiology, Giessen, Germany
[4]Justus-Liebig-University Giessen, Department of Neurosurgery, Giessen, Germany

Background

To demonstrate a neuromonitoring-guided laparoscopic technique for revision sacral plexus neuromodulation in a patient with chronic pelvic pain and extensive prior pelvic surgery.

Methods

We present a surgical video of a 40-year-old woman with long-standing therapy-resistant chronic pelvic pain, severe lumbar pain, and neuropelveologic symptoms. Her surgical history included multiple laparoscopic procedures for endometriosis and pelvic adhesive disease, including hysterectomy, ureterolysis, ovariopexy, and left adnexectomy. In 2019, she underwent implantation of a permanent neuromodulation system involving conus medullaris stimulation and left sacral plexus neuromodulation, resulting in significant symptomatic improvement. Progressive recurrent pelvic pain and right-sided radicular symptoms later developed secondary to suspected adhesions and electrode displacement.

Revision surgery was performed laparoscopically. Extensive adhesiolysis was first carried out to restore pelvic anatomy and remove the previously implanted left-sided neuromodulation system. Retroperitoneal nerve dissection was then performed on the right side with intraoperative neurostimulation-guided identification of the L5–S3 sacral nerve roots and sacral plexus. A new right sacral plexus neuromodulation electrode was subsequently implanted under direct laparoscopic visualization and neuromonitoring guidance.

Written informed consent for video recording and publication was obtained.

Results

The procedure was completed successfully without intraoperative complications. Total operative time was 160 minutes with an estimated blood loss of 20 mL. Postoperatively, the patient demonstrated satisfactory recovery and successful neuromodulation. At follow-up, she reported significant reduction in pelvic pain, high treatment satisfaction, improvement in quality of life, and return to normal daily activities.

Conclusions

Neuromonitoring-guided laparoscopic sacral plexus neuromodulation is feasible and effective in patients with chronic pelvic pain and complex prior pelvic surgery. Careful retroperitoneal dissection with precise neural identification may facilitate safe electrode revision and optimize neuromodulation outcomes in challenging neuropelveologic cases.

https://player.vimeo.com/video/1191249360?autoplay=1

ESGE35-0225 -
Free Communication

Laparoscopic anatomic identification of the inferior hypogastric plexus and nerve

Andreas Kavallaris[1,2], Antonis Gkoutzioulis[1], Panagiotis Papandreou[1], Stergios Kopatsaris[3], Dimitris Grigoriou[2], Dimitrios Zygouris[1]
[1]St. Luke's Hospital- Thessaloniki- Greece,
Department of Gynaecologic Oncology and Minimally invasive surgery, Thessaloniki, Greece
[2]Mother and Child Medical Center- Nicosia- Cyprus,
Department of Gynaecologic Oncology and Minimally invasive surgery, Nicosia, Cyprus
[3]Marienhospital Bottrop- Bottrop- Germany, Department of Gynaecology and Obstetrics, Bottrop, Germany

Background

To clarify the laparoscopic anatomy necessary for the nerve sparing radical hysterectomy and for the radical resection of deep infiltrating endometriosis. We meticulously separated the blood vessels and connective tissues to preserve, the pelvic splanchnic nerve, the hypogastric nerve and the bladder branch of the inferior hypogastric plexus. We present our technique, surgical and patient outcomes in patients that underwent laparoscopic nerve sparing surgery in our institution.

We aim to demonstrate the entire structure of the inferior hypogastric nerve and plexus in the female pelvis. We present data from 115 patients that were operated in St. Luke's Hospital in Thessaloniki during the last 12 years. All data were retrospectively collected and analysed, emphasizing on intraoperative and postoperative complications.

Methods

Operative procedure

Isolation of the deep uterine vein could preserve one of the branches of the pelvic splanchnic nerve. The hypogastric nerve in the lateral rectal wall was isolated to the inferior hypogastric plexus. During the division of the posterior leaf of the vesicouterine ligament, isolation of the inferior vesical vein could reveal the bladder branch from the inferior hypogastric plexus. Only the uterine branch from the inferior hypogastric plexus was isolated and divided. The T-shaped nerve plane consisting of the hypogastric nerve, the pelvic splanchnic nerve and the bladder branch from the inferior hypogastric plexus is preserved.

Results

In all patients the identification of the hypogastric nerve and plexus was passible. All patients recovered their urinary function completely by POD 3-5. This is a retrospective study of 72 patients with cervical cancer that underwent laparoscopic nerve sparing radical hysterectomy and 43 patients with deep infiltrating endometriosis. In all cases hypogastric nerve and hypogastric plexus were identified and preserved during the operation. The postoperative period was uneventful concerning voiding function.

Conclusions

Preservation of the pelvic splanchnic nerve as well as from the inferior hypogastric plexus can provide satisfactory postoperative voiding function and are crucial in cases of radical hysterectomy or deep infiltrating endometriosis. In all patients the identification of the hypogastric nerve and plexus was passible. All patients recovered their urinary function completely by POD 3-5.

https://player.vimeo.com/video/1191298671?autoplay=1

ESGE35-0485 -
Free Communication

Nerve-sparing laparoscopic excision of obturator nerve endometriosis associated with ureteral obstruction and hydronephrosis

Ahkam Göksel Kanmaz[1], Emrah Töz[2], Yaşam Kemal Akpak[2], Eda Güner Özen[2], Özgün Akbas[2]
[1]İzmir City Hospital, Department of Obstetrics and Gynaecology, İzmir- TR-MIGS, Türkiye
[2]İzmir City Hospital, Obstetrics and Gynaecology, İzmir, Türkiye

Background

Obturator nerve involvement represents an exceptionally rare manifestation of deep infiltrating endometriosis, with only eight symptomatic cases reported in the literature. Patients may present with neuropathic leg pain, gait impairment, and progressive neurological symptoms, often leading to delayed diagnosis and complex surgical management.

Methods

A 43-year-old woman presented with a two-year history of progressive left-sided pelvic pain radiating to the leg, difficulty walking, and poor response to analgesic therapy. Pelvic examination revealed tenderness and fullness on the left side of the cervix. Magnetic resonance imaging demonstrated a deep infiltrating endometriotic nodule originating from the left pelvic sidewall, extending along the ureter and infiltrating the obturator nerve region up to the bladder serosa. Grade 3 left hydronephrosis was also detected. Preoperatively, percutaneous nephrostomy and double-J ureteral stenting were performed to relieve urinary obstruction. The patient subsequently underwent nerve-sparing laparoscopic excision of the lesion with retroperitoneal dissection, ureterolysis, and meticulous neuroanatomical dissection.

Results

Complete laparoscopic excision of the endometriotic nodule was achieved without major intraoperative complications. The nephrostomy catheter was removed on postoperative day 5, the urinary catheter on postoperative day 10, and the double-J stent at postoperative month 3. At third-month follow-up, the patient reported complete resolution of pelvic pain and radiating leg pain. Minimal residual numbness persisted on the medial aspect of the left thigh. Imaging demonstrated persistent grade 1 hydronephrosis with preserved renal function.

Conclusions

This case highlights the importance of considering pelvic nerve endometriosis in patients presenting with neuropathic leg pain and gait disturbance. Advanced laparoscopic retroperitoneal nerve-sparing surgery is feasible and may provide significant neurological, urological, and symptomatic improvement in selected patients with complex deep infiltrating endometriosis.

https://player.vimeo.com/video/1191664470?autoplay=1

ESGE35-0746 -
Free Communication

Nerve-sparing surgery for deep infiltrating endometriosis with pelvic nerve and rectosigmoid involvement

Irem Müge Öztürk[1], Emre Kar[2], Mehmet Ceyhan[3], Ercan Baştu[4]
[1]Zara City Hospital, Obstetrics and Gynecology, Sivas, Türkiye
[2]Basaksehir Cam ve Sakura City Hospital, Obstetrics and Gynaecology, Istanbul, Türkiye
[3]Mehmet Ceyhan Clinic, Obstetrics and Gynaecology, Istanbul, Türkiye
[4]Prof. Dr. Ercan Bastu Endometriosis and Fertility Centre, Obstetrics and Gynecology, Istanbul, Türkiye

Background

Deep infiltrating endometriosis may involve the rectosigmoid colon and pelvic nerve region, causing severe pain, bowel symptoms, dyspareunia, and neuropathic complaints. In advanced cases, surgical management should aim not only for complete excision of endometriotic lesions but also for restoration of pelvic anatomy and preservation of pelvic organ function. This video demonstrates a systematic retroperitoneal, anatomy-based, nerve-sparing surgical approach in a patient with advanced deep infiltrating endometriosis involving the rectosigmoid colon and pelvic nerve region.

Methods

A 41-year-old multiparous woman presented with dysmenorrhea, heavy menstrual bleeding, dyschezia, dyspareunia, and right leg pain. Clinical examination and imaging revealed an adenomyotic uterus, a right uterosacral nodule, a rectosigmoid bowel nodule, and suspected appendiceal involvement.

The surgical objectives were complete excision of deep endometriotic lesions, restoration of normal pelvic anatomy, safe ureterolysis, and preservation of vital neurovascular structures. Surgery was initiated with bilateral retroperitoneal dissection. The pararectal spaces were developed, and both ureters were systematically identified, dissected, and mobilized from surrounding fibrotic tissue.

The rectosigmoid colon was densely adherent to the posterior uterus and upper vagina, resulting in marked distortion of normal pelvic anatomy. The rectovaginal space was carefully developed to restore anatomical planes. Further retroperitoneal dissection enabled clear visualization of the hypogastric plexus and sacral nerve region.

A deep infiltrating endometriotic nodule involving the right uterosacral ligament and extending toward the sacral nerve region was meticulously dissected under direct visualization using a nerve-sparing approach. After complete circumferential mobilization, the nodule was excised en bloc. A full-thickness discoid excision of the rectosigmoid nodule was then performed, followed by meticulous primary repair of the bowel wall. Suspected appendiceal involvement was not confirmed intraoperatively.

Results

Complete excision of deep endometriotic lesions was achieved while preserving adjacent neurovascular structures. The integrity of the bowel repair was confirmed with air, saline, and

methylene blue leak tests, with no evidence of leakage. No early postoperative complications were observed. The patient recovered uneventfully, her pain symptoms improved, and no new bladder, bowel, sexual, or neurological dysfunction was observed.

Conclusions

This case highlights the educational value of a systematic retroperitoneal, anatomy-based, nerve-sparing approach in advanced deep infiltrating endometriosis with rectosigmoid and pelvic nerve region involvement. Careful identification of the ureters, hypogastric plexus, and sacral nerve region may facilitate complete excision while minimizing functional morbidity.

https://player.vimeo.com/video/1195400971?autoplay=1

ESGE35-0162 -
Free Communication
Postconceptional simplified laparoscopic cervical cerclage: technique and results of a series of 164 cases

Huang Xiaowu[1], *Xu Ruonan*[2]
[1]*Fuxing Hospital- Capital Medical University, Hysteroscopic Center, Beijing, China*
[2]*Fuxing Hospital- Capital Medical University, Hysteroscopy Center, Beijing, China*

Background

Laparoscopic cervical cerclage (LCC) reduces the risk of mid-trimester miscarriage and preterm delivery in women with refractory cervical insufficiency. However, performing postconceptional LCC is challenging due to an enlarged, soft uterus, increased vascularity, and obscured anatomy. It is important to determine the correct anatomic landmark for suture placement—the internal cervical os (cervico-isthmic junction), medial to the uterine vessels. This study aimed to assess surgical and obstetrical outcomes in patients undergoing postconceptional LCC using a simplified technique: a special cup utero-elevator helps identify the cervico-isthmic junction, allowing easy needle puncture without opening the bladder reflection peritoneum or dissecting paracervical vessels.

Methods

This retrospective cohort study included 164 patients who underwent simplified postconceptional LCC for cervical insufficiency at a single tertiary hospital (from **January 2013 to July 2025**). Indications were previous failed vaginal cerclage (53 cases), previous cervical surgery (30 cases), or recurrent mid-trimester losses without prior cerclage (81 cases). Surgical parameters (blood loss, operation time, complications) and obstetric outcomes were recorded. Ethical approval was obtained from the institutional review board (NO. 2026FXHEC-KSP105). Informed consent was waived due to the retrospective design.

Results

Among the 164 cases, mean gestational age at surgery was 8.9±1.4 (range 7–14) weeks. Mean surgical time was 46.9±18.9 min and mean estimated blood loss was 11.9±17.8 ml. Comparing the >12 weeks (n=9) versus ≤12 weeks group (n=155), surgery time was longer in the >12 weeks group (66.3±24.8 vs. 45.7±18.0 min, p=0.002), but blood loss did not differ significantly (29.4±56.7 vs. 10.9±12.2 mL, p=0.129). No severe perioperative complications (e.g., conversion to laparotomy, bowel/bladder/ureter injury) occurred.

Four cases were lost to follow-up, four had early embryonic arrest, and one underwent termination for foetal malformation. Among the remaining 155 cases, live birth rates at ≥28 weeks, ≥34 weeks, and at term (>37 weeks) were 94.2% (146/155), 91.0% (141/155), and 74.2% (115/155), respectively. For singleton gestations (n=141), mean gestational age at delivery was 37.3±1.7 weeks and live birth rate was 94.3% (133/141). Eight mid-trimester losses occurred (six intrauterine foetal deaths, two amniotic sac prolapse). For twin gestations (n=14), mean gestational age at delivery was 35.5±1.5 weeks and live birth rate was 92.9% (13/14), with one loss due to uncontrolled uterine contraction.

Live birth rates did not differ between singletons and twins ($p=0.584$), but gestational age at delivery was significantly longer for singletons ($p<0.001$).

Conclusions

This simplified postconceptional LCC technique is safe and effective for selected patients with cervical insufficiency. Performing LCC before 12 gestational weeks is recommended, as surgery becomes more difficult with an enlarged uterus after 12 weeks. Singleton gestations have a longer gestational age at delivery than twin gestations.

ESGE35-0173 -
Free Communication

Persistent pain and reoperation after hysterectomy for chronic pelvic pain: the role of ovarian conservation versus bilateral salpingo-oophorectomy

Nura Fitnat Topbas Selcuki[1], *Sahara Pandit*[2], *Michal Krassowski*[3], *Katy Vincent*[1]
[1]*University of Oxford, Nuffield Department of Women's and Reproductive Health, Oxford, United Kingdom*
[2]*North Bristol NHS Trust, Obstetrics and Gynaecology, Bristol, United Kingdom*
[3]*University of Oxford, Open Teams, Oxford, United Kingdom*

Background

Hysterectomy is a common surgical intervention for chronic pelvic pain (CPP), yet the effect of concurrent bilateral salpingo-oophorectomy (BSO) on postoperative pain and reoperation risk remains poorly defined. This systematic review and meta-analysis aimed to compare persistent pelvic pain and reoperation rates following hysterectomy with BSO versus ovarian conservation in women undergoing surgery for CPP.

Methods

A systematic review and meta-analysis was conducted in accordance with PRISMA guidelines, with prospective registration on PROSPERO (CRD42020138587). MEDLINE, EMBASE, CINAHL, and CENTRAL were searched from inception to December 2024. eligible studies enrolled adult women (≥18 years) undergoing hysterectomy for CPP as the primary indication and reported persistent pain or reoperation rate. risk of bias was assessed using a structured tool adapted for observational studies. Pooled risk ratios (RR) with 95% confidence intervals (CI) were calculated using random-effects meta-analysis (DerSimonian and Laird), with statistical heterogeneity quantified by I^2.

Results

Eight studies published between 1995 and 2022 met eligibility criteria, enrolling 10,287 women (9,189 ovarian conservation; 1,098 BSO). no randomised controlled trials were identified. Seven studies reported persistent pain. combined rates at six months were 35.4% with ovarian conservation versus 17.2% with BSO; at three years, 45.5% versus 10.9%. Meta-analysis at all time points yielded non-significant summary RRs however with substantial heterogeneity (I^2 73.8–91.3%). Reoperation data were available from two studies (n=308). ovarian conservation was associated with a statistically significant nearly fourfold higher risk of reoperation at five years (RR 3.81, 95% CI 1.23–11.81), while the two-year estimate was directionally consistent but non-significant (RR 1.98, 95% CI 0.67–5.92).

Conclusions

Ovarian conservation at hysterectomy for CPP is associated with a significantly higher risk of reoperation at five years compared with BSO. Persistent pain rates are directionally higher with ovarian conservation at most time points, though pooled estimates are constrained by marked heterogeneity and an exclusively observational evidence base. Adequately powered prospective

studies incorporating patient-reported pain outcomes are urgently needed to inform this clinically important intraoperative decision.

ESGE35-0568 -
Free Communication

Minimally invasive management of placenta accreta spectrum at 14 weeks of gestation: total laparoscopic hysterectomy in the early second trimester

Can Dinç[1], Ömer Faruk Öz[1], Selen Doğan[1], Nasuh utku Doğan[1], Murat Özekinci[2], İnanç İbrahim Mendilcioğlu[3]
[1]Akdeniz University, Obstetrics and Gynaecology- TR-MIGS, Antalya, Türkiye
[2]Akdeniz University, Reproductive Endocrinology and Infertility- Obstetrics and Gynaecology- TR-MIGS, Antalya, Türkiye
[3]Akdeniz University, Maternal-Foetal Medicine- Obstetrics and Gynaecology- TR-MIGS, Antalya, Türkiye

Background

To present a case of placenta accreta spectrum (PAS) diagnosed at 14 weeks of gestation and managed by total laparoscopic hysterectomy (TLH), and to demonstrate the operative technique including retroperitoneal uterine artery ligation, bladder dissection in the presence of focal serosal invasion, and safe completion of minimally invasive hysterectomy in the early second trimester.

Methods

A 32-year-old woman (gravida 5, para 3, one miscarriage; three prior caesarean sections) was referred at 14 weeks and two days of gestation following identification of absent foetal cardiac activity at an external centre. Transvaginal ultrasound confirmed anhydramnios and absence of foetal cardiac activity with foetal biometry consistent with gestational age. Clinical assessment and imaging raised strong suspicion of placenta accreta spectrum, and surgical management was planned accordingly. Total laparoscopic hysterectomy was performed. The retroperitoneal space was entered bilaterally, and the uterine arteries were dissected and ligated at their origin prior to uterine manipulation.

Bladder dissection was then performed. Focal placental invasion of the uterine serosa was identified at the lower uterine segment; the bladder was carefully mobilised without entry into the bladder lumen, and the area of serosal invasion was managed without extension to cystotomy. The hysterectomy was completed laparoscopically and the specimen delivered vaginally.

Results

TLH was completed without conversion to laparotomy. No intraoperative bladder or ureteric injury occurred.

Histopathological examination confirmed placenta accreta with trophoblastic invasion exceeding two-thirds of the uterine wall thickness. The postoperative course was uneventful. The patient was discharged on postoperative day two without complications.

Conclusions

Total laparoscopic hysterectomy is a feasible minimally invasive option for placenta accreta spectrum diagnosed in the early second trimester, when performed by an experienced team in an appropriately equipped centre. Retroperitoneal uterine artery ligation prior to uterine manipulation provides early haemostatic control and reduces intraoperative blood loss. Careful laparoscopic bladder dissection allows safe management of focal serosal invasion without conversion. Early second trimester diagnosis of PAS, while rare, should prompt multidisciplinary surgical planning.

https://player.vimeo.com/video/1191691590?autoplay=1

ESGE35-0728 -
Free Communication

Improving same-day discharge rates following total laparoscopic hysterectomy through a standardized enhanced recovery pathway: A quality improvement project in a district general hospital

Hira Fatima[1], Samreen Muhammad[2], Manos Damigos[1], Chukwuemeka Atuanya[1], Remko Beukehnholdt[1], Shirsha Maitra[3]
[1]Darlington Memorial Hospital, Gynaecology and Obstetrics, Darlington, United Kingdom
[2]Sheffield Teaching Hospital, Gynaecology and Obstetrics, Sheffield, United Kingdom
[3]Singleton Hospital- Swansea Bay Healthboard, Gynaecology and Obstetrics, Swansea, United Kingdom

Background

Same-day discharge following total laparoscopic hysterectomy (TLH) is increasingly important within gynaecological surgery particularly in district general hospitals managing increasing surgical demand and limited inpatient capacity. Despite uncomplicated surgery many patients in our unit continued to stay overnight due to variation in perioperative practice discharge planning and patient expectations. We aimed to assess whether introduction of a standardized enhanced recovery pathway could improve same-day discharge rates following TLH without compromising patient safety.

Methods

This was a two-cycle quality improvement project carried out in a district general hospital between October 2025 and March 2026. Baseline data were collected retrospectively for 24 patients undergoing TLH for indications including fibroids adenomyosis endometriosis heavy menstrual bleeding endometrial hyperplasia and selected early endometrial malignancy cases.

Outcome measures included same-day discharge rate length of stay postoperative nausea and vomiting opioid requirement 30-day readmission and perioperative complications.

Following baseline review a standardized enhanced recovery pathway was introduced. This included focused preoperative counselling regarding same-day discharge, standardisation of analgesia and antiemetic protocols, early catheter removal, mobilisation within six hours following surgery and use of a structured discharge checklist.

A second cycle included a further 24 patients undergoing TLH following implementation of the intervention.

Results

Following introduction of the enhanced recovery pathway same-day discharge rates improved from 25.0% (6/24) to 70.8% (17/24). Mean postoperative length of stay reduced from 27 hours to 10 hours.

Postoperative opioid requirement reduced from 58.3% to 29.2% while postoperative nausea and vomiting reduced from 29.2% to 8.3%. Thirty-day readmission rates remained low in both groups

(8.3% vs 4.2%) with no increase in perioperative complications return to theatre or unplanned review following discharge. No cases required conversion to laparotomy.

The pathway was associated with an estimated reduction of 25 inpatient bed-days across the study period with potential cost savings for the NHS through reduced bed occupancy and improved patient flow. Earlier discharge also appeared to reduce disruption to patients' daily life with faster return to normal activity

Conclusions

Introduction of a standardized enhanced recovery pathway significantly improved same-day discharge rates following TLH in a district general hospital setting without compromising patient safety including in selected benign, pre-malignant and oncological cases. In addition to improving patient recovery the pathway demonstrated potential financial benefit for the NHS through reduced inpatient bed utilisation and more efficient use of surgical resources. Wider adoption of similar pathways may provide a practical and cost-effective model for managing increasing surgical demand within NHS gynaecology services.

ESGE35-0699 -
Free Communication

Feasibility and outcomes of total laparoscopic hysterectomy compared to abdominal hysterectomy in large sized uterus: a prospective randomized comparative study

Mohammed Mamdouh Saleh[1], Ahmed Mostafa Mohamed[2], Adel Shafik Salah El DIn[3], Shaimaa Elsayed Belal[2], Hossam Abdou Elmansy[2], Mai Raafat[2]
[1]Suez Canal University, Obstetrics and Gynaecology, Ismaillia, Egypt
[2]Helwan University Hospitals, OBS/GYN Department, Cairo, Egypt
[3]Ain Shams University, OBS/GYN Department, Cairo, Egypt

Background

Hysterectomy remains the most commonly performed gynaecological procedure worldwide. While total abdominal hysterectomy (TAH) has long been the standard approach, total laparoscopic hysterectomy (TLH) has emerged as a minimally invasive alternative. Performing TLH on large uteri remains technically challenging, and evidence comparing both approaches in this specific context is still evolving. This study aims to investigate the feasibility and safety of TLH compared to TAH in women with large uteri

Methods

A prospective, randomized comparative surgical interventional study was conducted at Badr University Hospital enrolling 36 women with benign uterine pathology (fundal level >12 weeks) scheduled for hysterectomy. Patients were randomly assigned into two equal groups: Group I (TAH, n=18) and Group II (TLH, n=18). Primary outcomes were operative time and intraoperative blood loss. Secondary outcomes included intraoperative complications, specimen extraction time, postoperative pain, and duration of hospital stay.

Results

Both groups were comparable in age, BMI, surgical history, parity, and uterine pathology. No significant difference was found in operative duration (1.93±0.37 h vs. 1.88±0.35 h, P=0.648), fundal level (17.22±2.76 cm vs. 17.56±2.33 cm, P=0.698), or uterine volume (657.72±376.86 cm^3 vs. 577.72±349.6 cm^3, P=0.514). No conversions to laparotomy occurred. Intraoperative blood loss was significantly lower in the TLH group (216.67±72.76 ml compared to TAH 333.33±59.41 ml, P<0.001). Hospital stay was significantly lower in TLH group (14.39±3.71 h vs. 28.06±3.92 h, P< 0.001). Complication rates were low and comparable, with one bladder injury in each group and one ureteric injury in the TLH group.

Conclusions

Total laparoscopic hysterectomy is a safe and feasible alternative to total abdominal hysterectomy for women with large benign uteri, offering significantly reduced intraoperative blood loss and hospital stay, while maintaining comparable operative time and complications rates. These findings support TLH as the preferred approach for eligible patients with large uteri, but larger studies are needed.

ESGE35-0886 -
Free Communication

Comparative perioperative and postoperative outcomes of minimally invasive hysterectomy techniques: laparoscopic, vaginal, and vaginal natural orifice transluminal endoscopic surgery approaches

Zuhal Altintas Sakaoglu[1], Meryem Hocaoglu[2], Neslisah Ar[2], Busra Albayrak[2], Seyma Tastekin[2], Abdulkadir Turgut[2]
[1]Istanbul Medeniyet University,
Department of Obstetrics and Gynaecology- Goztepe Prof. Dr. Suleyman Yalcin City Hospital, Istanbul, Türkiye
[2]Istanbul Medeniyet University,
Department of Obstetrics and Gynaecology- Goztepe Prof. Dr. Suleyman Yalcin City Hospital, Istanbul, Türkiye

Background

The aim of this study was to compare the perioperative and postoperative outcomes of laparoscopic, vaginal, and vaginal natural orifice transluminal endoscopic surgery (vNOTES) hysterectomies performed for benign gynecologic indications.

Methods

This retrospective single-center cohort study included patients who underwent vNOTES, total laparoscopic hysterectomy (TLH), or vaginal hysterectomy for benign gynecologic indications between 2022 and 2026. All procedures were performed by a single surgeon. Demographic characteristics, obstetric history, perioperative findings, and postoperative outcomes were analysed. Continuous variables were compared using the Kruskal–Wallis test followed by Dwass–Steel–Critchlow–Fligner post-hoc analysis. Categorical variables were evaluated using the chi-square test. Multivariable linear regression analyses were performed to identify independent predictors of operative time and postoperative hospital stay.

Results

A total of 183 patients were included; 62 underwent vNOTES, 89 TLH, and 32 vaginal hysterectomies. BMI values were similar among groups ($p=0.995$). Parity and the number of normal spontaneous deliveries (NSD) were higher in the vaginal hysterectomy group compared with the TLH group ($p=0.002$ and $p<0.001$, respectively), whereas caesarean section history was more frequent in the TLH group ($p<0.001$).

Post-hoc analyses demonstrated that operative time was longest in the TLH group and significantly longer than in both the vNOTES and vaginal hysterectomy groups ($p<0.001$ and $p=0.010$, respectively). No significant difference in operative time was observed between the vNOTES and vaginal hysterectomy groups ($p=0.297$). Uterine weight was lower in the vaginal hysterectomy group compared with the TLH and vNOTES groups ($p<0.001$ and $p=0.023$, respectively). In multivariable regression analysis adjusted for age, BMI, and caesarean section history, operative time remained longer in the TLH group compared with the vNOTES group ($\beta=63.3$, 95% CI: 38.5–88.1, $p<0.001$).

Postoperative hospital stay was significantly shorter in the vNOTES group compared with the TLH group ($p<0.001$). No significant difference was observed between the vNOTES and vaginal hysterectomy groups ($p=0.089$) or between the TLH and vaginal hysterectomy groups ($p=0.200$). Postoperative haemoglobin, haematocrit, and platelet values were similar among groups ($p>0.05$). In multivariable regression analysis adjusted for age, BMI, uterine volume, and caesarean section history, TLH was independently associated with longer postoperative hospital stay compared with vNOTES ($\beta=1.02$, $p<0.001$). Increased age was also independently associated with prolonged postoperative hospital stay ($p=0.012$).

Conclusions

vNOTES hysterectomy was associated with shorter operative time and postoperative hospital stay compared with TLH, with outcomes comparable to vaginal hysterectomy. Vaginal hysterectomy was more frequently preferred in older and multiparous patients with lower uterine weights, whereas vNOTES was also feasible in patients with larger uterine volumes. These findings suggest that the vNOTES approach may represent an effective minimally invasive surgical alternative for benign gynecologic disease within a standardized single-surgeon setting.

ESGE35-0661 -
Free Communication

Glow and go: paraaortic lymphadenectomy in the icg era

Muhterem Melis Canturk[1], *Burak Giray*[1], *Oytun Turkkan*[1], *Dogan Vatansever*[1], *Cagatay Taskiran*[1]
[1]*Koc University Hospital,*
Department of Obstetrics and Gynaecology / Division of Gynaecologic Oncology, Istanbul, Türkiye

Background

Ureteral injury is among the most serious complications of paraaortic lymphadenectomy in gynecologic oncology. Indocyanine green (ICG) fluorescence imaging has emerged as a promising technique for real-time ureteral identification during complex retroperitoneal dissection. We describe a standardized technique for laparoscopic infrarenal paraaortic lymphadenectomy with ICG fluorescence-guided ureteral identification, emphasize anatomical landmarks, exposure strategy, and intraoperative safety measures.

Methods

Bilateral ureteral catheters were placed at the outset, with ICG (one ampule diluted in 20 mL saline; 2 mL per side) instilled intraureteral to enable continuous fluorescence visualization. Dissection was performed using the Powerseal energy device. The right ureter was identified early in the dissection prior to any nodal excision. A surgical sponge was used to elevate and suspend the descending colon and its mesentery toward the anterior abdominal wall, displacing the left ureter out of the operative field. The lymphadenectomy was carried out systematically between the inferior mesenteric artery inferiorly and the left renal vein superiorly, encompassing the left paraaortic, pre-caval, and paracaval nodal regions. Titanium clips were applied to all lymphatic pedicles to reduce the risk of postoperative lymphorrhea.

Results

Both ureters were continuously visualized under ICG fluorescence throughout the entire dissection. Real-time fluorescence guidance confirmed ureteral position at each critical step, including during left paraaortic and paracaval nodal excision, without evidence of ureteral injury.

Conclusions

ICG fluorescence-guided ureteral identification via intraureteral instillation provides reliable, real-time anatomical confirmation during laparoscopic paraaortic lymphadenectomy. Combined with systematic colon suspension and meticulous lymphatic clipping, this technique offers a reproducible framework for minimizing the risk of ureteral injury and lymphorrhea in retroperitoneal nodal dissection.

https://player.vimeo.com/video/1194347084?autoplay=1

ESGE35-0897 -
Free Communication

Laparoscopic bowel reconstruction after emergency laparotomy and temporary stoma creation in advanced ovarian cancer

Filippo Cucinella[1], Matteo Marchetti[1], Tommaso Vezzaro[1], Andrea Mura[1], Roberto Tozzi[1]
[1]Department of Gynecology and Obstetrics- University of Padua,
Division of Women and Children's Health, Padua, Italy

Background

Emergency laparotomy with temporary stoma creation for bowel obstruction in advanced ovarian cancer represents a challenging scenario for subsequent minimally invasive surgery because of postoperative adhesions, distorted anatomy and complexity of bowel reconstruction. This video demonstrates a stepwise laparoscopic approach for restoration of bowel continuity during interval cytoreductive surgery.

Methods

A 65-year-old woman with high-grade serous ovarian carcinoma initially presented with bowel obstruction at the rectosigmoid junction requiring emergency exploratory laparotomy and loop colostomy creation. Following six cycles of neoadjuvant chemotherapy and subsequent laparoscopic assessment demonstrating disease amenable to complete cytoreduction, interval debulking surgery was performed within the ULTRALAP trial.

The video focuses on the bowel reconstructive phase and highlights the principal surgical steps. Reconstruction of the double-barrel stoma was initially performed through the previous stoma site. Subsequent assessment of bowel mobility demonstrated the need for additional adhesiolysis and mobilization of the descending colon toward the splenic flexure to achieve a tension-free reconstruction. Intracorporeal colorectal anastomosis was completed using a circular stapling device. Anastomotic integrity was assessed using an air leak test, followed by omental coverage and placement of a perianastomotic drain.

Results

Complete macroscopic cytoreduction (R0) and restoration of bowel continuity were successfully achieved through a fully laparoscopic approach. The previous stoma site was utilized both for bowel reconstruction and specimen extraction, including the en bloc pelvic specimen, omentum and peritoneal specimens, avoiding the need for an additional abdominal extraction site. Final histology demonstrated high-grade serous carcinoma with Chemotherapy Response Score (CRS) 3.

Conclusions

Previous emergency laparotomy with temporary stoma creation should not necessarily preclude minimally invasive interval cytoreductive surgery in selected patients with advanced ovarian cancer. This case illustrates the feasibility of the ULTRALAP approach in achieving complete macroscopic cytoreduction (R0) and safe restoration of bowel continuity, even in complex surgical scenarios. When

feasible, a structured laparoscopic strategy may allow complete cytoreduction while potentially preserving the benefits associated with minimally invasive surgery.

https://player.vimeo.com/video/1195677915?autoplay=1

ESGE35-0878 -
Free Communication

From vulva to retropubic space: laparoscopic approach to cellular angiofibroma

Olga Khrustaleva[1], Alissa Seljanko[2], Tatiana Zakharova[2], Katrin Kressel[3], Georgi Džaparidze[4]
[1]West Tallinn Central Hospital- Women's Clinic, Centre of Gynaecology, Tallinn, Estonia
[2]West Tallinn Central Hospital- Women's Clinic, Centre of Gynaecology, Tallinn, Estonia
[3]West Tallinn Central Hospital, Centre of Radiology, Tallinn, Estonia
[4]East Tallinn Central Hospital- Women's Clinic, Centre of Gynaecology- Centre of Pathology, Tallinn, Estonia

Background

Cellular angiofibroma (CAF) is a rare benign mesenchymal tumor of the lower female genital tract, most commonly arising in the vulvovaginal region. Due to its slow growth, well-circumscribed appearance, and nonspecific presentation, it is frequently misdiagnosed as a Bartholin cyst or other benign vulvar lesion. We present rare case of deep vulvovaginal CAF extending into the retropubic space, managed using combined laparoscopic and vaginal approach.

Methods

A 41-year-old woman presented with slowly growing painless mass of the right labia majora, clinically suspected to be 3cm Bartholin cyst. During first vaginal surgery, well-defined elongated tubular mass extending from the right labia majora toward the retropubic space was identified instead. Due to the absence of preoperative imaging and close proximity to the bladder and urethra, complete excision was not safely possible during the initial procedure. Histopathology confirmed benign CAF.
After 1.5 years, the patient developed enlargement of the right labia majora. MRI demonstrated residual tumor tissue with progressive enlargement up to 10cm, extending toward the right labia majora. The patient consented to combined laparoscopic and vaginal excision.

Results

The first step of laparoscopy was development of the Retzius space. The median umbilical ligament was retracted and incised, followed by dissection within the avascular plane above the peritoneum and umbilicovesical fascia. Pneumoperitoneum facilitated exposure of the retropubic space. The tumor origin was identified at the pubocervical fascia, and careful dissection allowed progressive mobilization of the smooth encapsulated lesion. Under laparoscopic guidance, the mass was completely shelled out through a right labial incision. Final histopathology confirmed benign CAF.

Conclusions

CAF is rare benign mesenchymal soft-tissue tumor of the vulvovaginal region, often misdiagnosed as Bartholin cyst due to its slow growth and asymptomatic presentation. Complete surgical excision is the treatment of choice. In our case, a combined laparoscopic and vaginal approach enabled radical excision while preserving surrounding structures and minimizing recurrence risk.

https://player.vimeo.com/video/1195700015?autoplay=1

ESGE35-0917 -
Free Communication

Laparoscopic utero-ovarian ligament plication for prevention of recurrent ovarian torsion: a video case report

Maria Bordas Solé[1], Anna Ruano Lopez[1], Laura Mañalich Barrachina[1], Sonia Monreal Clua[1], Diana Guerrero Lojano[1], Maria Elena Suarez Salvador[1]
[1]Vall Hebron University Hospital, Obstetrics and Gynaecology, Barcelona, Spain

Background

Recurrent ovarian torsion is a rare but clinically significant condition in reproductive-age women, with no standardized surgical strategy for prevention. Oophoropexy techniques have been increasingly described to preserve ovarian function and reduce the risk of retorsion. This video demonstrates laparoscopic utero-ovarian ligament plication as a fertility-preserving approach in a patient with multiple episodes of recurrent ovarian torsion.

Methods

A 31-year-old woman with recurrent left ovarian torsion requiring four previous laparoscopic detorsion procedures, including ovarian cystectomy and prior left oophoropexy, presented with acute pelvic pain. Transvaginal ultrasound demonstrated an enlarged edematous left ovary without Doppler flow, suggestive of recurrent torsion. The surgical video shows laparoscopic exploration, ovarian detorsion, ovarian cystectomy, and subsequent plication of the left utero-ovarian ligament using a continuous 2-0 Vicryl suture.

Results

Laparoscopic exploration revealed a left ovary twisted four times around its pedicle and enlarged by a 3 cm solid lesion compatible with ovarian fibroma. Following atraumatic detorsion, ovarian reperfusion was achieved, allowing ovarian preservation. Cystectomy was successfully performed, followed by utero-ovarian ligament plication to reduce adnexal mobility while preserving tubo-ovarian anatomy and fertility. No intraoperative complications occurred. At one-month follow-up, the patient remained asymptomatic without pelvic pain.

Conclusions

Laparoscopic utero-ovarian ligament plication is a simple, reproducible, and fertility-sparing technique that may help prevent recurrent ovarian torsion in selected patients undergoing conservative ovarian surgery.

https://player.vimeo.com/video/1195756885?autoplay=1

ESGE35-0014 -
Free Communication

Clinical and sonographic predictors of caesarean scar niche formation and associated symptoms: a prospective cohort study

Moran Nardi-Arad[1], Liat Mor[1], Eldar Volpart[1], Ohad Gluck[1], Eran Weiner[1], Ron Sagiv[1]
[1]Edith Wolfson Medical Center, Obstetrics & Gynaecology, Holon, Israel

Background

Caesarean scar niche, an anatomic defect at the uterine incision site, has been associated with abnormal uterine bleeding, pelvic pain, and subfertility. However, the determinants of niche development and its clinical significance remain incompletely understood.
This study aimed to identify predictors of caesarean scar niche formation, and to examine their association with postoperative symptoms.

Methods

In this prospective cohort study, women undergoing elective or emergent caesarean delivery were evaluated 3–6 months postpartum. Participants completed standardized questionnaires assessing postmenstrual bleeding, dysmenorrhea, dyspareunia, and chronic pelvic pain. Transvaginal ultrasound assessed caesarean scar morphology, including adjacent myometrial thickness (AMT), residual myometrial thickness (RMT), AMT/RMT ratio, and niche width. A niche was defined as a myometrial indentation ≥2 mm, and large niche as an AMT/RMT ratio ≤0.5, or RMT≤3 mm. Multivariate logistic regression analyses were used to identify predictors of niche formation, large niche, and symptoms.

Results

Among 381 women included in the analysis, 243 (63.8%) were found to have a caesarean scar niche, of whom 92 (24.1% of the total cohort) had a large niche. Niche formation was significantly more common among women with higher body mass index (BMI) (31.1±6.0 vs. 29.1±4.9; p=0.032). In multivariable analysis, both higher BMI (aOR 1.07, 95% CI 1.00–1.14; p=0.035) and emergent caesarean delivery (30.4% vs. 28.9%; aOR 3.57, 95% CI 1.11–11.49; p=0.033) remained independent predictors of niche formation. Large niche was independently associated with diabetes mellitus (9.7% vs. 2.6%; p=0.017) and lower foetal station at the time of caesarean delivery (p = 0.029). Severe symptoms were independently associated with repeated caesarean delivery (29.3% vs. 21.0%; aOR 2.98, 95% CI 1.09–8.15; p=0.033) and hormonal contraceptive use (29.6% vs. 20.2%; aOR 3.42, 95% CI 1.38–8.48; p=0.008). Importantly, no association was observed between uterine closure technique - barbed versus Vicryl sutures, and the risk of niche formation (59.2% vs. 62.3%; aOR 1.02, 95% CI 0.46–2.19; p=0.976).

Conclusions

In this large cohort, higher BMI and emergent caesarean delivery independently predicted caesarean scar niche formation, while diabetes mellitus and lower foetal station at the time of delivery were associated with the development of larger defects. Notably, the use of barbed sutures was not

associated with an increased risk of niche formation.
These findings support the role of early targeted sonographic assessment in risk stratification and in guiding personalized counselling and follow-up.

ESGE35-0175 -
Free Communication

Loss of WT1 causes agenesis of the female reproductive tract via disruption of Müllerian duct elongation

Jia Kang[1], *Lan Zhu*[1]
[1]*Peking Union Medical College Hospital, Obstetrics and Gynaecology, Beijing, China*

Background

The Müllerian ducts are embryonic precursors of the female reproductive tract, giving rise to the fallopian tubes, uterus, and upper vagina. Developmental disturbances of these structures can result in severe congenital anomalies such as Mayer-Rokitansky-Küster-Hauser (MRKH) syndrome. While several signaling pathways regulating Müllerian duct formation have been identified, the role of the Wilms' tumor suppressor gene (Wt1) in female reproductive tract development remains poorly understood.

Methods

To investigate the function of Wt1, we generated conditional knockout (cKO) mice using Amhr2-Cre to specifically delete Wt1 in the Müllerian mesenchyme. Histological, immunohistochemical, and wholemount immunofluorescence analyses were performed to evaluate reproductive tract morphology and gene expression during embryogenesis and postnatal development.

Results

WT1 was found to be highly expressed throughout the development of the Müllerian duct and postnatal uterus. Unlike global Wt1 null mice, Wt1 cKO females were viable but completely infertile, displaying agenesis of the oviduct, uterus, and vagina, which were replaced by a thin membranous structure. Embryonic analysis revealed that Müllerian duct elongation was arrested around embryonic day 13.5 in mutants. Moreover, expression of WNT7A, a key epithelial marker essential for duct development, was markedly reduced, suggesting that WT1 may regulate epithelial–

mesenchymal interactions through WNT7A.



Conclusions

Our findings demonstrate that WT1 plays an indispensable role in female reproductive tract formation by regulating Müllerian duct elongation and differentiation. This study provides novel mechanistic insights into the molecular basis of congenital reproductive tract anomalies and highlights WT1 as a critical upstream regulator in female tract development.

ESGE35-0318 -
Free Communication

Association of uterine contractility characteristics at embryo transfer (ET) and ongoing pregnancy in IVF/ICSI patients with dysmenorrhoea – the WAVES method in a Chinese population

Connie Rees[1], *Yizhou Huang*[2], *Xijing Chen*[3], *Qiong Luo*[4], *Massimo Mischi*[2], *Benedictus Schoot*[5]
[1]*Catharina Hospital, Gynaecology and Obstetrics, Eindhoven, The Netherlands*
[2]*Eindhoven University of Technology, Signal Processing Systems, Eindhoven, The Netherlands*
[3]*Women's Hospital School of Medicine Zhejiang University, Reproductive Endocrinology, Hangzhou, China*
[4]*Women's Hospital- Zhejiang University School of Medicine-, Obstetrics, Hangzhou, China*
[5]*Catharina Hospital Eindhoven, Obstetrics and Gynaecology, Eindhoven, The Netherlands*

Background

We aimed to investigate whether specific uterine contractility characteristics assessed at the time of embryo transfer (ET) are associated with ongoing pregnancy (OP) in IVF/ICSI patients with dysmenorrhoea. In particular, this study aimed to evaluate whether uterine contraction coordination, as measured using the WAVES method, may reflect underlying uterine dysfunction and provide prognostic value for reproductive outcomes.

Methods

This preliminary subgroup analysis is part of an ongoing prospective observational cohort study conducted at the Women's Hospital, Zhejiang University School of Medicine, Hangzhou, China. From 2024 onwards, 68 IVF/ICSI patients undergoing fresh or frozen ET were included, of whom 29 reported dysmenorrhoea. Patients were included regardless of IVF/ICSI indication, stimulation protocol, or embryo quality.

Immediately prior to ET, all patients underwent a 4-minute transvaginal ultrasound examination in the mid-sagittal uterine plane. Ultrasound recordings were analysed offline using the WAVES method, a dedicated speckle tracking and strain analysis technique used to quantify uterine contractility. Parameters extracted included contraction frequency, amplitude, direction, velocity, and coordination. Clinical and contractility characteristics were compared between patients with and without OP using chi-squared analysis, independent t-tests, and Mann–Whitney U tests where appropriate.

Results

Among the dysmenorrhoeic subgroup, 12 patients achieved OP and 11 did not. Baseline characteristics, including age, BMI, infertility duration, endometrial thickness, serum progesterone levels at ET, fertilization method, embryo quality, stage of embryo transfer (day 3 versus day 5), and single versus double embryo transfer, were comparable between groups (all $p>0.05$).

Patients achieving OP demonstrated significantly higher uterine contraction frequency (1.66 ± 0.42 vs. 1.41 ± 0.26 contractions/minute; $p=0.011$) and contraction velocity (0.97 ± 0.16 vs. 0.82 ± 0.12

mm/second; p=0.015) compared with patients without OP. In addition, better uterine contraction coordination at ET was significantly associated with OP (-0.12 ± 0.40 vs. 0.13 ± 0.26; p=0.011).

Conclusions

Uterine contractility characteristics measured at ET appear to be associated with subsequent ongoing pregnancy in IVF/ICSI patients with dysmenorrhoea. In particular, contraction coordination may represent a functional marker of underlying uterine dysfunction and reproductive potential. These preliminary findings support further investigation of uterine contractility assessment as a potential biomarker for patient stratification and individualized reproductive care in symptomatic IVF/ICSI populations.

ESGE35-0328 -
Free Communication

Evaluation of the diagnostic value of MRI in patients with accessory cavitated uterine malformation and cystic adenomyosis

Zichen Zhao[1], Yafei Qi[2], Qingyue Zheng[3], Huadan Xue[2], Lan Zhu[3]
[1]Peking Union Medical College Hospital- Chinese Academy of Medical Sciences and Peking Union Medical College, Department of Obstetrics and Gynaecology, Beijing, China
[2]Peking Union Medical College Hospital- Chinese Academy of Medical Sciences and Peking Union Medical College, Department of Radiology, Beijing, China
[3]Peking Union Medical College Hospital- Chinese Academy of Medical Sciences and Peking Union Medical College, Department of Obstetrics and Gynaecology, Beijing, China

Background

This study aimed to analyze the preoperative MRI features of accessory cavitated uterine malformation (ACUM) and cystic adenomyosis and explore the clinical diagnostic value of MRI for differentiating these two uterine lesions.

Methods

This is a retrospective study comparing patients diagnosed with ACUM and cystic adenomyosis. All patients underwent preoperative pelvic MRI scanning with conventional T1WI, T2WI and DWI sequences. We comparatively analysed MRI manifestations including lesion location, size, morphology, structural characteristics, peripheral myometrial changes, junctional zone thickness, uterine cavity morphology and concurrent pelvic lesions in the two groups.

Results

A total of 30 patients confirmed by postoperative pathology were enrolled, including 16 ACUM patients (mean age: 25.8 years, range: 15–39 years) and 14 patients with cystic adenomyosis (mean age: 35.5 years, range: 19–45 years). All patients presented with dysmenorrhea. Some of them presented with lumbago or acyclic abdominal pain. Both lesions showed typical layered MRI features, with T2-hypointense peripheral myometrial rims and T1-hyperintense central cystic hematomas. ACUM lesions were mostly solitary, round or oval, and predominantly located at the uterine fundal lateral wall, with a high incidence of concentric ring structures and rare junctional zone thickening or combined uterine adenomyosis. In contrast, cystic adenomyosis lesions were widely distributed, prone to be multiple and irregular, and accompanied by uneven peripheral myometrial thickness and frequent uterine cavity compression. Additionally, cystic adenomyosis was commonly combined with junctional zone thickening, uterine fibroids, and ovarian endometriosis, which were rarely observed in ACUM cases.

Conclusions

Preoperative MRI can clearly display the morphological and structural differences between ACUM and cystic adenomyosis. Typical clinical features including patient age, lesion location, morphology, concentric ring structure and combined pelvic lesions can effectively distinguish the two diseases.

MRI serves as a reliable and valuable imaging tool for the preoperative diagnosis and differential diagnosis of ACUM and cystic adenomyosis, providing accurate evidence for clinical treatment.

ESGE35-0556 -
Free Communication

From diagnosis to decision-making: second-level gynecological ultrasound as a key tool for tailored management of infertile patients before ART

Ludovica Niccolini[1], Fabiola Nardelli[1], Antonia Tessitore[1], Luigi Vigilante[1], Ida Strina[1], Brunella Zizolfi[1]
[1]University of Naples Federico II- Naples- Italy, Department of Public Health - School of Medicine, Naples, Italy

Background

Second-level gynecological ultrasound is an advanced tool for evaluating female infertility, providing detailed two-dimensional (2D) and three-dimensional (3D) assessment of the uterus and adnexa. Accurate detection of structural abnormalities can guide medical or surgical treatment prior to assisted reproductive technologies (ART). This study aimed to assess the role of second-level ultrasound in identifying previously undetected or inadequately characterized abnormalities and its impact on subsequent clinical management of infertile patients.

Methods

A retrospective observational study was conducted on patients with primary or secondary infertility referred to the second-level gynecological ultrasound unit at the University of Naples Federico II from March 2025 to April 2026. Exclusion criteria were age <18 or >45 years, ongoing pregnancy or gynecologic oncologic disease. All patients underwent comprehensive ultrasound evaluation with 2D images and 3D volumes stored. The prevalence of the main structural abnormalities detected was analysed, along with changes in clinical management compared with prior evaluation.

Results

A total of 178 patients were included. Second-level ultrasound revealed previously missed pathologies as well as known conditions that were better characterized. Adenomyosis was detected in 56% of patients, not diagnosed previously. Congenital uterine malformations were found in 8.2% of patients; 58% were suspected on prior 2D ultrasound, mainly septate or bicorporeal, but 3D reconstruction enabled more precise characterization of septa extent and morphology. The remaining 42% of malformations, including dysmorphic uteri and other anomalies difficult to detect on 2D imaging, were diagnosed only through 3D assessment. Uterine fibroids were present in 52% of patients. Second-level ultrasound, particularly with 3D reconstruction, enabled more accurate characterization of number, size, location, and relationship with the uterine cavity. FIGO reclassification occurred in 18% of fibroids, including 10% reclassified from type 3 to type 4 and 8% from type 4 to type 3. Endometriosis was diagnosed in 23% of patients with improved definition of lesion extent, particularly in case of uterosacral ligament involvement or rectal nodules, while endometrial or cervical polyps were identified in 6.8%. Overall, second-level ultrasound findings led to changes in clinical management in 64% of patients. Surgical treatment via laparoscopy or laparotomy was indicated in 28% of cases due to symptomatic fibroids or severe endometriosis. Operative hysteroscopy was recommended in 15% of patients, mainly for polyps, submucosal fibroids (FIGO 0–3), or uterine malformations. Targeted pharmacological therapy was prescribed in 21% of

cases, particularly for moderate to severe adenomyosis, small ovarian endometriosis, or small fibroids not deforming the uterine cavity. The remaining 36% continued conservative management or follow-up.

Conclusions

Second-level gynecological ultrasound is crucial in infertility evaluation, improving the detection and characterization of uterine and adnexal abnormalities before ART. Integrated with hysteroscopy and reproductive surgery, it guides early targeted treatment and supports a tailored strategy to optimize reproductive outcomes.

ESGE35-0474 -
Free Communication

Clinical relevance of isthmoceles according to imaging modality: a prospective cohort study

Nur Durcanoğlu[1], Pınar Kumru[2], Sultan Karakuş[3], Resul Karakuş[2]
[1]University of Health Sciences- Zeynep Kamil Women and Children's Diseases Training and Research H ospital- Istanbul- Turkey, Obstetrics and Gynecology, Istanbul, Türkiye
[2]University of Health Sciences- Zeynep Kamil Women and Children's Diseases Training and Research H ospital, Obstetrics and Gynecology, Istanbul, Türkiye
[3]Obstetrics and Gynecology Private Clinic, Obstetrics and Gynecology, Istanbul, Türkiye

Background

The increasing rates of caesarean delivery require accurate identification and characterization of caesarean scar defects; however, the clinical significance of defects detected by different imaging modalities remains uncertain, particularly regarding their association with clinical symptoms.

Methods

This prospective cohort study enrolled women with a history of at least one caesarean section presenting to a tertiary gynecology clinic. All participants underwent transvaginal ultrasonography (TVUS). Saline infusion sonohysterography (SIS) was performed in women without a defect on TVUS. Participants were categorized into three groups: TVUS-detected isthmocele, SIS-only isthmocele, and no isthmocele. Associations between imaging-defined groups and composite bleeding outcome were assessed using logistic regression.

Results

A total of 682 women were included. Isthmocele was detected in 69.2% on TVUS and in 92.5% following the addition of SIS in TVUS-negative women. Postmenstrual spotting and intermenstrual bleeding differed significantly across groups (p=0.015 and p=0.013, respectively). In multivariable analysis, parity (OR 1.29; 95% CI 1.08–1.53; p=0.004) and TVUS-detected isthmocele (OR 1.84; 95% CI 1.02–3.31; p=0.042) were independently associated with composite bleeding, whereas SIS-only isthmocele was not (OR 1.26; 95% CI 0.66–2.38; p=0.481). Among women with TVUS-detected isthmocele, niche length and depth showed weak associations with bleeding, whereas residual myometrial thickness did not.

Conclusions

TVUS-detected isthmocele was independently associated with bleeding symptoms, whereas defects identified exclusively by SIS were not. TVUS should be considered the primary modality for identifying defects that may warrant clinical attention.

ESGE35-0867 -
Free Communication

Accuracy Of Transvaginal Ultrasound Sliding Sign In Predicting Pouch Of Douglas Obliteration And Pelvic Adhesions In Women Undergoing Vaginal Natural Orifice Transluminal Endoscopic Surgery(V-NOTES)

Gulin Sena Koca[1], Zuhal Altintas Sakaoglu[1], Nazlı Aktas Asena[1], Neslisah Ar[1], Meryem Hocaoglu[1], Abdulkadir Turgut[1]
[1]Goztepe Prof. Dr. Suleyman Yalcin City Hospital Affiliated with Istanbul Medeniyet University, Department of Obstetrics and Gynaecology, Istanbul, Türkiye

Background

Vaginal natural orifice transluminal endoscopic surgery (V-NOTES) is a minimally invasive gynecological approach, particularly for hysterectomy and adnexal procedures, associated with reduced postoperative pain, shorter hospitalization, and faster recovery compared with conventional laparoscopy. Successful outcomes depend on appropriate patient selection and safe access to the posterior pelvic compartment. The sliding sign is a sonographic marker reflecting mobility between pelvic structures, and its absence has been associated with pouch of Douglas (POD) obliteration and severe pelvic adhesions. This study aimed to evaluate the accuracy of preoperative transvaginal ultrasound (TVUS) sliding sign in predicting POD obliteration and pelvic adhesions in women undergoing V-NOTES procedures.

Methods

This retrospective study included 75 patients who underwent V-NOTES procedures between September 2024 and May 2026. The sliding sign in the POD was assessed along the posterior vagina and defined as positive when the anterior rectal wall glided smoothly over the posterior vagina and cervix. All patients demonstrated a positive sliding sign and were analysed as a sliding sign–positive cohort. Preoperative TVUS and intraoperative adhesion assessments were performed by the same surgeon. Demographic and clinical characteristics, surgical outcomes, and conversion to laparotomy were recorded. Adhesions were classified intraoperatively as Grade 1 (mild), Grade 2 (moderate), and Grade 3 (severe). Associations between adhesions, severity, and laparotomy conversion were analysed using Fisher's exact test, with $p<0.05$ considered significant. The primary outcome was the positive predictive value of the posterior sliding sign.

Results

The mean age was 51±12.3 years and mean BMI was 29.4±5.8 kg/m². Previous abdominal surgery was present in 38 patients (50.7%), including caesarean section (21.3%), appendectomy (9.3%), other gynecological procedures (8.0%), and other abdominal surgeries (10.6%). Eleven patients (14.6%) had multiple prior surgeries.

Pelvic adhesions were observed in 25 patients (33.3%), most commonly in the vesicouterine pouch (26.7%), followed by adnexal (9.3%), fundal (5.3%), and Douglas pouch/retrocervical adhesions (4.0%). All Douglas pouch adhesions were Grade 1. Vesicouterine adhesions included Grade 1 (12.0%), Grade 2 (10.6%), and Grade 3 (4.0%), while Grade 3 adhesions were confined to this region.

Laparotomy conversion occurred in 4 patients (5.3%), and laparoscopy in 1 (1.3%). Conversion was significantly higher in patients with adhesions (20%) compared to those without (p=0.003). A significant association was found between adhesion severity and laparotomy requirement ($\chi^2 = 35.1$, df = 3, $p<0.001$), with all Grade 3 cases requiring conversion. A moderate positive correlation was observed (Spearman's rho = 0.457, $p<0.001$). Complication rates were higher in patients with adhesions (16.0% vs. 4.0%), but not statistically significant (p=0.091).

A positive sliding sign showed a 66.7% positive predictive value for absence of adhesions and 96.0% for detecting Douglas pouch/retrocervical adhesions.

Conclusions

A positive sliding sign does not fully exclude pelvic adhesions in V-NOTES candidates, while severe adhesions are associated with increased laparotomy conversion rates.

ESGE35-0937 -
Free Communication

Ultrasound-guided hysteroscopic myolysis of uterine fibroids: preliminary clinical outcomes and sonographical findings.

Serena Guerra[1], Sabrina Reppuccia[1], Erika Catania[2], Danilo Borrelli[1], Brunella Zizolfi[1], Maria Chiara De Angelis[3]
[1]University of Naples Federico II, Department of Public Health- School of Medicine, Naples, Italy
[2]University of Palermo, Department of Gynaecology and Obstetrics, Palermo, Italy
[3]University of Naples Federico II,
Department of Neuroscience and Reproductive and Odontostomatological Sciences- School of Medicine, Naples, Italy

Background

Uterine fibroids are a common gynaecological condition often associated with significant symptoms including heavy menstrual bleeding (HMB), pelvic pain and dysmenorrhea. Among minimally invasive treatment options, ultrasound-guided hysteroscopic myolysis represents a novel fertility-sparing technique. The aim of our study is to evaluate the short-term clinical efficacy and sonographical outcomes of hysteroscopic ablation using radiofrequency (RFA) or microwaves (MWA) in women with symptomatic uterine fibroids (UF) seeking an alternative to surgery or long-term medical therapy.

Methods

An ongoing prospective observational study is being conducted at Federico II University of Naples since July 2025. Premenopausal women with symptomatic FIGO type 1, 2 and 3 uterine fibroids were included, All the patients underwent hysteroscopic myolysis using either RFA or MWA under ultrasound guidance. Preoperative assessment included 2D and 3D transvaginal ultrasound, Color Doppler evaluation and elastography and office hysteroscopy. A follow up at 1 and 3 months after treatment included clinical evaluation, ultrasound assessment with Color Doppler and elastography and hysteroscopic evaluation.

Results

To date, 22 patients have been enrolled, with a mean age of 43.8 years. Four patients (18%) presented FIGO Type 1 fibroids, n=12 (55%) with Type 2, n=6 (27%) with Type 3. Mean maximal fibroid diameter was 43,4 mm (range 18-74 mm). At baseline, Most UF (19/22, 86%) showed moderate to high vascularisation (Color Score ≥3). Mean UF volume reduction was 28% ± 9 at 1-month follow-up, increasing to 35% ± 12 at 3 months. Complete devascularisation (Color Score 1) was observed in 18/22 cases (81%) at 1-month follow-up. UF topography did not change after treatment, except for one Type 3 fibroid that underwent spontaneous expulsion 10 days after myolysis. Smaller lesions (<40 mm) were associated with better volume reduction rates compared to larger lesions (>60 mm) (52% vs 31%, p=0.03). Clinical improvement in HMB symptoms was observed in 81% of patients, with a mean reduction of 4.3 points on the VAS scale at 1 month. Higher baseline stiffness at elastography was associated with lower treatment response. At 3-month follow-up, 18/22 patients (82%) reported clinical improvement, while 4/22 (18%) reported experienced persistent mild

symptoms. Two patients subsequently underwent surgical management (one due to persistent symptoms and one upon personal request). Mean operative time was 14.7 minutes (range 10–20 minutes). No major peri- and post-operative complications were observed.

Conclusions

Hysteroscopic thermal ablation appears to represent a safe, promising and innovative uterus-preserving therapeutic option for women with symptomatic UF wishing to avoid surgery or long-term medical treatment. Better therapeutic response was observed in smaller lesions, while increased stiffness was associated with lower treatment efficacy. These preliminary findings support the role of advanced ultrasound assessment, including elastography, in patient selection and post-treatment monitoring, supporting a tailored minimally invasive management approach.

ESGE35-0241 -
Free Communication

Endometriosis-associated hydronephrosis: a potentially silent but devastating entity. A retrospective single-centre analysis and proposal of a clinical pathway

Milena Petrovic[1], *Surabhi Iyer*[2], *Jonathan Lewin*[1], *Mohamed Mabrouk*[1], *Arvind Vashisht*[1], *Ertan Saridogan*[1]
[1]*University College London Hospital, Endometriosis, London, United Kingdom*
[2]*University College London, University College London, London, United Kingdom*

Background

Urinary tract endometriosis represents an uncommon but clinically significant manifestation, with ureteral involvement being particularly infrequent yet associated with a substantial risk of silent renal compromise**.** Our objective was to characterise clinical presentation, management strategies, and outcomes in women with endometriosis-associated hydronephrosis, and to propose a diagnostic and management pathway.

Methods

A retrospective cohort study was conducted at an accredited tertiary Endometriosis Centre in the United Kingdom. Women diagnosed with hydronephrosis secondary to endometriosis between 2009 and 2026 were identified from our institutional databases. Demographic, clinical, imaging, management and outcome data were analysed.

Results

Seventy-five women with unilateral or bilateral hydronephrosis attributable exclusively to endometriosis were identified. Of these, forty-three women (57.3%) reported no urinary symptoms at presentation. Complete unilateral renal function loss was detected in nine women (12%) at diagnosis. Among fifty-six women in whom surgical management was planned, ureteric reimplantation was performed in eighteen cases and ureterolysis in nineteen, while nineteen remained on the waiting list at the time of review. Of the nineteen women awaiting surgery, ureteric stenting or nephrostomy was used as a temporary measure in ten women. Hydronephrosis resolved in 36 of 37 women (97.3%) who completed surgical treatment. Resolution was also observed in six women with mild hydronephrosis managed expectantly. Postoperative complications occurred in two women (ureteric stricture, n=1; ureterovaginal fistula, n=1).

Conclusions

Endometriosis-associated hydronephrosis is frequently clinically silent with respect to urinary symptoms yet carries a substantial risk of irreversible renal damage. Early imaging, functional renal assessment, and multidisciplinary management are essential to optimise outcomes and prevent renal function loss.

ESGE35-0244 -
Free Communication

Pelvic venous disorders in women with chronic pelvic pain: an international and multidisciplinary eDelphi consensus on diagnosis

Naila Loudini[1], Otmar Randolph Marald Wikkeling[2], Marie-Josee van Rijn[3], Mark de Wolf[4], Robert De Leeuw[5]
[1]Amsterdam UMC, Obstetrics and Gynaecology, Amsterdam, The Netherlands
[2]Nij Smellinghe, Surgery, Drachten, The Netherlands
[3]Erasmus MC, Surgery, Rotterdam, The Netherlands
[4]Erasmus MC, Radiology, Rotterdam, The Netherlands
[5]Amsterdam UMC, Obstetrics & Gynaecology, Amsterdam, The Netherlands

Background

Chronic pelvic pain (CPP) affects an estimated 26% of women worldwide and accounts for approximately 40% of gynaecological laparoscopies, yet its aetiology frequently remains unidentified after investigation. Pelvic venous disorders (PeVD), classified by the Symptoms-Varices-Pathophysiology (SVP) system, encompass the full spectrum of pelvic venous disease across multiple phenotypes; this study focuses on the reflux phenotype, characterised by retrograde flow through the ovarian vein and its pelvic tributaries resulting in CPP and pelvic varices. This phenotype remains underrecognized and systematically overlooked, including in women with coexisting endometriosis or adenomyosis whose pain is not fully explained by gynaecological pathology alone. This study aimed to establish the first internationally and multidisciplinary diagnostic framework for this phenotype of PeVD.

Methods

An eDelphi study was conducted with an international expert panel including vascular surgeons, interventional radiologists, gynaecologists, phlebologists and angiologists. Consensus was defined as ≥70% agreement. Rounds 1 and 2 addressed nomenclature, CPP definition, symptom profile, physical findings, differential diagnoses, medical history, non-imaging diagnostic tests and medical imaging modalities. Round 3 integrated prior findings into definitive diagnostic criteria and a structured expert discussion phase will follow if required.

Results

Historical terms such as pelvic congestion syndrome did not achieve consensus, experts endorsed an anatomically inclusive designation aligned with the SVP classification, recognising PeVD as a spectrum of haemodynamic disorders rather than a syndrome. Consensus was established on a CPP duration of ≥6 months, with functional impairment confirmed as a mandatory quality-of-life outcome measure. Symptoms achieving consensus as highly characteristic of PeVD form a distinctive clinical pattern: post-coital pain, CPP of venous origin and postural pelvic heaviness worsening with prolonged standing being features that are positional and postural rather than cyclical, clinically distinguishable from dysmenorrhoea and endometriosis-associated pain. Physical findings were classified as supportive rather than essential. In the differential diagnostic framework, endometriosis and

adenomyosis were confirmed as essential pre-diagnostic exclusions. Assessment extended to gastroenterological, urological, psychosocial, vascular and musculoskeletal domains. Non-imaging workup, including validated pain assessment, pain mapping and pelvic floor evaluation, was confirmed as core. A stepwise imaging protocol was established, with pelvic venography as the gold standard for the definitive diagnosis of PeVD.

Conclusions

This study establishes the first consensus-derived diagnostic framework for pelvic venous disorders of the ovarian vein reflux phenotype, a condition woven into the full spectrum of gynaecological practice. CPP is the common thread across the gynaecologist's most diagnostically demanding presentations: endometriosis, adenomyosis, adnexal pathology, uterine disorders and pain that persists without explanation despite thorough investigation. For each, this framework positions pelvic venous aetiology not as a peripheral consideration, but as a diagnosis to actively pursue, a coexisting condition to evaluate in parallel and the answer to seek when gynaecological treatment alone leaves a woman's pain unresolved.

ESGE35-0253 -
Free Communication

Endometriosis versus adenomyosis in infertile women: a comparative ultrasound study of reproductive outcomes

Eugenia Costantini[1], Alessia Stella[2], Giulia Monaco[2], aikaterini selntigia[3], Alfredo Ercoli[4], Caterina Exacoustos[2]
[1]Obstetrics and Gynaecological Clinic- University of Siena, Department of Molecular and Developmental Medicine, Siena, Italy
[2]Gynecological Unit- University of Rome "Tor Vergata", Department of Surgical Sciences, Rome, Italy
[3]Gynecological Unit- University of Rome "Tor Vergata", Department of Surgical Sciences, Roma, Italy
[4]Gynecological Unit- University of Rome "Tor Vergata", Department of Biomedicine And Prevention, Rome, Italy

Background

Endometriosis and adenomyosis are common in infertile women and are increasingly diagnosed using standardized ultrasound criteria. Both conditions are associated with reduced fertility and poorer ART outcomes, but their relative and combined impact remains unclear. Previous studies often relied on surgical diagnosis or evaluated each disease separately. Few studies have compared reproductive outcomes among women with isolated adenomyosis, isolated endometriosis, and combined disease using modern ultrasound classifications. Clarifying these differences may help tailor fertility counselling and management strategies.

Methods

This observational cohort study included 200 infertile women evaluated between 2020 and 2025 and assigned to four groups (n=50 each) based on tvus findings: isolated adenomyosis (a), isolated endometriosis (e), combined adenomyosis and endometriosis (a+e), and infertility without pelvic pathology (i). diagnoses followed MUSA and IDEA criteria. women with male-factor infertility, genetic/endocrine disorders, uterine malformations, or fibroids (FIGO 1–3or>4cm) were excluded. outcomes were: live birth rate, overall pregnancy and miscarriage rates after spontaneous conception or art.

Results

Infertility duration was longer in a and a+e than in i (months: 51.4±33.5, 55.7±36.0vs 34.9±19.3; e 36.7±25.3;$p<0.05$). live birth rates were similar across groups (a86%,e70%,a+e80%,i83%). spontaneous pregnancy was more frequent in i than a (23%vs5%;$p<0.05$). art was required in 65%–80% of cases. mean embryo transfer number was higher in a than e (a 3.0±2.2; e 1.6±1.2; a+e 2.3±2.1; i 2.4±1.6;$p<0.05$). overall pregnancy rate was higher in i than a (60%vs38%), with higher odds of pregnancy in i (or 2.5, 95%ci 1.0–6.1). uterine volume was greater in a than in the other groups (cm^3: 103.5±67.7vs74.2±21.8, 70.3±26.3, 63.2±18.3; $p<0.05$). posterior adenomyosis was more frequent in a+e than a (85%vs46%;$p<0.05$). in women with endometriosis, rectosigmoid (48%vs23%;$p<0.05$) and parametrial (48% vs 8%;$p<0.05$) involvement were more frequent in a+e than e.

Conclusions

Adenomyosis, isolated or combined with endometriosis, was associated with longer infertility and poorer reproductive outcomes. women without adenomyosis/endometriosis had higher overall pregnancy rates, while live birth rates after conception were similar. distinct tvus patterns support adenomyosis heterogeneity and a different phenotype when associated with endometriosis.

ESGE35-0470 -
Free Communication

Whole exome sequencing identifies candidate endometriosis susceptibility variants in Israeli women.

Anya Kushnir Greenfield[1], *Eitan Friedman*[2], *Hadas Volkov*[3], *Noam Shomron*[3], *Shlomi Cohen*[4]
[1]*Sheba Medical Center, Gynaecology Department, Ramat Gan, Israel*
[2]*Tel-Aviv University, Gray Faculty of Medicine, Tel Aviv, Israel*
[3]*Tel-Aviv University, Gray Faculty of Medicine, Tel-Aviv, Israel*
[4]*Sheba Medical Center, Endometriosis Unit- Department of Gynaecology, Tel-Aviv, Israel*

Background

Genetic factors are believed to contribute substantially to endometriosis susceptibility; however, the specific germline variants involved remain incompletely characterized.

Methods

Whole exome sequencing (WES) was performed in 39 Israeli Jewish women from 35 unrelated families, 35 of the women had surgically and histopathologically confirmed endometriosis. Variants were prioritized using a multistep bioinformatic filtering pipeline incorporating rarity, predicted functional impact, deleteriousness scores, and relevance to endometriosis-associated pathways.

Results

Thirteen candidate missense variants located in eight genes were identified as potentially relevant to endometriosis susceptibility. Notably, seven variants involved HLA-related genes, while additional variants were identified in LILRB1 and LILRB2, genes involved in immune regulation through interactions with MHC class I molecules.

Conclusions

This exploratory pilot study identified several candidate germline variants potentially involved in endometriosis susceptibility, particularly within immune-regulatory pathways. Larger ethnically diverse studies incorporating functional validation and independent replication cohorts are required to confirm these observations.

ESGE35-0491 -
Free Communication

Timing of postoperative hormonal therapy after endometriosis surgery and recurrence: results from a retrospective pilot study

Enrico Pazzaglia[1], *Manuela Maletta*[1], *Valeria De Gobbi*[1], *Paola Mete*[1], *Renato Seracchioli*[1], *Diego Raimondo*[2]
[1]*IRCCS Azienda Ospedaliero-Universitaria di Bologna,*
Department of Medical and Surgical Sciences DIMEC- University of Bologna, Bologna, Italy
[2]*IRCCS Azienda Ospedaliero-Universitaria di Bologna,*
Division of Gynaecology and Human Reproduction Physiopathology, Bologna, Italy

Background

Surgery is an effective treatment for endometriosis-associated pain and impaired quality of life; however, postoperative recurrence remains common. Postoperative hormonal therapy has been shown to significantly reduce recurrence risk, although the optimal timing for treatment initiation remains unclear. This study aimed to evaluate whether the timing of postoperative hormonal therapy initiation influences the recurrence rate of endometriosis after surgery.

Methods

This pilot retrospective cohort study included women aged 18–50 years who underwent uterine-ovarian-sparing surgery for endometriosis at a tertiary referral center between January 2019 and December 2021. Women were divided into two groups according to the timing of therapy initiation: immediate initiation (II), starting the day after surgery, and delayed initiation (DI), starting at the one-month postoperative visit. Recurrence was defined as anatomical and/or clinical. Anatomical recurrence was identified by imaging findings consistent with endometriosis at least 6 months after surgery, whereas clinical recurrence was defined as Numeric Rating Scale (NRS) ≥5 for one or more pain symptoms previously reported before surgery. The primary outcome was the difference in overall recurrence rate between groups. Secondary outcomes included anatomical recurrence, clinical recurrence, and hazard ratio (HR) for recurrence according to treatment timing. Kaplan–Meier analysis, log-rank test, and Cox regression models were used for statistical analysis.

Results

A total of 164 women were included: 59 (36%) in the II group and 105 (64%) in the DI group. Baseline demographic and clinical characteristics were comparable between groups, although rectosigmoid and rectovaginal endometriosis were more frequent in the DI group. Overall, 41/164 women (25%) experienced recurrence during follow-up. Anatomical recurrence occurred in 20 women, most frequently involving the ovary (45%), uterosacral ligaments (20%), and rectosigmoid (15%), with 75% of recurrences occurring at the original anatomical site. Overall recurrence was significantly lower in the II group compared with the DI group (15% vs 30%, p = 0.049). No significant differences emerged in clinical recurrence (13% vs 25%, p = 0.134) or anatomical recurrence (10% vs 13%, p = 0.730). At univariate analysis, delayed initiation was associated with an increased risk of recurrence (HR 2.128,

95% CI 1.015–4.461, p = 0.046), whereas multivariate analysis showed borderline significance (HR 2.136, 95% CI 0.980–4.657, p = 0.056).

Conclusions

Immediate initiation of postoperative hormonal therapy may reduce the risk of endometriosis recurrence after surgery compared with delayed initiation at one month. Although the association did not remain statistically significant after multivariate adjustment, these findings suggest a potential role for the perioperative hormonal suppression window in preventing recurrence. Larger prospective randomized studies are needed to confirm these preliminary results and clarify the clinical relevance of treatment timing.

ESGE35-0924 -
Free Communication

Minimally invasive molecular characterization of adenomyosis (Translational Adenomyosis, TRADE-1 Study): next-generation sequencing from hysteroscopic tru-cut biopsy.

Serena Guerra[1], *Danilo Borrelli*[1], *Maria Chiara De Angelis*[2], *Brunella Zizolfi*[1], *Umberto Malapelle*[1], *Attilio Di Spiezio Sardo*[1]
[1]*University of Naples Federico II, Department of Public Health- School of Medicine, Naples, Italy*
[2]*University of Naples Federico II,*
Department of Neuroscience and Reproductive and Odontostomatological Sciences, Naples, Italy

Background

Adenomyosis is a benign uterine condition characterised by the presence of endometrial glands and stroma within the myometrium. Despite its clinical significance, the molecular mechanisms underlying the pathology and its progression are poorly understood, mainly due to the lack of accessible tissue for histological and molecular analysis, as hysterectomy is no longer routinely performed. To overcome this limitation, we propose a translational approach combining minimally invasive hysteroscopic tru-cut uterine biopsy with next-generation sequencing (NGS). Our aim is to identify molecular targets of adenomyosis by high-quality DNA obtained from endo-myometrial tissue sampled on adenomyosis sites (presence of direct signs at ultrasound, according to the MUSA Terms and Definitions) and downstream molecular analysis using next-generation sequencing (NGS).

Methods

A prospective study is ongoing at Federico II University of Naples, Italy. Endo-myometrial tissue samples are obtained via hysteroscopic tru-cut biopsy (Spirotome, BioNcise®, Belgium) in patients with sonographic diagnosis of adenomyosis. After histological confirmation, 5-µm sections are subjected to manual microdissection to enrich lesional tissue. DNA is extracted using a commercial kit and analysed using a microfluidic platform (TapeStation 4200) to assess DNA concentration and integrity (DNA Integrity Number, DIN). Extracted DNA is stored and undergoes NGS analysis using a 50-gene panel targeting cancer-related and signaling pathways.

Results

Preliminary data confirm the histopathological diagnosis of adenomyosis in all the patients, validating the accuracy of the sampling technique. DNA extraction yields a mean concentration of 11.9 ng/µL. Microfluidic analysis (DNA Concentration, DIN: 5.8) indicates moderate fragmentation but sufficient quality for downstream molecular analysis. Fragment size distribution ranges from 4,000 to 48,500 base pairs. NGS analysis is ongoing.

Figure 1. Data output from TapeStation 4200 system. DIN (5.8) and DNA concentration (11.9 ng/µl) calculated by proprietary software.

Conclusions

These findings confirm that minimally invasive hysteroscopic biopsy can provide DNA of adequate quality for genomic profiling in adenomyosis. This approach may overcome the limitations associated

with the lack of surgical specimens and enable future genomic characterization of the disease. The integration of minimally invasive sampling with NGS is ongoing to identify key checkpoints of adenomyosis pathogenesis and developing targeted therapeutic strategies.

ESGE35-0571 -
Free Communication

The impact of pregnancy on endometriomas: a systematic review and meta-analysis

Olga Bougie[1], Xin Xu[2], Nicole Dumonski[2], Jessica Pudwell[2], Jade Desilets[3], Sarah Shamiya[3]
[1]Mount Sinai Health Systems, Obstetrics and Gynaecology, Toronto, Canada
[2]Queen's University, Obstetrics and Gynaecology, Kingston, Canada
[3]University of Toronto, Obstetrics and Gynaecology, Toronto, Canada

Background

Approximately one-third of endometriosis cases manifest as ovarian endometriomas, which carry risks of complications including torsion and rupture. The incidence of pregnancies involving endometriomas has increased significantly, now among the most common adnexal masses identified in pregnancy. Pregnancy is hypothesized to promote endometrioma regression secondary to elevated progesterone levels, although existing studies report conflicting findings. Therefore, the overall impact of pregnancy on endometriomas remains unclear. This study synthesized the literature on the natural history of endometriomas in pregnancy.

Methods

This systematic review and meta-analysis was prospectively registered with PROSPERO (CRD420250626626). MEDLINE, Embase, Web of Science, and CINAHL were searched from inception to March 31, 2026 for original human studies assessing the impact of pregnancy on endometriomas. Following PRISMA guidelines, study selection, data extraction, and risk-of-bias assessment were conducted by two independent reviewers, with a third author resolving discrepancies. Risk-of-bias was assessed using the JBI critical appraisal tool. The primary outcome was a change in endometrioma size during pregnancy (growth, regression, resolution, or no change). The secondary outcomes were decidualization, rupture, abscess development, torsion, malignant transformation, need for emergency surgery, need for elective surgery before delivery, and need for surgical management during caesarean section. Proportional meta-analysis using random-effects models was performed to calculate the pooled proportion of endometriomas that developed the primary and secondary outcomes. Meta-regression was performed to assess the associations between age, parity, body mass index, history of endometriosis, and number and laterality of endometriomas and the primary and secondary outcomes.

Results

Our search yielded 11,534 unique articles. Following screening and full-text review, 10studies with a total sample size of 467 pregnant patients with 472 ultrasound-confirmed endometriomas were included. All studies were observational (6 retrospective and 4prospective). Risk-of-bias was low-to-moderate. Overall, 13.5% of endometriomas grew (95%CI 7.7-22.6%, I 2 = 76.0%), 26.6% remained stable (95% CI 19.6-34.5%, I 2 = 59.2%), 45.4%regressed (95% CI 24.0-68.7%, I 2 = 88.0%), and 29.1% resolved (95% CI 23.0-36.1%, I 2 =53.0%). Decidualization was observed in 24.1% of endometriomas (95% CI 11.2-44.5%, I 2 =85.8%). Complications including rupture, abscess development, torsion, and malignant transformation each occurred in less than 5% of endometriomas. Meta-regression did not

identify significant predictors of the primary and secondary outcomes. Funnel plots showed minimal evidence of publication bias.

Conclusions

Pregnancy appears to have an overall favourable effect on endometriomas. Most endometriomas remain stable, regress, or resolve during pregnancy and can be safely managed expectantly with low complication rates. Larger and more robust studies are needed to further characterize the natural history of endometriomas during pregnancy and to identify predictors of complications, which may improve risk-stratification and clinical decision-making.

ESGE35-0598 -
Free Communication

Malignant transformation of caesarean section scar endometriosis: diagnostic pitfalls and poor oncologic outcomes in a retrospective case series

Agnieszka Kotlarz[1,2], Ewa Rabiej-Wronska[1,2], Marta Balajewicz-Nowak[1,2], Magdalena Loboda[1,2], Pawel Basta[1,2]
[1]Jagiellonian University- Medical College, Department of Gynaecology and Oncology, Krakow, Poland
[2]University Hospital in Krakow, Department of Gynecology and Oncological Gynaecology, Krakow, Poland

Background

Malignant transformation of endometriosis within caesarean section (CS) scars is rare but highly aggressive. Due to its low incidence, no standardized screening or diagnostic algorithms exist, often resulting in delayed diagnosis and poor outcomes.

Methods

We retrospectively analysed four patients treated between 2018 and 2025 for malignant transformation of CS scar endometriosis. Clinical history, diagnostic work-up, histopathology, treatment, and outcomes were reviewed. A focused literature review was performed.

Results

The interval between caesarean section and cancer diagnosis varied. Only one patient developed malignancy more than two decades after caesarean section; in this case, transformation occurred 13 years after excision of a previously benign abdominal wall endometriosis nodule. In the remaining cases, the interval was under 20 years. Histopathology revealed two clear cell carcinomas and two endometrioid carcinomas arising from abdominal wall endometriosis.

Diagnostic pitfalls were common. Two patients were initially managed as having typical abdominal wall endometriosis without advanced imaging or biopsy. Two patients underwent core-needle biopsy; in one case, the initial biopsy was false-negative and malignancy was confirmed only after repeat biopsy. In three cases, complete preoperative staging imaging was not performed prior to surgical treatment. One patient presented with disseminated disease confirmed on ultrasound and computed tomography, precluding surgical management.

Despite surgical treatment and subsequent systemic therapy, disease progression was rapid. Three patients died within 7–14 months, while the remaining patient is alive 20 months after primary surgery following resection of recurrent disease performed last month.

Conclusions

Malignant transformation of CS scar endometriosis is associated with frequent diagnostic underestimation and extremely poor prognosis despite treatment. These findings highlight the need for red-flag criteria, standardized diagnostic pathways, and dedicated multidisciplinary management strategies.

ESGE35-0766 -
Free Communication

Fluoroscopy-assisted alcohol sclerotherapy for ovarian endometrioma: technical workflow and safety considerations

Haticegül Tuncer[1], Ahmet Onur Kilic[2], Utku Akgor[3], Derman Basaran[3], Murat Gultekin[3], Turkmen Ciftci[2]
[1]Hacettepe University, Department of Obstetrics and Gynaecology, Ankara, Türkiye
[2]Hacettepe University, Department of Radiology, Ankara, Türkiye
[3]Hacettepe University, Department of Obstetrics and Gynaecology- Division of Gynecologic Oncology, Ankara, Türkiye

Background

To describe the standardized procedural workflow and safety principles of ultrasound and fluoroscopy-assisted alcohol sclerotherapy (FAAS) for ovarian endometriomas in a high-volume tertiary referral center. Although laparoscopic cystectomy remains the conventional treatment, surgical excision may adversely affect ovarian reserve through inadvertent removal of healthy ovarian tissue and thermal injury. This video abstract focuses primarily on the technical aspects, multidisciplinary patient selection, and procedural safety measures of FAAS as a fertility-preserving minimally invasive alternative, with particular emphasis on fluoroscopic cystography as a critical safety step before ethanol instillation.

Methods

Over a 5-year period, more than 350 patients with ovarian endometriomas underwent FAAS performed by a dedicated multidisciplinary team consisting of an interventional radiologist and gynecologist at Hacettepe University. All patients were initially evaluated in the gynecology outpatient clinic with transvaginal ultrasonography, serum CA-125, and AMH measurements. Pelvic MRI was subsequently performed to confirm the diagnosis, evaluate deep infiltrating endometriosis, and exclude malignancy. Cases were reviewed by a dedicated gynecologic oncology council before referral to the multidisciplinary interventional gynecology team consisting of an interventional radiologist and gynecologist.

Patients fulfilling institutional treatment criteria, including cyst diameter>3cm, dysmenorrhea, chronic pelvic pain, infertility, or recurrent endometrioma, were scheduled for FAAS. Procedures were performed under conscious sedoanalgesia without any preoperative preparation. Depending on cyst accessibility, transvaginal or transabdominal access was obtained using an 18-gauge needle or an 8-F drainage catheter under ultrasound guidance. Approximately 20% of cyst contents were initially aspirated, followed by fluoroscopic cystography using contrast injection to exclude extracystic leakage. If no leakage was detected, saline irrigation and repeated aspiration were performed until the hemorrhagic fluid became serous. Subsequently,96% ethanol corresponding to 30–50% of the cyst volume was instilled and maintained for 10minutes before complete aspiration. Aspirated cyst contents were routinely sent for cytological examination. Patients were discharged on the same day or after overnight observation and followed with imaging and clinical assessment.

Results

The technique demonstrated excellent technical feasibility and procedural safety over a 5-year period. Contrast leakage during fluoroscopic cystography was identified in only 2 patients (0.57%); ethanol administration was withheld in these cases, preventing potential complications. More than 90% reduction in cyst volume or complete remission was achieved during follow-up. Radiation exposure during fluoroscopy was extremely low (mean dose:0.36 microGray), with no observed detrimental effect on ovarian reserve. Major complications were exceedingly rare, and post-procedural AMH levels remained preserved. Fertility outcomes and long-term recurrence data will be presented separately in outcome-focused studies.

Conclusions

FAAS is a safe, reproducible, and fertility-preserving minimally invasive technique for the management of ovarian endometriomas. Fluoroscopic cystography constitutes a critical safety step by enabling real-time exclusion of cyst leakage before ethanol instillation. With negligible radiation exposure, low complication rates, and high rates of cyst regression, FAAS represents a valuable alternative to surgical cystectomy.

https://player.vimeo.com/video/1195521001?autoplay=1

ESGE35-0844 -
Free Communication

Patient-facing augmented reality volumetric pelvic models to support counselling and shared decision-making in deep endometriosis surgery

Rami Marios Saad[1], *Caitlin Insley*[1], *Jonathan Prest-Smith*[1], *Konstantinos Lamprou*[1], *Philip Pratt*[2], *Thomas Bainton*[1]
[1]*Chelsea and Westminster Hospital, Gynaecology, London, United Kingdom*
[2]*Medical iSight UK Ltd, Medical iSight UK Ltd, London, United Kingdom*

Background

Patients with deep endometriosis requiring rectovaginal excision are often asked to make complex decisions about symptom drivers, disease extent, risks to adjacent structures and possible bowel surgery. Standard counselling using imaging, diagrams and verbal explanation may not fully convey three-dimensional pelvic anatomy or the relationship between disease and planned surgical treatment.

Aim

To develop and evaluate a patient-facing augmented reality counselling tool using interactive volumetric pelvic models for patients undergoing counselling for complex endometriosis surgery.

Methods

Interactive augmented reality volumetric models were developed to demonstrate normal pelvic anatomy, severe endometriosis with adenomyosis, ovarian endometrioma, rectovaginal disease, ureteric proximity and a fibroid uterus comparator. The models can be manipulated, viewed from multiple angles and bisected to demonstrate internal anatomy and disease relationships. They were based on real case CT and MRI scans. The tool was embedded into pre-operative counselling for patients discussed through the endometriosis MDT and being considered for rectovaginal excision.

Patient experience was assessed using structured questionnaires before, during and after the AR session. Likert-scale domains included understanding of diagnosis, anatomical disease location, treatment options, procedural confidence, anxiety, headset comfort and willingness to recommend the experience. Free-text feedback was collected to explore perceived benefits and limitations. Data collection is ongoing, with updated quantitative analysis planned prior to presentation.

Results

Patient-reported feedback demonstrates strong acceptability of the augmented reality counselling tool across key domains of understanding, confidence and overall experience. Patients reported improved understanding of their diagnosis, the anatomical location of disease, the relationship between endometriosis and symptoms, and the rationale for proposed surgical treatment.

Feedback also showed high levels of confidence in understanding the planned procedure and potential treatment options, including surgery involving adjacent organs. Patients consistently reported that the AR experience was easy to follow, comfortable to use and useful as part of

counselling. Responses supported the role of volumetric 3D visualisation in reducing anxiety and improving shared decision-making.

Free-text feedback highlighted the value of seeing endometriosis in three dimensions, particularly in understanding organ involvement, surgical complexity and the reason different operative approaches may be required. Ongoing patient feedback will allow expanded quantitative analysis prior to presentation.

Conclusions

Patient-facing augmented reality volumetric pelvic models are a feasible and highly acceptable adjunct to counselling for complex endometriosis surgery. Early implementation demonstrates improved patient understanding, confidence and engagement with shared decision-making. This approach has potential to enhance counselling for patients undergoing complex benign gynaecological surgery, particularly where disease extent and operative planning are difficult to convey using conventional two-dimensional methods.

ESGE35-0903 -
Free Communication

A systematic review of laparoscopic and robotic surgery for posterior deep infiltrating endometriosis, based on surgical process modelling

Ndeye Racky Sall[1], Marie Lepage[2], Arnaud Huaulmé[1], Pierre Jannin[1], Krystel Nyangoh Timoh[1,2]
[1]University of Rennes- INSERM- LTSI - UMR 1099, Médicis Team, Rennes, France
[2]University Hospital of Rennes, Department of Obstetrics and Gynaecology, Rennes, France

Background

Posterior deep infiltrating endometriosis (DIE) represents a complex entity and often requires advanced surgical management. Standardization using a surgical process model (SPM) approach could improve reproducibility, training, and comparability across studies. The aim was to propose a preliminary generic SPM (gSPM) for posterior DIE surgery based on a systematic review.

Methods

A systematic PubMed search from January 1, 2004, to December 31, 2024. The keywords used were (pelvic endometriosis OR deep infiltrating endometriosis OR rectal endometriosis OR bladder endometriosis OR adenomyosis) AND surgery. Randomized controlled trials, observational studies, and surgical video reports addressing laparoscopic or robot-assisted management of posterior DIE and providing detailed surgical descriptions were included. Data were independently analysed by two investigators (NRS and ML). Procedural data were extracted to identify procedures, phases, and steps for construction of the gSPM.

Results

A total of 2.440 records were identified; after screening, 141 articles were assessed for eligibility, with 87 included in the final analysis. Symptoms were reported in 62 (72.1%) articles, and prior endometriosis surgery in 42 (48.8%). Preoperative investigations were documented in 67 (77.9%) articles. Four main surgical procedures were identified: bowel resection n=45, bowel discoid excision n=21, bowel shaving n=13, and posterior DIE resection without bowel involvement n=15. For bowel resection, nine operative phases were identified, including four conditional phases. The most cited steps were pararectal space opening n=29 (64.5%), rectovaginal space opening n=27 (60%), and distal bowel resection using an automatic linear endoscopic stapler n=37 (82.2%). Discoid excision involved eleven phases and two optional phases, with two main pathways depending on the shaved area location above the anus. The most frequently cited steps included pararectal space opening and rectovaginal space opening both n=20 (95.2%) and rectal shaving n=21 (100%). Bowel shaving required nine phases and two conditional phases, with the most reported steps was pararectal space opening n=10 (76.9%), rectovaginal space opening n=8 (61.5%), and resorbable stitches if muscular damage n=10 (76.9%). Posterior DIE resection without bowel involvement included nine common steps and three optional steps, en bloc resection was the most adopted strategy n=7 (46.7%).

Conclusions

Surgical management of posterior DIE involves a series of reproducible steps, reflecting a common underlying framework but considerable variability persists in the reporting These findings provide a foundation for the development of an international Delphi consensus. Validation of a gSPM for posterior DIE may support surgical training, the development of surgical tools and applications for laparoscopic and robotic surgery.

ESGE35-0056 -
Free Communication

A complete robotic treatment of deep infiltrating endometriosis: a combination of robotic HIFU treatment of rectal endometriosis and robotic assisted partial bladder resection

Alexia Mazard[1], *Said Ouarfali*[2], *Manon Basso*[1], *Gil Dubernard*[1]
[1]*Hospices Civils of Lyon, Gynaecology and Obstetrics, Lyon, France*
[2]*Hospices Civils of Lyon, Urology, Lyon, France*

Background

Deep infiltrating endometriosis (DIE) may present as multifocal disease involving both colorectal and urinary structures, and its management remains challenging, particularly in patients desiring fertility preservation. This video presents a novel minimally invasive strategy combining robotic high-intensity focused ultrasound (HIFU) and laparoscopic robotic-assisted surgery.

Methods

We report the case of a 36-year-old nulliparous woman with primary infertility and symptomatic bifocal DIE refractory to medical therapy. Preoperative MRI identified a rectal nodule of the uterine torus extending to the anterior rectal wall (9–11 cm from the anal verge, 60° circumference involvement) without parametrial invasion, and a second hemorrhagic bladder dome nodule adherent to the vesicouterine pouch and right round ligament. A combined procedure was performed under a single anesthesia: HIFU ablation of the rectal lesion followed by robot-assisted partial bladder resection. Tubal patency was also assessed intraoperatively.

Results

Total operative time was 150 minutes, with no intraoperative or postoperative complications. The patient was discharged on postoperative day 1 with a urinary catheter, removed on day 6 with complete recovery of spontaneous voiding. Mild rectal bleeding and transient burning were reported during the first 24 hours. By day 6, the patient reported improved bowel function compared with baseline.

Conclusions

This video demonstrates the feasibility of a first combined minimally invasive approach using HIFU and robotic surgery for multifocal DIE. This strategy may represent a valuable alternative to extensive colorectal resection in carefully selected patients, particularly when fertility preservation is a priority.

https://player.vimeo.com/video/1188488002?autoplay=1

ESGE35-0649 -
Free Communication

Precision surgery for colorectal deep endometriosis: strategies for complete excision without segmental resection

Emad Mikhail[1], *Sonia Eskandarion*[2], *Jasmine Eliwa*[1], *Diana Encalada Soto*[1], *Robert D Bennett*[3]
[1]*University of South Florida, Obstetrics and Gynecology, Tampa, USA*
[2]*University of South Florida, Department of Obstetrics and Gynecology, Tampa, USA*
[3]*University of South Florida, General and Colorectal Surgery, Tampa, USA*

Background

Objective: To demonstrate different surgical strategies to ensure complete excision of colorectal deep endometriosis without segmental resection.

Design: Educational surgical video illustrating a stepwise robotic approach with integrated intraoperative ultrasound to guide lesion identification, excision, and real-time decision-making.

Setting: Tertiary academic center.

Methods

A 38-year-old nulligravida presented for evaluation of severe endometriosis associated with chronic pelvic pain, dysmenorrhea, dyschezia, and infertility. She had a prior rectal shaving procedure, but symptoms recurred. Transvaginal ultrasound identified a hypoechoic nodular lesion in the posterior cul-de-sac, MRI showed rectosigmoid deep endometriosis and submucosal penetration (mushroom-cap appearance).

Results

Surgical strategy included robotic excision with intraoperative ultrasound. Two bowel lesions were identified: a proximal sigmoid lesion (15 × 5 mm) and a distal rectal lesion (24 × 9 mm). The sigmoid lesion was excised using a linear stapler, and the rectal lesion underwent discoid excision with a circular stapler. Intraoperative ultrasound confirmed complete excision of the sigmoid lesion, but residual disease at the rectal margin required a second discoid excision. Repeating ultrasound confirmed no residual disease. Histopathology confirmed endometriosis.

Conclusions

Robotic surgery combined with intraoperative ultrasound, facilitates precise excision of colorectal deep endometriosis and supports intraoperative decision-making. Stapler selection should be tailored to lesion location and morphology. Post-excision ultrasound verification ensures complete removal, potentially reducing recurrence and avoiding segmental bowel resection. Careful preoperative planning and meticulous robotic dissection and the integration of intraoperative ultrasound allow safe, complete excision while preserving bowel integrity.

https://player.vimeo.com/video/1193342139?autoplay=1

ESGE35-0912 -
Free Communication

Unusual locations of endometriosis - retrorectal disease

Maciej Pliszkiewicz[1], *Katarzyna Hanus-Durlej*[1], *Joanna Jacko*[1], *B. Paweł Siekierski*[1]
[1]*Medicover Hospital, Department of Gynaecology, Warszawa, Poland*

Background

Endometriosis affects 6% to 15% of the female population of childbearing potential, with a wide range of symptoms and complaints. Involvement of adjacent systems, such as digestive and/or urinary tracts, or nervous system, is a possible consequence of endometriosis. Depending on the disease location, the disease may produce variable symptoms, or none at all. The challenge begins when massive symptoms are present, but disease evidence is scarce or inexistent.

Methods

The objective was to present a case of challenging robotic surgery for suspected (and later confirmed) endometriosis of the retrorectal / precoccygeal space, with lacking pathological evidence of peritoneal or deep disease following a first line laparoscopy

Surgery was performed in a 38-year-old patient who presented with chronic pelvic pain radiating to the right buttock, vagina and rectum (VAS 10), constant dyschezia (VAS 7), dysuria (VAS 8) and dyspareunia (7/10), with minimal to moderate reaction following dienogest and relugolix therapy. The patient underwent laparoscopy and Douglas pouch peritonectomy at another facility, with no endometriosis present in the pathology report. Echography and MRI showed minimal evidence of adenomyosis, no evidence of other lesions, apart from a cystic lesion located between the rectum and the coccyx. Radiologists opted for endometriosis rather than a tailgut cyst, which was listed among other possibilities. With ineffective conservative approach, surgery was deemed necessary.

Results

Robotic surgery was performed, requiring extensive dissection of pararectal and retrorectal spaces, with access from both sides of the mesorectum. During surgery, a rectal probe and transvaginal echography were utilised as guiding methods, finally allowing the excision of a cystic lesion that did not appear to be endometriosis, but was confirmed as such in the final pathology report. Symptom nearly completely withdrew, the patient remains under follow-up, showing no evidence of recurrence.

Conclusions

Endometriosis remains a mystery disease that may be found in the least expected locations, such as the retrorectal space, and that without other apparent endometriotic lesions within the pelvis. This case shows how surprising it can be, and confirms how robotic surgery enables access to sites

https://player.vimeo.com/video/1195755847?autoplay=1

ESGE35-0221 -
Free Communication

Laparoscopic sacrocolpopexy (LSCP) for advanced pelvic organ prolapse: short and long term follow up data using polyvinylidene fluoride (PVDF) mesh.

Dimitrios Zygouris[1], Panagiotis Papandreou[1], Antonis Gkoutzioulis[1], Stergios Kopatsaris[2], Dimitris Grigoriou[3], Andreas Kavallaris[1,3]
[1]St. Luke's Hospital- Thessaloniki- Greece,
Department of Gynaecologic Oncology and Minimally invasive surgery, Thessaloniki, Greece
[2]Marienhospital Bottrop- Bottrop- Germany, Department of Gynaecology and Obstetrics, Bottrop, Germany
[3]Mother and child medical center- Nicosia- Cyprus,
Department of Gynecologic Oncology and Minimally invasive surgery, Nicosia, Cyprus

Background

Our aim was to evaluate the feasibility, safety and outcomes of laparoscopic sacrocolpopexy (LSCP) using polyvinylidene fluoride mesh (PVDF).

Methods

We analyzed retrospectively 277 women, who underwent laparoscopic genital prolapse repair at St. Luke's Hospital in Thessaloniki, Greece and at Mother and Child Medical Centre in Nicosia, Cyprus. The patients with Descensus uteri underwent total laparoscopic hysterectomy with BSO and then laparoscopic sacrocolpopexy using PVDF mesh. PRR for either cyctocele or rectocele and PRS for both. All the patients were reviewed at 1 month, 3 months, 9 months and then every 6 months after the surgery for a period of 5 years. The follow-up was between 6 months and 104 months (2015-2026).

Results

All procedures were successfully completed laparoscopically without any major intraoperative or postoperative complication. In 256 cases we performed Total Hysterectomy and Sacrocolpopexy. The median age was 60.1years and the median BMI 26.6 kg/m^2. The estimated blood loss was 67 ml and the median hospital stay 1.6 days. There was no case of vaginal erosion or infection, while there were 3 cystocele recurrence.

Conclusions

There were no major intraoperative or postoperative complications, and we had no mesh exposure or erosion. The mean hospitalization stay was 2.1 days. The laparoscopic sacrocolpopexy using PVDF is an effective and safe technique to repair the pelvic organ prolapses. The long term anatomical functional results are very satisfactory with no major complications.

ESGE35-0306 -
Free Communication

Robot-assisted single-port Burch colposuspension for stress urinary incontinence: a feasibility and early outcomes study

Leonardo Nelva Stelio[1], Eleonora Burello[2], Carmela Quatrale[1], Luca Calzolari[1], Federica Ottolini[1], Federico Spelzini[1]
[1]ASST Grande Ospedale Metropolitano Niguarda, OB/GYN, Milan, Italy
[2]Università degli Studi di Milano, Ob/Gyn, Milan, Italy

Background

Stress urinary incontinence (SUI) is common in urogynaecology and significantly affects quality of life. Mid-urethral slings are the most frequent treatment, but non-prosthetic alternatives are needed in cases of sling failure or contraindications to synthetic materials. Burch colposuspension is a well-established technique with favourable long-term outcomes. Robotic surgery, particularly the Da Vinci Single-Port System, allows complex pelvic procedures through a single access. This study evaluates the safety, feasibility, and functional efficacy of single-port robotic Burch colposuspension.

Methods

We conducted a retrospective analysis of 10 consecutive patients who underwent single-port robotic Burch colposuspension at Grande Ospedale Metropolitano Niguarda between May 2025 and February 2026. Demographic, clinical, and perioperative data were collected, including operative time, robotic docking time, estimated blood loss, Clavien–Dindo complications, and hospital stay. Functional outcomes were assessed using the International Consultation on Incontinence Questionnaire–Short Form (ICI-SF) pre- and postoperatively and patient-reported improvement via the Patient Global Impression of Improvement (PGI-I). Paired pre- and postoperative ICI-SF scores were compared using the Wilcoxon signed-rank test. Percentage reduction, effect size (r), and 95% confidence intervals (CI) were calculated.

Results

Mean age was 53 ± 7 years, mean BMI 28 ± 3 kg/m². Mean operative time was 126 ± 18 minutes, docking time 15 ± 4 minutes. Blood loss was minimal (<50 mL), with no conversions to laparotomy and no major complications. Median hospital stay was 2 days. At a median follow-up of 3 months, mean ICI-SF score improved significantly from 17 ± 3.2 to 3 ± 2.1, with a mean reduction of 82% ($p < 0.01$; $r \approx 0.80$; 95% CI 72–92%). Ninety percent of patients reported significant clinical improvement on PGI-I.

Conclusions

Single-port robotic Burch colposuspension is safe, feasible, and effective for treating SUI. The single-port approach offers minimally invasive access while maintaining robotic precision, representing a valid alternative in cases of sling failure or contraindications to prosthetic materials. Prospective studies with larger cohorts and longer follow-up are needed to confirm these findings.

ESGE35-0070 -
Free Communication

vNotes lateral suspension and high uterosacral ligament suspension for treating pelvic organ prolapse

Serkan Ustuntas[1], Kemal Gungorduk[2], Emre Biton[3]
[1]Faculty of Medicine- Muğla Sıtkı Koçman University, Department of Obstetrics and Gynaecology, Mugla, Türkiye
[2]Mugla Sıtkı Kocman University, Gynaecologic Oncology, Mugla, Türkiye
[3]Mugla Sitki Kocman University, Gynaecology and Obstetrics, Mugla, Türkiye

Background

Background: The aim of this video presentation is to demonstrate the surgical technique and feasibility of combining NOTES (Natural Orifice Transluminal Endoscopic Surgery) lateral suspension with high uterosacral ligament suspension for the management of advanced pelvic organ prolapse (POP).

Methods

Methods: We present the clinical evaluation of a 56-year-old obese woman (G3P3, BMI: 34 kg/m²) reporting pelvic pressure and the sensation of a vaginal bulge. Her personal and family medical histories were unremarkable. Clinical examination confirmed Stage 3 apical vaginal prolapse based on the POP-Q system (Point C: +4). A pelvic ultrasound demonstrated a normal-sized uterus with no endometrial abnormalities, leading to the decision for an endoscopic approach via the vaginal route.

Results

Results: The accompanying video thoroughly demonstrates the surgical steps, including obtaining pelvic access via the scarless NOTES technique, performing the lateral suspension, and subsequently applying a high uterosacral ligament suspension to further reinforce anatomical apical support. The surgical procedure was completed successfully.

Conclusions

Conclusions: The combined use of NOTES lateral suspension and high uterosacral ligament suspension is a safe, effective, and innovative minimally invasive surgical option for treating advanced apical prolapse. This approach is particularly advantageous for obese patients, as it completely avoids abdominal wall incisions and associated morbidities.

https://player.vimeo.com/video/1189151083?autoplay=1

ESGE35-0346 -
Free Communication

Combined laparoscopic lateral suspension and ventral rectopexy for multicompartment pelvic organ prolapse

Isabel Martínez Walters[1], *Inés Abad Martínez*[1], *Belén Ortiz Cruz*[1], *Josefa Ignacia Valdivieso Jara*[1], *Cristina Vera Mansilla*[2], *Juan Antonio Solano Calvo*[1]
[1]*Hospital Universitario Príncipe de Asturias, Ginecología y Obstetricia, Alcalá de Henares, Spain*
[2]*Hospital Universitario Príncipe de Asturias, Cirugía General y Aparato Digestivo, Alcalá de Henares, Spain*

Background

The compartments of pelvic organ prolapse (POP) can be treated individually, with surgical planning according to each patient's defects. This video demonstrates a laparoscopic lateral suspension combined with ventral rectopexy. The objective is to illustrate how to properly manage each of the compartments of the POP by multidisciplinary decision-making in one patient. The objective is to illustrate the multidisciplinary management of multicompartment POP and associated obstructed defecation syndrome in a single patient.

Methods

The patient is a 50-year-old woman with a grade III cystocele, grade II uterine prolapse, and grade II–III rectocele, associated with a widened genital hiatus and a paralateral defect. She also presented with obstructed defecation syndrome, which constituted an indication for ventral rectopexy. The patient was evaluated multidisciplinary by the Gynecology and the colorectal surgery team, and a combined laparoscopic approach was planned. Laparoscopic lateral suspension, as described by Dubuisson, was performed together with ventral mesh rectopexy. The procedure was completed with perineoplasty.

Results

The patient has no residual prolapse six months after surgery. In addition to the anatomical reconstruction, she experienced a marked improvement in obstructed defecation symptoms, achieving normal bowel function.

Conclusions

POP can be repaired compartment-by-compartment, with the collaboration of various specialists. It is important to pay attention to each patient´s defects to plan the surgery.

https://player.vimeo.com/video/1191520703?autoplay=1

ESGE35-0361 -
Free Communication

Safe Retropubic TVT Placement Using Laparoscopic Assistance

Yavuz Yilmaz[1], Ömer Faruk Öz[1], Can Dinç[1], Selen Doğan[2], Murat Özekinci[3], İbrahim İnanç Mendilcioğlu[4]
[1]Akdeniz University, Obstetrics and Gynaecology- TR-MIGS, Antalya, Türkiye
[2]Akdeniz University, Gynecologic Oncology- Obstetrics and Gynaecology- TR-MIGS, Antalya, Türkiye
[3]Akdeniz University, Reproductive Endocrinology and Infertility- Obstetrics and Gynaecology- TR-MIGS, Antalya, Türkiye
[4]Akdeniz University, Maternal-Fetal Medicine- Obstetrics and Gynaecology- TR-MIGS, Antalya, Türkiye

Background

To demonstrate retropubic mid-urethral sling placement under laparoscopic guidance for stress urinary incontinence (SUI) in a high-parity patient with multiple prior caesarean sections and coexisting pelvic organ prolapse, and to illustrate the role of simultaneous laparoscopic visualisation in ensuring safe bladder-sparing passage of the sling trocars.

Methods

A 41-year-old woman (gravida 6, para 5, one miscarriage; three deliveries by caesarean section, two vaginal) presented with stress urinary incontinence manifesting as urinary leakage on coughing and sneezing, alongside vaginal laxity and passage of vaginal flatus. She was an active smoker with a twenty-year history. Urodynamic assessment confirmed stress-predominant incontinence. Pelvic floor evaluation revealed a positive stress test, positive Q-tip test, grade 2 cystocele, and grade 1 uterine descent. Conservative management had been previously attempted. Retropubic mid-urethral sling placement was performed under general anaesthesia. A combined vaginal and laparoscopic approach was used: following suburethral tunnel dissection and sling trocar placement via the retropubic space, simultaneous laparoscopic visualisation of the space of Retzius was employed to confirm bilateral trocar passage lateral to the bladder and to exclude bladder injury in real time. Cystoscopy was performed at the conclusion of the procedure to confirm bladder integrity and bilateral ureteric jet patency.

Results

The procedure was completed without intraoperative complications. Laparoscopic visualisation confirmed safe bilateral trocar passage with no bladder injury. Cystoscopy demonstrated intact bladder mucosa and bilateral ureteric jets. The patient was discharged on postoperative day one. Stress urinary incontinence resolved at follow-up, with no voiding dysfunction reported.

Conclusions

Retropubic mid-urethral sling placement remains the gold standard surgical treatment for stress urinary incontinence. In patients with multiple prior caesarean sections and altered retropubic anatomy, simultaneous laparoscopic visualisation of the space of Retzius provides an additional layer of safety, enabling real-time confirmation of trocar position and immediate detection of bladder

injury. This technique should be considered in high-risk patients where retropubic anatomy may be distorted by prior surgery.

https://player.vimeo.com/video/1191534366?autoplay=1

ESGE35-0373 -
Free Communication

Awake robotic single port Burch: colposuspension under spinal-epidural anesthesia.

Leonardo Nelva Stelio[1], Luca Calzolari[1], Carmela Quatrale[1], Federica Ottolini[1], Claudia Granata[2], Federico Spelzini[1]
[1]ASST Grande Ospedale Metropolitano Niguarda, OB/GYN, Milan, Italy
[2]ASST Grande Ospedale Metropolitano Niguarda, Departments of Anaesthesiology, Milan, Italy

Background

Single Port (SP) robot-assisted Burch colposuspension is an effective surgical procedure for the treatment of female stress urinary incontinence. Traditionally, it is performed under general anesthesia. Recently, robot-assisted procedures under neuraxial anesthesia have been reported, demonstrating feasibility in selected patients.

Methods

We report a case of robot-assisted extraperitoneal Burch colposuspension performed under combined spinal–epidural anesthesia (CSE) using the da Vinci SP surgical system in a 40-year-old woman with bothersome daily stress urinary incontinence and a history of bilateral hysterosalpingectomy.

Results

The procedure was completed in the supine position via an extraperitoneal approach. Total operative time was 70 minutes, with negligible blood loss. No intraoperative complications occurred. The procedure was well tolerated, with effective postoperative pain control. The patient was discharged on postoperative day 1, with no post-void residual urine and complete resolution of stress urinary incontinence.

Conclusions

Robot-assisted extraperitoneal Burch colposuspension under combined spinal–epidural anesthesia appears to be a feasible and safe approach, potentially avoiding general anesthesia in selected patients. Larger studies are required to better define its role.

https://player.vimeo.com/video/1191558821?autoplay=1

ESGE35-0502 -
Free Communication

Mesh-free laparoscopic hysterosacropexy: the Bologna technique

Manuela Maletta[1,2], Alberto Aguzzi[1,2], Linda Bertoldo[1,2], Renato Seracchioli[1,2], Diego Raimondo[1]
[1]IRCCS Azienda Ospedaliero-Universitaria di Bologna,
Division of Gynecology and Human Reproduction Physiopathology, Bologna, Italy
[2]University of Bologna, Department of Medical and Surgical Sciences- DIMEC, Bologna, Italy

Background

Sacropexy is a surgical procedure consisting of suspension of the apical compartment to the anterior longitudinal ligament (ALL) and is widely considered the most effective surgical treatment for uterovaginal prolapse. When performed with uterine preservation, this procedure is called hysterosacropexy and is often performed with a polypropylene mesh attached caudally to the uterine isthmus and cranially to the sacral promontory. When mesh-related complications occur (e.g. erosion, infection etc.), they may significantly impair quality of life and are often difficult to manage because mesh removal is technically demanding. For this reason, mesh-free hysterosacropexy techniques are increasingly being investigated.

Methods

In this video article, we present a surgical demonstration of the Bologna mesh-free technique for laparoscopic hysterosacropexy (LSHP) in a 62-year-old postmenopausal woman with stage III pelvic organ prolapse with uterine leading edge, symptomatic for genital bulging, dyspareunia, and a sensation of incomplete bladder emptying.

The Bologna mesh-free technique for laparoscopic sacropexy can be applied to hysterosacropexy, cervicosacropexy, and colposacropexy. In case of LSHP, this technique involves suspension of the uterine isthmus to the ALL using a continuous nonabsorbable braided polyester suture (Ti-Cron™). The main steps of the surgical technique are described below.

5. After identification of the right ureter and exposure of the sacral promontory, the presacral space is dissected. The common iliac vessels, the superior hypogastric plexus, and the right hypogastric nerve are identified and preserved.
6. The suture is anchored to the ALL, taking care to preserve the middle sacral vessels and the autonomic nerve structures.
7. The right uterosacral ligament is then progressively plicated in a craniocaudal direction.
8. A second suture is used to perform a bilateral uterosacral ligament approximation (culdoplasty).
9. Using this second suture, the uterine isthmus is incorporated by creating a loop passage: posterior-to-anterior on the right side and backward on the left side.
10. The second suture is then secured to the first one using a suture-to-suture knot, allowing approximation of the uterus to the sacrum.

Written informed consent was obtained from the patient for presentation and publication of this video article.

Results

No intra- or postoperative complications were recorded. The patient was discharged after 24 hours from surgery. At 6-month follow-up, the patient showed no evidence of prolapse recurrence, with resolution of symptoms and no mesh-related complications.

Conclusions

LSHP using the Bologna mesh-free technique represents a feasible and effective minimally invasive option for the treatment of apical pelvic organ prolapse with uterine preservation while avoiding the use of synthetic mesh and its potential complications.

https://player.vimeo.com/video/1191673613?autoplay=1

ESGE35-0510 -
Free Communication

Combined vaginal and vNOTES repair of post-cystectomy anterior enterocele with vaginal vault prolapse and concomitant umbilical hernia: a video case report

Camilla Riccetti[1], Sara Mastrovito[2], Giovanni Panico[2], Davide Arrigo[1], Anna Fagotti[2], Francesco Fanfani[2]
[1]Fondazione Policlinico Universitario Agostino Gemelli IRCCS- Catholic University of the Sacred Heart, Department of Woman- Child and Public Health, Rome, Italy
[2]Gynecologic Oncology Unit- Fondazione Policlinico Universitario Agostino Gemelli IRCCS- Catholic University of the Sacred Heart, Department of Woman- Child and Public Health, Rome, Italy

Background

Vaginal and pelvic support defects after radical cystectomy are uncommon but challenging sequelae of oncologic pelvic surgery. Post-cystectomy anterior enterocele is rare, and evidence on optimal reconstructive management remains limited. This video case report describes a combined vaginal and transvaginal natural orifice transluminal endoscopic surgery (vNOTES) approach for post-cystectomy anterior enterocele, vaginal vault prolapse, and concomitant umbilical hernia.

Methods

A 58-year-old woman previously treated for urothelial carcinoma with radical cystectomy, hystero-adnexectomy, left nephroureterectomy, lymphadenectomy, right ureterocutaneostomy, and adjuvant chemotherapy was referred for a symptomatic residual vaginal canal defect. Computed tomography showed anterior enterocele with small bowel and mesenteric fat herniation into the vaginal lumen. Pelvic examination revealed a 4-cm anterior-apical vaginal wall defect. The procedure included partial vaginal colpectomy with frozen-section assessment, transvaginal vNOTES access, adhesiolysis, retropubic ligament colposuspension, vaginal colporrhaphy, and concomitant umbilical hernia repair.

Results

The procedure was completed through a combined vaginal and vNOTES approach. The compromised vaginal mucosa was circumferentially incised, excised, and sent for frozen-section evaluation, which was negative. After vNOTES access, apical support was restored by placing three PDS sutures on the retropubic ligament at the 10, 12, and 2 o'clock positions, followed by suspension of the anterior and lateral vaginal walls. A concomitant 5 × 6 cm umbilical hernia was repaired using a Symbiotex™ composite mesh fixed with two Prolene sutures and circumferential AbsorbaTack fixation. Operative time was 180 minutes, estimated blood loss was minimal, and no intraoperative or early postoperative complications occurred. The patient was discharged on postoperative day 2. At 3-month follow-up, prolapse symptoms had resolved, with no recurrence of the vaginal defect or umbilical hernia.

Conclusions

A combined vaginal and vNOTES approach may be feasible for selected patients with post-cystectomy anterior enterocele and concomitant umbilical hernia. Longer follow-up is required to assess durability and functional outcomes.

https://player.vimeo.com/video/1191672070?autoplay=1

ESGE35-0995 -
Free Communication

Laparoscopic sacrohysteropexy with bilateral pelvic floor mesh reinforcement for the management of uterovaginal prolapse

Aditya Moruskar[1], *Rahul Lakhe*[1]
[1]*Kalavati Hospital, Obgy, Akola, India*

Background

Uterovaginal prolapse is a debilitating condition arising from failure of pelvic floor muscular and ligamentous support, significantly impairing quality of life. While traditional repairs relying on approximation of weakened native tissues carry unacceptably high recurrence rates approaching 35% at two years, modern laparoscopic surgery has transformed management. For women desiring uterine conservation — a preference expressed by the majority when equally effective alternatives exist — laparoscopic sacrohysteropexy offers an effective, minimally invasive solution. The guiding principle is tension-free repair: a synthetic polypropylene mesh acts as a scaffold, inducing supportive fibrosis and creating a durable neo-ligament without subjecting tissues to tension.

Methods

We present a novel modification of laparoscopic sacrohysteropexy incorporating bilateral pelvic floor mesh reinforcement. Nine sequential steps define the technique:

1) Pre-sacral dissection on the right side
2) Retroperitoneal tunnelling medial to the right uterosacral ligament
3) Bilateral medial pararectal dissection to the pelvic floor
4) Broad ligament window creation bilaterally to facilitate para-cervical passage
5) Fixation of both arms of a Y-shaped mesh to the pelvic floor using non-absorbable sutures
6) Passage of a Mersilene tape through the lateral cervical wall bilaterally creating a neo-pericervical ring
7) Attachment of the mesh base to the Mersilene tape at the internal os level
8) Sacral fixation with non-absorbable sutures
9) Reperitonealization.

Results

Unlike conventional sacrohysteropexy, which fixes mesh solely to the posterior cervix, this modification distributes tension-free support across the entire pelvic floor.

Conclusions

Published success rates for laparoscopic sacrohysteropexy range from 85% to 100%, with a pooled anatomical success rate of 90% reported in systematic review. This novel technique aims to further reduce recurrence by simultaneously reinforcing apical, anterior, and posterior compartments while preserving the uterus and avoiding mesh exposure risks associated with concomitant hysterectomy.

https://player.vimeo.com/video/1200581114?autoplay=1

ESGE35-0364 -
Free Communication

Safety and feasibility of single-port robotic-assisted surgery for deep infiltrating endometriosis and adenomyosis: a one-year experience from a referral centre

Chiara Ripepi[1], *Martina Venier*[1], *Filippo Molinari*[1], *Mariateresa Mirandola*[1], *Giulia Bolomini*[1], *Daniele Mautone*[1]
[1]*P.Pederzoli Hospital, Obstetrics and Gynaecology, Peschiera del Garda VR, Italy*

Background

In recent years, robot-assisted surgery has gained increasing interest across several surgical fields, particularly in selected groups of patients. However, studies investigating the role of robotic surgery in the treatment of deep infiltrating endometriosis remain limited, especially when considering the Robot Single Port platform. Endometriosis and adenomyosis are benign diseases that typically affect young women and are characterized by a chronic and progressive course. In this context, surgery for deep infiltrating endometriosis represents a particularly challenging procedure.

Methods

This is a single-center, observational retrospective study evaluating prospectively collected data from our internal database. The study population included 33 patients who underwent surgery for suspected endometriosis or adenomyosis, based on symptoms and/or ultrasound findings, between June 2025 and April 2026. We collected anamnestic data (BMI, parity, comorbidities), surgical data (rASRM stage, site of localization), histopathological findings, and 30-day postoperative outcomes.

Results

Among the 33 patients, 14 (42%) were diagnosed with adenomyosis only, while 19 (58%) had endometriosis associated with adenomyosis. The mean age of the patients was 37 years. Among the 19 patients with endometriosis, 11 had deep infiltrating endometriosis (DIE), classified as rASRM stage III (7) or IV (6), and 6 had superficial endometriosis stage II. 24 patients (73%) underwent hysterectomy, including 11 B1 radical hysterectomies according to the Querleu–Morrow classification (in patients with associated endometriosis). 9/33 patients who were younger or wished to preserve fertility underwent bilateral nerve-sparing parametrectomy associated with bilateral ureterolysis. Additional procedures included one discoid resection, one rectal shaving, one vaginal resection, one vaginal shaving and one bladder shaving. The mean operative time was 140 minutes, considering that abdominal access and robot docking required approximately 15 minutes. There were no conversions to laparotomy and the median estimated blood loss was 50 ml. The median length of hospital stay was 4 days for patients who underwent parametrectomy and 3 days for the others. Only two Clavien–Dindo complications ≥ II occurred. No anastomotic leaks, postoperative ileus, blood transfusion requirements, or voiding dysfunction were observed, and all patients reported symptom improvement within 30 days.

Conclusions

Robot-assisted single-port surgery for adenomyosis and deep infiltrating endometriosis is safe and feasible, with acceptable operative times and hospital stay, and a low risk of postoperative complications. Moreover, it enables surgeons to perform technically challenging procedures through a 2.5–3 cm peri-umbilical incision, providing excellent access to the abdominal cavity while ensuring a satisfactory aesthetic result.

ESGE35-0408 -
Free Communication

Patient-reported cosmetic outcomes after robotic and laparoscopic hysterectomy

Pier Carlo Zorzato[1], Calogero Dario Savio Montaperto[1], Marco Tondi[1], Erica Trimarchi[1], Simone Garzon[1], Stefano Uccella[1]
[1]University of Verona, Obstetrics and Gynaecology, Verona, Italy

Background

To compare patient-reported cosmetic outcomes between robotic and conventional laparoscopic hysterectomy and to evaluate the impact of trocar positioning and trocar size on scar perception and patient satisfaction following minimally invasive surgery.

Methods

A prospective observational comparative study was conducted on consecutive patients undergoing minimally invasive hysterectomy during 2024 and 2025. Patients were treated either by conventional laparoscopy or robotic surgery using three robotic platforms. Trocar placement differed according to surgical approach and platform configuration. At 6-month follow-up, cosmetic outcomes were assessed using the Patient Scar Assessment Scale (PSAS) 3.0 questionnaire evaluating scar appearance, pain, sensitivity, colour, and overall satisfaction. Patients were additionally asked to identify the scar perceived as the worst. The primary endpoint was global cosmetic satisfaction. Secondary endpoints included identification of the worst scar site and analysis of scar-related symptoms.

Results

A total of 310 patients were included: 153 underwent conventional laparoscopy and 157 robotic surgery. Patients undergoing robotic surgery were older than those treated by laparoscopy (57.8±11.9 vs 52.0±9.3 years, $p<0.001$), while BMI and parity were comparable between groups. Robotic surgery was associated with longer operative times (145.4±47.9 vs 120.6±43.5 minutes, $p<0.001$). Cosmetic satisfaction was significantly higher after conventional laparoscopy, with better global PSAS satisfaction scores compared with robotic surgery (4.68±0.57 vs 4.41±0.82, $p=0.010$). Uniform scar perception (“all scars equal”) was more frequent after laparoscopy (76% vs 25%), whereas robotic surgery was associated with a dominant poorly tolerated scar ($p<0.001$). In robotic procedures, the worst scars were predominantly located at Palmer’s point (29%) and the umbilical site (30%). Robotic surgery was also associated with poorer patient-reported scar outcomes, including worse scar colour ($p=0.014$), increased pain ($p=0.016$), and altered sensitivity ($p=0.027$).

Conclusions

Robotic hysterectomy was associated with lower patient-reported cosmetic satisfaction compared with conventional laparoscopy at 6-month follow-up. Trocar positioning appears to represent a critical and potentially modifiable determinant of cosmetic outcomes, particularly regarding upper abdominal access sites. These findings challenge the assumption of cosmetic equivalence among

minimally invasive approaches and support optimization of robotic trocar strategies to improve patient-centered outcomes.

ESGE35-0701 -
Free Communication

Laparoscopic versus robotic excision of endometriosis requiring bowel intervention: a retrospective comparative audit

Mohamed Elsheikh[1], *Spyridon Roditis*[2], *Gourab Misra*[1], *Zeiad El-Gizawy*[1]
[1]*University Hospitals of North Midlands- UK, Obstetrics and Gynaecology, Stoke On Trent, United Kingdom*
[2]*University Hospitals of North Midlands- UK, General Surgery/Colorectal Surgery, Stoke On Trent, United Kingdom*

Background

Bowel endometriosis frequently requires complex minimally invasive surgical management. Robotic surgery has increasingly been adopted; however, comparative data with conventional laparoscopy remain limited. This audit aimed to compare perioperative outcomes between laparoscopic and robotic approaches in patients undergoing excision of endometriosis requiring bowel intervention.

Methods

A retrospective audit was performed of patients undergoing surgery for endometriosis between **2016 and 2025**. Patients requiring bowel intervention were included, comprising rectal shave, disc excision and anterior/segmental resection procedures. Converted cases were retained within the laparoscopic cohort. Data collected included demographics, type of bowel intervention, operative time, length of stay, conversion rates, postoperative complications and requirement for further surgery.

Results

A total of **211 cases** were included: **136 laparoscopic** and **75 robotic**. Median age was similar between groups (**39 vs 39 years**), while median BMI was slightly higher in the robotic cohort (**25.9 vs 28.5 kg/m²**). The distribution of bowel interventions differed between groups. In the laparoscopic cohort, procedures included shave (**73/136**), disc excision (**26/136**) and anterior resection (**37/136**). In the robotic cohort, procedures included shave (**48/75**), disc excision (**20/75**) and anterior resection (**7/75**).

Median operative time was shorter in the robotic group (**155.5 vs 203 minutes**), with shorter median length of stay (**2 vs 3 days**). Conversion to open surgery occurred in **3 laparoscopic cases** and **0 robotic cases**. Major complications were comparable (**6/136; 4.4%** vs **4/75; 5.3%**). Further surgery was recorded more frequently following laparoscopy (**21/136; 15.4%**) compared with robotic surgery (**5/75; 6.7%**).

Conclusions

Robotic excision of endometriosis requiring bowel intervention was associated with shorter operative duration and shorter length of stay, while major complication rates remained similar between approaches. Differences in procedure complexity and distribution between cohorts should be considered when interpreting these findings.

ESGE35-0961 -
Free Communication

Does the MIS surgical approach impact in perioperative results in endometrial cancer patients?

Ramon Rovira[1], Giulio Bonaldo[2], Marta Sanjose[3], Alba Farres[3], Cristina Soler[3], Silvia Cabrera[3]
[1]Hospital Sant Pau Barcelona- Spain, Gynaecology Oncology, Barcelona, Spain
[2]Hospital Sant Pau, Gynaecology Oncology, Barcelona, Spain
[3]Hospital Sant Pau, Gyn Onc, Barcelona, Spain

Background

To evaluate perioperative surgical results in Endometrial Cancer patients surgically treated by MIS approach including laparoscopy, XI Multiport and Single Port Da Vinci Platform.

Methods

We conducted a retrospective study of Endometrial Cancer patients surgically treated at Hospital Sant Pau from January 2018 to May 2026. MIS Surgical approach was divided in 3 groups (laparoscopy, XI Da Vinci System and SP Da Vinci System). Several clinical variables wer analysed: Age, BMI, ASA, Surgical approach, Conversion to laparotomy and reason, surgical time, blood loss, number of transfusions, reoperation and reason, hospital stay, intraoperative and post-operative complications, Clavien Dindo classification. Surgical technique was classified in different groups (Hysterectomy and bilateral adnexectomy +/- SLND +/- Pelvic Lymphadenectomy (Unilat / Bilat) in case of no ICG migration.

Results

From a total of 236 patients, we excluded 49 patients which lymph node assessment included paraaortic lymphadenectomy. 187 patients were enrolled in the study (91 laparoscopy, 80 Xi, 15 SP)

No statistical differences were observed in all the variables studied. Surgical time was slightly shorter in SP system. No differences were observed in intra and post-operative complications and in median hospital stay.

	Laparoscopy	**XI**	**SP**
Age	62	63	59
IMC	31	32	27
Conversion to laparotomy	no	1	No
Reason		Severe adhesions	
Surgical time	129	153	120

	Laparoscopy	XI	SP
Blood loss	90	69	77
Hospital stay	2,5	2,4	3,2

Conclusions

Robotic learning curve in Xi and SP platforms did not impact in worse perioperative results in Endometrial Cancer Surgical procedures in a previous high experienced team in laparoscopic approach.

ESGE35-0102 -
Free Communication

Robotic resection of metastatic lymph nodes

Xiang Xue[1], *Pijun Gong*[2]
[1]*the Second Affiliated Hospital of Xian Jiao Tong University, Dept of Obstetrics and Gynaecology, Xi'an, China*
[2]*The second affiliated hospital of Xi'an jiao tong university, Dept of Obstetrics and Gynaecology, Xi'an, China*

Background

Through surgical demonstration of robot-assisted laparoscopic resection of huge metastatic lymph nodes at para-aorta, and the bifurcation of the internal and external iliac veins in the pelvis, and beside the obturator nerve, to discusses the key points and strategies of robotic surgery, to demonstrates the advantages of robot-assisted laparoscopic surgery in metastatic lymphadenectomy.

Methods

A 56-year-old patient, postmenopausal vaginal bleeding for 8 months. endometrial biopsy: endometrioid adenocarcinoma. MRI and CT ： enlarged lymph nodes around the right iliac vessels, and in front of the inferior vena cava. perform extended total hysterectomy, pelvic and para - aortic lymphadenectomy.

Results

successfully completed robot-assisted laparoscopic extended total hysterectomy with bilateral adnexectomy, pelvic and para-aortic lymphadenectomy. during the operation, a huge metastatic lymph node (6x6x5.5cm) beside the aorta and metastatic lymph nodes (3x2.5x3cm) at the medial side of the intersection of the external and internal iliac veins and beside the obturator nerve were smoothly and completely resected. The intraoperative blood loss was 30ml, and the patient was discharged smoothly after the operation.

Conclusions

1, the robotic surgical system has advantages such as 360° wristed instruments, tremor filtration, ergonomic design, a higher-magnification surgical field, and naked-eye 3D vision. that are conducive to performing anatomical operations of para-aortic lymph node dissection with higher precision and reducing surgeons' dependence on assistants.
2, create tension with the third arm for easy separation, but avoid excessive traction at the same time.
3, the first step is to free the tissues around the mass. isolating the transferred mass, then it dissected from the blood vessels and nerves. this is an important strategy to facilitate the prevention of rupture and bleeding of the transferred blood vessels and ensure better control.
4, attempt to resect metastatic lymph nodes completely, and do not disrupt the capsule of nodes to

prevent cancer implantation or dissemination. meanwhile, promptly place the resected nodes into a bag.

https://player.vimeo.com/video/1190718448?autoplay=1

ESGE35-0473 -
Free Communication

Robotic-assisted isthmocele repair under indocyanine green fluorescence guidance

Chaima Mbarki[1], Marie Carbonnel[1], Hind Abbou[1], Jennifer Asmar[1], Jean-Marc Ayoubi[1]
[1]Foch University Hospital,
Department of Obstetrics and Gynaecology and Reproductive medicine- Professor Jean-Marc Ayoubi, Suresnes, France

Background

The isthmocele, a complication of caesarean section, is being diagnosed with increasing frequency. It is associated with pelvic pain, abnormal uterine bleeding, infertility, and impaired quality of life. With the development of minimally invasive techniques, its management has become increasingly standardized. Among these, indocyanine green (ICG) fluorescence imaging has emerged as a valuable intraoperative tool, improving the identification of anatomical planes and scar boundaries and enabling safer and more precise surgical repair.

Methods

We present the case of a 35-year-old woman (Gravida 2 and Para 1) who had a caesarean section in 2023. In 2025, she presented with an ectopic pregnancy in the niche of the caesarean scar, which was managed with two doses of methotrexate followed by aspiration of the gestational sac. She subsequently developed pelvic pain and intermenstrual bleeding. An ultrasound demonstrated a full-thickness isthmocele with a residual myometrial thickness of 2 mm. After obtaining informed consent, we performed a robot-assisted laparoscopic isthmocele repair. Indocyanine green (ICG) was injected vaginally, and Firefly fluorescence imaging was used to map the C-section defect intraoperatively, enhancing visualization of tissue planes and guiding dissection. This procedure enabled the precise identification of the isthmocele margins under fluorescence guidance, facilitating accurate tissue dissection for optimal repair.

Results

The surgery was uneventful with 1-days hospital stay, and symptoms resolved completely.

Conclusions

Robot-assisted laparoscopic repair of caesarean scar defect (isthmocele) is a feasible and effective minimally invasive approach allowing precise dissection with uterine preservation. The use of indocyanine green fluorescence imaging in Firefly mode enhances intraoperative visualization of the defect and surrounding tissue planes, facilitating accurate and tailored repair. This technique may contribute to improved fertility outcomes and enhanced quality of life in patients affected by symptomatic isthmocele.

https://player.vimeo.com/video/1191325709?autoplay=1

ESGE35-0275 -
Free Communication

Single-port robotics in giant uterus surgery: coordinated instrumentation within a restricted operative field

Saima Farooq[1], Amer Raza[1], Kostas Lamprou[2]
[1]Cromwell Hospital, Gynaecology, London, United Kingdom
[2]Chelsea and Westminster hospital NHS Foundation Trust

Background

Robotic hysterectomy is increasingly utilised in the management of complex benign and malignant uterine pathology, particularly in cases involving markedly enlarged uteri. While conventional multiport robotic systems have expanded the boundaries of minimally invasive surgery, the evolution of single-port robotic platforms introduces a distinct operative perspective in which spatial orientation, instrument geometry, and coordinated movement become fundamental to navigating distorted pelvic anatomy safely and efficiently.

Methods

This video presentation demonstrates a single-port robotic hysterectomy performed for a significantly enlarged uterus weighing 1.4 kg. A structured stepwise operative strategy is illustrated, including abdominal entry, bladder mobilisation, retroperitoneal exposure, identification and control of the uterine vasculature, and progressive specimen mobilisation. A key technical feature of this approach is the coordinated deployment of four articulating robotic instruments through a single access point. The video highlights how instrument choreography, traction-countertraction dynamics, and controlled energy application can be synchronised within a confined operative field to facilitate precise dissection and maintain anatomical orientation throughout surgery. Particular emphasis is placed on the geometric alignment of instruments and optimisation of operative angles during complex pelvic dissection.

Results

The single-port robotic platform provided a centralised coaxial operative view, enhancing access to deep pelvic structures and facilitating controlled vascular dissection. Despite the substantial uterine size, the procedure was completed efficiently without the need for additional ports or conversion. Instrument articulation and spatial coordination allowed stable tissue handling and anatomically consistent dissection throughout the operation.

Conclusions

This case demonstrates how single-port robotic hysterectomy can successfully address the technical challenges associated with giant uteri through refined spatial geometry and coordinated instrument control. In experienced hands, this approach supports precise minimally invasive surgery, streamlines complex pelvic dissection, and reinforces the expanding role of single-port robotics in advanced gynaecological surgery.

https://player.vimeo.com/video/1199574565?autoplay=1

ESGE35-0417 -
Free Communication

Robotic single-port hysterectomy for a 2 kg uterus: feasibility and outcomes in extreme uterine enlargement

Leonardo Nelva Stelio[1], Luca Calzolari[1], Carmela Quatrale[1], Federica Ottolini[1], Federico Spelzini[1], Marco Battistello[1]
[1]ASST Grande Ospedale Metropolitano Niguarda, OB/GYN, Milan, Italy

Background

The management of very large uteri remains a challenge in minimally invasive gynecologic surgery. Robotic single-port (SP) platforms may may increase indications even in extreme cases. This video aims to demonstrate the feasibility, safety, and technical considerations of robotic SP hysterectomy for a massively enlarged uterus.

Methods

A robotic single-port hysterectomy was performed using the Da Vinci SP system through a single umbilical incision in a 50-year-old woman (height 160 cm, weight 80 kg BMI 31) with symptomatic uterine fibromatosis. The patient presented with pelvic bulk symptoms, including difficulty with bowel and bladder emptying, and severe menometrorrhagia leading to acute anaemia requiring intravenous iron therapy. Preoperative MRI showed no suspicion of sarcoma. The uterus reached 2 cm above the transverse umbilical line, with predominant fundal development, corresponding to approximately 18 weeks' gestation size (largest myoma 16×11×15 cm). Temporary vascular control was achieved by bilateral clamping of the uterine arteries at their origin. Total hysterectomy was completed robotically via single-port access. Specimen extraction was performed by contained morcellation.

Results

Total operative time was 80 minutes. Vaginal Morcellation required an additional 90 minutes. Estimated blood loss was approximately 100 mL. No intraoperative or postoperative complications occurred. The postoperative course was uneventful, and the patient was discharged on postoperative day two.

Conclusions

Robotic single-port hysterectomy is a feasible and safe approach even in cases of extreme uterine enlargement when performed in experienced hands. Adequate vascular control and careful preoperative assessment are key to minimizing blood loss. This approach challenges traditional size limitations of minimally invasive surgery and supports the advantages of single-port robotics in complex gynecologic cases.

https://player.vimeo.com/video/1191613497?autoplay=1

ESGE35-0610 -
Free Communication

Robotic laparoscopic hysterectomy without a uterine manipulator: an anatomy-driven, blood-sparing approach in a patient with cervical stenosis

E Cansu Cevik[1], Yasmin Abozenah[2], Andriana Marijic Buljubasic[3], Gary Altwerger[4]
[1]Yale School of Medicine, Obstetrics- Gynaecology- and Reproductive Sciences, New Haven, USA
[2]University of South Florida- Tampa General Hospital Cancer Institute,
Department of Obstetrics and Gynaecology- Division of Gynecologic Oncology, Tampa, USA
[3]Yale School of Public Health, Social and Behavioral Sciences- Maternal & Child Health Promotion, New Haven, USA
[4]University of Chicago School of Medicine,
Department of Obstetrics & Gynaecology- Division of Gynecologic Oncology, Chicago, USA

Background

Cervical stenosis and large myomatous uterus may make placement of a uterine manipulator impossible during minimally invasive hysterectomy. In such cases, the absence of a manipulator can increase the technical demands of uterine traction, exposure of surgical planes, vascular control, colpotomy, and maintenance of hemostasis. This is more challenging when there is a fibroid uterus with significant blood supply. This video demonstrates a robotic laparoscopic hysterectomy performed without a uterine manipulator in a patient with a 19 cm, 810 grams myomatous uterus and cervical stenosis, emphasizing an anatomy-driven strategy based on early retroperitoneal dissection, ureteral safety, and vascular control at the origin.

Methods

The video presents a stepwise robotic technique for complex hysterectomy without intrauterine manipulation. Initial inspection demonstrates the uterus, adnexa, and operative anatomy. The retroperitoneal spaces are developed early to identify critical landmarks, including the ureter, external iliac vessels, and uterine vessels. The uterine artery and accompanying veins are skeletonized and controlled at their origin to achieve early devascularization, development of the pararectal, paravesical and Latzko's space, allowing for vascular control before colpotomy. Uterine mobilization, colpotomy, specimen management, and vaginal cuff closure are completed robotically without routine assistant suction.

Results

The procedure demonstrates that complex robotic hysterectomy can be completed safely without a uterine manipulator in the setting of a large (19 cm) myomatous uterus with cervical stenosis. Early retroperitoneal access allows consistent identification and lateralization of the ureters before desiccation of uterine vessels. Bilateral control of the uterine arteries at their origin results in progressive devascularization of the uterus, reduced venous engorgement, and minimal visible blood loss throughout the operation. Adequate exposure is achieved through robotic traction, countertraction, and anatomy-based dissection rather than intrauterine manipulation. The colpotomy

and vaginal cuff suturing are completed with preserved hemostasis. The final operative field demonstrates excellent anatomic exposure and no significant blood accumulation.

Conclusions

Manipulator-free robotic laparoscopic hysterectomy in a large myomatous uterus is feasible in selected complex cases when guided by a structured retroperitoneal, anatomy-first approach. Early ureter identification and vascular control at the origin may enhance safety and minimize blood loss, particularly when cervical stenosis prevents manipulator placement. This technique may have broader implications for blood-conservation surgery, low-resource or reduced-staffing environments, reduced operative clutter, and advanced robotic surgical autonomy and efficiency.

https://player.vimeo.com/video/1195548617?autoplay=1

ESGE35-0759 -
Free Communication

Robotic resection of peritoneal recurrence in a dermatofibrosarcoma protuberans-like low-grade uterine mesenchymal neoplasm: a case report with surgical video

Maria Varone[1], *Chiara Munerol*[1], *Giorgio Bogani*[1], *Simone Bruni*[1], *Simona Palladino*[1], *Valentina Chiappa*[1]
[1]*Fondazione IRCCS Istituto Nazionale dei Tumori, Gynaecologic Oncology, Milan, Italy*

Background

A 48-year-old nulliparous woman underwent total hysterectomy and bilateral salpingectomy at an outside institution in 2019 for a suspected low-grade leiomyosarcoma (16 cm). Histological revision at our institution identified a hypercellular mesenchymal neoplasm harbouring the COL1A1-PDGFB fusion gene onFISH analysis, leading to the conclusive diagnosis of low-grade uterine mesenchymal neoplasm resembling dermatofibrosarcoma protuberans (DFSP-like). Due to the known imatinib sensitivity of DFSP, systemic treatment with imatinib 400 mg/day was initiated in August 2020 following radiological evidence of peritoneal recurrence (right pelvic sidewall nodule 18 mm, left pelvic nodule 7 mm). The patient achieved complete radiological response by November 2022. However, by March 2026, MRI and PET-FDG documented disease recurrence with a 40 mm solid retrovesical nodule (SUVmax 3.4). Following multidisciplinary tumor board discussion, surgical resection was indicated.

Methods

Preoperative transvaginal ultrasound performed by an expert examiner demonstrated a recurrent lesion adherent to the peritoneum overlying the vaginal vault and prevesical space, without infiltration of adjacent organs. Based on these findings, the patient underwent robot-assisted minimally invasive surgery. The procedure included excision of the peritoneal recurrence, achieved without the need for visceral resection thanks to the preserved cleavage planes identified pre-operatively.

Results

The video illustrates key surgical steps: identification and dissection of the lesion from the vaginal vault peritoneum and prevesical space, careful preservation of bladder and rectum exploiting the intact tissue planes, and en-bloc specimen retrieval.

Conclusions

This case highlights the role of expert ultrasound assessment in guiding surgical planning and supports the feasibility of precision robotic surgery combined with targeted therapy in the multidisciplinary management of rare uterine mesenchymal tumors.

https://player.vimeo.com/video/1195437495?autoplay=1

ESGE35-0935 -
Free Communication

Single-port robotic-assisted hysterectomy, bilateral adnexectomy, omentectomy and bilateral icg-guided sentinel lymphonodectomy in a 84-year-old patient with serous endometrial cancer.

Harald Krentel[1]
[1]*Klinikum Aschaffenburg, Gynaecology and Obstetrics, Aschaffenburg, Germany*

Background

With this video we aim to demonstrate the use of single-port robotic assisted surgery in the minimally invasive surgical treatment of serous cancer in an elderly patient and highlight the advantages of this innovative technology.

Methods

We present a video case of an 84-year-old patient with serous cancer undergoing an oncological procedure including hysterectomy, bilateral salpingo-oophorectomy, infracolic omentectomy and ICG-guided pelvic lymphonodectomy. We demonstrate peri- and post-operative outcomes.

Results

The surgery was uneventful, without any complications. Operative time was 135 min. Histopathological examination revealed serous endometrial carcinoma and the final classification was pT1a pN0 (0/3sn) M0 L0 V0 R0, G3. Length of hospital stay was 3 days. No intra- or postsurgical complications occurred.

Conclusions

The video case report demonstrates the feasibility of single-port robotic surgery in elderly patients with serous endometrial cancer. The minimally invasive single-incision approach in combination with the possibility to access all four abdominal quadrants represent the main advantages of this technology. This allows for a fast mobilization and fast recovery of elderly patients combined with a short length of hospital stay. Future studies have to confirm these outcomes.

https://player.vimeo.com/video/1195766601?autoplay=1

ESGE35-0195 -
FC 17: Free Communication in Plenary

Artificial intelligence in gynaecology: the importance of transparency, accuracy, and honest representation

Amr Magdi Mohamed Moneib[1]
[1]*London Northwest Healthcare NHS Trust, Obstetrics and Gynaecology, London, United Kingdom*

Background

Artificial intelligence (AI) is being increasingly marketed within healthcare including gynaecology, imaging, education, workflow optimisation and surgical planning. But the rapid commercialisation of systems has led to the increasing misapplication of the term "AI", with systems as diverse as real adaptive machine learning systems, simple scripted automation, presentation software or avatar-generation platforms being interchangeably described as artificial intelligence. Such imprecision is likely to confuse clinicians, researchers, institutions and patients about the true capabilities, limitations and evidence base of emerging technologies. Sometimes claims of proprietary algorithms, years of software development or "self-built AI systems" are exaggerated and do not reflect the underlying technology being deployed. Therefore, honest scientific reporting is essential for the integrity of academia and the trust in digital innovation in medicine.

Methods

To examine the importance of transparency and accurate terminology in the presentation of AI technologies within gynaecology and digital health.

Results

True AI systems use adaptive computational methodologies such as machine learning, neural networks, probabilistic modelling or data-driven model refinement. Many products marketed as "AI" on the other hand are based on pre-existing commercial platforms, scripted workflows or audiovisual rendering technologies, and lack true model adaptation or autonomous learning capability. With an increasing reliance on tools created by others for avatars, language models, automated media software, the line between innovation and repackaging has become blurred. These technologies may still have some clinical utility, but confusing them with AI developed independently or exaggerating the difficulty of development does not contribute to scientific credibility.

Full disclosure is required on the part of academic medicine on:the base technologies, the level of model adaptation, sources of data and training methodology, software dependencies and actual developmental contribution.

Conclusions

There is huge potential for AI to change the way gynaecological care, education and surgical planning are delivered. But the progress depends not only on the development of technology but also on the integrity of the description and presentation of innovations. It is important to make a clear distinction

between adaptive AI systems, automation tools and presentation technologies to enable responsible research, ethically sound adoption and meaningful scientific progress.

ESGE35-0725 -
FC 17: Free Communication in Plenary

Artificial intelligence-assisted operative coding in minimally invasive gynaecological surgery: a pilot quality improvement project in a district general hospital

Hira Fatima[1], *Javeria Zahid*[2], *Muazzam Ali*[3], *Samreen Muhammad*[4], *Remko Beukehnholdt*[5]
[1]*Darlington Memorial Hospital, Gynaecology and Obstetrics, Stockton-on-Tees, United Kingdom*
[2]*Independent University Hospital, Surgery, Faisalabad, Pakistan*
[3]*Holy Family Hospital, Paediatrics, Islamabad, Pakistan*
[4]*Sheffield Teaching Hospital, Gynaecology and Obstetrics, Sheffield, United Kingdom*
[5]*Darlington Memorial Hospital, Gynaecology and Obstetrics, Darlington, United Kingdom*

Background

Accurate operative coding in minimally invasive gynaecological surgery is important for clinical documentation, service evaluation and NHS reimbursement. Complex laparoscopic and robotic procedures can be undercoded, particularly when operative notes contain multiple surgical steps. We aimed to assess whether artificial intelligence (AI)-assisted review of operative notes could improve identification of procedural coding elements in minimally invasive gynaecological surgery.

Methods

This pilot quality improvement project was carried out in a district general hospital between October 2025 and March 2026. Data were collected retrospectively from 55 robotic and advanced laparoscopic gynaecological procedures including robotic hysterectomy, laparoscopic hysterectomy, endometriosis surgery, adhesiolysis, ureterolysis and bilateral salpingo-oophorectomy.

Original operative coding assigned through standard hospital coding pathways was compared with AI-assisted review of anonymised operative notes. AI-assisted review was performed using a large language model to identify potentially missed procedural components from free-text operative documentation. Suggested coding elements were reviewed by the surgical team prior to comparison with final coding outcomes.

Outcome measures included coding discrepancy rate, additional procedural elements identified, estimated financial impact and time required for coding review

Results

AI-assisted review identified additional coding elements in 27.3% (15/55) of cases compared with standard coding pathways. Commonly missed procedural components included adhesiolysis, ureterolysis, excision of endometriosis and retroperitoneal dissection, particularly in more complex robotic procedures.

A total of 23 additional procedural coding elements were identified following AI-assisted review. The intervention identified potential undercoding associated with an estimated annual tariff recovery of £12,400 if applied across the unit's minimally invasive gynaecological workload.

Mean time required for coding review reduced from approximately 11 minutes to 6 minutes per case following introduction of AI-assisted support. The intervention also improved consistency of operative documentation review in procedures involving multiple surgical components.

Conclusions

AI-assisted review of operative notes improved identification of procedural coding elements in minimally invasive gynaecological surgery within a district general hospital setting. The project demonstrated potential financial benefit for the NHS through improved recognition of operative complexity and reduced risk of undercoding complex laparoscopic and robotic procedures.

AI-assisted coding review may provide a practical and cost-effective method for supporting accurate documentation and improving administrative efficiency within advanced minimally invasive gynaecology services.

ESGE35-0452 -
FC 17: Free Communication in Plenary

AI assisted detection of deep rectosigmoid endometriosis on transvaginal ultrasound and rectosonography

Charles Jayyosi[1], Mathilde Borrot[2], Florian Cartier[2], Marylin Rolfe[2], Alexia Mazard[1], Gil Dubernard[1]
[1]Hospices Civils de Lyon- Hôpital de la Croix Rousse, Gynecologie et Obstétrique, Lyon, France
[2]Femnov, Research and Development, Paris, France

Background

In recent years, considerable efforts have been directed toward improving diagnostic approaches for deep infiltrating endometriosis (DE). Transvaginal ultrasound (TVUS) and rectosonography (TVUS with rectal water contrast) has been proposed as a first-line imaging procedure in cases of suspected endometriosis by several clinical guidelines issued by learned societies.
Given the numerous diagnostic challenges associated with endometriosis and the high level of expertise required to perform and interpret transvaginal rectosonography, artificial intelligence (AI) has emerged as a promising assistance to support endometriosis diagnosis in the near future.

Methods

Three readers — junior, intermediate (gynaecology resident), and expert (senior gynaecologist who also defined the ground truth) — analysed the same set of 50 video clips twice: first unaided, then with an AI overlay displaying tracked detections of rectosigmoid endometriotic nodules. The clip order differed between sessions to limit memorization, with a mandatory washout between sessions. For each clip, readers localized suspected nodules with bounding boxes, answered a structured questionnaire, and rated their confidence on a 1–5 Likert scale. Decision time per clip was logged automatically.

The set of 50 video clips included 32 patients (18 with confirmed DE lesions, 12 without DE lesion as controls). Diagnostic metrics (sensitivity, specificity, F1) were computed at lesion, clip and patient level against the expert reference. AI vs. no-AI comparisons used a repeated-measures analysis of variance (ANOVA) and the Wilcoxon signed-rank test. The study used anonymized clinical imaging and was conducted in accordance with the institutional ethics framework for retrospective imaging research.

Results

AI assistance produced large, consistent gains for the junior reader: lesion-level sensitivity increased from 22.9% to 77.8% (+54.9 percentage points, pp); patient-level F1 from 28.6% to 85.0% (+56.4 pp); confidence from 2.56 to 3.60 (+1.04 pt, $p<10^{-6}$); decision time decreased from 79.0s to 47.6s per clip (−31.3s, $p<10^{-5}$). The intermediate reader was already near-ceiling unaided (lesion-level F1 90.1% vs. 89.6% with AI) but read significantly faster (64.5s → 52.2s, p=0.001). The expert reader showed no change in accuracy, confidence or decision time. At every analysis level, the human + AI pair reached a higher F1 than the AI alone. Pooled across readers, confidence increased (+0.41 pt, $p<10^{-6}$) and decision time fell (−11.7s, p≈0.001).

Conclusions

AI assistance behaved as a leveller: large diagnostic, confidence and time gains were concentrated in the non-expert reader, intermediate performance was preserved with faster reading, and expert performance was unaffected. This profile supports deployment of AI as decision-support both in initial training of sonographers and in routine practice, while reaffirming the need and crucial role of human readers.

https://player.vimeo.com/video/1191638890?autoplay=1

ESGE35-0101 -
Free Communication

High-intensity focused ultrasound treatment of rectal endometriosis: short- and long-term results of a double-blind randomised trial versus sham procedures

Gil Dubernard[1], *Alexia Mazard*[2], *Manon Basso*[2], *Charles Jayyosi*[2]
[1]*Croix-Rousse University Hospital- Hospices Civils de Lyon- Université Claude Bernard Lyon 1, Gynaecology Obstetrics, Lyon, France*
[2]*Croix-Rousse University Hospital- Hospices Civils de Lyon, Gynaecology Obstetrics, Lyon, France*

Background

Rectal endometriosis often generates pain and digestive disorders. We tested the ability of high-intensity focused ultrasounds (HIFU) to shrink the lesions, relieve pain, and alleviate digestive symptoms

Methods

In a nine-hospital-based double-blind trial (NCT05755958, closed) with computer-generated randomisation and stratification by hospital, 32 French patients underwent HIFU treatment and 28 a sham treatment then evaluations, at months one (M1) and three (M3), of intensity (0-10 scale) of acute pelvic pain (APP) and other symptoms. In an open-label extension –OLE– phase, 24 (86%) sham-treated patients underwent HIFU treatment then same evaluations. All participants had MRI at M3 and a follow-up at Year 1 and/or Year 2 per available follow-up. Analysis followed the intention-to-treat approach, and missing data were not imputed.

Results

In both arms, the average level of APP and pain on defecation decreased significantly over M1 (**$p \leq 0{\cdot}002$)** but not much thereafter. At M3, constipation improved more importantly in the HIFU arm **($p \leq 0{\cdot}023$)**. The mean lesion volume decreased significantly only in the HIFU arm ($p < 0.001$) (29% vs 7% in the sham treatment arm). In OLE participants, APP, dyspareunia, and pain on defecation decreased **significantly** at M1 (**$p \leq 0{\cdot}01$)** then remained moderate. The average scores for diarrhoea and constipation decreased markedly at M1 then stabilized up to M3. The lesions shrank by 54·7%. The levels of APP, dysmenorrhoea, and dyspareunia showed remained significantly improved over two years in the initial HIFU arm; they decreased over Y1 in OLE participants.

Conclusions

HIFU could i) relieve APP, especially pain on defecation, ii) improve digestive and gynaecological symptoms, iii) shrink lesions, iv) shorten sick leaves, and, v) maintain the improvement of symptoms over one to two years. It should be considered as a serious alternative to risky surgery.

ESGE35-0261 -
Free Communication

Long-term follow-up of adolescents with endometriosis according to the #Enzian classification

Ilaria Mazzera[1], Elvira Nocita[2], Sara Valeriani[2], Daniele Farsetti[2], Alfredo Ercoli[3], Caterina Exacoustos[2]
[1]University of Udine, Obstetrics and Gynaecology- Department of Medical Area DAME, Udine, Italy
[2]University of Rome "Tor Vergata", Department of Surgical Sciences Gynaecological Unit, Rome, Italy
[3]University of Rome "Tor Vergata", Department of Biomedicine and Prevention, Rome, Italy

Background

This study aims to assess endometriosis in adolescents using the #Enzian classification to evaluate disease development and symptoms over a follow-up period up to 36 months.

Methods

In this retrospective study, between January 2020 and March 2026, 104 adolescents (aged 12–20 years) referred to our Gynecological Ultrasound Unit with a non-invasive ultrasound diagnosis of endometriosis were included. None had previous surgery or hormonal treatment at baseline evaluation. After initial ultrasound evaluation and #Enzian classification, all patients underwent to continuous hormone therapy inducing amenorrhea. Clinical and ultrasound examinations were performed every 6–8 months, classifying the disease at baseline and during follow up at 12, 24 and 36 months according to #Enzian classification for each compartment.

Results

The mean follow-up period was 23.7 ± 2.2 months. During continuous therapy, dysmenorrhea and heavy menstrual bleeding disappeared, while chronic pelvic pain and dyspareunia were significantly reduced already after 12 months of follow up. Ovarian endometriomas (O compartment) were detected in 19.2% of patients, adenomyosis (FA compartment) in 50.9%, posterior deep endometriosis in 2.9% (A compartment) and 6.7 % (C compartment), and uterosacral ligament thickening (B compartment) in 56.73 %. At 12 months, a reduction in O2 lesions and a relative increase in O1 was observed, reflecting a decrease in endometrioma size. After 36 months, 60.0% of endometriomas were no longer detectable. B compartment showed a volumetric reduction (B2 to B1) in 15.3% of cases, remaining stable at 24 and 36 months. Compartments FA, A, and C showed no changes, indicating disease stability under therapy.

Conclusions

We observed a reduction in B and O compartments and no changes in other compartments, confirming that continuous medical treatment reduced the progression of the disease. The #Enzian classification is a useful, standardized and objective method to evaluate the development of pelvic endometriosis in adolescents.

ESGE35-0653 -
Free Communication

Advanced office hysteroscopy using miniaturized 15fr instrumentation under local paracervical anesthesia: prospective patient-reported outcomes and predictors of procedural pain and tolerance in a single-centre study

Dominika Jasińska-Stasiaczek[1], *Mariusz Wójtowicz*[1]
[1]*Municipal Hospital in Zabrze, Woman and Child Health Center in Zabrze, Zabrze, Poland*

Background

Technological miniaturization has enabled the transition of hysteroscopy from operating theatre procedures under general anesthesia to advanced ambulatory interventions performed under local paracervical anesthesia. Ultra-miniaturized 15FR instrumentation now allows complex operative hysteroscopy to be safely performed in office settings. As patients remain fully conscious, procedural success depends not only on surgical technique, but also on patient-centered care, perceived safety and procedural tolerance. This study aimed to evaluate patient-reported outcomes and predictors of procedural pain during advanced office hysteroscopy performed under local paracervical anesthesia.

Methods

This prospective questionnaire-based study included consecutive patients undergoing office hysteroscopy between 1 April 2025 and 1 May 2026 at the Minihysteroscopy Department, Mother and Child Health Center in Zabrze. During the study period, 416 hysteroscopic procedures were performed; procedures requiring general anesthesia were excluded. All included procedures were performed under local paracervical infiltration anesthesia using 1% lidocaine and ultra-miniaturized 15FR instrumentation, including advanced procedures such as endometrial resection, myomectomy and adhesiolysis. A structured patient-centered care pathway focused on peri-procedural counselling, anxiety reduction, environmental comfort, relaxation and continuous support was systematically implemented, including individualized music selection and a calm procedural setting. Patients completed post-procedural questionnaires evaluating pain (VAS), overall procedural experience, comfort/safety, satisfaction and recommendation likelihood. Procedure type, endometriosis/adenomyosis/pelvic pain status, delivery history, age, dysmenorrhea severity, nitrous oxide use, hormonal therapy and comorbidities were analysed as predictors of procedural pain and tolerance using Mann–Whitney U, Kruskal–Wallis and Spearman rank correlation tests.

Results

A total of 373 patients fulfilled inclusion criteria and completed questionnaire analysis. Advanced operative office hysteroscopy, including endometrial resection, myomectomy and adhesiolysis, was successfully performed under local paracervical anesthesia with excellent patient-reported outcomes and high procedural tolerance. Overall satisfaction and recommendation scores demonstrated strong ceiling effects across the cohort.
Procedure type was not significantly associated with higher procedural pain or lower satisfaction outcomes. Endometriosis/adenomyosis/pelvic pain status was significantly associated with higher pain perception ($p<0.001$). Delivery history was significantly associated with pain scores ($p<0.001$),

with previous vaginal delivery associated with lower procedural pain. Younger age and higher dysmenorrhea severity were associated with significantly higher pain scores ($p=0.004$ and $p<0.001$, respectively). Dysmenorrhea intensity positively correlated with procedural pain ($rho=0.33$, $p<0.001$). Nitrous oxide use was not associated with significantly lower pain scores or improved satisfaction outcomes. Procedural pain negatively correlated with overall patient experience ($rho=-0.25$, $p<0.001$) and recommendation likelihood ($rho=-0.16$, $p=0.003$), although absolute satisfaction remained high.

Conclusions

Advanced office hysteroscopy using ultra-miniaturized 15FR instrumentation under local paracervical anesthesia enables complex operative procedures to be safely performed in ambulatory settings. Pain perception appears to be driven predominantly by patient-related factors rather than procedural complexity. Appropriate patient preparation, communication and peri-procedural support are essential for optimizing procedural tolerance, reducing pain perception and improving overall patient experience.

ESGE35-0947 -
Free Communication

Indocyanine green-guided ureteral mapping in complex deep endometriosis surgery: feasibility and surgical outcomes in high-risk cases

Julie Alaert[1], *Karampelas Stavros*[1]
[1]*Chu Brugmann, Gynecology, Brussels, Belgium*

Background

Deep endometriosis (DE) is a complex multifocal disease frequently involving pelvic organs, ureters, and retroperitoneal structures, making surgical management challenging and increasing perioperative risk. Indocyanine green (ICG) fluorescence imaging has been proposed to improve intraoperative ureteral visualization. This study aimed to evaluate the feasibility of ICG-guided ureteral mapping in complex DE surgery and assess surgical outcomes in high-risk patients.

Methods

We conducted a retrospective single-center cohort study including patients undergoing laparoscopic surgery for DE between January 2021 and October 2025 (n=191). Patients receiving ICG-guided ureteral mapping (n=22) were compared with a contemporaneous cohort without ICG (n=169). ICG was selectively injected under cystoscopic guidance to enable near-infrared visualization of ureteral trajectories. Outcomes included perioperative data and complications classified using Clavien–Dindo and ClassIntra v1.0 systems.

Results

Twenty-two patients underwent successful ICG-guided ureteral mapping, achieving intraoperative ureteral visualization in 100% of cases. Previous pelvic surgery was reported in 72.7% (16/22) of patients. According to the #Enzian classification, the cohort demonstrated advanced multifocal deep endometriosis, with severe pelvic adhesions or frozen pelvis (T3) in 50.0% (11/22) of cases, parametrial involvement (B3) in 36.4% (8/22), and colorectal involvement (C1–C3) in 54.5% (12/22). Extragenital disease was frequent, including bladder involvement (n=3), ureteral infiltration (n=3), and complex neuropelveolytic dissection involving hypogastric nerves or sacral roots (n=5). Rectovaginal nodules (A compartment) were present in 11 patients, although assessment was incomplete in some cases. Median operative time in the ICG group was 265 minutes, compared with 180 minutes in the overall deep endometriosis cohort. Median estimated blood loss was 25 mL, and median length of hospital stay was 2 days. Intraoperative adverse events occurred in 1/22 patients (4.5%) in the ICG group compared with 9/169 patients (5.3%) in the remaining deep endometriosis cohort. Overall, intraoperative adverse events were observed in 10/191 cases (5.2%). In the non-ICG group, 8 events were classified as ClassIntra grade II and one as grade III, consisting of a rectal perforation requiring intraoperative repair. The most frequent intraoperative events were intestinal injuries (n=3) and vascular injuries (n=2). In the ICG group, one grade III event occurred, consisting of a ureteral meatus breach despite fluorescence-guided ureteral mapping. Postoperative complication rates were 22.7% (5/22) in the ICG group compared with 10.7% (18/169) in the remaining deep

endometriosis cohort. According to Clavien–Dindo classification, in the ICG group, complications were grade I (n=1), II (n=2), IIIb (n=1), and IVb (n=1).

Conclusions

Indocyanine green-guided ureteral mapping is feasible and allows reliable intraoperative ureteral identification in complex deep endometriosis surgery. In this highly selected cohort with advanced multicompartment disease, the technique was associated with satisfactory perioperative outcomes. Further studies are required to clarify its role in reducing intraoperative and postoperative morbidity in high-risk patients.

ESGE35-0787 -
Free Communication

Radical laparoscopic excision of deep endometriosis in the presence of tubo-ovarian abscess: surgery in an infected field

Mehtap Akin Efe[1], *Mehmet Ceyhan*[2], *Emre Kar*[3], *Hale Goksever Celik*[4], *Ercan Bastu*[5]
[1]*Istanbul Training and Research Hospital, Obstetrics and Gynaecology, Istanbul, Türkiye*
[2]*Endometriosis and IVF Center-Nesta Clinic- Istanbul- Turkey, Obstetrics and Gynaecology, Istanbul, Türkiye*
[3]*Başakşehir Çam and Sakura City Hospital, Obstetrics and Gynaecology, Istanbul, Türkiye*
[4]*Acibadem University Medical Faculty, Obstetrics and Gynaecology, Istanbul, Türkiye*
[5]*Endometriosis and IVF Center- Nesta Clinic, Obstetrics and Gynaecology, Istanbul, Türkiye*

Background

To demonstrate the feasibility and surgical principles of performing radical laparoscopic excision of deep endometriosis in a contaminated operative field in the presence of a tubo-ovarian abscess.

Methods

This step-by-step narrated video presents the case of a 43-year-old woman with persistent pelvic pain despite previous drainage of a tubo-ovarian abscess. Preoperative imaging revealed a right adnexal abscess and suspected hydrosalpinx. Laparoscopic exploration demonstrated a frozen pelvis with dense adhesions involving the uterus, adnexa, and bowel. Bilateral retroperitoneal dissection and systematic ureterolysis were performed to identify and protect both ureters. During ovarian mobilization, the abscess cavity was opened, resulting in drainage of purulent material. Immediate suction and copious irrigation were performed to achieve source control. Extensive adhesiolysis was continued to restore pelvic anatomy. The rectum was carefully dissected and preserved. Deep infiltrating endometriosis involving the posterior compartment, including the uterosacral ligaments and rectovaginal space, was completely excised. Bilateral salpingectomy and partial ovarian resection were performed, and all specimens were removed laparoscopically.

Results

The procedure was completed entirely laparoscopically without conversion to laparotomy or intraoperative complications. Despite severe inflammation and distorted anatomy, normal pelvic planes were successfully restored. Postoperatively, inflammatory markers normalized and the patient experienced complete resolution of pelvic pain during follow-up under medical therapy.

Conclusions

Radical laparoscopic excision of deep endometriosis can be safely and effectively performed in an infected surgical field when meticulous dissection, systematic ureterolysis, and adequate source control are achieved. The presence of infection should not preclude definitive minimally invasive surgery in carefully selected patients managed by experienced surgeons.

https://player.vimeo.com/video/1195586641?autoplay=1

ESGE35-0763 -
Free Communication

Robotic segmental resection of a large mushroom lesion - Joint Gynaecology Colorectal Case

Danya Chandrakumar[1], Mohammed Deputy[2], Phakanant Chaichanavichkij[2], Richard Boulton[2], Yemi Coker[1]
[1]Barking- Havering and Redbridge University Hospitals NHS Trust, Gynaecology, London, United Kingdom
[2]Barking- Havering and Redbridge University Hospitals NHS Trust, Colorectal, London, United Kingdom

Background

Deep infiltrating endometriosis can present with variable and non-specific symptoms, requiring careful imaging, multidisciplinary planning, and individualized surgical management. This video demonstrates the multidisciplinary robotic management of rectovaginal endometriosis involving a large segment of the anterior rectal wall. Given the size and depth of bowel involvement, segmental rectal resection was undertaken. This video highlights the key operative steps.

Methods

A 51-year-old woman presented with a two-year history of deep pelvic pain and cyclical rectal bleeding. She had a partial symptomatic response to gonadotropin-releasing hormone agonists, with improvement in monthly pain and rectal bleeding, but persistent daily pelvic discomfort continued to affect her quality of life. MRI demonstrated an ill-defined spiculated lesion in the pouch of Douglas, densely adherent to the lower uterine segment/cervix and upper rectum, with associated eccentric anterior rectal mural thickening extending over 4 cm and a maximum thickness of 15 mm. Following multidisciplinary team discussion, she was planned for joint robotic gynaecology and colorectal surgery.

Results

The procedure comprised of a robotic hysterectomy, bilateral salpingo-oophorectomy, excision of the rectovaginal endometriotic nodule, segmental resection, and colorectal anastomosis. Key steps from the colorectal perspective included nerve-sparing pararectal dissection, mobilisation into the rectovaginal septum, excision of a cuff of posterior vagina with the endometriotic nodule, division of the rectum below the nodule using Sureform 60mm and division of the upper rectum proximal to the nodule with scissors. The specimen was delivered via the vaginal opening, and a purse string suture with 3.0 PDS used to secure CDH29 anvil, with a resultant tension-free end-to-end anastomosis between upper and lower rectum. Anastomotic integrity was confirmed with a negative air leak test and endoluminal inspection, followed by staple-line reinforcement.

Conclusions

This case illustrates how MDT-planned, anatomy-guided robotic surgery can facilitate safe and complete excision of complex bowel endometriosis, with careful attention to functional preservation.

https://player.vimeo.com/video/1195452419?autoplay=1

ESGE35-0974 -
Free Communication

Silent renal loss secondary ureteral endometriosis: a case report

Nazlı Bozkurt[1], *Ali Akdemir*[2]
[1]*Ege University Faculty of Medicine, Department of Obstetrics and Gynaecology, Izmir, Türkiye*
[2]*Ege University Faculty of Medicine, Gynecology and Obstetrics, Izmir, Türkiye*

Background

Ureteral endometriosis is a rare but potentially severe manifestation of deep infiltrating endometriosis. Because it may remain asymptomatic for a prolonged period, delayed diagnosis can result in irreversible renal function loss. We present a case of silent renal loss secondary to ureteral endometriosis managed laparoscopically.

Methods

A 39-year-old woman with known endometriosis presented with severe dysmenorrhea, dyspareunia, and chronic pelvic pain. Preoperative evaluation demonstrated severe left hydroureteronephrosis with complete loss of left renal function. Laparoscopic surgery was performed, including bilateral ureterolysis, excision of deep infiltrating endometriosis, restoration of the pararectal and prerectal spaces, resection of endometriotic nodules, and salpingectomy for hydrosalpinx.

Results

Intraoperatively, extensive deep infiltrating endometriosis involving both pelvic sidewalls and severe left ureteral obstruction were identified. The left ureter was completely encased by endometriotic tissue, explaining the loss of renal function. Complete excision of visible endometriotic lesions and bilateral ureterolysis were achieved. At six months of follow-up, the patient reported complete symptomatic relief with resolution of pelvic pain.

Conclusions

Ureteral endometriosis may remain clinically silent despite advanced urinary tract involvement and irreversible renal damage. Early recognition and timely surgical management are essential to preserve renal function and prevent disease progression.

https://player.vimeo.com/video/1198909142?autoplay=1

ESGE35-0089 -
Free Communication

A biodegradable intrauterine hydrogel spacer for prevention of recurrent intrauterine adhesions following hysteroscopic adhesiolysis: results from a multicentre randomized controlled trial

Christina Salazar[1], Scott Chudnoff[2], Kelly Roy[3], Heather Huddleston[4], Bhala Bhagavath[5], Malcolm Munro[6]
[1]The University of Texas at Austin- Dell Medical School, Minimally Invasive Gynaecologic Surgery, Austin, USA
[2]Maimonides Medical Center, Obstetrics and Gynaecology, Brooklyn, USA
[3]Arizona Gynecology Consultants, Gynaecology, Phoenix, USA
[4]The University of California- San Francisco, Department of Reproductive Sciences, San Francisco, USA
[5]The University of Wisconsin, Obstetrics and Gynaecology, Madison, USA
[6]The University of California at Los Angeles- David Geffen School of Medicine, Obstetrics and Gynaecology, Los Angeles, USA

Background

Endometrial trauma resulting from intrauterine surgical procedures is a well-recognized contributor to the development of intrauterine adhesions (IUAs). Adjuvant mechanical barriers are intended to support endometrial repair and reduce adhesion formation. The objective of this study was to evaluate the effectiveness of a biodegradable in situ-forming intrauterine hydrogel spacer with a prolonged residence time for reducing recurrent IUAs following hysteroscopic adhesiolysis.

Methods

Randomized, multicentre, subject- and evaluator-blinded trial conducted across fifteen academic and community-based gynaecologic surgery centres in the United States. Of 238 potential participants between August 2022 and January 2025, 67 women in the adhesiolysis subgroup with moderate-to-severe IUAs by March classification were randomized 2:1 after completion of adhesiolysis to receive Juveena™ hydrogel spacer, and 35 to the control arm which received no intrauterine barrier. Prespecified subgroup analysis were performed.

Results

The primary endpoint was absence of IUAs at second-look hysteroscopy (SLH). Analyses were performed in the modified intention-to-treat population and supported in the full analysis set and per-protocol populations. In the modified intention-to-treat cohort of adhesiolysis participants, the absence of IUAs at SLH was higher with Juveena than with control (60.3% [38/63] vs 32.3% [10/31]; p=0.015; OR 3.19, 95% CI 1.29–7.90). Severe IUAs at SLH were less frequent in the Juveena arm (6.3% vs 32.3%; p=0.002; OR 0.14, 95% CI 0.04–0.50). In a post-hoc responder analysis, the rate of at least 2-category improvement in adhesion severity was higher with Juveena (66.7% vs 32.3%; p=0.002; OR 4.20, 95% CI 1.68–10.51). Findings were consistent across supportive analysis populations.

Conclusions

Among patients undergoing hysteroscopic adhesiolysis, use of a biodegradable in situ-forming intrauterine hydrogel spacer with a 2–3-week residence time was associated with higher rates of adhesion-free status at second-look hysteroscopy and lower rates of severe residual adhesions. These findings support a clinically meaningful benefit in a high-risk population.

ESGE35-0114 -
Free Communication

Transrectal ultrasound (TRUS)-guided vaginoscopic treatment of obstructive longitudinal vaginal septum in OHVIRA syndrome

Artur Ludwin[1], Lucja Zaborowska[1], Inga Ludwin[2]
[1]Medical University of Warsaw, 1st Department of Obstetrics and Gynaecology, Warsaw, Poland
[2]Ludwin&Ludwin Gynecology, Ludwin&Ludwin Gynaecology, Kraków, Poland

Background

OHVIRA syndrome is a rare congenital anomaly of the female reproductive tract characterized by the coexistence of an obstructed hemivagina and ipsilateral renal agenesis. Affected patients commonly present with severe dysmenorrhea and chronic pelvic pain and are frequently subjected to delayed diagnosis, misdiagnosis, and inadequate treatment. The aim of this study was to describe the surgical technique, clinical outcomes, and potential complications of transrectal ultrasound-guided vaginoscopic treatment of various types of obstructive longitudinal vaginal septa in patients with OHVIRA syndrome.

Methods

This retrospective multicentre study included patients who underwent surgical treatment between 2014 and 2025 at two referral centres specializing in congenital uterine anomalies. The study included 34 patients with OHVIRA who underwent vaginoscopic treatment for oblique longitudinal vaginal septum and associated features such as (i) hemihydrocolpos, (ii) hemihematocolpos, (iii) "old blood" deposits in blind hemivagina. Five of included patients had intact hymen. Seven patients had to be reoperated due to suboptimal septum incision or resection performed in other medical centres. The diagnosis of OHVIRA syndrome was established using saline infusion contrast sonovaginocervicography (3D-SVC) with virtual speculoscopy, three-dimensional transvaginal/transrectal ultrasound, two-dimensional transabdominal ultrasound, and/or magnetic resonance imaging. All patients underwent single-stage vaginoscopic septoplasty performed under transrectal ultrasound guidance. A septum incision was performed with a resectoscope and Collin's needle; the second cervix, or the second part of the septate cervix, was subsequently visualized. The obtained opening was widened using a loop electrode. Five patients underwent simultaneous uterine septum resection.

Results

All 34 patients reported an improvement in reported symptoms associated with obstruction of the reproductive tract (dysmenorrhea, chronic pelvic pain, "old blood" deposits). We reported one (1/34, 2.94%) early complication associated with post-operative haemorrhage and subsequent anaemia (haemoglobin of 9.0 mg/dL).

Conclusions

Vaginoscopic resection of oblique longitudinal vaginal septum is a safe and effective treatment for pain and obstruction associated with OHVIRA syndrome. A minimally invasive vaginoscopic approach

allows for virginity-sparing management with optimal anatomical results. The described procedure can be combined with simultaneous uterine septum resection.

ESGE35-0913 -
Free Communication

An alternative facilitating technique in the hysteroscopic management of Robert's uterus: use of a transvaginal ultrasound-guided oocyte retrieval needle

Zeynep Gurbuz[1], *Defne Ceylin Gurbuz*[2], *Ali Sami Gurbuz*[3]
[1]*Koç University School of Medicine, Obstetrics and Gynaecology, Istanbul, Türkiye*
[2]*Istinye University, Obstetrics and Gynecology, Istanbul, Türkiye*
[3]*Novafertil IVF Center, Obstetrics and Gynecology, Konya, Türkiye*

Background

Robert's uterus is one of the rarest Müllerian duct anomalies and is characterized by an asymmetric intrauterine septum despite a normal external uterine contour. One hemicavity resembles a unicornuate uterus, while the contralateral side is completely obstructed and commonly associated with hematometra. Delayed diagnosis may lead to severe dysmenorrhea, pelvic pain, retrograde menstruation, and advanced endometriosis. Hysteroscopic treatment may be technically challenging due to distorted anatomy and partial rotation of the uterine cavity.

Methods

A 30-year-old nulliparous patient with severe dysmenorrhea and chronic pelvic pain was evaluated. She had previously undergone four laparoscopic surgeries for endometriosis. 2D–3D ultrasonography and pelvic MRI demonstrated Robert's uterus with an obstructed left hemicavity filled with particulate fluid. Following cervical dilation, a 16-gauge OPU needle was advanced through the septum into the obstructed cavity under transvaginal ultrasound (TVUS) guidance. After fluid aspiration, the needle was left in place to guide the hysteroscopic procedure. A 15-Fr mini resectoscope was introduced, and septal incision toward the fundus was performed under OPU needle guidance. Due to cavity contraction secondary to hematometra, a second-stage hysteroscopic procedure was planned.

Results

At one-month follow-up, patient reported complete resolution of dysmenorrhea. HSG demonstrated a broad cavity with residual septal remnants. During the second hysteroscopic procedure, the remaining septal tissue extending from the fundus to the cervix was completely resected, resulting in a unified uterine cavity. Hyaluronic acid gel and estradiol therapy were administered to reduce adhesion formation risk.

Conclusions

Early diagnosis and appropriate management of Robert's uterus are essential to prevent complications associated with retrograde menstruation and endometriosis. TVUS-guided OPU needle assistance facilitates hysteroscopic orientation within a potentially rotated uterine cavity and may contribute to safer and more effective septal incision.

https://player.vimeo.com/video/1195756752?autoplay=1

ESGE35-0576 -
Free Communication

Managing hemorrhagic complications after a minor cervical polypectomy

Luca Iazzetta[1], Paolo Casadio[1], Giulia Di Liello[1], Sara Tolentino[1], Francesco Cecchieri[1], Alessandro Arena[1]
[1]Division of Gynaecology and Human Reproduction Physiopatology- IRCCS Azienda Ospedaliero-Universitaria di Bologna- Italy,
Department of Medical and Surgical Sciences- DIMEC- University of Bologna- Bologna- Italy, Bologna, Italy

Background

Cervical polyps are common pedunculated growths arising from the endocervical canal or ectocervix. While cervical polypectomy is a routine gynecological procedure, traditional "cold" torsion precludes direct control of the vascular pedicle. This video-article shares our institutional experience regarding a rare but severe post-procedural hemorrhage, highlighting the essential role of operative hysteroscopy in managing and preventing such complications.

Methods

We present the case of a woman admitted to the Emergency Room with profuse vaginal bleeding three hours after an outpatient blind torsion polypectomy. Initial conservative management (comprehensive of tranexamic acid local and systemic administration) proved ineffective; the resulting hemodynamic instability and severe anaemia necessitated blood transfusions. Urgent operative hysteroscopy was performed to resolve the hemorrhage.

Results

A continuous-flow hysteroscopy emerged as the definitive solution, successfully managing a life-threatening hemorrhage that had proven refractory to all prior conservative interventions. Utilizing a 26 Fr resectoscope with a 5mm unipolar rollerball electrode, through systematic craniocaudal manoeuvres we managed to effectively coagulate the bleeding pedicle of the polyp.

Conclusions

In conclusion, hysteroscopy proved to be an effective tool for managing severe, although rare, complications. Moreover, given the availability of miniaturized electrosurgical instruments suitable for an outpatient setting, elective hysteroscopy should be considered a primary approach for the treatment of cervical polyps, potentially reducing the risk of hemorrhagic events from the outset

https://player.vimeo.com/video/1191696691?autoplay=1

ESGE35-0754 -
Free Communication

Hysteroscopic management of cystic adenomyoma mimicking submucosal myoma

Vehbi Yavuz Tokgoz Assistant Professor[1], *Mehmet Çopuroğlu*[2]
[1]*Eskisehir Osmangazi University,*
Obstetrics and Gynaecology- Reproductive Endocrinology and Infertility Unit, Eskişehir, Türkiye
[2]*Kayseri City Hospital, Obstetrics and Gynaecology, Kayseri, Türkiye*

Background

Cystic adenomyoma is a rare form of adenomyosis that may mimic a submucosal myoma both radiologically and hysteroscopically. Intraoperative identification may be challenging, particularly when unusual cavity formation and mucosal-like structures are encountered during hysteroscopic resection. We present the hysteroscopic management of a cystic adenomyoma associated with unexpected intraoperative findings

Methods

We reported a case of a 46-year-old woman presented with abnormal uterine bleeding persisting for one month. A levonorgestrel-releasing intrauterine device had been inserted at another center two years ago. It had been removed one week earlier because of worsening bleeding symptoms. We performed transvaginal ultrasonography and demonstrated a 25-mm intracavitary lesion with cystic, hyperechogenic, and solid components suggestive of a degenerating submucosal myoma. Operative hysteroscopy was performed using standard resectoscopic loop excision techniques. During resection, brown-coloured fluid drainage and a large cavitary defect with mucosal-like surfaces were unexpectedly encountered, raising suspicion of entry into an adjacent organ. Careful hysteroscopic evaluation, identification of the tubal ostium, and methylene blue testing were performed to exclude urinary tract injury.

Results

Further resection demonstrated findings consistent with cystic adenomyoma. The adenomyotic cystic cavity and surrounding myometrial tissue were successfully excised hysteroscopically. No bladder injury or uterine perforation was identified intraoperatively. Histopathological examination confirmed adenomyotic endometrial and myometrial tissue. The patient experienced significant postoperative symptom relief.

Conclusions

Cystic adenomyoma may rarely mimic submucosal myoma during hysteroscopic surgery and may create unexpected intraoperative findings suggestive of adjacent organ injury. Awareness of this rare presentation and systematic intraoperative evaluation are essential to avoid misdiagnosis and unnecessary surgical intervention.

https://player.vimeo.com/video/1195420277?autoplay=1

ESGE35-0758 -
Free Communication

Hysteroscopic resection of caesarean scar pregnancy

Amal Mouzali[1], *Ayache Kaouther*[1]
[1]*Thenia hospital, Medecine, Boumerdes, Algeria*

Background

Caesarean scar pregnancy (CSP) is an increasingly recognized pathology, occurring in parallel with the rising global caesarean section rate. Accurate characterization of implantation is essential, particularly to distinguish whether the pregnancy is *in the scar* or *on the scar*.

Assessment of the residual myometrial thickness is crucial. When the residual myometrium measures less than 2–3 mm, the pregnancy is classified as **"in the scar"**; otherwise, it is considered **"on the scar."** This distinction is highly important, as pregnancies implanted *in the scar* carry a significantly higher risk of severe complications, including early uterine rupture and hysterectomy, with reported hysterectomy rates exceeding 50%.

Methods

Over an 18-month period at **Thenia Hospital**, we collected **11 cases of caesarean scar pregnancy**, of which **8 were managed hysteroscopically**. Gestational age at diagnosis ranged between **6 and 8 weeks**.

We present two representative cases. The first involved a **34-year-old woman** with a history of **two previous caesarean sections**, diagnosed with CSP at **7 weeks of gestation**. Using an **18.5 Fr bipolar resectoscope**, hysteroscopic treatment was performed through **cold resection**, combined with **bipolar coagulation** and limited additional resection to achieve complete removal and hemostasis.

The second case concerned a 38-year-old woman with a history of two previous caesarean sections. Caesarean scar pregnancy (CSP) was diagnosed at 8 weeks of gestation, and hysteroscopic management was undertaken. Histopathological analysis of the evacuated tissue revealed a partial molar pregnancy.

Results

The postoperative outcome was favorable, with successful preservation of the uterus and no major complications.

Several therapeutic options have been proposed for the management of caesarean scar pregnancy, including medical and surgical approaches. Among them, **hysteroscopy appears to be a safe, minimally invasive, and fertility-preserving option**, particularly in selected early cases. However, larger prospective studies are needed to further evaluate its efficacy and long-term outcomes.

Conclusions

Hysteroscopy may represent an effective first-line approach in the management of early caesarean scar pregnancy.

https://player.vimeo.com/video/1195428428?autoplay=1

ESGE35-0885 -
Free Communication

Reconstructive hysteroscopic surgery in an infertile patient with dysmorphic uterus and G3 uterine fibroids.

Virginia Todisco[1], Emma Bonetti Palermo[2], Mariangela Ravo[3], Nicosia Anthony[4], Federica Pozzati[5], Ursula Catena[5]
[1]University of Turin, Department of Obstetrics and Gynaecology, Turin, Italy
[2]ASST Spedali Civili of Brescia, Unit of Obstetrics and Gynaecology, Brescia, Italy
[3]University of Campania Luigi Vanvitelli,
Department of Woman- Child and General and Specialized Surgery- Obstetrics and Gynaecology Unit, Naples, Italy
[4]University Hospital Maggiore della Carità, Department of Gynaecology and Obstetrics, Novara, Italy
[5]Fondazione Policlinico Universitario A. Gemelli- IRCSS,
Department of Women- Children and Public Health, Rome, Italy

Background

Dysmorphic uterus is characterized by a reduced-volume uterine cavity with tubular morphology and thickened lateral walls, a condition potentially associated with impaired embryo implantation. The concomitant presence of intramural fibroids may further contribute to uterine cavity distortion and infertility. Operative hysteroscopy represents an effective minimally invasive approach for restoring normal uterine cavity anatomy. We present the case of an infertile patient undergoing reconstructive hysteroscopic surgery, consisting in ampliative metroplasty with simultaneous myomectomy.

Methods

A 39-year-old nulliparous woman with a history of recurrent implantation failure underwent transvaginal 3D ultrasound and diagnostic hysteroscopy, revealing a reduced-volume tubular uterine cavity consistent with a dysmorphic uterus associated with two lateral G3 fibroids measuring approximately 10 mm in the right and left uterine walls respectively. After dedicated counselling and desogestrel administration for endometrial preparation, the patient underwent operative hysteroscopy under general anesthesia with laryngeal mask airway, according to an outpatient model of care. Using a 15 Fr mini-resectoscope with a Collins loop, bilateral lateral wall incisions were performed. During the procedure, both fibroids were identified, dissected from the surrounding myometrium and progressively fragmented until complete removal. Redundant lateral endomyometrial tissue was subsequently resected using a 90° angled loop.

Results

The procedure was completed without intraoperative complications. Postoperative ultrasound examination showed a uterine cavity with regular morphology and restored volume.

Conclusions

This case highlights the importance of hysteroscopic restoration of the uterine cavity in infertile patients with dysmorphic uterus associated with intramural myomas. The combined approach of

hysteroscopic ampliative metroplasty and myomectomy represents an effective minimally invasive technique for restoring normal uterine anatomy and may contribute to improved reproductive potential in selected infertile patients.

https://player.vimeo.com/video/1195733127?autoplay=1

ESGE35-0803 -
Free Communication

Surgical management of colorectal endometriosis through multidisciplinary collaboration. - with a focus on preoperative diagnosis, advanced surgical techniques, and perioperative management -

Mari Kitade[1], Shiori Takeuchi[2], Keisuke Murakami[2], Yu Kawasaki[2], Yasuho Yanagihara[2], Yasuhisa Terao[2]
[1]Juntendo University Faculty of Medicine, Obstetrics and Gynaecology, Tokyo, Japan
[2]Juntendo University- Faculty of Medicine, Obstetrics and Gynaecology, Tokyo, Japan

Background

Colorectal endometriosis (CRE) is a hormone-dependent disease that most commonly affects the rectum, sigmoid colon, and ileo-caecal region. Thickening of the intestinal wall and luminal stenosis give rise to symptoms including defecation difficulty, painful bowel movements, and haematochezia. Although both hormonal therapy and surgery are available, hormonal therapy is contraindicated in patients desiring pregnancy. It is often ineffective for upper gastrointestinal tract lesions, making surgery the first-line treatment. We present the preoperative diagnostic strategy and surgical procedures for CRE undertaken through collaboration between the departments of gastrointestinal surgery and gynaecology, and discuss the criteria for treatment selection.

Methods

We retrospectively reviewed 21 patients with CRE who underwent intestinal resection at our institution between 2002 and 2022. The median age was 38 years (range, 28–48). Chief complaints comprised diverse gastrointestinal symptoms, including intestinal obstruction, painful defecation, and haematochezia. Surgery was performed collaboratively: a gynaecologist first managed concomitant gynecological disease and dissected severe perirectal adhesions, after which a gastrointestinal surgeon resected the lesion.

Results

A definitive preoperative diagnosis was achieved by colonoscopy in only one case (4.8%), whereas the MRI jelly method visualized CRE in all cases. Preoperative hormonal therapy was administered in 19 cases (90.5%). Lesions were located in the sigmoid colon (2), rectum (15), ileum (5), and overlapping ileum and rectum (1). Obliteration of the pouch of Douglas was observed in all lower-tract lesions. As a rule, low anterior resection was performed for lower-tract lesions and ileocecal resection for ileocecal lesions; 19 cases (90.5%) were completed laparoscopically, and two by open surgery. A temporary ileostomy was created in four cases at high risk of anastomotic leakage. Postoperatively, symptoms improved in all patients, and CA125 levels decreased significantly. Histopathologically, the deepest endometriotic invasion reached the submucosa in 15 cases (68.2%) and the muscularis propria in seven (31.8%), consistent with invasion from the serosal side. Early complications comprised one case each of anastomotic leakage and ileus, both resolving conservatively; late complications comprised one case each of anastomotic stricture, intestinal stricture, and rectovaginal fistula. Although postoperative symptoms resolved in all cases, prophylactic medical therapy was administered in 13 (61.9%). Postoperative recurrence occurred in only one case (4.8%), and

pregnancy was achieved in two (50.0%) of four patients desiring conception (follow-up period: 2,088 days).

Conclusions

Multidisciplinary collaboration from the preoperative stage enables appropriate diagnosis and treatment selection for CRE and permits highly complex surgery through a clear division of roles. This approach contributes to both recurrence prevention and functional preservation.

ESGE35-0147 -
Free Communication

Surgical mapping with indocyanine green (icg) in the management of large isthmocele and total dehiscence: a laparoscopic approach

Merve Menteşe[1], Emin Erhan Dönmez[2], Yağmur Solak[2]
[1]Istanbul Training and Research Hospital, Obstetrics and Gynaecology, İstanbul, Türkiye
[2]Istanbul Training and Research Hospital, Obstetrics and Gynaecology, Istanbul, Türkiye

Background

Caesarean scar defect (isthmocele) is an increasingly recognized complication associated with rising caesarean delivery rates worldwide. Inadequate healing of the myometrium at the site of the caesarean incision may result in abnormal uterine bleeding, dysmenorrhea, chronic pelvic pain, infertility, and severe obstetric complications such as uterine rupture and caesarean scar pregnancy. Surgical treatment of large isthmoceles associated with total dehiscence remains technically challenging because accurate delineation of the defect borders and preservation of healthy tissue are essential for safe reconstruction. We present a rare case of a large isthmocele with total dehiscence successfully managed using laparoscopic repair combined with Indocyanine Green (ICG)-guided surgical mapping.

Methods

A G3P3L4 patient with a history of three previous caesarean sections presented with persistent abnormal vaginal bleeding for approximately two months. The patient had no known chronic disease, medication use, smoking history, or alcohol consumption. Gynecological examination was unremarkable, and no active bleeding was observed during speculum examination. Laboratory investigations, including complete blood count, biochemical profile, coagulation parameters, infectious disease screening, tumor markers, and serum beta-hCG levels, were within normal limits.

Transvaginal ultrasonography demonstrated a retroverted uterus with a 12 mm fluid collection within the endometrial cavity. A 53×57 mm anterior uterine wall defect communicating with the uterine cavity was identified, suspicious for a large isthmocele associated with hematoma formation, fistulization, or total dehiscence. Bilateral ovaries were normal, and no free fluid was observed in the pouch of Douglas. Due to the patient's persistent symptoms and the size of the defect, laparoscopic surgical repair was planned.

Following laparoscopic pelvic exploration, a hysterometry device was inserted intraoperatively to identify and preserve the healthy endometrial cavity during dissection and suturing. A 14 F catheter was then introduced into the isthmocele pouch to delineate the borders of the caesarean scar defect. To improve visualization of the anatomical planes, Indocyanine Green (ICG) was administered directly into the defect area. Under fluorescence-guided imaging, the borders of the isthmocele and the total dehiscence area were clearly identified. Fibrotic and thinned tissues surrounding the defect were laparoscopically excised while preserving healthy myometrium. Subsequently, the dehiscent uterine wall was repaired with full-thickness laparoscopic suturing, restoring the anatomical integrity of the uterus.

Results

ICG-guided fluorescence imaging enabled precise identification of the isthmocele borders and dehiscent area, facilitating safe excision and preservation of healthy surrounding tissue. The combined use of hysterometry and catheter-guided mapping improved intraoperative orientation and supported accurate laparoscopic reconstruction. Complete anatomical repair of the uterine wall was successfully achieved without intraoperative complications.

Conclusions

ICG-guided laparoscopic repair may provide effective surgical mapping and safer anatomical restoration in patients with large isthmoceles associated with total dehiscence. The combined use of fluorescence imaging and hysterometric guidance appears to facilitate precise defect visualization and successful minimally invasive reconstruction.

https://player.vimeo.com/video/1190985475?autoplay=1

ESGE35-0689 -
Free Communication

Deep infiltrating endometriosis- a multidisciplinary laparoscopic approach

Nilsu Guvencer[1], Ercan Bastu[2], Mehmet Ceyhan[2], Bugra Yilmaz[3], Emre Kar[4]
[1]Acıbadem University- Acibadem Fulya Hospital, Obstetrics and Gynecology, Istanbul, Türkiye
[2]Nesta Clinic, Obstetrics and Gynecology, Istanbul, Türkiye
[3]Istanbul Research and Training Hospital, Obstetrics and Gynecology, Istanbul, Türkiye
[4]Basaksehir Cam Sakura City Hospital, Obstetrics and Gynecology, Istanbul, Türkiye

Background

Deep infiltrative endometriosis involving the bowel presents a major surgical challenge, causing debilitating pelvic pain, severe dysmenorrhea, and recurrent fertilization failure. This video aims to demonstrate a systematic laparoscopic approach to eliminate severe endometriosis symptoms and optimize reproductive outcomes through a planned full-thickness discoid resection and comprehensive fertility optimization strategies.

Methods

A 34-year-old female presented with severe dyspareunia, dysmenorrhea, and a history of 6 failed ivf cycles secondary to extensive endometriosis. Pelvic magnetic resonance imaging confirmed a 4 cm rectosigmoid infiltration, bilateral uterosacral ligament involvement, and kissing ovaries. Laparoscopy revealed total obliteration of the pouch of douglas due to a dense bowel mass adherent to the posterior uterine wall. The procedure commenced with bilateral retroperitoneal dissection and detailed ureterolysis to secure the surgical field and protect pelvic nerves. A left salpingectomy was performed for a toxic hydrosalpinx to optimize future embryo transfer conditions, followed by careful ovarian adhesiolysis to restore anatomy while protecting the ovarian reserve. Following the excision of pelvic nodules, a multidisciplinary discoid excision of the rectosigmoid lesion was executed using a circular stapler.

Results

The full-thickness discoid resection of the rectosigmoid lesion was successfully executed, and the staple line was reinforced using barbed sutures to ensure a secure, watertight primary closure. Intraoperative bowel integrity was rigorously validated using negative air-leak tests. Total operative time was 180 minutes with minimal blood loss, and the patient was discharged on postoperative day 2 without complications. At the 3-month follow-up, she reported a near-complete resolution of symptoms and was successfully scheduled for a new ivf cycle with a fully restored pelvic anatomy.

Conclusions

Laparoscopic discoid resection combined with immediate pelvic and adnexal restoration is an effective fertility-sparing option for advanced rectosigmoid deep infiltrative endometriosis. This targeted multidisciplinary approach successfully eliminates severe endometriosis pain, significantly improves quality of life, and safely prepares the pelvic environment for future fertilization and successful pregnancy outcomes.

https://player.vimeo.com/video/1195139887?autoplay=1

ESGE35-0703 -
Free Communication

Aggressive angiomyxoma of the pelvis and vulvovaginal region: combined laparoperineal excision

Nasuh Utku Doğan[1], Bilge Uslu Aybar[2], Omer Faruk Oz[3], Selen Dogan[4]
[1]Dogan Gynecology Clinic, Gynaecologic Oncology, Antalya, Türkiye
[2]Memorial Hospital, Gynaecology, Antalya, Türkiye
[3]Akdeniz University, Gynaecology, Antalya, Türkiye
[4]Akdeniz University, Gynaecologic Oncology, Antalya, Türkiye

Background

To present the surgical management and outcomes of a giant aggressive angiomyxoma involving the pelvis, vagina, and vulva using a combined laparoperineal minimally invasive approach.

Methods

A 29-year-old nulliparous woman was admitted with pelvic pain. Transvaginal ultrasonography demonstrated an 11 cm semisolid pelvic mass located in the paravesical space and extending toward the vagina. Pelvic magnetic resonance imaging (MRI) revealed a 12 cm mass closely associated with the bladder and vagina, extending into the vulvar region, with a preoperative diagnosis of aggressive angiomyxoma. Due to the extensive pelvic and vulvovaginal involvement, a combined laparoperineal surgical approach was planned.

Results

The operation was completed successfully with a total operative time of 185 minutes and estimated blood loss of 40 cc. The postoperative course was uneventful, and the patient was discharged on postoperative day 4. Histopathological examination confirmed the diagnosis of aggressive pelvic angiomyxoma.

Conclusions

Aggressive angiomyxoma can be accurately characterized preoperatively with pelvic MRI, allowing optimal surgical planning. In cases with vulvar extension, a combined laparoperineal approach facilitates complete tumor excision while maintaining the advantages of minimally invasive surgery. Careful multidisciplinary evaluation and meticulous surgical dissection are crucial to achieve favourable outcomes in these rare and locally infiltrative tumors.

https://player.vimeo.com/video/1195206751?autoplay=1

ESGE35-0064 -
Free Communication

Recurrent uterine niche after a laparoscopic uterine reconstruction: the first clinical evidence.

Natalia Mazur-Ejankowska[1], Anna Abacjew-Chmyłko[1], Dariusz Wydra[1], Magdalena Grzybowska[1]
[1]Medical University of Gdańsk,
Department of Gynecology- Obstetrics and Neonatology- Division of Gynecology and Obstetrics, Gdańsk, Poland

Background

Caesarean section complications, including defective post caesarean section uterine scars, known as uterine niches, are gaining clinical and scientific importance. Numerous studies investigate the incidence and risk factors of uterine niche formation, confirming high rates of uterine niches after first caesarean section from 24% to 70%, depending on the imaging technique used. Many authors confirm that the incidence of uterine niche after multiple caesarean sections is higher than after the first caesarean section.

Uterine niche laparoscopic reconstruction is a well-established procedure for symptomatic patients with large uterine niches who are planning next pregnancies. Repairing the defective uterine myometrium enables appropriate re-suturing of the uterine wound edges which should lead to correct uterine healing, and resolution of uterine niche symptoms. Uterine niche resection enables future conception, as large caesarean scar defects decrease fertility and are a risk factor of caesarean scar pregnancy.

Recurrent uterine niche refers to a caesarean scar defect in a patient who previously underwent surgical repair of a uterine niche, by a laparoscopic reconstruction, subsequently conceived, and delivered again by caesarean section, with a new niche identified at postpartum follow-up. Recurrent uterine niche has not been investigated to date, and this is the first study presenting evidence of niche recurrence in another pregnancy after a laparoscopic uterine niche reconstruction.

Methods

The study investigated a series of recurrent uterine niches. 127 women with a uterine niche after caesarean section were qualified for a laparoscopic uterine niche resection and uterine reconstruction. Following the uterine niche resection, 46 women were pregnant and 43 women delivered by caesarean section. At the follow up after the last caesarean section, 5 out of 43 patients were diagnosed with a new uterine niche. The age, BMI, concomitant diseases, surgery protocols, laboratory and ultrasonographic results of those patients were compared.

Results

Statistical analysis was not possible due to a small sample size of the group. Upon a qualitative analysis, the patients had a normal BMI and no concomitant chronic or genetic conditions. Transvaginal ultrasonography examination confirmed a new niche at the site of second caesarean section uterotomy incision. The patients were observed and secondary uterine niche surgical treatment was offered.

Conclusions

The study discusses the first evidence of recurrent uterine niche after a prior uterine niche laparoscopic reconstruction and another caesarean section. The retrospective character of the study and a relatively small sample size are limitations of the study. In light of no biochemical markers or known genetic predispositions of the uterine niche, large prospective ultrasonography and histopathological studies should be conducted to establish if recurrence of uterine niches is correlated with genetic or biochemical factors. Patients after laparoscopic uterine niche reconstruction require a careful ultrasonography examination after each caesarean section to rule out recurrent uterine niche.

ESGE35-0501 -
Free Communication

How big is too big? a size-dependent spectrum in surgical decision-making for ovarian cyst surgery

Nissim Arbib[1], Chen Manor Bar[2], Shanny Kolp-Asis[3], Roni Sinay Sadaka[2], Yair Daykan[2], Zvi Klein[2]
[1]Gray Faculty of Medical and Health Sciences- Tel Aviv University- Tel Aviv- Israel., Department of Obstetrics and Gynaecology- Meir Medical Center- Kfar Saba- Israel, Ramat Pinkas, Israel
[2]Gray Faculty of Medical and Health Sciences- Tel Aviv University- Tel Aviv- Israel., Department of Obstetrics and Gynaecology- Meir Medical Center- Kfar Saba- Israel, Kfar Saba, Israel
[3]Gray Faculty of Medical and Health Sciences- Tel Aviv University- Tel Aviv- Israel., Department of Obstetrics and Gynaecology- Mayanei Hayeshua Medical Center- Bnei Brak- Israel, Bnei Brak, Israel

Background

The feasibility of laparoscopic surgery for ovarian cysts is strongly influenced by cyst size, yet the true threshold beyond which laparoscopy becomes unlikely remains uncertain.

Study Objective was to evaluate the relationship between ovarian cyst size and surgical approach selection, and how it influences surgical decision-making.

Methods

Design: Retrospective cohort study.

Setting: Tertiary referral center with standardized minimally invasive gynecologic surgical care.

Patients or Participants: A total of 402 women who underwent surgical management for ovarian cysts.

Interventions: Laparoscopic or open (laparotomy) surgical management based on preoperative assessment and intraoperative findings.

The study has been approved by IRB

Results

Measurements and Primary Results: Cyst size was strongly associated with both the planned and final surgical approach ($p<0.001$). Laparoscopy was performed in >95% of cysts ≤9 cm, decreased to 73.3% in 10–14 cm, and to 17.4% in ≥15 cm cysts, while laparotomy rates increased to 28.9% and 95.7%, respectively. In multivariable analysis, cyst size was independently associated with laparotomy, with a 3.8% increase in odds per 1-mm increase (OR 1.038, 95% CI 1.027–1.050, $p<0.001$). Laparotomy was associated with longer operative time (122 vs. 102 minutes, $p=0.015$), greater haemoglobin drop ($p=0.013$), longer hospital stay (3.96 vs. 2.72 days, $p<0.001$), and higher oophorectomy rates (13.2% vs. 4.1%, $p<0.001$), with no difference in overall complication rates. Spillage was more common in laparoscopy (58.3% vs. 34.0%, $p<0.001$). Several large cysts initially planned for laparoscopy required intraoperative conversion to laparotomy.

Conclusions

Cyst size significantly influences surgical approach; however, it represents a spectrum rather than a strict cutoff. While cysts ≤9 cm are reliably managed laparoscopically and cysts ≥15 cm are predominantly treated by laparotomy, a clinically relevant transition zone exists between 10–14 cm. These findings provide a practical framework for surgical decision-making and support an individualized, risk-based approach that integrates cyst size with clinical and imaging factors rather than relying on rigid thresholds.

ESGE35-0752 -
Free Communication

Clinical application and evaluation of AI-assisted technology in laparoscopic gynecological surgery

Shiori Takeuchi[1], Yanagihara Yasuho[2], Kawasaki Yu[3], Keisuke Murakami[4], Kitade Mari[4]
[1]Juntendo University School of Medicine, Obstetrics and Gynaecology, Tokyo, Japan
[2]Juntendo University Hospital, Obstetrics and Gynaecology, Tokyo, Japan
[3]Junetendo University, Obstetrics and Gynaecology, Tokyo, Japan
[4]Juntendo University, Obstetrics and Gynaecology, Tokyo, Japan

Background

In recent years, the use of AI systems in surgery has been increasing, with various commercially available solutions emerging. Laparoscopic surgery has become the standard approach in gynaecology; however, complex cases involving severe adhesions, uterine anomalies, or multiple myomas remain technically challenging, highlighting the need for advanced intraoperative guidance.

Methods

Two types of AI-assisted imaging systems were assessed. First, a three-dimensional virtual reality (3D-VR) preoperative simulation platform (Holoeyes MD) was applied in a case of ORVIRA syndrome complicated by peritonitis secondary to a tubo-ovarian abscess (TOA). Preoperative 3D images were used for surgical planning, and intraoperative real-time 3D projection was employed to aid anatomical orientation. Second, an intraoperative visual recognition support system (Eureka) designed to highlight ureters, vessels, and loose connective tissue was retrospectively evaluated using recorded intraoperative videos from gynecological laparoscopic cases. Additionally, a surgeon eye-tracking system (Tobii Technology) was utilized to analyze gaze direction and distribution during specific operative steps for educational purposes.

Results

Use of the 3D-VR platform facilitated anatomical understanding and enabled safe completion of surgery in the complex ORVIRA case. The visual recognition support system demonstrated fairly accurate identification of dissection planes, ureters, and blood vessels; however, accuracy tended to decrease in surgical fields with significant bleeding. The eye-tracking system clearly visualized differences in gaze directionality and dispersion across operative steps, suggesting potential as an educational tool for surgical skill development. Ongoing collaborative research with the system developer aims to improve recognition accuracy in challenging operative fields.

Conclusions

Although AI imaging technology in gynecological laparoscopic surgery is not yet fully mature, these systems show promise in reducing complication rates, intraoperative blood loss, and surgeon fatigue, while also contributing to surgical education. Further development and validation are warranted to support their integration into safe laparoscopic practice.

ESGE35-0011 -
Free Communication

'Ad a no myoma – a stepwise approach to performing laparoscopic adenomyomectomy

Sophie Strong[1], *Funlayo Odejinmi*[1]
[1]*Barts Health Trust, Gynaecology, London, United Kingdom*

Background

Laparoscopic myomectomy remains one of the most common surgical managements for women with uterine fibroids, adenomyomectomy however is less frequently performed, likely due to the surgical complexities with significant risk of haemorrhage and emergency hysterectomy. Video modelling has been shown to be a successful educational tool in improving hands-on surgical skills and technique in laparoscopy. We present a stepwise guide to performing a safe laparoscopic adenomyomectomy alongside a laparoscopic myomectomy with in-bag morcellation to serve as an educational guide.

Methods

A video from a surgery performed at Whipps Cross Hospital for a 43-year-old patient presenting with heavy menstrual bleeding and pelvic pressure effects from a large fibroid and adenomyoma has been utilised. The patient previously had undergone a uterine artery embolization without success. The patient consented for her case to be presented and published.

Results

Once the fibroid was removed, challenges were faced in trying to close the uterus and a large adenomyoma presented itself. An adenomyomectomy was then performed to facilitate uterine closure and achieve haemostasis. We provide an easy guide to performing this surgery and discuss tips and tricks for overcoming potential challenges which may be encountered during the procedure.

Conclusions

Video guides for performing laparoscopy are becoming a mainstay of education for operators of all experience levels, they serve to flatten the learning curve and can be used in developing safe techniques for advanced procedures, such as in laparoscopic adenomyomectomy.

https://player.vimeo.com/video/1174808311?autoplay=1

ESGE35-0151 -
Free Communication

Hysteroscopic management of persistent RPOC after repeated blind D&C revealing iatrogenic Asherman Syndrome and uterine septum in recurrent pregnancy loss

Dominika Jasińska-Stasiaczek[1], *Mariusz Wójtowicz*[1]
[1]*Municipal Hospital in Zabrze, Woman and Child Health Center in Zabrze, Zabrze, Poland*

Background

Blind dilatation and curettage (D&C) is still widely performed despite evidence indicating an increased risk of intrauterine adhesions and a higher incidence of persistent, retained products of conception (RPOC). The aim of this video is to demonstrate the successful hysteroscopic management of iatrogenic Asherman syndrome following repeated blind D&C, along with the diagnosis and treatment of an unrecognized Müllerian anomaly.

Methods

We report the case of a 41-year-old patient (G3P0) with a history of two prior miscarriages managed surgically (2009, 2019). In her third pregnancy, a pharmacologically induced miscarriage was followed by two repeated blind D&C procedures. One month later, persistent RPOC was diagnosed. The patient was primarily referred for another D&C. We suggested operative hysteroscopy. A 15 Fr miniresectoscope was used. A staged approach was applied, including primary hysteroscopy, second-look hysteroscopy after 21 days, and third-look hysteroscopy after 14 days. Postoperative evaluation included hysterosalpingography (HSG).

Results

Initial hysteroscopy revealed RPOC and intrauterine adhesions consistent with Asherman syndrome, involving approximately half of the uterine cavity. Complete removal of RPOC and extensive adhesiolysis were performed. A uterine septum was suspected. Second-look hysteroscopy confirmed a Müllerian anomaly and hysteroscopic septum resection was completed. Third-look hysteroscopy confirmed restoration of normal uterine cavity anatomy without adhesions. HSG showed left tubal patency and right tubal occlusion. The patient subsequently conceived spontaneously and is currently at 13 weeks of an ongoing uncomplicated pregnancy.

Conclusions

Operative hysteroscopy allows effective management of RPOC, treatment of intrauterine adhesions, and simultaneous diagnosis and correction of Müllerian anomalies. It should be considered a first-line approach in the management of miscarriage, especially in patients with recurrent pregnancy loss or infertility, to improve reproductive outcomes. Blind uterine evacuation procedures should be limited due to their higher risk of complications compared to modern, minimally invasive, image-guided techniques.

https://player.vimeo.com/video/1191065447?autoplay=1

ESGE35-0684 -
Free Communication

Improving the recognition, diagnosis, and management of ovarian collision tumours: a case report

Elizabeth Andrews[1], *Rhonda Flemming*[1], *Guldzhan Vorona*[1]
[1]*Whittington Hospital, Obstetrics and Gynaecology, London, United Kingdom*

Background

Ovarian collision tumours are rare, defined by the coexistence of two or more histologically distinct neoplasms within the same ovary, without intermixing. This case report highlights the diagnostic challenges and clinical significance of ovarian collision tumours by reviewing their clinical presentation, diagnostic work-up, and management strategies.

Methods

We describe two patients presenting with distinct clinical scenarios. Firstly, a 37-year-old nulliparous woman with polyendocrine metabolic ovarian syndrome, a previous dermoid cystectomy, and a family history of breast cancer. Pelvic MRI demonstrated a 10 × 5 cm lesion arising from the left ovary, consistent with a possible mature cystic teratoma. A spillage-free laparoscopic technique was employed. Histopathology confirmed a mature cystic teratoma coexisting with a mucinous cystadenoma.

A second case involved a 32-year-old nulliparous woman presenting acutely with severe abdominal pain and pyrexia, in the context of a known cystic teratoma and a family history of breast cancer. MRI revealed a 5 × 3 × 4.6 cm cystic teratoma containing calcified components, and with a posterior haemorrhagic signal indicating an endometrioma, concurrent ovarian torsion could not be excluded. Following multidisciplinary discussion, the patient underwent emergency laparoscopic management, during which a ruptured endometrioma was identified.

Results

Postoperatively, both patients recovered with minimal blood loss. Patient 1 was discharged on the same day without intraoperative or postoperative complications. Patient 2 experienced an uncomplicated perioperative course and histopathological evaluation confirmed stage IV endometriosis.

Conclusions

This video abstract highlights the challenges of managing ovarian collision tumours. Although rare, these tumours require early recognition to allow appropriate multidisciplinary management. The presented cases demonstrate the difficulty in identifying ovarian collision tumours preoperatively. Advanced imaging modalities may mimic malignancy, potentially influencing clinical decision-making and prompting more extensive intervention. Further research is required to improve preoperative diagnostic accuracy and understanding of the pathogenesis of these tumours.

https://player.vimeo.com/video/1195095344?autoplay=1

ESGE35-0783 -
Free Communication

A twist in the tale: isolated fallopian tube torsion leading to auto-amputation secondary to a giant para-ovarian cyst

Maria Eduarda Ferreira Bruco[1], Charlotte Colley[1], Anastasia Russell-Dalton[1], Pallavi Arya[2], Amila Gunawardhana[3], Guldzhan Vorona[1]
[1]Whittington Health NHS Trust, Women's Health Department, London, United Kingdom
[2]Whittington Health NHS Trust, General Surgery Department, London, United Kingdom
[3]Whittington Health NHS Trust, Anaesthetic Department, London, United Kingdom

Background

Our objectives are to report a rare case of fallopian tube torsion secondary to a para-ovarian cyst, resulting in spontaneous autoamputation, and to highlight the diagnostic challenges in distinguishing acute torsion from chronic pelvic conditions such as endometriosis. This case underscores the importance of timely surgical intervention to prevent irreversible tissue damage and optimise fertility preservation.

Methods

A 31-year-old woman presented with a second episode of pelvic pain within one week, with lower abdominal tenderness on examination. Blood tests showed raised inflammatory markers: white cell count 11.2 × 10^9/L and C-reactive protein 95 mg/L. Computed tomography demonstrated a 9 cm left para-ovarian cyst with twisting of the left adnexal pedicle, an 8 mm dilated appendix, marked pelvic fat stranding and free fluid. She had known deep infiltrating endometriosis on magnetic resonance imaging and a previously documented 13 cm adnexal cyst on pelvic ultrasound, raising suspicion of torsion.

Results

Diagnostic laparoscopy revealed a devitalised 13 × 15 cm para-ovarian cyst with torsion of the ipsilateral fallopian tube. The cyst and fimbrial end had undergone spontaneous autoamputation. The remaining tube was torted, oedematous and non-viable, necessitating salpingectomy. Concurrent appendicectomy was performed due to an inflamed appendix.

The patient recovered well and was discharged the same day, with follow-up arranged via the specialist endometriosis clinic. Histopathology confirmed a benign serous cystadenoma and torted fallopian tube with no malignancy; the appendix showed inflammatory changes only. Intraoperative findings were documented with written patient consent for educational use.

Conclusions

This case demonstrates rare fallopian tube autoamputation secondary to para-ovarian torsion in complex chronic pelvic disease. Existing endometriosis and overlapping imaging findings contributed to delayed definitive surgery. This case highlights the need for a high index of suspicion for adnexal torsion in acute-on-chronic pelvic pain and clear preoperative counselling regarding realistic surgical objectives and possible loss of tubal function.

https://player.vimeo.com/video/1195579238?autoplay=1

ESGE35-0900 -
Free Communication

Laparoscopic management of a viable caesarean section scar ectopic pregnancy

Ahmed Salama Hassan[1], *Gourab Misra*[1], *Ammar Rafiq*[1]
[1]*University hospitals of North Midlands, Gynaecology, Stoke on Trent, United Kingdom*

Background

Caesarean section scar ectopic pregnancy (CSEP) is a rare but potentially life-threatening form of ectopic pregnancy associated with increasing caesarean section rates. Early diagnosis is essential to prevent catastrophic haemorrhage, uterine rupture, and loss of fertility. Multiple treatment modalities have been described; however, optimal management remains individualized according to type, gestational age, myometrial thickness, patient stability, and future fertility wishes. We present a case of successful laparoscopic management of a large viable CSEP in a 46-year-old woman.

Methods

A 46-year-old patient presented with a suspected CSEP diagnosed on transvaginal ultrasound scan and further characterized by pelvic MRI. MRI demonstrated a gravid uterus with a gestational sac implanted within the previous caesarean section scar measuring 5.1 × 5.3 cm, with foetal crown-rump length of 43 mm. Residual myometrial thickness measured 4.7 mm maximally, with significant anterior myometrial deficiency extending 15 mm and posterior extension of 42 mm. The bladder wall was not involved. Following multidisciplinary team discussion, definitive laparoscopic surgical management was planned.

The operative procedure included laparoscopic confirmation of the diagnosis, Vasopressin 20 IU diluted in 100 mL of normal saline was injected into the lower uterine segment and the uterovesical fold to achieve haemostasis, incision of the lower uterine segment and caesarean scar, evacuation of products of conception from the scar niche, retrieval using an endoscopic retrieval bag, suction evacuation of residual intrauterine products, application of haemostatic sealant (Floseal) to the scar bed and endometrial cavity, and multilayer uterine closure using 2-0 Vicryl sutures in three layers. Haemostasis was confirmed at the completion of the procedure. Estimated blood loss was 250 mL.

Results

Laparoscopic management was completed successfully without intraoperative complications or need for conversion to laparotomy. Complete excision of the ectopic pregnancy was achieved with preservation of the uterus. Haemostasis was effectively secured following multilayer uterine reconstruction and adjunctive haemostatic agent application. The products of conception were removed safely via the lateral port within the retrieval bag. The patient had an uncomplicated postoperative recovery.

Conclusions

Laparoscopic management of CSEP is a safe and effective minimally invasive option in appropriately selected patients when undertaken by an experienced gynaecological endoscopy team. Preoperative imaging with ultrasound and MRI facilitates accurate assessment of myometrial invasion and bladder

involvement, supporting operative planning. This case highlights the feasibility of laparoscopic excision and uterine reconstruction for advanced viable CSEP with minimal blood loss and favourable surgical outcome.

https://player.vimeo.com/video/1195741732?autoplay=1

ESGE35-0930 -
Free Communication

Ovarian torsion and contralateral adnexal mass: a challenging laparoscopic scenario

Ebru Kara[1], Mehtap Akın Efe[1], Hevra Ekin Ulusoy[1]
[1]Istanbul Training and Research Hospital, Department of Obstetrics and Gynaecology, Istanbul, Türkiye

Background

This video demonstrates the laparoscopic management of an unusual case of contralateral ovarian torsion associated with a large complex ovarian cyst originating from the opposite adnexa, highlighting unexpected intraoperative findings, diagnostic challenges, and individualized ovarian preservation strategies in emergency gynecologic surgery.

Adnexal torsion may present with unexpected intraoperative findings despite apparently concordant clinical and radiological evaluation. Such discrepancies can significantly influence surgical strategy and intraoperative decision-making, particularly in premenopausal women where ovarian preservation remains an important consideration. We present a rare case in which physical examination, ultrasonography, and computed tomography consistently suggested a left adnexal mass with suspected torsion, whereas laparoscopic exploration revealed left ovarian torsion associated with a contralateral ovarian mass displaced toward the left pelvis, creating an unexpected intraoperative scenario.

Methods

A 52-year-old premenopausal woman presented to the emergency department with acute-onset left lower quadrant pain associated with nausea and vomiting. Physical examination demonstrated localized tenderness with voluntary guarding. Ultrasonography and pelvic computed tomography revealed a myomatous uterus and a 10-cm multiloculated complex cystic lesion occupying the left adnexal region, raising suspicion for adnexal torsion associated with a left adnexal mass. Emergency diagnostic laparoscopy with planned unilateral salpingo-oophorectomy was performed.

Intraoperatively, the left ovary was found to be torsed by three complete rotations despite the absence of a significant ipsilateral adnexal mass. Unexpectedly, the 10-cm complex cystic lesion originated from the right ovary and had displaced toward the left pelvis, resulting in misleading localization on both imaging and clinical examination. Following careful detorsion, progressive reperfusion and restoration of normal ovarian coloration were observed on the left side. Considering the patient’s premenopausal status, ovarian preservation was preferred on the torsed side. Due to the presence of a large complex right ovarian mass and the inability to perform frozen-section analysis under emergency conditions, right salpingo-oophorectomy was performed laparoscopically. The specimen was removed intact within an endoscopic retrieval bag.

Results

Histopathological examination demonstrated mucinous cystadenoma. The postoperative course was uneventful, and follow-up demonstrated satisfactory recovery without complications.

Conclusions

Adnexal torsion is typically expected to occur ipsilateral to the associated adnexal mass. This case demonstrates that large adnexal lesions may deviate across the pelvis and create misleading radiologic and clinical findings, resulting in unexpected contralateral torsion. The video highlights the importance of systematic laparoscopic pelvic evaluation, careful assessment of adnexal anatomy, and individualized ovarian preservation strategies in emergency gynecologic surgery. This step-by-step minimally invasive approach provides valuable educational insight into intraoperative decision-making and management of complex adnexal torsion cases.

https://player.vimeo.com/video/1195764961?autoplay=1

ESGE35-0074 -
Free Communication

Dysmenorrhoea and non-menstrual pelvic pain reduction among clinically relevant subgroups of women with endometriosis-associated pain treated with Linzagolix in the EDELWEISS-3 trial

Ertan Saridogan[1], Herrera Francisco Carmona[2], Beatrice Suero[3], Rowena Cottrell[4], Elke Bestel[5]
[1]University College London Hospital, Women's Health Division, London, United Kingdom
[2]Faculty of Medicine. Hospital Clínico and Provincial. University of Barcelona, Department of Gynaecology, Barcelona, Spain
[3]STATLOG, Statlog, Montreal, Canada
[4]Theramex, Medical Affairs, London, United Kingdom
[5]Theramex, Medical Affairs, London, United Kingdom

Background

Linzagolix (LGX), an oral Gonadotropin-releasing hormone (GnRH) antagonist is approved as treatment for the management of endometriosis-associated pelvic pain. In EDELWEISS-3, its phase 3 trial, LGX200mg with add-back therapy (ABT) demonstrated clinically meaningful and statistically significant reductions in dysmenorrhoea (DYS) and non-menstrual pelvic pain (NMPP) at months 3 (p-values <0.001 and 0.007, respectively), while LGX75mg significantly reduced DYS but was not statistically significant for NMPP (p-values <0.001 and 0.279, respectively). A post-hoc analysis was conducted to assess whether the efficacy of LGX differs across clinically relevant subgroups of women based on age, level of baseline pain, BMI, and time since endometriosis diagnosis in the EDELWEISS-3 trial.

Methods

In EDELWEISS, women with endometriosis-associated pelvic pain were equally randomised to a 6-months treatment period with either LGX200mg+ABT, LGX75mg, or placebo. The two co-primary efficacy endpoints were a clinically meaningful reduction of DYS and NMPP over the last 28 days of randomised treatment up to Month 3, along with stable or decreased use of analgesics for endometriosis-associated pain. DYS and NMPP were assessed in electronic diaries using a verbal rating scale (VRS, scale 0-3), and VRS reductions of 1.1 (dysmenorrhea) and 0.8 (NMPP) were considered clinically meaningful. Month 3 odds ratios (ORs) for the co-primary endpoints were estimated via logistic regression with baseline pain statistical adjustment and Bonferroni-corrected p-values. Subgroups (n=11) were defined based on age (<median, ≥median), body mass index (BMI; <median, ≥median), baseline dysmenorrhea (<median, ≥median), baseline NMPP (<median, ≥median), and years since endometriosis diagnosis (<2y, 2-4y, 5+y).

Results

In EDELWEISS-3, 486 eligible women were randomised to LGX200mg+ABT, LGX75mg, or placebo; 484 women were assessed for efficacy. The subgroup analyses were consistent with the primary results from the EDELWEISS-3 trial. Women treated with LGX had significantly higher odds of achieving a clinically meaningful reduction in DYS compared to placebo. For LGX200mg+ABT, ORs versus placebo

ranged from 5.02 to 16.81 across all 11 subgroups ($p < 0.001$). LGX75mg also showed significantly increased odds for DYS in 9 of the 11 subgroups ($p < 0.05$), with ORs ranging from 2.26 to 3.48.

The treatment effect was less pronounced for NMPP, but still reached statistical significance ($p < 0.05$) in three subgroups: women > 35years (ORs 3.12 and 2.30 for LGX200mg+ABT and LGX75mg, respectively), women with baseline DYS below the median of 2.29 (LGX200mg+ABT; OR 3.03), and women with baseline NMPP below the median of 1.83 (LGX200mg+ABT; OR 2.77). No subgroup deviated importantly from the overall population, supporting the robustness and generalizability of the result.

Conclusions

This subgroup analysis indicates that LGX provides consistent pain reduction across clinically relevant subgroups, including baseline pain, BMI, and time since endometriosis diagnosis. This supports LGX potential as a broadly applicable and flexible option for women who require a rapid-onset oral endometriosis treatment.

ESGE35-0126 -
Free Communication

Correlation between pre-operative hormonal therapy and post-operative complications in endometriosis: results from a retrospective study

Benedetta Dalmagioni[1], Enrico Pazzaglia[1], Antonio Raffone[2], Luigi Cobellis[2], Renato Seracchioli[1], Diego Raimondo[3]
[1]Division of Gynaecology and Human Reproduction Physiopathology- IRCCS Azienda Ospedaliero - Uni versitaria di Bologna- Bologna- Italy,
Department of Medical and Surgical Sciences DIMEC- University of Bologna- Bologna- Italy, Bologna, Italy
[2]University of Campania "Luigi Vanvitelli"- Naples- Italy,
Department of Woman- Child- and General and Specialized Surgery, Napoli, Italy
[3]IRCCS Azienda Ospedaliero - Universitaria di Bologna- Bologna- Italy,
Division of Gynaecology and Human Reproduction Physiopathology, Bologna, Italy

Background

To study the possible association between preoperative hormonal therapy and the risk of postoperative surgical complications in patients undergoing minimally invasive surgery for endometriosis.

Methods

A retrospective, single-centre, observational cohort study was conducted the Gynaecology Unit of the IRCCS Azienda Ospedaliero-Universitaria di Bologna, a tertiary referral center for endometriosis. Eligible patients were women aged 18–55 years with a preoperative clinical, ultrasound or magnetic resonance imaging suspicion of endometriosis, subsequently confirmed intraoperatively, who underwent laparoscopic or robotic surgery with complete macroscopic excision of endometriotic lesions. Patients were divided into two groups: those receiving preoperative hormonal therapy for at least three months, (Hormonal Therapy group), and those who did not receive any hormonal treatment prior to surgery, (non-Hormonal Therapy group). The primary outcome was the association between preoperative hormonal therapy and the incidence of postoperative surgical complications, defined as any deviation from the expected postoperative course and classified according to the Clavien–Dindo classification, considering only Clavien–Dindo grade 2 or higher complications. Secondary outcome was the same analysis in a subgroup of patients with rectal endometriosis, defined as ENZIAN C≥1. To this purpose a multivariable logistic regression analysis was used, adjusting for potential confounders such as age, infertility history, presence of ovarian endometriotic cysts and disease extent. A subgroup analysis was performed in patients with rectal endometriosis.

Results

Between the 812 considered patients, 516 (63.5%) received preoperative hormonal therapy, while 296 (36.5%) did not. Disease severity, as reflected by ENZIAN classification, was significantly higher in the non-Hormonal Therapy group: these patients presented a larger involvement of rectovaginal space, vagina, retro-cervical area, uterosacral and cardinal ligaments, pelvic sidewall, rectum,

intestine, ureter. Postoperative complications of grade 2 or higher occurred with no statistically significant difference between the Hormonal Therapy group and the non- Hormonal Therapy group (14.3% vs. 12.2%; p=0.397). After multivariable logistic regression analysis, no association between preoperative hormonal therapy and the risk of postoperative complications was found out (odds ratio 1.297; 95% confidence interval 0.891–1.901; p=0.177). A similar result was observed in the subgroup of patients with rectal involvement (OR 1.193; CI95% 0.746–1.934; p=0.466).

Conclusions

Preoperative hormonal therapy is not associated with the risk of postoperative complications in women undergoing surgery for endometriosis. These findings suggest that hormonal therapy may be safely recommended for symptoms management before surgery, without significantly affecting surgical risk. Further research is needed to evaluate the possible impact of type and duration of hormonal regimens on endometriosis lesions appearance and surgical risk.

ESGE35-0643 -
Free Communication

Influence of intraureteral indocyanine green application on laparoscopic ureterolysis frequency and ureteral injury incidence during endometriosis surgery

Rok Sumak[1], *Jure Knez*[2]
[1]*University Medical Centre Maribor, Department of General Gynaecology and Gynaecologic Urology, Maribor, Slovenia*
[2]*University Medical Centre Maribor, Department of Gynaecologic and Breast Oncology, Maribor, Slovenia*

Background

To evaluate the impact of routine intraureteral indocyanine green (ICG) application on the frequency of ureterolysis during laparoscopic surgery for endometriosis.

Methods

This retrospective cohort study included patients who underwent laparoscopic surgery for endometriosis at a tertiary referral center. Patients were divided into two groups according to the implementation of routine intraureteral ICG on April 4, 2025. The primary outcome was the rate of ureterolysis before and after ICG introduction. Secondary outcomes included ureteral injury. Statistical analysis was performed using SPSS version 25. Categorical variables were compared using Fisher's exact test.

Results

A total of 165 procedures were included, with 149 performed before and 16 after ICG implementation. Ureterolysis was performed in 72/149 cases (48.3%) before ICG and in 3/16 cases (18.8%) after ICG introduction, representing a significant reduction after implementation ($p = 0.033$). Posterior compartment involvement was comparable between groups (67.8% vs. 68.8%, $p = 1.00$), as were combined ovarian/tubo-ovarian involvement (69.1% vs. 56.3%, $p = 0.40$) and peritoneal involvement (19.5% vs. 25.0%, $p = 0.53$).Ureteral injury occurred in two cases before ICG implementation and in none after.

Conclusions

Routine intraureteral ICG application was associated with a significant reduction in ureterolysis during laparoscopic endometriosis surgery, despite comparable disease distribution and surgical complexity. These findings suggest that fluorescence-guided ureter visualization may support a more selective approach to ureteral dissection and improve surgical strategy in complex endometriosis surgery.

ESGE35-0650 -
Free Communication

Pregnancy outcomes after surgical treatment of endometriosis: a phenotype-specific cohort study

Mehmet Çopuroğlu[1], Mustafa Bertan Demir[1], Tufan Öge[2]
[1]Kayseri City Hospital, Department of Obstetrics and Gynaecology, Kayseri, Türkiye
[2]Eskişehir Osmangazi University, Department of Obstetrics and Gynaecology, Eskişehir, Türkiye

Background

Endometriosis is increasingly associated with adverse pregnancy outcomes beyond infertility. However, the effect of previous surgical treatment and endometriosis phenotype on obstetric risk remains unclear. This study evaluated pregnancy outcomes following previous endometriosis surgery and compared obstetric risks according to disease phenotype.

Methods

This retrospective cohort study included singleton pregnancies delivered at a tertiary referral center between January 2020 and December 2025. Women with surgically confirmed endometriosis were classified as ovarian endometrioma surgery or deep infiltrating endometriosis (DIE) surgery groups. DIE was defined as lesions infiltrating >5 mm beneath the peritoneal surface. Women without endometriosis served as controls. Preterm birth (<37 weeks) was the primary outcome. Secondary outcomes included caesarean delivery, placenta previa, postpartum hemorrhage (PPH), and neonatal intensive care unit (NICU) admission. Multivariable logistic regression analyses were adjusted for maternal age, body mass index, previous caesarean delivery, and assisted reproductive technology (ART) use. Sensitivity analyses excluding ART pregnancies were performed.

Results

A total of 612 singleton pregnancies were included: 218 women with previous ovarian endometrioma surgery, 124 women with prior DIE surgery, and 270 controls. ART use was significantly more frequent among women with previous endometriosis surgery. Women with previous endometriosis surgery showed significantly higher rates of adverse pregnancy outcomes than controls. Preterm birth occurred in 17.5% versus 9.3% (p=0.006), while caesarean delivery was observed in 61.7% and 42.6%, respectively (p<0.001). Placenta previa was more common in the surgical group (6.1% vs 2.2%, p=0.021), and NICU admission occurred in 15.2% and 8.5%, respectively (p=0.014). Phenotype-specific analyses demonstrated less favourable outcomes after DIE surgery. Preterm birth occurred in 22.6% of women with previous DIE surgery compared with 14.7% after ovarian endometrioma surgery (p=0.041). PPH rates were higher in the DIE group (10.5% vs 4.6%, p=0.028), and NICU admission was more frequent after DIE surgery (19.4% vs 12.8%, p=0.048). After adjustment, previous endometriosis surgery remained independently associated with preterm birth (aOR=2.01; 95% CI: 1.29–3.12; p=0.002) and placenta previa (aOR=2.44; 95% CI: 1.08–5.53; p=0.031), whereas associations with caesarean delivery and NICU admission were attenuated after adjustment. Previous DIE surgery showed the strongest association with adverse outcomes, particularly preterm birth (aOR=2.63; 95% CI: 1.44–4.82; p=0.001). The association between previous endometriosis surgery and preterm birth remained significant after exclusion of ART pregnancies.

Conclusions

Previous surgical treatment for endometriosis was associated with increased adverse pregnancy outcomes, particularly after DIE surgery. Endometriosis phenotype may contribute to obstetric risk stratification in surgically treated women.

ESGE35-0303 -
Free Communication

Postmenopausal endometriosis classified by #Enzian: a long term ultrasound and clinical follow-up

Aikaterini Selntigia[1], Sabrina Sassone[1], Elvira Nocita[1], Giorgia Macciocca[1], Alfredo Ercoli[2], Caterina Exacoustos[1]
[1]Policlinico Tor Vergata,
Department of Surgical Sciences- Gynaecological Unit- University of Rome "Tor Vergata" Rome- Italy., Rome, Italy
[2]Policlinico Tor Vergata,
Department of Biomedicine and Prevention. Gynaecological Unit University of Rome Tor Vergata- Rom e- Italy, Rome, Italy

Background

This study aims to describe the longitudinal ultrasound features and clinical course of deep pelvic endometriosis, ovarian endometriomas and adenomyosis in postmenopausal women, to improve diagnostic accuracy and guide follow-up.

Methods

This retrospective observational study included postmenopausal patients with at least one transvaginal sign of endometriosis and/or adenomyosis, monitored with serial ultrasound examinations from premenopause for a minimum of 24 months. All underwent two-dimensional (2D) and three- dimensional (3D) transvaginal ultrasound assessed using IDEA and MUSA criteria in our Gynecological Ultrasound Unit (April 2018-April 2026). All the lesions diagnosed by ultrasound were classified according to #Enzian compartments.

Results

In 102 postmenopausal patients with at least one ultrasound sign of endometriosis and/or adenomyosis serial TVS scans was performed before menopause and in postmenopuse with follow-up of at least of 24 months. Mean age was 54.2 ± 4.3 years, with 4.4 ± 2.9 years since menopause. A consistent reduction in percentage was observed for compartments C, B, O and FA between pre and postmenopause. In particular C3 lesions decreasing from 32% to 21% and C2 lesions increasing from 10% to 18%, indicating shrinkage. Rectal nodules (C compartment) and ovarian endometriomas (O compartment) showed the greatest size reduction, approximately 25–40%. Concerning ultrasound endometriomas characteristics, ground-glass echogenicity was present in 82.2% at baseline, while irregular walls became more frequent, from 11.1% to 38.6% (p=0.003) such us non-vascularized hyperechoic areas, from 17.8% to 38.6%. Adenomyosis significantly decreased from 89.5% in premenopause to 71.6% in postmenopause and remained stable thereafter.

Conclusions

This study shows a progressive regression of endometriotic and adenomyotic disease burden following the menopausal transition, with the greatest improvement in deep longer rectal and ovarian lesions, while smaller or localized foci tend to persist. Postmenopausal ovarian

endometriomas usually have a benign course, with an early size reduction and late-onset morpho-structural changes.

ESGE35-0344 -
Free Communication

Tailored surgical strategy for multicentric and multifocal bowel endometriosis

Catalin Bogdan Coroleuca[1], Andrei Manu[2], Ciprian-Andrei Coroleucă[2], Cristina-Maria Iacob[2], Mihaela Arina Banu[2], Elvira Brătilă[2]
[1]Clinical Hospital of Obstetrics & Gynaecology "Prof. Dr. Panait Sarbu"- Bucharest- Romania, Obstetrics & Gynecology, Bucharest, Romania
[2]Clinical Hospital of Obstetrics and Gynaecology "Prof. Dr. Panait Sîrbu" and Faculty of Medicine- "Car ol Davila" University of Medicine and Pharmacy, Obstetrics and Gynaecology, Bucharest, Romania

Background

Bowel endometriosis represents one of the most complex manifestations of deep infiltrating disease, frequently involving multiple segments at different levels of the gastrointestinal tract. The heterogeneity of lesion distribution — ranging from rectal and sigmoid involvement to ileal, caecal and appendiceal localisations — makes a single standardised surgical approach inadequate. Effective management requires detailed preoperative mapping, systematic intraoperative exploration and an individualised selection of bowel procedures adapted to lesion location, depth and distribution. The aim of this study is to describe a tailored surgical strategy for multicentric and multifocal bowel endometriosis, integrating preoperative assessment, intraoperative decision-making and procedure selection according to each individual pattern of disease.

Methods

We reviewed our institutional experience with surgically managed bowel endometriosis in a tertiary referral setting, with particular attention to patients with multicentric or multifocal disease involving the rectum, sigmoid colon, ileum, caecum and appendix. Preoperative assessment included clinical examination, transvaginal ultrasound, MRI and multidisciplinary planning. Surgical strategy was individualised according to lesion size, depth of infiltration, number of nodules, distance between lesions, bowel segment involved, fertility objectives and expected functional impact.

Results

The institutional cohort included 688 patients with surgically managed endometriosis, of whom 355 had rASRM stage IV disease. Rectal involvement was identified in 325 cases (Enzian C3 in 203, C2 in 79, multiple nodules in 61), sigmoid in 63, ileal in 41, appendiceal in 23 and caecal in 15. Surgical management was adapted to disease distribution: segmental bowel resection was performed in 269 cases and rectal shaving in 42. Small bowel procedures included ileal resections, ileocaecal and ileo-ileal anastomoses, appendicectomy and caecal resection when indicated. In ileal, caecal and appendiceal localisations, careful intraoperative inspection and palpation were essential, as these lesions are frequently small, multifocal and missed on preoperative imaging. Symptom improvement was reported in more than 90% of patients, with no conversion to laparotomy.

Conclusions

Multicentric and multifocal bowel endometriosis requires detailed preoperative mapping, systematic intraoperative exploration and a tailored choice among shaving, disc excision, segmental resection and small bowel or ileocaecal procedures. Surgical customisation allows complete excision while preserving bowel function and avoiding unnecessary radicality — including unnecessary right colectomy or diverting stoma. The guiding principle is not the most aggressive operation, but the most anatomically appropriate one for each individual pattern of disease.

ESGE35-0374 -
Free Communication

Psychiatric comorbidity in women newly referred to a secondary-care endometriosis pathway: prevalence, clinical phenotype and treatment engagement

Sophie Bracke[1], *Wai Phyo Maung*[1], *Saskia Delray*[1], *Guldzhan Vorona*[1]
[1]*Whittington Health NHS Trust, Obstetrics & Gynaecology, London, United Kingdom*

Background

Endometriosis is increasingly recognised as a condition with substantial psychological as well as physical morbidity. Despite this, mental-health burden is not routinely characterised within endometriosis pathways, and little is known about how psychiatric comorbidity influences symptoms, engagement and treatment uptake. This audit aims to quantify the prevalence of psychiatric and neurodevelopmental comorbidity in women referred to a secondary-care endometriosis service, and to assess whether mental-health status was associated with symptom burden, comorbidity profile and treatment engagement.

Methods

Retrospective single-centre case-note audit of new patients seen in an endometriosis clinic between 01 January and 30 June 2025. Mental-health documentation was classified using a structured keyword schema; psychiatric conditions (depression, anxiety, post-traumatic stress, eating disorders, psychotic and personality disorders, self-harm) and neurodevelopmental conditions (ADHD, autism, learning difficulties) were analysed separately. Categorical associations were tested with chi-square or Fisher exact tests, continuous variables with Mann-Whitney U.

Results

Of 138 analysable referrals, 63 (45.7%) had a documented psychiatric condition. Depression (35.5%) and anxiety (31.9%) dominated; self-harm or suicidality was recorded in 5.8% and severe mental illness (psychotic, personality or eating disorders, or suicidality) in 10.1%. Only 2.9% had a recorded neurodevelopmental diagnosis, almost certainly under-ascertained against UK adult prevalence estimates exceeding 5%. Mental-health prevalence was numerically higher in the most deprived areas (61.9% versus 50.0%, odds ratio 1.62). Mental-health-positive women carried a heavier symptom burden: more chronic pelvic pain (82.5% versus 72.0%, odds ratio 1.84) and heavy menstrual bleeding (23.8% versus 17.3%). They also carried higher rates of overlapping pain syndromes: migraine (19.0% versus 10.7%, odds ratio 1.97), irritable bowel syndrome (12.7% versus 6.7%, odds ratio 2.04) and fibromyalgia (3.2% versus 1.3%) - a constellation consistent with central sensitisation, the recognised co-clustering of chronic pain and mood disorders. Clinicians recognised this complexity: mental-health-positive women were more likely to be offered hormonal therapy (66.7% versus 52.0%, odds ratio 1.85) and less likely to be discharged at first attendance (3.2% versus 12.0%). Strikingly, this subgroup showed greater engagement: treatment acceptance was numerically higher (75.0% versus 69.2%), with did-not-attend rate (19.0% versus 21.3%) and waiting time (146 versus 153 days) no different from mental-health-negative women.

Conclusions

Almost half of new endometriosis referrals carry psychiatric comorbidity; one in ten meet criteria for severe mental illness or self-harm. The bidirectional pain-mood loop means these women are simultaneously most motivated and most vulnerable in the pathway, yet receive care without embedded psychological support. We propose five concrete pathway changes: (1) validated psychological screening (PHQ-2, GAD-2) at first attendance with onward-referral protocols to clinical psychology positive scorers; (2) structured neurodevelopmental enquiry within the new-patient documentation; (3) embedded clinical psychology within the multidisciplinary team; (4) pre-operative psychological optimisation, capacity-assessment and liaison-psychiatry input for severe mental illness; and (5) mental health training for clinic staff.

ESGE35-0419 -
Free Communication

Ovarian endometrioma associated with Mayer–Rokitansky–Küster–Hauser syndrome: a rare case report

Mukadder Gök[1], Müge Ateş Tıkız[2], Elif Iltar[2], Fatma Ceren Güner[2], Hasan Aykut Tuncer[2]
[1]Akdeniz University, Obstetrics and Gynaecology, Antalya, Turkiye
[2]Akdeniz University, Gynecologic Oncology- Obstetrics and Gynaecology, Antalya, Turkiye

Background

Mayer–Rokitansky–Küster–Hauser (MRKH) syndrome is a rare congenital anomaly characterized by agenesis of the uterus and upper vagina in 46,XX females. Endometriosis is traditionally explained by retrograde menstruation; however, its occurrence in MRKH patients—who typically lack functional endometrium—remains poorly understood. This raises consideration of alternative pathogenetic mechanisms such as coelomic metaplasia. We present a rare case of ruptured ovarian endometrioma in an MRKH patient without radiologic evidence of functional endometrium.

Methods

A 22-year-old virgin woman with a history of primary amenorrhea presented with severe abdominal pain and distention. Physical examination revealed normal secondary sexual characteristics. Laboratory evaluation showed markedly elevated CA-125 and CA 19-9 levels. Imaging (ultrasound, CT, and MRI) demonstrated an approximately 20 cm complex cystic mass with solid components and ascites, raising suspicion for ovarian malignancy. The uterus was not visualized, and findings were consistent with vaginal atresia. The patient underwent exploratory laparotomy by the gynecologic oncology team with a differential diagnosis of mucinous ovarian carcinoma versus ruptured endometrioma.

Results

Intraoperatively, a ruptured 20 cm endometrioma originating from the left ovary was identified, with widespread cyst content throughout the peritoneal cavity and adhesions to the omentum. Bilateral rudimentary uterine horns were present, confirming MRKH syndrome. The left fallopian tube appeared as hydrosalpinx, while the right adnexa was normal. Wedge resection of the left ovary and peritoneal and omental biopsies were performed. Frozen section and final histopathology confirmed a benign endometrioma. The postoperative course was uneventful, and the patient was discharged on postoperative day 10. Progestin therapy was initiated.

Conclusions

This case demonstrates that ovarian endometrioma can occur in MRKH syndrome even in the absence of functional endometrium. Such presentations challenge the retrograde menstruation theory and support alternative mechanisms such as coelomic metaplasia. Additionally, markedly elevated tumor markers and complex imaging findings may mimic malignancy, emphasizing the importance of including benign conditions in the differential diagnosis. This rare presentation

contributes to the understanding of atypical endometriosis pathogenesis and highlights the need for a comprehensive, multidisciplinary diagnostic approach.

ESGE35-0506 -
Free Communication

Total intracorporeal anastomosis for rectosigmoid endometriosis: a systematic review and meta-analysis.

Paola Tesi[1], Manuela Maletta[1], Paola Mete[1], Diego Raimondo[2], Antonio Raffone[3], Renato Seracchioli[1]
[1]Division of Gynaecology and Human Reproduction Physiopathology- IRCCS Azienda Ospedaliero-Universitaria di Bologna- Bologna- Italy,
Department of Medical and Surgical Sciences DIMEC- University of Bologna, Bologna, Italy
[2]IRCCS Azienda Ospedaliero-Universitaria di Bologna- Bologna- Italy,
Division of Gynaecology and Human Reproduction Physiopathology, Bologna, Italy
[3]Department of Woman- Child- and General and Specialized Surgery- University of Campania "Luigi V anvitelli"- Naples- Italy, Department of Medical and Surgical Sciences DIMEC- University of Bologna, Bologna- Napoli, Italy

Background

This systematic review aims to compare intraoperative and postoperative outcomes between totally intracorporeal anastomosis and extracorporeal anastomosis in patients undergoing surgery for rectosigmoid endometriosis.

Methods

A systematic search of Web of Science, Scopus, ClinicalTrials.gov, MEDLINE, PubMed, Cochrane Library, and Google Scholar from inception to January 2026 was performed. The review was registered in PROSPERO (CRD420261282629). Peer-reviewed studies comparing totally intracorporeal anastomosis and extracorporeal anastomosis in rectosigmoid endometriosis surgery using laparoscopic or robotic approaches and reporting surgical outcomes were included. Reviews, case series, case reports, video articles, non-English publications, and studies with non-extractable data were excluded. Data were extracted according to PICO criteria. Outcomes included operative time, blood loss, complications, hospital stay, postoperative pain, functional outcomes, and recurrence. Risk of bias was assessed using MINORS and Cochrane RoB 2 tools. Continuous outcomes were analyzed as mean differences and dichotomous outcomes as odds ratios, with 95% confidence intervals. A random-effects model was applied.

Results

Five studies were included in the quantitative analyses with 295 patients undergoing bowel resection for rectosigmoid endometriosis, 116 (39.3%) in the totally intracorporeal anastomosis group and 179 (60.7%) in the extracorporeal anastomosis group. No significant differences were observed between TIA and EA in mean operative time (MD 14.84 minutes, 95% CI −38.58 to 68.26; $p = 0.59$; $I^2 = 74\%$) or hospital stay (MD −0.22 days, 95% CI −0.90 to 0.46; $p = 0.52$; $I^2 = 0\%$). Rates of intraoperative (OR 0.51; 95% CI 0.06–4.78; $p = 0.56$) and postoperative complications (OR 0.94; 95% CI 0.48–1.81; $p = 0.84$) were comparable. Meta-analysis was not feasible for intraoperative blood loss, postoperative pain, functional outcomes, and recurrence due to limited data. Sensitivity analysis confirmed no significant difference in operative time between totally intracorporeal anastomosis and

extracorporeal anastomosis. Sensitivity and post hoc analyses confirmed comparable results, including major complications.

Conclusions

Totally intracorporeal anastomosis appears comparable to extracorporeal anastomosis in surgical outcomes and may be considered when feasible in rectosigmoid endometriosis. However, evidence remains limited, and larger prospective studies are needed.

ESGE35-0066 -
Free Communication

Dorsolateral parametrectomy and oopherectomy for deep endometriosis with a suspicious adnexial mass

Serkan Ustuntas[1], Kemal Gungorduk[2], Beril Nesli Kanat[2]
[1]Tıp Fakültesi- Muğla Sıtkı Koçman Üniversitesi, Kadın Hastalıkları ve Doğum Anabilim Dalı, Mugla, Türkiye
[2]Mugla Sıtkı Kocman University, Gynecologic Oncology, Mugla, Türkiye

Background

The aim of this video presentation is to demonstrate the surgical technique and feasibility of laparoscopic right salpingo-oophorectomy and bilateral dorsolateral parametrectomy in the management of deep infiltrating endometriosis presenting with a suspicious adnexal mass.

Methods

We present the clinical data and surgical steps of a 38-year-old patient (G1P1) with a 10-year history of endometriosis, suffering from severe pelvic and distal vaginal pain, particularly during menstruation. She had a history of two previous laparoscopic surgeries for endometriosis. Pelvic MRI revealed a 70x60 mm hyperdense lesion with mixed solid and cystic components in the right adnexa (ORADS-3). With a CA-125 level of 290 U/mL and a ROMA score of 10%, a surgical intervention was performed.

Results

The video illustrates the step-by-step surgical procedure, including the restoration of distorted pelvic anatomy, excision of deep endometriotic nodules, and the safe removal of the suspicious adnexal mass. The laparoscopic right salpingo-oophorectomy combined with bilateral dorsolateral parametrectomy was completed successfully.

Conclusions

In cases of recurrent, severe deep endometriosis associated with suspicious adnexal masses, laparoscopic dorsolateral parametrectomy combined with adnexectomy is a feasible and safe surgical approach for both effective disease clearance and symptom relief.

https://player.vimeo.com/video/1189147799?autoplay=1

ESGE35-0420 -
Free Communication

Robotic single-port surgery for deep infiltrating endometriosis with rectal disc resection

Leonardo Nelva Stelio[1], Carmela Quatrale[1], Luca Calzolari[1], Federica Ottolini[1], Pietro Carnevali[2], Federico Spelzini[1]
[1]ASST Grande Ospedale Metropolitano Niguarda, OB/GYN, Milan, Italy
[2]ASST Grande Ospedale Metropolitano Niguarda, Digestive Surgery, Milan, Italy

Background

Deep infiltrating endometriosis (DIE) involving the rectum represents one of the most challenging scenarios in minimally invasive gynecologic surgery. While multiport laparoscopy and robotics are well established, the role of single-port (SP) robotic surgery in combined gynecologic and colorectal procedures remains unexplored. This study aims to demonstrate the feasibility and safety of a pure single-port robotic approach for complex DIE with rectal involvement.

Methods

We report the case of a 39-year-old woman presenting with severe dysmenorrhea, dyspareunia and tenesmus. Preoperative imaging revealed bilateral ovarian endometriomas and a rectouterine ligament nodule of approximately 2 cm with suspected infiltration of the rectal muscularis.

A robotic single-port procedure was performed using the Da Vinci SP system through a single 27 mm transumbilical incision, without additional trocars. Intraoperative findings confirmed bilateral ovarian endometriomas, dense adhesions, complete obliteration of the pouch of Douglas, and a rectouterine ligament endometriotic nodule with infiltration of the rectum.

Surgical procedure included adhesiolysis, bilateral ureterolysis, enucleation of bilateral endometrioma, bilateral salpingectomy and excision of the uterosacral ligament nodule. A discoid rectal resection was performed using a transanal circular stapler (CPH34). Pneumatic leak test was negative, and additional reinforcing sutures were placed.

Results

The procedure was completed entirely through a single umbilical access without the need for additional laparoscopic ports. Estimated blood loss was negligible. No intraoperative or postoperative complications occurred.

The rectal endometriotic nodule was completely excised and intraoperative rectoscopy confirmed adequate resection with intact mucosa prior to stapling and proper anastomotic integrity after resection. The postoperative course was without complications

Conclusions

Robotic single-port surgery enables safe and effective management of complex deep infiltrating endometriosis, including cases requiring rectal discoid resection, without additional abdominal access.

This approach allows precise dissection in confined pelvic spaces while maintaining the advantages of minimal invasiveness. This case shows the feasibility of a multidisciplinary approach in robotic SP surgery for severe endometriosis, offering an alternative to conventional multiport techniques.

https://player.vimeo.com/video/1191615943?autoplay=1

ESGE35-0523 -
Free Communication

ICG-guided ureteral identification and ureterolysis in severe endometriosis

Ece Aksakal[1], Irem Usta Korkut[1], Bulent Urman[1]
[1]American Hospital, Obstetrics and Gynecology, Istanbul, Türkiye

Background

Indocyanine green, commonly known as ICG, is a fluorescent dye widely used in modern surgery for real-time tissue visualization and perfusion assessment. After excitation with near-infrared light, ICG emits fluorescence, allowing enhanced identification of anatomical structures that may otherwise be difficult to distinguish during complex surgical procedures.

In gynecologic surgery, ICG has increasingly been utilized for sentinel lymph node mapping, assessment of tissue vascularization, evaluation of bowel perfusion, and identification of ureters during advanced pelvic surgery. Its application has become particularly valuable in deep infiltrating endometriosis cases, where severe fibrosis and distorted pelvic anatomy may increase the risk of ureteral injury.

Methods

A 45-year-old patient diagnosed with deep infiltrating endometriosis and adenomyosis was scheduled for laparoscopic hysterectomy. Due to multiple previous laparotomies and severe pelvic adhesions, identification and visualization of the ureters up to the level of the pelvic inlet were technically challenging.

Therefore, bilateral ureteral ICG instillation was performed cystoscopically to facilitate intraoperative ureteral identification. Near-infrared fluorescence imaging enabled continuous visualization of both ureters throughout the procedure, allowing safe and effective ureterolysis and dissection during the surgical management of advanced endometriosis.

Results

Ureteral dissection during endometriosis surgery can be technically demanding due to dense adhesions and retroperitoneal fibrosis. In such cases, intraureteral administration of ICG via cystoscopy provides real-time fluorescent visualization of the ureters, facilitating safer and more precise dissection.

Conclusions

In this video, we demonstrate the use of cystoscopic ureteral ICG instillation to enhance ureteral identification during laparoscopic endometriosis surgery. Near-infrared fluorescence imaging enabled continuous visualization of the ureteral pathway throughout the dissection, contributing to improved anatomical orientation and surgical safety.

https://player.vimeo.com/video/1191679447?autoplay=1

ESGE35-0821 -
Free Communication

Atypical presentation of bladder endometriosis during pregnancy complicated by severe pain, hematuria, and atypical eclampsia: a video case report

Berfin Duran[1], Duygu Guzel[2], Mehmet Ali Vardar[2], Bulent Soyupak[3], Nazife Kartal Kara[4], Alper Eken[3]
[1]Cukurova University, Obstetrics and Gynaecology, Adana, Türkiye
[2]Cukurova University, Gynaecologic Oncology, Adana, Türkiye
[3]Acibadem Adana Hospital, Urology, Adana, Türkiye
[4]Acibadem Adana Hospital, Obstetrics and Gynaecology, Adana, Türkiye

Background

Endometriosis is an estrogen-dependent chronic inflammatory disease that is rarely symptomatic during pregnancy. Urinary tract involvement accounts for a small proportion of cases, with bladder endometriosis being the most common form. Clinical presentation during pregnancy may be atypical and can mimic obstetric, infectious, or urologic emergencies, making diagnosis and management particularly challenging. We aimed to present a rare and complex case of bladder endometriosis during pregnancy associated with recurrent severe pain, hematuria, atypical eclampsia, and suspected sepsis.

Methods

A pregnant patient at 19 weeks of gestation was admitted with severe lower abdominal pain and gross hematuria. Initial management consisted of supportive and palliative treatment. Due to recurrent severe pain, cystoscopy was performed, revealing bladder lesions suspicious for endometriosis. Biopsy and cauterization were carried out during the same procedure. Pelvic magnetic resonance imaging demonstrated findings consistent with bladder endometriosis. One week later, the patient was rehospitalized because of persistent severe pain, and diagnostic laparoscopy with repeat cystoscopy was performed. Clinical course, imaging findings, surgical procedures, and obstetric outcomes were retrospectively reviewed and presented as a video case report.

Results

Histopathologic and radiologic findings supported the diagnosis of bladder endometriosis during pregnancy. Despite repeated surgical and supportive interventions, the patient experienced recurrent severe abdominal pain requiring multiple hospitalizations. At 24 weeks of gestation, the patient developed atypical eclampsia accompanied by clinical deterioration, raising suspicion of sepsis. Emergency cesarean delivery was performed because of maternal indications. Intraoperative findings demonstrated an infected and inflammatory appearance of the uterine cavity. The case required multidisciplinary management involving obstetrics, urology, anesthesia, and intensive care teams.

Conclusions

Bladder endometriosis during pregnancy is a rare and challenging condition that may present with severe abdominal pain and hematuria, mimicking obstetric, infectious, or urologic emergencies. Recurrent symptoms during pregnancy should prompt consideration of urinary tract endometriosis in

the differential diagnosis. Early multidisciplinary evaluation and individualized surgical management are essential to optimize maternal outcomes in such complex cases.

https://player.vimeo.com/video/1195646826?autoplay=1

ESGE35-0104 -
Free Communication

Minimally invasive endometrial cancer screening: cytology and methylation beat traditional imaging in high-risk women

Jiaqi Li[1], *Bingxin Cai*[2], *Yu-Ligh Liou*[1], *Qinping Liao*[1]
[1]*Beijing Tsinghua Changgung Hospital, Department of Obstetrics and Gynaecology, Beijing, China*
[2]*Department of Obstetrics and Gynaecology, Gansu Provincial Maternity and Child-care Hospital, Lanzhou, China*

Background

Endometrial cancer (EC) demonstrates a high incidence in postmenopausal women, being the most prevalent gynecologic malignancy in developed regions. However, current diagnostic methods face significant limitations. Transvaginal ultrasound (TVS), while widely adopted as a first-line tool, exhibits low specificity—frequently resulting in unnecessary invasive procedures such as dilation and curettage (D&C), which entail risks of patient discomfort, sampling errors, and elevated healthcare costs. This study aimed to compare the clinical performance of two minimal-invasive alternatives—endometrial brushing-based liquid cytology and cervical exfoliated cell CDO1/CELF4 gene methylation testing—for EC detection in postmenopausal women. Using histopathology as the gold standard, we evaluated their feasibility as outpatient screening tools to improve diagnostic accuracy while reducing reliance on invasive interventions.

Methods

This study analysed 586 postmenopausal women with valid histopathological comparisons. Endometrial cells were collected using a specialized endometrial brush and processed via liquid-based cytology. Additionally, cervical exfoliated cells from 552 women with postmenopausal bleeding were evaluated for CDO1/CELF4 methylation levels by quantitative PCR. All results were compared with histopathological findings from hysteroscopic biopsy or dilation and curettage (D&C). Diagnostic performance (sensitivity, specificity) of the novel methods was benchmarked against traditional transvaginal sonography (TVS) and histopathology.

Results

Endometrial cytology demonstrated a sensitivity of 75.9% and specificity of 83.3% for detecting EC in 567 comparable cases. The inadequate sample rate for cytology was significantly lower than for D&C (4.1% vs. 25.8%, $p < 0.001$). In contrast, CDO1/CELF4 methylation testing achieved superior performance: sensitivity 87.5%, specificity 95.9% in 552 samples, with all type II EC cases (n=6) detected. The AUC for methylation testing was 0.917, outperforming cytology. For traditional TVS (endometrial thickness ≥5 mm), sensitivity was 72.5% with low specificity (43.9%), and AUC 0.672, highlighting its limitations in reducing false positives compared to the novel methods.

Conclusions

Endometrial cytology and cervical CDO1/CELF4 methylation testing demonstrated superior clinical performance compared to traditional transvaginal sonography (TVS) and invasive histopathology

(hysteroscopic biopsy or D&C). These methods are simpler to implement and better tolerated by patients, making them suitable as first-line screening tools for postmenopausal women with bleeding. Further large-scale prospective studies are needed to validate their long-term efficacy and integration into routine clinical pathways.

ESGE35-0400 -
Free Communication

A novel platelet-rich plasma (PRP) injection protocol for endometrial regeneration in infertile patients

Danilo Borrelli[1], Virginia Foreste[1], Sabrina Reppuccia[1], Vincenzo Marrone[1], Ida Strina[1], Brunella Zizolfi[1]
[1]University of Naples Federico II, Public Health, Naples, Italy

Background

The aim of the study is to evaluate the effects of a novel platelet-rich plasma (PRP) protocol combining hysteroscopically guided subendometrial PRP infiltration followed by intrauterine PRP infusion on endometrial ultrasonographic characteristics and reproductive outcomes in infertile patients with refractory thin endometrium (TE) and/or recurrent implantation failure (RIF).

Methods

This prospective, interventional, non-randomized study was conducted at a tertiary referral center between June 2023 and December 2025. Infertile patients undergoing frozen embryo transfer (FET) were enrolled, including women with refractory TE (endometrial thickness <7 mm despite standard therapy) and/or RIF. All patients underwent hysteroscopic subendometrial PRP infiltration during the proliferative phase of the cycle preceding embryo transfer. A total of 4 mL of autologous PRP was injected into the subendometrial layer of the anterior, posterior, and lateral uterine walls under direct hysteroscopic visualization. In the subsequent FET cycle, 2 mL of PRP was administered via intrauterine infusion between cycle days 10 and 14. Endometrial characteristics, including endometrial thickness (EMT), were assessed by transvaginal ultrasound before and after each PRP procedure. The primary outcome was the change in EMT following PRP infiltration and infusion. Secondary outcomes included clinical pregnancy rate (CPR), live birth rate (LBR), and miscarriage rate (MR).

Results

Fifty-nine patients were included: 29 with TE (Group A) and 30 with RIF (Group B). The hysteroscopic procedure was technically feasible in all cases, with a mean duration of approximately 3.5 minutes and no reported complications. In Group A, EMT significantly increased following both PRP infiltration and infusion. Mean EMT increased from 4.50 ± 1.30 mm before infiltration to 6.23 ± 1.81 mm after the procedure ($p < 0.0001$), and from 5.84 ± 0.98 mm before infusion to 7.86 ± 1.41 mm after infusion ($p < 0.0001$). Reproductive outcomes in this group showed a clinical pregnancy rate of 58.6% (17/29), a live birth rate of 41.4% (12/29), and a miscarriage rate of 17.2% (5/29). In Group B, EMT also significantly increased after treatment. Mean EMT increased from 7.18 ± 1.41 mm to 9.50 ± 2.18 mm after PRP infiltration ($p < 0.0001$), and from 8.17 ± 1.91 mm to 10.54 ± 2.02 mm after infusion ($p < 0.0001$). In this group, CPR was 30% (9/30), LBR was 13.3% (4/30), and MR was 13.3% (4/30), with one ongoing pregnancy.

Conclusions

The sequential administration of hysteroscopically guided subendometrial PRP infiltration followed by intrauterine PRP infusion was associated with a significant improvement in endometrial thickness and encouraging reproductive outcomes in patients with refractory TE and RIF. This combined regenerative strategy may enhance endometrial receptivity beyond conventional therapies. Larger randomized controlled trials are needed to confirm the efficacy of this protocol and to identify the patients most likely to benefit from PRP-based treatments.

ESGE35-0505 -
Free Communication

Safety and complications of advanced laparoscopic procedures in gynaecologic oncology: a single-centre prospective cohort

Stamatios Petousis[1], *Chrysoula Margioula-Siarkou*[1], *Stefanos Flindris*[1], *Aristarchos Almperis*[1], *Emmanouela-Aliki Almperi*[1], *Konstantinos Dinas*[1]
[1]*Aristotle University of Thessaloniki, 2nd Department of Obstetrics and Gynaecology, Thessaloniki, Greece*

Background

Laparoscopic surgery increasingly consists the main surgical approach in a wide spectrum of gynaecologic oncology procedures. Main objective of the present study was to assess feasibility, perioperative outcomes and predictors of complications in laparoscopic gynecological oncological procedures.

Methods

A prospective cohort study was conducted regarding the period 2021-2025. All kinds of laparoscopic procedures for gynecological malignancies were included in the present study. The primary outcomes of the analysis were laparoscopic conversion rate and complication rates according to the Clavien-Dindo classification. Subgroup analyses concerned endometrial cancer, cervical cancer, and apparent early-stage ovarian cancer staging. Multivariable logistic regression was performed to identify predictors of major complications (≥ grade II).

Results

A total of 227 laparoscopic procedures with complete data recorded were performed during the study period. Overall conversion rate was 2.2% (5/227). Major complications occurred in 3.5% of interventions and minor complications in 6.2%. Converted cases had greater blood loss (450±100 vs 170±60 mL; p=0.011), longer hospitalization (5.1±1.2 vs 2.3±0.6 days; p=0.018), and a higher rate of ICU admission (50% vs 1.6%; p=0.003). Independent predictors of major complications were operative time >180 min (OR 3.12; 95% CI 1.45–6.71; p=0.004), blood loss >200 mL (OR 2.89; 1.32–6.12; p=0.007), and conversion (OR 9.23; 2.61–32.64; p<0.001), while patients' age > 65 years and final cancer stage were not demonstrated as significant predictors.

Conclusions

Advanced laparoscopy performed by well-trained gynecologic oncologists achieves low conversion and morbidity rates. Operative efficiency and conversion avoidance are key parameters for minimizing complications while delivering high-quality oncologic care.

ESGE35-0827 -
Free Communication

Use of Linzagolix for endometriosis, fibroids and heavy menstrual bleeding: a single-centre retrospective cohort study.

Prince Osam Duodu[1], Rafiq Ammar[1], Luke Martin[2], Yasmin Hussein[1], Kazi Mahmuda Akter[1], Rana Ahmed[1]
[1]University Hospital of North Midlands, Obstetrics and Gynaecology, Stoke-On-Trent, United Kingdom
[2]Keele Medical University, faculty of medicine, Stoke-On-Trent, United Kingdom

Background

To evaluate real-world use of Linzagolix in a tertiary gynaecology unit and assess its effectiveness in managing symptoms related to endometriosis, fibroids and heavy periods. Also to look at the patient experience in terms of common side effects, use of add back therapy.

Methods

We performed a retrospective review of all patients seen by the gynaecology team at University Hospital of North Midlands NHS Trust who were prescribed Linzagolix in last two years and had at least three months of therapy and continued follow-up. Eligible patients were identified via hospital pharmacy records, and electronic and paper notes were reviewed for demographics, indication and presenting symptoms. Patients were subsequently contacted by telephone and completed a structured questionnaire on symptom change, side effects, HRT use and global satisfaction. Data were entered into a predefined proforma and analysed descriptively.

Results

117 patients were identified to have been prescribed Linzagolix. 103 had taken it for more than three months and responded for telephone interview and were included in the study. Mean age was 37.3 years and mean body mass index 30.4 kg/m². Indications were endometriosis in 61.7%, fibroids in 25.0% and HMB without structural pathology in 7 11.7% patients. Mean treatment duration was 5.7 months (range 3–12). Among patients with evaluable follow-up, amenorrhoea was achieved in 82.5% and HMB improved in 55.4%. Hot flushes or night sweats occurred in 69.5%, mood changes in 64.4% and vaginal dryness in 30.5%. Add-back therapy was used by 61.0%, most commonly transdermal oestrogen patches.

Conclusions

In this single-centre cohort, Linzagolix was used predominantly for endometriosis and fibroid-related symptoms and achieved high rates of amenorrhoea and clinically meaningful improvement in HMB at a median duration of just over six months. Vasomotor and mood-related side effects were common and more than half of patients required HRT, underscoring the importance of proactive counselling and structured follow-up when prescribing this class of agents.

ESGE35-0026 -
Free Communication

Reality bites: vNOTES with a twist

Aya Mohr-Sasson[1], Alvaro Montealegre[1], Randa Jalloul[1], Asha Bhalwal[1]
[1]McGovern Medical School at The University of Texas Health Science Center, Department of Obstetrics- Gynaecology & Reproductive Sciences, Houston, USA

Background

Robotic vaginal natural orifice transluminal endoscopic surgery (vNOTES) represents an innovative advancement in minimally invasive gynecologic surgery, combining the benefits of vaginal access with enhanced visualization and instrument dexterity. As an emerging technique, it is associated with distinct intraoperative challenges that require adaptation and experience, underscoring the importance of sharing practical strategies and disseminating technical expertise. The aim of this video is to demonstrate a step-by-step robotic vaginal natural orifice transluminal endoscopic surgery (vNOTES) hysterectomy using a complete vaginal approach, with emphasis on techniques to manage and overcome intraoperative challenges.

Methods

This surgical video presents a 46-year-old G2P2002 with a history of two prior vaginal deliveries, who presented with abnormal uterine bleeding. Imaging revealed a 9.6 cm uterus with multiple fibroids and endometrial polyp. The patient underwent a robotic-assisted vNOTES total hysterectomy with bilateral salpingectomy via a complete vaginal approach.

Results

The video highlights key intraoperative challenges encountered during robotic vNOTES, including instrument positioning, ring misalignment, completion of the colpotomy under direct visualization, bleeding control, and limited access due to instrument length constraints. Practical techniques to optimize exposure, maintain hemostasis, and overcome technical difficulties are demonstrated. The procedure was completed successfully without intraoperative complications.

Conclusions

Mastery of vaginal access and the application of adaptive, strategic problem-solving enable surgeons to overcome intraoperative challenges encountered during Robotic vNOTES hysterectomy. This video provides practical insights to support wider adoption and optimize surgical outcomes.

https://player.vimeo.com/video/1183862025?autoplay=1

ESGE35-0620 -
Free Communication

At the crossroads of haematology and gynaecology: optimising open myomectomy in sickle cell disease

Justina Igwe[1], Dhanuson Dharmasena[1], Guldzhan Vorona[1]
[1]Whittington Health NHS Trust, Obstetrics and Gynaecology, London, United Kingdom

Background

The coexistence of symptomatic uterine fibroids and sickle cell disease (SCD) creates a compounded perioperative risk profile spanning gynaecological, haematological, and anaesthetic domains. There remains limited guidance on the optimal perioperative management of myomectomy in this high-risk population, and an unmet need for a structured, reproducible approach to training clinicians in its complexity.

Methods

We present a case of open myomectomy in a 37-year-old nulliparous woman with SCD, symptomatic multi-fibroid uterus, and heavy menstrual bleeding, with primary fertility aspirations. MRI confirmed a markedly enlarged uterus reaching the umbilicus, with haemorrhagic degeneration and adenomyosis. Pre-operative optimisation included medical management of heavy menstrual bleeding and exchange transfusion completed three days prior to surgery. Individualised consent encompassed haemorrhage, organ injury, fibroid recurrence, and conversion to hysterectomy. Formal multidisciplinary input from haematology and high-risk anaesthetics informed all stages of the perioperative plan. Intra-operatively, a layered haemostatic strategy was employed comprising intramyometrial terlipressin, mechanical tourniquet application, warmed IV fluids, and warm wet packs to maintain uterine temperature and prevent sickling.

Results

Exchange transfusion achieved a pre-operative haemoglobin of 98g/L, reflecting the physiological ceiling in this patient group. Over 30 fibroids were successfully removed. A significant intra-operative challenge was differentiating discrete fibroid from adenomyotic tissue, where the absence of a clear pseudocapsule required meticulous sharp dissection. Uterine conservation was achieved with no conversion to hysterectomy and no gynaecological complications. Post-operatively, the patient experienced a delayed transfusion reaction, managed in collaboration with haematology, underscoring the importance of sustained MDT vigilance beyond the operative field.

Conclusions

Safe myomectomy in sickle cell disease demands coordinated MDT planning and haematological optimisation within realistic physiological limits. Beyond the surgical outcome, this case offers a valuable training paradigm. The trainee who follows this patient's full journey develops longitudinal, anticipatory clinical reasoning rather than isolated technical skill, transitioning from reactive technician to anticipatory clinician.

https://player.vimeo.com/video/1191718784?autoplay=1

ePOSTER PRESENTATIONS

ESGE35-0039 - P001
ePoster Presentations

Impact of a Multisensory Clinical Setting on Pain and Patient Experience During Office Hysteroscopy: The VISION-HYST Randomized Controlled Pilot Trial

Alessandro Messina[1], Paolo Alessi[1], Giovanni Lipari[1], Giulia Parpinel[1], Livio Leo[2], Bianca Masturzo[1]
[1]Degli Infermi Hospital, Division of Obstetrics & Gynaecology, Biella, Italy
[2]Beauregard Hospital, Division of Obstetrics & Gynaecology, Aosta, Italy

Background

Pain and anxiety remain major barriers to the tolerability and widespread adoption of office hysteroscopy, despite advances in minimally invasive techniques and the use of nitrous oxide (N_2O) analgesia. Non-pharmacological interventions targeting the clinical environment may enhance patient experience. The objective of this study is to evaluate the impact of a multisensory clinical setting, including visual environmental distraction, on pain perception during operative office hysteroscopy under nitrous oxide analgesia.

Methods

This randomized, parallel-group pilot trial enrolled 50 women undergoing operative office hysteroscopy in an outpatient setting. Participants were allocated to standard care with N_2O (control group) or N_2O combined with a multisensory intervention including a wall-mounted “virtual window” displaying relaxing visual content (intervention group). The primary outcome was procedural pain assessed by Visual Analogue Scale (VAS). Secondary outcomes included procedural completion and referral to the operating room. Between-group differences were analysed using appropriate statistical tests.

Results

The multisensory setting was associated with a significant reduction in perceived pain compared to standard care ($p < 0.001$). The effect remained consistent across different hysteroscopic techniques and was particularly evident in multiparous women. No significant differences were observed in procedural completion rates or need for referral to the operating room. No adverse events related to the intervention were reported.

Conclusions

The addition of a simple visual environmental distraction to standard nitrous oxide analgesia significantly reduces pain during office hysteroscopy. This low-cost, easily implementable approach may improve patient experience and support the broader adoption of outpatient hysteroscopic procedures. Larger studies are warranted to confirm these findings.

ESGE35-0022 - P002
ePoster Presentations

The Role of Diagnostic Hysteroscopy in Evaluating Endometrial Pathology in Breast Cancer Patients on Tamoxifen Therapy: A Multicentre Retrospective Analysis

Kwang Beom Lee[1], *Jong-Min Lee*[2]
[1]*Gachon University Gil Medical Center- Gachon University College of Medicine, Obstetrics and Gynaecology, Incheon, Korea- Republic Of*
[2]*Kyung Hee University Hospital at Gangdong- Kyung Hee University College of Medicine, Obstetrics and Gynaecology, Seoul, Korea- Republic Of*

Background

Tamoxifen is a fundamental endocrine therapy for breast cancer, yet its pro-estrogenic effect on the uterus often leads to endometrial pathologies or "pseudo thickening" on ultrasound, creating a diagnostic dilemma. This research was initiated to address the clinical need for a more definitive, minimally invasive diagnostic approach that avoids the limitations of ultrasound while ensuring patient safety. We aim to assess the efficacy, safety, and histopathological outcomes of diagnostic hysteroscopy performed under mask anesthesia in breast cancer patients on Tamoxifen presenting with abnormal uterine bleeding (AUB) or asymptomatic thickened endometrium.

Methods

A multicentre retrospective observational study was conducted jointly by Gachon University Gil Medical Center and Kyung Hee University Hospital at Gangdong. A total of 143 breast cancer patients, all of whom were receiving active Tamoxifen therapy, underwent diagnostic hysteroscopy under mask anesthesia between January 2022 and December 2025. Data regarding the duration of Tamoxifen use, endometrial thickness measured by transvaginal ultrasound (TVUS), hysteroscopic visual findings, and final histopathology from targeted biopsies were collected and analysed.

Results

All 143 patients included in the study from both institutions were on active Tamoxifen therapy. Hysteroscopy under mask anesthesia was successfully completed in a day surgery setting for all patients (100%) without significant anesthesia-related or surgical complications. The most prevalent hysteroscopic finding was atrophic endometrium (80.6%), followed by endometrial polyps (15.0%) and endometrial hyperplasia (3.0%). Hysteroscopic targeted biopsy diagnosed endometrial carcinoma in 2 patients (1.4%). The sensitivity and specificity of diagnostic hysteroscopy for detecting premalignant or malignant lesions were 96.5% and 92.3%, respectively, demonstrating superior diagnostic accuracy compared to TVUS alone.

Conclusions

Diagnostic hysteroscopy under mask anesthesia with targeted biopsy is a safe, highly accurate, and essential minimally invasive modality for evaluating the uterine cavity in breast cancer patients treated with Tamoxifen. This joint study confirms that it provides optimal patient comfort, precise direct visualization, and accurate tissue.

ESGE35-0029 - P003
ePoster Presentations

Pelvic Endometriosis: A Case Series of Canal of Nuck, Rectus muscle and Umbilical Endometriosis

Coreen Kwai Ling Soh[1], Sobha Ramakoti[2], Hannah Ribbans[2], David Bowden[3], Andrew D Abbott[2], Wafa Osman[2]
[1]Countess of Chester Hospital NHS Foundation Trust, Gynaecology, Liverpool, United Kingdom
[2]Countess of Chester Hospital NHS Foundation Trust, Gynaecology, Chester, United Kingdom
[3]Countess of Chester Hospital NHS Foundation Trust, Colorectal, Chester, United Kingdom

Background

Extra-pelvic endometriosis is an uncommon manifestation of endometriosis and often presents a diagnostic challenge due to its atypical location and non-specific symptoms. We present a case series of four patients with rare extra-pelvic endometriosis involving the canal of Nuck (n=2), rectus muscle and sheath (n=1), and umbilicus (n=1), highlighting clinical presentation, diagnostic pathway, surgical management, and outcomes.

Methods

This is a retrospective case series of four women presenting to a tertiary gynaecology unit with cyclical pain and/or swelling in extra-pelvic locations. Clinical evaluation included detailed menstrual history and physical examination. Imaging modalities included ultrasound and MRI where indicated. In all cases, ultrasound-guided core biopsy was undertaken prior to definitive surgical planning to exclude other benign and malignant conditions. Following multidisciplinary discussion, patients underwent complete surgical excision of the lesions. Histopathological confirmation of endometriosis was obtained in all cases. Postoperative follow-up assessed symptom resolution and recurrence.

Results

The two patients with canal of Nuck endometriosis presented with painful inguinal swelling, initially suspected to be inguinal hernia. Imaging suggested soft tissue lesions along the round ligament pathway. Both underwent complete surgical excision with no perioperative complications. The patient with rectus muscle and sheath endometriosis presented with a palpable abdominal wall mass associated with cyclical pain, with MRI demonstrating a well-defined lesion within the rectus abdominis muscle. Wide local excision with clear margins was performed. The umbilical endometriosis case presented with cyclical umbilical pain and discoloration without prior laparoscopic port placement. Surgical excision of the umbilical lesion was undertaken. Histology confirmed endometriosis in all four cases. At follow-up, all patients reported significant symptom resolution with no early recurrence observed.

Conclusions

Extra-pelvic endometriosis, although rare, should be considered in women presenting with cyclical pain and mass lesions in atypical locations, particularly along embryological pathways such as the round ligament and abdominal wall. Pre-operative tissue diagnosis can aid exclusion of alternative

pathology and optimise surgical planning. Complete surgical excision remains the cornerstone of management. Increased awareness may prevent misdiagnosis and delayed treatment.

ESGE35-0182 - P004
ePoster Presentations

Decision Making for Robotic-Assisted Surgery Versus Open Surgery in Endometrial Cancer: A Retrospective Cohort Study

Keshuo Hu[1,2], Dimitrios I. Bolovis[1,3], Cosima V. M. Brucker[1]
[1]Paracelsus Medical Private University- Nuremberg General Hospital, Department of Gynaecology and Obstetrics, Nuremberg, Germany
[2]The Affiliated Hospital of Beihua University, Department of Breast Surgery, Jilin, China
[3]Henry Dunant Hospital, 2nd Department of Gynaecology, Athens, Greece

Background

To identify the applicable patient characteristics for robotic and open surgery in endometrial cancer, and to provide evidence-based and quantifiable references for formulating individualized clinical surgical decision-making.

Methods

This study enrolled patients with endometrial cancer who underwent surgery at the Department of Gynaecology, Klinikum Nord Nürnberg, Germany, from January 2020 to September 2025. The study was designed in two parts with distinct focus areas. Part 1 enrolled 173 patients with early-stage endometrial cancer to compare perioperative outcomes between robotic-assisted surgery (RAS, n=105) and open surgery (OS, n=68), utilizing univariate analysis (Mann-Whitney U and Chi-square tests) to screen for potential clinical predictors of the surgical approach. Part 2 performed a stratified analysis within an expanded RAS cohort (n=109 for preliminary data) using a 3×2 factorial stratification matrix based on BMI (thresholds: 30 and 35 kg/m², respectively) and uterine volume (threshold: 82.5 cm³). Non-parametric tests were employed to compare perioperative outcomes across the resulting subgroups.

Results

Preliminary data from Part 2 indicate significant differences in operative duration across the anatomical subgroups ($p = 0.049$). Notably, patients with BMI 30.01–35.00 kg/m² and uterine volume < 82.5 cm³ (Group 3) exhibited the highest surgical efficiency, with a median operative time of 65.50 minutes (IQR: 55.25–83.50). Other secondary outcomes, including hemoglobin loss, numeric rating scale (NRS), and complications classified according to Clavien-Dindo showed no significant inter-group differences ($p > 0.05$), confirming the stability and safety of the robotic platform across varied patient profiles. Data analysis for Part 1 is currently underway.

Conclusions

This study examines the clinical applicability of RAS through anatomical stratification. Preliminary findings identify a potential optimal intervention window at BMI 30.01–35.00 kg/m² and uterine volume < 82.5 cm³. By integrating comparative data from Part 1, this study will further provide comprehensive clinical evidence to refine the selection criteria between robotic and open surgery. As

the study is currently ongoing, these preliminary results may be subject to minor adjustments as the sample size expands to enhance the overall statistical power.

ESGE35-0646 - P005
ePoster Presentations

Optimising IVF referral pathways: Lessons from a clinical audit of practice and patient communication

Sowmiya Kalyana Sundaram[1], Baydaa Abdulrahim[1]
[1]lister hospital, Gynaecology, Stevenage, United Kingdom

Background

To evaluate compliance with local eligibility criteria for in vitro fertilisation (IVF) referrals in Bedford and Hertfordshire regions, with emphasis on adequacy of ovulation induction and quality of patient counselling prior to referral.

Methods

A retrospective audit of IVF referrals from January 2025 to March 2026 was conducted using electronic patient records. data collected included age, body mass index (BMI), smoking status, ovarian reserve testing, GP registration, prior treatments including ovulation induction, and referral outcomes. 15 patients from Bedford and 24 from Hertfordshire were analysed. Compliance was assessed against local integrated care board criteria with a target of 100%.

Results

In the Bedford cohort, 87% (13/15) of referrals met eligibility criteria. Most patients fulfilled age, BMI, and smoking requirements; however, ovarian reserve assessment was incomplete in a proportion of cases, and GP registration criteria were not met in 13%.In the Hertfordshire cohort, only 67% (16/24) of referrals met eligibility criteria, with 33% (8/24) deemed inappropriate. The main contributing factors included failure to complete adequate ovulation induction treatment prior to referral, not meeting BMI requirements, and GP registration issues. Several patients required further ovulation induction following referral, with at least one achieving pregnancy after optimisation of treatment. Communication gaps were identified across both cohorts. Key eligibility criteria, including BMI thresholds, GP registration requirements, and the need for completion of ovulation induction, were not consistently communicated at initial consultation. this resulted in rejected referrals, delays in treatment, and patient dissatisfaction, including formal complaints.

Conclusions

Inappropriate IVF referrals remain common, particularly in the Hertfordshire cohort, and are largely driven by suboptimal pre-referral management and inconsistent patient counselling. Failure to complete adequate ovulation induction treatment prior to referral represents a missed opportunity to achieve pregnancy without IVF and contributes to inefficient use of specialist fertility services. Implementation of a structured referral proforma and standardised counselling pathway is likely to improve referral appropriateness, reduce delays, and enhance patient experience. Re-audit is recommended following intervention.

ESGE35-0099 - P006
ePoster Presentations

Laparoscopic Plication of the Utero-Ovarian Ligament to Prevent Recurrent Torsion in Massive Ovarian Edema: A Case Report

Teppei Suzuki[1], Akira Aoyama[1], Yuriko Sano[1], Maki Goto[1]
[1]Okazaki City Hospital, Obstetrics and Gynaecology, Aichi, Japan

Background

Massive ovarian edema is a rare benign condition characterized by diffuse stromal edema and ovarian enlargement, most commonly reported in young women. Ovarian torsion has been described in association with this condition. When ovarian preservation is attempted, prevention of recurrent torsion is an important concern; however, no standard preventive procedure has been established. Oophoropexy to the uterus or pelvic peritoneum and ovarian volume reduction by partial resection or capsular incision have been reported. In contrast, plication of the utero-ovarian ligament as a preventive measure against recurrent torsion is rarely described. We report a case of ovarian torsion due to massive ovarian edema treated by laparoscopic detorsion and plication of the utero-ovarian ligament.

Methods

A 19-year-old nulligravid woman, who had been receiving progestin therapy for amenorrhea due to polycystic ovary syndrome for three years, presented to our emergency department with left lower abdominal pain. Contrast-enhanced computed tomography showed a markedly enlarged left ovary measuring 105 mm with a whirl sign, suggesting ovarian torsion. Transvaginal ultrasonography demonstrated an enlarged ovary with heterogeneous low echogenicity, and malignancy could not be excluded. Therefore, contrast-enhanced magnetic resonance imaging was performed. The enlarged left ovary showed peripheral cystic structures suggestive of follicles and high signal intensity of the stroma on T2-weighted imaging. Based on these findings, torsion associated with massive ovarian edema was suspected, and emergency laparoscopic surgery was performed on the same day.

Results

Laparoscopy revealed a markedly enlarged, dark-purple left ovary twisted 540 degrees. After detorsion, the colour of the ovary improved, and ovarian preservation was selected. To prevent recurrent torsion, fixation of the ovary to the pelvic peritoneum was initially attempted; however, the edematous ovarian tissue was fragile and difficult to suture securely. Therefore, the utero-ovarian ligament was plicated laparoscopically to reduce ovarian mobility. The postoperative course was uneventful, and the patient was discharged on postoperative day 3. At 6 months after surgery, the enlarged ovary had decreased in size, and no recurrent torsion was observed.

Conclusions

Massive ovarian edema often affects young women, and ovarian-preserving surgery is desirable when torsion occurs. Preventing recurrent torsion should be considered, but direct oophoropexy may be

difficult because the edematous tissue is fragile. Laparoscopic plication of the utero-ovarian ligament may be a useful and feasible option to prevent recurrent torsion in massive ovarian edema.

ESGE35-0183 - P009
ePoster Presentations

The effectiveness of GnRH receptor antagonists for the management of endometriosis related pelvic pain

Jessica Clements[1], *Eilis Higgins*[1], *Benjamin Twist*[1]
[1]*Wirral University Teaching Hospital, Gynaecology, Wirral, United Kingdom*

Background

GnRH receptor antagonists Relugolix (in combination with estradiol and norethisterione acetate) and Linzagolix have now been made available to use on the NHS based on NICE guidance and the results of the Spirit trial. This audit reviewed the use of the medications in a tertiary endometriosis clinic to assess if they match the expected compliance of a 75% improvement in moderate to severe dysmenorrhoea and a 50% improvement in non menstrual pelvic pain. The audit aimed to demonstrate if they are a useful pharmacological treatment for endometriosis in those where other treatments have not been beneficial.

Methods

A retrospective audit of 39 patients who were seen in a specialist endometriosis clinic between August to December 2025 and commenced on a GnRH receptor antagonist. Data was collected from clinical notes looking into patient profile, symptoms, previous treatment and diagnosis, as well as response to treatment and acceptability for continuing long term. Results included data from 34, patients as 5 did not attend follow up or are yet to be followed up, and 1 never started treatment.

Results

35 patients were commenced on Relugolix, and 4 on Linzagolix. Patients ranged in age from 19 to 51 and had an average age of 34. 34 patients had a diagnosis of endometriosis and 3 had adenomyosis; 27 of those were confirmed by histological findings or MRI. 72% of the patients had dysmenorrhoea, and 62% had non menstrual related pelvic pain.
53% of the patients found an improvement in symptoms, 28% had some improvement and 19% had no improvement in symptoms. Of the 53% that had an improvement, 76% wished to continue treatment The remaining patients stopped due to side effects and were offered alternative treatment options. Overall, 53% of the patients wished to continue treatment. The most common side effects seen were low mood or mental health issues, unacceptable bleeding and headaches.

Conclusions

Our results demonstrated a 46% improvement in moderate to severe dysmenorrhoea and a 45% improvement in non menstrual pelvic pain. Although not meeting the outcomes expected by NICE, 53% of the patients did wish to continue treatment, therefore showing GnRH receptor antagonists can be a useful management option of endometriosis related pelvic pain. Discontinuation of treatment was driven by side effects, rather than lack of clinical effectiveness. It was also seen that the majority of patients had already tried multiple treatment options which had also failed to work, highlighting the complex and treatment resistant nature of menstrual and non menstrual pelvic pain.

ESGE35-0098 - P010
ePoster Presentations

A Rare Twist on Acute Abdomen: Spontaneous Torsion of a Pedunculated Fibroid in a Nulliparous 27-Year-Old

Ping Tan[1], Stephania Drymiotou[1], Deepali Sinha[1]
[1]Newham University Hospital, Obstetrics and Gynaecology, London, United Kingdom

Background

Uterine fibroids are common benign tumours affecting women of reproductive age. However, torsion of a pedunculated fibroid is rare, with an estimated incidence of 0.25%. Prompt diagnosis is essential because of the risk of ischaemia, necrosis, peritonitis, and sepsis. We report a rare case of torsion of a large broad-based pedunculated fibroid presenting with acute abdominal pain in a 27-year-old nulliparous woman.

Methods

A 27-year-old nulliparous woman presented with a 3-day history of severe abdominal pain. Initial investigations demonstrated a negative hCG, mildly elevated white cell count, and CRP of 141 mg/L. On examination, she had a distended abdomen with the uterus palpable to approximately 34 weeks' size. During admission, she developed pyrexia with worsening inflammatory markers. CT imaging of the abdomen and pelvis demonstrated multiple large fibroids, including a 14.8 × 8.4 × 12.2 cm broad-based pedunculated fibroid in the left lumbar quadrant with markedly reduced enhancement and surrounding fat stranding, suspicious for torsion. MRI confirmed a markedly enlarged multifibroid uterus with a large left-sided pedunculated fibroid measuring 14.2 × 11.4 cm, showing poor contrast enhancement and features concerning for vascular compromise. Associated findings included free fluid, bladder compression, and mild bilateral fullness of the pelvicalyceal systems.

Results

The patient underwent diagnostic laparotomy via Pfannenstiel incision. Intraoperatively, the uterus was mobile and markedly enlarged with multiple fibroids including three pedunculated fibroids measuring 14 cm each. They were located at the posterior fundus, right anterior, and left anterior aspects of the uterus. Torsion of the left anterior fibroid was identified, associated with dextrorotation of the uterus. The left fallopian tube appeared congested secondary to the torsion; however, both ovaries and fallopian tubes were viable at the end of the procedure. All fibroids were successfully removed, and normal uterine anatomy was restored. The total combined weight of the resected fibroids was 2.5 kg. The postoperative course was uncomplicated. Histopathological analysis confirmed leiomyoma with areas of infarction.

Conclusions

Torsion of a pedunculated fibroid is an uncommon but important differential diagnosis in women presenting with acute abdominal pain and a known or suspected fibroid uterus. This case highlights the diagnostic challenge posed by non-specific symptoms and distorted pelvic anatomy in large

multifibroid uteri. Early surgical intervention is essential when fibroid torsion is suspected to prevent necrosis, peritonitis, and sepsis. Broad-based pedunculated fibroids may still undergo torsion despite their relatively wide attachment, and clinicians should maintain a high index of suspicion in acute presentations.

ESGE35-0124 - P011
ePoster Presentations

Robotic single-site robotic hysterectomy versus multiport robotic hysterectomy in benign condition : A retrospective comparison of clinical and surgical outcomes

Sungyob Kim[1]
[1]*Jeju National University Hospital, Gynaecology, Jeju, Korea- Republic Of*

Background

In gynaecology, the paradigm of surgical intervention has shifted significantly toward minimally invasive surgery (MIS) to improve patient recovery and aesthetic outcomes. While multiport robotic surgery (MRS) has long been considered the standard approach for treating benign gynecologic diseases, the emergence of robotic single-site and single-port (SP) platforms has further pushed the boundaries of MIS, .Despite the growing adoption of single-site and single-port robotic surgery, The objective of this study is to evaluate and compare the perioperative outcomes of robotic single-port (SP) hysterectomy and conventional multiport robotic hysterectomy in patients with benign gynecologic diseases

Methods

By analysing a dedicated cohort of approximately 40 cases per group, we aim to investigate key clinical indicators, including operative time, estimated blood loss (EBL), postoperative haemoglobin change, and the incidence of postoperative complications. Through this comparative analysis, we seek to provide more refined clinical evidence that can guide surgical decision-making and optimize the selection of robotic platforms for benign gynecologic interventions. All statistical analyses were conducted to compare baseline characteristics and outcomes between groups. Continuous variables were first assessed for normality using graphical methods and Shapiro–Wilk test. As most variables did not follow a normal distribution, and between-group comparisons were performed using the Mann–Whitney U test. Categorical variables were presented as frequencies and percentages, and differences between groups were assessed using the chi-square test. Variables with missing data were analysed using available cases only; observations with missing values for a given variable were excluded from the corresponding analysis. A two-sided p-value of <0.05 was considered statistically significant. All analyses were performed using SAS software (version 9.4; SAS Institute Inc., Cary, NC, USA).

Results

After adjusting for BMI, age, and uterine weight, surgical type was not significantly associated with postoperative complications (multi-port vs. one-port: OR, 1.247; 95% CI, 0.409–3.798; p = 0.698). None of the other variables, including BMI (OR, 1.079; 95% CI, 0.958–1.216; p = 0.210), age (OR, 0.962; 95% CI, 0.878–1.054; p = 0.405), and uterine weight (OR, 0.999; 95% CI, 0.997–1.001; p = 0.337), were significantly associated with postoperative complications.

Conclusions

The present study sought to evaluate the clinical feasibility and surgical outcomes of the robotic single-port (SP) platform compared to conventional multiport robotic surgery (MRS) in benign gynecologic diseases. Our analysis revealed that the SP approach not only matches the established gold standard but, in several key metrics, offers superior perioperative efficiency.

ESGE35-0321 - P013
ePoster Presentations

Struma Ovarii Mimicking Epithelial Ovarian Cancer: A Diagnostic Pitfall in Postmenopausal Women : A Case Report

Yasmine Chiba[1], *Hadfi Safa*[1], *Hfaiedh Ines*[1], *Tlili Eya*[1], *Bouassida Mehdi*[1], *Mourali Mechaal*[1]
[1]*Habib Bougatfa University Hospital in Bizerte, Department of Obstetrics and Gynaecology, Bizerte, Tunisia*

Background

Struma ovarii is a rare monodermal teratoma defined by predominant thyroid tissue composition, accounting for less than 5% of ovarian teratomas. Its preoperative diagnosis remains challenging due to nonspecific imaging features that frequently mimic epithelial ovarian malignancy. We report a case initially suspected as ovarian cystadenocarcinoma on magnetic resonance imaging (MRI).

Methods

This case report describes the clinical presentation, imaging findings, laparoscopic management, and histopathological examination of an ovarian cyst in a postmenopausal patient.

A 64-year-old multiparous postmenopausal woman (G7P7) presented with chronic pelvic pain, without associated digestive or urinary symptoms. Clinical examination revealed no alteration in general condition. Pelvic examination was unremarkable.

Pelvic ultrasound showed a 13 × 10 cm left adnexal bilocular anechoic cystic mass with thin walls, without septa, vegetations, or Doppler vascularization, classified as indeterminate according to IOTA criteria. Tumor markers were within normal limits, except for a mildly elevated Alpha-fetoprotein (AFP) (8.2 ng/mL). Pelvic MRI suggested a right ovarian cystadenocarcinoma.

Results

Following multidisciplinary discussion, laparoscopic bilateral adnexectomy was performed with peritoneal staging.
Intraoperatively, the left adnexa harboured a 16 cm solid-cystic mass without surface vegetations or abnormal vascularization. The right adnexa appeared unremarkable. No ascites was noted. Limited peritoneal carcinomatosis was identified, confined to the left paracolic gutter, with a Fagotti score of 0.
Histopathological examination demonstrated a benign left ovarian struma ovarii (monodermal mature cystic teratoma) without malignant features. Peritoneal cytology and biopsies were negative.

Conclusions

Struma ovarii should be systematically included in the differential diagnosis of complex adnexal masses. Histopathological assessment remains the diagnostic gold standard.

ESGE35-0332 - P014
ePoster Presentations

Clinical Feasibility and Safety Profile of Robotic vNOTES Hysterectomy in Benign Uterine Disease : Initial Experience

Soyun PARK[1], Taekyung Lee[1], Ha Kyun Chang[1], Hye-Sung Moon[1]
[1]Ewha Womans University Seoul Hospital- College of Medicine- Ewha Womans University, Department of Obstetrics and Gynaecology, Seoul, Korea- Republic Of

Background

This study aimed to compare the surgical outcomes of robotic single-port Hysterectomy[RSPH] and robotic vaginally assisted natural orifice transluminal endoscopic surgery [vNOTES] hysterectomy procedures in women with benign gynecological disease.

Methods

This retrospective, case-controlled study evaluated patients who underwent benign gynecological hysterectomy procedures at Ewha Woman's University Medical Center between March 1, 2024, and March 31, 2026. A total of 54 women aged 42–58 years were enrolled and stratified into two groups based on the surgical approach: the robotic single-port hysterectomy (RSPH) group (29 patients) and the robotic vaginally assisted natural orifice transluminal endoscopic surgery (vNOTES) hysterectomy group (25 patients). All surgical interventions were performed using the da Vinci® SP surgical system (Intuitive Surgical, Sunnyvale, CA, USA). Medical records were retrospectively reviewed to collect clinical and perioperative outcomes, including uterine dimensions, final pathology reports, total operation time, and estimated blood loss. Additionally, pre- and postoperative haemoglobin and haematocrit levels, duration of postoperative hospital stay, rates of conversion to laparotomy, and peri- or postoperative complications were analysed. Postoperative pain management was assessed by recording the cumulative dose of administered analgesics and pain intensity using the Visual Analog Scale (VAS) at 24 hours post-surgery.

Results

There was no significant difference between RSPH and vNOTES hysterectomy groups regarding age (46.3 vs. 46.9 years, p = 0.16), parity (2 vs. 2, p = 0.74), and BMI (22.8 vs. 22.5 kg/m^2, p = 0.31), mean uterus weight [395g vs 371g, p=0.52]. There was no significant difference in console time [50.55±46.13 vs. 51.27±40.29, p= 0.44] , but the docking time [2.29±1.71 vs. 14.72±6.53, p=0.01] were significant longer in vNOTES group. Meanwhile, the total operation time tended to be shorter in vNOTES group (104.03 ±55.9 vs. 91.2± 52.2, p=0.08) , but it was not statistically significant.

Estimated blood loss, intraoperative blood loss, the presence of peri-, postoperative complications, conversion to laparotomy, postoperative Hb, postoperative hospital stay were no significant difference in two groups.

The 24th hour VAS score was lower (VAS score 1 vs. 2, p = 0.03) in favour of the vNOTES hysterectomy group. There was one conversion case RSPH to vNOTES due to severe adhesion near the umbilicus

due to previous operation, and one conversion case from vNOTES to RSPH due to full obliteration of posterior cul-de-sac.

Conclusions

Robotic vNOTES hysterectomy demonstrates favourable operative outcomes, offering shorter operative times and superior 24-hour pain control without additional morbidity compared to RSPH. Notably, robotic vNOTES hysterectomy serves as a highly useful alternative in cases with severe umbilical adhesions; however, its feasibility is limited by full obliteration of the posterior cul-de-sac, which may necessitate conversion to RSPH.

ESGE35-0492 - P016
ePoster Presentations

Surgical Management of Mixed-Type Gestational Trophoblastic Disease in the Setting of Cystic Fibrosis: A Minimally Invasive Approach

Maciej Sielski[1], Michał Ciebiera[2], Diana Massalska[2], Wojciech Skorupa[3], Rafał Karwowski[1], Grzegorz Szewczyk[1]
[1]St. John Paul II Mazovian Regional Hospital,
Department of Obstetrics- Gynaecology and Gynecological Oncology, Siedlce, Poland
[2]Warsaw Institute of Women's Health, Department of Gynaecology, Warsaw, Poland
[3]institute of Tuberculosis and Lung Diseases, Medical Director, Warsaw, Poland

Background

Placental site trophoblastic tumor (PSTT) is a rare trophoblastic neoplasm with limited chemosensitivity; therefore, surgery remains the standard treatment for disease confined to the uterus. The aim of this report is to present the case of a 22-year-old woman with PSTT and coexisting cystic fibrosis, in whom the choice of minimally invasive robot-assisted surgery was driven not only by oncologic considerations but also by the need to reduce surgical risk and recovery-related complications.

Methods

A 22-year-old woman with cystic fibrosis was hospitalized because of vaginal bleeding in early pregnancy. Imaging showed abnormal intrauterine contents, and hCG was significantly elevated. Initial uterine evacuation and histopathological assessment did not allow a definitive diagnosis, while follow-up demonstrated persistent bleeding and abnormal hCG dynamics. Based on the overall clinical, biochemical, and repeat histopathological findings, trophoblastic disease including PSTT was suspected.

Results

The patient was qualified for surgical treatment. Robot-assisted laparoscopy with hysterectomy, bilateral salpingectomy, and a sentinel lymph node procedure was performed. The intraoperative and postoperative courses were uneventful. Final postoperative histopathology demonstrated a complete hydatidiform mole coexisting with an early placental site trophoblastic tumor. After surgery, close oncologic surveillance with serial hCG measurements showed gradual normalization.

Conclusions

This case shows that the diagnosis of trophoblastic disease may require multistep correlation of clinical findings, hCG dynamics, and sequential histopathological results, particularly when initial findings are inconclusive. In this patient, the coexistence of a complete hydatidiform mole and early PSTT further highlights the diagnostic complexity. The minimally invasive robot-assisted surgical approach was justified both by the uterine-confined nature of the disease and by coexisting cystic fibrosis, with reduction of surgical trauma and support for faster recovery as important elements of treatment planning.

ESGE35-0397 - P018
ePoster Presentations

comparative impact of laparoscopic and robot-assisted surgery on perioperative stress response and health-related quality of life in gynecologic patients

Lucia Anna Otten[1], Lara Müller[2], Eva K. Egger[3], Carolin Schröder[3], Dominique Koensgen[3], Alexander Mustea[3]
[1]University Hospital Bonn, Department of Gynaecology and Gynaecological Oncology-, Bonn, Germany
[2]Department of Gynaecology and Gynaecological Oncology, University Hospital Bonn, Bonn, Germany
[3]University Hospital Bonn, Department of Gynaecology and Gynaecological Oncology, Bonn, Germany

Background

this prospective single-center study aimed to compare the perioperative stress response, intraoperative nociception, postoperative pain, health-related quality of life, sexual function, and patient satisfaction between conventional laparoscopic surgery (ls) and robot-assisted laparoscopic surgery (rls) using the DaVinci® xi surgical system in patients undergoing gynecologic procedures.

Methods

a total of 100 patients undergoing surgery for benign or malignant gynecologic conditions at the department of Gynaecology, university hospital Bonn, were prospectively enrolled between January 2023 and October 2024. following shared decision-making, 50 patients underwent conventional laparoscopy and 50 underwent robot-assisted surgery. perioperative stress response was assessed by measuring adrenocorticotropic hormone (acth) and cortisol levels at five predefined time points: preoperative assessment, induction of anesthesia, emergence from anesthesia, postoperative day 1, and postoperative day 3. intraoperative nociception was continuously monitored using the nociception level (nol) index. subjective pain intensity was evaluated using the numeric rating scale (nrs) and visual analog scale (vas). health-related quality of life was assessed using the sf-36 questionnaire, while selected female sexual function Index (fsfi)-based items evaluated postoperative sexual function. additional outcomes included operative time, blood loss, analgesic consumption, shoulder pain, cosmetic satisfaction, and surgical satisfaction.

Results

baseline demographic characteristics were largely comparable between groups, except for a certain difference regarding the surgical indication, as more Urogynaecological procedures were performed robotically. Intraoperative blood loss, complication rates, conversion rates, and postoperative analgesic consumption were comparable between groups. mean operative time was significantly longer in the rls group (172.8 ± 64.5 vs. 119.5 ± 35.1 minutes, $p < 0.001$). capnoperitoneum pressure was slightly higher in rls procedures (14.5 vs. 13.7 mmHg, $p = 0.039$). no significant differences were observed in acth or cortisol levels at any perioperative time point, indicating a comparable physiological stress response. similarly, intraoperative nol values, postoperative pain scores (nrs/vas), shoulder pain, cosmetic satisfaction, sexual function, and mental and physical sf-36 outcomes showed

no clinically relevant differences between groups. both approaches demonstrated low complication rates and high patient satisfaction.

Conclusions

conventional laparoscopy and robot-assisted surgery demonstrated comparable perioperative stress responses, nociceptive burden, postoperative pain control, health-related quality of life, and sexual function in gynecologic patients. although robot-assisted procedures were associated with significantly longer operative times, no clinically meaningful advantages regarding patient-reported outcomes or physiological stress markers were identified. these findings suggest that both minimally invasive techniques are safe and clinically effective approaches in gynecologic surgery.

ESGE35-0480 - P020
ePoster Presentations

Alterations in Toll-like Receptor Expression and Selected Gut Microbiota Species in Women with Endometriosis

Anna Dudzińska[1], Paulina Mertowska[1], Sebastian Mertowski[1], Ewelina Grywalska[1]
[1]Medical University of Lublin, Department of Experimental Immunology, Lublin, Poland

Aim

The aim of this study was to evaluate selected parameters of innate immune response and gut microbiota composition in women with endometriosis, prior to treatment, in comparison with healthy controls. The analysis focused on the expression of Toll-like receptors — TLR2, TLR3, TLR4, TLR7, TLR8, and TLR9 — on peripheral blood lymphocyte subpopulations, including CD4+ T cells, CD8+ T cells, and CD19+ B cells. Additionally, soluble forms of these receptors were assessed in serum and urine, together with selected intestinal microbiota species.

Background

Endometriosis is a chronic inflammatory gynecological disorder characterized by the presence of endometrial-like tissue outside the uterine cavity [1,2]. Although its pathogenesis remains incompletely understood, current evidence suggests a multifactorial etiology involving endocrine and immunological disturbances, particularly innate immune mechanisms and Toll-like receptor signaling pathways [3]. Disturbances in gut microbiota composition may also contribute to the maintenance of chronic inflammation and immune imbalance.

Materials / Patients

The study included 30 women: 15 patients with histopathologically confirmed endometriosis and 15 healthy women forming the control group. Diagnosis was established according to the criteria of the American Society for Reproductive Medicine [4, 5], and confirmed histopathologically following laparoscopy. Peripheral blood samples were obtained for immunophenotyping and serum isolation, while midstream urine samples were collected for the assessment of soluble immune parameters. Stool samples were collected for the analysis of selected gut microbiota species.

Methods / Results

The expression of TLR2-9 on lymphocyte subpopulations was assessed using flow cytometry. Concentrations of soluble TLRs in serum and urine were determined using immunoenzymatically methods. Microbial DNA was isolated from stool samples, and selected intestinal bacterial species were identified.
Women with endometriosis showed increased expression of selected TLRs on peripheral blood lymphocyte subpopulations, together with elevated concentrations of soluble TLRs in serum and urine, compared with healthy controls. These findings suggest activation of innate immune mechanisms and systemic inflammatory signaling in endometriosis. Analysis of stool samples revealed differences in the prevalence of selected intestinal microbiota species between the study groups. Patients with endometriosis demonstrated a higher prevalence of potentially pathogenic

bacteria, including Escherichia coli and Enterococcus faecalis, and a lower prevalence of beneficial bacteria, particularly Lactobacillus species, indicating features of intestinal dysbiosis.

Discussion

TLRs are key mediators of innate immunity and inflammatory signaling pathways. Among them, TLR4 appears to play a particularly important role in the pathophysiology of endometriosis [6,7]. Moreover, intestinal dysbiosis may be correlated with the occurrence of endometriosis [8]. The observed coexistence of altered TLR expression and changes in selected gut microbiota species supports the concept of immune-microbiota interactions in endometriosis.

Conclusion

This study demonstrates that endometriosis is associated with alterations in innate immune response and gut microbiota composition.

Impact to Patients' Health

Combined evaluation of immune dysregulation and gut microbiota disturbances may improve understanding, diagnosis, and personalized treatment of endometriosis.

ESGE35-0498 - P021
ePoster Presentations

Improving of medical performance in laparoscopy and ICU departments of our department

Romina-Marina Sima[1], Mihaela Amza[1], Ileana-Maria Conea[1], Liana Ples[1]
[1]Carol Davila University of Medicine and Pharmacy, Obstetrics and Gynaecology, Bucharest, Romania

Background

The identified problem was communication deficiencies between the anesthetic-surgical team. It is a problem encountered in many hospitals around the world and it has an impact on the optimization and efficient use of the time spent in the operating room, having medical, economics and social consequences.

Methods

This problem was identified in our daily practice, especially in the return after the pandemic when Bucur maternity was exclusively used for COVID cases. During this period, due to the restriction of scheduled surgical activity and the limited access of patients only to those tested positive, the functioning, organization and communication between the ICU department and laparoscopy departments was completely disrupted in order to comply with the epidemiological rules imposed.

Results

The distinct distribution of the 4 operating rooms according to the types of pathologies especially laparoscopy and hysteroscopy. The establishment of a firm program that assigned an anaesthesiologist to each operating room for days and weeks. Development of an operational procedure to optimise the operating program and allow the elimination of the time spent in the hospital prior to the operation by the patient. It has been standardized that the operating program to be established one week in advance and reconfirmed 48 hours before the operation. Optimizing operative and interoperative times by eliminating coordination and communication deficiencies. Optimizing operative and anaesthetic times through workshops and instructions on the use by doctors and nurses of the new equipment brought to the department. These workshops were supported both by the anaesthesiologists and the gynaecologists for the colleagues in the specialty and the medical assistants in the department.

Conclusions

From this experience we learned that only by establishing step by step each stage of work we can obtain an optimal result. By standardizing, making well-established plans and explaining them before implementation, we can achieve performance in laparoscopy and ICU.

ESGE35-0497 - P022
ePoster Presentations

Where can we find a IUD during laparoscopy?

Romina-Marina Sima[1], Mihaela Amza[1], Andrei Sebastian Diaconescu[2], Diaconescu Denise Cristina[3], Liana Ples[1]
[1]Carol Davila University of Medicine and Pharmacy, Obstetrics and Gynaecology, Bucharest, Romania
[2]Carol Davila University of Medicine and Pharmacy, General Surgery, Bucharest, Romania
[3]Bucur Maternity, Obstetrics and Gynaecology, Bucharest, Romania

Background

Periodic gynecological evaluation after insertion of an intrauterine device (IUD) is very important to prevent the occurrence of complications associated with IUD migration, as well as the evaluation of diagnostic and therapeutic methods in this case.

Methods

We presented the case of a 41-year-old patient who had an IUD inserted 1 year ago and which was identified outside the uterine cavity.

Results

We presented the case of a 41-year-old patient without significant pathologies, who had an IUD placed 1 year ago. After 6 months, the patient became pregnant and decided medical termination of pregnancy. It was necessary to perform uterine curettage after the medical abortion. Subsequently, the patient underwent an ultrasound scan and a normal-appearing uterus and right ovary were found, and in the area of the left adnexa apparently in the left ovary, a hyperechoic image suggestive of an IUD. Computed tomography examination confirmed the presence of the IUD outside the uterine cavity. Exploratory laparoscopy was performed and IUD was extracted from the left ovary. The patient's evolution was favourable and without complications.

Conclusions

Despite the fact that the IUD is a safe and effective method of contraception, periodic gynecological consultation is necessary in order to be able to identify early IUD migration and the occurrence of possible complications. Laparoscopy is both a diagnostic and therapeutic method in the case of a migrated IUD.

ESGE35-0514 - P023
ePoster Presentations

Uterine rupture with placental abruption in a primigravid 34 weeks caeserean delivery without any risk factors

Mine Kiseli[1], Didem Cakmak[2], Arzu Bostanci Durmus[3]
[1]Lokman Hekim University- Faculty of Medicine, Department of Obstetrics and Gynaecology, Ankara, Türkiye
[2]Etlik Governity Hospital, Department of Obstetrics and Gynaecology, Ankara, Türkiye
[3]Ankara Atatürk Sanatoryum Research and Education Hospital,
Department of Obstetrics and Gynaecology, Ankara, Türkiye

Background

Uterine rupture in a preterm pregnancy is a very rare obstetrical complication with severe maternal and perinatal outcomes. Usually it is seen in scarred uteruses. Previous caesarean section, previous myomectomy, instrumental delivery, excessive induction are main risk factors. The associated morbidity and mortality makes it an important situation not to be disregarded. Here we present a case of cornual rupture with placental abruption who presented with foetal distress at 34 weeks of pregnancy.

Methods

A 34 weeks old pregnant woman admitted to the hospital with a recent onset abdominal pain. The obstetric history was uneventful with all regular tests were normal except a slight growth retardation beginning at 32 weeks. The patient had no history of curettage nor any surgical procedure that would cause the uterus scarred.

The ultrasonography revealed a viable foetus who has estimated weight of 2000 grams. The presentation was breech. Amniotic fluid was slightly decreased. Non stress test was reactive at first admission with no visible contractions on topography. She wasn't in active labour as she had 1 cm dilatation with %40 effacement. She had still some widespread pain spreading to the groin area. Intravenous hydration and administration of betamethasone was performed. After a while, foetal heart rate started to show late decelerations. There was no vaginal bleeding nor any cord prolapsus. Urgent caesarean was decided.

Results

As the abdomen was introduced, there was 200 mL free blood and clots in the abdominal cavity incomprehensibly. After aspiration of blood, low transverse incision to the uterus was carried out. A female live foetus (2050 gr) has been delivered via breech. The cord was tightly wrapped three full times around the baby’s neck. Her Apgar score was 8 and 10, at 1 and 10 minutes respectively. After the baby’s delivery, the placenta was removed. It was abrupted and was separated. When the uterus was out of the abdominal cavity, a small full thickness rupture in the right cornual region was seen. There was no active bleeding. The uterus was repaired with sutures. There was no uterine anomaly. The caesarean was completed uneventfully. The baby survived well after 10 days of intensive care unit for prematurity.

Conclusions

The uterine rupture is very unexpected in cases without any scar or damage history. Also without an active labour, mechanism is very unclear. Most probably, placental abruption occurred due to the rupture and it caused foetal heart rate decelerations. The management of suspected uterine rupture should include a prompt diagnosis followed by timely and definitive surgical management with concurrent maternal haemodynamic stabilisation.

ESGE35-0616 - P024
ePoster Presentations

A case study of an Incidental Benign Mesothelial Cyst following an ovarian cystectomy

Ayooluwa Olateju[1]
[1]*Manchester University Foundation Trust, Gynaecology, Manchester, United Kingdom*

Background

To present a case of an incidental benign pelvic finding that mimicked other pelvic pathologies and influenced surgical decision-making.

Methods

We report the case of a para 2 woman in her mid-forties who had completed her family. She previously underwent a laparoscopic left ovarian cystectomy for an 11 cm symptomatic ovarian cyst confirmed on MRI. Tumour markers, including CA-125, LDH, AFP, and hCG, were normal, and histology demonstrated a benign mucinous cystadenoma.

Eighteen months later, the patient re-presented with worsening chronic pelvic pain affecting her quality of life. Initial pelvic ultrasound demonstrated a 64 × 50 mm right hydrosalpinx, which subsequently increased in size to 80 × 40 mm on repeat imaging.

A laparoscopic salpingectomy with or without oophorectomy was offered. Intraoperatively, no hydrosalpinx was identified. Instead, a large presumed peritoneal inclusion cyst with superficial adhesions was found in the pouch of Douglas. Laparoscopic adhesiolysis, cyst drainage, and instillation of anti-adhesion fluid were performed. The cyst wall was sent for histological analysis. Both fallopian tubes and ovaries appeared normal, although the left ovary was adherent to the left pelvic sidewall secondary to the previous cystectomy. The patient was discharged the same day and made a good postoperative recovery.

Results

Histological examination confirmed a benign mesothelial cyst, and the patient was reassured as appropriate.

Conclusions

Pelvic mesothelial cysts are rare benign lesions that may mimic other pelvic pathologies on imaging, potentially influencing clinical management. This case highlights the limitations of ultrasound imaging and the importance of thorough preoperative counselling. Additional imaging, such as pelvic MRI, may have aided preoperative diagnosis and could have supported consideration of alternative management approaches, including image-guided drainage by interventional radiology.

Although these cysts are often incidental findings, prior pelvic surgery may represent a potential risk factor. Management should be individualised, but outcomes are generally favourable and reassuring for patients.

ESGE35-0670 - P025
ePoster Presentations

Hysteroscopic findings in endometrial cancer: an iconographic study

Amal Mouzali[1], *Benkharchi Samia*[1]
[1]*Thenia hospital, Medecine, Boumerdes, Algeria*

Background

Endometrial cancer is the sixth most common cancer among women worldwide, with an estimated 420,368 new cases and 97,723 deaths annually (Globocan 2022). In Algeria, it ranks 14th among female cancers, with an incidence of 2.7 per 100,000 inhabitants according to the National Cancer Registry Network of Algeria (2022). It predominantly affects postmenopausal women and most commonly presents with abnormal uterine bleeding. Early and accurate diagnosis is essential for improving prognosis. Hysteroscopy, which allows direct visualization of the endometrial cavity and targeted biopsy of suspicious lesions, has become an essential diagnostic tool in the evaluation of endometrial pathology. Several hysteroscopic scoring systems and visual criteria—including tissue fragility, abnormal vascular patterns, irregular surface morphology, and white or yellowish lesions—have demonstrated high sensitivity and specificity for the detection of malignancy. The aim of this study was to describe the characteristic hysteroscopic features of endometrial neoplasia and evaluate their correlation with histopathological findings.

Methods

This retrospective descriptive study was conducted in the Department of Gynaecology and Obstetrics at the Hospital of Thenia, Boumerdes, Algeria, from October 2025 onward. A total of 23 patients investigated for suspected endometrial cancer were initially identified. Among them, 11 patients were included in the final analysis. The remaining cases were excluded because of poor-quality or non-interpretable hysteroscopic images due to intrauterine bleeding, or because hysteroscopy had not been performed and patients were referred with already completed medical records. All included patients underwent office diagnostic hysteroscopy followed by targeted endometrial biopsy. Histopathological examination was used as the reference standard for diagnosis.

Results

Irregular vascularization was strongly associated with malignant lesions and represented the most frequent suspicious finding. Necrotic areas were mainly observed in advanced disease and appeared to correlate with more aggressive lesions. Vegetative growths and irregular endometrial architecture were also highly suggestive of endometrial malignancy. The combined presence of irregular endometrial surface, abnormal vascularization, and tissue fragility demonstrated a high predictive value for malignancy and showed strong correlation with histopathological confirmation of endometrial neoplasia.

Conclusions

Diagnostic hysteroscopy is a valuable and minimally invasive tool in the evaluation of endometrial neoplasia. Specific hysteroscopic findings, particularly irregular vascularization, endometrial

irregularity, tissue fragility, and necrosis, should raise strong suspicion of malignancy and prompt targeted biopsy. Although definitive diagnosis remains histopathological, hysteroscopy significantly improves early detection, diagnostic accuracy, and clinical decision-making in patients with suspected endometrial cancer.

ESGE35-0674 - P026
ePoster Presentations

The use of indocyanine green in distinguishing between malignant and benign ovarian tumors.

Michal Kostrzanowski[1], *Grzegorz Ziółkowski*[1], *Filip Dąbrowski*[1]
[1]*Center of Postgraduate Medical Education, Department of Gynaecology and Gynecological Oncology, Warsaw, Poland*

Background

Ovarian cancer was the eighth most common cancer among women worldwide in 2020. Most ovarian tumors are epithelial in origin. Benign lesions account for 60% of all epithelial ovarian tumors. To differentiate malignant lesions from benign tumors intraoperatively, we assessed the fluorescence of ovarian tumors using indocyanine green and correlated the lesions' fluorescence with histopathological confirmation of whether they were malignant or benign.

Methods

For this study, patients with suspected ovarian cancer were selected based on imaging findings, laboratory tests (ROMA test), and clinical symptoms. The study was approved by the local Bioethics Committee. Indocyanine green (ICG) was prepared by dissolving 25 mg of ICG in water for injection. ICG was administered intravenously at a dose of 0.25 mg/kg one hour before skin incision. During laparoscopy, the tumors were visualized using fluorescence mode and classified as either ICG-positive or ICG-negative before being submitted for frozen section analysis. After histopathological confirmation, correlations between lesion type (malignant or benign) and fluorescence patterns were analysed.

Results

A group of six patients with ovarian cancer and six patients with benign tumors were analysed. In the ovarian cancer group, eight ovaries were confirmed to contain cancerous lesions, and all specimens were ICG-positive. One ovary from a cancer patient tested negative for cancer cells and was ICG-positive. Overall, 10 lesions were negative for cancer cells; among these, five were ICG-positive and five were ICG-negative. The sensitivity of ICG fluorescence imaging for detecting ovarian cancer lesions was 100%, while the specificity was 50%.

Conclusions

ICG fluorescence could indicate the presence of malignant lesions in the ovaries. The low specificity means that it could not be used unambiguously in distinguishing between malignant and benign ovarian tumors. Frozen section remains the gold standard for intraoperative assessment of tumor malignancy and, consequently, for determining the appropriate extent of surgery.

ESGE35-0708 - P027
ePoster Presentations

Reproductive outcomes of a hybrid strategy combining preoperative embryo cryopreservation with laparoscopic myomectomy for fibroid-associated infertility

Yasuho Yanagihara[1], *Keisuke Murakami*[1], *Shiori Takeuchi*[1], *Yu Kawasaki*[1], *Mari Kitade*[1]
[1]*Juntendo University School of Medicine, Obstetrics & Gynaecology, Tokyo, Japan*

Background

The management of infertility associated with uterine fibroids requires balancing two competing priorities: surgical correction of uterine factors and preservation of ovarian reserve. Performing laparoscopic myomectomy (LM) prior to assisted reproductive technology (ART) delays embryo transfer and risks age-related decline in ovarian reserve, whereas proceeding directly with ART may result in difficult oocyte retrieval, impaired implantation, and increased obstetric complications due to the presence of fibroids. A hybrid approach—preoperative embryo cryopreservation followed by LM and subsequent frozen-thawed embryo transfer (FET)—has been proposed as a strategy to address this clinical dilemma. Despite its theoretical advantages, published data on ART outcomes following this approach remain limited. The aim of this study was to describe ART outcomes in patients with fibroid-associated infertility who underwent hybrid therapy at our institution.

Methods

We retrospectively reviewed 35 patients (51 oocyte retrieval cycles; 65 embryo transfer cycles) who underwent hybrid therapy for fibroid-associated infertility at our institution between January 2015 and December 2025. The hybrid protocol consisted of ovarian stimulation and oocyte retrieval with embryo cryopreservation, followed by LM, and subsequent FET after surgical recovery. Outcomes assessed included the number of cryopreserved embryos prior to surgery, clinical pregnancy rate, miscarriage rate, and perinatal complications.

Results

The mean patient age was 38.2 ± 4.9 years, and the mean anti-Müllerian hormone (AMH) level was 2.03 ± 2.31 ng/mL. Ovarian stimulation protocols included clomiphene citrate plus hMG (20 cycles), GnRH antagonist (14 cycles), short protocol (10 cycles), and others (7 cycles). The mean number of cryopreserved embryos per patient was 3.6 ± 2.1. Of 126 cryopreserved embryos, 65 (51.6%) were cleavage-stage embryos and 61 (48.4%) were blastocysts. Regarding fibroid characteristics, the mean maximum diameter was 6.3 ± 3.4 cm, and the mean number of enucleated fibroids was 4.0 ± 2.9. No perioperative complications were observed. The clinical pregnancy rate per patient was 42.9% (15/35), and the miscarriage rate was 26.7% (4/15). Obstetric outcomes among those who achieved pregnancy were favourable, with no perinatal complications recorded.

Conclusions

This retrospective case series demonstrates that the hybrid strategy of preoperative embryo cryopreservation followed by LM is a feasible approach for managing fibroid-associated infertility. By securing ovarian reserve as cryopreserved embryos before surgery, this strategy allows LM to be

performed at an appropriate time without concern for further age-related fertility decline. Our findings suggest acceptable pregnancy outcomes and favourable perinatal results. However, as treatment selection is inherently influenced by patient characteristics such as age and ovarian reserve, comparative studies with appropriate adjustment for confounding factors are needed to further define the role of this approach.

ESGE35-0757 - P030
ePoster Presentations

Left fallopian tube dermoid cyst causing isolated fallopian tube torsion

Nikola Sambandan[1], Srisanjeevan Sriskanthan[1], Fredric Willmott[1]
[1]Whipps Cross Hospital- Barts Health NHS Trust, Obstetrics and Gynaecology, London, United Kingdom

Background

Teratomas of the fallopian tubes are extremely rare, with 70 cases reported worldwide.[1] Diagnosis is rarely made preoperatively therefore, laparoscopy with histological assessment is necessary for the definitive diagnosis. Radiological evaluation of tubal cystic teratomas are frequently interpreted as ovarian in origin therefore, we must consider tubal teratoma both in acute presentations and where the origin of the adnexal mass is unclear.[2]

Methods

We present a 28 year old nulliparous Caucasian lady, BMI 19, presenting, out of hours with sudden onset of left iliac fossa abdominal pain progressively worsening over 6 hours. The pain was localised to the left iliac fossa to suprapubic region, eased with hip flexion and associated with vomiting, low grade fever and reduced appetite. The patient denied any shoulder tip pain, change in bowel habit or urinary symptoms. The pain was scored 10/10 severity and eased to 6/10 with 10mg of morphine. She reported her cervical smears were normal to date. She had a kylena coil in situ for contraception.

On examination she was febrile 37.8'C, tachycardic (101 bpm) and normotensive. The abdomen was soft, tender in the left iliac fossa with no distension. Speculum examination was unremarkable with a palpable mobile left adnexal mass on bimanual. Urinalysis was negative. Serum HCG was negative with an elevated lactate of 3. All remaining bloods were normal except mild neutrophilia (10.1x9/L). Bedside abdominal and transvaginal ultrasound suggested a normal sized uterus, small amount of free fluid with a cystic mass in the pouch of Douglas. Both ovaries appeared separate and normal.

Results

The patient underwent a diagnostic laparoscopy with initial detorsion of the fallopian tube, x3 clockwise rotations observing for reperfusion. The 7cm ischaemic fallopian tube was distended causing secondary haemoperitoneum. Salpingotomy was attempted revealing sebaceous contents, hair and cartilage within the fallopian tube in keeping with a dermoid cyst. Due to poor tubal viability the patient underwent laparoscopic left salpingectomy. The right fallopian tube was normal. The specimen was removed via a 10mm umbilical port with memory bag. Haemostasis was confirmed following copius normal saline washout. The post-operative Hb 115g/L. She was discharged home within 24 hours with an uncomplicated post-operative recovery.

Conclusions

Fallopian tube MCT's are a rare yet important consideration in patients presenting with symptoms mimicking ovarian torsion. The diagnosis is often made intraoperatively therefore, in the event of

clinical suspicion one should have a low threshold to proceed with diagnostic laparoscopy and histological evaluation to avoid delayed diagnosis and tubal rupture.

ESGE35-0788 - P032
ePoster Presentations

Why do polyps return? Incidence and systemic predictors of endometrial polyp recurrence in 1816 women

Zofia Kiestrzyn[1,2], Karolina Chmaj-Wierzchowska[3,4], Maciej Wilczak[3]
[1]Poznań University of Medical Sciences, Medical Faculty, Poznań, Poland
[2]Poznań University of Medical Sciences, Student Scientific Society of Obstetrics and Gynaecology, Poznań, Poland
[3]Poznań University of Medical Sciences,
Department of Maternal and Child Health and Minimally Invasive Gynecological Surgery, Poznań, Poland
[4]Poznań University of Medical Sciences,
Laboratory of Modern Interventional Therapies in Gynaecology and UroGynaecology, Poznań, Poland

Background

Endometrial polyps are amongst the most common uterine lesions, occurring in about 7.8% to 34.9% of female patients [1]. Despite a successful treatment via hysteroscopic polypectomy, such lesions can recur. Recurrence rates vary significantly between populations from 5.6% to 13.3% [2-4]. There is a deficit in data about Polish patients and endometrial polyp recurrence, thus the aim of this study is to establish a recurrence rate of endometrial polyps following hysteroscopic polypectomy under local anaesthesia in a cohort of Polish patients treated at a tertiary referral center from 2022 to 2025. Additionally, the secondary objective is to identify and evaluate independent clinical factors of polyp recurrence, including: polyp size, obesity, hypertension, diabetes mellitus type II, tamoxifen use, endometrial hyperplasia and menopausal status.

Methods

A retrospective cohort study was conducted at the center for Hysteroscopy Under Local Anesthesia of the Heliodor Święcicki Gynecological and Obstetric University Hospital, affiliated with the Poznan University of Medical Sciences. The analysis included 1816 patients treated between 2022 and 2025 using the GUBBINI Mini-Hystero-Resectoscope ® under paracervical anaesthesia with the Hystero-Block ® system. Statistical analysis of the polyp size was conducted through Welch's test. Other risk factors were analysed statistically using Fisher's exact test. Odds ratios (OR) were also calculated for independent risk factors.

Results

Out of 1816 patients, the overall polyp recurrence rate in this study was remarkably low at 2.4% (n=44). Evaluation of secondary objectives revealed that primary polyp size did not differ significantly between the recurrence and non-recurrence groups (11.57 ± 6.86 mm vs. 11.52 ± 6.86 mm; p=0.97). Among systemic factors, a history of breast cancer (associated with tamoxifen use) was the strongest clinical predictor, with a nearly 14-fold increased recurrence risk (25.0% vs. 2.4%; OR=13.71, p=0.094). Obesity showed a twofold clinical trend toward higher recurrence (OR=2.30, p=0.20). Conversely, diabetes mellitus type II, hypertension, and endometrial hyperplasia did not increase the

recurrence risk (p=1.00 for all factors). This might suggest the neutralizing effect of ongoing pharmacological management. Evaluation of menopausal status was impossible due to severe database underreporting.

Conclusions

11. The recurrence rate of endometrial polyps in the analysed Polish tertiary center following hysteroscopic polypectomy under paracervical anaesthesia is exceptionally low (2.4%), highlighting the high efficacy of this operative approach.
12. Primary polyp size does not predict future regrowth, suggesting that recurrence is influenced by systemic biological factors rather than lesion dimensions.
13. The profound risk increase observed in patients with an oncological history mandates rigorous, targeted ultrasound surveillance for those undergoing tamoxifen therapy.
14. Metabolic conditions controlled with pharmacotherapy appear to neutralize the risk of polyp recurrence.

ESGE35-0006 - P034
ePoster Presentations

primary cutaneous endometrioma

Mihaela Michituc[1], Sihem Imessaoudene[1], Carolina Lopez[2]
[1]North and East Hertfordshire NHS Trust, Obstetrics and Gynaecology, Stevenage, United Kingdom
[2]East and North Hertfordshire NHS Trust, Radiology, Stevenage, United Kingdom

Background

primary cutaneous endometrioma is a very rare gynaecological condition without a clear etiology. the proposed pathogenesis includes metaplasia of local tissue into endometrial cells, lymphatic or vascular spread of endometrial cells and hormonal influence - oestrogen - driven proliferation.

Methods

we report the case of a 44-year old nulliparous woman who attended the gynaecology clinic with menorrhagia, dysmenorrhoea, vulvodynia and subfertility concerns. she had been diagnosed in the past with adenomyosis and fibroids for which she underwent an open myomectomy and a diagnostic laparoscopy. now the patient mentioned a nodule on the right side of mons pubis, increasing in size and becoming more painful during menses. she had no previous surgery or scar at this level. on examination, a smooth, round, fixed nodule of approximately 5 cm was palpable, without peripheral lymphadenopathy.

Results

pelvic magnetic resonance imaging was suggestive of endometriosis of canal of Nuck. within the adipose tissue of the mons pubis there was a focal lesion with features of endometriosis, located close to the clitoris but away from the urethra, bladder and femoral vessels. there was no evidence of a fistula or a sinus formation, aneurysm or abnormal vascularity. the patient underwent a complete surgical removal of the mass. an irregular grey brown fatty tissue measuring 70 x 70 x 45 mm was removed. cut surface showed grey, white and brown patches. histopathological examination confirmed endometriosis, with endometrial glands associated with stroma. no atypia or malignancy was seen.

Conclusions

this report emphasises the importance of recognising primary cutaneous endometrioma as a rare differential diagnosis for suspicious vulval tumours in patients of fertile age.
this case was successfully managed through a multidisciplinary approach involving radiology, gynaecology and plastic surgery teams.

ESGE35-0018 - P035
ePoster Presentations

Diagnostic Laparoscopy for Chronic Pelvic Pain: Spigelian Hernia

Ewaenaretan Ikhatua[1], Anusha Sivasuriam[1], Kumarswamy MaradiThippeswamy[2]
[1]Prince Charles Hospital- Cwm Taf Morgannwg University Health Board, Obstetrics and Gynaecology, Merthyr Tydfil, United Kingdom
[2]Prince Charles Hospital- Cwm Taf Morgannwg University Health Board, Surgery, Merthyr Tydfil, United Kingdom

Background

We present a rare finding at laparoscopy in a 54 year old with right sided chronic pelvic pain.

She had undergone two caesarean sections in the past. Her pain was thought to be due to adhesions or endometriosis. However, findings at laparoscopy were of an entirely different pathology which is often not seen in Gynaecology.

Methods

Spigelian (lateral ventral) hernia is an abdominal defect in the Spigelian zone (zone of transition, 3-37mm wide, between the muscular fibres and aponeurosis of the transversus abdominis, lateral to the rectus muscle.

Muscle wasting, multiparity, obesity and severe straining are precipitating factors.

Patients are usually elderly, complain mainly of localised constant or recurrent pain or discomfort made worse by coughing or straining and relieved by lying down.

Complications include irreducibility and strangulation. Operative repair is undertaken because of the risk of strangulation.

Results

Laparoscopy revealed a right Spigelian hernia. The defect was approximately 5cm containing small bowel with chronic adhesions to the hernial sac and the anterior abdominal wall.

Following careful sharp dissection of the small bowel by the surgical consultant, the defect in the anterior abdominal wall was exposed. Repair of the defect was performed using interrupted Nylon 1 sutures with Endo Close device. Thereafter, a mesh was placed and secured using tacks. She was discharged home after overnight observation.

Conclusions

This highlighted the possibility of non-gynaecological cause of pelvic pain. Considering unexpected findings and thorough discussion/informed consent for any required additional procedure meant that the surgeon was able to proceed with the repair. Also knowing one's own limitations, when and who to ask for assistance is important. The incidence of Spigelian hernias is low (0.12% to 2% of all abdominal wall hernias). Multi-disciplinary approach in its management is mandatory.

ESGE35-0019 - P036
ePoster Presentations

Medical management of atypical endometrial hyperplasia in young (≤40) pre-menopausal women: a 6 year retrospective review of cases from a North London Hospital

Chloe Hall[1], *Claudia Main*[1], *Akila Karthikeyan*[1]
[1]*North Middlesex University Hospital, Obstetrics and Gynaecology, London, United Kingdom*

Background

Atypical endometrial hyperplasia (AEH) is a precancerous condition, typically affecting peri- or postmenopausal women, characterised by abnormal endometrial thickening and an increased gland-to-stroma ratio. Risk factors include obesity, nulliparity, anovulation (e.g. perimenopause, PCOS), and some medications. Up to 40% of patients have concurrent endometrial cancer; therefore, surgical management (total hysterectomy with bilateral salpingectomy) is standard. However, in younger patients wishing to preserve their uterus, progestogen therapy with close surveillance may be used as an alternative.

Methods

We conducted a six-year retrospective review (2020–2025) of women aged ≤40 with AEH managed medically at a London district general hospital, examining risk factors and outcomes. Patients were identified via gynaecology oncology MDT records. Inclusion criteria were AEH on initial biopsy, age ≤40, and medical management with oral or intrauterine progesterone. Patients over 40, with alternative diagnoses, or managed surgically as first-line were excluded. Data were collected from case notes, MDT records, hysteroscopy reports, and histopathology.

Results

We identified 16 patients who met our inclusion criteria. The patients had an average age of 32 years old and an average BMI of 40.6 – 15/16 (94%) patients had a BMI in the obese range. Every patient had either confirmed (14) or suspected (2) PCOS. 14/16 (87.5%) patients were nulliparous. 4/16 (25%) were diagnosed with endometrial cancer at a subsequent biopsy - these patients were all diagnosed at their first follow up biopsy after treatment and it is possible, or even likely, that they were in the group of those with AEH who already have cancer at the time of initial diagnosis. One patient diagnosed with cancer opted to undergo hysterectomy, the other 3 continued medical management with subsequent regression. Including those who initially progressed, 12/16 (75%) achieved regression with hormonal management. 2 (12.5%) patients have maintained AEH. One patient has not yet had a follow up biopsy. No patient had progression to advanced stage or metastatic cancer. We had limited data on pregnancy outcomes, but from records could only confirm one live-birth from our cohort and this was in a patient with proven prior fertility.

Conclusions

Medical management of young patients with AEH is an incredibly safe and effective strategy. PCOS and obesity are universal risk factors in those aged ≤40, highlighting the importance of endometrial protection in PCOS, particularly in those with obesity. This is a significant public health issue given the

high prevalence of both conditions; obesity rates have doubled since the 1990s, with around 29% of adults affected (NHSE). As more patients may qualify for medical management, robust healthcare infrastructure is needed to support regular hysteroscopies and biopsies, alongside clear clinical frameworks and patient decision aids that address invasive follow-up burden, guarded fertility outcomes, and the psychological impact of either choice of treatment.

ESGE35-0031 - P037
ePoster Presentations

Frailty assessment as a predictor of postoperative outcomes in gynecologic surgery: comparison of minimally invasive and open approaches

Paweł SADŁECKI[1,2], *Małgorzata Walentowicz-Sadłecka*[1,2]
[1]*Regional Polyclinical Hospital, Department of Obstetrics- Gynaecology- and Gynaecologic Oncology, Grudziądz, Poland*
[2]*University of Science and Technology, Faculty of Medicine, Bydgoszcz, Poland*

Background

Frailty is increasingly recognized as a clinically relevant marker of reduced physiological reserve and postoperative vulnerability. This study aimed to evaluate the predictive value of frailty assessment for postoperative outcomes in women undergoing gynecologic surgery, with particular emphasis on differences between minimally invasive surgery and laparotomy.

Methods

This retrospective single-center study included 268 women who underwent surgical treatment for oncological and non-oncological gynecologic indications between June 2022 and December 2025. Surgical approaches included robot-assisted surgery using the CMR Versius system, conventional laparoscopy, and open surgery. Patients were stratified into two groups: minimally invasive surgery, including robotic and laparoscopic procedures, and laparotomy. Preoperative frailty was assessed using the Clinical Frailty Scale (CFS), the 11-item Modified Frailty Index (mFI-11), and the 5-item Modified Frailty Index (mFI-5). Postoperative outcomes included overall complications, reoperation, and delayed discharge. Logistic regression models and receiver operating characteristic curve analyses were used to evaluate the predictive performance of frailty-related scores.

Results

Among 268 patients, 211 underwent minimally invasive surgery and 57 underwent laparotomy. Age did not differ significantly between the groups, whereas oncological indications were more frequent in the laparotomy group. In patients undergoing laparotomy, both the mFI-11 and mFI-5 were significant predictors of postoperative complications. Each increase in the mFI-11 was associated with an approximately 2.69-fold higher odds of complications, while each increase in the mFI-5 was associated with an approximately 2.43-fold higher odds. Receiver operating characteristic analysis confirmed the predictive value of the mFI-11 for complications in the laparotomy group, with an area under the curve of 0.7245. In the minimally invasive surgery group, frailty indices were not significant predictors of postoperative complications. However, the CFS was a significant predictor of delayed discharge in this group, with each one-point increase associated with an approximately 1.90-fold higher odds of prolonged hospitalization.

Conclusions

Frailty assessment provides clinically useful information for perioperative risk stratification in gynecologic surgery. The Modified Frailty Index appears particularly relevant for predicting

postoperative complications after laparotomy, whereas the CFS may help identify patients at risk of delayed discharge after minimally invasive surgery. These findings support the incorporation of simple frailty tools into preoperative assessment to guide individualized surgical planning and postoperative care.

ESGE35-0046 - P039
ePoster Presentations

Peer Supported Consultant-to-Consultant Teaching Addressing Surgical Training Gaps in the UK Obstetrics and Gynaecology Specialist Training Programme

Joanna Brecher[1], *Chukwumaobi Uzowuru*[1], *Ranti Anthony*[1]
[1]*Princess Alexandra Hospital, Obstetrics and Gynaecology, Harlow, United Kingdom*

Background

This study aims to evaluate the extent of informal intraoperative support provided by senior gynaecology consultants to assess the demand for a formal, peer-supported consultant-to-consultant teaching model. The core objective is to address the widely recognised deficiency in gynaecological surgical training within the UK's postgraduate specialist education framework.

Methods

A targeted survey was distributed to gynaecology consultants in the UK with five or more years' experience. The research focused on the frequency of ad-hoc intraoperative assistance provided to junior consultants over a 24-month period, preferred teaching structures and the professional incentives required to formalise mentorship for newly appointed colleagues.

Results

A staggering 94% (n = 17) of senior consultants reported being called to theatre to provide emergency intraoperative support to a consultant colleague within the last two years. Data revealed that high-stakes procedures were the primary driver of this need, with 41% (n = 7) of respondents called to assist in total abdominal hysterectomies, complex caesarean sections and the surgical management of postpartum haemorrhage. There was 100% universal willingness among senior consultants to support newly appointed colleagues if teaching sessions are pre-arranged and structured. To enable this, 76% (n = 13) of respondents identified job plan adjustments as the most beneficial incentive. While 100% of senior consultants were prepared to offer teaching sessions locally, 35% were also open to supporting external units if appropriately renumerated.

Conclusions

The reliance on senior consultants for unplanned surgical support is a systematic reality in the UK, highlighting that newly qualified gynaecology consultants are entering the workforce with significant training gaps. However, there is an evident, untapped willingness among senior clinicians to formalise additional surgical training support. This study emphasises that transitioning from 'emergency call-outs' to 'pre-planned peer teaching' is achievable but requires Trusts to prioritise job plan flexibility and professional recognition over ad-hoc solutions.

ESGE35-0049 - P040
ePoster Presentations

Toward a Combined Surgical and Medical Strategy for Definitive Endometriosis Surgery: Experience with 535 Cases Without Ureteral Injury

Hiroyuki Kobori[1], Noriko Kato[1], Chisato Noji[1], Noriko Yamamoto[1], Yuko Kumakiri[1], Tomoko Hagiwara[1]
[1]Medical Topia Soka Hospital, Gynaecology, Saitama, Japan

Background

Definitive surgery for severe endometriosis is technically demanding and is associated with an increased risk of perioperative complications, particularly ureteral injury. This study aimed to evaluate the safety and clinical outcomes of a landmark-based, minimal-dissection strategy for total laparoscopic hysterectomy with salpingo-oophorectomy in patients with endometriosis, and to explore the role of postoperative medical therapy for residual or recurrent symptoms.

Methods

We retrospectively reviewed patients with endometriosis who underwent total laparoscopic hysterectomy with unilateral or bilateral salpingo-oophorectomy at our institution between April 2012 and December 2025. Our perioperative strategy consisted of careful preoperative assessment using pelvic examination, ultrasonography, and magnetic resonance imaging; selection of surgical candidates according to disease severity, surgeon experience, and institutional resources; and consideration of preoperative GnRH analogue therapy when appropriate. Intraoperatively, we used a colpotomy cup as a surgical landmark, began adhesiolysis from less adhesive cranial areas, avoided excessive dissection around the posterior vaginal fornix, and limited deep endometriosis resection to large lesions. Bowel endometriosis without stenosis was managed conservatively. Postoperatively, estrogen replacement therapy was considered after bilateral salpingo-oophorectomy according to age and symptoms, and dienogest was considered when pain persisted or recurred, or when enlargement of a preserved ovary was observed. Ureteral integrity was assessed by cystoscopic observation at the end of surgery and postoperative ultrasonographic evaluation for hydronephrosis.

Results

A total of 535 patients underwent surgery for endometriosis during the study period. No ureteral injuries were observed. One patient required surgical hemostasis for postoperative bleeding, and one patient had suspected rectal injury, which was managed conservatively. In the subgroup previously reported using this non-aggressive strategy, the mean operative time was 108.0 ± 26.8 minutes and the mean blood loss was 110.8 ± 126.0 g. Additional postoperative medical therapy for recurrent pain or ovarian enlargement was required in only a small proportion of patients.

Conclusions

A landmark-based, minimal-dissection strategy for definitive endometriosis surgery may achieve both safety and therapeutic efficacy. Rather than pursuing aggressive excision of all deep endometriotic lesions, a balanced approach that combines safe surgery with selective postoperative medical

therapy, such as dienogest for persistent or recurrent pain, may represent a practical future model for the management of severe endometriosis.

ESGE35-0078 - P041
ePoster Presentations

Isolated Fallopian Tube Torsion in a Single Centre in Singapore: A Case Series and Sonographic Features for Diagnosis

V Lakshmi Dhevi[1], Meei Jiun Seet[1], Marielle Valerie Fortier[2], Thida Win[2]
[1]KK Womens and Children's Hospital, Obstetrics and Gynaecology, Singapore, Singapore
[2]KK Womens and Children's Hospital, Radiology, Singapore, Singapore

Background

Isolated fallopian tube torsion is a rare gynaecological emergency. Although its true incidence is unknown, it is estimated to occur in approximately 1 in 1,500,000 women. Patients often present with non-specific symptoms, making diagnosis challenging, as there are currently no pathognomonic clinical, imaging, or laboratory features. In our centre, diagnosis is frequently suspected sonographically and subsequently confirmed surgically. We aimed to identify sonographic features characteristic of isolated fallopian tube torsion.

Methods

This is a single-centre retrospective case series of 13 surgically confirmed cases of isolated fallopian tube torsion managed at a tertiary hospital in Singapore between 2011 and 2019. The median age was 16 years (range 10 - 35). All patients presented with abdominal pain, and 11 of 13 also reported nausea or vomiting. Seven cases involved the right fallopian tube and six involved the left.

Results

All 13 patients underwent pelvic ultrasound prior to surgery. Eight cases were accurately diagnosed pre-operatively on ultrasound. In all eight cases, a whirlpool sign or twisted pedicle was identified. This appeared as a convoluted tubular structure in the adnexa adjacent to the ovary, with a mean maximum diameter of 2.6cm (range 1.6 – 4.9cm). Twelve patients had concurrent tubal pathologies, including hydrosalpinx, paratubal cyst, tubal cyst, mesothelial inclusion cyst, cystadenofibroma, serous cystadenoma and follicular cyst. These were visualised on ultrasound as adnexal cystic or mass-like lesions separate from the ovary, with maximum diameter ranging from 2.0 – 10.5cm.

Conclusions

A high index of suspicion is required for timely diagnosis of isolated fallopian tube torsion. Ultrasound features suggestive of this condition include a fallopian tube pathology seen as a cystic or mass-like adnexal structure separate from the ovary, and a twisted pedicle or whirlpool sign located between this structure and the ipsilateral ovary. Pelvic ultrasound is a useful and effective first-line imaging modality for suspected isolated fallopian tube torsion.

ESGE35-0080 - P042
ePoster Presentations

Clinical Outcomes of Microwave Ablation in the Management of Uterine Fibroids: A Case Series of Ten Patients

Josif Goreski[1], Iva Gjoreska Malahova[2], Aleksandar Gjoreski[3], Irena Shuplinovska[4], Katerina Nikoloska[5]
[1]Clinical Hospital Acibadem Sistina - Skopje, Gynaecology and Obstetrics, Skopje, Macedonia- Former Yugoslav Republic.
[2]University Clinic of Gynaecology and Obstetrics, Urogynaecology, Skopje, Macedonia- Former Yugoslav Republic.
[3]Clinical Hospital Acibadem Sistina - Skopje, Radiology, Skopje, Macedonia- Former Yugoslav Republic.
[4]Clinical Hospital Acibadem Sistina - Skopje, Gynaecology and Obstetrician, Skopje, Macedonia- Former Yugoslav Republic.
[5]University Clinic of Gynaecology and Obstetrics, Oncogynaecology, Skopje, Macedonia- Former Yugoslav Republic.

Background

Uterine fibroids are the most common benign tumors of the female reproductive system and are frequently associated with symptoms such as abnormal uterine bleeding and pelvic pain. Minimally invasive techniques, including microwave ablation (MWA), have emerged as promising alternatives to conventional surgical management.

Methods

This case series included ten patients with symptomatic uterine fibroids treated with ultrasound-guided microwave ablation. The cohort comprised two patients with solitary intramural fibroids measuring 7 cm and 8 cm, four patients with two intramural fibroids each (ranging from 3–5 cm), and four patients with multiple fibroids measuring between 2–5 cm. Clinical and imaging follow-up assessments were performed to evaluate fibroid volume reduction and symptom improvement.

Results

All patients demonstrated a significant reduction in fibroid size, with a decrease in volume exceeding 50% at follow-up. Clinically, 80% of patients reported marked improvement in menometrorrhagia, while 85% experienced substantial relief of pelvic pain. No major complications were observed.

Conclusions

Microwave ablation appears to be an effective and safe minimally invasive treatment option for patients with uterine fibroids, leading to significant reduction in fibroid size and meaningful improvement in symptoms. These findings support the potential role of MWA as an alternative to more invasive surgical approaches, particularly in patients seeking uterine preservation.

ESGE35-0091 - P044
ePoster Presentations

Detection Method Strongly Influences Reported Incidence of Intrauterine Adhesions

Christina Salazar[1], Angelo Hooker[2], Bala Bhagavath[3], Heather Huddleston[4], Ian Feldberg[5]
[1]The University of Texas at Austin- Dell Medical School, Minimally Invasive Gynecologic Surgery, Austin, USA
[2]Zaans Medical Center, Obstetrics and Gynaecology, Zaandam, The Netherlands
[3]University of Wisconsin, Obstetrics and Gynaecology, Madison, USA
[4]University of California- San Francisco, Reproductive Sciences, San Francisco, USA
[5]IBF Consulting Services, Consulting, Sudbury, USA

Background

To investigate the large discrepancy between low intrauterine adhesion (IUA) incidence estimates reported in administrative data and substantially higher rates reported in the literature, and to examine how detection method, follow-up intensity, and underlying procedure population influence reported incidence.

Methods

Comparative methodological analysis of administrative data and published systematic review/meta-analytic literature of women undergoing uterine evacuation.

Results

Incidence estimates were examined from: 1) a large retrospective administrative cohort of women undergoing dilation and curettage; and 2) published systematic review/meta-analytic literature reporting IUA incidence prospectively collected after intrauterine procedures including evacuation of products of conception. Administrative data showed a low cumulative incidence of IUAs of approximately 0.8%, based on clinically coded diagnoses. In contrast, published literature has reported substantially higher incidence estimates, including rates around 20% or more in some procedural populations when systematic follow-up and direct uterine assessment with second look hysteroscopy are performed. These differences suggest that reported IUA burden is influenced not only by ascertainment method and intensity of follow-up, but also by the underlying clinical population being evaluated. CPT-coded procedural groups should therefore not be assumed to represent a uniform adhesiogenic risk when interpreting incidence estimates.

Conclusions

Reported IUA incidence varies substantially across clinical contexts and is strongly influenced by detection methodology, follow-up intensity, and the procedure populations under study. Studies relying on administrative diagnosis likely underestimate true disease burden, whereas studies incorporating systematic follow-up provide a more complete characterization of postoperative adhesions. These findings have important implications for both disease awareness and interpretation of the literature.

ESGE35-0103 - P045
ePoster Presentations

Ruptured Ovarian Mature Cystic Teratoma Causing Chemical Peritonitis: A Rare Cause of Acute Abdomen

Rahila Bhand[1], Roxanne Zhi Xin Gan[1], Christina Pappa[1], Andreas Zouridis[1]
[1]Oxford University Hospitals NHS, Gynaecology, Oxford, United Kingdom

Background

Mature cystic teratomas are common benign ovarian tumours in reproductive-age women. Spontaneous rupture is uncommon but may lead to chemical peritonitis secondary to spillage of sebaceous material into the peritoneal cavity, creating diagnostic and surgical challenges.

Methods

That is a case presentation

Results

A 23-year-old nulliparous woman presented with a three-day history of worsening right iliac fossa pain associated with nausea, vomiting and anorexia. Clinical examination demonstrated localised tenderness and guarding with features of peritonism. Laboratory investigations showed leukocytosis and elevated inflammatory markers. CT imaging demonstrated an 8–9 cm fat-containing cystic pelvic mass with peripheral calcifications, free pelvic fluid and diffuse peritoneal enhancement suggestive of peritonitis. Malignant peritoneal disease could not initially be excluded.

Following urgent multidisciplinary review, exploratory laparoscopy was performed. Extensive inflammatory adhesions and reactive peritoneal fluid were identified. The right ovary was replaced by a ruptured dermoid cyst with leakage of sebaceous material and hair. Due to severe inflammation and distorted tissue planes, right salpingo-oophorectomy, omental biopsy and extensive peritoneal lavage were undertaken.

Histopathology confirmed a ruptured benign mature cystic teratoma with granulomatous inflammation and foreign-body giant cell reaction without evidence of malignancy. Postoperative recovery was complicated by prolonged inflammatory response and respiratory complications requiring readmission and supportive treatment.

Conclusions

Ruptured dermoid cysts are a rare but important differential diagnosis in young women presenting with acute abdomen. Recognition of characteristic imaging findings and timely minimally invasive surgical management with meticulous peritoneal lavage are essential to minimise morbidity.

ESGE35-0112 - P046
ePoster Presentations

Exploring Hypoxia-Driven Mechanisms in Endometriosis: A Pilot Study Using Patient-Derived Endometrial Organoids

Monika Dugatova[1], Petra Belvoncikova[2], Barbora Puzderova Barbora[2], Kamila Bernathova[2], Redecha Mikuláš[1], Monika Barathova[2]
[1]Bory Hospital- I. Kadlečíka 6851/2- 841 03 Bratislava- Slovakia,
Department of Obstetrics and Gynaecology, Bratislava, Slovakia
[2]Mabpro- a.s.- Dubravska cesta 9- Bratislava- Slovakia,
Biomedical Research Center- Slovak Academy of Sciences- Dubravska cesta 9- Bratislava- Slovakia, Bratislava, Slovakia

Background

Endometriosis is a chronic estrogen-dependent disease characterized by the presence of endometrial-like tissue outside the uterine cavity. It affects approximately 10% of women of reproductive age. The endometriotic microenvironment has received increasing attention in studies of disease pathogenesis. Hypoxia is a key component of this microenvironment and represents one of the first stressors encountered by retrogradely displaced endometrial tissue. Cellular adaptation to oxygen deprivation is mediated primarily by the transcription factors HIF-1 and HIF-2, which regulate the expression of a broad range of genes. Carbonic anhydrase IX (CA IX) is considered a key enzyme of hypoxic adaptation and one of the most reliable markers of hypoxia. This pilot study aimed to establish three-dimensional endometrial organoid models from fresh patient tissue and to investigate hypoxic signaling in endometriosis.

Methods

Native endometrial tissue samples were obtained during surgical procedures. The study was approved by the Ethics Committee of Bory Hospital (no. 001-2025), and all patients provided written informed consent. Endometrial organoids (EMOs) were prepared from fresh tissue. The growth and viability of EMOs were assessed by immunofluorescence using confocal microscopy. The presence of hypoxia and the hypoxia marker CA IX was evaluated in FFPE tissue samples by immunohistochemistry. The expression of hypoxia-related markers was analysed using qPCR.

Results

The pilot study included 13 patients with histologically confirmed endometriosis or adenomyosis. Patients undergoing surgery had ultrasound-confirmed endometriosis according to the IDEA protocol or adenomyosis according to MUSA criteria. They also reported pain refractory to hormonal treatment. We optimized the protocol for the preparation of EMOs. EMOs were successfully established from native tissue in 9 of 13 patients (69.2%). Confocal microscopy confirmed the expression of the hypoxia marker CA IX in EMOs. Immunohistochemical staining demonstrated CA IX protein positivity in 5 patients (38.5%). qPCR analysis further confirmed the activation of hypoxic signaling through the expression of hypoxia-regulated genes, including VEGF-A.

Conclusions

We have successfully established patient-derived EMOs and demonstrated expression of the hypoxia-associated protein CA IX in this system. In FFPE samples, CA IX positivity was detected in 5 of 13 cases (38.5%), further supporting the relevance of hypoxia in vivo. In addition, the presence of other hypoxia-related markers was confirmed at the transcriptional level by qPCR. These results highlight the importance of hypoxia-driven mechanisms in endometriosis and demonstrate that EMOs represent a state-of-the-art in vitro platform for investigating hypoxic adaptation in endometriosis.

ESGE35-0132 - P047
ePoster Presentations

Hysteroscopic repair of isthmocele: a case series of 10 patients

Razvan Socolov[1], Loredana Toma[2], Madalina Ciuhodaru[1], Demetra Socolov[1], Gabriela Dumachita Sargu[3], Andreea Pruteanu[1]
[1]Grigore T Popa University of medicine and pharmacy- Iasi, Department of Mother and Child Medicine, Iasi, Romania
[2]Grigore T Popa University of medicine and pharmacy- Iasi, Department of Biomedical Science, Iasi, Romania
[3]Grigore T Popa University of medicine and pharmacy, Department of Morpho-functional sciences no 1, Iasi, Romania

Background

Isthmocele, also known as caesarean scar defect or uterine niche, is an acquired diverticulum-like pouch located at the anterior lower uterine segment at the site of a previous caesarean section scar. The primary objective of this study was to evaluate the safety, feasibility, and clinical efficacy of hysteroscopic repair in patients with symptomatic isthmocele. Secondary objectives included assessment of symptom resolution, fertility outcomes, and the role of this minimally invasive technique in the context of the globally rising caesarean section rates, which are expected to increase the future incidence of isthmocele.

Isthmocele classification is based primarily on defect depth and residual myometrial thickness (RMT). Defects are typically categorized as small (<5 mm), medium (5–10 mm), or large (>10 mm). RMT is the key safety parameter: RMT <3 mm carries higher risks of uterine rupture in future pregnancies, while RMT >4 mm permits safe hysteroscopic repair. Additional hysteroscopic classifications consider niche shape (triangular, semicircular) and the presence of fibrotic tissue. Symptomatic isthmocele commonly present with abnormal uterine bleeding (AUB), especially heavy menstrual bleeding or prolonged postmenstrual spotting, secondary infertility, dysmenorrhea, and chronic pelvic pain. Coexisting uterine fibroids may worsen symptoms.

Methods

This retrospective case series included 10 patients who underwent hysteroscopic isthmocele repair at our center between 2023 and 2025. Inclusion criteria were symptomatic isthmocele (abundant uterine bleeding and/or infertility) with defect depth between 6 mm and 18 mm and residual myometrial thickness (RMT) >4 mm, confirmed by transvaginal ultrasound and diagnostic hysteroscopy. Associated uterine fibroids were present in several cases.

The surgical technique involved complete resectoscopy excision of the fibrotic tissue at the base and margins of the niche to restore a normal uterine cavity contour. In 3 out of 10 cases (30%), additional shaving of the isthmocele margins was performed to promote optimal re-epithelialization.

Results

No intraoperative complications (uterine perforation, hemorrhage, or fluid overload) were recorded. All patients were discharged within 24 hours.

At follow-up, all patients experienced significant reduction or complete resolution of symptoms, with normalization of menstrual bleeding. Two of the ten patients (40% of those with infertility) achieved spontaneous pregnancy within one year after the intervention.

Conclusions

Hysteroscopic resectoscopy, with or without margin shaving, is a safe, effective, and fertility-preserving treatment for symptomatic isthmocele when RMT exceeds 4 mm. The procedure provided excellent symptom relief and a 20% pregnancy rate in this series. Given the projected rise in caesarean deliveries worldwide and the consequent increase in isthmocele incidence, hysteroscopic repair should be actively promoted and taught as a first-line minimally invasive option. Larger prospective multicentre studies with longer follow-up are warranted to confirm these promising results and establish standardized protocols.

ESGE35-0140 - P048
ePoster Presentations

Challenging diagnosis of broad ligament fibroid with myxoid degeneration: a case report

Bassem Skaff[1], Marita Saliba[2], Omar Alameddine[3], Sara El Lakiss[4]
[1]New Mazloum Hospital, Gynaecology and obstetrics, Tripoli, Lebanon
[2]University Of Balamand, obstetrics and Gynaecology, Beirut, Lebanon
[3]American university of Beirut, obstetrics and Gynaecology, Beirut, Lebanon
[4]New Mazloum Hospital, Radiology, Tripoli, Lebanon

Background

Broad ligament leiomyomas arise either as extensions of uterine fibroids or as primary lesions within the broad ligament. the primary type is typically non-pedunculated and represents an uncommon entity, accounting for less than 1% of all leiomyomas, posing a radiologic diagnostic challenge. we report the case of a 44-year-old woman presenting for chronic pelvic pain, leading to intraoperative diagnosis of broad ligament fibroid that was misdiagnosed by ultrasound (us) and magnetic resonance imaging (MRI).

Methods

A 44-year-old patient g7p4a3 with four previous vaginal deliveries and 3 spontaneous abortions, regular cycles, presented for chronic pelvic pain and abnormal vaginal bleeding of a few months duration. an ultrasound was performed, showing an anteverted uterus of normal size and echotexture, normal right ovary, and a 9 centimetre complex left ovarian mass. further evaluation was prompted for better assessment through tumor marker values and a pelvic MRI. Laboratory values reported were as follow: lactate dehydrogenase (LDH) 136 iu/l, beta-HCG: 1.00 mIU/ml, alpha-fetoprotein (AFP): 2.66 ng/ml, carcinoembryonic antigen (CEA): 0.92 ng/ml and cancer antigen 125 (ca-125): 44.45 mIU/ml. MRI of the pelvis showed large left adnexal lesion, heterogeneously predominantly, showing thick peripheral core and central fluid matrix, sharply circumscribed without diffusion restriction and having thin peripheral enhancement. the lesion is saccular like estimated 10 cm x 2cm x 5.3cm; 127 ml in volume. differential diagnoses included benign left complex ovarian cyst, left paraovarian cyst, endometriosis cyst, subserosal fibroid or gastrointestinal stromal tumor. Laparoscopy was decided.

Results

During laparoscopy, retroperitoneal dissection was performed, and a non-pedunculated mass was noted in the left broad ligament, suggesting leiomyoma with no blood supply from the uterus, but by diffusion from the peritoneum. bilateral ovaries and uterus were normal. excision of the fibroid was done. hemostasis was ensured with no intraoperative complications, and the post-operative phase was uneventful. histopathology confirmed the diagnosis of broad ligament fibroid with myxoid degeneration.

Conclusions

This case highlights the diagnostic challenges around broad ligament fibroids, that receive blood flow by diffusion from the peritoneum, and not by a pedicle through the uterus. their location poses diagnostic issues and might delay appropriate treatment. ultrasound and mri in that case failed to accurately diagnose the leiomyoma, requiring laparoscopy for definitive diagnoses and management.

Patient consent has been obtained for anonymous presentation and publication.

ESGE35-0142 - P049
ePoster Presentations

A rare case of benign inguinal leiomyoma presenting as an inguinal hernia

Anusha Bhattacharjee[1], Kaustav Bhattacharjee[2], Parijat Bhattacharjee[3], Aruna Munasinghe[4]
[1]The Hillingdon Hospital, General Surgery, London, United Kingdom
[2]Medical University Plovdiv, Student, Plovdiv, Bulgaria
[3]North West London Hospitals NHS Trust, Gynaecology, London, United Kingdom
[4]Clementine Churchill Hospital, Bariatric Surgery, London, United Kingdom

Background

To highlight the diagnostic challenge of inguinal leiomyoma presenting as an inguinal hernia and emphasise the importance of maintaining a broad differential diagnosis for inguinal masses in women.

Methods

A 50-year-old woman presented with persistent right inguinal swelling associated with discomfort but without significant gastrointestinal symptoms. She was receiving hormone replacement therapy and had a previous history of transcervical fibroid resection. Clinical examination identified a 5 × 3 cm right inguinal mass without a cough impulse. Magnetic resonance imaging (MRI) demonstrated a 4.6 × 3.6 cm solid lesion within the right inguinal canal, continuous with the round ligament. Multidisciplinary assessment involving gastrointestinal and gynaecological surgeons was undertaken. Joint surgical excision of the mass was performed, followed by histopathological examination.

Results

Intraoperative findings demonstrated a well-circumscribed mass arising from the round ligament within the right inguinal canal. The lesion was successfully excised without complications. Histopathological analysis confirmed a benign leiomyoma. The patient had an uneventful postoperative recovery. The clinical presentation closely mimicked an incarcerated inguinal hernia, highlighting the diagnostic difficulty associated with this rare condition.

Conclusions

Round ligament leiomyoma is a rare cause of inguinal swelling that can mimic an incarcerated inguinal hernia. Careful clinical assessment, imaging, and multidisciplinary surgical planning are essential for accurate diagnosis and safe management. Consideration of this uncommon differential diagnosis may help avoid misdiagnosis and inappropriate treatment in women presenting with atypical inguinal masses.

ESGE35-0146 - P050
ePoster Presentations

Massive hematocolpos mimicking adnexal malignancy with elevated CA 19-9 in an adolescent: diagnostic challenges and minimally invasive management

Elif Irem Kavutçu[1], *Yusuf Üstün*[1], *Murat Gözüküçük*[1]
[1]*Ankara Research and Training Hospital, Obstetrics and Gynaecology, Ankara, Türkiye*

Background

Imperforate hymen is a rare obstructive congenital anomaly that may present during adolescence with hematocolpos and severe pelvic distension. In rare cases, markedly elevated tumor markers and distorted pelvic anatomy may closely mimic adnexal malignancy, leading to significant diagnostic and therapeutic challenges.

Methods

A 15-year-old adolescent girl presented with acute pelvic and perineal pain, progressive abdominal distension, and primary amenorrhea. Ultrasonography demonstrated a giant cystic pelvic mass extending to the umbilical level, while ovarian origin could not initially be excluded. Magnetic resonance imaging (MRI) revealed a 14×12×21 cm hemorrhagic cystic lesion filling the vagina and pelvis with associated bladder compression. Serum CA 19-9 level was markedly elevated (605 U/mL). Clinical, radiological, surgical, and postoperative findings were evaluated.

Results

Severe vaginal distension prevented adequate visualization of normal anatomy during examination. Minimally invasive needle aspiration through the imperforate hymen confirmed retained menstrual blood and established the diagnosis of massive hematocolpos. Hymenotomy with drainage of approximately 400 mL retained blood and excision of excess hymenal tissue was successfully performed. Histopathological examination demonstrated inflamed congested mucosa without evidence of malignancy. Postoperative imaging confirmed restoration of normal pelvic anatomy and complete resolution of the cystic distension. The patient experienced full symptomatic relief and menstrual normalization.

Conclusions

Massive hematocolpos should be considered in adolescent patients presenting with pelvic pain, primary amenorrhea, and giant pelvic masses, even in the presence of markedly elevated tumor markers suggestive of malignancy. Early recognition of obstructive genital tract anomalies and minimally invasive diagnostic confirmation may prevent unnecessary extensive surgical interventions and optimize patient outcomes.

ESGE35-0196 - P052
ePoster Presentations

The GYRO score: a novel clinical scoring system for risk stratification and surgical decision-making in suspected ovarian torsion

Panagiotis Vlastarakos[1], Mohamed Ragab[2], Jesner Ora[1], Nandita Deo[1]
[1]Whipps Cross Hospital- Barts NHS Health Trust, Emergency Gynaecology Unit, London, United Kingdom
[2]Whipps Cross Hospital- Barts NHS Health Trust, Obstetrics and Gynaecology, London, United Kingdom

Background

Ovarian torsion accounts for 3–5% of acute gynaecological emergencies, with an estimated incidence of 2–7 per 100,000 women annually. Delayed diagnosis carries a significant risk of oophorectomy and permanent fertility loss. This study aimed to develop a simple point-based clinical scoring system to stratify the probability of ovarian torsion and support timely surgical decision-making.

Methods

A retrospective cohort study was conducted at Whipps Cross Hospital, London (2020–2025), including 93 patients who underwent emergency surgery for suspected ovarian torsion. Multivariable logistic regression was used to identify independent clinical predictors, and integer points were assigned in proportion to the adjusted odds ratios (aORs). Model discrimination was evaluated using the area under the receiver operating characteristic curve (AUC).

Results

Torsion was confirmed in 58 of 93 patients (62.4%). Multivariable analysis identified three independent predictors: dermoid cyst histology (aOR 3.58, p=0.034), vomiting at presentation (aOR 3.17, p=0.025), and adnexal cyst size ≥7 cm (aOR 2.78, p=0.040). Symptom duration of less than 12 hours demonstrated borderline significance (aOR 4.09, p=0.089) and was retained in the final model. The resulting GYRO score ranges from 0 to 14 points and achieved an AUC of 0.789 (p<0.001), reflecting good overall discriminatory performance. Risk stratification into Low-Risk (score 0–4) and High-Risk (score 6–14) categories yielded confirmed torsion rates of 35.6% and 87.5%, respectively (OR 12.69, p<0.001), with a sensitivity of 72.4%, specificity of 82.9%, and positive predictive value (PPV) of 87.5%.

Conclusions

The GYRO score is a straightforward, four-variable point-based tool offering robust discriminatory ability for ovarian torsion risk stratification. Its high PPV in the high-risk category supports prompt surgical intervention to reduce the risk of adnexal loss, while its specificity may help avoid unnecessary operations in low-risk presentations. Prospective external validation across multiple centres is warranted before widespread clinical adoption.

ESGE35-0199 - P053
ePoster Presentations

Primary abdominal ectopic pregnancy implanted on the sigmoid mesentery: a case report and literature review

Mohamed Ragab[1], Panagiotis Vlastarakos[2], Ora Jesner[2], Nandita Deo[2], Sotiris Vimplis[1], Fredric Willmott[1]
[1]Whipps Cross Hospital- Barts NHS Health Trust, Gynaecological Oncology Unit, London, United Kingdom
[2]Whipps Cross Hospital- Barts NHS Health Trust, Emergency Gynaecology Unit, London, United Kingdom

Background

Abdominal ectopic pregnancy accounts for fewer than 1% of all ectopic gestations. Implantation on the sigmoid mesentery is exceptionally rare and poses considerable diagnostic and surgical challenges, primarily due to the risk of life-threatening haemorrhage.

Methods

A 27-year-old woman presented with severe abdominal pain, haemodynamic instability, and a significant drop in haemoglobin. CT imaging demonstrated massive haemoperitoneum in the absence of an intrauterine pregnancy. Emergency diagnostic laparoscopy revealed approximately three litres of intraperitoneal blood. An ectopic pregnancy implanted on the sigmoid mesentery was identified, with no tubal or ovarian involvement. Pregnancy tissue was carefully dissected from the mesenteric surface and haemostasis was achieved using bipolar diathermy. Bowel resection was not required. Histopathological examination confirmed the presence of products of conception.

Results

A systematic literature review identified 16 previously reported cases of ectopic pregnancy implanted on the sigmoid mesentery or mesocolon. The majority presented with abdominal pain and haemoperitoneum, frequently in the context of haemodynamic compromise. Ultrasound commonly failed to localise the implantation site, whereas CT or MRI improved both diagnostic accuracy and preoperative surgical planning. Reported management strategies included laparoscopic and open surgical approaches, with the extent of mesenteric involvement and vascular anatomy guiding the choice between complete tissue excision and conservative haemostatic techniques.

Conclusions

Sigmoid mesentery ectopic pregnancy represents one of the rarest and most surgically demanding implantation sites encountered in gynaecological practice. Prompt recognition and immediate surgical intervention are critical given the potential for life-threatening haemorrhage. Optimal outcomes depend on a multidisciplinary approach, with colorectal surgical support readily available in view of the proximity to the bowel. This case adds to the limited published literature, the continued accumulation of which remains essential to inform future surgical decision-making.

ESGE35-0201 - P054
ePoster Presentations

Ectopic pregnancy management in a dedicated early pregnancy unit: a retrospective audit of treatment outcomes across all modalities

Panagiotis Vlastarakos[1], Nandita Deo[1], Mehrnoosh Aref-Adib[1], Anupama Shahid[1], Funlayo Odejinmi[1], Ora Jesner[1]
[1]Whipps Cross Hospital- Barts NHS Health Trust, Emergency Gynaecology Unit, London, United Kingdom

Background

Ectopic pregnancy management has evolved beyond purely surgical intervention, with expectant and medical approaches now recognised as safe and effective in appropriately selected patients. This audit evaluates management strategies and clinical outcomes across all treatment modalities within a dedicated early pregnancy unit.

Methods

A retrospective audit was conducted of 140 consecutive ectopic pregnancy cases managed during 2025. Haemodynamically stable patients were stratified according to serial serum hCG trends. Expectant management was offered for hCG below 1000 IU/L or with a decline of ≥15%; methotrexate or surgical intervention was offered for hCG below 5000 IU/L with minimal decline or a rising trend. Laparoscopic salpingectomy or salpingotomy was performed based on patient preference, the presence of a live ectopic, or rupture. Eleven patients initially allocated to methotrexate subsequently requested surgery following a change of preference and were incorporated into the surgical group. The final cohort comprised surgical (n=84), expectant (n=48), and methotrexate (n=8) management groups, with median hCG values of 2340, 282, and 1799 IU/L respectively. The series included five interstitial ectopic managed by cornuotomy or wedge resection, one abdominal ectopic implanted on the sigmoid mesentery, one ovarian ectopic, and five caesarean scar ectopic managed by ultrasound-guided dilatation and curettage.

Results

Of 48 expectantly managed patients, 11 required subsequent intervention, yielding a success rate of 77.1%. Reasons for intervention included pain leading to elective laparoscopy (n=4), sonographic growth of the gestational mass (n=3), a leaking ectopic (n=3), and rupture (n=1). Of 8 patients receiving methotrexate, 2 required surgical rescue, yielding a success rate of 75.0%; indications were pain (n=1) and a growing ectopic on follow-up (n=1). Both success rates are consistent with published benchmarks (expectant: 66–91%; methotrexate: 65–95%).

Conclusions

A structured, protocol-driven approach within a dedicated early pregnancy unit achieves outcomes comparable to published benchmarks across the full spectrum of ectopic pregnancy presentations, including rare and surgically complex implantation sites. These findings support the feasibility and safety of a multimodal management strategy in a specialised unit setting.

ESGE35-0203 - P055
ePoster Presentations

Ultrasound-guided evacuation as primary management for caesarean scar pregnancy: a single-centre retrospective audit

Panagiotis Vlastarakos[1], Nandita Deo[1], Mehrnoosh Aref-Adib[1], Funlayo Odejinmi[1], Anupama Shahid[1], Ora Jesner[1]
[1]Whipps Cross Hospital- Barts NHS Health Trust, Emergency Gynaecology Unit, London, United Kingdom

Background

To evaluate the clinical presentation and outcomes of caesarean scar pregnancy (CSP) managed within a dedicated emergency gynaecology unit (EGU).

Methods

A retrospective audit was conducted of 28 CSP cases managed at the EGU between 2020 and 2025. One patient did not attend for treatment and was excluded, leaving 27 cases for analysis. Median gestational age at diagnosis was 7 weeks (IQR 5+4 to 8+2). Presenting complaints included vaginal bleeding alone (n=17), combined vaginal bleeding and abdominal pain (n=6), abdominal pain alone (n=3), and incidental asymptomatic findings (n=2). Median number of prior caesarean sections was 2 (IQR 1–2). Median serum hCG at diagnosis was 11,488 IU/L (IQR 898–41,147) and median progesterone was 43 nmol/L (IQR 16–66). Management was individualised based on clinical presentation, haemodynamic status, and ultrasound characteristics.

Results

Twenty-five patients underwent ultrasound-guided evacuation of retained products of conception (ERPC) as primary management; 24 received intraoperative uterotonics and 8 underwent prophylactic cervical cerclage. Three patients subsequently required further intervention — one diagnostic and therapeutic laparoscopy and two courses of systemic methotrexate for persistent retained products — yielding a primary ERPC success rate of 88%. One patient was managed expectantly and one underwent primary laparoscopy. Median estimated blood loss was 150 ml (IQR 100–200 ml). Two patients required postoperative blood transfusion; both had low pre-operative haemoglobin levels.

Conclusions

Ultrasound-guided ERPC with intraoperative uterotonics represents an effective primary management strategy for CSP, achieving an 88% success rate with acceptable blood loss. Selective use of prophylactic cervical cerclage and a structured multidisciplinary approach may further optimise outcomes. Standardisation of CSP diagnostic criteria and management protocols across institutions remains essential to enable meaningful comparison of published data. These findings represent preliminary results of an ongoing audit.

ESGE35-0213 - P056
ePoster Presentations

Observer Variability in FIGO Fibroid Classification: The Added Value of Gel-Enhanced Transvaginal Sonography

Jolien Haesen[1], Fleur Van Cleuvenbergen[1], Wouter Froyman[1], Dirk Timmerman[1], Arne Vanhie[1], Thierry Van den Bosch[1]
[1]UZ Leuven, Obstetrics & Gynaecology, Leuven, Belgium

Background

The objective of the study is to determine whether 2D/3D gel instillation sonography (GIS) provides greater accuracy in the FIGO classification and volume measurements of uterine fibroids compared to unenhanced 2D/3D transvaginal ultrasound (TVUS) without fluid instillation.

Methods

This prospective, single-center, observational pilot study included 14 patients referred for fibroid assessment. Two raters, a non-expert and an expert rater independently evaluated offline 3D ultrasound volumes at two timepoints. Fibroids were classified according to the FIGO classification system and volumes were calculated using three perpendicular diameters. Agreement was assessed using Cohen's kappa coefficient and intraclass correlation coefficient (ICC).

Results

For TVUS, intra-observer agreement was fair for FIGO classification (κ = 0.29) and good for fibroid volume (ICC = 0.86). Inter-observer agreement remained limited (κ = 0.06 to 0.32), with poor volume agreement (ICC = 0.43 to 0.34).

For GIS, intra-observer agreement for FIGO classification was almost perfect (κ = 0.84) and good for fibroid volume (ICC = 0.89), with inter-observer agreement improving to almost perfect at timepoint 2 (κ = 0.88, ICC = 0.91).

Conclusions

Intra-observer agreement for both FIGO classification and fibroid volume was good to almost perfect using 3D GIS, with almost perfect inter-observer agreement achieved at second timepoint. In contrast, TVUS showed only fair intra-observer agreement for FIGO classification and limited inter-observer agreement across all timepoints. These findings suggest that 3D GIS provides added value in discriminating between FIGO classes of uterine fibroids compared to TVUS, particularly in the hands of a non-expert rater.

ESGE35-0214 - P057
ePoster Presentations

A rare case of misdiagnosed benign cervical adenomyoma presenting as a prolapsing fibroid

Kaustav Bhattacharjee[1], Anusha Bhattacharjee[2], Parijat Bhattacharjee[3]
[1]Medical University Plovdiv, Student, Plovdiv- Bulgaria, United Kingdom
[2]The Hillingdon Hospital, General Surgery, London, United Kingdom
[3]London North West University Hospitals Trust, Gynaecology, London, United Kingdom

Background

To highlight the diagnostic challenge of cervical adenomyoma presenting as a prolapsing fibroid and to emphasise the importance of considering rare differential diagnoses in women presenting with atypical cervical masses and abnormal uterine bleeding.

Methods

A 51-year-old woman presented with continuous heavy vaginal bleeding and a prolapsing mass through the cervix. She also reported urinary frequency, urgency, and occasional incontinence. Clinical examination demonstrated a 5 cm mass within the vagina protruding through the cervical canal. Initial clinical and radiological assessment suggested a prolapsing leiomyoma. Magnetic resonance imaging (MRI) of the pelvis demonstrated a possible lower uterine or cervical fibroid, with coexisting adenomyosis within the uterus. The patient underwent hysteroscopy and transcervical resection of the lesion. Histopathological examination was subsequently performed.

Results

Intraoperatively, the mass was noted to arise from the endocervical canal, and transcervical resection was completed without complications. Histopathological analysis demonstrated a benign cervical adenomyoma rather than the presumed leiomyoma. The atypical clinical and imaging findings contributed to the preoperative diagnostic uncertainty. The patient recovered uneventfully following surgical management.

Conclusions

Cervical adenomyoma is a rare benign lesion that may mimic a prolapsing leiomyoma both clinically and radiologically. Careful assessment, imaging, hysteroscopic evaluation, and histopathological examination are essential for accurate diagnosis and appropriate management. Awareness of this uncommon differential diagnosis may help avoid misdiagnosis and optimise surgical planning in women presenting with atypical cervical masses and abnormal uterine bleeding.

ESGE35-0224 - P058
ePoster Presentations

When benign mimics malignancy: a cervico-isthmic lipoleiomyoma

Manar Akel[1], Haytham Elmeligy[2], Bernd Holthaus[2]
[1]St. Elisabeth hospital, Department of Gynaecology and Minimally Invasive Surgery-, Damme- Niedersachsen, Germany
[2]St. Elisabeth hospital, Department of Gynaecology and Minimally Invasive Surgery, Damme- Niedersachsen, Germany

Background

Uterine lipoleiomyomas are rare benign tumors composed of smooth muscle and mature adipose tissue, most commonly arising in the uterine corpus. Cervico-isthmic localization is exceptional and may pose significant diagnostic challenges, particularly when imaging findings simulate locally advanced malignancy.

Methods

A 51-year-old postmenopausal woman with a history of colorectal cancer presented with progressive pelvic pain and urinary symptoms. Transvaginal ultrasound demonstrated a highly vascularized cervico-isthmic mass measuring 49 × 48 × 79 mm. Contrast-enhanced computed tomography revealed a 7 cm lesion abutting the urinary bladder with obliteration of the intervening fat plane, raising strong suspicion for invasive cervical malignancy. No adnexal pathology or distant metastatic disease was identified.

Given the high index of suspicion for malignancy, a total laparoscopic hysterectomy with bilateral salpingo-oophorectomy was performed. Intraoperatively, severe distortion of the cervico-vesical anatomy and obliteration of normal tissue planes necessitated meticulous stepwise dissection of the vesico-uterine space and early bilateral ureteral identification to minimize the risk of urinary tract injury.

Results

Histopathological examination revealed multiple lipoleiomyomas without cytologic atypia or evidence of malignancy. The postoperative course was uneventful, and the patient experienced complete resolution of symptoms.

Conclusions

Lipoleiomyomas, although rare, should be considered in the differential diagnosis of pelvic and cervical masses. They remain a diagnostic dilemma, particularly in patients with a prior oncologic history. This case contributes to the limited literature on the laparoscopic management of cervical lipoleiomyomas and highlights the importance of thorough preoperative evaluation in patients with complex oncologic backgrounds. It also demonstrates the feasibility and safety of advanced laparoscopic surgery in challenging anatomical situations.

ESGE35-0240 - P059
ePoster Presentations

Perioperative outcomes of Robotic assisted versus conventional laparoscopic hysterectomy in a district general hospital- A retrospective comparative Audit

Daniel Darko[1], *Emma Cervanak*[2], *Alice Hockey*[3], *Nicholas Matthews*[4]
[1]*South Tyneside and Sunderland NHS Foundation, Gynaecology, Sunderland, United Kingdom*
[2]*South Tyneside and Sunderland NHS Trust, Gynaecology, Sunderland, United Kingdom*
[3]*South Tyneside and Sunderland, Gynaecology, Sunderland, United Kingdom*
[4]*South Tyneside and Sunderland NHS, Gynaecology, Sunderland, United Kingdom*

Background

Minimally invasive hysterectomy is the recommended surgical standard for both benign and malignant gynaecological indications. Robotic-assisted laparoscopic hysterectomy (RALH) has been introduced with purported advantages over conventional total laparoscopic hysterectomy (TLH) in complex cases, yet evidence from district general hospital (DGH) settings — where patient volumes and resources differ markedly from tertiary centres —remains limited

Methods

A retrospective clinical audit was conducted of all minimally invasive hysterectomies performed at a single DGH between January 2023 and December 2025. Cases were classified as RALH (n = 149) or TLH (n = 418). Primary outcomes included operative duration, intra-operative complication rate, conversion to laparotomy, estimated blood loss exceeding 300 mL, and length of hospital stay (day-case; <23 hours; >48 hours). Secondary outcomes comprised immediate post-operative complications, unexpected ITU admission, return to theatre within 48 hours, and readmission within 42 days. Continuous variables were compared using the Mann–Whitney U test; categorical variables using chi- squared or Fisher's exact test as appropriate. Statistical significance was set at $P < 0.05$

Results

A total of 567 patients underwent minimally invasive hysterectomy. The RALH cohort was significantly older (median 55 vs 49 years; $p < 0.001$), had a higher median BMI (31.8 vs 30.2 kg/m²; $p = 0.015$), and comprised a greater proportion of malignant indications (28.2% vs 15.6%). Operative duration was significantly longer in the RALH group (median 110 vs 90 minutes; $p < 0.001$).

RALH was associated with significantly higher day-case (65.8% vs 51.0%; $p = 0.003$) and same-day discharge rates (87.2% vs 66.7%; $p < 0.001$), a markedly lower intra-operative complication rate (10.7% vs 23.9%; $p < 0.001$), and fewer 42-day readmissions (10.7% vs 19.6%; $p = 0.020$). Immediate postoperative complications occurred less frequently afterRALH (2.0% vs 5.3%; $p = 0.108$), though this did not reach statistical significance. Rates of conversion to laparotomy, estimated blood loss exceeding 300 mL, return to theatre, and unexpected ITU admission did not differ significantly between groups

Conclusions

In this large single-centre DGH audit, RALH was associated with significantly higher day-case and same-day discharge rates, a lower intra-operative complication rate, and fewer 42-day readmissions compared with TLH, despite the robotic cohort harbouring a higher risk case mix (older age, greater BMI, and a higher proportion of malignant pathology). Operative duration was longer with the robotic approach. These findings support the feasibility and safety of robotic-assisted hysterectomy as a primary minimally invasive modality within a DGH setting and suggest potential downstream benefits to patient recovery and health service utilisation. Prospective studies with propensity-matched cohorts are warranted to validate these observations.

ESGE35-0242 - P060
ePoster Presentations

Giant ovarian cyst managed laparoscopically: A case report

Diana Lerinc[1], Slađana Mihajlović[1], Miroslav Nikolić[1], Nikola Potparević[1]
[1]KBC "Dr Dragiša Mišović - Dedinje", Bolnica za ginekologiju i akušerstvo, Belgrade, Serbia

Background

It is common to encounter cystic pelvic tumors originating from the ovaries, but giant ovarian cysts measuring more than 20 cm are rare. Traditionally giant cysts are managed via laparotomy due to malignancy concerns and technical limitations.

Methods

A 49-year-old perimenopausal woman presented with complaints of weight gain, urinary frequency and recurrent urinary infections. On ultrasound and MRI a large cystic adnexal mass measuring 17x10x22 cm was found, with thin septa, no vascularization and smooth walls. Tumor marker levels also suggested a benign lesion. The patient underwent a laparoscopic intraoperative cyst decompression to reduce tumor size, avoid spillage and allow safe manipulation, followed by left adnexectomy using bipolar energy device. Peritoneal lavage and drainage were performed.

Results

The postoperative course was uneventful and the patient was discharged on the first postoperative day. Histopathological analysis confirmed mucinous cystadenoma. The patient made a full recovery.

Conclusions

Carefully selected patients with giant ovarian cysts can be safely and effectively managed laparoscopically, with significant benefits over traditional laparotomy. Proper patient selection and controlled decompression technique are the essential factors.

ESGE35-0252 - P062
ePoster Presentations

Successful Concurrent Ovarian Cystectomy for a Large Ovarian Cyst During Elective Caesarean Section via Pfannenstiel Incision: A Case Report and Literature Review

Sara Wynne[1], Maria Constantinides[1], Shital Sawant[1]
[1]Newham University Hospital, Obstetrics & Gynaecology, London, United Kingdom

Background

To present a rare and surgically challenging case of concurrent ovarian cystectomy during elective repeat caesarean section in a patient with a large ovarian cyst and to review the operative management of adnexal masses encountered during pregnancy. This case also explores the feasibility of performing cystectomy through a standard Pfannenstiel incision despite the large size of the adnexal mass.

Methods

A 34-year-old multiparous woman with one previous spontaneous vaginal delivery and one previous caesarean section for intrauterine foetal death at term was reviewed at 36 weeks' gestation to discuss elective repeat caesarean section. Her pregnancy was additionally complicated by diet-controlled gestational diabetes. Antenatal ultrasound demonstrated a large complex left adnexal mass. MRI pelvis confirmed a left ovarian cyst measuring 21 × 17 × 12 cm displacing the gravid uterus. A mural nodular component measuring 16 × 12 mm with fat content was identified. No radiological features suspicious for malignancy were seen and tumour markers were negative.

Following multidisciplinary discussion between obstetric and gynaecology teams, a plan was made for concurrent cystectomy at the time of elective caesarean delivery. Despite the size of the ovarian mass, a Pfannenstiel incision was selected in preference to vertical midline laparotomy.

Results

Following uncomplicated fetal delivery, the ovarian cyst was mobilised, exteriorised and placed into a containment bag. Controlled decompression was achieved using suction drainage of approximately 2.8 litres of cyst fluid without intraoperative spillage, permitting complete cystectomy through the same Pfannenstiel incision. The remaining ovarian tissue was preserved and reconstructed using purse-string suturing. Estimated blood loss was 1.5 litres and postoperative recovery was uncomplicated.



Histopathological examination demonstrated a benign mucinous cystadenoma without atypia or invasive features.

Adnexal masses complicate approximately 1–2% of pregnancies, with most lesions being benign. Concurrent cystectomy at caesarean section has been reported as a safe option in selected patients, avoiding interval surgery, repeat anaesthetic exposure and complications including torsion, rupture and labour obstruction. However, literature describing management of very large ovarian cysts during caesarean section remains limited, with most reported cases favouring vertical midline laparotomy to optimise access.

Emerging evidence suggests selected benign adnexal masses may be safely managed through Pfannenstiel incision, offering reduced postoperative pain, lower wound morbidity, improved cosmetic outcomes and faster recovery. Reports describing successful ovarian conservation in such large cystectomy cases are similarly scarce.

Conclusions

This case demonstrates successful management of a large benign ovarian cyst during elective repeat caesarean section via Pfannenstiel incision with preservation of ovarian tissue. Careful preoperative imaging, multidisciplinary planning and meticulous surgical technique enabled definitive management in a single procedure while avoiding the morbidity associated with vertical laparotomy and repeat surgery.

ESGE35-0262 - P063
ePoster Presentations

Between hemorrhage and thrombosis: a challenging case of ruptured ovarian tumor with bilateral pulmonary embolism

Yasmine Chiba[1], *Barouni Rihab*[1], *Hfaiedh Ines*[1], *Zoghlami Achref*[1], *Jaafar Wissal*[1], *Mourali Mechaal*[1]
[1]*Habib Bougatfa University Hospital in Bizerte,*
Department of Obstetrics and Gynaecology- Bizerte- Tunisia., Bizerte, Tunisia

Background

Rupture of an ovarian tumor with hemoperitoneum is an uncommon but life-threatening condition in postmenopausal women and may reveal an underlying malignancy. The coexistence of acute pulmonary embolism (PE) creates a major therapeutic dilemma regarding timing of surgery and anticoagulation.

The aim:

To report a rare surgical emergency combining ruptured ovarian malignancy with massive hemoperitoneum and concomitant bilateral PE, highlighting perioperative management challenges.

Methods

We report the case of a 71-year-old woman with no significant medical history who presented with acute abdominal pain after minor trauma.

Results

The patient was hemodynamically and respiratory stable on admission. Abdominal ultrasound revealed a large hemoperitoneum reaching Morrison's pouch, confirmed by computed tomography (CT) imaging. CT angiography demonstrated rupture of a 13-cm left ovarian mass with no peritoneal carcinomatosis and associated bilateral proximal PE without right ventricular strain.

Emergency midline laparotomy was performed. Approximately 3 liters of hemoperitoneum were evacuated. Intraoperatively, a ruptured 13-cm ovarian cystic tumor with a 4-cm intracystic papillary vegetation was identified, densely adherent to the posterior uterus and broad ligament. A bilateral adnexectomy was performed with meticulous hemostasis. No ascites or peritoneal implants were observed. The Peritoneal Cancer Index **was 0**.

Postoperatively, anticoagulation was initiated after hemostasis using unfractionated heparin within 48 hours, followed by low-molecular-weight heparin.

Final histopathology confirmed an invasive mucinous adenocarcinoma of ovarian origin. Staging work-up showed no distant metastases. According to the FIGO staging system for ovarian cancer, the tumor was classified as Stage IC2. Multidisciplinary tumor board recommended completion staging and consideration of adjuvant chemotherapy.

Conclusions

Ruptured ovarian cancer associated with PE represents a rare but complex surgical emergency requiring rapid intervention and multidisciplinary coordination.

Impact to patients' health:

Early recognition and prompt surgical management significantly improve survival in life-threatening hemoperitoneum. Structured postoperative anticoagulation allows safe management of concomitant PE, while early oncologic staging guides appropriate adjuvant therapy and improves long-term prognosis.

ESGE35-0276 - P064
ePoster Presentations

Single-Port Versus Multi-Port Robotic Gynaecological Surgery: Comparative European Outcomes in Early Postoperative Pain

Saima Farooq[1], *Amer Raza*[1]
[1]*Cromwell Hospital, Gynaecology, LONDON, United Kingdom*

Background

Single-port robotic surgery has emerged as an important evolution in minimally invasive gynaecological surgery, aiming to reduce abdominal wall trauma while maintaining operative precision and surgical versatility. Postoperative pain remains a major determinant of recovery quality, patient satisfaction, mobilisation, and early functional outcomes. Although robotic surgery continues to expand across Europe, comparative data evaluating pain outcomes between single-port and conventional multi-port robotic techniques remain limited, particularly within complex gynaecological surgery.

Methods

A comparative cohort study was conducted in patients undergoing robotic gynaecological surgery at a tertiary referral centre. Postoperative pain intensity was assessed using a standardised numerical rating scale (0–10) at predefined postoperative intervals including 4 hours, 8 hours, day 3, and day 7 following surgery. Comparative analyses were performed across the overall cohort as well as procedure-specific subgroups including endometriosis surgery, robotic myomectomy, and hysterectomy. Statistical analysis incorporated adjustment for multiple comparisons using false discovery rate methodology to improve robustness of the findings.

Results

Patients undergoing single-port robotic procedures demonstrated consistently lower postoperative pain scores compared with those undergoing multi-port surgery during the early postoperative recovery period. The most significant differences were observed at 4–8 hours and day 3 after surgery, with statistical significance maintained following correction for multiple testing ($p<0.01$). By postoperative day 7, pain levels became comparable between groups. Subgroup analysis demonstrated a consistent trend favouring the single-port approach across multiple gynaecological procedures. In patients undergoing surgery for endometriosis, a marked reduction in pain severity was identified following single-port surgery. Similar trends were observed within robotic myomectomy and hysterectomy cohorts. The analgesic benefit associated with reduced abdominal wall access trauma appeared most pronounced during the immediate and intermediate postoperative phases.

Conclusions

This study presents early European comparative evidence supporting the role of single-port robotic gynaecological surgery in reducing postoperative pain without compromising surgical feasibility. By minimising access-related tissue trauma while preserving the advantages of robotic minimally

invasive surgery, the single-port platform may enhance postoperative recovery and patient-centred outcomes. These findings further support the expanding integration of single-port robotics into advanced gynaecological surgical practice.

ESGE35-0280 - P065
ePoster Presentations

Complex Surgery, Complex Recovery: Lessons From a Prolonged Postoperative Course of Adhesive Small-Bowel Obstruction Following Advanced Robotic Endometriosis Excision

Saima Farooq[1], Fevzi Shakir[1], Ibnauf Suliman[1], Carmen Nicoleta Ghioci[1], Mahmoud Motawae[1], Shafiq Ahmed[2]
[1]Royal Free Hospital, Gynaecology, LONDON, United Kingdom
[2]Lancashire Hospital NHS Trust, Gynaecology, Lancashire, United Kingdom

Background

Advanced endometriosis surgery frequently involves extensive pelvic dissection, adhesiolysis, bowel surgery, and retroperitoneal reconstruction, all of which increase the risk of postoperative morbidity beyond the index procedure itself. Adhesive small-bowel obstruction (SBO) remains an uncommon but clinically significant complication that may require early recognition, multidisciplinary escalation, and timely surgical intervention to avoid bowel compromise. While minimally invasive robotic surgery may reduce adhesion formation compared with open surgery, complex stage IV disease with dense inflammatory fibrosis continues to present substantial perioperative challenges. We report a prolonged postoperative course highlighting the importance of structured escalation pathways and collaborative gynaecology–colorectal management in severe adhesive SBO following advanced robotic endometriosis surgery.

Methods

Case: A 44-year-old nulliparous woman wishing to conceive presented with severe deep infiltrating endometriosis. MRI demonstrated upper rectal tethering to the posterior uterine fundus over a 3 cm segment, bilateral ovaries fixed medially with endometriomas, and bilateral hematosalpinx, without evidence of ureteric compression on CT urogram. She underwent combined robotic surgery in November 2025, including cystoscopy with ureteric indocyanine green visualisation, extensive adhesiolysis, bilateral ureterolysis, hypogastric nerve-sparing excision, rectal shaving, sigmoid disc excision, bilateral salpingectomy, and appendicectomy. Dense inflammatory adhesions were encountered intraoperatively, requiring mini-Pfannenstiel access. A small-bowel enterotomy was recognised immediately and repaired primarily in two layers. Flexible sigmoidoscopy confirmed a negative leak test following closure of the sigmoid disc defect.
Complication and Management:
From postoperative day 11, the patient developed vomiting, abdominal distension, high nasogastric output, and inflammatory markers with white cell count rising to 17. CT imaging demonstrated dilated small bowel with multiple calibre changes and no drainable collection. Despite PICC-supported total parenteral nutrition, nasogastric decompression, and Gastrographic challenge, repeat CT on day 20 identified a right-sided transition point concerning for mechanical obstruction. The patient underwent laparoscopy, converted to midline laparotomy, revealing extensive inter-loop adhesions and multiple omental bands, including a constricting band approximately 40 cm proximal to the ileocecal valve. Complete adhesiolysis and omentectomy were performed, successfully avoiding bowel resection.

Results

Gradual bowel recovery followed with progressive dietary escalation, enabling discharge on 26 December 2025. This case highlights the importance of early imaging, clearly defined reoperation thresholds, and close multidisciplinary collaboration between advanced gynaecology and colorectal teams in the management of postoperative adhesive SBO after complex endometriosis surgery

Conclusions

Prompt escalation and timely surgical rescue may minimise bowel morbidity while preserving favourable long-term recovery outcomes.

ESGE35-0281 - P066
ePoster Presentations

The 30 cm Dilemma: Fertility-Sparing Laparoscopic Surgery for a Giant Borderline Ovarian Tumour

Saima Farooq[1], *Fevzi Shakir*[1]
[1]*Royal Free Hospital, Gynaecology, LONDON, United Kingdom*

Background

Management of giant ovarian cysts in reproductive-age women presents a significant surgical challenge, particularly when borderline ovarian pathology cannot be confidently excluded preoperatively. Although minimally invasive surgery offers advantages including reduced postoperative pain, shorter recovery, and fertility preservation, concerns regarding intraoperative cyst rupture, tumour spillage, and oncological safety remain important considerations in large adnexal masses. Borderline mucinous ovarian tumours are particularly challenging due to their size, heterogeneous imaging characteristics, and occasionally normal tumour markers despite malignant potential. case highlights a structured laparoscopic strategy prioritising controlled decompression, specimen containment, and preservation of ovarian reserve in an unexpected borderline pathology.

Methods

Case Overview: A 27-year-old nulliparous woman presented with progressive abdominal pain and increasing abdominal distension. Imaging demonstrated a rapidly enlarging left ovarian cyst measuring approximately 30 cm, with no definitive radiological evidence of invasive malignancy and normal tumour markers.
A modified Hasson entry technique was utilised because of marked abdominal distension and limited safe access zones. Controlled decompression of the cyst was performed under direct visualisation, aspirating approximately 7 litres of clear cyst fluid to optimise operative space while minimising uncontrolled spillage. Given the rapid interval growth and possibility of borderline disease, meticulous tissue handling and spillage-conscious dissection were maintained throughout the procedure. The cyst wall was stabilised and progressively dissected from preserved ovarian tissue using careful traction-countertraction techniques. Specimen retrieval was performed within a large endoscopic retrieval bag to reduce risk of peritoneal contamination. Ovarian reconstruction was completed using fine suturing techniques with adjunct haemostatic agents to maximise preservation of ovarian reserve and haemostasis.

Results

Histopathology confirmed a borderline mucinous ovarian tumour with intestinal immunophenotype.

Conclusions

This case demonstrates that giant ovarian cysts may harbour borderline pathology despite reassuring imaging and tumour markers Careful patient selection, multidisciplinary planning, and meticulous intraoperative technique remain central to balancing fertility preservation with surgical safety in complex ovarian pathology.

ESGE35-0282 - P067
ePoster Presentations

Silent Obstruction, Irreversible Renal Loss: Robotic Multidisciplinary Surgery for Advanced Ureteric Endometriosis

Saima Farooq[1], *Fevzi Shakir*[1]
[1]*Royal Free Hospital, Gynaecology, LONDON, United Kingdom*

Background

Deep infiltrating endometriosis involving the ureter is an uncommon yet potentially organ-threatening manifestation of advanced pelvic disease. Ureteric endometriosis may progress silently, with patients often remaining minimally symptomatic despite progressive obstruction, hydroureteronephrosis, and irreversible renal loss. Delayed diagnosis contributes significantly to morbidity, and management frequently requires close collaboration between advanced gynaecological, colorectal, and urological teams. Robotic surgery offers enhanced visualisation, fluorescence-guided dissection, and improved dexterity within distorted retroperitoneal anatomy, facilitating safe management of complex ureteric disease while preserving surrounding pelvic structures. This case demonstrates a structured multidisciplinary robotic strategy in a patient presenting with complete functional loss of a kidney secondary to severe ureteric endometriosis.

Methods

Case Overview: A 59-year-old nulliparous woman was diagnosed with extensive right-sided uterosacral and torus uterinus endometriosis causing distal ureteric obstruction, chronic hydroureteronephrosis, and a non-functioning right kidney. Despite prolonged ureteric stenting, nuclear medicine imaging confirmed negligible residual renal function. Following multidisciplinary endometriosis and urology review, definitive combined robotic surgery was planned. Surgical Technique: The procedure was jointly performed by robotic urology and gynaecology teams with preoperative theatre choreography and strategic port placement allowing seamless transition between upper tract and pelvic phases. Cystoscopy with intra-ureteric indocyanine green (ICG) instillation was undertaken to aid ureteric identification. A robotic right nephroureterectomy was then performed in modified flank position with individual vascular control and adrenal preservation. The ureter was intentionally traced distally to maintain continuity with the pelvic dissection phase. The patient was subsequently repositioned for pelvic surgery. Bilateral ureterolysis with hypogastric nerve-sparing excision was completed through dense parametrial and uterosacral fibrosis. Robotic hysterectomy with bilateral salpingo-oophorectomy, rectal shaving, and bladder cuff excision were undertaken to achieve complete disease clearance. Bowel integrity was confirmed with intraoperative sigmoidoscopy and air-leak testing. ICG fluorescence assessment additionally confirmed preserved perfusion and integrity of the remaining ureteric and pelvic structures.

Results

The patient had an uncomplicated postoperative recovery with successful resolution of obstructive disease. This case highlights that ureteric endometriosis may progress silently to irreversible renal loss despite stenting and prolonged conservative management. Early recognition, timely imaging, and multidisciplinary referral remain critical in preventing delayed intervention.

Conclusions

Robotic multidisciplinary surgery, combined with fluorescence-guided dissection and structured operative sequencing, can facilitate safe management of extreme ureteric disease while protecting remaining renal and pelvic organ function.

ESGE35-0283 - P068
ePoster Presentations

Multidisciplinary Management of Giant Ovarian Fibroma with Meigs Syndrome Mimicking Advanced Ovarian Cancer

Saima Farooq[1], *Fevzi Shakir*[1]
[1]*Royal Free Hospital, Gynaecology, LONDON, United Kingdom*

Background

Meigs syndrome is a rare benign clinical entity characterised by ovarian fibroma, ascites and pleural effusion, frequently mimicking advanced ovarian malignancy both clinically and radiologically. Markedly elevated CA-125 levels, extensive adhesions and concurrent venous thromboembolism (VTE) may further complicate diagnostic interpretation and perioperative planning. Distinguishing benign from malignant pathology pre-operatively remains challenging, particularly in postmenopausal women presenting with large adnexal masses and systemic manifestations. This case highlights the importance of multidisciplinary decision-making and tailored surgical planning in complex adnexal pathology where malignancy cannot be confidently excluded.

Methods

Case Presentation A 70-year-old postmenopausal multiparous woman presented with progressive abdominal distension, exertional dyspnoea and early satiety. Imaging demonstrated a large complex adnexal mass associated with ascites and pleural effusion. She was admitted with pulmonary embolism, hepatic vein thrombosis and proximal femoral vein thrombosis. Tumour markers revealed markedly elevated CA-125 at 1241, while CA19-9 and CEA remained within normal limits. Ascitic fluid cytology demonstrated inflammatory changes without malignant cells. Following multidisciplinary discussion involving gynaecology, haematology and respiratory teams, therapeutic anticoagulation was initiated and definitive surgery deferred for six weeks after pulmonary embolism to optimise perioperative safety and reduce thrombotic risk. Surgical Management: Given the size of the adnexal mass, dense adhesions and persistent concern regarding occult malignancy, laparotomy was selected in accordance with current recommendations for large ovarian fibromas with malignant potential. Total abdominal hysterectomy, bilateral salpingo-oophorectomy and extensive adhesiolysis were performed. Intra-operatively, a >15 cm left ovarian fibroma was identified, densely adherent to the pelvic sidewall, pouch of Douglas and omentum, with associated ascites. Careful retroperitoneal dissection and left ureterolysis facilitated safe mobilisation of the mass and protection of surrounding structures. Estimated blood loss was 150 ml with no intra-operative complications.

Results

Postoperative recovery was uncomplicated and the patient was discharged on postoperative day four. Final histology confirmed a benign left ovarian fibroma, right ovarian Leydig cell hyperplasia and uterine leiomyomas with degenerative change. This case demonstrates how Meigs syndrome can closely resemble advanced gynaecological malignancy, particularly in the presence of markedly elevated tumour markers and thromboembolic disease.

Conclusions

It emphasises the importance of MDT-led perioperative optimisation, individualised surgical planning and maintaining diagnostic caution in complex adnexal masses. Open surgery remains an important and appropriate approach in selected patients where safe minimally invasive excision and oncological certainty cannot be guaranteed.

ESGE35-0301 - P071
ePoster Presentations

Audit of Benign Hysterectomy Practice at University Hospital Lewisham (UHL): Opportunities to Increase Minimal Access Surgery Rate

Andreas Kalampalikis[1], *Rifa Riyaz*[1], *Iona Talbot*[1], *Mickey Buckingham*[1], *Mansi Tiwari*[1], *Heena Mehra*[1]
[1]*University Hospital Lewisham, Women's Health, London, United Kingdom*

Background

Minimal Access Surgery (MAS) is the recommended route of hysterectomy, as it is associated with a lower complication rate and morbidity, faster recovery, and shorter hospital stay. The UK Getting It Right First Time (GIRFT) initiative sets the national MAS target at 77.7%. This audit re-evaluated hysterectomy practice at UHL to identify opportunities to increase MAS uptake.

Methods

A retrospective review of 100 consecutive benign hysterectomies performed between January-December 2025 was conducted. Patients with confirmed or suspected malignancy, including atypical hyperplasia or fibroids were excluded.

Demographics, BMI, indication, planned vs actual hysterectomy route, intraoperative and postoperative complications, Length of Stay (LOS), and readmissions were extracted from electronic health records and analysed on Microsoft Excel.

Results

MAS accounted for 42% of all hysterectomies (33% laparoscopic, 1% vaginal hysterectomy, and 8% laparoscopically assisted vaginal hysterectomy), well below the national target, with the rest being abdominal. Among the 58 abdominal hysterectomies, 40 had uterine size ≥16 weeks. Of the remaining,15 had uterine size <16 weeks, of which two had multiple operations and one had a large ovarian fibroma. For three of them no uterine size was recorded, but one patient had opted for abdominal hysterectomy. In comparison, 3/42 MAS cases had uterine size ≥16 weeks.

Complication rate for open surgery was higher (20.7%, major 1.7%) compared to MAS (9.5% without any majors) as was blood loss ≥1L (10.3% abdominal vs 4.8% for MAS). Mean LOS for MAS was 1.85 compared to 2.78 for abdominal hysterectomies, with improved LOS over the weekend compared to previous year (42% vs 52.5%). There were 7 emergency department presentations following abdominal hysterectomy compared to 4 following MAS without any readmissions.

Conclusions

Abdominal hysterectomies were associated with increased complication rate and longer LOS. MAS utilisation remained below national target, however, based on documentation, this could potentially increase by 15-18%. Potential contributing factors include the high prevalence of fibroids in the African/Afro-Caribbean population, which constituted 39% of our cohort, and the lack of access to a morcellator. Strategies to streamline perioperative pathways

and improve case selection, preoperative optimisation, and equipment availability, have been proposed, as well as re-evaluation in a year.

ESGE35-0310 - P072
ePoster Presentations

From False Reassurance to Targeted Diagnosis: the Power of Resectoscopy.

Marek Kudła[1], Tomasz Bryś[1], Karolina Karoń[1], Julia Graca-Gruchalska[1]
[1]Faculty of Medical Sciences- Medical University of Silesia,
Department of Perinatology and Oncological Gynaecology, Sosnowiec, Poland

Background

One of the most common causes of abnormal uterine bleeding in both, reproductive-aged and postmenopausal women, is the presence of endometrial polyps. The majority of these lesions are benign; however, the risk of malignancy is significantly higher when bleeding is present as an accompanying symptom, reaching approximately 4.5% in general and 5.4% in postmenopausal women.
Ultrasonography allows for suspicion of an endometrial polyp; however, the definitive diagnosis is established based on histopathological examination.
Uterine sarcomas represent a heterogeneous group of malignancies arising from mesenchymal tissues, including smooth muscle and connective tissue, and account for less than 10% of uterine neoplasms. They are most frequently diagnosed postoperatively, based on histopathological evaluation of specimens obtained after myomectomy or hysterectomy.

Methods

A 67-year-old woman was admitted for evaluation of postmenopausal uterine bleeding. Her gynecological history was notable for one spontaneous vaginal delivery and four prior procedures of dilatation and curettage (D&C) performed due to endometrial hyperplasia. No additional gynecological symptoms were reported. On physical examination, features consistent with metabolic syndrome were observed, including arterial hypertension (BP 160/95 mmHg), obesity (BMI 32 kg/m^2), and type 2 diabetes mellitus.
Transvaginal ultrasonography demonstrated a large intrauterine lesion measuring 50 × 54 × 50 mm, consistent with an endometrial polyp exhibiting pronounced and irregular vascularization.
A characteristic single feeding vessel was identified, arising from the anterior uterine wall. An attempt was made to remove the lesion via D&C; however, complete excision proved technically unfeasible. The procedure yielded only a limited amount of tissue for histopathological assessment, which did not reveal any atypical or malignant cells. The histopathological diagnosis was simple endometrial hyperplasia, consistent with findings from the patient's previous curettage procedures.

Results

Subsequently, operative hysteroscopy (resectoscopy) was undertaken, allowing partial resection of the lesion, with approximately 40% of the polyp successfully excised. The final pathological diagnosis was: Myosarcoma.
Further treatment of the patient included surgery, according to the oncology treatment standards required in this situation.

Conclusions

The presented case underscores the importance of incorporating detailed Doppler ultrasonography and favouring hysteroscopic resection over blind dilatation and curettage (D&C) in the management of suspicious endometrial lesions, in order to obtain an adequate tissue sample for accurate histopathological assessment in postmenopausal patients.

ESGE35-0313 - P073
ePoster Presentations

Role of hysteroscopy in the management of atypical precancerous lesions of endometrium

Nilopher Surti[1], Balika Balika[1], Ganapathy Chandrakala[1]
[1]Barnet Hospital, Obstetrics and Gynaecology, London, United Kingdom

Background

Atypical polypoidal adenomyoma (APA), Disordered proliferative endometrium (DPP) and complex Mucinous Metaplasia of Endometrium (cMME) may co-exist with concurrent endometrial hyperplasia (EH) or endometrial carcinoma (EC) and they have a potential to progress to EH/ EC. Risk factors for these conditions are same as those for EC. The diagnosis is by histology.

Objectives: To propose structured pathway for management of APA, DPP and cMME.

Methods

We conducted a literature search and reviewed 31 articles to find incidence, molecular markers, risk of progression to EH/EC, presence of concurrent lesions and management of these conditions.

Results

APA and MME are uncommon conditions and their exact incidence is unknown.

APA most commonly affects younger women. Reported recurrence of APA after conservative treatment by blind dilatation and curettage or polypectomy can be as high as 38% and after Hysteroscopic transcervical resection (TCR) is 22- 29.8%. The risk of malignant progression is 5–11% with one study showing progression risk of 33%. Atypical EH may be present in 5-18% of case and EC can be present in 6-16% of cases.

cMME which show KRAS mutation is significantly associated with EH/EC. One study showed Incidence of endometrial cancer increased from 64.7% to 100% as the complexity increases while another showed 83% of concomitant EC/EH.

There is not much literature available regarding association of EH/EC with DPP. A North-West London based audit showed concurrent EH in 4% of cases and progression to EH in 10 % of cases if left untreated. Progesterone treatment showed 91% resolution rate.

Conclusions

We found is a significant association of APA, cCME and DPP with EH/EC. At present there are no standardised management pathways for these condition. We have proposed a management pathway from the literature review.

Cases with histology showing APA, cMME, DPP should have an individualised management plan based on risk factors, patient age, fertility wishes, and associated pathology. Hysterectomy is the definitive treatment for APA and cMME. Patients declining or not suitable for hysterectomy should be under regular surveillance.

Hysteroscopic TCR is preferred mode of treatment for conservative management for APA in women who want to preserve fertility. Patient managed conservatively should have a review in 3 months for clinical symptoms and trans-vaginal ultrasound. They should be advised repeat endometrial biopsy every 6 months for 2 years and then yearly biopsy for lifetime or until definitive treatment.

Cases diagnosed with cMME with risk factors for EC should have repeat endometrial biopsy at least every 6 months.

Cases with diagnosis of DPP should have follow up like simple endometrial hyperplasia if they have risk factors for EC.

ESGE35-0314 - P074
ePoster Presentations

Fooled by Imaging, Rescued by Endoscopy: Suspicious Tumor Case in Pregnancy.

Marek Kudła[1], Karolina Karoń[1], Tomasz Bryś[1], Karolina Stolorz-Sierka[1]
[1]Faculty of Medical Sciences- Medical University of Silesia,
Department of Perinatology and Oncological Gynaecology, Sosnowiec, Poland

Background

The incidence of adnexal masses during pregnancy ranges from 0.05% to 2.4%. The majority of these lesions are benign, with only 1–6% found to be malignant. Most adnexal masses are asymptomatic, and their detection rate has increased due to the widespread use of ultrasonography during pregnancy.
Ovarian endometriosis during pregnancy is observed in approximately 0.05–0.5% of patients, among whom cyst decidualization occurs in 12% of cases.
Borderline ovarian tumors account for 2–5% of adnexal lesions. Accurate diagnosis of borderline ovarian tumors and appropriate surgical management are associated with an excellent prognosis, with favourable outcomes reported in 95–99% of patients.

Methods

We report the case of a 28-year-old woman evaluated at 14 weeks' gestation during her third pregnancy. Transvaginal ultrasonography revealed a left ovarian mass characterized by hypoechoic content and peripherally located hyperechoic papillary projections with moderate vascular flow. The sonographic appearance was suggestive of papillary serous borderline ovarian tumor or decidualized endometrioma (measuring 30.4 × 17.7 × 25 mm). Notably, there was no documented history of a pre-existing endometriotic cyst in the affected ovary.
Given the imaging findings, differential diagnosis included a serous borderline ovarian tumor as well as an early-stage epithelial ovarian malignancy. In order to avoid an unnecessary operation that could threaten the course of the pregnancy, a decision was made to implement close surveillance with serial ultrasonographic assessments performed during routine prenatal visits.

Results

The morphology of the lesion remained stable throughout the pregnancy. The patient delivered vaginally at 39 weeks' gestation. At a routine follow-up visit one month postpartum, the adnexal mass persisted. Serum Ca-125 level at that time was within normal limits (15 U/mL). Due to the ongoing suspicious sonographic features, laparoscopic excision of the lesion (tubectomy) was performed. Histopathological analysis of the resected specimen revealed a papillary serous borderline tumor originating from the fallopian tube. Due to the patient's future pregnancy plans, a decision was made for conservative treatment, and periodic expert ultrasound examinations were ordered every three months during the first year after surgery, followed by check-ups twice a year.

Conclusions

This case highlights the potential for overlap in ultrasonographic features between decidualized endometriomas and serous borderline tumors during pregnancy.
The presented case highlights the significant importance of ultrasonographic assessment of the uterus and adnexa in pregnant patients in the very early phase of pregnancy, which allows for planning the procedure after the end of pregnancy or potentially implementing minimally invasive surgical treatment without excessive risk to the further course of the pregnancy.

ESGE35-0330 - P076
ePoster Presentations

Atypical presentation of large pelvic masses in Gynaecology

Chandrakala Ganapathy[1], *Hafsa Rifai*[1], *Michal Chinn*[1], *Kannappar Jeyanthan*[1]
[1]*Barnet/ Chase Farm hospitals- Royal Free NHS Trust, Obstetrics/ Gynaecology, London, United Kingdom*

Background

Uterine fibroids are the most common benign tumour in women of reproductive age, and the impact from heavy bleeding, pelvic pain and pressure symptoms is well-known. However, large fibroids can also cause venous compression leading to venous stasis and subsequent venous thromboembolism (VTE), which can present acutely. Management of large fibroids is commonly by myomectomy or hysterectomy, and current literature supports the use of temporary inferior vena cava (IVC) filters or venous occlusion techniques during emergency pelvic surgery to reduce the perioperative embolic risk. Although VTE is a rare complication of large fibroids, it may be an increasing concern for those patients facing long waiting times for surgical management of fibroids, as these fibroids can continue to grow, further increasing the risk of VTE. Informed consent was obtained from the patient to present the case.

Methods

We present the case of a 42-year-old woman, with known large uterine fibroids, who presented to the Emergency Department feeling generally unwell with non-specific abdominal pain. Blood tests showed raised inflammatory markers. CT abdomen and pelvis showed partial compression of the IVC by the large fibroid uterus and thrombosis of the left common iliac vein, external iliac vein and common femoral veins. Given the extensive deep vein thromboembolism (DVT) and persistent tachycardia, a CT pulmonary angiogram was done, which confirmed the presence of bilateral pulmonary emboli as well as evidence of right heart strain. She was admitted under joint care with the medical team for therapeutic anticoagulation and cardiac monitoring. MR Pelvis was done to map and characterise the fibroids prior to surgery and showed a 27cm uterus with innumerable fibroids and an 18cm pedunculated right-sided fibroid.

Results

In view of the extensive fibroid burden, and to relieve the pressure on the IVC, she underwent an emergency total abdominal hysterectomy and bilateral salpingectomy as definitive management. Prior to this, she had insertion of a temporary IVC filter to prevent embolisation of the DVTs to the lungs after removal of the obstructing fibroid uterus. The surgery was successful and the IVC filter was scheduled for removal three weeks later.

Conclusions

This case demonstrated the rare but life-threatening complication of VTE secondary to large fibroids. This patient had unfortunately been waiting for a myomectomy for over 2 years, on account of long surgery waiting lists, which likely contribute in part to the degree of morbidity from the large

fibroids. However, the case also highlighted the importance of the multi-disciplinary team in the care of complex patients, in particular, the role of interventional radiology and IVC filters in emergency pelvic surgery.

ESGE35-0342 - P077
ePoster Presentations

When Hysteroscopy Fails: Laparoscopic Management of Delayed Uterine Perforation with Contraceptive Device

Shu Hui Lim[1]
[1]*KK Women's and Children's Hospital, Department of O&G, Singapore, Singapore*

Background

Uterine perforation with occult migration of an intrauterine device is an uncommon but significant complication. Diagnosis may be delayed, sometimes for years, when retrieval threads remain visible on examination and ultrasound suggests an intrauterine position. We report a case of complete delayed Mirena extrusion, highlighting the importance of early suspicion and surgical planning prior to definitive minimally invasive management.

Methods

Case Presentation:

A 33-year-old woman with three previous caesarean sections underwent Mirena insertion at 6 weeks postpartum and subsequently developed amenorrhoea. Eighteen months later, she presented with irregular bleeding and requested device removal and change to Implanon.

Initial outpatient removal was unsuccessful initially due to non-visible threads. Following successful bedside retrieval of the threads, marked resistance was encountered on traction. Transvaginal ultrasound demonstrated a low-lying intrauterine device. Operative hysteroscopy identified only the retrieval threads traversing the uterine cavity with no visible body of the device seen. Attempts at removal using alligator forceps and enlargement of the myometrial tract with hysteroscopic scissors were unsuccessful, and the procedure was abandoned as consent for laparoscopy had not been obtained prior to surgery.

Results

Pelvic MRI subsequently demonstrated the device in the left adnexal region with moderate haemoperitoneum. 1 month later, a second surgery with concurrent diagnostic laparoscopy and hysteroscopy revealed complete extrusion of the Mirena through the left posterior uterine wall, suspended by adhesions. There was no residual defect seen on the myometrium and the threads were no longer visible on hysteroscopy. Laparoscopic retrieval was successfully performed and the device was removed easily.

Conclusions

Visible threads of intrauterine contraceptive devices do not exclude uterine perforation. Resistance during traction and discordant imaging findings should prompt early suspicion of extrauterine migration or embedded device. This case highlights the potential role of early imaging after insertion when ensuring the device is fitted in a satisfactory position. It also demonstrates the importance of provision for hysteroscopy with concurrent laparoscopy when planning for surgical retrieval after

failed office removal. This ensures the possibility of definitive diagnosis and treatment in the same surgery, avoiding repeated procedures and potential morbidity.

ESGE35-0347 - P078
ePoster Presentations

Analysing the heart rate changes, as an indicator of pain, during hysteroscopic procedures

Péter Török[1], Dániel Fehér[2], Márton Lipták[3]
[1]UDMHSC, Obstetrics and Gynaecology, Debrecen, Hungary
[2]University of Debrecen, Obstetrics and Gynaecology, Debrecen, Hungary
[3]Méhtükrözés, Méhtükrözés, Debrecen, Hungary

Background

Heart rate is a readily recordable vital parameter that allows for the objective assessment of pain during hysteroscopic procedures. The aim of the study was to evaluate how the heart rate changes during hysteroscopic procedures in both inpatient and outpatient settings.

Methods

Prospective study including 16 patients who underwent hysteroscopic surgery. General anesthesia was administered for hysteroscopic procedures performed in inpatient settings, while no anesthesia was used for procedures conducted in outpatient settings. The heart rate was recorded using a CMS50D+ pulse oximeter, which was attached to one of the patient's fingers during hysteroscopy. Recording of the heart rate commenced prior to the insertion of the hysteroscope and was discontinued following the complete removal of the hysteroscope. Video recordings were obtained of the hysteroscopic procedures. The heart rate recordings were analysed in correlation with the video recordings of the procedures. Heart rate values were analysed at baseline (prior to hysteroscopic entry), during vaginal penetration, at various stages of cervical passage (external os – cervical canal – internal os), and during the intrauterine procedure.

Results

Recordings were obtained in 4 patients under inpatient settings with the use of general anesthesia. No significant changes in heart rate were observed during the whole procedures. Data were obtained from 12 patients in the outpatient settings. Operative hysteroscopy using a working channel was performed in 10 cases, but in the final analysis, the heart rate values of two patients' were excluded, as they were identified as outliers in the distribution (mean age: 40.63 years; mean BMI: 28.07 kg/m²). Resectoscopic intervention was performed in 2 patients, involving one TCRP and TCRS (mean age: 52.50 years; mean BMI: 31.46 kg/m²). The mean heart rate values in using a working channel group versus the resectoscopic intervention group were as follows: 94.50 bpm vs 88.5 at baseline, 92.98 bpm vs 78.87 bpm during vaginal entry, 92.38 bpm vs 77.43 bpm at the external os, 91.73 bpm vs 76.68 bpm in the cervical canal, and 90.87 bpm vs 73.05 bpm at the internal os. 86.66 bpm vs 69.94 bpm during the intrauterine procedure. The mean maximum heart rate was 96.75 bpm vs 92 bpm, while the mean minimum heart rate was 76.88 bpm vs 61.5 bpm. The mean heart rate recorded throughout the entire duration of the procedures, from the insertion of the hysteroscope to its removal, was 90.30 bpm vs 71.71 bpm.

Conclusions

The highest heart rate values were recorded at baseline, followed by a declining trend across the subsequent points of analysis. This likely suggests that patients become more composed after the initial entry, as they do not perceive significant pain.

ESGE35-0351 - P079
ePoster Presentations

How to avoid bladder injury during laparoscopic sacrocolpopexy: tips and tricks

Deepali Sinha[1], Maria Constantinides[1], Shaimaa Ibrahim[1]
[1]Newham University Hospital- Barts Health NHS Trust, Obstetrics and Gynaecology, London, United Kingdom

Background

To demonstrate a standardised stepwise technique for laparoscopic sacrocolpopexy (lscp).
To highlight strategies to avoid bladder injury, particularly in patients with previous caesarean section.
To identify key anatomical landmarks, including the ureter and sacral promontory, and improve reproducibility in advanced pelvic organ prolapse repair.

Methods

A patient with advanced multi-compartment pelvic organ prolapse, including vault prolapse (c +7 cm), grade 3 cystocele (+4), grade 3 rectocele (+3), and complete vault eversion, with a history of previous caesarean section, underwent lscp with mesh repair.

Abdominal access was established using a veress needle technique, followed by insertion of a 10 mm optical port under direct vision. additional ports included two 5 mm left-sided ports, one 5 mm right-sided port, and a 10 mm suprapubic port.

Key steps to minimise bladder injury included careful adhesiolysis with lateral-to-medial dissection, anticipation of bladder adhesions, identification of the correct vesicovaginal plane, maintaining dissection close to the vaginal wall, and use of sharp dissection with minimal energy to reduce thermal injury.

The sigmoid colon was mobilised to expose the right pelvic sidewall, and the ureter was identified. the vesicovaginal and rectovaginal spaces were developed to expose the anterior and posterior vaginal walls. a y-shaped polypropylene mesh was positioned and secured to the vaginal walls and then fixed to the sacral promontory. the peritoneum was closed over the mesh.

Intraoperative cystoscopy was performed to confirm bladder integrity and bilateral ureteric efflux.

Results

The procedure was completed without intraoperative complications. Estimated blood loss was 100 ml. Adequate mesh placement and secure fixation were achieved. No bladder injury occurred. Postoperative recovery was uneventful, with early catheter removal and discharge on postoperative day 1.

Conclusions

Bladder injury during lscp can be minimised through anticipation of altered anatomy, particularly in patients with previous caesarean section, and adherence to key surgical principles. maintaining the correct vesicovaginal plane, limiting energy use, and performing intraoperative cystoscopy are critical safety steps. This standardised approach enhances surgical safety, reproducibility, and training in advanced pelvic organ prolapse repair.

ESGE35-0356 - P081
ePoster Presentations

Uterine Preservation following Transcervical Radiofrequency Ablation for symptomatic fibroids: Real World Outcomes from a single center cohort

Phoebe Li Bee Tan[1], *Yahia Refaee*[1], *Ayisha.A. Ashmore*[1], *Shilpa Kolhe*[1]
[1]*University Hospitals of Derby and Burton, Gynaecology, Derby, United Kingdom*

Background

Transcervical radiofrequency ablation (SONATA) is a minimally invasive, uterus preserving treatment for symptomatic uterine fibroids. While clinical trials demonstrate efficacy, real world outcomes remain limited.

Methods

A retrospective cohort study of all patients undergoing SONATA was performed. Outcomes included bleeding and QoL scores at baseline, 3 months (FU1), 6 months (FU2), and 12 months (FU3) using the Uterine Fibroid Symptom and Health Related Quality of Life Questionnaire(UFS-QoL). Hysterectomy rates and need for additional treatment were recorded. Data was analysed using a linear mixed effects model.

Results

A total of 45 patients were included. Median age was 45 years, with predominantly FIGO type 2-4 fibroids and a median fibroid diameter of 50 mm. Mean bleeding scores improved significantly from 15.0 at baseline to 10.9 at FU1 (mean difference −4.1, 95% CI −6.0 to −2.3; $p < 0.001$) and 10.6 at FU2 (mean difference −4.4, 95% CI −6.8 to −2.2; $p < 0.001$). Mean QoL scores improved from 118.3 at baseline to 85.3 at FU1 (mean difference −33.0, 95% CI −46.2 to −19.8; $p < 0.001$) and 87.8 at FU2 (mean difference −30.5, 95% CI −46.6 to −14.4; $p < 0.001$). Improvements were significant at both follow-up timepoints, with no statistically significant difference between FU1 and FU2, indicating sustained benefit. FU3 demonstrated a similar trend; however, findings were not statistically significant because of limited follow-up data. Hysterectomy was required in 4% (n = 2) of patients. Additional treatment was required in 34% (n = 17), predominantly adjunctive medical therapy with only one patient requiring further surgical intervention (myomectomy). Overall patient satisfaction was high, with 84% (n= 38) reporting symptomatic improvement.

Conclusions

SONATA is associated with significant and sustained improvement in bleeding symptoms and quality of life in a real world cohort, with high rates of uterine preservation. However outcomes are heterogenous and further prospective studies with longer follow-up are warranted.

ESGE35-0415 - P084
ePoster Presentations

Laparoscopic excision of a non-communicating right rudimentary uterine horn with ipsilateral salpingectomy: a case report

Karolina Bednarz[1], Jakub Staniczek[1], Rafał Stojko[1], Marcin Sadłocha[1]
[1]Medical University of Silesia,
Chair and Clinical Department of Gynaecology- Obstetrics and Gynaecological Oncology, Katowice, Poland

Background

To describe the diagnostic work-up and stepwise laparoscopic excision of a symptomatic non-communicating right rudimentary uterine horn with functional endometrium, focusing on anatomical mapping, ureteric safety, and preservation of the functional hemi-uterus.

Methods

A 36-year-old patient was hospitalised at the Chair and Clinical Department of Gynaecology, Obstetrics and Gynaecological Oncology, Medical University of Silesia in Katowice, Poland, due to progressive dysmenorrhoea and recurrent right-sided pelvic pain that had become insufficiently controlled with conservative treatment. Previous diagnostic laparoscopy had been performed elsewhere, but no operative documentation was available. Pelvic ultrasonography suggested a unicornuate uterus with an accessory right-sided cavitated structure. Magnetic resonance imaging confirmed a 32 x 18 x 19 mm uterine-like structure located posteriorly and superiorly to the right broad ligament, without identifiable continuity with the main uterine cavity, and helped define its relationship to the adnexa, bladder and pelvic sidewall. After pregnancy was excluded and written informed consent for treatment, presentation and publication was obtained, operative laparoscopy was performed. The right fallopian tube and rudimentary horn were identified. The retroperitoneal space was opened, the ureter was visualised and the uterine vessels were assessed. Ipsilateral salpingectomy and excision of the horn from the functional hemi-uterus were performed with meticulous haemostasis. The myometrial defect was closed laparoscopically and the specimen was submitted for histopathological examination.

Results

The procedure was completed entirely laparoscopically without conversion to laparotomy. Blood loss was minimal, and no injury to the ureter, bladder, bowel or preserved uterus occurred. Postoperative recovery was uneventful, with early mobilisation and discharge in good clinical condition. Histopathology confirmed a rudimentary uterine horn with functional endometrial tissue and a fallopian tube, with no evidence of malignancy. At follow-up, the patient reported complete resolution of cyclic right-sided pelvic pain and marked improvement in dysmenorrhoea. No early postoperative complications or recurrent haematometra were observed.

Conclusions

Laparoscopic excision of a symptomatic non-communicating functional rudimentary horn with ipsilateral salpingectomy can provide definitive, fertility-sparing treatment when preceded by high-quality imaging and careful operative planning. Key safety steps include preoperative anatomical mapping, retroperitoneal ureteric identification, controlled dissection from the functioning hemi-uterus, secure haemostasis and laparoscopic reconstruction of the myometrium. Early recognition and treatment may relieve pain and reduce risks related to obstructed menstruation, endometriosis and future rudimentary horn pregnancy.

ESGE35-0428 - P085
ePoster Presentations

Is office hysteroscopy a useful approach for repositioning displaced intrauterine devices? Clinical outcomes and cost considerations

Belén Ortiz Cruz[1], Inés Abad Martínez[1], Isabel Martínez Walters[1], Juan José Delgado Espeja[1], Rocío García Berrio[1], Juan Antonio Solano Calvo[1]
[1]University Hospital Príncipe de Asturias, Obstetrics and Gynaecology, Madrid, Spain

Background

IUD displacement and partial expulsion are recognized complications that may compromise contraceptive efficacy and often lead to device removal. Hysteroscopic repositioning has been proposed as an alternative strategy to preserve the device, though evidence on its effectiveness remains limited. The aim of this study was to assess the usefulness of office hysteroscopy for repositioning displaced or partially expelled intrauterine devices (IUDs) as a strategy to preserve the device rather than removing and replacing it. The primary outcome was the rate of IUD expulsion or re-displacement during follow-up after repositioning. Secondary outcomes included the duration of correct IUD positioning prior to re-displacement and a comparison of the economic impact of hysteroscopic repositioning versus new IUD insertion.

Methods

This retrospective descriptive study included patients who underwent office hysteroscopic repositioning of a partially expelled IUD between 2020 and March 2026 at our center. Only cases in which the repositioning procedure was successful were included. During the procedure, IUDs that had descended into the endocervical canal were repositioned to the uterine fundus under hysteroscopic guidance, following a thorough evaluation of the uterine cavity. Patients were subsequently followed up in the outpatient setting to assess IUD retention and correct positioning using transvaginal ultrasound. Data from the procedures and follow-up visits were obtained from medical records, while cost data were retrieved from the Official National Registry of Public Healthcare costs.

Results

A total of 27 patients with ultrasound-confirmed IUD descent into the endocervical canal underwent successful office hysteroscopic repositioning. 15 patients (55.56%) experienced IUD expulsion or re-displacement during follow-up, while 10 patients (37.04%) maintained correct IUD positioning. Two patients (7.41%) were lost to follow-up. Among the 15 patients with expulsion or redisplacement, 8 cases (53.33%) occurred at the 2-month follow-up visit, 4 cases (26.67%) between 2 months and 1 year, and 3 cases (20.00%) more than 1 year after the procedure. Regarding economic costs, the average cost of office hysteroscopy in the Spanish Public Healthcare System is approximately €450, whereas outpatient IUD insertion costs €212. The cost of the IUD is not covered when used for contraceptive purposes and is approximately €110.

Conclusions

Hysteroscopic repositioning of partially expelled or displaced IUDs appears to be an ineffective approach, given the high rate of expulsion or redisplacement observed. Alternative strategies, including removal and reinsertion of a new IUD, should be considered, although further studies are needed to confirm these findings. From a cost perspective, direct IUD replacement appears to be a more cost-effective strategy than office hysteroscopic repositioning.

ESGE35-0432 - P086
ePoster Presentations

Intrauterine adhesions after hysteroscopic metroplasty for dysmorphic uterus

Duna Trobo Marina[1], Laura Pérez Martín[1], María Teresa Navarro Gonzalez[1], Elena Ceballos Garcia[1], Sonsoles Moreno Hernandez[1], Federico Mariano Perez Milan[1]
[1]Hospital General Universitario Gregorio Marañón, Obstetrics and Gynaecology, Madrid, Spain

Background

T-shaped uterus is a congenital uterine anomaly associated with infertility, recurrent pregnancy loss, and impaired reproductive outcomes. Hysteroscopic metroplasty has become an increasingly adopted minimally invasive procedure to restore normal uterine cavity morphology and improve fertility potential. Despite its widespread use, concerns remain regarding postoperative complications, particularly the development of intrauterine adhesions, which may negatively affect menstrual function and future reproductive outcomes. Current evidence on the incidence and clinical significance of adhesions following hysteroscopic metroplasty for T-shaped uterus remains limited. This study aims to evaluate the risk of intrauterine adhesion formation after hysteroscopic metroplasty and its impact on subsequent reproductive outcomes in infertile patients.

Methods

Descriptive retrospective study reporting intrauterine adhesions occurred in infertile patients hysteroscopic metroplasty for dysmorphic uterus, in a tertiary University Hospital in Madrid (Spain) between January 2023 and December 2025. Result variables in the exposed population are expressed in absolute numbers and percentages.

Results

A total of 42 hysteroscopic metroplasties were performed during the study period in patients diagnosed with dysmorphic uterus. Among them, 22 patients were diagnosed with T-shaped uterus, 12 with Y-shaped uterus, 6 with tubular/I-shaped uterus, and 2 with incomplete uterine septum. Mean patient age was 37,8 years, with a mean infertility duration of 2,21 years. Mean Anti-Müllerian Hormone levels were 2,33 ng/ml. Twenty out of 42 patients had a history of previous uterine surgery, including 3 myomectomies, 16 uterine curettages, and 1 caesarean section. Concomitant endometriosis or adenomyosis was present in 6 patients. Eight patients required two procedures in order to achieve a satisfactory metroplasty. Bipolar energy was used in 22 procedures, whereas scissors were employed in 20 cases. Anti-adhesion treatment with hyaluronic acid gel was administered in 28 patients. Postoperative intrauterine adhesions were diagnosed in 5 patients. None of these patients had undergone metroplasty using bipolar energy, and 3 of them had additionally received intrauterine hyaluronic acid gel for adhesion prevention. Furthermore, 5 patients presented with persistently thin endometrium (<7 mm) following metroplasty; notably, all of them had already demonstrated thin endometrium prior to surgery.

Conclusions

Hysteroscopic metroplasty for the correction of dysmorphic uterus appears to be a safe procedure with a relatively low rate of postoperative intrauterine adhesions. In this cohort, intrauterine adhesions were not observed in patients treated with bipolar energy, suggesting that the use of electrosurgical techniques may not increase the risk of intrauterine synechiae when appropriately performed. Moreover, the persistence of thin endometrium after surgery seemed to be associated with pre-existing endometrial impairment rather than the metroplasty procedure itself. Further prospective studies with larger sample sizes are needed to better identify risk factors for intrauterine adhesion formation and to evaluate the potential protective role of anti-adhesion strategies following hysteroscopic metroplasty.

ESGE35-0463 - P089
ePoster Presentations

Haemothorax as the First Presentation of Endometriosis

Suzie Gordon[1], Mihai Gherghe[1], Mohammed Allam[1]
[1]University Hospital Wishaw, Gynaecology Department, NHS Lanarkshire, United Kingdom

Background

Thoracic endometriosis syndrome (TES) is uncommon and often diagnosed late. We present a case of haemothorax as the initial presentation of extensive pelvic and thoracic endometriosis, initially investigated as possible ovarian malignancy with thoracic spread.

Methods

A 38-year-old Nigerian woman, P0+4, BMI 24, ASA 1, presented to respiratory physicians with acute right-sided chest pain and shortness of breath after an 18-month history of worsening catamenial right chest and shoulder-tip pain. Her background included hypertension, previous open appendicectomy, evacuation of miscarriage complicated by uterine perforation, laparoscopic adhesiolysis and uterine repair, laparoscopic myomectomy, and five unsuccessful IVF cycles with recurrent miscarriage. She was a non-smoker and did not drink alcohol.

Examination revealed reduced right-sided air entry and coarse crepitations. She remained haemodynamically stable without oxygen requirement. Chest radiograph demonstrated a large right pleural effusion. Ultrasound-guided drainage removed 600ml of bloodstained pleural fluid. Cytology was negative for infection or malignancy; microscopy showed inflammatory cells, reactive mesothelial cells and haemosiderin-laden macrophages.

Further imaging was undertaken for suspected occult malignancy. CT demonstrated a mixed-density left adnexal lesion measuring 8.8 × 6.6 × 5.2 cm, associated haematosalpinx, omental and peritoneal infiltration, and persistent pleural effusion. Transvaginal ultrasound suggested a left endometrioma. Pelvic MRI showed adenomyosis, bilateral haemorrhagic endometriomas, widespread adhesions and possible deep infiltrating endometriosis involving the bladder. Tumour markers showed negative hCG, LDH 339 and CA125 752.

Results

Following multidisciplinary discussion, the clinical history and imaging were considered consistent with TES, with raised CA125 attributed to extensive endometriosis and LDH to resorption of haemorrhagic fluid. She commenced triptorelin 11.25 mg with tibolone 2.5 mg add-back therapy. Within 1–2 weeks she developed severe abdominal, pelvic and chest pain, worsening exertional breathlessness and 16 days of vaginal bleeding. This was complicated by recurrent right pleural effusion with mediastinal shift requiring chest drain insertion. Clinically suspicious for exacerbation of endometriosis related to GnRH flare effect. Five weeks later she was amenorrhoeic with reduced symptom burden.

She was referred to cardiothoracic surgery and underwent robotic single-port video-assisted thoracoscopic surgery. Findings included suspected posterior pleural endometriosis, diaphragmatic

fenestrations and extensive adhesions between lung lobes, chest wall and diaphragm. Diaphragmatic and posterior pleural endometriosis were excised and adhesiolysis performed. She awaits definitive gynaecological management, likely including laparoscopic pelvic clearance.

Conclusions

Haemothorax due to endometriosis was first reported in 1953, yet TES remains difficult to diagnose. TES should be suspected in patients with catamenial pneumothorax, haemothorax, haemoptysis or pulmonary nodules, particularly with symptoms or imaging suggestive of pelvic endometriosis. Most reported cases are right-sided (90%) and many patients have co-existing pelvic disease (>80%), especially deep endometriosis. This case highlights the importance of recognising catamenial thoracic symptoms to avoid delay, unnecessary malignancy pathways and repeated pleural interventions.

ESGE35-0486 - P093
ePoster Presentations

Central Sensitization Inventory in Adenomyosis: An Exploratory Validation Study

Federica Tegazi[1,2], Linda Bertoldo[1,2], Caterina Bianchedi[1,2], Alberto Aguzzi[1,2], Renato Seracchioli[1,2], Diego Raimondo[1]
[1]IRCCS Azienda Ospedaliero-Universitaria di Bologna- Bologna- Italy,
Division of Gynaecology and Human Reproduction Physiopathology-, Bologna, Italy
[2]University of Bologna, Department of Medical and Surgical Sciences DIMEC, Bologna, Italy

Background

Central sensitization (CS), assessed using the Central Sensitization Inventory (CSI), shows a high prevalence among patients with endometriosis (41.1%-59.2%). Higher baseline CSI scores have also been associated with poorer postoperative pain outcomes. The association between adenomyosis and Central Sensitivity Syndromes (CSSs) has not yet been investigated, and the CSI has not been validated in adenomyosis patients. Therefore, the aim of the present study was to evaluate the ability of the CSI to identify patients with adenomyosis presenting with ≥3 CSSs and to determine the optimal cut-off value.

Methods

Prospective, single-center, observational study conducted at the IRCCS Azienda Ospedaliero-Universitaria di Bologna, a tertiary referral center for endometriosis and adenomyosis care, and reported according to STROBE guidelines. Women aged 18–50 years with ultrasound-diagnosed adenomyosis based on MUSA criteria were enrolled from December 10, 2025, to March 31, 2026. Clinical, demographic, ultrasound, and pain-related data were prospectively collected. Receiver Operating Characteristic (ROC) curve analysis was performed to assess the discriminative ability of the CSI and to identify an optimal cut-off value, followed by group comparisons based on this threshold and multivariable models to identify risk factors for central sensitization.

Results

A total of 147 women with adenomyosis were included in the study, with a mean (±SD)age of 35.9 (±8.1) years and a mean (±SD) CSI score of 37.4 (±17.0). 46.9% of patients reported at least one CSS. ROC analysis demonstrated a fair-to-good ability of the CSI to identify women reporting ≥3 CSSs (AUC=0.779). A CSI cutoff of ≥48 provided the best discriminative performance, with 76.8% specificity and 59.1% sensitivity. Women with CSI scores ≥48 showed significantly higher rates of deep dyspareunia (p=0.045), dysuria (p=0.013), and chronic pelvic pain (p<0.001).Applying 48 as cut off, the prevalence of central sensitization (CS) was 28.6% (42/147).Multivariable logistic regression analysis showed that chronic pelvic pain (NRS ≥5) was independently associated with CS (CSI ≥48) (OR 4.04; p=0.007). Similarly, temporomandibular joint disorders (OR 15.02; p=0.001) and anxiety and panic attacks (OR 3.97; p=0.004) were significantly associated with CS.

Conclusions

Our preliminary results suggest that the Central Sensitization Inventory may represent a useful tool for identifying central sensitization in patients with adenomyosis. The optimal cut-off identified (≥48) showed fair-to-good discriminative ability. The prevalence of CS in this patient population was 28.6%, and associated risk factors included chronic pelvic pain (NRS ≥5), anxiety and panic attacks, and temporomandibular disorders. Early identification of CS enables referral to a multidisciplinary therapeutic approach.

ESGE35-0490 - P094
ePoster Presentations

Placental Site Nodule: A Clinical Case.

Eleazar Bravo Moreno[1], Maria Elena Perez Morales[1], Cristina María Cornejo Rueda[1], Maria Alejandra Santana Suarez[1], Yolanda Gil Gonzalez[1], Alicia Inmaculada Martin Martinez[1]
[1]HOSPITAL UNIVERSITARIO MATERNO INFANTIL DE CANARIAS, OBSTETRICIA Y GINECOLOGÍA, LAS PALMAS DE GRAN CANARIA, Spain

Background

A placental site nodule (PSN) is an uncommon, benign lesion, usually discovered incidentally, composed of remnants of intermediate trophoblast cells. These cells form a well-defined nodule, single or multiple, in the uterus or, exceptionally, in extrauterine locations. Clinically, it is characterized by abnormal uterine bleeding. Histologically, placental site nodules (PSNs) are composed of trophoblastic cells, without mitotic activity or atypia, which differentiates them from neoplastic lesions with which they may share clinical characteristics, such as placental site trophoblastic tumors.

Objective: To report a case of placental bed nodule diagnosed at our center, its clinical characteristics, diagnosis, and treatment.

Methods

Clinical case

Results

A 36-year-old woman with no relevant personal or family history. Her history included one delivery and three miscarriages.

In October 2024, she underwent a voluntary termination of pregnancy (VTP) that was successfully treated with medication. A follow-up transvaginal ultrasound revealed a 10 mm endometrium. In January 2025, she went to the emergency department due to metrorrhagia, associated with mild, continuous, non-radiating lower abdominal pain. On examination it was observed that there was heavy vaginal bleeding. The cervix was closed. A transvaginal ultrasound was performed, revealing an endometrial cavity distended with a vacuolated, heterogeneous image inside. In the right adnexa functional follicle was observed. The left adnexa was normal. A small amount of free fluid was present in the pouch of Douglas. Laboratory tests were not pathological findings, and a negative pregnancy test.

During her stay in the emergency department, she remained hemodynamically stable.

In January 2025, a follow-up appointment was scheduled in the Gynaecology clinic. Given the persistence of a 16x25mm heterogeneous formation on the anterior wall with moderate vascularization and a Doppler score of 1-2 suggestive of retained products of conception, a diagnostic hysteroscopy was indicated.

During the hysteroscopy, the following was observed: normal vaginoscopy, normal external cervical os, normal cyclic canal, normal internal cervical os, normal morphology of the vaginal cavity, visualized ossification, hypotrophic endometrium with a pregestational effect, and a minimal necrotic pearly formation on the anterior wall, consistent with an area of retained products of conception, which was sent for histopathological study with te results: placental bed nodule.

Follow-up was conducted in the Gynaecology clinic without any episodes of bleeding.

Conclusions

Placental bed nodules occur in women of reproductive age with a history of previous pregnancy. They are usually found incidentally, as a histopathological result after a dilation and curettage (D&C) or hysterectomy performed for other indications. They are usually asymptomatic but may be associated with metrorrhagia or pelvic pain. The nodules are not usually visible macroscopically, and the diagnosis is typically made through histopathology.

The importance of their correct diagnosis lies in being able to distinguish them from malignant variants of trophoblastic disease.

ESGE35-0494 - P095
ePoster Presentations

Focal atypical hyperplasia in polyps: a case report.

Eleazar Bravo Moreno[1], Maria Elena Perez Morales[1], Carla del Pino Dominguez Sanchez[1], Maria Alejandra Santana Suarez[1], Yolanda Gil Gonzalez[1], Alicia Inmaculada Martin Martinez[1]
[1]HOSPITAL UNIVERSITARIO MATERNO INFANTIL DE CANARIAS, OBSTETRICIA Y GINECOLOGÍA, LAS PALMAS DE GRAN CANARIA, Spain

Background

Endometrial polyps are localized hyperplastic overgrowths of glands and stroma. Although the vast majority are benign, the reported incidence of malignancy ranges between 3.4% and 3.57%. Factors such as obesity, age, and infertility increase the risk of developing them. The risk of coexisting hyperplasia (with or without atypia) has been reported in 7–18% of patients with polyps. In patients desiring fertility, polypectomy is the treatment of choice, as it may improve pregnancy rates.

Methods

A 38-year-old woman with a history of allergic rhinitis and hypermenorrhoea presented with active reproductive desire. Following an initial evaluation for suspected endometrial polyp and a period of expectant management at the patient's request, she was referred to the reproductive medicine unit for infertility assessment. Complete resection was performed by hysteroscopy. Histopathological examination revealed a 4 × 4 mm focus of focal atypical hyperplasia within one of the polyps. After multidisciplinary evaluation with the oncology department, where treatment options including progestin therapy or definitive surgery were discussed, the patient reaffirmed her priority of fertility preservation. A subsequent follow-up hysteroscopy with targeted endometrial biopsy demonstrated proliferative endometrium without evidence of atypia or malignancy. The case concluded with successful reproductive outcome, as spontaneous pregnancy was achieved immediately afterward, demonstrating that selective resection and close surveillance are viable alternatives for the management of focal atypical lesions in patients wishing to preserve fertility.

Results

The management of polyps with focal atypia in young patients is challenging. Current literature suggests that hysteroscopic polypectomy is superior to curettage, as the latter may miss focal lesions. In this case, the lesion was strictly focal (4 × 4 mm) within a 2 cm polyp. Although the standard treatment for atypical hyperplasia is hysterectomy with bilateral salpingo-oophorectomy, comprehensive conservative management may be considered in patients with reproductive desire once resolution of the lesion has been confirmed (with conservative treatment consisting of progestins with or without hysteroscopic follow-up). In infertility settings, removal of polyps has been shown to improve pregnancy rates, particularly prior to assisted reproductive techniques.

Conclusions

Follow-up biopsy showed proliferative endometrium without atypia. The success of conservative management was confirmed by the achievement of spontaneous pregnancy (LMP 09/11/2025) only one month after hysteroscopy. This highlights that complete resection of polyps with focal atypia may be a viable and safe fertility-preserving option in carefully selected patients under strict follow-up.

ESGE35-0500 - P096
ePoster Presentations

HyCoSy in Infertility Workup: Just a Tubal Test or a Comprehensive Assessment?

Ping Tan[1], *Maria Constantinides*[1], *Shital Sawant*[1]
[1]*Newham University Hospital, Obstetrics and Gynaecology, London, United Kingdom*

Background

To evaluate the diagnostic utility and safety of Hysterosalpingo-contrast sonography (HyCoSy) in the assessment of tubal patency, uterine abnormalities and ovarian reserve in women referred for fertility evaluation.

Methods

A retrospective cohort study of patients undergoing HyCoSy for infertility assessment was undertaken at a secondary care NHS university hospital in London, United Kingdom. Demographic characteristics, antral follicle count (AFC), uterine and adnexal findings, tubal patency and procedural outcomes were analysed. Tubal patency and cavity assessment was determined by contrast flow. Complications and procedural success were recorded.

Results

A total of 172 patients underwent HyCoSy for infertility assessment. The mean age was 33.5 (range 22-43) with a mean body mass index of 26.7 kg/m² (range 17.0 - 40.85 kg/m²). The cohort was predominantly Asian (61.2%), followed by white (18.2%) and black (12.4%) ethnic groups. Primary infertility was present in 75.4% of patients, and secondary infertility in 24.6%. Polycystic ovary syndrome (PCOS) was identified in 35.6% of patients.

Analgesia was administered in 71.0% of patients; easy cannulation was achieved in 61.4%, while a tenaculum was required in 27.5%. Uterine pathology was identified in 23.1% of cases, most commonly fibroids (10.7%), including submucosal fibroids (1.8%), followed by polyps (4.8%) and adenomyosis (3.6%). 7 (4%) patients had features suggestive of endometriosis including presence of endometrioma or adherent ovaries. Other findings were uncommon, including caesarean scar niche (1.16%). Bilateral tubal patency was demonstrated in 85.1% of patients, with 14.9% showing impaired or absent patency. Hydrosalpinx was identified in 0.6% of cases and free fluid was present in 2.4%. 6 (3.4%) patients underwent laparoscopy and dye test following HyCoSy for further evaluation.

The majority of patients demonstrated AFC > 20(43.29 %) with AFC 5–20 in 50.61% and low AFC <5 in 6.1%. The average age in the low AFC group was 38.1 years old.

Complications were minimal, with bleeding, post-procedural infection and vasovagal reactions each observed in 0.6% of cases with no allergic reactions reported. The procedure failure rate was 1.78 %.

Conclusions

HyCoSy enables comprehensive infertility assessment, providing evaluation of tubal patency and pelvic pathology with a favourable safety profile. in addition, it facilitates identification of uterine abnormalities, endometriosis and appropriate referral such as for hysteroscopic or laparoscopic management prior to assisted reproductive treatment when indicated.

ESGE35-0517 - P099
ePoster Presentations

Assessment of the breast imaging findings and mastalgia in women with endometriosis compared to women without endometriosis

Mehtap Korkut[1], Meryem Hocaoglu[2], Ibrahim ali Ozemir[3], Surahbil Yagbasa[3], Abdulkadir Turgut[4]
[1]Catak State hospital, Department of Obstetrics and Gynaecology, Van, Türkiye
[2]Prof. Dr. Süleyman Yalçın City Hospital, Department of Obstetrics and Gynaecology, İstanbul, Türkiye
[3]Prof. Dr. Süleyman Yalçın City Hospital, Department of General Surgery, İstanbul, Türkiye
[4]Prof. Dr. Süleyman Yalçın City Hospital, Department of Obstetrics and Gynaecology, Istanbul, Türkiye

Background

Growing evidence suggests a positive association between endometriosis and breast diseases. We aimed to investigate breast imaging findings and mastalgia in women with endometriosis compared to those without endometriosis.

Methods

This retrospective study included women initially diagnosed with endometriosis who were candidates for hormonal therapy, as well as consecutive patients without endometriosis (control group) who underwent routine breast screening between January 2022 and May 2025. All participants underwent breast imaging modalities, including mammography (MMG), breast ultrasonography (USG), and/or magnetic resonance imaging (MRI), as well as breast examinations conducted by the General Surgery Department. Clinical and demographic data were retrieved from the electronic medical record system and compared between the two groups.

Results

The presence of a family history of breast cancer, infertility, lactation status, parity, age at menarche, and age at first pregnancy did not significantly different between the two groups ($p>0.05$).However, the presence of deep dyspareunia, dysmenorrhea, and the use of progestins was significantly higher in the endometriosis group ($p<0.001$). The presence of mastalgia and the mean visual analogue scale (VAS) scores for mastalgia were significantly higher in women with endometriosis compared to the controls (3.31 ± 2.81 vs. 1.73 ± 2.58, $p<0.001$). Moreover, there were no significant differences in terms of MMG BI-RADS scores ($p=0.957$), breast density distribution (Type A–D; $p=0.947$), MMG ($p=0.911$), and USG findings between the groups ($p>0.05$). According to MRI evaluation, the number of BI-RADS 1–3 findings was significantly higher in the endometriosis group ($p=0.022$). However, no significant differences were observed between the two groups concerning breast density and lesion types ($p>0.05$).

Conclusions

The prevalence and severity of mastalgia, as well as the number of BI-RADS 1–3 findings on MRI, were significantly higher in the endometriosis group, compared to the control group. Our findings emphasize that women with endometriosis need to undergo regular breast screening.

ESGE35-0520 - P100
ePoster Presentations

Operating in Reverse: Multidisciplinary Laparoscopic Excision of Stage IV Rectosigmoid Endometriosis in Complete Situs Inversus

Saima Farooq[1], Eleni Mavrides[1], Suliman Ibnauf[1]
[1]Royal Free Hospital, Gynaecology, LONDON, United Kingdom

Background

Deep infiltrating endometriosis (DIE) involving the bowel represents one of the most technically demanding forms of advanced pelvic surgery. The coexistence of complete situs inversus further increases operative complexity because of mirror-image visceral anatomy, distorted pelvic landmarks, and altered surgical orientation. Reports describing radical excision of advanced bowel endometriosis in patients with situs inversus remain exceptionally rare.

Methods

Case Presentation

A 31-year-old nulliparous woman presented with severe dysmenorrhoea, chronic pelvic pain, dyspareunia, and stage IV endometriosis refractory to hormonal treatment. MRI and multidisciplinary team review demonstrated severe posterior compartment DIE with rectosigmoid involvement, complete obliteration of the pouch of Douglas, bilateral ovarian fixation, bladder endometriosis, and extensive pelvic fibrosis. Complete situs inversus with dextrocardia was identified preoperatively. Additional comorbidities included inflammatory connective tissue disease managed with Rituximab.

Surgical Technique

Following multidisciplinary planning involving gynaecology, colorectal surgery, and urology teams, prophylactic bilateral ureteric stents were inserted under fluoroscopic guidance prior to surgery. Laparoscopy demonstrated extensive endometriosis involving the pelvic sidewalls, rectovaginal septum, sigmoid colon, mid-rectum, bladder, ovaries, umbilicus, and pelvic peritoneum. Mirror-image anatomy was confirmed with the liver occupying the left upper quadrant and sigmoid colon located within the right hemipelvis.
Extensive bilateral ureterolysis and adhesiolysis were performed. Deep rectovaginal endometriosis was excised with mobilisation of the sigmoid and descending colon. An anterior resection with primary colorectal anastomosis was undertaken for severe rectosigmoid disease. Intraoperative indocyanine green (ICG) fluorescence confirmed satisfactory bowel vascularisation. Flexible sigmoidoscopy, air leak testing, and methylene blue testing confirmed anastomotic integrity. Additional procedures included excision of bladder and umbilical endometriosis, drainage of a right ovarian abscess, right salpingectomy, and concurrent left inguinal hernia repair.

Results

The procedure was completed laparoscopically without intraoperative complications or requirement for stoma formation. Histopathology confirmed extensive endometriosis involving the bowel, bladder, adnexa, and pelvic peritoneum. The postoperative recovery was satisfactory with multidisciplinary follow-up and delayed ureteric stent removal at six weeks.

Conclusions

This case demonstrates the feasibility of radical multidisciplinary laparoscopic excision of advanced bowel endometriosis in the setting of complete situs inversus. Profound anatomical distortion combined with reversed visceral orientation requires meticulous surgical planning, advanced anatomical awareness, and collaborative expertise to achieve safe disease clearance while minimising morbidity.

ESGE35-0522 - P101
ePoster Presentations

Through the Looking Glass: Immediate Recognition and Precision Layered Repair of Endometrial Cavity Breach During Complex Laparoscopic Myomectomy

Saima Farooq[1], *Fevzi Shakir*[1]
[1]*Royal Free Hospital, Gynaecology, LONDON, United Kingdom*

Background

Endometrial cavity breach is a recognised challenge during complex laparoscopic myomectomy, particularly in women with submucosal fibroids and coexisting deep infiltrating endometriosis. Prompt intraoperative recognition and meticulous reconstruction are essential to preserve uterine integrity and optimise reproductive outcomes.

Methods

Case: A 41-year-old nulliparous woman presented with symptomatic fibroids, chronic pelvic pain, and MRI-confirmed deep infiltrating endometriosis involving the rectum and pouch of Douglas, associated with haematosalpinx and severe pelvic adhesions. Technique:A complex laparoscopic procedure was undertaken including myomectomy, excision of endometriosis, extensive adhesiolysis, right salpingectomy, bilateral ureterolysis, and ICG-guided ureteric identification. During excision of a deeply located submucosal fibroid, inadvertent entry into the endometrial cavity occurred and was recognised immediately. The defect was repaired using a meticulous layered closure technique. The endometrium was approximated using interrupted Vicryl sutures, followed by multilayer myometrial reconstruction with barbed sutures to restore uterine architecture and achieve optimal haemostasis. Hypogastric nerve-sparing pelvic dissection was performed, and dense rectal adhesions were carefully released. Serosal reinforcement sutures were placed where indicated to optimise tissue integrity.

Results

The surgery was completed entirely laparoscopically with minimal blood loss and no intraoperative complications. Ureteric integrity was preserved bilaterally, and satisfactory anatomical restoration was achieved. The postoperative course was uncomplicated, and the patient was discharged home on postoperative day three.

Conclusions

This video highlights the importance of immediate recognition and structured layered repair of endometrial cavity breach during advanced laparoscopic myomectomy. With careful surgical planning, precise reconstruction, and adherence to anatomical principles, complex fertility-preserving surgery can be performed safely even in the setting of severe endometriosis and distorted pelvic anatomy.

ESGE35-0528 - P102
ePoster Presentations

Laparoscopic Myomectomy in Severe Endometriosis: Management of Endometrial Cavity Breach During Submucosal Fibroid Excision

Saima Farooq[1], *Fevzi Shakir*[1]
[1]*Royal Free Hospital, Gynaecology, LONDON, United Kingdom*

Background

Coexisting fibroids and deep infiltrating endometriosis (DIE) present significant surgical challenges due to distorted pelvic anatomy and increased technical complexity. Submucosal fibroids carry a recognised risk of breaching the endometrial cavity during myomectomy, requiring prompt recognition and meticulous repair to preserve uterine integrity.

Methods

Case Presentation:

A 41-year-old nulliparous woman presented with heavy menstrual bleeding, dysmenorrhoea, and pressure symptoms significantly affecting her quality of life. Imaging demonstrated an enlarging intracavitary submucosal fibroid (3.4 cm) and a 5 cm fundal fibroid, alongside features of DIE with rectal attachment, pouch of Douglas scarring, and right haematosalpinx. Following multidisciplinary discussion, she underwent laparoscopic myomectomy with excision of endometriosis.

Surgical Technique:

Laparoscopic myomectomy was performed using vasopressin-assisted dissection. Following removal of the fundal fibroid, excision of the submucosal fibroid resulted in entry into the endometrial cavity, which was immediately recognised. A structured layered repair was performed using 2-0 Vicryl for endometrial closure followed by barbed sutures for myometrial reconstruction, ensuring restoration of uterine integrity and haemostasis.

Extensive adhesiolysis and excision of endometriosis were undertaken. Bilateral ureterolysis was performed with indocyanine green (ICG) guidance, and hypogastric nerve-sparing dissection was employed. Bowel adhesions were released, and areas of rectal serosal thinning were reinforced with sutures. A right salpingectomy was performed for haematosalpinx.

Results

The procedure was completed laparoscopically without conversion. Blood loss was minimal (100 mL). The postoperative course was uncomplicated, and the patient was discharged on day 3. Histology confirmed benign leiomyoma and widespread endometriosis, including rectovaginal and paracolic nodules.

Conclusions

This case demonstrates that endometrial cavity breach during laparoscopic myomectomy, particularly in the presence of submucosal fibroids and DIE, can be safely managed with prompt recognition and meticulous layered repair. Advanced laparoscopic techniques enable effective management of complex pathology while preserving uterine integrity.

ESGE35-0532 - P103
ePoster Presentations

Nerve-Sparing Laparoscopic Management of Deep Infiltrating Endometriosis with Rectal Involvement: A Multidisciplinary Case Approach

Saima Farooq[1], *Fevzi Shakir*[1]
[1]*Royal Free Hospital, Gynaecology, LONDON, United Kingdom*

Background

Deep infiltrating endometriosis (DIE) involving the bowel represents one of the most severe forms of the disease, often associated with significant pain, distorted pelvic anatomy, and complex surgical challenges. Optimal management frequently requires a multidisciplinary approach and advanced laparoscopic techniques to achieve complete excision while preserving function.

Methods

Case Presentation:

A 40-year-old woman (P1) presented with severe dysmenorrhoea, dyspareunia, and chronic pelvic pain significantly impacting her quality of life and mental wellbeing. She had a history of bilateral endometriomas and previously failed hormonal management, including removal of a levonorgestrel intrauterine system due to pain. MRI demonstrated deep infiltrating endometriosis with rectosigmoid involvement, posterior compartment scarring with pouch of Douglas obliteration, and large bilateral endometriomas (up to 7.7 cm), with both ovaries fixed in the midline. Preoperative colonoscopy was normal, and CT imaging showed no ureteric obstruction. Following multidisciplinary team discussion and colorectal surgical input, she opted for definitive surgical management, having completed her family.

Surgical Technique:

The patient underwent total laparoscopic hysterectomy with bilateral salpingo-oophorectomy, extensive adhesiolysis, bilateral ureterolysis with indocyanine green (ICG) guidance, and hypogastric nerve-sparing dissection. Bilateral endometriomas were excised, and the appendix was removed due to disease involvement. Dense adhesions between the rectum and posterior uterus were carefully dissected. A rectal shaving technique was performed for bowel endometriosis, followed by reinforcement of the rectal serosa with suturing. Intraoperative sigmoidoscopy and air leak testing confirmed bowel integrity.

Results

The procedure was completed laparoscopically without the need for bowel resection. Blood loss was minimal (100 mL), and there were no intraoperative complications. The postoperative course was uneventful, and the patient was discharged on day 3. Histology confirmed widespread endometriosis involving the uterus, ovaries, fallopian tubes, appendix, and rectosigmoid nodules, with coexisting adenomyosis.

Conclusions

This case highlights the feasibility and safety of advanced nerve-sparing laparoscopic excision of complex DIE with bowel involvement without the need for segmental resection. A multidisciplinary approach, combined with meticulous surgical technique and adjuncts such as ICG-guided ureterolysis, allows effective disease clearance while minimising morbidity.

ESGE35-0536 - P105
ePoster Presentations

From Scan to Scalpel: A retrospective comparison of imaging, surgical findings and histology in posterior compartment disease.

Philippa Hallchurch[1], *Jennifer Shallop*[1], *Sharon Davidesko*[1], *Alexander Knighton*[2], *Prashant Purohit*[2], *Nitish Narvekar*[2]
[1]*King's College Hospital, Department of Obstetrics and Gynaecology, London- UK, United Kingdom*
[2]*King's College Hospital, Department of Obstetrics and Gynaecology, London- UK, United Kingdom*

Background

Accurate pre-operative imaging is useful in the diagnosis and management of endometriosis, particularly deep infiltrating disease. MRI is widely used for pre-operative mapping and performs well for certain anatomical sites; however, sensitivity varies by location, and its correlation with histological findings remains less well characterized. Precise surgical excision with histological confirmation underpins quality-assured care and definitive diagnosis. This audit examines the correlation between pre-operative MRI findings, surgical findings, and histological results across three anatomical sites within the posterior compartment.

Methods

A retrospective audit of all complex endometriosis surgical cases performed at a BSGE-accredited centre between January and December 2025 was conducted. Pre-operative MRI findings were compared with intra-operative surgical findings and histological confirmation of excised lesions. Variables assessed included site of MRI-identified disease, concordance with intra-operative findings, and histological confirmation for posterior compartment lesions.

Results

A total of 57 patients were included, of which 40 had pre-operative MRI, and the majority underwent robotic (68%) compared to laparoscopic approach (32%). Across 105 posterior compartment site-level samples, the proportion of surgically identified sites confirmed on histology was 47% overall, with right pararectal nodule sites yielding the highest rate (59%; 13/22).In 17 procedures rectal shave was performed. Pre-operative MRI was performed in 81% of positive cases but correctly identified rectal nodules in only 33%, with the majority identified intra-operatively in the absence of MRI. In the pararectal, mesorectal and bowel subgroup, 38 cases were reviewed. MRI performed poorly as a negative predictor: of 19 MRI-negative patients over a third were found to have positive histology confirming endometriosis (36%). Conversely, rectovaginal disease showed better concordance with a negative predictive value of 100%; however, interpretation is limited by small numbers of patients in this subgroup (n= 4). Notably, surgical PPV was highest in this subgroup when no prior MRI was performed (73%), highlighting the need for surgical attentiveness and potential for false reassurance from pre-operative imaging.

Conclusions

We demonstrate that pre-operative MRI can be an unreliable negative predictor for posterior compartment endometriosis at several anatomical sites, specifically in the pararectal, mesorectal, and bowel subgroup in our cohort. The higher histological confirmation rate observed in the absence of pre-operative MRI may underline the potential for imaging to create a degree of false reassurance, potentially unknowingly tapering the surgeon's intraoperative assessment. These findings support the development of standardised perioperative imaging protocols, such as ENZIAN, that account for site-specific diagnostic limitations. The data further underlines the importance of precise intra-operative detection of endometriosis and excision within dedicated endometriosis centres.
Prospective evaluation is warranted to validate these findings in the future.

ESGE35-0545 - P106
ePoster Presentations

Inguinal Endometriosis Associated with Deep Infiltrating Disease: The Role of Laparoscopic Management

Miruna Peiu[1], *Manu Andrei*[1], *Bratila Elvira*[1], *Coroleuca Catalin*[1]
[1]*Clinical Hospital of Obstetrics and Gynaecology Prof Dr Panait Sirbu Bucharest, Obstetrics and Gynaecology, Bucharest, Romania*

Background

To describe the diagnostic and surgical value of laparoscopy in patients with inguinal endometriosis associated with deep infiltrating endometriosis, emphasizing the importance of treating both the extra pelvic lesion and the underlying pelvic disease.

Methods

We reviewed three cases of patients diagnosed with inguinal endometriosis and associated deep infiltrating endometriosis. Clinical presentation, physical examination, magnetic resonance imaging findings, intraoperative disease distribution, surgical procedures and follow-up were analysed. The surgical strategy focused on complete excision of the inguinal lesion, treatment of associated pelvic endometriosis and reconstruction of the inguinal region when required.

Results

All three patients presented with symptoms suggestive of deep endometriosis, including dysmenorrhea, dyspareunia and chronic pelvic pain radiating toward the hip. In two cases, physical examination identified a painful inguinal mass. Magnetic resonance imaging demonstrated complex disease, including right inguinal masses associated with pelvic deep infiltrating endometriosis involving structures such as the parametrium, ovaries, rectosigmoid or adenomyosis.

All patients underwent laparoscopic management with complete excision of endometriotic lesions. Rectal endometriosis was present in all three cases and required segmental laparoscopic bowel resection. The round ligament was completely excised in two cases, reflecting its potential role as a pathway or site of inguinal disease extension. In two patients, mesh repair was used after excision to cover the hernia orifice and restore inguinal wall integrity. No recurrence was observed during follow-up, which ranged from one to six years.

Conclusions

Inguinal endometriosis is a rare extra pelvic manifestation that should raise suspicion for associated deep infiltrating pelvic disease, particularly when symptoms include dysmenorrhoea, dyspareunia or catamenial groin pain. Laparoscopy offers a critical advantage by allowing simultaneous exploration and treatment of both pelvic and inguinal disease in a single procedure. Management should not be limited to excision of the groin mass alone, but must include systematic pelvic evaluation, complete excision of associated deep infiltrating endometriosis and multidisciplinary reconstruction when indicated.

ESGE35-0578 - P108
ePoster Presentations

Clinical and reproductive outcomes following surgical treatment of isthmocele: a retrospective case series analysis

Neus Cuadern Puig[1], *Sonia Monreal*[2], *Elena Suarez*[3]
[1]*Hospital Vall d'Hebron, Department of Obstetrics and Gynaecology, Barcelona, Spain*
[2]*Hospital Vall d'Hebrón, Obstetrics and Gynaecology- Minimally Invasive Surgery, Barcelona, Spain*
[3]*Hospital Vall d'Hebrón, Obstetrics and Gynaecology- Minimally Invasive Surgery, Barcelona, Spain*

Background

Isthmocele is a myometrial defect, typically pouch-like in morphology, located at the site of a previous uterine scar, usually following a caesarean section. Its pathogenesis is attributed to deficient healing, and its prevalence after caesarean delivery varies widely in the literature (20%-70%). Although it may remain asymptomatic, it is frequently associated with gynecological manifestations such as abnormal uterine bleeding (AUB) and chronic pelvic pain, as well as secondary infertility. Furthermore, it increases the risk of severe obstetric complications, notably caesarean scar ectopic pregnancy, placenta accreta spectrum, and uterine rupture.

Methods

An observational, descriptive, and retrospective study was conducted on 12 patients diagnosed with isthmocele and surgically treated at Hospital Vall d'Hebron (2016–2025). Risk factors for deficient healing, clinical manifestations (spotting, AUB, chronic pelvic pain, dysmenorrhea and secondary infertility), previous caesarean sections, ultrasound parameters (uterine retroversion and residual myometrial thickness (RMT)), surgical approach, complications and postoperative outcomes (symptom resolution, pregnancy rate, and reintervention) were analysed.

Results

Twelve women aged 32–43 years diagnosed with isthmocele were included. Risk factors for impaired healing included coagulopathy (N=1/12; 8.33%), endometriosis (N=2/12; 16.67%), polymyomatous uterus (N=3/12; 25%), and smoking (N=2/12; 16.67%).
All patients had prior caesarean section (N=12/12; 100%). Regarding previous caesarean sections, eight patients had one (N=8/12; 66.67%), three had two (N=3/12; 25%), and one had four (N=1/12; 8.33%). All symptoms began after the last caesarean.
Most frequent symptoms were intermenstrual spotting (N=8/12; 66.67%) and infertility (N=6/12; 50%). AUB, dysmenorrhea, and pelvic pain occurred in (N=3/12; 25%).
On ultrasound, retroverted uterus was found in (N=7/12; 58.33%). The mean RMT value for all cases was 2.55 mm (0–6 mm), while the mean value in cases treated by hysteroscopy was 3.6 mm (2–6 mm).
Surgical treatment included hysteroscopy (N=5/12; 41.67%), laparoscopy (N=3/12; 25%), combined laparoscopy-hysteroscopy (N=1/12; 8.33%), and robotic surgery (N=2/12; 16.67%). Complete anatomical correction was achieved in (N=7/12; 58.33%) and symptom resolution in (N=9/12; 75%). In all cases, the symptoms persisted in the form of spotting.

Finally, among patients desiring pregnancy (N=5/12; 41.67%), all achieved viable pregnancy (N=5/5; 100%), spontaneous in (N=3/5; 60%) and In Vitro Fertilization in (N=2/5; 40%). In all cases, the pregnancy was delivered by caesarean section.

Conclusions

Surgical treatment of isthmocele is recommended in patients presenting with symptoms such as spotting, abnormal uterine bleeding, or secondary infertility. Hysteroscopic treatment might be a suitable option when the RMT is greater than 2.5–3 mm.

ESGE35-0599 - P109
ePoster Presentations

Cornual Pregnancy – Diagnostic Challenges and Therapeutic Options: Case Reports

Pavlina Magerova[1], Andrea Hledikova[2], Ivana Meixnerova[1], Robert Hudecek[1], Lenka Mekinova[1], Lubos Minar[1]
[1]University Hospital Brno, Department of Gynaecology- Obstetrics and Neonatology, Brno, Czech Republic
[2]Hospital University Brno, Department of Gynaecology- Obstetrics and Neonatology, Brno, Czech Republic

Background

Cornual (interstitial) pregnancy represents a rare yet clinically significant form of ectopic pregnancy resulting from implantation of the embryo within the interstitial portion of the fallopian tube, i.e., its intramural segment traversing the myometrium in the region of the uterine horn. Its incidence is estimated at approximately 1 in 2,500–5,000 pregnancies (2–4 % of ectopic pregnancies), while mortality reaches up to 2.5 %, which is up to seven times higher compared to other forms of ectopic pregnancy. The specific anatomy of this region, characterized by a thick myometrial layer and rich vascular supply, allows prolonged asymptomatic growth of the pregnancy. Cornual pregnancy usually manifests clinically from the 7th week of gestation, while rupture of the uterine horn typically occurs around the 12th gestational week and is associated with the risk of massive hemoperitoneum and hemorrhagic shock.

The main risk factors include previous tubal surgery, assisted reproductive techniques, and a history of pelvic inflammatory disease. Clinical presentation may vary widely, ranging from minimal symptoms (with up to 75 % of cases presenting as missed abortion before the 12th week of gestation) to an acute abdomen posing a life-threatening condition. Diagnosis is primarily based on transvaginal and abdominal ultrasonography, which represents the key modality for early detection of the condition, while accurate interpretation of imaging findings is crucial for subsequent management.

Methods

Therapeutic options include both surgical treatment and conservative pharmacological management using methotrexate (administered systemically or locally) in early-diagnosed and hemodynamically stable patients. Surgical management mainly involves laparoscopic procedures, such as cornuostomy or resection of the uterine horn, often combined with ipsilateral salpingectomy, while laparotomy may be required in advanced or complicated cases.

Results

The aim of this presentation is to summarize current knowledge regarding the diagnostics and treatment of cornual pregnancy and to supplement it with case reports of patients managed by surgical resection of the uterine horn followed by long-term outpatient follow-up, including perioperative and ultrasound documentation.

Conclusions

Cornual pregnancy represents a serious clinical entity associated with a high risk of complications, in which early diagnosis and correct interpretation of ultrasound findings play a crucial role. The therapeutic approach should be individualized and may include both conservative and surgical options, while the presented case reports illustrate situations requiring surgical management. From a reproductive perspective, subsequent pregnancies are associated with an increased risk of uterine rupture; therefore, delivery by caesarean section is recommended.

ESGE35-0606 - P110
ePoster Presentations

When Endometriosis Breathes: Combined Single-Port Robotic and Bilateral VATS Surgery for Recurrent Thoracic Endometriosis

Saima Farooq[1], *Amer Raza*[1]
[1]*Cromwell Hospital, Gynaecology, LONDON, United Kingdom*

Background

Thoracic endometriosis is a rare and complex manifestation of extra pelvic endometriosis that may present with cyclical chest pain, diaphragmatic symptoms, breathlessness, and recurrent thoracic disease. Surgical management becomes increasingly challenging in recurrent cases following previous thoracic intervention. We present a multidisciplinary approach combining single-port robotic pelvic excision with bilateral video-assisted thoracoscopic surgery (VATS) in a single operative setting.

Methods

CaseA 42-year-old woman presented with severe recurrent pelvic, diaphragmatic, thoracic, and upper abdominal pain associated with cyclical respiratory symptoms despite multiple previous surgeries, including prior thoracic procedures for thoracic endometriosis. Imaging and clinical assessment suggested recurrent multicompartment disease with associated adenomyosis. Surgical Technique A combined operation was undertaken involving gynaecological and thoracic surgical teams. Single-port robotic surgery was performed via a trans umbilical approach. Extensive pelvic peritoneal inflammation, scarring, uterosacral disease, rectovaginal involvement, and pararectal fibrosis were excised using bilateral ureterolysis and nerve-sparing dissection techniques. Subtotal hysterectomy with bilateral salpingectomy was completed while preserving the ovaries. Simultaneously, bilateral VATS demonstrated thoracic adhesions and suspicious diaphragmatic and pulmonary lesions requiring thoracic excision and partial lobectomy. Thorough inspection of the diaphragm, pleura, and lung parenchyma was performed.

Results

Complete multidisciplinary excision was achieved successfully without conversion to open surgery or intraoperative complications. The patient demonstrated satisfactory postoperative recovery with improvement in symptoms.

Conclusions

Combined single-port robotic pelvic surgery with bilateral thoracoscopic excision represents a feasible and effective strategy for recurrent thoracic endometriosis, enabling comprehensive management of multicompartment disease within a single operative session.

ESGE35-0621 - P111
ePoster Presentations

Robotic-Assisted Versus Conventional Laparoscopic Myomectomy: Perioperative Outcomes From a Tertiary Hospital.

Andrea Sánchez Iglesias[1], *Sonia Monreal Clua*[1], *Laura Mañalich Barrachina*[1], *Elena Suarez Salvador*[1]
[1]*Hospital Universitari Vall d'Hebron, Obstetrics and Gynaecology, Barcelona, Spain*

Background

To compare intraoperative blood loss between conventional laparoscopic and robotic-assisted (Da Vinci) myomectomy and to evaluate factors associated with surgical approach selection.

Methods

A retrospective comparative study was conducted including patients undergoing laparoscopic or robotic myomectomy. Baseline clinical and surgical variables were analysed, including body mass index (BMI), dominant fibroid size, number of fibroids, operative time, and estimated blood loss (EBL). Continuous variables were compared using Student's t-test or Mann–Whitney U test according to data distribution. A multivariable linear regression model was performed to identify independent predictors of intraoperative blood loss, adjusting for fibroid size, number of fibroids, and operative time. Fibroid size was additionally categorized (<6 cm, 6–8 cm, >8 cm) to evaluate its association with surgical approach.

Results

A total of 158 patients were included, comprising 89 laparoscopic and 69 robotic myomectomies. No significant differences were observed between groups regarding BMI, dominant fibroid size, number of fibroids, or unadjusted estimated blood loss. Median EBL was 250 ml in both groups (p=0.576). Operative time was significantly longer in the robotic group (p<0.001).

On multivariable analysis, robotic-assisted surgery was independently associated with lower intraoperative blood loss (β−117 ml; p=0.043), after adjustment for fibroid size, number of fibroids, and operative time. Larger fibroid size and longer operative time were independently associated with increased blood loss (p<0.001 for both). No significant association was found between categorized fibroid size and the selection of robotic surgery (p=0.39).

Conclusions

Robotic-assisted myomectomy was associated with reduced intraoperative blood loss after adjustment for surgical complexity factors, despite longer operative times. Fibroid size alone did not significantly influence the selection of robotic versus conventional laparoscopic approach.

ESGE35-0669 - P114
ePoster Presentations

Robotic-assisted laparoscopy vs conventional laparoscopy for the treatment of deep infiltrating endometriosis

Nicole Macečková[1], *Martin Trhlík*[1], *Ondřej Novák*[1], *Jiří Bartoš*[2]
[1]*AGEL Hospital Nový Jičín a.s., Gynecological and obstetrics department, Nový Jičín, Czech Republic*
[2]*AGEL Hospital Nový Jičín a.s., Surgical department, Nový Jičín, Czech Republic*

Background

The aim of the study was to compare the newly introduced robotic treatment of DIE, including procedures on the intestine, with commonly performed laparoscopic procedures.

Methods

In this retrospective study, we included a total of 60 patients aged 20-45 years who underwent surgery at our institution in 2024-2026, the inclusion condition was zero postoperative residue. In our group, there were 30 patients operated laparoscopically, of which 20 were without bowel intervention (group 1) and 10 with bowel intervention – i.e. with segmental or discoid resection of the rectum or sigmoid (group 3). We compared these patients with 30 operated robotically, of which 20 were again without bowel intervention (group 2) and 10 with bowel intervention (group 4). We compared the duration of the surgical procedure, blood loss and length of hospitalization. Furthermore, we monitored the number of conversions to laparotomy and revision, complications within 24 hours and within 7 days and the number of rehospitalizations in these patients. For comparison, we used a two-sample t-test with equal variances, all hypothesis testing was conducted at the 5% level of significance.

Results

The duration of laparoscopic operations ranged from 39 to 250 min, with a mean of 117 min, and for robotic operations, the duration ranged from 35 to 450 min, with a mean of 130 min. The difference in the averages is not statistically significant in this case. Blood loss was on average 58 ml for laparoscopic operations, and only 33 ml for robotic operations. Again, the difference in average losses is not statistically significant. The length of hospitalization in our institution is standardized according to the type of procedure, and was therefore the same on average for both laparoscopic and robotic approaches, namely 8 days. Rehospitalization was not necessary even once. Conversion to laparotomy was performed three times – always with the laparoscopic approach. We did not record any surgical revision or complication within 24 hours. Of the complications within 7 days, we only addressed transient bladder hypotonia and one bladder infection in 2 laparoscopic patients, and in 1 robotic patient we noted transient numbness of the left thigh and left labia. There were no intestinal complications.

Conclusions

Our study therefore shows that the introduction of robotic DIE surgery at our institution was without complications and the quality of laparoscopic and robotic DIE treatment is comparable.

ESGE35-0675 - P115
ePoster Presentations

Premenarchal Isolated Fallopian Tube Torsion

Nehal Shah[1], Shereen Ibrahim[2]
[1]Lister Hospital, Obstetrics and Gynaecology, Stevenage- Hertfordshire, United Kingdom
[2]Lister Hospital, Obstetrics and Gynaecology, Stevenage- Hertfordshire, United Kingdom

Background

We present a case of isolated torsion of the fallopian tube (IFTT) in an 11-year-old premenarchal girl diagnosed incidentally during laparoscopy performed for suspected appendicitis.

IFTT is an exceptionally rare cause of acute abdominal pain in paediatric and adolescent females. Due to its nonspecific clinical presentation, it is frequently misdiagnosed as more common surgical conditions, such as acute appendicitis, resulting in delayed diagnosis and potential loss of tubal viability with implications for future fertility. The case highlighted the diagnostic challenge and importance of early surgical intervention to preserve reproductive potential.

Methods

An 11-year-old girl presented with a history of abdominal pain initially localised to the epigastrium, migrating to the periumbilical region and the right iliac fossa. Associated symptoms included vomiting and low-grade fever. On examination, she was mildly tachycardic but haemodynamically stable. Abdominal examination demonstrated right iliac fossa tenderness with rebound tenderness. Investigations revealed raised inflammatory markers, and a provisional diagnosis of acute appendicitis was made.

Following informed consent, the patient underwent diagnostic laparoscopy under the care of the general surgeons. Intra-operatively, 50mL of haemoperitoneum was identified along with bluish discolouration of the right fallopian tube. The appendix and both ovaries appeared normal.

An urgent intra-operative gynaecology consultation was obtained, a diagnosis of IFTT was established, and a multidisciplinary discussion was undertaken regarding optimal management.

Results

After multidisciplinary discussion between the general surgical, gynaecology and anaesthetic team, laparoscopic detorsion of the left fallopian tube was performed with the aim of preserving tubal function and future fertility. The tube was found to be twisted three times around its pedicle. Following detorsion, the colour improved from bluish-purple to pink, indicating restoration of vascular perfusion. Salpingectomy was therefore avoided. Appendicectomy was not performed.

Postoperatively, the patient recovered well clinically with down trending of inflammatory markers and resolution of abdominal pain. The patient and her mother received detailed counselling regarding the operative findings and the rationale for conservative fertility-preserving management. They were also informed about the potential risks of recurrent torsion, irreversible ischaemia, infection, and the

possible future need for repeat laparoscopy or salpingectomy if symptoms recurred or vascular compromise developed.

The patient was referred to a tertiary paediatric and adolescent gynaecology service for specialist follow-up, including consideration of interval imaging, second look laparoscopy if clinically indicated, and long-term fertility counselling.

Conclusions

This case highlights the diagnostic difficulty of IFTT in a premenarchal girl and reinforces the importance of including gynaecological pathology in the differential diagnosis of acute abdomen in paediatric patients. Early surgical exploration and prompt multidisciplinary collaboration are crucial to maximise the likelihood of tubal preservation and future fertility. Conservative laparoscopic detorsion should be considered whenever tubal viability appears salvageable.

ESGE35-0676 - P116
ePoster Presentations

Real World Comparison of Vaginoscopy and Modified Traditional Hysteroscopy: Women's Experiences, Pain, and Satisfaction in an Outpatient Setting

Laxmi Saha[1], *Ruvana Tabassum*[2]
[1]*George Eliot Hospital, Obstetrics and Gynaecology, Nuneaton and Bedworth, United Kingdom*
[2]*George Eliot Hospital, Obstetrics and Gynaecology, Nuneaton, United Kingdom*

Background

Outpatient hysteroscopy (OPH) is performed using either vaginoscopy, where the hysteroscope is introduced directly without a speculum, or a modified traditional technique using speculum-assisted cervical visualisation without grasping the cervix. This study compared clinical effectiveness—procedure time and failure rate—and women's experiences, including pain, emotional responses, and satisfaction, between these two real-world OPH methods.

Methods

A prospective comparative audit was conducted at George Eliot Hospital over June and July 2025. Fifty-one women scheduled for outpatient hysteroscopy were recruited; three were excluded due to incomplete data. Twenty-seven women underwent vaginoscopy and twenty-one the modified traditional approach. A structured post-procedure questionnaire captured clinical indication, procedure duration, pain score (VAS 0–10), emotional state during the procedure, and overall satisfaction. All data were anonymised and analysed descriptively. Audit standards included ≥95% provision of written pre-appointment information and a mean intra-procedural pain score <5.2.

Results

Among the 48 analysed participants, 53% underwent vaginoscopy. The mean age was 57.3 years, with 51% of women aged 50–59. Postmenopausal bleeding was the most common indication (65%), followed by heavy menstrual bleeding (15%). Pre-procedural information was received by 86% of women, and 76% took the recommended analgesia; two participants reported not receiving any information.

Procedure failure rates were similar between the two groups, with 18.5% in the vaginoscopy group and 19% in the modified traditional group. The mean procedure duration was 12.9 minutes for vaginoscopy and 10.4 minutes for the traditional approach.

Pain scores were ≤5 in twenty-two women (43%). A higher proportion of women in the vaginoscopy group reported severe pain (≥8/10). Entonox was required in 11.7% of cases (five in the vaginoscopy group and one in the traditional group). Anxiety was common in both groups (33.3% vs. 28.6%), and one vasovagal episode occurred in the vaginoscopy cohort.

Overall service satisfaction was high: 78% rated the waiting area as excellent, and 84% rated the overall care as excellent. Sixty-one percent strongly agreed that they would choose treatment at the trust again.

Conclusions

Vaginoscopy remains the evidence-based preferred technique for outpatient hysteroscopy in line with national guidance, including RCOG Green-top Guideline No. 59. However, in real-world practice—where training time and opportunities to develop vaginoscopy competency may be limited—the modified traditional approach demonstrated non-inferior tolerability and effectiveness. It was also associated with slightly shorter procedure times and reduced need for intra-procedural analgesia.

While vaginoscopy should remain the long-term standard, this audit suggests that during the learning curve clinicians may safely use speculum-assisted cervical visualisation without grasping the cervix as an acceptable interim technique. To support full adherence to national guidelines, service improvements should prioritise structured training programmes, access to smaller-diameter hysteroscopes, universal provision of high-quality patient information, and tailored analgesia and anxiety-reduction strategies to optimise patient experience and procedural success.

ESGE35-0691 - P120
ePoster Presentations

Co-occurrence of endometriosis and adenomyosis with gynaecological and non-gynaecological malignancies: a single-centre retrospective cohort.

Zofia Borowiec[1], Ewa Milnerowicz-Nabzdyk[1], Mariusz Kasperski[1], Krzysztof Nowak[1]
[1]Opole Oncology Center- Faculty of Medicine- University of Opole,
Department of Oncological Gynaecology, Opole, Poland

Background

Endometriosis and adenomyosis are increasingly recognised as conditions that may co-exist and possibly contribute to malignant transformation, most consistently in endometrioid and clear-cell ovarian and endometrial carcinomas. However, the full clinico-pathological spectrum of cancers occurring in women with histologically confirmed endometriosis, with or without coexisting adenomyosis, remains poorly characterised. We aimed to describe the distribution of malignancies and pre-invasive lesions across organ sites, histological subtypes and endometriosis locations in a single-centre cohort, and to compare profiles between women with endometriosis only (ENDO_only) and those with concomitant adenomyosis (ENDO+ADENO).

Methods

We conducted a retrospective single-centre review of histopathology records from the Department of Oncological Gynaecology, Opole Oncology Center (Poland), 2014–2025. The denominator comprised 7,873 women admitted to the department during the study period. All women with histologically confirmed endometriosis and a concurrent or subsequent diagnosis of malignancy or pre-invasive lesion were included. Cases were classified at patient level following deduplication by patient identifier. Endometriosis–adenomyosis status was assigned per the Mezzapesa 2025 / Beck 2026 framework. Cancer location was categorised as gynaecological (GYNE — single-organ or multifocal), non-gynaecological (NON-GYNE), or pre-invasive (CIN/HSIL/AIS). Endometriosis lesion sites were recorded using a standardised 12-site grid. The study was approved by the local ethics committee.

Results

Sixty-seven women met inclusion criteria (78 histopathology reports), yielding a crude prevalence of co-occurrence of 0.85% (67/7,873). Forty-seven (70.1%) had endometriosis without adenomyosis and 20 (29.9%) had concomitant adenomyosis. The dominant cancer site was the endometrial corpus, accounting for 29/67 cases (43.3%), with a notably higher proportion in ENDO+ADENO than in ENDO_only (12/20 [60.0%] vs 17/47 [36.2%]). Multifocal gynaecological cancers were observed in 14/67 (20.9%), most frequently cervix+endometrium (n=4) and endometrium+ovary (n=3). Ovarian malignancies (including two borderline tumours and one tubal STIC) occurred in 7/67 (10.4%), cervical cancers in 3/67 (4.5%), and isolated tubal disease in 1/67 (1.5%). Non-gynaecological malignancies represented 10/67 (14.9%), led by breast carcinoma (n=5) and gastrointestinal/appendiceal neoplasms (n=2, including a LAMN/pseudomyxoma peritonei). Pre-invasive cervical lesions accounted for 2/67 (3.0%). Endometrioid was the predominant histology (30/78 reports), followed by serous (n=7), adenocarcinoma (n=3), clear-cell (n=2), squamous (n=2)

and leiomyosarcoma (n=2). Beyond adenomyosis, the most frequent endometriosis sites were ovarian endometrioma (11/67), fallopian tube (7/67) and bowel/rectum (7/67).

Conclusions

In this single-centre cohort, women with histologically confirmed endometriosis and a co-occurring neoplasm displayed a broad clinico-pathological spectrum extending well beyond the classicalendometrioid–clear-cell ovarian association. Endometrial cancer was the most common malignancy, particularly with concomitant adenomyosis; breast cancer accounted for 7.5%. These findings argue for an integrated diagnostic pathway in endometriosis surgery, with systematic endometrial assessment and awareness of multifocal and extra-gynaecological disease. This systematic histopathological reappraisal suggests that co-occurrence of endometriosis with malignancy may be more frequent than previously reported in registry-based cohorts.

ESGE35-0697 - P121
ePoster Presentations

Laparoscopic repair of severe caesarean scar defects with residual myometrium below three millimetres: a single-surgeon consecutive series from a tertiary endometriosis and reproductive surgery centre

Jan Humplík[1], *Lukáš Prajka*[1], *Jiří Presl*[1]
[1]*University hospital in Pilsen, Department of Gynaecology & Obstetrics, Pilsen, Czech Republic*

Background

Caesarean scar defect (isthmocele) can cause abnormal uterine bleeding (AUB), chronic pelvic pain, secondary infertility, caesarean scar pregnancy and obstetric complications. Current literature recommends laparoscopic repair for severe defects with a residual myometrial thickness (RMT) below 2.5–3 mm. We report anatomical and safety outcomes of laparoscopic isthmocele repair in consecutive patients with severe defects treated at a tertiary referral centre.

Methods

Retrospective analysis of consecutive patients undergoing laparoscopic isthmocele repair between November 2022 and April 2026 at a tertiary endometriosis and reproductive surgery centre. Inclusion criteria: preoperative RMT below 3 mm on transvaginal ultrasound (TVUS), either symptomatic disease or desire for future fertility with severe defect. All procedures were performed by a single surgeon. Operative steps included bladder dissection, defect identification (with intraoperative hysteroscopic transillumination when indicated), excision of fibrotic scar tissue and two-layer uterine closure. Concomitant pelvic pathology (adhesions, endometriosis) was addressed in the same procedure when present. The primary outcome was change in RMT measured by TVUS at 6–12 weeks postoperatively. Secondary outcomes included operative time, blood loss, intraoperative and postoperative complications, conversion rate, hospital stay, symptom resolution and reproductive outcomes. Wilcoxon signed-rank test for paired comparisons.

Results

Twenty-two patients were included. Mean age was 34.9 ± 4.1 years and mean body mass index 24.8 ± 4.7 kg/m². Previous caesarean sections: one (77%), two (18%), three (5%). Preoperative symptoms were AUB in 50%, chronic pelvic pain in 18%, secondary infertility in 9% and caesarean scar pregnancy in 5%; 77% expressed desire for future fertility. Concomitant procedures: adhesiolysis (41%) and endometriosis treatment (23%). Mean operative time was 62.9 ± 16.6 minutes (range 38–100) and mean blood loss 42.7 ± 30.7 mL. RMT increased from a mean of 1.35 ± 0.67 mm (range 0–2.5; all patients below 3 mm) preoperatively to 6.14 ± 1.28 mm (range 4–8) at 6–12 weeks, a mean increase of 4.78 mm (95% CI 4.21–5.35; $p<0.001$). No intraoperative complications occurred and no procedure was converted to laparotomy. One patient (4.5%) developed postoperative endometritis managed conservatively. Mean hospital stay was 3.2 days. At follow-up, all patients with preoperative AUB (n=11) and chronic pelvic pain (n=4) reported complete symptom resolution. Among women with available postoperative reproductive data, spontaneous conception with live birth was documented, while two patients experienced recurrent pregnancy loss.

Conclusions

In a strictly defined cohort of severe caesarean scar defects (RMT below 3 mm), single surgeon laparoscopic repair restored mean RMT from 1.35 to 6.14 mm and achieved complete resolution of preoperative AUB and pelvic pain, without intraoperative complications or conversions. Coexisting pelvic pathology in nearly half of patients supports a comprehensive single-stage laparoscopic approach in tertiary reproductive surgery centres. Reproductive outcomes remain preliminary and require longer follow-up.

ESGE35-0707 - P122
ePoster Presentations

Giant Infected Endometrioma: A Diagnostic Pitfall Mimicking Tubo-Ovarian Abscess: A Case Report.

Yasmine Chiba[1], Hadfi Safa[1], Hfaiedh Ines[1], Nouiji Sabrine[1], Jaafar Wissal[1], Mourali Mechaal[1]
[1]Habib Bougatfa University Hospital in Bizerte, Department of Obstetrics and Gynaecology, Bizerte, Tunisia

Background

Infected endometrioma is a rare but serious complication of ovarian endometriosis, whose polymorphic presentation frequently mimics tubo-ovarian abscess or acute digestive pathology, making preoperative diagnosis particularly challenging. Pelvic magnetic resonance imaging (MRI) remains the gold standard for lesion characterization, providing precise delineation of cystic content and differential diagnosis.

Methods

We report the case of a 34-year-old nulliparous woman with an unremarkable medical history who presented with acute febrile pelvic pain and remained hemodynamically stable. Pelvic ultrasound revealed a left adnexal mass measuring 88 × 79 mm, characterized by homogeneous echogenic content, thickened walls, and sparse incomplete septa, findings that precluded reliable sonographic differentiation between an infected endometrioma and a tubo-ovarian abscess. Pelvic MRI confirmed the diagnosis, demonstrating a giant ovarian lesion measuring 97 × 75 × 101 mm, without associated deep endometriosis. Furthermore, laboratory workup revealed markedly elevated inflammatory markers, consistent with an infectious process. Notably, anti-Müllerian hormone (AMH) level was significantly diminished at 0.34 ng/mL, reflecting an already compromised ovarian reserve. In this context, surgical intervention was deliberately deferred as a first-line approach, given the substantial risk of further iatrogenic impairment of the residual ovarian reserve and the imperative to preserve fertility potential in this patient. Intravenous triple-agent antibiotic therapy combining cefotaxime, metronidazole, and gentamicin was initiated with close clinico-biological monitoring.

Results

The patient was hospitalized for eight days, during which a favourable clinical course was observed under combined antibiotic therapy. Apyrexia was achieved within 48 hours of treatment initiation, accompanied by progressive resolution of pelvic pain and a significant decline in inflammatory biomarkers, including normalization of C-reactive protein and white blood cell count. Serial clinical and biological monitoring confirmed sustained improvement throughout the admission, supporting the decision to pursue exclusive conservative management without surgical intervention.

Conclusions

Ovarian endometrioma complicated by infection represents a rare clinical entity, notorious for mimicking tubo-ovarian abscess and constituting a genuine diagnostic pitfall. This case underscores the pivotal role of MRI in establishing the correct diagnosis and demonstrates the feasibility of

exclusive medical management in hemodynamically stable patients, thereby avoiding emergency surgical intervention and preserving reproductive potential.

ESGE35-0734 - P124
ePoster Presentations

Transvaginal Natural Orifice Endoscopic Bilateral Tubal Ligation in a Patient with Previous Caesarean Sections: A Minimally Invasive Approach for Permanent Contraception

Yavuz Yilmaz[1], Ömer Faruk Öz[1], Selen Doğan[2], Nasuh Utku Doğan[1], Murat Özekinci[3], İnanç Mendilcioğlu[4]
[1]Akdeniz University, Obstetrics and Gynaecology- TR-MIGS, Antalya, Türkiye
[2]Akdeniz University, Gynecologic Oncology- Obstetrics and Gynaecology- TR-MIGS, Antalya, Türkiye
[3]Akdeniz University, Reproductive Endocrinology and Infertility- Obstetrics and Gynaecology- TR-MIGS, Antalya, Türkiye
[4]Akdeniz University, Maternal-Foetal Medicine- Obstetrics and Gynaecology- TR-MIGS, Antalya, Türkiye

Background

To present the feasibility and surgical outcomes of transvaginal natural orifice transluminal endoscopic surgery (vNOTES) bilateral tubal ligation (BTL) performed for permanent contraception in a patient with previous caesarean deliveries and menorrhagia.

Methods

A 42-year-old G3P2A1 woman with a history of two previous caesarean sections requested permanent contraception. The patient also reported menorrhagia and had an intrauterine device in situ. Preoperative gynecologic evaluation demonstrated normal adnexal structures and no sonographic evidence of pelvic pathology. Cervical smear results were negative for intraepithelial lesion or malignancy.

A vNOTES approach was selected to provide minimally invasive bilateral tubal ligation while avoiding additional abdominal scars. Following transvaginal access to the peritoneal cavity, endoscopic visualization of the pelvic anatomy was achieved and bilateral tubal occlusion was completed successfully. Intraoperative and postoperative findings were evaluated.

Results

The procedure was completed successfully without conversion to conventional laparoscopy or laparotomy. Adequate visualization of the pelvic cavity and adnexal structures was achieved despite the history of previous caesarean sections. No intraoperative complications, including bleeding, bowel injury, bladder injury, or anaesthetic complications, were observed. Postoperative recovery was uneventful, and the patient was discharged in stable condition.

Conclusions

vNOTES bilateral tubal ligation appears to be a safe and feasible minimally invasive alternative for permanent contraception in appropriately selected patients, including those with previous caeserean deliveries. The technique offers scarless surgery, satisfactory pelvic visualization, and rapid postoperative recovery. Wider experience and further comparative studies are needed to better define the role of vNOTES in routine contraceptive surgery.

ESGE35-0737 - P125
ePoster Presentations

Total Laparoscopic Hysterectomy Without Uterine Manipulator in a Patient With Previous HSIL and LEEP History: A Challenging Minimally Invasive Surgical Approach

Yavuz Yilmaz[1], Can Dinç[1], Selen Doğan[2], Nasuh Utku Doğan[1], Murat Özekinci[3], İnanç Mendilcioğlu[4]
[1]Akdeniz University, Obstetrics and Gynaecology- TR-MIGS, Antalya, Türkiye
[2]Akdeniz University, Gynecologic Oncology- Obstetrics and Gynaecology- TR-MIGS, Antalya, Türkiye
[3]Akdeniz University, Reproductive Endocrinology and Infertility- Obstetrics and Gynaecology- TR-MIGS, Antalya, Türkiye
[4]Akdeniz University, Maternal-Foetal Medicine- Obstetrics and Gynaecology- TR-MIGS, Antalya, Türkiye

Background

To present the surgical management of a challenging total laparoscopic hysterectomy (TLH) with bilateral salpingectomy (BS) performed without a uterine manipulator in a patient with previous HSIL and LEEP history causing cervical distortion and obscured cervical anatomy.

Methods

A 56-year-old postmenopausal G3P2A1 patient presented with postmenopausal bleeding and symptomatic uterine myomas. The patient had a history of HPV positivity, HSIL/CIN3 diagnosed after LEEP procedure, and significant cervical tissue alteration secondary to previous excisional treatment. Due to cervical stenosis and inability to clearly identify the external cervical os, insertion of a uterine manipulator was not feasible.

A total laparoscopic hysterectomy with bilateral salpingectomy was planned. Vaginal tampon guidance was used intraoperatively to help identify tissue planes and define the vaginal cuff borders. Special attention was paid to retroperitoneal anatomy and ureteral course throughout the procedure. Bilateral ureters were identified and inspected both before and after hysterectomy. Careful dissection was performed to ensure complete cervical tissue excision despite distorted anatomy related to previous LEEP.

Results

The procedure was completed laparoscopically without conversion to laparotomy. Adequate identification of anatomical landmarks was achieved despite the absence of a uterine manipulator and altered cervical anatomy. Ureteral integrity was preserved bilaterally, and no intraoperative complications occurred. Final surgical inspection confirmed complete removal of cervical tissue. The postoperative course was uneventful.

Conclusions

TLH without a uterine manipulator can be safely performed in selected patients with previous HSIL and LEEP history when meticulous anatomical dissection and continuous ureteral evaluation are applied. Vaginal tampon guidance may facilitate identification of surgical planes in cases with

distorted cervical anatomy. This approach represents a feasible minimally invasive alternative in technically challenging hysterectomy cases.

ESGE35-0740 - P126
ePoster Presentations

Laparoscopic Management of Ruptured Ovarian Endometrioma With Ovarian Reserve Preservation in a Young Patient

Yavuz Yilmaz[1], Can Dinç[1], Selen Doğan[2], Nasuh Utku Doğan[1], Murat Özekinci[3], İnanç Mendilcioğlu[4]
[1]Akdeniz University, Obstetrics and Gynaecology- TR-MIGS, Antalya, Türkiye
[2]Akdeniz University, Gynecologic Oncology- Obstetrics and Gynaecology- TR-MIGS, Antalya, Türkiye
[3]Akdeniz University, Reproductive Endocrinology and Infertility- Obstetrics and Gynaecology- TR-MIGS, Antalya, Türkiye
[4]Akdeniz University, Maternal-Foetal Medicine- Obstetrics and Gynaecology- TR-MIGS, Antalya, Türkiye

Background

To present the laparoscopic management of ruptured ovarian endometrioma in a young patient with emphasis on ovarian reserve preservation and minimization of thermal ovarian damage.

Methods

A 24-year-old nulligravid virgin patient presented with sudden-onset severe abdominal pain. The patient had a previous surgical history of ruptured ovarian endometrioma in 2021. Imaging demonstrated a complex right adnexal cystic lesion associated with free intraperitoneal fluid, raising suspicion for endometrioma rupture.

Due to possible pelvic adhesions related to previous surgery and endometriosis, abdominal access was obtained using the open Hasson technique. Diagnostic laparoscopy revealed ruptured ovarian endometrioma with diffuse endometriotic fluid within the pelvic cavity. Careful aspiration of cyst contents was performed followed by extensive irrigation using saline solution.

The endometrioma cyst wall was meticulously dissected and excised using an endoscopic retrieval bag. Particular attention was paid to preservation of ovarian reserve. Bipolar energy use was minimized, thermal injury was avoided whenever possible, and dissection near the ovarian hilum was performed carefully. Ovarian reconstruction was completed using Vicryl sutures to reduce tissue loss and potential follicular atresia. Hemostasis was confirmed and a pelvic drain was placed.

Results

The procedure was completed laparoscopically without intraoperative complications or conversion to laparotomy. Adequate removal of cyst tissue and endometriotic contents was achieved while preserving healthy ovarian tissue. Hemostasis was successfully maintained with minimal use of electrosurgery. The postoperative course was uneventful.

Conclusions

Laparoscopic management of ruptured endometrioma should prioritize ovarian reserve preservation, particularly in young patients. Careful cyst excision, minimal thermal energy application, protection of

the ovarian hilum, and ovarian reconstruction may help reduce ovarian damage while maintaining effective surgical treatment.

ESGE35-0741 - P127
ePoster Presentations

Combined Total Laparoscopic Hysterectomy, Bilateral Salpingo-Oophorectomy, and Tension-Free Vaginal Tape Procedure With Routine Cystoscopic and Laparoscopic Urinary Tract Assessment

Ömer Faruk Öz[1], Can Dinç[1], Selen Doğan[2], Nasuh Utku Doğan[1], Murat Özekinci[3], İbrahim İnanç Mendilcioğlu[4]
[1]Akdeniz University, Obstetrics and Gynaecology- TR-MIGS, Antalya, Türkiye
[2]Akdeniz University, Gynecologic Oncology- Obstetrics and Gynaecology- TR-MIGS, Antalya, Türkiye
[3]Akdeniz University, Reproductive Endocrinology and Infertility- Obstetrics and Gynaecology- TR-MIGS, Antalya, Türkiye
[4]Akdeniz University, Maternal-Foetal Medicine- Obstetrics and Gynaecology- TR-MIGS, Antalya, Türkiye

Background

To present the surgical management of pelvic organ prolapse and mixed urinary incontinence using combined total laparoscopic hysterectomy (TLH), bilateral salpingo-oophorectomy (BSO), and tension-free vaginal tape (TVT) procedure with routine intraoperative urinary tract evaluation.

Methods

A 66-year-old multiparous postmenopausal patient presented with vaginal bulging sensation and mixed urinary incontinence. Pelvic examination demonstrated grade 3 cystocele and stress urinary incontinence confirmed by Q-tip and stress testing.

A combined minimally invasive surgical approach including TLH, BSO, and TVT procedure was planned. Following completion of laparoscopic hysterectomy and adnexal surgery, tension-free vaginal tape placement was performed for anti-incontinence treatment.

Routine intraoperative cystoscopy was subsequently carried out to evaluate bladder integrity and exclude lower urinary tract injury after TVT placement. Simultaneously, laparoscopic pelvic inspection was used to assess the anatomical relationship of the tape and surrounding pelvic structures. Bladder integrity and bilateral ureteral pathways were carefully evaluated throughout the procedure.

Results

The procedure was completed successfully without conversion to laparotomy. Cystoscopic examination confirmed intact bladder mucosa and absence of tape-related or trocar-related bladder injury. Laparoscopic visualization additionally demonstrated safe TVT positioning and preserved pelvic anatomy. No intraoperative urinary tract complications occurred. The postoperative course was uneventful.

Conclusions

Combined TLH, BSO, and TVT surgery represents a feasible minimally invasive approach for patients with concomitant pelvic organ prolapse and urinary incontinence. Routine cystoscopic and

laparoscopic assessment following TVT placement may improve surgical safety through immediate recognition and exclusion of urinary tract injury.

ESGE35-0742 - P128
ePoster Presentations

Emergency Laparoscopic Detorsion and Ovarian Reserve-Preserving Management of Ovarian Torsion Associated With Ruptured Hemorrhagic Cyst

Yavuz Yilmaz[1], Can Dinç[1], Selen Doğan[2], Nasuh Utku Doğan[1], Murat Özekinci[3], İbrahim İnanç Mendilcioğlu[4]
[1]Akdeniz University, Obstetrics and Gynaecology- TR-MIGS, Antalya, Türkiye
[2]Akdeniz University, Gynecologic Oncology- Obstetrics and Gynaecology- TR-MIGS, Antalya, Türkiye
[3]Akdeniz University, Reproductive Endocrinology and Infertility- Obstetrics and Gynaecology- TR-MIGS, Antalya, Türkiye
[4]Akdeniz University, Maternal-Foetal Medicine- Obstetrics and Gynaecology- TR-MIGS, Antalya, Türkiye

Background

To present the laparoscopic management of ovarian torsion associated with ruptured hemorrhagic ovarian cyst in a young patient, emphasizing ovarian reserve preservation and minimization of thermal ovarian injury.

Methods

A 34-year-old woman presented with acute pelvic pain and signs of acute abdomen. Imaging demonstrated a right adnexal cystic lesion approximately 6 cm in diameter suspicious for hemorrhagic cyst and possible ovarian torsion. Emergency diagnostic laparoscopy was performed.

Intraoperative evaluation confirmed right ovarian torsion associated with ruptured hemorrhagic ovarian cyst. Initial detorsion of the adnexa was carefully completed to restore ovarian perfusion. Following detorsion, cyst aspiration was performed and the cyst wall was meticulously dissected and removed.

Particular attention was paid to preservation of healthy ovarian tissue and ovarian reserve. Thermal energy use was minimized whenever possible, and careful dissection near the ovarian hilum was maintained during cyst wall stripping. Hemostasis was achieved with minimal bipolar coagulation. Ovarian reconstruction was subsequently performed using suturing techniques to reduce tissue loss and potential follicular atresia.

Results

The procedure was completed laparoscopically without conversion to laparotomy. Ovarian anatomy and vascularization were preserved following detorsion. Complete cyst excision was achieved while maintaining maximal healthy ovarian tissue. No intraoperative complications occurred, and the postoperative course was uneventful.

Conclusions

Emergency laparoscopic management of ovarian torsion should prioritize preservation of ovarian function, particularly in reproductive-age patients. Early detorsion combined with careful cystectomy,

minimal thermal energy application, protection of the ovarian hilum, and ovarian reconstruction may help optimize preservation of ovarian reserve while providing effective surgical treatment.

ESGE35-0751 - P129
ePoster Presentations

Patient-Reported Satisfaction and Health-Related Quality of Life Following Office Hysteroscopy: A Cross-Sectional Study Using FIPS and SF-36

Paulina Pietrzyk[1], Jagoda Dradrach[1], Andrzej Zmaczyński[1], Robert Jach[1], Dominika Trojnarska[1]
[1]University Hospital in Kraków,
Clinical Department of Gynecological Endocrinology and Gynecological Oncology, Kraków, Poland

Background

Patient satisfaction and quality of life are important patient-reported outcomes following office hysteroscopy. This study aimed to evaluate patient satisfaction using the Freiburg Index of Patient Satisfaction (FIPS) and its association with health-related quality of life assessed using the Short Form Health Survey (SF-36) questionnaire.

Methods

A cross-sectional study was conducted among women undergoing office hysteroscopy to validate the FIPS questionnaire and to assess patient satisfaction with the procedure. Satisfaction was assessed using the Polish version of the FIPS questionnaire, while quality of life was evaluated using SF-36. Internal consistency was assessed using Cronbach's alpha coefficient, and correlations between questionnaires were analysed using Spearman's rank correlation coefficient.

Results

A total of 149 questionnaires were analysed. The mean age of participants was 42.3 ± 12.7 years. The FIPS questionnaire demonstrated acceptable internal consistency (Cronbach's $\alpha = 0.70$; standardized $\alpha = 0.77$). The mean FIPS score was 2.38 ± 0.86, indicating high patient satisfaction after office hysteroscopy. The mean SF-36 score was 70.21 ± 14.10. Correlation analysis demonstrated associations between patient satisfaction and selected SF-36 domains, suggesting that better quality of life was associated with higher satisfaction after the procedure.

Conclusions

Office hysteroscopy was associated with high patient satisfaction and favourable quality of life outcomes. The Polish version of the FIPS questionnaire appears to be a reliable tool for assessing patient satisfaction following office hysteroscopy.

ESGE35-0753 - P130
ePoster Presentations

Laparoscopic diagnosis of an ESHRE/ESGE U4a hemiuterus with rudimentary horn misinterpreted as a right adnexal mass on ultrasound and magnetic resonance imaging

Irena Aleksioska[1], Marija Joksimovic[2], Natasha Ilieva[3], Borivoje Pavlovski[1], Onur Dika[1], Drage Dabeski[1]
[1]University Clinic of Obstetric and Gynaecology, Urogynaecology, Skopje, Macedonia- Former Yugoslav Republic.
[2]University Clinic Of Obstetric and Gynaecology, Gynecologic oncology, Skopje, Macedonia- Former Yugoslav Republic.
[3]University Clinic of Obstetric and Gynaecology, Infertility, Skopje, Macedonia- Former Yugoslav Republic.

Background

Objectives: To present a case of an unrecognized Müllerian anomaly diagnosed during laparoscopic exploration for presumed ovarian neoplasm in an infertile patient, highlighting the diagnostic limitations and imaging pitfalls associated with rudimentary uterine horns.

Methods

Methods: 31-year-old nulliparous woman was referred for evaluation of primary infertility of one-year duration accompanied by progressive dysmenorrhea and intermittent right-sided pelvic pain. Transvaginal ultrasonography demonstrated a newly identified solid right adnexal lesion measuring 3 × 3.5 cm, with regular contours and heterogeneous echogenicity, apparently distinct from the uterus. No sonographic suspicion of congenital uterine anomaly was raised during the initial assessment. Pelvic magnetic resonance imaging demonstrated a well-circumscribed solid right adnexal lesion with imaging characteristics suggestive of a fibrous ovarian neoplasm, most likely ovarian fibroma/fibrothecoma. No definitive uterine malformation was identified on preoperative imaging. Given the indeterminate adnexal finding and the patient's infertility, diagnostic laparoscopy with possible surgical management was undertaken.

Results

Results: Laparoscopic examination unexpectedly revealed a unicornuate uterus with a right-sided rudimentary horn connected to the hemiuterus by a fibromuscular band, consistent with ESHRE/ESGE classification U4a. The presumed adnexal mass identified on ultrasound and magnetic resonance imaging corresponded to the rudimentary uterine horn rather than ovarian pathology. Both ovaries and fallopian tubes were macroscopically unremarkable. Intraoperative chromopertubation demonstrated unilateral tubal patency associated with the developed hemiuterus, while the contralateral rudimentary horn appeared noncommunicating. Retrospective review of the magnetic resonance imaging demonstrated subtle asymmetric uterine morphology that had initially been interpreted as adnexal pathology. The postoperative course was uneventful, and the patient was subsequently referred for reproductive counselling and fertility-oriented management.

Conclusions

Conclusions: Rudimentary uterine horns may represent a considerable diagnostic challenge and can occasionally mimic solid adnexal masses on both ultrasonography and magnetic resonance imaging, particularly in the absence of classical radiological features of Müllerian anomaly. This case emphasizes the importance of considering congenital uterine anomalies in the differential diagnosis of indeterminate adnexal lesions in infertile patients. Minimally invasive surgical exploration remains of substantial diagnostic value in cases with inconclusive or discordant imaging findings.

ESGE35-0768 - P132
ePoster Presentations

Laparoscopic surgical management of ureteric involvement in deep endometriosis: a single-centre experience.

Maja Mrugała[1], Dąbrowska Alicja[1], Krzysztof Nowak[1], Ewa Milnerowicz-Nabzdyk[1]
[1]University of Opole, Oncological Gynaecology Department and Reference Endometriosis Centre, Opole, Poland

Background

Deep endometriosis (DE) is a multifocal disease that can involve the peritoneum, uterosacral ligaments, vagina, bowel, bladder, and ureter, frequently with multi-compartment lesions in the same patient. Within this broad spectrum, ureteric involvement requires technically demanding laparoscopic procedures and multidisciplinary cooperation. The optimal surgical approach to the affected ureter — conservative ureterolysis and shaving versus radical resection with reimplantation — remains a subject of ongoing debate. We present a single-centre experience of laparoscopic surgery in an unselected consecutive cohort of patients operated for all forms of DE, focusing specifically on the subgroup with ureteric involvement and on the spectrum of ureter-directed techniques, perioperative parameters, and ureter-related complications.

Methods

We conducted a retrospective analysis of a prospectively maintained institutional database of consecutive patients undergoing laparoscopic surgery for DE between January 2020 and 2024 at a tertiary referral centre. The cohort included the full anatomical spectrum of DE: peritoneal, ovarian, utero-sacral / parametrial, vaginal, bladder, bowel, and ureteric disease — typically with multi-compartment involvement. Patients with ureteric involvement were identified through a dedicated ureter-focused sub-database. Data extracted for this subgroup included demographics (age, BMI), preoperative urinary symptoms (dysuria, pollakiuria, urgency, haematuria, incontinence), imaging findings (pelvicalyceal dilatation on ultrasound, indicative of ureteric obstruction), ureter-directed procedure type (ureterolysis, ureteric shaving, ureteric resection with primary uretero-ureteral anastomosis or ureteroneocystostomy with psoas hitch / Boari flap, nephrectomy in the setting of non-functioning kidney secondary to long-standing ureteric obstruction), DJ stent placement and laterality, side of ureteric involvement, concomitant bowel and bladder procedures, operative time, estimated blood loss, perioperative inflammatory markers (CRP, PCT), length of stay, and intra- and postoperative ureter-related complications.

Results

During the study period, 282 consecutive patients underwent laparoscopic surgery for the full spectrum of DE (peritoneal, ovarian, utero-sacral, vaginal, bladder, bowel, and ureteric disease). Within this overall DE cohort, ureteric involvement requiring active surgical intervention was identified in 56 patients (19.9%). The spectrum of ureter-directed procedures comprised ureteric shaving in 28 cases (50.0%), ureteric resection with primary repair or ureteroneocystostomy in 25 cases (44.6%), and nephrectomy for non-functioning kidney secondary to ureteric obstruction in 3

cases (5.4%). Reconstructive techniques used in selected complex cases included psoas hitch and Boari flap. Prophylactic DJ stenting was performed in 85 patients overall — unilateral in 43 (50.6%) and bilateral in 42 (49.4%). Concomitant bowel and bladder procedures were frequently required, reflecting multi-compartment disease.

Conclusions

Within a heterogeneous cohort of laparoscopically treated DE encompassing all anatomical forms of the disease, ureteric involvement was present in approximately one in five patients and required a wide spectrum of techniques, with ureteric shaving and ureteric resection-reimplantation each accounting for approximately half of interventions. A structured multidisciplinary protocol permits a fully laparoscopic approach even in complex reconstructions.

ESGE35-0775 - P134
ePoster Presentations

Effects of preventive measures on reducing the risk of urinary tract complications during multi-organ surgery in deep endometriosis.

Alicja Dąbrowska[1], Maja Mrugała[1], Marek Fiutowski[1], Aneta Machnicka-Rusek[1], Ewa Milnerowicz-Nabzdyk[1]
[1]Oncological Gynaecology Department- Reference Endometriosis Center- Opole University, Faculty of Medicine Head: Prof. Ewa Milnerowicz-Nabzdyk MDPhD, Opole, Poland

Background

Surgical treatment of deep endometriosis (DE) involving the urinary tract is one of the most challenging procedures in operative Gynaecology. Extensive ureteral dissection, bladder lesion resection, and simultaneous procedures on other pelvic organs increase the risk of severe urological complications. The aim of this study was to evaluate the impact of intraoperative preventive procedures on the incidence of urological complications during multi-organ surgeries for deep endometriosis involving the urinary tract.

Methods

A retrospective analysis included 130 patients who underwent surgery between 2020 and 2025 for deep endometriosis infiltrating the urinary tract. The average patient age was 37 ± 5 years and mean of BMI was 23.1 ± 3.2 kg/m². The study analysed the types of procedures performed, urinary tract involvement, preventive measures applied, and postoperative urological complications. Preventive strategies included ureteral stent placement with double-J catheters following intraoperative assessment of ureteral blood supply, tissue sealing using fibrin glue, use of an omental flap, assessment of intestinal vascularization with indocyanine green (ICG), reinforcement of bowel anastomoses with protective sutures, and creation of a protective stoma in selected cases. All surgeries were performed at a referral endometriosis center by a multidisciplinary team specialized in advanced DE surgery.

Results

Procedures involving the urinary tract, intestine, and uterus simultaneously accounted for 60.8% of surgeries, confirming the high complexity of cases. Ureteral procedures were performed in 77 patients, including 23.4% ureteral reimplantation, while bladder surgery was required in 84 patients; 38% had full-thickness infiltrations requiring resection. Intraoperative ureteral stent placement due to extensive dissection was performed in 80 patients. The overall complication rate was 11.5% (15 patients), with late complications accounting for 80%. The most common complications were ureterovaginal fistulas (6 patients) and vesicovaginal fistulas (3 patients). Complications were associated with a higher number of previous surgeries, extensive full-thickness bladder infiltration, and the need for complex multiorgan procedures. The use of fibrin glue was associated with a lower rate of postoperative complications. Despite the complexity of the surgeries and extensive organ involvement, the complication rate remained relatively low, suggesting the effectiveness of the preventive strategies used.

Conclusions

Extensive ureteral dissection, resection of full-thickness bladder lesions, and multiorgan surgery increase the risk of urinary tract fistulas, ureteral stenosis, and postoperative urinary leakage. Preventive procedures focused on ureteral protection, tissue perfusion assessment, and bowel anastomosis reinforcement are associated with a lower complication rate, even in high-risk patients. Treatment in specialized referral centres by experienced multidisciplinary teams reduces the risk of urinary tract injury and the need for secondary surgical interventions under conditions of altered postoperative anatomy.

ESGE35-0776 - P135
ePoster Presentations

Concordance between ultrasound-based and laparoscopic #Enzian staging and its relationship with r-ASRM classification across endometriosis subtypes: an internal audit of a tertiary endometriosis centre

Zdenka Lisa[1], Janoštiak Radoslav[1], Kristýna Hlinecká[1], Michal Mára[1], Michael Fanta[1]
[1]General University Hospital in Prague, Center of minimally-invasive surgery- Department of Obstetrics- Gynaecology and Neonatology, Prague, Czech Republic

Background

Accurate preoperative mapping of endometriosis is essential for surgical planning, patient counselling and multidisciplinary management. The #Enzian classification provides a compartment-based description of endometriosis, while the revised American Society for Reproductive Medicine classification remains widely used as a global staging system. This study aimed to evaluate the concordance between preoperative ultrasound-based #Enzian and laparoscopic #Enzian staging across endometriosis subtypes, and to assess the relationship between #Enzian findings, r-ASRM stage and symptom severity in a tertiary endometriosis.

Methods

This prospective observational cohort study included women aged 18–45 years undergoing laparoscopic surgery for suspected or confirmed endometriosis, and endometriosis-free controls undergoing benign gynaecological laparoscopy, between 2023 and 2025. All participants underwent expert preoperative ultrasound assessment according to the International Deep Endometriosis Analysis consensus, with systematic recording of ultrasound-based #Enzian [#Enzian(u)]. Intraoperative disease extent was documented using laparoscopic #Enzian [#Enzian(s)] and r-ASRM classification. The primary outcome was concordance between #Enzian(u) and #Enzian(s) across anatomical compartments. Secondary outcomes included correlations between r-ASRM stage, #Enzian-based disease extent and pain scores.

Results

A total of 145 women were included: ovarian endometriosis (n=33), deep endometriosis (n=55), peritoneal endometriosis (n=25) and endometriosis-free controls (n=32). Baseline characteristics were comparable across groups. Pain profiles differed by phenotype: dysmenorrhoea was most pronounced in deep endometriosis, whereas non-cyclic chronic pelvic pain and dyspareunia were highest in peritoneal disease. Ultrasound- and laparoscopy-based #Enzian concordance differed by subtype. In ovarian endometriosis, agreement was observed for compartments A, B and C and ovarian involvement, whereas in deep and peritoneal endometriosis concordance was strongest for ovarian and tubal involvement and weaker for deep compartments. r-ASRM stage correlated with laparoscopic #Enzian scores across all subtypes, supporting the internal consistency of intraoperative anatomical staging, but showed weaker associations with ultrasound-based #Enzian in deep endometriosis. Pain domains and composite pain scores overlapped substantially across r-ASRM stages, without a consistent stage-dependent increase.

Conclusions

Preoperative ultrasound-based #Enzian staging showed clinically useful concordance with laparoscopic findings, particularly for ovarian and tubal involvement. Agreement for deep compartments was more variable, especially for compartments B and C, highlighting the need for further refinement of compartment-specific ultrasound assessment and targeted training. Compared with r-ASRM, #Enzian provided a clearer, more structured and anatomically detailed tool for mapping disease extent, surgical planning and quality assessment within an expert endometriosis centre. However, neither #Enzian nor r-ASRM showed a consistent correlation with symptom severity, indicating that anatomical staging alone does not fully reflect the overall burden of endometriosis. These findings support the adequacy of internal audit as a quality-control tool for identifying areas requiring diagnostic improvement.

ESGE35-0782 - P136
ePoster Presentations

Selected parameters of sexual function of women with uterine fibroids prior to surgical treatment

Joanna Głogowska[1], Michał Ciebiera[2]
[1]Second Department of Obstetrics and Gynaecology- Centre of Postgraduate Medical Education- Warsaw- Poland - Warsaw Institute of Women's Health- Warsaw- Poland,
Second Department of Obstetrics and Gynaecology-, Warsaw, Poland
[2]Second Department of Obstetrics and Gynaecology- Centre of Postgraduate Medical Education- Warsaw- Poland- Warsaw Institute of Women's Health- Warsaw- Poland,
Second Department of Obstetrics and Gynaecology, Warsaw, Poland

Background

Female Sexual Dysfunction (FSD) is a significant but often underestimated health problem, especially in the perimenopausal female population and with concomitant Urogynaecological conditions. The Female Sexual Function Index (FSFI) is a tool recommended for the screening of sexual function in six domains: sexual desire, arousal, lubrication, orgasm, satisfaction and pain. The study aimed to assess sexual function in women with uterine fibroids qualified for operative UF removal and the clinical parameters associated with the FSFI score.

Methods

The study included 86 women aged 28–59 (M=44.0; SD=6.9) diagnosed with uterine fibroids and qualified for operative treatment. Overweight or obesity (BMI≥25) was reported by 52.3%, chronic diseases by 69.8%, and clinically confirmed pelvic organ prolapse by 29.1%. Fibroid location was classified by the FIGO system (types 0–7; n=80) and size expressed as maximum dimension in mm (n=81; range 4–200 mm). Sexual function was assessed using the Polish version of the FSFI (FSD risk threshold ≤26.55 per Wiegel et al.), pelvic floor muscle strength with the Oxford scale, and subjective complaints with the VAS scale. Statistical analysis included descriptive statistics, 95% CI for the mean, and Pearson correlation coefficients.

Results

The mean total FSFI score was 18.65 points (SD=8.42; 95% CI: 16.84–20.45; median 21.2). The risk of sexual dysfunction (FSFI≤26.55) was confirmed in 72 of 86 women (83.7%). The lowest domain scores were observed for pain (M=2.26; SD=1.76) and desire (M=2.97; SD=1.21), the highest for satisfaction (M=3.58) and lubrication (M=3.42). Age (r=−0.14), BMI (r=−0.05), parity (r=0.04), VAS score (r=0.02), fibroid location by FIGO (r=0.04; n=80), and fibroid size (r=−0.16; n=81) showed no clinically significant association with total FSFI score. Pelvic floor muscle strength was the only variable demonstrating a moderate positive correlation with sexual function (r=0.33).

Conclusions

In the study population of women with uterine fibroids presenting for an operative procedure, the incidence of the risk of sexual dysfunction (83.7%) is clearly higher than in the general female population, indicating the need for routine FSFI screening in this group. The greatest deficits are

found in the domains of pain and desire. The features of the fibroid, i.e., both its size and location according to the FIGO classification, do not account for the differences in FSFI scores, similarly to classic demographic and obstetric factors (age, BMI, parity). As regards the evaluated variables, only pelvic floor muscle strength demonstrated a moderate positive relationship with sexual function. It suggests that in this group of patients, sexual function may be more clearly associated with the functional state of the pelvic floor than with the anatomical features of the fibroid, and Urogynaecological rehabilitation may constitute a valuable element of supportive care.

ESGE35-0794 - P137
ePoster Presentations

Primary and Secondary Bladder Endometriosis: Two Different Disease Phenotypes ? A retrospective single-center cohort study.

Lidia Kisielewska[1], Martyna Masternak[2], Tomasz Szaflik[2], Krzysztof Szyłło[2]
[1]Polish Mother's Memorial Hospital Research Institute,
Department of Gynaecology- Oncological Gynaecology and Treatment of Endometriosis, Łódź, Poland
[2]Polish Mother's Memorial Hospital Research Institute,
Department of Gynaecology- Oncological Gynaecology and Treatment of Endometriosis, Łódź, Poland

Background

Although relatively rare (affecting 1% of women with endometriosis), bladder endometriosis (BE) is a clinically significant manifestation of the disease. BE may be divided into primary and secondary forms, which represent two heterogeneous clinical presentations and potentially have divergent pathogeneses.

Primary BE is believed to develop as a result of the intraperitoneal spread of endometrial cells and their gradual invasion into the bladder wall. By contrast, secondary BE results from caesarean sections and gynaecological procedures, which may point to iatrogenic implantation of endometrial cells into the bladder wall during surgery.

The aim of the study was to compare the clinical characteristics, diagnostic processes, and intraoperative findings in patients with primary and secondary BE, with a particular focus on the patients' age and concomitant endometriotic lesions.

Methods

A retrospective cohort study was conducted at the Department of Gynaecology, Oncological Gynaecology and Treatment of Endometriosis of the Polish Mother's Memorial Hospital Research Institute in Lodz between 2017 and May 2026. Data were retrospectively collected from patients' medical records in May 2026. The study group included 13 patients who underwent surgery for BE (6 patients with primary BE and 7 patients with secondary BE). Laparotomy was performed in 2 patients, whereas 11 patients underwent laparoscopic surgery. The analysis included patients' age, obstetric history, clinical symptoms, imaging findings, cystoscopic findings, coexistence with other endometriosis lesions, surgical treatment, and histopathological results.

Results

The symptoms most commonly reported in all cases included pelvic pain, dysmenorrhea, dysuria, urinary urgency, and dyspareunia.

Patients with primary BE were younger than those affected by the secondary disease phenotype (median age 34.5 vs 39 years).

The secondary BE group demonstrated a wider age distribution (SD 4.2) than the primary BE group (SD 3.0)

Concomitant BE occurs more commonly than the isolated form in patients with primary BE (83.3% vs 42.9%).

Conversely, the isolated form, limited to the bladder, was more common in patients with secondary bladder endometriosis (57.1% vs. 16.7%).

Bladder lesions were identified in imaging tests, including transvaginal ultrasound (TVUS) and magnetic resonance imaging (MRI). Cystoscopy was an important component of the preoperative diagnostic process (including preoperative histopathological confirmation) and during the surgical procedure. Histopathological examination confirmed endometriosis in postoperative tissue samples from all the patients.

Conclusions

Despite affecting the same anatomical location, primary and secondary bladder endometriosis seem to constitute two distinct clinical phenotypes.

Primary BE more frequently coexists with additional endometriosis locations. By contrast, secondary BE more commonly presents as isolated bladder involvement. The differences observed between primary and secondary BE may support the hypothesis that these two forms of the condition are triggered by distinct pathogenic mechanisms.

ESGE35-0798 - P138
ePoster Presentations

Management of Uterine Perforation and Mirena Coil Migration One Year Post Insertion

Aisha Baldo[1], Suganya Sukumaran[1], Ruvana Tabassum[1]
[1]George Eliot Hospital, Obstetrics and Gynaecology, Nuneaton, United Kingdom

Background

The objective of this case report is to present an unusual finding in a patient listed for laparoscopy and hysteroscopy when she presented with heavy painful periods.

Methods

A 45-year-old patient referred for a Mirena coil insertion for contraception. She was on depot injections and was commenced on HRT by the GP to reduce her perimenopausal symptoms. She had a LLETZ in the past and had normal smears since. She is nulliparous and was fit and well. She had a mirena coil inserted under general anaesthesia as per her request. During a follow up with her GP, the threads were not visualised. An ultrasound scan showed no evidence of the coil within the endometrial cavity and a subsequent X ray showed the coil in the pelvis. She was booked for a laparoscopy and a hysteroscopy. Hysteroscopy under general anaesthesia showed omentum to be filling cavity, and extending towards cervical canal. Laparoscopy showed coil embedded in omentum with no bowel involvement. The coil was removed via 5mm port and a hysteroscopy was carried out simultaneously. This showed a clear cavity now with a small defect near the left cornual end. The defect was approximated using a 3-0 barbed suture.

Results

This case report shows the importance of systematic assessment prior to biopsy from the tissue seen within the endometrial cavity. The defect was closed as there was a risk of recurrence with the omentum entering the cavity which may result in omental necrosis.

Conclusions

Careful systematic assessment and clinical suspicion is crucial when the findings are unusual during hysteroscopy to avoid inadvertent complications.

ESGE35-0802 - P139
ePoster Presentations

Operative route, patient profile and perioperative outcomes in hysterectomy for non-malignant indications: a single-centre cohort focused on previous caesarean section

Hikmet Tunc Timur[1], Elif Şeyma Çetinkaya[1], Doga Dilber[1], Zeynep Bayramoglu[2], Sefa Kurt[1]
[1]Dokuz Eylul University School of Medicine, Obstetrics and Gynaecology, Izmir, Türkiye
[2]Dokuz Eylul University School of Medicine, Pathology, Izmir, Türkiye

Background

Previous caesarean section (C/S) is often cited as a reason to favour total abdominal hysterectomy (TAH) over total laparoscopic hysterectomy (TLH). We assessed whether previous C/S or other abdominopelvic surgery was associated with operative route or complications in women undergoing hysterectomy for non-malignant indications.

Methods

Single-centre retrospective cohort of 117 consecutive women undergoing hysterectomy (TAH n = 41; TLH n = 76). Extracted variables: age, gravidity, parity, number of previous C/S, previous abdominopelvic surgery other than C/S, operative time, perioperative haemoglobin (Hb) drop, hospital stay, uterine specimen weight, and complications (intra-operative organ injury — bladder, ureter, bowel — and documented post-operative complications). Multivariable logistic regression for TLH selection used pre-operative variables only; uterine specimen weight (measured post-operatively) was excluded. Continuous variables: median [interquartile range, IQR], Mann–Whitney U or Spearman correlation. Categorical: exact (Clopper–Pearson) 95% confidence intervals (CIs), χ^2 or Fisher exact. Two-sided $p < 0.05$ was significant.

Results

Median age (50 [46–56] vs 49.5 [45–57] years; p = 0.82), parity (1 [1–2] vs 2 [1–2]; p = 0.33), C/S history (31.7% vs 38.2%; p = 0.55) and other abdominopelvic surgery (39.0% vs 39.5%; p = 1.0) were similar in TAH and TLH groups. Multivariable model (n = 117) — no pre-operative factor reached significance: previous C/S aOR 1.35 (95% CI 0.59–3.09); other abdominopelvic surgery 1.05 (0.48–2.29); age 1.00/year (0.96–1.05); parity 1.12/birth (0.80–1.56); all p > 0.4. Model discrimination was no better than chance (area under the ROC curve [AUC] 0.536; likelihood-ratio p = 0.91). Median post-operative uterine specimen weight was higher in TAH (165 [87–347] g) than TLH (115 [83–163] g; p = 0.005). Median Hb drop was greater in TAH (1.0 [0.5–1.4] g/dL) than TLH (0.5 [0.0–0.9]; p = 0.001). Median operative time (150 [130–180] vs 145 [124–180] min; p = 0.63) and hospital stay (3 [3–4] vs 3 [3–4] days; p = 0.37) did not differ. Complications were rare: TAH 2/41 = 4.9% (95% CI 0.6–16.5%) versus TLH 3/76 = 3.9% (0.8–11.1%), Fisher exact p = 1.0; within TLH, rates with vs without prior C/S were 3.4% (1/29; 0.1–17.8%) vs 4.3% (2/47; 0.5–14.5%; Fisher exact p = 1.0). Within TLH, number of previous C/S (median 0, range 0–3) showed no Spearman correlation with operative time, Hb drop or hospital stay (all p > 0.1).

Conclusions

In this cohort, none of the pre-operative patient factors examined — including previous C/S — was independently associated with operative route. The difference in resected uterine weights between routes is consistent with case selection by uterine size, which was not captured pre-operatively. Complications were rare; the study lacked events to detect whether the presence or number of previous C/S affects complication risk in TLH.

ESGE35-0814 - P141
ePoster Presentations

Early outcomes and learning curve after implementation of a new robotic platform for robotic sacrocolpopexy: a single-center comparative study

Masafumi Katakura[1], *Kenbun Sone*[1], *Yukiko Katagiri*[1], *Masahiko Nakata*[1]
[1]*Toho University Omori Medical Center, Obstetrics and Gynaecology, Tokyo, Japan*

Background

To evaluate perioperative safety, early surgical outcomes, and the learning curve after implementation of the Hugo RAS system for robotic sacrocolpopexy (RSC), using the da Vinci platform as the institutional reference.

Methods

This was a single-center retrospective study of consecutive patients who underwent RSC for cystocele, uterine prolapse, or vaginal vault prolapse between 2023 and April 2026. Five procedures were performed using the da Vinci platform and 21 using the Hugo RAS system. The primary outcome was 30-day morbidity, defined as Clavien-Dindo grade II or higher complications. Secondary outcomes included operative time, console time, estimated blood loss, length of postoperative hospital stay, conversion, and reoperation. Because of the limited sample size, results were analysed descriptively. Learning curve assessment was performed using cumulative sum (CUSUM) analysis of console time for a single primary surgeon who had prior experience of approximately 200 robotic procedures. Ethical approval was obtained.

Results

Perioperative outcomes were comparable between the two platforms. In the Hugo cohort, mean operative time was 182 minutes, mean console time was 127 minutes, mean estimated blood loss was 18 mL, and mean postoperative hospital stay was 5.0 days. Corresponding values in the da Vinci cohort were 186 minutes, 118 minutes, 18.4 mL, and 5.1 days, respectively. One Clavien-Dindo grade II surgical site infection occurred in each group, while no grade III or higher complications were observed. No conversion, reoperation, or major device-related adverse event occurred in either group. In the surgeon with established robotic experience, CUSUM analysis demonstrated an inflection point at approximately the fifth Hugo case, after which console time began to decrease.

Conclusions

Implementation of the Hugo RAS system for RSC was feasible and safe in a center with prior robotic experience. Although mean console time remained slightly longer during the early adoption phase, overall perioperative outcomes were comparable to those of the institutional da Vinci cohort. In an experienced robotic surgeon, console efficiency improved after approximately five cases, suggesting a relatively short learning curve. Structured team familiarization and accumulated case experience may facilitate safe adoption of a new robotic platform for RSC.

ESGE35-0816 - P142
ePoster Presentations

Efficacy of Conservative Surgical Management in Tubal Ectopic Pregnancy: A Retrospective Descriptive Study

Yasmine Chiba[1], Zoghlami Achref[1], Mellouli Ferdaous[1], Hfaiedh Ines[1], Bouassida Mehdi[1], Mourali Mechaal[1]
[1]Habib Bougatfa University Hospital in Bizerte, Department of Obstetrics and Gynaecology, Bizerte, Tunisia

Background

Ectopic pregnancy remains a major cause of maternal morbidity during the first trimester of pregnancy. Conservative surgical management aims to preserve tubal function and future fertility while ensuring effective resolution of the ectopic gestation. The objective of this study was to evaluate the efficacy of conservative surgical treatment for tubal ectopic pregnancy through postoperative β-hCG monitoring.

Methods

We conducted a retrospective descriptive study over a period of two and a half years in a tertiary Gynaecology department. Fifty patients who underwent surgical management for tubal ectopic pregnancy were initially included. Twenty-five patients treated by radical surgery (salpingectomy) were excluded because of poor tubal quality, large ectopic pregnancy size, or persistent intraoperative bleeding. The final study population included 25 patients treated conservatively by tubal-sparing surgery. The age distribution showed that 4 patients (16%) were between 41 and 45 years old, 7 patients (28%) were between 36 and 40 years old, 10 patients (36%) were between 31 and 35 years old, and 4 patients (16%) were between 25 and 30 years old. Postoperative follow-up was based on serial serum β-hCG measurements. Treatment success was defined by a decrease of more than 50% in β-hCG levels within 48 hours after surgery, followed by complete negativization within the following weeks.

Results

Conservative surgical treatment demonstrated a high efficacy rate in the selected population. The predominance of patients aged between 31 and 40 years suggests that ectopic pregnancy requiring conservative management occurs mainly in women of active reproductive age, often with a strong desire for fertility preservation. All patients included in the conservative management group showed a significant postoperative decline in serum β-hCG levels, exceeding 50% within 48 hours after surgery. Complete β-hCG negativization was achieved within a few weeks in the majority of cases, confirming successful resolution of the ectopic pregnancy without the need for secondary radical intervention. No major postoperative complications were reported.

Conclusions

Conservative surgical management of tubal ectopic pregnancy is an effective therapeutic option in selected patients with favourable clinical and intraoperative findings. Careful patient selection and

close postoperative β-hCG monitoring are essential to ensure treatment success while preserving reproductive potential.

ESGE35-0818 - P143
ePoster Presentations

beyond imaging: endoscopic diagnosis of neovaginal-enteric fistula in a patient with MRKH syndrome

Jagoda Dradrach[1], Robert Jach[2], Andrzej Zmaczyński[2]
[1]University Hospital in Krakow,
Clinical Department of Gynecological Endocrinology and Gynecological Oncology, Cracow, Poland
[2]Jagiellonian University Medical College,
Clinical Department of Gynecological Endocrinology and Gynecological Oncology, Cracow, Poland

Background

Neovaginal-enteric fistula is a rare but serious complication following neovaginal reconstruction in patients with MRKH syndrome. Diagnosis may be particularly challenging in cases of small fistulous tracts, as standard imaging modalities can remain inconclusive despite persistent clinical symptoms. Additional minimally invasive diagnostic techniques may therefore be required to establish the diagnosis and guide surgical management.

Methods

A 23-year-old patient with MRKH syndrome was referred to our tertiary center due to suspected neovaginal-enteric fistula. The patient had undergone a Davydov-Moore procedure in another institution in 2023, followed by four surgical procedures due to complications. Prior to referral, pelvic magnetic resonance imaging (MRI), rectal contrast examination were performed; however, none of these modalities demonstrated a definite fistulous tract. Due to persistent clinical symptoms and inconclusive imaging findings, diagnostic vaginoscopy was undertaken.

Results

Diagnostic vaginoscopy revealed a small fistulous opening measuring approximately 3–4 mm, located at the apex of the neovagina. The lesion had not been visualized on previous imaging studies. The patient underwent excision of a rectovaginal fistula with Martius flap reconstruction under hysteroscopic guidance, combined with laparoscopic diverting ileostomy. The postoperative course was uneventful. The ileostomy closure is scheduled for July.

Conclusions

Neovaginal-enteric fistula is a rare but significant complication following neovaginal reconstruction in patients with MRKH syndrome. Imaging studies may remain inconclusive, particularly in cases of small fistulous tracts. Diagnostic vaginoscopy may provide crucial additional information and should be considered in symptomatic patients with negative or equivocal radiological findings. Furthermore, vaginoscopy is a quick, minimally invasive, and well-tolerated diagnostic procedure.

ESGE35-0845 - P144
ePoster Presentations

Fluid Overload Syndrome Following Operative Hysteroscopic Myomectomy Requiring Intensive Care Management: A Case Report

Lucie Bánovská[1], Dominika Rieglová[2], Eliška Gazárková[3], Viktor Agalarev[4]
[1]Bánovská L. M.D- Rieglová D. M.D.- Gazárková E. M.D.- Agalarev V. M.D.,
Department of Gynaecology- Obstetrics and Neonatology- University Hospital Brno- Brno- Czech Republic- Clinic of anaesthesiology- resuscitation and intensive medicine- University Hospital Brno- Czech Repubic Faculty of Medicine- Masaryk University- Brno- Czech Republic, Brno, Czech Republic
[2]University Hospital Brno- Brno- Czech Republic- Masaryk university Brno,
Department of Gynaecology- Obstetrics and Neonatology- University Hospital Brno- Brno- Czech Republic, Brno, Czech Republic
[3]University Hospital Brno- Brno- Czech Republic- Masaryk university Brno,
Department of Gynaecology- Obstetrics and Neonatology, Brno, Czech Republic
[4]University Hospital Brno- Czech RepubicFaculty of Medicine- Masaryk University- Brno- Czech,
Clinic of anaesthesiology- resuscitation and intensive medicine, Brno, Czech Republic

Background

To present a rare but severe case of fluid overload syndrome following operative hysteroscopy and to highlight the importance of early recognition and intensive care unit management.

Methods

A 36-year-old woman underwent operative hysteroscopy for infertility, with a probable submucosal myoma as the underlying cause.
The procedure was performed under general anesthesia using monopolar resection with a physiological distension medium. The surgery was complicated by a blood loss of 500 mL, and a progressively increasing fluid deficit was observed, reaching approximately 4000 mL. Following the procedure, the patient developed respiratory deterioration with decreasing oxygen saturation and signs of pulmonary edema, leading to immediate termination of the surgery. A Foley catheter was placed in the uterine cavity to control the bleeding.

Results

Postoperatively, the patient was transferred to the intensive care unit because of acute respiratory insufficiency secondary to fluid overload syndrome. Laboratory investigations revealed electrolyte imbalance. Chest imaging confirmed pulmonary edema. Intensive care management included mechanical ventilation, intravenous diuretics, strict fluid restriction, electrolyte correction, and continuous hemodynamic monitoring. The patient demonstrated gradual clinical improvement within 2 days and was transferred to the standard Gynaecology ward on postoperative day 3. She was discharged home in stable condition without long-term sequelae and was scheduled for follow-up at the reproductive medicine outpatient clinic with sonohysterography.

Conclusions

Fluid overload syndrome remains a potentially life-threatening complication of operative hysteroscopy. Careful intraoperative monitoring of fluid balance, adherence to recommended fluid deficit limits, and prompt recognition of early clinical signs are essential to minimize morbidity. Early multidisciplinary management, including intensive care support, can lead to favorable outcomes even in severe cases.

ESGE35-0865 - P149
ePoster Presentations

Hysteroscopic view of uterine tuberculosis after menopause: case report and literature review

Rafal Watrowski[1], Philipp Kurz[2], Stoyan Kostov[3], Radmila Sparić[4], Ibrahim Alkatout[5], Salvatore Giovanni Vitale[6]
[1]Helios Hospital Millheim/ University of Freiburg, Department of Gynaecology/ Faculty of Medicine, Millheim/ Freiburg, Germany
[2]Institute of Pathology, Dres. Striepecke- Schwarzkopf- Kurz, Freiburg, Germany
[3]Hospital "Saint Anna"/ University of Pleven, Department of Gynaecology/ Research Institute, Varna/ Pleven, Bulgaria
[4]University of Belgrade/ University Clinical Centre of Serbia,
Faculty of Medicine/ Clinic for Gynaecology and Obstetrics, Belgrade, Serbia
[5]Medical University of Innsbruck, Department of Obstetrics and Gynaecology, Innsbruck, Austria
[6]University of Catania,
Obstetrics and Gynaecology Unit- "Gaspare Rodolico - San Marco" University Hospital- Department of General Surgery and Medical Surgical Specialties, Catania, Italy

Background

Female genital tuberculosis (FGTB) is exceptionally rare in low-incidence regions. In high-burden populations, especially in South Asia and Africa, oligosymptomatic FGTB is often detected during infertility work-up. Hysteroscopic documentation is scarce, and postmenopausal presentations are limited to a few case reports. We report a postmenopausal case of endometrial tuberculosis detected during hysteroscopic evaluation of a suspicious incidental ultrasound finding in an asymptomatic patient and discuss it in the context of the available literature.

Methods

A case report was prepared from clinical, ultrasound, hysteroscopic, histopathological, microbiological, and follow-up data, with written patient consent. The literature review focused on visual findings, diagnostic pitfalls, postmenopausal presentation, and clinical lessons for low-incidence settings.

Results

A 66-year-old postmenopausal woman was referred for hysteroscopic evaluation of a suspicious uterine finding on transvaginal ultrasound (TVUS). The patient explicitly requested TVUS during a routine gynecological check-up, although TVUS is not part of routine screening in Germany. She had no postmenopausal bleeding, vaginal discharge, cough, fever, or travel history to high-prevalence regions. The only reason for her request was a nonspecific pelvic sensation. TVUS showed serometra/pyometra with intracavitary material in a distorted, irregularly lined uterine cavity. The initial impression of intrauterine malignancy was weakened by absent perfusion in the solid regions. The preoperative diagnosis was therefore intrauterine necrosis of unclear origin. CA-125 was elevated at 54 U/mL, and C-reactive protein was 8 mg/L. After cervical dilatation, pus drained from the uterine cavity. Hysteroscopy showed a pyonecrotic cavity with turbid fluid, an irregular partly pale and partly

hyperemic-hemorrhagic edematous endometrium, and broad whitish-yellow avascular friable deposits, including large caseous-looking and smaller cotton-wool-like plaques. No typical vascular polypoid, myomatous, or papillary tumor pattern was seen. Histology was decisive and showed necrotizing granulomatous endometritis with epithelioid granulomas and Langhans-type giant cells, without malignancy. Interferon-gamma release assay was positive. Repeat endometrial sampling confirmed *Mycobacterium tuberculosis* complex by Xpert MTB/RIF Ultra, Xpert MTB/XDR, and IS6110 qPCR. Thoracic CT showed post-tuberculous/post-inflammatory changes but no active pulmonary tuberculosis. Antituberculous therapy was initiated. After five weeks, TVUS showed marked regression, with only slit-like residual fluid and restoration of the previously thinned myometrial contour.

The literature review identified only a small number of publications illustrating hysteroscopic FGTB findings (17 reports or series). Most were infertility-focused. Postmenopausal reports described bleeding, pyometra, discharge, endometrial thickening, ascites, elevated CA-125, cervical tumor mimicry, or peritoneal carcinomatosis mimicry. One published postmenopausal case had a lethal outcome after delayed recognition.

Conclusions

FGTB can occur beyond high-risk regions, high-risk populations, and the reproductive phase. In postmenopausal patients, it may be oligosymptomatic and may mimic genital malignancy. Hysteroscopic FGTB patterns are rarely seen in routine practice, but if correctly identified, they may direct the diagnosis along with histology (granulomas with Langhans-type giant cells) and mycobacterial testing.

ESGE35-0889 - P152
ePoster Presentations

Evaluation of Laparoscopic Training Among Obstetrics and Gynaecology Residents

Yasmine Chiba[1], Nouiji Sabrine[1], Mili Youssef[1], Hfaiedh Ines[1], Mellouli Ferdaous[1], Mourali Mechaal[1]
[1]Habib Bougatfa University Hospital in Bizerte, Department of Obstetrics and Gynaecology, Bizerte, Tunisia

Background

Laparoscopy is an essential component of modern gynecologic surgery. However, acquiring adequate minimally invasive surgical skills remains a major challenge in residency training, particularly in resource-limited settings. Structured evaluation of training quality is necessary to identify gaps and improve surgical education.

Objective

To evaluate laparoscopic training among obstetrics and Gynaecology residents in Tunisia, focusing on theoretical education, operative exposure, autonomy, satisfaction, and perceived barriers.

Methods

This was a descriptive cross-sectional study conducted among obstetrics and Gynaecology residents from different hospital centres in Tunisia.

Data were collected using an anonymous questionnaire assessing theoretical and practical exposure to laparoscopy, operative participation, level of autonomy, satisfaction, and perceived training barriers.

Results

Among participants, 86.4% reported that laparoscopic surgery is performed in their training center. Only 56.5% had received theoretical teaching, and among them, 71.4% considered it insufficient.

Exposure to surgery showed that 45.5% had observed more than 30 laparoscopic procedures, while 78.3% had participated in operative steps under supervision, mainly trocar placement (90%), pelvic exploration (85%), and kystectomy (70%).

However, only 17.4% reported being autonomous for simple laparoscopy, while 43.5% felt partially autonomous.

The main barriers to training were lack of supervision (65.2%), lack of simulation (56.5%), limited operating room time (47.8%), lack of cases (39.1%), and insufficient equipment (34.8%).

The most challenging skills were intracorporeal suturing (60.9%) and management of complications (56.5%). Overall, 78.3% of residents were dissatisfied with their training, and 91.3% believed that simulation-based training would significantly improve their skills.

Finally, 91.3% expressed the need for a structured additional training program.

Conclusions

Laparoscopic training among obstetrics and Gynaecology residents across Tunisian university hospitals remains insufficiently structured, with low autonomy and high dissatisfaction rates. The implementation of standardized curricula incorporating simulation-based training, supervised surgical exposure, and structured mentorship is essential to improve surgical competence and harmonize training quality across centres.

ESGE35-0892 - P153
ePoster Presentations

Mechanical Hysteroscopy in One-Day Surgery: Clinical Spectrum, Findings, and Diagnostic Efficacy in a Single-Center Experience of 249 Patients

Karolina Zeman[1,2], *Andrzej Zmaczyński*[1,2], *Robert Jach*[1,2]
[1]*Superior Centrum Medyczne, Ob/Gyn Department of Superior, Kraków, Poland*
[2]*University Hospital in Krakow,*
Clinical Department of Gynecological Endocrinology and Gynecological Oncology, Kraków, Poland

Background

To evaluate the clinical indications, hysteroscopic findings, histopathological correlation, and patient-reported pain scores associated with mechanical hysteroscopy performed in a one-day surgery setting.

Methods

A retrospective cohort study of 249 consecutive patients who underwent mechanical hysteroscopy between 2022 and 2026 at a single gynecological center. Clinical data including age, primary indications (e.g., infertility, pre-embryo transfer workup), intraoperative findings, visual analogue scale (VAS/NRS) pain scores, and subsequent histopathological(HP) outcomes were analysed.

Results

The study population had a mean age of 40.4 ± 8.6 years. Infertility or pre-embryo transfer workup was the primary indication in 51.8% (n=129) of cases. The most frequent hysteroscopic findings were endometrial polyps in 53.0% (n=132), followed by hysteroscopic features of chronic endometritis (CE) in 29.3% (n=73), uterine fibroids in 10.8% (n=27),retained products of conception (RPOC) in 4.8% (n=12), and congenital uterine anomalies in 4.0% (n=10). Only 2 cases (0.8%) presented oncologically suspicious lesions on HP examination. Histopathological confirmation of the visual diagnosis was achieved in 68.4% of cases. In patients monitored for pain, the procedure was well-tolerated with a mean intraoperative NRS score of 4.49 ± 2.30, decreasing to 2.09 ± 1.25 postoperatively.

Conclusions

Mechanical hysteroscopy is a safe, highly effective, and well-tolerated minimally invasive tool. It holds exceptional value in the pre-IVF and infertility workup, where a high prevalence of endometrial polyps and chronic endometritis can be identified and concurrently managed to optimize reproductive outcomes.

ESGE35-0893 - P154
ePoster Presentations

Minimally Invasive Surgical Management of Bowel Endometriosis: A Single-Center Case Series.

Edyta Leśniak[1], Michał Wojciechowski[2], Mateusz Jęckowski[3], Miłosz Wilczyński[2], Andrzej Malinowski[2]
[1]Polish Mother's Memorial Hospital Research Institute,
Department of Operative- Endoscopic and Oncological Gynaecology-, Lodz, Poland
[2]Polish Mother's Memorial Hospital Research Institute,
Department of Operative- Endoscopic and Oncological Gynaecology, Lodz, Poland
[3]Provincial Multi-Specialist Center of Oncology and Traumatology named after Nicolaus Copernicus,
Department of Oncological Surgery, Lodz, Poland

Background

Bowel endometriosis represents one of the most challenging manifestations of deep infiltrating endometriosis and often requires complex multidisciplinary surgical management. The aim of this study was to evaluate the feasibility, safety, and perioperative outcomes of minimally invasive surgical treatment of bowel endometriosis in a single-center case series.

Methods

A retrospective analysis of seven patients undergoing laparoscopic surgery for bowel endometriosis between January and May 2026 at the Department of Operative, Endoscopic and Oncological Gynaecology, Polish Mother's Memorial Hospital Research Institute, Lodz, Poland, was performed. Surgical procedures included discoid rectal resection, segmental colorectal resection, partial sigmoid and rectal resection, and small bowel resection with primary anastomosis. Additional gynecological procedures were performed when required. Selected colorectal procedures were performed using the natural orifice specimen extraction (NOSE) technique. Perioperative outcomes assessed included operative time, estimated blood loss, postoperative inflammatory markers, length of hospitalization, and perioperative complications. Postoperative inflammatory response was assessed by routine C-reactive protein (CRP) measurements obtained on postoperative days 1, 2, and 3 as a screening tool for early detection of anastomotic leakage.

Results

All procedures were completed laparoscopically without conversion to laparotomy. The mean operative time was 214 minutes (range 155–310 minutes). Surgical management was individualized according to lesion location and extent of infiltration. Procedures involved the rectum, sigmoid colon, and small bowel, with several patients requiring combined gynecological procedures including ovarian cystectomy, myomectomy, hysterectomy, adnexectomy, and bladder endometriosis excision. The mean postoperative hospitalization time was 6.4 days (range 5–7 days). Estimated blood loss ranged from 1.7 to 3.1 g/dL decrease in haemoglobin concentration. Two postoperative complications were observed: one postoperative wound hematoma classified as Clavien–Dindo grade II and one wound infection classified as Clavien–Dindo grade I. No anastomotic leakage, reoperation, or severe postoperative morbidity occurred. Postoperative inflammatory marker dynamics remained acceptable in all patients.

Conclusions

Minimally invasive surgery for bowel endometriosis is feasible and safe when performed in appropriately selected patients within an experienced multidisciplinary team. Surgical treatment should be individualized according to the location and extent of bowel infiltration. Complex laparoscopic bowel procedures, including NOSE techniques, can be performed with acceptable perioperative outcomes and low complication rates.

ESGE35-0901 - P155
ePoster Presentations

Laparoscopic Adnexectomy in Pelvic Ectopic Kidney: Conversion for Suspected Ureteral Injury

Yasmine Chiba[1], Fhal Ameni[1], Barouni Rihab[1], Hfaiedh Ines[1], Jaafar Wissal[1], Mourali Mechaal[1]
[1]Habib Bougatfa University Hospital in Bizerte, Department of Obstetrics and Gynaecology, Bizerte, Tunisia

Background

Objectives

To describe the surgical management of complex pelvic adhesions during laparoscopic bilateral adnexectomy in a patient with previous haemostatic hysterectomy and crossed pelvic ectopic kidney, highlighting the challenges of ureteral identification in distorted pelvic anatomy.

Methods

We report the case of a 65-year-old woman with a history of hysterectomy for postpartum hemorrhage, left mastectomy followed by radiotherapy and chemotherapy for breast cancer, and surgery for right renal lithiasis. Preoperative imaging revealed a 3.5 × 4.5 cm adnexal cystic lesion without suspicious vegetations associated with a crossed non-fused left pelvic ectopic kidney located in the right iliac fossa.

Laparoscopic exploration showed severe adhesions involving the left adnexa, sigmoid colon, bowel loops, and pelvic sidewall, with complete distortion of pelvic anatomy and an empty hysterectomy bed. Extensive adhesiolysis was required to restore anatomical landmarks.

During left adnexectomy, identification of the left ureter was difficult because of the aberrant urinary tract anatomy related to the ectopic kidney. Following uncertainty regarding ureteral integrity, conversion to laparotomy was performed. Intraoperative urologic evaluation including cystoscopy and left ureteral catheterization confirmed bilateral ureteral patency without contrast extravasation. Left adnexectomy was completed laparoscopically, while right adnexectomy was subsequently performed by laparotomy after careful ligation of the infundibulopelvic ligament.

Results

Complete excision of the adnexal lesion was achieved without bowel or urinary tract injury. Postoperative uro-CT scan confirmed a crossed non-fused pelvic ectopic kidney with aberrant ureteral course crossing the midline toward the left ureteric meatus, without urinary leakage or upper urinary tract dilatation. Histopathology revealed a benign simple ovarian cyst. Postoperative recovery was uneventful.

Conclusions

Previous haemostatic hysterectomy and pelvic ectopic kidney may considerably distort pelvic anatomy and increase the risk of ureteral injury during adnexal surgery. Careful adhesiolysis,

multidisciplinary collaboration, and timely conversion to laparotomy are essential to ensure surgical safety.

ESGE35-0911 - P156
ePoster Presentations

Benefits of robotic hysterectomy compared with laparoscopic hysterectomy for benign causes

Efthalia MARKOPOULOU[1], Paul Stanciu[2], Dimitris Tsolakidis[1], Grigoris Grimbizis[1]
[1]Aristotle University Of Thessaloniki, 1st Department of Obstetrics and Gynaecology, Thessaloniki, Greece
[2]West Hertfordshire NHS Trust, Watford General Hospital, Watford, United Kingdom

Background

Introduction: Robotics are becoming the emerging approach to hysterectomy for benign causes. Hence, laparoscopic hysterectomy (TLH) is the established minimally invasive approach, it has some limitations. These limitations include two- dimensional view, restricted range of motion and ergonomics that may increase the rate of conversion and complications. Robotic have showed advantages regarding improved dexterity, three-dimensional view, restriction of hand tremor, increased precision and ease of use of instruments. Robotic hysterectomy (RLH) may perform better in different clinical settings. The aim was to identify all benefits of RLH compared to TLH for different indications for hysterectomy and in different clinical settings.

Methods

Methods: A thorough and comprehensive literature search was conducted in Pubmed, Scopus, ScienceDirect databases in May 2026. The search strategy included a combination of Medical Subject Headings (MESH) "robotic hysterectomy" and "laparoscopic hysterectomy" for retrospective studies and RCTS. All duplicate findings were removed. All results were screened in title and abstract format for relevance with the topic. All studies referring to pelvic organ prolapse and malignancy were excluded. All studies that included cases in which another minimal invasive approach other that the TLH was performed were excluded. Retrospective, prospective and propensity score- matched studies and RCTs were only included. Studies not published in English were excluded. All studies not published in full- text were excluded. Data regarding operation duration, intraoperative blood loss, intraoperative and postoperative complications were assessed.

Results

Results: 1741 records in Pubmed, 2083 records in Scopus and 1728 records in ScienceDirect were identified. 4 RCTs and 36 prospective and retrospective cohort studies were finally included in the analysis. 4 RCTs were found that compared operative time for benign hysterectomy. In 2 RCTs increased operative time was needed in RLH while the other 2 RCTs showed decreased operative time in RLH. In most retrospective and prospective observational studies operative time did not differ between RLH and TLH and it was affected mainly by uterine weight and complexity of surgery. In two RCTs that compared intraoperative blood loss in RLH with that in TLH opposite results were shown. However, in most observational studies estimated blood loss was lower in RLH compared to TLH. Complication rates in 2 RCTs were lower in RLH compared to TLH whereas no statistically significant difference was observed in one RCT and in most prospective and retrospective cohort studies.

Conclusions

Conclusion: RLH is an acceptable alternative for hysterectomy for benign cause compared to TLH. Although it seems that RLH has specific limitations such as docking that may increase operating time, this was not proven in most studies. Intraoperative blood loss seems to be reduced in RLH and there seems to be no difference in postoperative complications with both methods.

ESGE35-0918 - P157
ePoster Presentations

Endometriosis service audit 2024 at University Hospitals of North Midlands: a tertiary Endometriosis centre experience

Ahmed Salama Hassan[1], *Gourab Misra*[1], *Ammar Rafiq*[1], *Aisling Mccann*[1], *Ayesha Mahmud*[1]
[1]*University hospitals of North Midlands, Gynaecology, Stoke on Trent, United Kingdom*

Background

High-quality multidisciplinary care is essential for women with complex endometriosis. Regular service audit is a key requirement for maintaining standards within British Society for Gynaecological Endoscopy–accredited centres. This audit reviews surgical activity, outcomes and imaging correlation within the University Hospitals of North Midlands (UHNM) endometriosis service during 2024.

Methods

A retrospective audit was conducted of all patients undergoing surgery for endometriosis at UHNM between 1 January and 31 December 2024. Data were collected from the BSGE database, electronic patient records and operative notes, and collated following removal of patient identifiers. Outcomes assessed included type of surgery, multidisciplinary involvement, peri-operative and post-operative complications, length of stay, histological confirmation and correlation between pre-operative MRI and operative findings.

Results

Fifty-nine surgical cases were identified. All patients had histologically confirmed endometriosis. Surgery was performed laparoscopically or robotically, with a significant proportion requiring joint operating with colorectal and/or urology teams, reflecting case complexity. Urinary tract and bowel disease were managed appropriately within a multidisciplinary setting. There were no ureteric injuries. One bowel fistula was reported. No post-operative complications occurred in 57 cases. Length of stay was short in the majority of patients. MRI demonstrated good correlation with operative findings, with a mean accuracy score of 8.2 out of 10.

Conclusions

This audit demonstrates safe, effective multidisciplinary surgical management of endometriosis at UHNM, with low complication rates and excellent histological and imaging concordance. Ongoing service development, including adoption of robotic surgery and participation in clinical trials, supports continued quality improvement.

ESGE35-0954 - P158
ePoster Presentations

Renal Preservation Following Multidisciplinary Surgery for Extrinsic Peri-Ureteric Endometriosis: Experience from a Tertiary Endometriosis Centre

Saima Farooq[1], *Fevzi Shakir*[2]
[1]*Cromwell Hospital, Gynaecology, LONDON, United Kingdom*
[2]*Royal Free Hospital, Gynaecology, London, United Kingdom*

Background

Ureteric endometriosis represents a rare but clinically significant manifestation of deep infiltrating endometriosis and may result in silent obstruction, hydronephrosis, and progressive renal impairment. Disease extent is frequently underestimated on pre-operative imaging, making multidisciplinary assessment and tailored surgical management essential. Contemporary minimally invasive approaches, including advanced laparoscopic and robotic ureterolysis, may facilitate effective renal preservation while minimising surgical morbidity.

Methods

A retrospective observational study was conducted of patients undergoing surgery for ureteric endometriosis between January and December 2025. Clinical presentation, imaging, intra-operative findings, surgical approach, histopathology, peri-operative complications, and renal outcomes were reviewed. All cases were discussed within a specialist multidisciplinary endometriosis meeting. Pre-operative assessment included pelvic MRI with selective CT urogram utilisation. Renal function was assessed using serum creatinine and radiological evaluation of hydronephrosis.

Results

Fifteen patients were included with a mean age of 41.1 years. All patients presented with chronic pelvic pain and 80% had previous pelvic surgery. MRI identified ureteric involvement pre-operatively in only 20% of cases. Intra-operatively, extrinsic peri-ureteric fibrosis predominated, with bilateral disease identified in 66.7% of patients. All patients underwent ureterolysis-based surgery. Surgical management was laparoscopic in 73.3%, robotic in 20%, and open in 6.7%, with minimally invasive techniques utilised in 93.3% overall. One patient required nephrectomy secondary to severe renal compromise. Histopathology confirmed endometriosis in 86.7% of cases. Early postoperative complications occurred in three patients, including one Clavien–Dindo IIIb complication. Renal function improved in four patients and remained stable in the remainder.

Conclusions

Extrinsic peri-ureteric endometriosis frequently remains under-recognised prior to surgery despite advanced imaging. MDT-led minimally invasive ureterolysis-based management enables effective renal preservation with acceptable morbidity and favourable functional outcomes. Early recognition and anatomy-driven multidisciplinary surgery remain essential in preventing irreversible renal compromise in advanced endometriosis.

ESGE35-0975 - P160
ePoster Presentations

Ureteral Endometriosis: A Case of Silent Renal Function Loss

Nazlı Bozkurt[1], Ali Akdemir[2]
[1]Ege University Faculty of Medicine, Department of Obstetrics and Gynaecology, Izmir, Türkiye
[2]Ege University Faculty of Medicine, Gynaecology and Obstetrics, Izmir, Türkiye

Background

Ureteral endometriosis is a rare but potentially severe manifestation of deep infiltrating endometriosis. Because it may remain asymptomatic for a prolonged period, delayed diagnosis can result in irreversible renal function loss. We present a case of silent renal loss secondary to ureteral endometriosis managed laparoscopically.

Methods

A 39-year-old woman with known endometriosis presented with severe dysmenorrhea, dyspareunia, and chronic pelvic pain. Preoperative evaluation demonstrated severe left hydroureteronephrosis with complete loss of left renal function. Laparoscopic surgery was performed, including bilateral ureterolysis, excision of deep infiltrating endometriosis, restoration of the pararectal and prerectal spaces, resection of endometriotic nodules, and salpingectomy for hydrosalpinx.

Results

Intraoperatively, extensive deep infiltrating endometriosis involving both pelvic sidewalls and severe left ureteral obstruction were identified. The left ureter was completely encased by endometriotic tissue, explaining the loss of renal function. Complete excision of visible endometriotic lesions and bilateral ureterolysis were achieved. At six months of follow-up, the patient reported complete symptomatic relief with resolution of pelvic pain.

Conclusions

Ureteral endometriosis may remain clinically silent despite advanced urinary tract involvement and irreversible renal damage. Early recognition and timely surgical management are essential to preserve renal function and prevent disease progression.

ESGE35-0977 - P161
ePoster Presentations

Twisted Malignancy: Pre-operative MRI Diagnosis of Uterine Torsion Revealing High-Grade Epithelioid Angiosarcoma Arising in a Leiomyoma

Saima Farooq[1], Assma Eshaq[1], Aayushi Pandya[1], Peter Wylie[1]
[1]Royal Free Hospital, Gynaecology, LONDON, United Kingdom

Aim

Uterine torsion in non-pregnant women is exceptionally rare and is most commonly associated with large leiomyomas. Primary uterine angiosarcoma is an exceedingly uncommon and highly aggressive malignancy, with very few cases reported in the literature. We present a unique case in which pre-operative MRI identified uterine torsion within a large presumed fibroid uterus, with final pathology demonstrating high-grade epithelioid angiosarcoma arising in association with a leiomyoma.

Background

Uterine torsion in non-pregnant women is exceptionally rare and is most commonly associated with large leiomyomas. Primary uterine angiosarcoma is an exceedingly uncommon and highly aggressive malignancy, with very few cases reported in the literature. We present a unique case in which pre-operative MRI identified uterine torsion within a large presumed fibroid uterus, with final pathology demonstrating high-grade epithelioid angiosarcoma arising in association with a leiomyoma.

Materials / Patients

Case Presentation A: 74-year-old postmenopausal woman presented with worsening abdominal pain, bloating, and a palpable abdominal mass. Ultrasound demonstrated an enlarged fibroid uterus with adenomyosis, a thickened postmenopausal endometrium, and a large right-sided cystic lesion thought to represent an endometrioma. CT imaging revealed a highly vascular heterogeneous 20 cm pelvic mass of likely uterine origin, raising concern for underlying malignancy. MRI demonstrated a grossly enlarged uterus measuring approximately 20 cm with a definite rotational component at the uterocervical junction. Associated findings included distortion of pelvic vascular anatomy, venous congestion, haemorrhagic change within the lesion, restricted diffusion, and compression of adjacent pelvic vessels. MDT review favoured uterine torsion involving a large pedunculated fibroid, although sarcoma could not be excluded. The patient underwent urgent total abdominal hysterectomy with bilateral salpingo-oophorectomy. Intra-operatively, uterine torsion with a large necrotic uterine mass was confirmed. Histopathological examination demonstrated a large tumour with extensive haemorrhage and necrosis arising in close association with a leiomyoma. Initial pathology raised concern for a high-grade uterine sarcoma, prompting referral to a tertiary sarcoma centre. Specialist review subsequently confirmed grade 3 epithelioid angiosarcoma arising within a leiomyoma

Methods / Results

This case highlights the diagnostic challenge posed by large pelvic masses in postmenopausal women and demonstrates the value of MRI in identifying uterine torsion pre-operatively. Although torsion of a fibroid uterus is rare, underlying malignancy should remain an important differential diagnosis

when atypical radiological features are present. To our knowledge, the combination of pre-operatively diagnosed uterine torsion and uterine epithelioid angiosarcoma arising within a leiomyoma is exceptionally uncommon.

Discussion

As above

Conclusion

As above

Impact on Patients' Health

As above

ESGE35-0987 - P163
ePoster Presentations

Clinical and demographic characteristics and FIGO stage distribution patterns of childhood cervical cancer patients

Konul Mardanova[1]
[1]*National Oncology Center, Department of Diagnosis and Treatment of Precancerous Diseases, Baku, Azerbaijan*

Background

Cervical cancer (CC) remains one of the most prevalent malignant tumors among women worldwide. Investigating the clinical and demographic factors that influence disease stage is of great importance for optimizing prevention and early detection programs. To analyze the relationship between clinical and demographic characteristics of cervical cancer patients and their disease stage according to the FIGO classification.

Methods

A retrospective analysis was conducted on 116 cervical cancer patients treated at the National Oncology Center between 2017 and 2020. Clinical variables (age, histological type, treatment modality) and demographic data (residence area) were collected, and staging was performed based on the FIGO 2018 classification system. Statistical analyses were carried out using IBM SPSS Statistics version 26.0, with a significance level of $p<0.05$.

Results

The mean age of patients was 52.3 ± 10.7 years. With increasing age, the proportion of patients diagnosed at advanced stages also increased. Among urban residents, early-stage disease (I–II) accounted for 62.5% of cases, whereas in rural regions, advanced stages (III–IV) predominated at 55.9%. Squamous cell carcinoma (SCC) was mostly detected in advanced stages, while adenocarcinoma (AC) was relatively more common in early stages. Surgical treatment predominated in early stages (66.7%), whereas combined chemoradiotherapy and tri-modal approaches were more frequent in advanced stages

Conclusions

A statistically significant relationship was observed between the FIGO stage of cervical cancer and clinical–demographic parameters. Age and place of residence significantly influenced stage distribution. Early detection was more frequent among urban residents, while advanced stages were more prevalent among rural and elderly populations. These findings highlight the need to expand screening programs in regional areas and to implement individualized treatment strategies tailored to histological and demographic profiles.

ESGE35-1003 - P165
ePoster Presentations

Radiofrequency Myolysis Followed by Intrauterine Mechanical Shaving: An Advanced Fertility-Sparing Strategy for FIGO 2 Fibroids

Elena Iuliana Anamaria Berbecaru[1,2], George Lucian Zorila[1,2], Anca-Maria Istrate-Ofiteru[2,3], Roxana Dragusin[1,2], Dominic Gabriel Iliescu[1,2]
[1]Univeristy of Medicine and Pharmacy of Craiova, Obstetrics and Gynaecology, Craiova, Romania
[2]Clinical County Hospital of Craiova, Obstetrics and Gynaecology, Craiova, Romania
[3]University of Medicine and Pharmacy of Craiova, Histology, Craiova, Romania

Background

Submucosal and transitional uterine fibroids (FIGO type 2) are an important cause of menometrorrhagia and subfertility in reproductive-aged women. Conventional resectoscopic myomectomy often requires extensive cervical dilation and prolonged use of thermal energy, increasing the risk of cervical incompetence and intrauterine adhesions. We describe a two-step, fertility-preserving technique combining radiofrequency (RF) myolysis with intrauterine mechanical morcellation to optimize fibroid removal while minimizing mechanical and thermal trauma.

Methods

A 26-year-old nulliparous woman presented with menometrorrhagia and iron-deficiency anaemia due to a symptomatic FIGO type 2 submucosal fibroid. To preserve her reproductive potential, a tailored two-step procedure was performed under intravenous anesthesia. In the first phase (15 minutes), targeted RF myolysis was applied to the fibroid to induce coagulative necrosis, reduce lesion vascularity, and decrease tissue density and volume. In the second phase (15 minutes), the remodelled fibroid was extracted using an intrauterine mechanical morcellation (shaver) system, which allowed continuous fluid-medium visualization without the need for extensive cervical dilation, due to its small outer diameter, and without applying thermal energy to the surrounding endometrium.

Results

The combined procedure (total operative time 30 minutes) was completed without intraoperative or postoperative complications. The mechanical morcellation system allowed fibroid tissue to be simultaneously fragmented and evacuated under continuous high-definition visualization, with stable intrauterine pressure throughout the procedure. At the 6-month follow-up, the patient reported complete resolution of menometrorrhagia and a normalized menstrual cycle. Transvaginal ultrasound confirmed an intact, regular endometrial lining with no evidence of intrauterine synechiae.

Conclusions

The sequential combination of RF myolysis and mechanical intrauterine morcellation offers a fertility-sparing alternative for the management of FIGO type 2 submucosal fibroids. By avoiding thermal injury to the endometrium and reducing the need for cervical dilation, this approach may help limit the risk of cervical incompetence and postoperative intrauterine adhesions.

ESGE35-1004 - P166
ePoster Presentations

Preserving the Myometrium, Restoring Fertility: The Clinical Efficacy of Radiofrequency Ablation in Adenomyosis

Elena Iuliana Anamaria Berbecaru[1,2], *George Lucian Zorila*[1,2], *Anca Maria Istrate Ofiteru*[2,3], *Roxana Dragusin*[1,2], *Dominic Gabriel Iliescu*[1,2]
[1]*University of Medicine and Pharmacy of Craiova, Obstetrics and Gynaecology, Craiova, Romania*
[2]*Clinical County Hospital of Craiova, Obstetrics and Gynaecology, Craiova, Romania*
[3]*University of Medicine and Pharmacy of Craiova, Histology, Craiova, Romania*

Background

Adenomyosis is a common cause of dysmenorrhea, heavy menstrual bleeding, and subfertility in women of reproductive age, and management is often constrained by the desire to preserve fertility, which precludes radical surgery or extensive myometrial excision. Radiofrequency ablation (RFA) has emerged as a minimally invasive, uterine-sparing alternative for thermal myolysis. We describe two cases illustrating the clinical application of RFA in adenomyosis: one with focal disease presenting with heavy menstrual bleeding and dysmenorrhea, and the other with diffuse disease presenting with dysmenorrhea, heavy menstrual bleeding, and secondary infertility.

Methods

Two reproductive-aged women with symptomatic adenomyosis underwent ultrasound-guided RFA. The first was a 28-year-old nulliparous woman with a focal adenomyotic lesion measuring 2.3 cm, presenting with severe dysmenorrhea (visual analogue scale 8/10) and heavy menometrorrhagia (pictorial blood loss assessment chart score >150). The second was a 30-year-old woman with diffuse adenomyosis and an enlarged uterus (estimated volume 182 cm^3), presenting with dysmenorrhea, heavy menstrual bleeding, and a 3-year history of secondary infertility, in whom other infertility factors had been excluded or optimized. In both cases, RFA was performed under ultrasound guidance, with energy delivered either directly into the focal lesion or systematically across multiple affected myometrial zones, depending on lesion distribution, while preserving surrounding healthy myometrium. Procedure time was approximately 30–40 minutes per case, performed under conscious sedation or general anesthesia. Clinical and ultrasound re-evaluation was performed at 3 and 6 months postoperatively.

Results

Both procedures were completed without intraoperative or postoperative complications. At 6-month follow-up, both patients reported resolution of dysmenorrhea (visual analogue scale reduced to 1/10) and normalization of menstrual flow (pictorial blood loss assessment chart score <100). Transvaginal ultrasound showed a reduction in lesion volume of approximately 50%, with improved myometrial echo-architecture in both cases and a decrease in overall uterine volume in the second patient to approximately 130 cm^3. The second patient, previously infertile for 3 years, achieved a spontaneous pregnancy approximately 5 months after the procedure, with an ongoing, uncomplicated course at the time of reporting.

Conclusions

In these two cases, radiofrequency ablation provided effective symptom control, measurable myometrial volume reduction, and favourable remodelling in both focal and diffuse adenomyosis, without compromising uterine integrity. The resolution of pain and bleeding alongside the spontaneous pregnancy in the second patient suggests a possible role for RFA in improving both symptomatic and fertility outcomes in selected patients with adenomyosis, though this observation requires confirmation in larger series.

ESGE35-0021 - P167
ePoster Presentations

Beyond Mesh: Comparison of Mesh-Free Sacropexy Techniques for Pelvic Organ Prolapse

Paola Mete[1], Manuela Maletta[2], Mariangela Frascella[2], Diego Raimondo[2], Renato Seracchioli[2]
[1]IRCCS Azienda Ospedaliero-Universitaria di Bologna,
Department of Gynaecology and Human Reproduction Physiopathology, Bologna, Italy
[2]IRCCS Azienda Ospedaliero-Universitaria di Bologna,
Department of Gynaecology and Human Reproduction Physiopathology, Bologna, Italy

Background

To compare long-term recurrence outcomes of three laparoscopic mesh-free sacropexy procedures performed according to the Bologna technique using Ti-Cron™ sutures, and to identify predictors of recurrence.

Methods

This was an observational retrospective cohort study conducted at a tertiary referral hospital. Consecutive patients with pelvic organ prolapse stage ≥2 according to the Pelvic Organ Prolapse Quantification (POP-Q) system, who underwent laparoscopic sacropexy without mesh between January 1, 2011, and December 31, 2021 were included. Exclusion criteria were age >80 years, previous prolapse surgery, and lack of follow-up data. Procedures were classified into three surgical subgroups: hysterosacropexy (LSHP), cervicosacropexy (LSCP), and colposacropexy (LScP). In all cases, a Ti-Cron™ suture was anchored to the anterior longitudinal ligament of the sacrum, the right uterosacral ligament was progressively plicated, and the suture was incorporated into the uterus, cervix, or vaginal vault according to the procedure, and tied in a tension-free manner to achieve adequate apical suspension.

Results

A total of 81 patients were included: 12 (15%) in the LSHP group, 48 (59%) in the LSCP group, and 21 (26%) in the LScP group. In multivariable Cox regression analysis, LSHP was independently associated with a significantly lower risk of objective recurrence compared with LSCP. Advanced prolapse (POP-Q stage IV) was identified as an independent predictor of recurrence, while no other clinical or surgical variables were significantly associated with objective recurrence-free survival. Postoperative anatomical outcomes were comparable across groups, with greater anterior and apical compartment improvement observed in LSCP patients without recurrence. Patient-reported outcomes significantly improved in all groups, with reductions in POPDI-6, UDI-6, and PFDI-20 scores. Subjective recurrence-free survival showed similar trends across surgical approaches.

Conclusions

In an aging population with increasing demand for pelvic organ prolapse surgery, laparoscopic hysterosacropexy using non-absorbable braided polyester sutures appears to be an effective minimally invasive alternative to mesh-based sacropexy, with a low risk of prolapse recurrence. Larger prospective studies are warranted to confirm these findings.

ESGE35-0024 - P168
ePoster Presentations

Fast Discharge eligibility for benign robotic assisted Hysterectomy

Felix Neis[1], *Cosima Brucker*[2], *Bernhard Kraemer*[1]
[1]*University of Tübingen, Gynaecology and Obstetrics, Tübingen, Germany*
[2]*Klinikum Nuernberg, Department of Gynaecology, Nürnberg, Germany*

Background

Robotic surgery has become an integral part of routine gynecological practice. Regulatory requirements are mandating increasingly shorter postoperative hospital stays. As part of the GENERATE study, we conducted a detailed analysis of the timing of discharge for hysterectomies performed for benign indications.

Methods

In this multicentre, post-market, non-interventional study, the conditions for early discharge following robot-assisted (DaVinci) total laparoscopic hysterectomy for benign indications were analysed. Patients were divided into 4 groups based on discharge timing (0–2 days, 3 days, 4 days, ≥ 5 days).

Results

The most common surgical indication in all groups was uterine fibroids, followed by bleeding disorders and endometriosis. Patients with a longer hospital stay were older, had a higher Charlson Comorbidity Index, and experienced longer operative times, including longer console times. Pain scores showed no differences in the first 3 days. Adverse events occurred more frequently in the groups starting from 4 days, while serious adverse events were evenly distributed. Most complications occurred postoperatively (36/39; 92.3%). In six cases (17%), surgical interventions (Clavien-Dindo Grade III) were necessary.

Conclusions

Advanced age, longer surgical times, and comorbidities appear to be factors contributing to a longer hospital stay following robotic hysterectomy. By taking age and the Charlson Comorbidity Index into account, inpatient capacity can be planned preoperatively prior to robotic hysterectomy. Scarce inpatient hospital resources can thus be utilized more effectively.

ESGE35-0042 - P169
ePoster Presentations

Suture material and its association with vault dehiscence in minimal access surgery- a meta analysis

Kalaivani Ramalingam[1], Akshaya Gopinath[2], Pranav Rajasekaran[3]
[1]Medical Specialist Group- Guernsey, Obstetrics and Gynaecology, Guernsey, United Kingdom
[2]University of East Anglia, Medical student, Norwich, United Kingdom
[3]Stanley Medical College, Medical student, Chennai, India

Background

Vaginal vault closure is an important part of minimally invasive hysterectomy by the laparoscopic or robotic route. The choice of the suture material used for vaginal cuff closure after a total hysterectomy has been the object of discussion over the recent years. There are increasing options in suture material availability across the world. The choices depend on the surgeon's preference, training and local availability depending on unit practice. it will be interesting to evaluate the existing evidence on this topic. Vault dehiscence is a feared complication that may present as an acute surgical complication. This analysis evaluates the role of the type of the suture used on the incidence of vault dehiscence along with the technique of closure, route- laparoscopic/transvaginal, continuous or interrupted and intra or extracorporeal knotting were assessed.

Methods

A review of studies involving reported outcomes after type of suture for vaginal cuff closure was done. MESH- Medical subheadings- vaginal dehiscence, vaginal cuff closure, suture material in laparoscopy/robotic hysterectomy were used to identify studies from the medical databases over the past 20 years. The agreed qualifying criteria were applied to evaluate the studies for inclusion in the analysis. A CONSORT was used for the study inclusion. Th qualifying studies were analysed for the association of the relevant suture material and the incidence of vault dehiscence. 3 randomised controlled trials were available on the subject, 5 meta analyses and 30 studies were considered for the analysis.

Results

The lowest incidence of VCD(vaginal cuff dehiscence) was for the barbed suture PDS monofilament at 0.4%. The highest incidence was for chromic catgut. Inadequate data was available for Poliglecaprone. The incidence was 1% for polydioxanone and 2% for polyglactin. The single layer technique was acceptable in outcomes without increasing surgical time involving a double layer technique. The OR of laparoscopic closure and VCD was 0.33-0.97. Transvaginal closure had a higher incidence of VCD at 2.3% vs 1.1.6% Continuous barbed closure was more favourable for closure. The intracorporeal technique preserved a longer vaginal length with netter vault support though more technically demanding.

Conclusions

The incidence of vault cuff dehiscence was lower with use of continuous barbed closure at 0.35- 4% compared to 0.6-2% with convention suture. Similarly, robotic assisted incidences were 0.7-1% for

barbed suture compared to 1.645 for conventional sutures. The barbed sutures were self-retaining and knotless and conventional sutures- required a longer time needed for knotting during surgery.

ESGE35-0059 - P170
ePoster Presentations

New (robot) instruments for MIC: Transitioning from disposable to reusable design for improved sustainability

Frank Willem Jansen[1], *Storm Chabot*[2], *Leo Simon*[2], *Blikkendaal Mathijs*[3], *Tim Horeman*[2]
[1]*Leiden University medical center & TU Delft, Gynaecology, Leiden, The Netherlands*
[2]*Technical University Delft, BioMechanical Engineering, Delft, The Netherlands*
[3]*Reinier de Graaf Gasthuis, Dutch Endometriosis Clinic, Delft, The Netherlands*

Background

The implementation of novel surgical techniques is commonly associated with increased use of single-use medical devices. Over the past decade, a shift of approximately 60% from reusable to disposable instruments has been observed. This transition has contributed to a significant increase in medical waste and to the overall carbon footprint of healthcare, which is in general estimated to account for 4–7% of global CO_2 emissions. These trends highlight the need for the integration of sustainability principles into medical device design.

Methods

As a counter movement, a new design approach was used to conduct two engineering design studies based on a new modular reusable platform for advanced laparoscopy : 1. Development of a robust steerable, modular, reusable laparoscopic instrument line.
2. Design of a modular robotic surgical platform with interchangeable options.

Environmental impact was assessed using comparative metrics, including CO_2-equivalent emissions and energy consumption.

Results

Both designs met predefined technical and sustainability criteria and are suitable for further translational development.

The shaft-articulating reusable laparoscopic instrument (video shown) has modular features for forceps, scissors and coagulation options. It demonstrated a 58.4% reduction in CO_2-equivalent emissions and a 62.0% reduction in energy consumption compared with a functionally equivalent disposable instrument. The force feedback options were also measured and are comparable with the single-use instruments.

The AdLap project introduced a novel robotic instrumentation platform (video shown), incorporating a transition from cable-based to shaft-based architecture to facilitate repeated (unlimited) reuse. The system additionally supports bidirectional conversion between robotic-assisted and conventional minimally invasive surgery (MIS). This approach resulted in a 32% reduction in CO_2 footprint at the instrument level. Energy level reduction is still under construct.

Conclusions

The findings indicate that engineering-driven (re)design of surgical instruments, aligned with clinical requirements, can substantially reduce the environmental impact of MIS. Reusable systems demonstrate superior sustainability performance relative to single-use alternatives, primarily due to reduced material extraction and manufacturing burdens. Both, in the context of sustainable (robotic) surgery, the proposed design also offers potential economic advantages through extended instrument lifespan and operational flexibility.

In conclusion, the transition from disposable to reusable surgical instrumentation represents a feasible and effective strategy to mitigate the environmental impact of surgical care. Future performance is contingent upon optimization of reprocessing protocols and validation under real-world clinical conditions. This opens the path toward the development of a "waste-free" surgical (robotic) platform, enabling hospitals worldwide to access sustainable surgical technology that meets both global and environmental demands.

ESGE35-0128 - P171
ePoster Presentations

Feasibility and Safety of Hysteroscopically Guided Core Needle Biopsy for Uterine Leiomyomas: A Proof-of-Concept Study

Jaroslaw Sprawka[1], Paulina Dabrowska[1], Rafal Karwowski[1], Kamila Goledowska[1], Weronika Mydlinska[1], Grzegorz Szewczyk[1]
[1]St. John Paul II Mazovian Regional Hospital, Department of Obstetrics- Gynaecology and Gynecological Oncology, Siedlce, Poland

Background

While ultrasound-guided core needle biopsy of uterine fibroids is well-documented, direct hysteroscopic guidance represents a novel and less-investigated approach. This study aims to evaluate the technical feasibility and safety profile of hysteroscopically guided core needle biopsy for obtaining definitive histopathological diagnoses of suspected leiomyomas. The primary objective is the preoperative exclusion of atypia or occult malignancy to optimize clinical decision-making. Confirmation of benignity facilitates either conservative management for patients seeking to avoid intervention or the safe implementation of minimally invasive techniques, such as laparoscopic supracervical hysterectomy utilizing morcellation.

Methods

This preliminary proof-of-concept study enrolled 14 patients presenting with symptomatic uterine leiomyomas, specifically targeting lesions classified as FIGO types 3 to 5. Preoperative sonographic mapping was performed to ensure precise topographical localization of the lesions. All procedures were performed under total intravenous anaesthesia (TIVA). Following hysteroscopic access to the uterine cavity, a core biopsy needle was introduced alongside the hysteroscopic optic. Targeted biopsies were then performed under direct visualization. The primary endpoints included technical feasibility, diagnostic yield of the obtained specimens, procedural safety profile, and the subsequent impact on clinical management pathways.

Results

The hysteroscopic biopsy procedure was technically successful and yielded a definitive histopathological result of benign leiomyoma without atypia in 13 out of 14 patients. Only one case resulted in an inconclusive biopsy due to an insufficient tissue sample. No intraoperative or postoperative complications were observed during the study period. The histological confirmation successfully guided clinical management, allowing patients to be stratified into two distinct pathways. One cohort successfully concluded their medical process with clinical reassurance and completely avoided surgical intervention. The remaining patients safely underwent minimally invasive procedures without compromising oncological outcomes.

Conclusions

Hysteroscopically guided core needle biopsy represents a novel, feasible, and safe approach for the direct histopathological assessment of uterine fibroids. By providing reliable preoperative exclusion of

occult malignancy, this technique allows a subset of patients to safely avoid surgical intervention and facilitates a tailored, minimally invasive approach in those requiring surgery.

ESGE35-0302 - P172
ePoster Presentations

Hysteroscopic Resection and Post-treatment Management of Endometrial Tuberculosis: A Video Case Presentation

Zeynep Umay Gürbüz[1], Defne Ceylin Gürbüz[2], Ali Sami Gurbuz[3]
[1]Medical School of Koç University, Obstetrics and Gynaecology, Istanbul, Türkiye
[2]Istinye University, Obstetrics and Gynaecology, Konya, Türkiye
[3]Novafertil IVF Center, Obstetrics and Gynaecology, Konya, Türkiye

Background

Genital tuberculosis is one of the common forms of extrapulmonary tuberculosis and an important cause of infertility due to damage to the fallopian tubes and endometrium. We present the hysteroscopic findings, surgical management, and post-treatment course of a histopathologically confirmed case of endometrial tuberculosis complicated by intrauterine adhesions.

Methods

A 32-year-old woman with primary infertility, previously treated with two failed intrauterine insemination cycles and three IVF attempts, presented to our clinic for transfer of two frozen embryos remaining from her last IVF cycle. Initial transvaginal ultrasonography demonstrated irregular endometrium, prompting office hysteroscopy using a 6-mm Endotouch hysteroscope for further evaluation of the uterine cavity.

Results

Hysteroscopic examination revealed a thin, atrophic endometrium with multiple diffuse micropolypoid lesions throughout the uterine cavity. Scattered whitish-yellow nodules, abnormal vascular patterns, fibrotic bands, and small calcifications were observed on the endometrial surface. These lesions were resected hysteroscopically using shaving technique. Histopathological evaluation confirmed granulomatous endometritis consistent with tuberculosis. Further history revealed a family history of tuberculosis and a severe febrile illness with abdominal pain and significant uterine bleeding at age 16. On follow up, ultrasonographic evaluation demonstrated intrauterine adhesions, and second-look hysteroscopy was performed using a 15 Fr mini-resectoscope for adhesiolysis. Intrauterine hyaluronic acid gel and postoperative estrogen therapy were administered to reduce re-adhesion risk. Embryo transfer was subsequently performed; however, pregnancy was not achieved.

Conclusions

The hysteroscopic appearance of endometrial tuberculosis is highly variable and often non-specific. Findings such as yellow nodules, micropolypoid lesions, adhesions, and abnormal vascularity may raise suspicion, but no single feature is pathognomonic. Hysteroscopy plays a critical role in direct lesion visualization, targeted biopsy, and therapeutic intervention. Recognition of suspicious hysteroscopic findings and prompt histopathological confirmation are essential for accurate diagnosis and appropriate fertility-oriented management.

ESGE35-0228 - P173
ePoster Presentations

Comparative Analysis of Laparoscopic and Laparotomic Surgical Approaches in Early-Stage Ovarian Cancer: A Turkish Multi-Center Study Design on Oncological Safety and Surgical Quality (Tr-Migs)

Lena Türeyici[1], Atahan Toyran[2], Mehmet Ali Vardar[3]
[1]Ege University Faculty of Medicine, Gynecological Oncology, Izmir, Türkiye
[2]Istanbul University Faculty of Medicine, Gynecological Oncology, İstanbul, Türkiye
[3]Cukurova University Faculty of Medicine, Gynecological Oncology, Adana, Türkiye

Background

Ovarian cancer remains one of the most challenging malignancies in gynecologic oncology. The limited availability of early detection methods leads to 70–80% of patients being diagnosed at an advanced stage (Stage III-IV). While five-year survival rates for patients with early-stage disease (Stage I and II) range between 80% and 95%, the cornerstone of this success is 'accurate and comprehensive surgical staging'.
The majority of ovarian cancer patients present with advanced-stage disease, which has historically directed surgical strategies toward extensive laparotomies and maximal cytoreduction. The standard of care has traditionally involved comprehensive surgical staging via a midline laparotomy, total abdominal hysterectomy, bilateral salpingo-oophorectomy, omentectomy, peritoneal biopsies, and systematic pelvic and para-aortic lymphadenectomy. With the advancements in minimally invasive surgery (MIS) over the past two decades, the feasibility and safety of performing these comprehensive procedures laparoscopically have become a major focus in gynecologic oncology. Current literature highlights significant perioperative benefits of the laparoscopic approach, including reduced blood loss, shorter hospital stays, and a more rapid initiation of adjuvant chemotherapy.

In this study, our objective is to evaluate the oncological safety, surgical quality parameters, and recovery times of the laparoscopic approach compared to laparotomy in patients who underwent surgical staging with a diagnosis of apparent early-stage (FIGO Stage I-II) ovarian cancer, using data from high-volume centres representing the gynecological oncology patient population in Türkiye.

Methods

The study we will conduct is a retrospective observational study to be carried out with the participation of 12 gynecologic oncology centres from different geographical regions where the highest gynecologic oncology patient populations in Turkey are located. Patients over 18 years of age who have a suspicion of malignancy based on preoperative imaging (USG, MRI/CT) and tumor markers (IOTA/RMI) but whose mass is confined to the pelvis (apparent Stage I-II), and who have histologically confirmed ovarian cancer will be included in our study, whereas borderline ovarian tumors, those with clear imaging findings of Stage III or IV, and those whose primary surgery was performed in another center and whose data are inaccessible will be excluded.

Results

Expected Results

This large-scale national database will reflect the current status of gynecologic oncology practice in Türkiye and provide strong evidence regarding the reliability of minimally invasive surgery in early-stage ovarian cancer. The results of the study will assist in identifying surgical strategies that increase patient comfort without compromising oncological safety.

Conclusions

This national multi-center study will provide robust real-world evidence reflecting the current landscape of minimally invasive staging in early-stage ovarian cancer in Türkiye. The final outcomes will assist in refining surgical strategies to optimize patient recovery and comfort without compromising oncological safety, ultimately contributing to the standardization of surgical training and clinical practice.

ESGE35-0259 - P175
ePoster Presentations

Development of an assessment scale for vaginally assisted NOTES hysterectomy (VANH): A delphi consensus among international experts

Rebecca Henschen[1], Emma Ricour[2], Jan Baekelandt[3], Andrea Stuart[4], Martine Wassen[1], Patrice Crochet[2]
[1]Zuyderland Medical Center, Gynaecology and Obstetrics, Heerlen, The Netherlands
[2]Charles Nicolle Hospital, Gynaecology and Obstetrics, Rouen, France
[3]Imelda Hospital, Gynaecology and Obstetrics, Bonheiden, Belgium
[4]Helsingborg Hospital, Gynaecology and Obstetrics, Helsingborg, Sweden

Background

The adoption of vaginal natural orifice transluminal surgery (vNOTES) is increasing, supported by evidence of its safety, feasibility and clinical benefits. Successful implementation requires a structured training, appropriate surgical skills, and careful patient selection. Currently, standardized assessment tools and validated scoring systems for vNOTES are lacking. This study aimed to establish expert consensus on the essential procedural steps to be included in a structured scale for assessing surgical skills in low-complexity Vaginally Assisted NOTES Hysterectomy (VANH).

Methods

A two round Delphi study was conducted from November 2024 to December 2025 involving 20 vNOTES experts from 14 countries. A questionnaire was developed based on a hierarchical task analysis and literature. This questionnaire was divided into three parts: (A) vaginal access, (B) endoscopic and (C) specimen retrieval and vaginal closure. Each part was further broken down into phases and steps, which were rated for inclusion into the final scale using a five-point Likert scale (1: not relevant to 5: very relevant). Panelists could provide feedback and proposal for rewording after each round. The consensus rate threshold was 70%. For each step included in the final scale, performance anchors were constructed according to three predefined levels of competence: incompetent, just competent, and highly proficient.

Results

A total of 52 steps were submitted to the Delphi panel at the first round. The final assessment scale comprised 12 phases (6 in part A, 4 in part B and 2 in part C), covering 37 procedural steps for a VANH. Additionally, five steps for salpingectomy and three steps for salpingo-oophorectomy were included.

Conclusions

This study presents the first international consensus on a structured assessment scale for low-complexity VANH. This scale represents an important step toward standardized training, objective skill assessment and safer clinical implementation of vNOTES. Further studies are required to establish evidence of feasibility and validity, both in simulation models and in the operating room.

ESGE35-0211 - P176
ePoster Presentations

Preoperative Ischemic Stroke During Deep Infiltrative Endometriosis Resection

Asli Yarci Gursoy[1], Damla Özdemir[2], Züleyha Kazak Bengisun[3], Refah Sayın[4], Gamze Yurdakan Ozyardımcı[5], Polat Dursun[2]
[1]Ufuk University Faculty of Medicine, Obstetrics and Gynaecology, Ankara, Türkiye
[2]Ufuk University, Gynecologic Oncology, Ankara, Türkiye
[3]Ufuk University, Department of Anaesthesiology and Reanimation, Ankara, Türkiye
[4]Ufuk University, Department of Neurology, Ankara, Türkiye
[5]Ufuk University, Department of Pathology, Ankara, Türkiye

Background

This case report aims to delineate a rare and severe arterial complication following surgical intervention for deep infiltrative endometriosis (DIE). We emphasize the necessity for heightened clinical vigilance and comprehensive preoperative counselling regarding vascular risks in endometriosis related surgeries.

Methods

A 44-year-old patient (G1P1) presented with refractory chronic pelvic pain (CPP) and a prior diagnosis of **deep infiltrative endometriosis (DIE)**. Her surgical history was notable for a total abdominal hysterectomy and bilateral salpingectomy performed four years earlier for CPP. Despite a subsequent six-month course of **GnRH agonist** therapy, symptoms recurred immediately upon treatment cessation. The patient also reported persistent diarrhoea since her initial surgery. No personal or familial history of thrombophilia or cardiovascular disease was identified.

Physical examination revealed acute tenderness localized to the left lateral vaginal vault. While transvaginal ultrasonography (TV-USG) showed bilateral non-vascular ovarian cysts (1.5 cm right; 3 cm left), contrast-enhanced MRI identified a **2 cm DIE nodule** involving the vaginal cuff, left sacrouterine ligament, and the caudal pole of the left ovary. The lesion was fixed to the rectum over a 1.5 cm area but remained distinct from the left sacral plexus.

Given the refractory symptoms, the patient underwent an exploratory laparotomy for nodule excision and bilateral oophorectomy. Intraoperatively, dense adhesions were dissected within the left pelvic fossa. The rectal nodule was excised via sharp dissection, and rectal integrity was confirmed with a negative bubble test. Total operative time was 1.5 hours.

During immediate postoperative recovery, the patient developed acute neurological deficits, including facial palsy and progressive motor impairment of the unilateral extremities. Following MRI confirmation of an **ischemic stroke**, therapeutic-dose low-molecular-weight heparin (LMWH) was initiated. Although emergent cerebral angiography at a tertiary center revealed no acute thrombotic lesions, a 2/5 motor deficit persisted on the right side.

After 48 hours of ICU observation, the patient was transferred to the inpatient ward, where an **intra-abdominal hematoma** was identified. This was presumed to be secondary to the immediate

postoperative anticoagulation. Management included broad-spectrum antibiotics and red blood cell (RBC) replacement. A comprehensive thrombophilia workup, encompassing both hereditary and acquired etiologies, was unremarkable. The patient stabilized and was discharged on the eighth postoperative day for structured physiotherapy.

Results

The patient is currently participating in a physical rehabilitation program, with clinical expectations for maximal functional recovery.

Conclusions

Endometriosis and its surgical management may increase the risk of both venous and arterial vascular complications. Clinicians must address these potential risks during preoperative counselling and maintain high suspicion for neurological events in the perioperative period.

ESGE35-0218 - P179
ePoster Presentations

A standardized technique of Laparoscopic Hysterectomy without Uterine Manipulator. Large-Scale Surgical Experience and Clinical Outcomes

Dimitrios Zygouris[1], Antonis Gkoutzioulis[1], Panagiotis Papandreou[1], Stergios Kopatsaris[2], Dimitris Grigoriou[3], Andreas Kavallaris[1,3]
[1]St. Luke's Hospital- Thessaloniki- Greece,
Department of Gynecologic Oncology and Minimally invasive surgery, Thessaloniki, Greece
[2]Marienhospital Bottrop- Bottrop- Germany, Department of Gynaecology and Obstetrics, Bottrop, Germany
[3]Mother and child medical center- Nicosia- Cyprus,
Department of Gynecologic Oncology and Minimally invasive surgery, Nicosia, Cyprus

Background

This is a retrospective study aiming to evaluate the feasibility and safety of Total Laparoscopic Hysterectomy (TLH) without manipulator or any kind of vaginal tube. The We present our data on m intra-operative and post-operative morbidity.

Methods

Between January 2011 and January 2026, we performed 2.321 Total Laparoscopic Hysterectomies, without using any kind of uterine manipulator in women with benign indications for hysterectomy. The procedure is performed in a standardized way, as is previously described. All operations were performed by the same surgical team.

Results

The average age was 52.9 years and BMI 27.6 kg/m^2, while the mean operative time was 76 min (41-186 min), the estimated blood loss was 53 mL (20-279 ml) and the mean uterine weight was 272 g (40-1690 g). There was no case of conversion to laparotomy. A blood transfusion was required for 31 patients (1.3 %), while there was one case of ureteral injury and four cases where the bladder was opened and fixed laparoscopically. The average hospital stay was 1.2 days, with only 56 patients staying for two or more days. In the long term follow up, we had 10 cases (0.4 %) of vaginal vault dehiscence and two cases of vaginal vault hematoma.

Conclusions

Our data show that TLH without the use of a uterine manipulator is a feasible and safe procedure. It is a more demanding procedure with longer learning curve. However, when performed by well-trained and experienced laparoscopic surgeons, the procedure entails a short operative time and a low complications rate. As such, it should be the first step in the training of young doctors for performing laparoscopic radical hysterectomies.

ESGE35-0263 - P181
ePoster Presentations

#Enzian(u) (Ultrasound Scan) – the Key for any Endometriosis Centre

Miski Scerif[1], Tereza Indrielle-Kelly[1], Martin Beard[1], Alvaro Bedoya-Ronga[1]
[1]Midland Metropolitan Endometriosis Centre, Sandwell and West Birmingham Hospitals NHS Trust, Birmingham, United Kingdom

Background

Since its establishment in 2022, Midlands Metropolitan Endometriosis Centre (MMEC), utilised US in the assessment of Endometriosis; this is well described and recommended by NICE. Endometriosis US pairs the use of the International Deep Endometriosis Analysis (IDEA) consensus and the Morphological Uterus Sonographic Assessment (MUSA) criteria for diagnosis and stratification of the surgical approach.

The #Enzian classification was initially developed for surgical staging of Deep Infiltrating Endometriosis (DIE), more recently validated for diagnostic imaging and its use is now essential in the UK for British Society for Gynaecological Endoscopy (BSGE) Endometriosis Centre accreditation. The pre-operative #Enzian classification by Ultrasound Scan (US) provides a standardised framework which has shown high concordance with surgical findings.

Methods

We audited over 100 cases correlating US with surgical findings. We later conducted a #Enzian(u) feasibility audit of 18 BSGE surgical index cases.

Results

We confirmed a correlation of 90% for Superficial Endometriosis, 95% for Adenomyosis and 95% for DIE. Only the cases where we found DIE or Frozen Pelvis on USS, underwent MRI and MDT review prior to surgery, limiting the need for MRI to under 15% of our surgical patients.

Our #Enzian(u) feasibility audit found US to have a sensitivity (true positive rate) of 12%, 0% and 86% and a specificity (true negative rate) of 100%, 100% and 92% for #Enzian compartments A, B and C respectively.

Conclusions

#Enzian is the key for any Endometriosis Centre as it standardises US, MRI and surgical findings and thus facilitates communication, auditing and research among the multidisciplinary team (MDT). Our #Enzian(u) feasibility audit has highlighted areas for improvement, namely scanning for DIE of the rectovaginal space and utero-sacral ligaments.

ESGE35-0430 - P186
ePoster Presentations

Early outcomes of the toumai® mt-1000 robotic system in gynecologic surgery: a consecutive case series

Riccardo Oliva[1], Barbara Costantini[2], Angelica Naldini[3], Giorgia Gaia[4], Anna Fagotti[5], Francesco Fanfani[3]
[1]Fondazione Policlinico Universitario A. Gemelli IRCSS- Università Cattolica del Sacro Cuore- Roma, Department of Women's and Children's Health- Complex Unit of Gynecologic Oncology, Rome, Italy
[2]Fondazione Policlinico Universitario A. Gemelli IRCCS. Catholic University of Sacred Heart- Rome- Italy ., Department of Women's and Children's Health- Complex Unit of Gynecologic Oncology, Roma, Italy
[3]Fondazione Policlinico Universitario A. Gemelli IRCCS. Catholic University of Sacred Heart- Rome- Italy , Department of Women's and Children's Health- Complex Unit of Gynecologic Oncology, Rome, Italy
[4]ondazione Policlinico Universitario A. Gemelli IRCCS. Catholic University of Sacred Heart- Rome- Italy, Department of Women's and Children's Health- Complex Unit of Gynecologic Oncology, Rome, Italy
[5]Fondazione Policlinico Universitario A. Gemelli IRCCS. Catholic University of Sacred Heart- Rome- Italy ., Department of Women's and Children's Health- Complex Unit of Gynecologic Oncology, Rome, Italy

Background

The introduction of new-generation robotic platforms requires objective clinical validation in real-world surgical practice beyond technical specifications alone. The purpose of this study was to evaluate the technical feasibility and early workflow performance of the toumai® mt-1000 robotic system (microport medbot, china) in a consecutive series of benign gynecologic procedures performed by experienced robotic surgeons, with specific focus on setup reproducibility and perioperative outcomes.

Methods

A prospective database of 30 consecutive benign gynecologic procedures performed with the toumai robotic system at a single tertiary referral center was analysed. Cases were performed by three experienced robotic surgeons on established platforms (e.g., da vinci and hugo ras), minimizing the confounding effect of primary robotic learning curves. Recorded metrics included procedure time: total operative time, docking time, estimated blood loss, conversion rate, length of stay, intra-/post-operative complications (clavien–dindo scale), and technical workflow events (arm collisions, system faults and docking failures). A standardised four-arm configuration was adopted in all cases: bipolar forceps (arm 1), 3d endoscope (arm 2), monopolar scissors (arm 3), and grasper (arm 4). A single assistant trocar was positioned in the left subcostal region for suction, irrigation and additional traction. In all procedures, the integrated smoke removal mode was systematically activated from the console to maintain vision clarity during energy use.

Results

All 30 procedures were completed robotically without conversion. Median age was 49 years (37–72) and median bmi was 25 kg/m² (18–40). Concomitant bilateral salpingo-oophorectomy was performed in 25 cases (83.3%), while bilateral salpingectomy was performed in 5 cases (16.7%). median

operative time was 115 minutes (39–248). Median docking time was 8 minutes (6–17), reflecting reproducible setup across consecutive cases. Median estimated blood loss was 50 mL (0–200), and length of hospital stay was 2 days median (2–3). No docking failures or system faults requiring procedural interruption were observed. arm collisions resolved at the console occurred in 2 cases (6.7%). Postoperative complications occurred in 1 patient (3.3%; clavien–dindo II).

Conclusions

In this consecutive early experience performed by expert robotic surgeons, the toumai robotic system demonstrated technical feasibility and stable intraoperative performance in benign hysterectomy, with no conversions and no docking failures or critical system faults. Workflow interruptions were limited and manageable from the table assistant, supporting further structured evaluation of efficiency and ergonomics across larger multicentre cohorts with comparison with other established robotic platforms currently available.

ESGE35-0489 - P187
ePoster Presentations

Abdominal Wall Endometriosis: The Hidden Cause of Chronic Pelvic Pain

Anca-Mihaela Hashemi[1], Bogdan-Cătălin Coroleucă[1], Ciprian-Andrei Coroleucă[2], Andrei Manu[2], Elvira Brătilă[2]
[1]"Prof. Dr. Panait Sârbu" Clinical Hospital of Obstetrics and Gynaecology, Obstetrics and Gynaecology, Bucharest, Romania
[2]"Prof. Dr. Panait Sârbu" Clinical Hospital of Obstetrics and Gynaecology and "Carol Davila" University of Medicine and Pharmacy, Obstetrics and Gynaecology, Bucharest, Romania

Background

Parietal endometriosis is a rare condition characterized by endometrial tissue localised within the muscles and subcutaneous tissue of the abdominal wall. Patients typically present with an abdominal palpable mass associated with localized, cyclic pain. Diagnosis can be challenging because these lesions can be confused with granulomas, hematomas, hernias or malignancies. The aim of this study was to evaluate the clinical presentation, diagnostic challenges, surgical management and outcomes of patients diagnosed with abdominal wall endometriosis treated in our clinic over a five-year period. Additionally, we sought to assess the role of minimally invasive approaches in achieving symptom resolution and preventing recurrence.

Methods

We submit a prospective study conducted between January 2020 and May 2025. During this period 714 patients diagnosed with endometriosis were treated in our clinic. From these, we analysed the ones diagnosed with parietal endometriomas.

Results

In total, we identified 56 patients (7,84%) diagnosed with parietal endometriomas. The mean age of the patients was 35 years. All patients presented with abdominal pain and palpable mass. The majority of these patients received hormonal treatment for 3 to 6 months without significant improvement of the symptoms and no influence on the size of endometriomas. Thus, these patients required complete local excision of the masses, minimally invasive in 10,7% of the cases. All specimens underwent histopathological examination, which confirmed the diagnosis of endometriosis. Moreover, 35 patients (62,5%) also associated deep infiltrating endometriosis and were treated accordingly. In 5 cases, the aponeurotic defect was closed using a polypropylene mesh. Furthermore, we can report 2 cases of complications consisting of postoperative seroma. The recurrence rate was null and symptoms resolved completely in all cases without the need of postoperative therapy.

Conclusions

Even though parietal endometriosis is considered a rare condition, practice has shown us that its prevalence is rapidly increasing due to the rising rate of caesarean sections. Therefore, parietal endometriosis should always be considered a part of the differential diagnosis of abdominal masses

found in fertile women. Complete surgical removal is currently the optimal management strategy and approaching this through minimally invasive surgery has a positive impact on patients' quality of life.

ESGE35-0617 - P189
ePoster Presentations

Laparoscopic findings in patients with clinically or sonographically suspected endometriosis: a retrospective study

Dong LI[1], Natalie Khan[1], Joel Naftalin[1], Jessica Farren[1]
[1]University College London Hospitals NHS Foundation Trust,
Gynaecology Diagnostic and Treatment Unit, London, United Kingdom

Background

When performed by trained operators, transvaginal ultrasound (TVUS) is highly accurate in the detection of deep endometriosis (DE) and endometriomas. Although diagnosis of superficial endometriosis (SE) on ultrasound is improving, laparoscopy is considered the gold-standard in its detection. However, laparoscopy is inconvenient for the patient, costly and has well-documented surgical and anaesthetic risks. Furthermore, there is no evidence of long-term improvement in pelvic pain from the treatment of SE. This study aimed to determine: (1) the proportion of patients with a normal TVUS who had abnormal findings at laparoscopy; (2) the proportion of patients with a TVUS suggestive of SE who had endometriosis confirmed at surgery.

Methods

A retrospective study was conducted at a dedicated gynaecological diagnostic unit in the UK, with expertise in the ultrasound diagnosis of endometriosis. The surgical diary was searched using the keywords 'endometriosis', 'laparoscopy', or 'laparoscopic'. All patients with clinically suspected endometriosis with a normal scan, and those with a scan suggestive of SE, who underwent laparoscopic surgery with the general gynaecology team between September 2021 and December 2025 were identified. Only patients scanned by a Level 3 TVUS operator (expert or consultant-level operator) were included. Operative notes were reviewed using the EPIC electronic medical record system, and TVUS reports were accessed via the ViewPoint ultrasound reporting software.

Results

55 patients were included. TVUS findings were SE (n=23), normal pelvis (n=23), adenomyosis only (n=4), pelvic adhesions only (n=3), and ‘white line sign’ (a thick layer of hyperechoic tissue in anterior aspect of pouch of Douglas (POD)) only (n=2). Of the 23 patients with a normal TVUS, 13 (56.5%) had endometriosis confirmed at laparoscopy - predominantly SE (11 patients), while 8 (34.8%) found a normal pelvis and 2 (8.7%) had filmy adhesions only. 2 patients had DE that was missed on ultrasound. Of the 23 patients with TVUS evidence of SE, 20 (87.0%) patients had endometriosis confirmed at surgery; 2 (8.7%) had a normal pelvis and 1 (4.3%) had filmy adhesions. None of the 3 patients without endometriosis had cause for improvement between scan and surgery i.e. prolonged delay to surgery, or interim hormonal treatment. Of 4 patients with adenomyosis only, 2 had SE; of 3 patients with TVUS evidence of adhesions, 2 had SE; and of 2 patients with the ‘white line sign’ on TVUS, both had SE.

Conclusions

TVUS does not reliably exclude SE. In our unit, with expertise in the identification of endometriosis, patients with clinically suspected endometriosis without ultrasound features can be counselled that endometriosis will be identified in 56.5% cases. Suspected SE on TVUS has a high positive predictive value for finding endometriosis at surgery. These findings support informed preoperative counselling in a general gynaecology clinic.

ESGE35-0786 - P190
ePoster Presentations

Overview on genital tumors biomarkers

Anca-Teodora Constantin[1]
[1]*National Institute for Mother&Child Healthcare, Obstetrics & Gynaecology, Bucharest, Romania*

Background

Tumor biomarkers represent a wide spectrum of biomacromolecules produced by highly metabolic active malignant cells or by activated genes which remained unexpressed in early life or newly acquired antigens at cellular and sub-cellular levels.

Tumor biomarkers are continuously studied for clinical and research purposes and do not have sufficient sensitivity or specificity for screening. Results are integrated with clinical, imaging, pathological and molecular findings for diagnosis, risk stratification, personalized treatment and outcome assessment.

Circulating tumor DNA (ctDNA) theoretically represents a powerful biomarker for detecting otherwise occult disease.

Methods

Literature and clinical guidelines review for genital tumors biomarkers role in early and differential diagnosis, treatment monitoring and surveillance as predictive and prognostic factors. Increased values are consistent with elevated clinical stage (pTNM,FIGO) and recurrent disease.

Results

The invasive cervical carcinoma is divided into squamous cell (ectocervical) and reserve cell (endocervical) by histological and immunohistochemical examination.

Preinvasive and invasive squamous lesions are caused by a transforming high risk human papillomavirus (HPV) infection whereas only some cervical adenocarcinomas are related to high risk HPV infection. Cervical mRNA HPV detects the transforming HPV infection.

CA 125 - relatively useful in endometrial cancer and SCC-Ag (squamous cell carcinoma-associated antigen) - an important prognostic factor for cervical cancer, both are related to the tumor grade and cell type.

Uterine mesenchymal tumors traditionally classified by histomorphology and immunophenotype, are now increasingly defined by genetic alterations including multiple somatic mutations and copy number alterations that refine diagnosis and elucidate tumorigenesis. Further clinical trials need to validate these therapeutic targets.

Tumor markers such as CA-125, CA15-3, CA 19-9, HE4, hCG provide valuable insights into ovarian cancer diagnosis, monitoring, prediction and prognosis with the potential to enhance early detection, considering this disease silent progression and late-stage diagnosis.

HE4 when combined with CA-125 shows improved sensitivity and specificity, particularly in early-stage detection.

Serum HE4 differentiates malignant ovarian tumors from endometrioma and is elevated less frequently than CA 125 in women with benign gynecologic disorders, particularly in premenopausal patients.

Beta hCG, alphafetoprotein and LDH have provided useful markers for ovarian germ cell tumors, inhibin and AMH for sex cord tumors (granulosa cells).

Testing for beta-hCG is an integral part of the diagnosis and management of gestational trophoblastic disease.

Conclusions

Genetic changes irreversibly disrupt the DNA sequence and epigenetic alterations are reversible modifications which can become therapeutic targets.

ctDNA offers a less invasive alternative to tissue biopsy, high specificity for tumor biology and a base for molecular-targeted cancer therapies. In gynecologic cancers the use of ctDNA is limited by fewer comprehensive studies and clinical validations. More research is needed.

NGS technologies and novel molecular characterization (transcriptomics, immunophenotyping, epigenetic profile, single-cell analyses) are promising to provide new insights for precision cancer medicine.

ESGE35-0721 - P191
ePoster Presentations

Pelvic hydatid cyst mimicking an adnexal mass: a rare laparoscopic finding in a patient with previous hepatosplenic echinococcosis

Onur Ada[1]
[1]*Tepecik Training and Research Hospital, Obstetrics and Gynaecology, İzmir, Türkiye*

Background

Pelvic hydatid disease is an uncommon manifestation of echinococcosis and may closely mimic adnexal pathology on preoperative imaging. We present a rare case of a pelvic hydatid cyst initially interpreted as a solid right adnexal mass, emphasizing the diagnostic value of laparoscopy in patients with previous hepatosplenic hydatid disease.

Methods

A postmenopausal patient with a history of surgically confirmed hepatic hydatid cyst was evaluated for a right-sided adnexal lesion. Pelvic magnetic resonance imaging demonstrated a 3.5-cm non-enhancing hypointense lesion in the right adnexal region, suspicious for a solid adnexal mass. Transvaginal ultrasonography showed a persistent approximately 30-mm solid-appearing lesion adjacent to the right adnexa. The patient underwent total laparoscopic hysterectomy, bilateral salpingo-oophorectomy, excision of the pelvic mass, and cystoscopic assessment. Clinical, radiological, operative, and histopathological findings were reviewed.

Results

At laparoscopy, the uterus and both adnexa appeared macroscopically normal. Instead of an ovarian or tubal lesion, an approximately 3-cm extraperitoneal mass was identified in the right lateral bladder region. The lesion was carefully excised without apparent rupture and removed with the surgical specimen. The lesion was carefully dissected from its peritoneal attachment and removed vaginally together with the surgical specimen. Histopathological examination of the presumed adnexal mass revealed a fibrous capsule with mononuclear inflammatory cells and adjacent acellular membrane fragments, findings consistent with a hydatid cyst. The bilateral ovaries and fallopian tubes were histologically unremarkable.

Conclusions

Pelvic hydatid cyst is a rare but clinically relevant differential diagnosis of adnexal masses, particularly in endemic regions and in patients with previous hepatic or splenic echinococcosis. This case demonstrates that extra-adnexal pelvic hydatid disease may be mislocalized as an adnexal lesion on imaging. Laparoscopy can provide both diagnostic clarification and definitive excision by directly confirming adnexal integrity and identifying the true anatomical origin of the mass. Preoperative awareness is important to minimize the risk of cyst rupture, spillage, secondary dissemination, and inappropriate surgical manipulation.

ESGE35-0726 - P192
ePoster Presentations

Reducing failed outpatient hysteroscopy through a standardized vaginoscopic approach and enhanced pre-procedure counselling: A quality improvement project in a district general hospital

Hira Fatima[1], Samreen Muhammad[2], Tasmia Tahir[3], Maimoona Afzal[4], Remko Beukehnholdt[1]
[1]Darlington Memorial Hospital, Gynaecology and Obstetrics, Darlington, United Kingdom
[2]Sheffield Teaching Hospital, Gynaecology and Obstetrics, Sheffield, United Kingdom
[3]Pakistan Atomic Energy General Hospital Islamabad, Gynaecology and Obstetrics, Islamabad, Pakistan
[4]Walsall Manor Hospital, Gynaecology and Obstetrics, Walsall, United Kingdom

Background

Outpatient hysteroscopy is a key part of gynaecology services in a district general hospital but failed procedures still occur and often lead to repeat procedures or escalation to general anaesthesia. In our unit failures were mainly due to pain intolerance, difficulty with cervical access and anxiety before the procedure. We aimed to see if introducing a standardized vaginoscopic approach along with better pre-procedure counselling could reduce failed outpatient hysteroscopy and improve completion rates.

Methods

This was a two-cycle quality improvement project carried out in a district general hospital between August 2025 and May 2026. Baseline data were collected retrospectively from 50 outpatient hysteroscopies performed during the study period for abnormal uterine bleeding, postmenopausal bleeding and suspected endometrial pathology.

Outcome measures included failed procedure rate, requirement for hysteroscopy under general anaesthesia, patient-reported pain scores, vasovagal episodes and successful completion of planned diagnostic assessment. Subgroup analysis was also performed comparing postmenopausal and premenopausal patients.

Following baseline review a standardized outpatient hysteroscopy pathway was introduced. This included a vaginoscopic-first approach, avoidance of cervical instrumentation where feasible, enhanced pre-procedure counselling with clearer expectation setting and standardised local anaesthetic guidance. Operators were encouraged to use a stepwise low-pressure technique with ongoing verbal reassurance throughout the procedure.

A second cycle included a further 50 outpatient hysteroscopies performed following implementation of the pathway.

Results

Following introduction of the pathway failed outpatient hysteroscopy rates reduced from 20.0% (10/50) to 8.0% (4/50). Requirement for hysteroscopy under general anaesthesia reduced from 14.0% (7/50) to 6.0% (3/50).

Mean patient-reported pain scores reduced from 6.1 to 3.8 on a 10-point scale. Vasovagal episodes reduced from 10.0% (5/50) to 4.0% (2/50). Completion of intended diagnostic assessment improved from 74.0% (37/50) to 90.0% (45/50).

Improvement was more noticeable in postmenopausal patients where failed procedure rates reduced from 30.0% to 8.0%, compared to 12.0% to 8.0% in premenopausal patients. Reduced cervical instrumentation and improved counselling appeared to have the greatest benefit in postmenopausal women with cervical stenosis and higher baseline anxiety.

The intervention also improved consistency of outpatient hysteroscopy across different operators within the unit with more reliable completion at first attendance.

Conclusions

Introduction of a standardized vaginoscopic outpatient hysteroscopy pathway with enhanced pre-procedure counselling reduced failed outpatient hysteroscopy procedures in a district general hospital setting. The greatest improvement was seen in postmenopausal women who traditionally represent a more technically challenging group for outpatient hysteroscopy.

Simple standardisation of technique alongside better patient preparation improved completion rates and reduced escalation to hysteroscopy under general anaesthesia. This approach may provide a practical and easily reproducible model for improving outpatient hysteroscopy services within busy NHS gynaecology units.

ESGE35-0694 - P194
ePoster Presentations

Clinical, cytological and virological predictors of severity and recurrence in high-grade vaginal intraepithelial neoplasia (VAIN 2-3): a retrospective observational study

Mario Palumbo[1], Luigi Della Corte[2], Giuseppe D'Angelo[1], Mario Ascione[1], Giada Lavitola[1], Giuseppe Bifulco[1]
[1]University of Naples Federico II, Department of Public Health- Ob-GYN Unit, Naples, Italy
[2]University of Naples Federico II, Department of Neuroscience- Reproductive Sciences and Dentistry, Naples, Italy

Background

Vaginal intraepithelial neoplasia (VAIN) is an uncommon HPV-related condition characterized by a heterogeneous clinical course and a relevant risk of recurrence after treatment. Identifying factors associated with disease severity and post-treatment outcomes remains challenging.

Methods

This retrospective observational study included 41 women with histologically confirmed VAIN managed at a tertiary referral center between January 2020 and January 2026, to evaluate clinical, cytological, virological, and colposcopic factors associated with histological severity and recurrence in women with VAIN.
Patients underwent standardized assessment including vaginal cytology, high-risk HPV (HR-HPV) testing, and colposcopy. Histological diagnoses were classified as VAIN1 or high-grade disease (VAIN2–3). Treatment was individualized, with CO_2 laser vaporization as the main approach. Associations between clinical, virological, and colposcopic variables and disease severity and recurrence were assessed using bivariate analysis.

Results

High-grade disease (VAIN2–3) was observed in 75.6% of cases. HPV16 positivity was significantly associated with high-grade histology (51.6% vs 20.0%, p = 0.049), as was high-grade cytology (p = 0.048). During follow-up, recurrence occurred in 19.5% of patients. HPV16 infection was significantly more frequent in patients with recurrence than in those without (75.0% vs 36.4%, p = 0.048). Multiple HPV infection was strongly associated with recurrence (62.5% vs 18.2%, p = 0.028). No association was found between recurrence and age, histological grade, colposcopic findings, or treatment modality.

Conclusions

Virological factors, particularly HPV16 positivity and multiple HPV infection, are associated with disease severity and recurrence in VAIN. These findings support the role of HPV genotyping in risk stratification and surveillance.

ESGE35-0745 - P195
ePoster Presentations

Total laparoscopic hysterectomy for scar-related placenta increta presenting with persistent bleeding after second-trimester surgical termination.

Almoatazbellah Elramlawy[1], Mohamed Khater[1], Mohamed Koota[2], Auos Al-Dujaily[1]
[1]Hull University Teaching Hospitals, Obstetrics and Gynaecology, Hull, United Kingdom
[2]University Hospitals of North Midlands, Obstetrics and Gynaecology, Stoke-on-Trent, United Kingdom

Background

Placenta accreta spectrum is rarely diagnosed after second-trimester surgical termination of pregnancy. Persistent post-termination bleeding in women with previous caesarean sections should prompt consideration of abnormal placental invasion, particularly when imaging demonstrates a hypervascular lower-segment lesion.

Methods

A 36-year-old woman, P3+3, with three previous caesarean sections and previous placenta praevia, underwent surgical termination of pregnancy at 14 weeks' gestation. The procedure was complicated by heavy per vaginal bleeding requiring blood transfusion and intrauterine balloon tamponade. Placenta increta was not suspected at the time, and bleeding was initially attributed to gestation and parity. She subsequently experienced eight weeks of persistent per vaginal bleeding, with intermittent heavier episodes. Haemoglobin fell from 110 g/L to 94 g/L, and serum beta-human chorionic gonadotrophin remained positive at 49 IU/L.

Results

Pelvic ultrasound demonstrated a highly vascular, mixed echogenic irregular lesion in the anterior lower uterus extending to the right side, measuring approximately 71 × 56 × 71 mm, with appearances not typical of a fibroid. Magnetic resonance imaging showed an enlarged bulky uterus with an ill-defined vascular lesion within the lower uterine myometrium, inseparable from the endometrium, measuring approximately 5.5 × 6.4 cm. The findings were considered most consistent with placental abnormality with myometrial invasion, rather than gestational trophoblastic disease or fibroid.

Following multidisciplinary discussion, options included methotrexate, uterine artery embolisation, hysteroscopic resection and hysterectomy. After counselling, the patient chose definitive surgical management. She underwent total laparoscopic hysterectomy and bilateral salpingectomy with ovarian conservation. Key surgical steps included retroperitoneal dissection, ureteric identification, bilateral uterine artery isolation and sealing, bladder dissection, colpotomy and laparoscopic vault closure. Intra-operative findings included a 14–16-week-size uterus with a bulbous lower segment, normal adnexa and normal cervix. Estimated blood loss was 200 ml. Post-operative CT for severe pain showed no active bleeding or urinary tract injury, with mild ileus managed conservatively. Histology confirmed placenta increta.

Conclusions

This case highlights a rare, delayed diagnosis of scar-related placenta increta following second-trimester surgical termination. Ultrasound and MRI were central to diagnosis and helped avoid further blind uterine instrumentation. With appropriate planning, counselling and surgical expertise, total laparoscopic hysterectomy can be a safe definitive option for selected patients who do not wish to preserve fertility.

ESGE35-0731 - P196
ePoster Presentations

Not just an Obstetric issue: full dilatation Caesarean section and the downstream burden on niche formation

Sumayya Alattar[1], *Freja Forrest*[1], *Guldzhan Vorona*[1]
[1]*Whittington Hospital, Obstetrics and Gynaecology, London, United Kingdom*

Background

Caesarean section at full cervical dilatation (FD-LSCS) carries greater maternal and neonatal morbidity than elective caesarean or vaginal birth (Adewale, 2023) and now accounts for approximately 45% of births in England (2024–25). Cervical dilatation >5 cm, prolonged labour, and advanced foetal station are established risk factors for uterine scar niche formation, observed in approximately 60% of women post-caesarean on transvaginal ultrasound (Kulshrestha, 2020). Niche-related Caesarean Scar Disorder (CSDi) causes postmenstrual spotting, malodorous discharge from retained menstrual blood, dyspareunia, negative self-image, avoidance of sexual intercourse, and secondary infertility, with IVF live birth rates reduced from 23.3% to 15.9% compared with vaginal delivery (OR 0.63) (Vissers, 2020). Uterine incision extension further amplifies niche risk by disrupting tissue integrity at the lower uterine segment, creating irregular devascularised wound edges that impair healing and predispose to larger scar defects (Vervoort, 2015).

Methods

Two-cycle retrospective observational audit at Whittington Hospital NHS Trust (~2,500–3,000 deliveries/year). Cycle 1 reviewed 572 emergency caesareans (January–December 2023), identifying 26 FD-LSCS (4.5%). Cycle 2 reviewed cases from October 2024–November 2025, identifying 36 FD-LSCS (6.2%). Data collected included operative indications, intra-operative complications including uterine extension, umbilical cord gases, and neonatal outcomes. An anonymous survey explored barriers to instrumental delivery. Published niche prevalence rates at ≥6 cm dilatation was applied to estimate downstream burden.

Results

FD-LSCS rose from 4.5% to 6.2% of emergency caesareans, yielding 62 cases. Uterine extension rose from 11.5% to 19.4%, a complication independently associated with impaired scar healing and increased niche risk. Massive PPH fell from 11.5% to 2.8%. A significant reversal in the relationship between consultant presence and instrumental attempt rates was observed between cycles ($p=0.041$). Survey responses identified insufficient confidence and absent senior support as barriers. Applying 60% niche prevalence at ≥6 cm dilatation to our 62-case cohort, approximately 37 women (range 30–44) are at high risk of CSDi. The 19.4% extension rate suggests the true burden may be higher, as extensions compound niche risk through irregular lower-segment repair.

Conclusions

FD-LSCS is increasing and its impact extends well beyond the obstetric episode. The rising uterine extension rate is both an acute intraoperative complication and a key predictor of niche burden, with each extension adding risk of defective scar healing, offensive vaginal discharge, dyspareunia and secondary infertility. FD-LSCS sits at the interface of obstetrics and gynaecological endoscopy, creating a cohort of women with complex, under-recognised long-term morbidity. Prospective follow-up with transvaginal ultrasound at 6 and 12 months will define niche prevalence, assess the effect of suture material at second-stage caesarean on niche formation, and link intrapartum factors to later endoscopic intervention. Education of resident doctors on the downstream gynaecological sequelae of FD-LSCS is essential to improve prevention, counselling and referral.

ESGE35-0906 - P197
ePoster Presentations

A rare and atypical presentation of non-gestational choriocarcinoma (NGC).

Ammar Rafiq[1], Bibi Zeyah Fatemah Sairally[1], Priya Heer[1], Ramya Meka[1], Manjula Annappa[1], Alex Tan[1]
[1]University Hospitals of North Midlands NHS Trust, Obstetrics & Gynaecology, Stoke-on-Trent, United Kingdom

Background

NGC is an exceedingly rare, highly malignant subtype of gestational trophoblastic disease characterised by rapid haematogenous spread and markedly elevated serum β-hCG levels.

We present a diagnostically challenging case of metastatic NGC in a young woman whose presentation was complicated by a functional neurological disorder, an inconsistent clinical history, and poor follow-up. The patient's atypical reproductive history prompted consideration of both safeguarding issues and the rare possibility ofNGC.

Methods

A 33-year-old woman presented with pelvic pain and a serum β-hCG of 97,559 IU/L. She had two previous caesarean sections. Her ultrasound scan (USS) showed a thickened well-defined endometrium of 20mm with a complex heterogenous pelvic collection measuring 69 x 28 mm. There was high suspicion of a live rupturing ectopic pregnancy on the background of the USS findings, a dropping haemoglobin level and high β-hCG levels. However, significant difficulty was encountered in establishing shared understanding with the patient regarding the diagnosis due an atypical affect and denial of any recent sexual contact. A comprehensive review of the patient's history revealed a complex psychosocial background with extensively investigated fits identified to be non-epileptic attack disorder with frequent dissociative episodes and blackouts. This raised the possibility of sexual assault and safeguarding concerns were raised. Following discussion, the patient underwent a diagnostic laparoscopy and evacuation of the uterus. The intraoperative findings were suggestive of a ruptured cervical ectopic pregnancy with normal adnexa and blood in the pouch of Douglas. The post-operative plan was to perform serial β-hCG monitoring. The β-hCG level initially declined to 30,908 IU/L at 48 hours. However, following initial management, the patient was lost to follow-up.

Results

She re-presented 26 days later with abdominal pain, malaise, and vaginal bleeding. A repeat USS demonstrated a 63 x 61 mm heterogeneous left adnexal mass with an empty uterus and a β-hCG level of 893,535 IU/L. Her initial histopathological analysis had demonstrated normal products of conception. Further investigations were delayed and complicated by recurrent non-epileptic seizures and poor tolerance of imaging. Following sedation, her CT thorax, abdomen and pelvis demonstrate pulmonary and hepatic metastases with a bulky uterus. In view of this unexpected finding, a probable NGC was made and she was urgently referred to a regional trophoblastic disease centre for systemic chemotherapy.

Conclusions

This case highlights the importance of maintaining a high index of suspicion for trophoblastic malignancy in patients with persistently elevated β-hCG levels despite management and initial histopathology report. It also demonstrates how other variables may significantly delay diagnosis and continuity of care. Furthermore, in the setting of an atypical reproductive history, this case could indicate either gestational or non-gestational choriocarcinoma.

Early multidisciplinary involvement, specialist histopathological review, and prompt referral to trophoblastic disease centres are essential in managing complex presentations of metastatic choriocarcinoma.

ESGE35-0756 - P198
ePoster Presentations

Feasibility, specimen adequacy and tolerability of office hysteroscopic "rail biopsy": a prospective pilot study

Francesco Cecchieri[1], Luca Iazzetta[1], Sara Tolentino[1], Karima Beriane[1], Paolo Casadio[1], Alessandro Arena[1]
[1]IRCCS Azienda Ospedaliero-Universitaria di Bologna,
Division of Gynaecology and Human Reproduction Physiopathology, Bologna, Italy

Background

Obtaining an adequate endometrial sample during office hysteroscopy may be challenging, particularly in postmenopausal women or in case of thin endometrium.

Hysteroscopic "rail biopsy" has been proposed as a targeted and minimally invasive sampling technique.

The aim of this study was to evaluate the feasibility, specimen adequacy, and tolerability of office hysteroscopic "rail biopsy".

Methods

"Rail Biopsy" is a hysteroscopic targeted endometrial biopsy technique based on the creation of two parallel tracks ("rails") using cold scissors to isolate and retrieve a high-quality endometrial specimen while minimizing tissue manipulation and thermal damage.

A prospective observational pilot study was conducted, in a tertiary referral center, including consecutive women undergoing office hysteroscopic "rail biopsy" for endometrial assessment in an outpatient setting.

Primary endpoints were technical success and histological adequacy of the obtained sample. Secondary outcomes included procedural pain assessed by Visual Analog Scale (VAS), procedural time, complications, and the impact of cervical stenosis on procedural performance.

We enrolled a number of patients consistent with the predefined feasibility-based sample size estimation, providing a study power corresponding to p = 0.875 with a 95% confidence interval.

Results

Forty-three women were included. Mean age was 51.3 ± 12.2 years, mean body mass index was 30 ± 7.7 kg/m², and mean endometrial thickness was 5.2 ± 3.8 mm.

Technical success was achieved in all procedures (100%), while histological adequacy was obtained in 97.7% of cases. Mean procedural time was 111 seconds.

Procedural pain was low, with a mean VAS score of 3.3/10.

No procedure was interrupted because of pain or technical failure, and only one minor complication was recorded (Misalignment of the scissors before the beginning of the biopsy).

Cervical stenosis was associated with significantly longer procedural time compared with non-stenotic cases (152 vs 109 seconds, p=0.027), without significant differences in pain scores or sample adequacy.

Despite being performed by operators with different levels of experience, the procedure maintained high technical success and comparable procedural times.

Conclusions

Office hysteroscopic rail biopsy demonstrated high technical feasibility and excellent histological adequacy, with low pain scores and minimal complications.

Although cervical stenosis increased procedural time, it did not negatively affect procedural success or patient tolerability.

These findings suggest that hysteroscopic rail biopsy may be an effective and feasible office-based endometrial sampling technique, including in technically challenging clinical settings.

The consistently high success rate and limited procedural duration across operators suggest that hysteroscopic "rail biopsy" may be a reproducible and easily implementable office technique.

ESGE35-0926 - P199
ePoster Presentations

Evaluation of Patient-Reported Outcomes Following Laparoscopic Burch Colposuspension: A Single-Center Experience (TR-MIGS Study)

Filiz Gökçe Ikibudak[1], Elif Şeyma Çetinkaya[2], Aslı Akdöner[2], Onur Yavuz[2], Mehmet Güney[2]
[1]Dokuz Eylül University, Obstetrics and Gynaecology, İzmir, Türkiye
[2]Dokuz Eylul University, Obstetrics and Gynaecology, İzmir, Türkiye

Background

To evaluate the mid-term surgical outcomes, changes in quality of life, and patient satisfaction in women undergoing laparoscopic Burch colposuspension for stress urinary incontinence (SUI).

Methods

This retrospective study included patients who underwent laparoscopic Burch colposuspension for stress urinary incontinence at a tertiary referral center between 2022 and 2026. A total of 26 patients were assessed, and 24 patients with available postoperative follow-up data were included in the final analysis. Postoperative patient-reported outcomes were evaluated through telephone interviews using the validated Urogenital Distress Inventory-6 (UDI-6), Incontinence Impact Questionnaire-7 (IIQ-7), and Patient Global Impression of Improvement (PGI-I) questionnaires.

Demographic characteristics, smoking status, gravida, parity, history of previous gynecologic surgery, operative time, length of hospital stay, complications, and follow-up duration were recorded. Preoperative and postoperative UDI-6 and IIQ-7 scores were compared using the Wilcoxon signed-rank test. Statistical analyses were performed using SPSS software. Data were presented as median (minimum–maximum) or number (%).

Results

Among the included patients, 4 (16.7%) underwent isolated laparoscopic Burch colposuspension, whereas 20 (83.3%) underwent concomitant total laparoscopic hysterectomy plus laparoscopic Burch colposuspension.

The median age was 55 years (range, 41–75), and the median body mass index was 29 kg/m² (range, 20.2–34.8). Eight patients (33.3%) were smokers, and 2 patients (8.3%) had a history of previous gynecological surgery. Median gravida and parity were 3 (range, 1–13) and 2 (range, 1–4), respectively.

The median operative time was 112.5 minutes (range, 70–160), the median length of hospital stay was 3 days (range, 2–6), and the median follow-up duration was 35.5 months (range, 2–49). No perioperative complications were observed.

Postoperative assessment demonstrated improvement in both UDI-6 and IIQ-7 scores. Median UDI-6 scores decreased from 25 (range, 4.1–58.3) preoperatively to 20.8 (range, 0–37.5) postoperatively, showing a trend toward improvement without reaching statistical significance (p=0.06). Median IIQ-7

scores significantly decreased from 35.7 (range, 4.7–100) to 26.1 (range, 0–100) following surgery (p=0.03), indicating improved quality-of-life outcomes.

Postoperative patient satisfaction assessed using the PGI-I questionnaire demonstrated a median score of 1.5 (range, 1–6). Subjective treatment success, defined as PGI-I ≤2, was achieved in 14 of 24 patients (58.3%).

Conclusions

Laparoscopic Burch colposuspension appears to be a safe, minimally invasive, mesh-free, and effective surgical option for the treatment of stress urinary incontinence, providing favourable mid-term patient-reported outcomes and high patient satisfaction.

ESGE35-0790 - P200
ePoster Presentations

Ovarian collision tumour revealing deep infiltrating endometriosis: A diagnostic and surgical challenge in a nulliparous woman with fertility aspirations

Kerri Aresti[1], Anna Jimenez De Veciana[1], Guldzhan Vorona[1]
[1]Whittington Hospital NHS Trust, Obstetrics and Gynaecology, London, United Kingdom

Background

Ovarian collision tumours, defined as two histologically distinct neoplasms coexisting within the same ovary, are rare, with the dermoid cyst–endometrioma combination representing a particularly uncommon subset. We report a case in which a recurrently symptomatic right ovarian dermoid cyst with suspected torsion was the index presentation of previously unrecognised stage IV deeply infiltrating endometriosis (DIE) in a woman with no prior diagnosis and minimal classical symptoms. This case underscores the diagnostic challenges posed by complex adnexal pathology and outlines a staged, fertility-preserving surgical approach in a nulliparous woman.

Methods

A 32-year-old nulliparous woman planning conception presented twice as an emergency over three months with right iliac fossa pain and suspected ovarian torsion. She reported no dyspareunia, no chronic pelvic pain, and only occasional mild dysmenorrhoea. Diagnostic work-up included serial transabdominal and transvaginal ultrasound, computed tomography (CT), and pelvic magnetic resonance imaging (MRI). Serial tumour markers (CA-125, CA19-9, carcinoembryonic antigen, alpha-fetoprotein, and beta-human chorionic gonadotrophin) were measured to exclude underlying malignancy in this young patient.

Results

Initial CT demonstrated a 6 cm right ovarian dermoid cyst with an adjacent haematosalpinx and features suspicious for torsion. CA-125 was markedly elevated at first presentation (507 U/ml), with a concomitant rise in CA19-9 (199 U/ml), while CEA, AFP, and bHCG remained within normal limits. On repeat testing six weeks later, CA19-9 had normalised (27 U/ml) and CA-125 had fallen substantially but remained above the upper reference range (71 U/ml). Pelvic MRI prior to the second admission showed a fat-containing right ovarian cyst with multilocular haemorrhagic components and tethering to the right uterosacral ligament, raising suspicion of coexistent endometriosis. The dynamic changes in tumour markers were considered consistent with an ovarian cyst accident, such as intermittent torsion or rupture, rather than malignancy.

Diagnostic laparoscopy confirmed a right ovarian collision tumour comprising a dermoid cyst and endometrioma, right haematosalpinx, a left ovarian endometrioma (2.5 cm), uterosacral ligament endometriotic nodules (2 × 4 cm), and a uterus fixed to the pouch of Douglas, consistent with stage IV DIE. Histopathology confirmed the presence of both mature cystic teratoma and endometrioma within the right ovary. Right ovarian cystectomy and right salpingectomy were performed. Minimal residual right ovarian tissue was noted intraoperatively. Given the patient's fertility intentions, the left

endometrioma was preserved pending oocyte retrieval. Dienogest 2 mg was commenced post-operatively.

Conclusions

This case illustrates the diagnostic complexity of recurrent suspected ovarian torsion in the context of an ovarian collision tumour and previously unrecognised stage IV DIE. It underscores the potential for marked but non-malignant elevations of CA-125 and CA19-9 in complex benign adnexal disease and the possibility of advanced DIE in women with minimal preceding symptoms. Meticulous, fertility-preserving surgical planning within a multidisciplinary framework is crucial for young women with complex tubo-ovarian pathology.

ESGE35-0813 - P201
ePoster Presentations

Oncological safety of fertility-sparing treatment in atypical endometrial hyperplasia and early endometrial cancer: final surgical pathology after delayed definitive surgery

Fabio Forzan[1], Emma Bonetti Palermo[2], Mariangela Ravo[3], Emanuele Perrone[4], Francesco Fanfani[4], Ursula Catena[4]
[1]University of Padua, Department of Women and Children's Health, Padua, Italy
[2]ASST Spedali Civili of Brescia, Unit of Obstetrics and Gynaecology, Brescia, Italy
[3]University of Campania Luigi Vanvitelli,
Department of Woman- Child and General and Specialized Surgery- Obstetrics and Gynaecology Unit, Naples, Italy
[4]Fondazione Policlinico Universitario Agostino Gemelli IRCCS,
Department of Women- Children and Public Health Sciences, Rome, Italy

Background

Fertility-sparing treatment has emerged as a valuable option for selected women with atypical endometrial hyperplasia (AEH) and early-stage endometrial cancer (EC) wishing to preserve reproductive potential. However, concerns remain regarding the risk of oncological progression during prolonged conservative management before definitive surgery.

Methods

We retrospectively analysed patients managed according to a prospectively defined fertility-sparing protocol who subsequently underwent definitive surgery. Clinical and pathological data were collected from baseline histology and final surgical pathology. After the initial pathological diagnosis, all patients underwent hysteroscopic removal of macroscopically abnormal endometrial lesions combined with hormonal therapy. Hysteroscopic treatment was performed either as visual dilation and curettage, according to the Mazzon three-step technique, or according to the Catena technique. Following completion of reproductive plans, irrespective of pregnancy achievement, patients underwent laparoscopic total hysterectomy, bilateral salpingectomy, and pelvic lymph node assessment.

Results

Twenty-seven patients with available baseline and final histopathological data underwent fertility-sparing treatment followed by definitive surgery. The median interval between initiation of conservative treatment and surgery was 46.6 months (IQR 34.0–63.9; range 12.3–88.0). Baseline histology revealed AEH in 11 patients (40.7%), grade 1 endometrioid carcinoma in 13 patients (48.1%), and grade 2 endometrioid carcinoma in 3 patients (11.1%). Final surgical pathology showed no residual carcinoma in 18 patients (66.7%), including negative histology in 7 cases and AEH in 11 cases. Residual carcinoma was identified in 9 patients (33.3%), consisting of grade 1 disease in 7 cases and grade 2 disease in 2 cases. Histopathological upgrading between baseline biopsy and final surgical specimen occurred in only 2 patients (7.4%): one case progressed from AEH to grade 1

carcinoma and one from grade 1 to grade 2 carcinoma. No lymph node metastases, cervical involvement, or fallopian tube involvement were identified.

Conclusions

In this selected cohort, fertility-sparing treatment followed by delayed definitive surgery demonstrated reassuring oncological outcomes. The low rate of histopathological upgrading and the absence of nodal, cervical, or tubal involvement suggest that conservative management may represent an oncologically safe option in carefully selected and closely monitored patients.

ESGE35-0824 - P203
ePoster Presentations

The Gynovart Academy Minimally Invasive Urogynaecology Algorithm for Pelvic Organ Prolapse: A Compartment-Based Model Toward Surgical Standardization and Patient-Centered Outcomes

Omer Tapisiz[1], *Sadiman Kiykac Altinbas*[1]
[1]*Gynovart Women's Health Clinic, Obstetrics and Gynaecology, Ankara, Türkiye*

Background

Pelvic organ prolapse (POP) surgery remains heterogeneous despite major advances in minimally invasive and uterine-preserving procedures. Multiple vaginal and laparoscopic techniques are currently available; however, standardized decision pathways integrating anatomical defects, patient characteristics, and preferential minimally invasive approaches remain limited.

The **Gynovart Academy Minimally Invasive Urogynaecology Algorithm for POP** was developed to provide a structured and patient-oriented framework for POP management and to support surgical standardization.

The aim of this study was to introduce this algorithm and present its role as a practical roadmap for individualized minimally invasive prolapse surgery.

Methods

A compartment-based surgical algorithm was developed using cumulative surgical experience combined with contemporary evidence.

The algorithm incorporated:

- Apical, anterior, and posterior compartment evaluation

- Age-based surgical stratification

- Prior hysterectomy status

- Identification of paravaginal defects

- Preference for minimally invasive and uterine-preserving approaches whenever appropriate

Procedures highlighted in **red** within the algorithm were defined as **preferred first-line interventions**.

The algorithm was designed to facilitate standardization in minimally invasive POP surgery and to serve as a practical guide for improving patient-centered outcomes.

Results

The **Gynovart Academy Algorithm (Figure)** prioritizes restoration of apical support and applies compartment-specific management pathways.

For **vaginal cuff prolapse**, sacrospinous ligament fixation was preferred in older patients, whereas **laparoscopic lateral suspension represented the preferred first-line procedure in younger women.**

For **uterine prolapse, vaginal-assisted laparoscopic sacrohysteropexy (VALSH)** was identified as the preferred minimally invasive uterine-preserving strategy in younger patients, while vaginal hysterectomy with McCall culdoplasty remained the principal option in older populations.

In selected elderly patients, the **TAP-GAN technique** provided an additional cervical-preserving alternative.

Anterior compartment defects were categorized as **central or paravagina**l and managed using anterior colporrhaphy via vaginal approach for central defects, whereas paravaginal defects were corrected using vaginal or laparoscopic repair according to anatomical characteristics and surgical preference.

Posterior compartment defects were treated using **native tissue** reconstruction via vaginal approach.



The procedures highlighted in red represented the **recommended first-line interventions** and reflected the surgical philosophy adopted at Gynovart Academy.

Conclusions

The **Gynovart Academy Minimally Invasive UroGynaecology Algorithm for POP** provides a structured, compartment-based, and patient-centered framework integrating minimally invasive surgery, uterine preservation, anatomical correction, and age-adapted decision-making.

Although surgical options for POP are numerous, standardized minimally invasive pathways remain limited. This algorithm may serve as a practical guide for surgeons, contribute to surgical standardization, and support improved patient-centered outcomes.

ESGE35-0838 - P204
ePoster Presentations

Bilateral mature ovarian teratomas in an adolescent: diagnostic and surgical considerations in fertility-sparing management.

Sabina Kowalczyk[1], Katarzyna Wilk-Sikora[1], Maja Zięba-Domalik[1], Agnieszka Drosdzol-Cop[1]
[1]Śląski Uniwersytet Medyczny w Katowicach,
Katedra i Oddział Kliniczny Ginekologii- Położnictwa i Ginekologii Onkologicznej, Katowice, Poland

Background

Ovarian neoplasms in the paediatric and adolescent population constitute approximately 1-2% of all childhood tumors [1]. The majority are benign, with mature teratomas accounting for 50-70% of cases [1]. Bilateral involvement is observed in approximately 10-15% of patients [2]. The present case underscores the diagnostic complexity and surgical challenges associated with large bilateral ovarian teratomas in an adolescent patient, with particular focus on fertility preservation.

Methods

A 14-year-old female presented with acute lower abdominal pain. Physical examination revealed a large, tender, and poorly mobile abdominal mass occupying most of the abdominal cavity, with distension extending above the costal margins. Pelvic ultrasonography identified a right adnexal anechoic lesion measuring 14 × 9 cm and a left adnexal lesion measuring 8 × 6 cm. Computed tomography confirmed the presence of a right-sided cystic mass (87 × 138 × 114 mm) containing fatty components, alongside a contralateral polycyclic lesion causing ureteral compression. Given the patient's age, bilateral ovarian involvement, and the imperative to preserve reproductive potential, meticulous intraoperative assessment was essential.

Results

The patient underwent bilateral ovarian cystectomy via laparotomy, with maximal preservation of healthy ovarian tissue. Histopathological evaluation confirmed the diagnosis of bilateral mature ovarian teratomas. The postoperative course was uneventful, and the patient was discharged in good general condition with recommendation for outpatient follow-up.

Conclusions

The management of bilateral ovarian teratomas in adolescent patients necessitates a careful balance between complete tumor resection and preservation of ovarian function. Fertility-sparing surgical approaches should be prioritized whenever feasible, particularly in cases involving benign bilateral lesions in young patients [3;4]

ESGE35-0005 - P205
ePoster Presentations

Extra-Pelvic Endometriosis: A Case Series of Canal of Nuck, Rectus muscle and Umbilical Endometriosis

Sobha Ramakoti[1]
[1]*Countess of Chester Hospital, Gynaecology, Chester, United Kingdom*

Background

Extra-pelvic endometriosis is an uncommon manifestation of endometriosis and often presents a diagnostic challenge due to its atypical location and non-specific symptoms. We present a case series of four patients with rare extra-pelvic endometriosis involving the canal of Nuck (n=2), rectus muscle and sheath (n=1), and umbilicus (n=1), highlighting clinical presentation, diagnostic pathway, surgical management, and outcomes.

Methods

This is a retrospective case series of four women presenting to a tertiary gynaecology unit with cyclical pain and/or swelling in extra-pelvic locations. Clinical evaluation included detailed menstrual history and physical examination. Imaging modalities included ultrasound and MRI where indicated. In all cases, ultrasound-guided core biopsy was undertaken prior to definitive surgical planning to exclude other benign and malignant conditions. Following multidisciplinary discussion, patients underwent complete surgical excision of the lesions. Histopathological confirmation of endometriosis was obtained in all cases. Postoperative follow-up assessed symptom resolution and recurrence.

Results

The two patients with canal of Nuck endometriosis presented with painful inguinal swelling, initially suspected to be inguinal hernia. Imaging suggested soft tissue lesions along the round ligament pathway. Both underwent complete surgical excision with no perioperative complications.

The patient with rectus muscle and sheath endometriosis presented with a palpable abdominal wall mass associated with cyclical pain, with MRI demonstrating a well-defined lesion within the rectus abdominis muscle. Wide local excision with clear margins was performed.

The umbilical endometriosis case presented with cyclical umbilical pain and discoloration without prior laparoscopic port placement. Surgical excision of the umbilical lesion was undertaken.

Histology confirmed endometriosis in all four cases. At follow-up, all patients reported significant symptom resolution with no early recurrence observed.

Conclusions

Extra-pelvic endometriosis, although rare, should be considered in women presenting with cyclical pain and mass lesions in atypical locations, particularly along embryological pathways such as the round ligament and abdominal wall. Pre-operative tissue diagnosis can aid exclusion of alternative pathology and optimise surgical planning. Complete surgical excision remains the cornerstone of management. Increased awareness may prevent misdiagnosis and delayed treatment.

ESGE35-0013 - P208
ePoster Presentations

Quality of life follow up after robotic niche repair

Felix Neis[1], *Sara Brucker*[1], *Bernhard Kraemer*[1]
[1]*University of Tuebingen, Gynaecology and Obstetrics, Tuebingen, Germany*

Background

As caesarean section rates continue to rise in Germany, the incidence of uterine niches has increased significantly. Surgical revisions are guided by the patients' symptoms.

Methods

As part of the GENERATE study (a multicentre, post-market, non-interventional study), the single-center data of patients who underwent uterine niche repair were analysed.

Patient-reported outcomes (EQ-5D-5L, QoR-9, pain VAS, PFIQ-7, SSQ-8) were electronically recorded 30 days, 90 days, 6 months, and 12 months after surgery.

Results

Twenty patients underwent robot-assisted laparoscopic niche repair between January 2024 and May 2025. The mean age was 33.9 ± 4.9 years, BMI 26.4 ± 3.6 kg/m2; all were ASA I–II with a Charlson Comorbidity Index (CCI) of 0. The incision-to-suture time was 2.16 ±0.31 hours. No intraoperative complications occurred. Three adverse events (anal vein thrombosis, haematuria, lower abdominal pain) were observed. On the third postoperative day, pain scores (QoR-9) returned to preoperative levels.

Two patients are currently pregnant following niche repair. At 6 and 12 months postoperatively, the majority of patients reported an improvement in symptoms, reduced pain, and high satisfaction with the surgery (SSQ-8).

Conclusions

When standardized, robot-assisted niche repair is a well-executed, low-complication procedure with high patient satisfaction. Studies with larger case numbers are needed to confirm long-term postoperative outcomes.

ESGE35-0016 - P209
ePoster Presentations

Concurrent Bilateral Live Tubal Ectopic Pregnancy: A Diagnostic and Surgical Dilemma

Ayisha Ashmore[2], Bruce Hunt[1], Phoebe Tan[2], Shilpa Kolhe[2], James Davies[2], Summi Abdul[3]
[1]University of Nottingham, Medicine, Nottingham, United Kingdom
[2]University Hospitals of Derby and Burton, Gynaecology, Derby, United Kingdom
[3]DELTA centre, Office of the Director, Derby, United Kingdom

Background

Bilateral tubal ectopic pregnancy (BTEP) is an exceptionally rare form of ectopic gestation, characterised by simultaneous implantation within both fallopian tubes. It accounts for approximately 1 in 200,000 gestations. Concurrent bilateral live tubal ectopic pregnancies represent an even rarer clinical entity, with evidence largely confined to isolated case reports. The rarity of this condition, combined with its often-non-specific presentation, creates significant diagnostic and intraoperative management challenges. Suspicious contralateral findings during emergency surgery pose a dilemma: clinicians must balance the urgency of treating life-threatening pathology against the risk of unnecessary surgical intervention and potential permanent infertility. Careful clinical governance and systematic adnexal inspection are therefore essential in complex cases.

Methods

We present the case of a 34-year-old para 3 woman following ovulation induction at approximately 8 weeks' gestation with left-sided lower abdominal pain. Serial β-hCG levels demonstrated an appropriate rise, initially consistent with suspicion of a viable intrauterine pregnancy. However, transvaginal ultrasound (TVS) demonstrated a live left tubal ectopic pregnancy with free fluid and no evidence of an intrauterine gestation. The patient subsequently developed tachycardia and proceeded to emergency laparoscopy.

Intraoperatively, the left fallopian tube was consistent with a live ectopic pregnancy. The right tube appeared abnormal, demonstrating mid-tubal swelling without rupture. An intraoperative re-review of the imaging was undertaken. As the initial TVS was confirmatory of a left ectopic pregnancy, a staged approach was adopted to avoid unnecessary sterilisation. A left salpingectomy was performed, with plans for postoperative β-hCG surveillance and repeat imaging should biochemical trends prove discordant.

Results

Postoperative β-hCG levels rose unexpectedly rather than declining, raising suspicion of persistent trophoblastic tissue. Repeat TVS subsequently confirmed a second live right tubal ectopic pregnancy. A formal duty of candour discussion was undertaken with the patient. Multidisciplinary review was conducted, and consensus regarding tubal appearance and management was sought from three senior clinicians. A second laparoscopy was performed, and a right salpingectomy was undertaken without complication. Histopathological examination definitively confirmed the presence of trophoblastic villi within both fallopian tubes, establishing the diagnosis of concurrent bilateral live tubal ectopic pregnancy.

Conclusions

Although bilateral tubal ectopic pregnancy is extremely rare, it should be considered when intraoperative findings are contradictory with imaging or when contralateral tubal abnormalities are observed. This case highlights the importance of systematic bilateral adnexal inspection at surgery, structured postoperative β-hCG surveillance, multidisciplinary review, and transparent communication. A hybrid approach, which addresses the primary pathology while utilising postoperative imaging, is a valid management strategy in carefully selected and clinically stable patients. Furthermore, robust clinical governance processes are essential to reduce morbidity and preserve patient trust in rare and complex presentations.

ESGE35-0020 - P210
ePoster Presentations

Direct Trocar Insertion—A Safe and Fast Method in the Creation of Pneumoperitoneum in the Treatment of Gynecological Emergencies

Branka Bacotic[1], *Milena Acimovic*[2]
[1]*Department of Gynaecology and Obstetrics, Minimally Invasive Surgery, Uzice, Serbia*
[2]*General Hospital, Gynaecology and Obstetrics, Uzice, Serbia*

Background

Nowadays, laparoscopy is a method of choice in the treatment of the majority of gynecological emergencies. Half of all complications in laparoscopy occur during laparoscopic entry. The most commonly used laparoscopic entry techniques are the Veress needle technique, direct trocar insertion (DTI), and the open (Hasson) technique. DTI is the fastest method. In the treatment of emergencies, time is an important factor.
The aim of this study was to present data from a single institution's experience using direct trocar insertion for establishing pneumoperitoneum in gynecological laparoscopic surgery.

Methods

This is a case series of 3423 gynecological laparoscopic surgeries, scheduled and emergencies, performed in General Hospital Uzice, Serbia. Pneumoperitoneum was established with DTI in the umbilicus.

Results

The complications associated with DTI in all patients who underwent laparoscopic surgeries included solid organ injury in 4 patients (0.1%), trocar site bleeding in 34 patients (1.0%), and trocar site infection in 9 patients (0.3%). There were no failed entries, no insufflation complications, no bladder injuries, no bowel injuries, and no major vessel injuries. In emergency cases, we had trocar site bleeding in 3 patients (0.8%) and no other complications. All complications were managed by gynaecologists and did not prolong the hospitalization time. None of the emergency laparoscopies were converted to open surgery. There were no major complications.

Conclusions

Direct trocar insertion was associated, in our study, with a low incidence of complications, no major complications, and rapid attainment of pneumoperitoneum. Compared to the data from the literature, it has a lower incidence of complications compared to the Veress needle technique. When performed by skilled laparoscopic surgeons, DTI could be used as a laparoscopic entry technique of choice, especially in gynecological emergencies.

ESGE35-0025 - P211
ePoster Presentations

A Simple Step, a Significant Impact: Uterosacral Suspension during vNOTES Hysterectomy

Aya Mohr-Sasson[1], Claire Lewis[1], Alvaro Montealegre[1], Asha Bhalwal[1]
[1]McGovern Medical School at The University of Texas Health Science Center, Department of Obstetrics- Gynaecology & Reproductive Sciences, Houston, USA

Background

Pelvic support at the time of hysterectomy is critical to reducing the risk of subsequent pelvic organ prolapse. During vaginal natural orifice transluminal endoscopic surgery (vNOTES) hysterectomy, uterosacral ligaments are routinely transected, raising the question of whether concomitant prophylactic apical suspension should be incorporated into the procedure. The objective of this study was to compare surgical outcomes in women undergoing vNOTES hysterectomy with versus without concomitant high uterosacral suspension.

Methods

This retrospective cohort study included women undergoing vNOTES hysterectomy for benign indications between October 2024 and March 2026 at a tertiary academic medical center. Patients undergoing concomitant procedures were excluded. Cases were stratified based on whether high uterosacral suspension was performed at the surgeon's discretion. Demographic, clinical, intraoperative, and postoperative data were extracted from medical records. The primary outcome was a composite complication rate, including intraoperative and postoperative events (hemorrhage, organ injury, conversion to alternative approach, infection, and readmission).

Results

Seventy-seven patients met inclusion criteria, including 24 (31%) who underwent uterosacral suspension and 53 (69%) who did not. Baseline demographic and clinical characteristics were comparable between groups. Approximately half of the procedures in both groups were performed for abnormal uterine bleeding due to fibroids. Robotic assistance was used in 79% versus 73% of cases, respectively. Mean Foley catheter duration was similar between groups (79 minutes; p=0.23), and no cases required conversion to an alternative surgical approach. The composite complication rate did not differ significantly between the suspension and non-suspension groups (16.7% vs. 11.3%; p=0.52). Postoperative day 1 pain scores were low and comparable between groups (median VAS 4 [3–4] vs. 4 [2–6]; p=0.8). On multivariable analysis, uterosacral suspension was not associated with increased perioperative complications.

Conclusions

Prophylactic high uterosacral suspension can be safely incorporated into vNOTES hysterectomy without increasing perioperative morbidity. Given routine transection of the uterosacral ligaments during the procedure, concomitant apical suspension represents a potential opportunity to optimize pelvic support at the index operation and warrants further prospective evaluation.

ESGE35-0034 - P213
ePoster Presentations

Laparoscopic management of adnexal torsion across the age spectrum: a case series of three distinct pathologies

Bilge Pınar Keskinsoy[1], Hakan Baş[2], Aslı Yarcı Gürsoy[1]
[1]Ufuk University School of Medicine, Obstetrics and Gynaecology, Ankara, Türkiye
[2]Ufuk University School of Medicine, Radiology, Ankara, Türkiye

Background

Adnexal torsion is a gynaecological emergency requiring prompt surgical intervention. Its clinical and imaging presentation varies considerably depending on patient age and the nature of the underlying pathology. This case series examines the laparoscopic management challenges posed by three distinct pathologies, bilateral mature cystic teratoma, ovarian fibroma mimicking a pedunculated leiomyoma, and paratubal cyst torsion in a geriatric patient on antiplatelet therapy, with the aim of highlighting age-appropriate surgical decision-making and the role of minimally invasive surgery across clinical contexts.

Methods

We report three consecutive cases of surgically confirmed adnexal torsion managed at our institution between December 2025 and January 2026. Clinical data, preoperative imaging findings, intraoperative decisions, and histopathological results were reviewed. All patients provided written informed consent for publication.

Results

Case 1: A 33-year-old woman (G1P1), known bilateral dermoid cysts presented with acute abdominal pain. Transvaginal ultrasonography identified a 6-cm right ovarian dermoid cyst with decreased Doppler flow and a positive whirlpool sign. Laparoscopy confirmed 720° right adnexal torsion. Following detorsion with confirmed tissue viability, bilateral laparoscopic cystectomy was performed using endobags. Ovarian function was preserved bilaterally. Histopathology confirmed bilateral mature cystic teratoma.

Case 2: A 54-year-old postmenopausal woman (BMI 38) with a prior pelvic MRI showing an 11×8×10 cm fundal leiomyoma presented with acute right lower quadrant pain and WBC 20,700/µL. Preoperative imaging suggested torsion of a pedunculated subserosal myoma. Given the degree of leukocytosis, obesity, and diagnostic uncertainty regarding mass origin, laparotomy was performed. Intraoperatively, a 12-cm multilobulated, necrotic mass was found arising from the right ovary, not the uterus. Bilateral salpingo-oophorectomy was performed. Histopathology revealed an ovarian fibroma (right) and a simple serous cyst (left).

Case 3: An 82-year-old postmenopausal woman on clopidogrel following CABG surgery was admitted to the general surgery service with suspected acute appendicitis. After 24 hours of observation without a surgical gastrointestinal diagnosis, gynaecological consultation was sought. Contrast-enhanced MRI identified a 7×6.5 cm thin-walled, peripherally enhancing paratubal cyst in the pouch

of Douglas. Clopidogrel was discontinued 3 days preoperatively with enoxaparin bridging. Laparoscopy confirmed 720° right adnexal torsion. Bilateral salpingo-oophorectomy was completed without haemorrhagic or cardiac complications. The patient was discharged on postoperative day 1.

Conclusions

These three cases illustrate that laparoscopy is the preferred approach across the age spectrum in adnexal torsion, even in high-risk patients, provided adequate perioperative optimisation is undertaken. Ovarian fibroma can closely mimic pedunculated leiomyoma on preoperative imaging, and surgical teams must be prepared to adapt intraoperatively. In elderly patients on antiplatelet therapy, multidisciplinary coordination and structured anticoagulation bridging enable safe minimally invasive surgery. Diagnostic delay remains a critical issue in postmenopausal women, as illustrated by initial misdiagnosis as appendicitis in Case 3. Fertility-sparing laparoscopic detorsion and cystectomy is the evidence-based approach in premenopausal patients, even when bilateral pathology is present.

ESGE35-0035 - P214
ePoster Presentations

Preoperative identification of low-risk endometrial polyps to guide hysteroscopic management: a machine learning model

Ido Givon[1], Or Ben Chaim[1], Ran Matot[1], Daniel Nassie[1], Chen Goldchmit[1], Adi Borovich[1]
[1]Helen Schneider Hospital for Women- Rabin Medical Center,
Department of Obstetrics and Gynaecology, Petach Tikva- Israel, Israel

Background

Accurate preoperative risk stratification of endometrial polyps is essential to guide clinical decision-making and avoid unnecessary hysteroscopic interventions. This study aimed to develop and evaluate a model based on preoperative clinical and ultrasound variables for predicting malignancy, with the goal of identifying patients at low risk in whom hysteroscopy may be safely deferred

Methods

A retrospective cohort study was conducted at a tertiary university-affiliated medical center. Women who underwent hysteroscopic polypectomy for suspected endometrial polyps between 2012 and 2024 were included. Only cases with available histopathologic diagnosis were analysed. A supervised model based on gradient boosting was developed using exclusively preoperative clinical and ultrasound variables. Model performance was evaluated using cross-validation. The study was approved by the institutional review board

Results

A total of 619 procedures in 574 women were included. Malignant or premalignant pathology was identified in 68 cases (11%), reflecting a low-prevalence clinical scenario. The model demonstrated moderate discrimination between benign and malignant lesions (AUC = 0.70). At a high-sensitivity operating threshold, sensitivity reached 0.96 with a negative predictive value of 0.98, identifying a subgroup of patients at very low risk of malignancy. The most influential predictors included postmenopausal bleeding, menopausal status, body mass index, and polyp size, all available prior to intervention

Conclusions

A model based on preoperative clinical and imaging variables enables high-sensitivity risk stratification for malignancy in endometrial polyps. Its high negative predictive value supports a potential role in identifying patients in whom hysteroscopic intervention may be safely deferred in selected cases, while maintaining oncologic safety. Prospective validation is required prior to clinical implementation.

ESGE35-0036 - P215
ePoster Presentations

Is polyp size reliable? Discrepancies between ultrasound, hysteroscopy and pathology in endometrial polyps

Ido Givon[1], Or Ben Chaim[1], Ran Matot[1], Nati Bor[1], Daniel Nassie[1], Adi Borovich[1]
[1]Helen Schneider Hospital for Women- Rabin Medical Center,
Department of Obstetrics and Gynaecology, Petach Tikva- Israel, Israel

Background

Endometrial polyp size is commonly used to guide clinical decision-making and determine the need for hysteroscopic intervention. However, its reliability across different assessment modalities remains unclear. This study aimed to evaluate discrepancies between preoperative ultrasound, intraoperative hysteroscopic assessment and pathologic measurement of polyp size, and to assess their potential clinical implications.

Methods

A retrospective cohort study was conducted at a tertiary university-affiliated medical center. Women who underwent operative hysteroscopy for suspected endometrial polyps between 2010 and 2024 were included. Only cases with complete data from transvaginal ultrasound (TVUS), hysteroscopic assessment and pathology were analyzed. Polyp size was assessed using TVUS, intraoperative hysteroscopic estimation and pathologic volumetric measurement. Correlation between modalities was evaluated, and the frequency of clinically significant discrepancies was assessed.

Results

A total of 407 women were included in the final analysis. Mean maximal diameter was 14.2 ± 6.6 mm on TVUS and 16.7 ± 9.7 mm on hysteroscopy, with a mean extracted volume of 2.95 ± 3.9 mL on pathology. Correlation between modalities was limited (ultrasound vs hysteroscopy r = 0.45; ultrasound vs pathology r = 0.31). Clinically significant discrepancies were common: in approximately 40% of cases, the difference between ultrasound and hysteroscopic measurements exceeded 5 mm, and in 19% exceeded 10 mm. These discrepancies were observed across the full range of polyp sizes.

Conclusions

Size-based assessment of endometrial polyps demonstrates limited agreement across ultrasound, hysteroscopy and pathology, with frequent clinically significant discrepancies. Reliance on size alone may lead to misestimation of polyp burden and affect surgical planning and treatment decisions. These findings challenge the reliability of size-based decision-making and support the need for more robust approaches to preoperative assessment in hysteroscopic management.

ESGE35-0052 - P217
ePoster Presentations

Comparison of Conventional Multiport Laparoscopy, Single-Port Laparoscopy, and vNOTES for the Management of Large Adnexal Masses (≥ 10 cm): A Retrospective Cohort Study MIS Approaches

Kemal Güngördük[1], Emre Biton[2], Berican Sahin Uyar[2], Serkan Ustuntas[2], Berke Nur Ergu[2], Furkan Karaoz[2]
[1]Muğla Sıtkı Koçman University, Gynelogical Oncology, Muğla, Türkiye
[2]Mugla Sıtkı Koçman University, Department of Obstetrics and Gynaecology, Muğla, Türkiye

Background

We compared the surgical outcomes and quality of recovery of conventional multiport laparoscopy (CML), Single-port laparoscopy (SPL), and vaginal natural orifice transluminal endoscopic surgery (vNOTES) for managing large adnexal masses.

Methods

This multicentre, retrospective cohort study included 87 patients who underwent salpingo-oophorectomy for benign adnexal masses ≥ 10 cm between January 2020 and December 2025 (CML: n=38, SPL: n=26, vNOTES: n=23). The evaluated parameters included surgical timing (port setup, total operation, and specimen removal times), early postoperative pain using the Visual Analog Scale (VAS) and Faces Pain Scale Revised (FPS-R), and overall quality of recovery using the QoR-40 questionnaire at 24 h postoperatively. The secondary outcomes included cosmetic scar satisfaction and sexual function.

Results

CML demonstrated the shortest port setup time (2.5 ± 0.5 min) and total operation time (61.0 ± 14.7 min) among the groups. In contrast, vNOTES and SPL provided significantly faster specimen removal times than CML (6.1 ± 1.8 min and 6.6 ± 1.3 min vs. 9.3 ± 2.2 min, respectively; $P < 0.001$). The vNOTES group reported significantly lower VAS and FPS-R scores across all early postoperative time points (6, 12, and 24 h) and achieved the highest overall QoR-40 score (153.5 ± 9.7, $P = 0.004$). Multivariate logistic regression identified the vNOTES approach as the only independent predictor of excellent recovery (QoR-40 ≥ 150) (odds ratio [OR]: 1.8, 95% confidence interval [CI]: 1.1–3.1, $P = 0.012$). No significant differences were observed in terms of estimated blood loss, intraoperative complications, or long-term sexual function among the three groups.

Conclusions

CML, SPL, and vNOTES are safe and effective minimally invasive approaches for large adnexal masses. While CML is the fastest overall, vNOTES appeared to offer benefits including efficient specimen extraction, reduced postoperative pain, and enhanced quality of recovery. Given the retrospective design, the modest sample size, and the patient-preference-based allocation, these findings should be considered hypothesis-generating and confirmed in adequately powered prospective studies.

ESGE35-0057 - P218
ePoster Presentations

Real-Time Intraoperative Transrectal Ultrasonography for Localization of Non-Visible Intramural Fibroids During Laparoscopic Myomectomy: A Case and Literature Insight

Ömer Demir[1], *Hidayet Sal*[1], *Cihan Comba*[2]
[1]*Karadeniz Technical University Faculty of Medicine, Obstetrics and Gynaecology, Trabzon, Türkiye*
[2]*Istanbul Aydın University Faculty of Medicine, Gynecologic Oncology, Istanbul, Türkiye*

Background

Accurate localization of non-visible intramural fibroids remains a major challenge during laparoscopic myomectomy, particularly in patients where transvaginal ultrasonography and bimanual palpation are not feasible. Although intraoperative ultrasound has been described, data on the use of transrectal ultrasonography (TRUS) are limited. While intraoperative ultrasound guidance has been described—most commonly using transvaginal or laparoscopic probes—reports on the use of transrectal ultrasonography in this setting remain scarce. We aimed to highlight the role of intraoperative TRUS as a real-time navigation tool in complex myomectomy.

Methods

A 35-year-old virgin patient presented with severe heavy menstrual bleeding refractory to medical therapy. Preoperative TRUS identified a 35 mm intramural fibroid on the left anterior corpus distorting the endometrium, along with two 15 mm fibroids located at the anterior and posterior fundal walls with intracavitary protrusion. Laparoscopic myomectomy was planned. Intraoperatively, the dominant fibroid was identified by its serosal protrusion and enucleated, followed by standard myometrial repair. However, the smaller fibroids were not identifiable visually or by palpation. Real-time intraoperative TRUS was therefore performed, enabling precise localization. TRUS-guided targeted serosal incisions allowed successful enucleation of the remaining fibroids, and all defects were repaired appropriately.

Results

Complete removal of all preoperatively detected fibroids was achieved. Intraoperative TRUS provided accurate real-time guidance, facilitating detection of otherwise occult intramural lesions and preventing unnecessary uterine dissection. The procedure was completed without complications.

Conclusions

In selected patients, intraoperative TRUS may serve as a highly effective adjunct to laparoscopic myomectomy, particularly when conventional localization methods fail. Given the limited data in the literature, this case supports the potential of TRUS to improve surgical precision and completeness of fibroid removal. Wider adoption and further studies are warranted to define its role in minimally invasive gynecologic surgery.

ESGE35-0062 - P219
ePoster Presentations

Vaginal Natural Orifice Transluminal Endoscopic Surgery versus Conventional Multiport Laparoscopy for Hemorrhagic Ovarian Cyst Rupture with Hemoperitoneum: A Multicentre Retrospective Cohort Study

Emre Biton[1], Serkan Ustuntas[1], Furkan Karaoz[1], Berican Sahin Uyar[1], Kemal Gungorduk[2]
[1]Mugla Sitki Kocman University, Department of Obstetrics and Gynaecology, Mugla, Türkiye
[2]Mugla Sitki Kocman University,
Department of Obstetrics and Gynaecology Division of Gynecologic Oncology, Mugla, Türkiye

Background

Objective: To compare perioperative outcomes, early postoperative pain and recovery, and patient-reported sexual and cosmetic outcomes between vaginal natural orifice transluminal endoscopic surgery (vNOTES) and conventional multiport laparoscopy (CML) in hemodynamically stable women undergoing urgent surgery for hemorrhagic ovarian cyst rupture with hemoperitoneum.

Methods

Design: Multicentre retrospective cohort study.

Setting: Departments of Obstetrics and Gynaecology of two tertiary referral centres, January 2020 through December 2025.

Participants: Forty-two non-pregnant women aged ≥18 years with imaging-confirmed hemoperitoneum from a ruptured ovarian cyst and clinical evidence of ongoing or progressive bleeding who underwent minimally invasive surgery.

Interventions: vNOTES via posterior colpotomy with a multichannel single-port device (n = 13) or CML with a 10-mm umbilical and two or three 5-mm ancillary trocars (n = 29). Approach was selected jointly by surgeon and patient based on vaginal accessibility, suspected adhesions, and surgeon experience. Both groups followed a standardized Enhanced Recovery After Surgery protocol.

Results

Outcomes were operative time; estimated blood loss; visual analog scale (VAS) pain at 6, 12, and 24 hours; length of stay; Quality of Recovery–15 (QoR-15) at discharge; complications (Clavien–Dindo); conversion; transfusion; additional analgesia; and Female Sexual Function Index (FSFI) and Female Genital Self-Image Scale (FGSIS) at 6 months. Baseline characteristics were comparable. Operative time (mean 44.6 ± 17.1 vs 49.1 ± 16.5 min; $P = .20$), blood loss (median 90 [IQR 40–180] vs 100 [50–190] mL; $P = .72$), transfusion (7.7% vs 6.9%; $P > .99$), and intraoperative complications (7.7% vs 6.8%; $P > .99$) did not differ; no conversion occurred. VAS pain at 12 hours was lower after vNOTES (1.9 ± 0.7 vs 3.2 ± 1.1; mean difference 1.3, 95% CI 0.5–2.0; $P = .002$), although 6- and 24-hour scores did not differ. FGSIS at 6 months was higher after vNOTES (24.28 ± 1.80 vs 22.31 ± 3.47; $P = .009$); FSFI total scores were similar (26.78 ± 2.53 vs 27.30 ± 3.15; $P = .38$), with a small reduction in the lubrication subscale after vNOTES (4.26 ± 0.85 vs 4.85 ± 0.88; $P = .001$). Multiplicity was not corrected.

Conclusions

In a small, non-randomized cohort of hemodynamically stable women with hemorrhagic ovarian cyst rupture, vNOTES was feasible and safe, with haemostatic efficacy comparable to CML. Differences in 12-hour pain and genital self-image are hypothesis-generating and should be confirmed in adequately powered prospective studies.

ESGE35-0068 - P220
ePoster Presentations

Total Vaginal Natural Orifice Transendoscopic Hysterectomy versus Single-Incision Laparoscopic Hysterectomy in Patients with a Narrow Pubic Arch

Kemal Güngördük[1], *Emre Biton*[2], *Serkan Ustuntas*[2], *Berican Sahin Uyar*[2]
[1]*Muğla Sıtkı Koçman University, Gynelogical Oncology, Muğla, Türkiye*
[2]*Mugla Sitki Kocman University, Department of Obstetrics and Gynaecology, Mugla, Türkiye*

Background

Aim: This study aimed to compare the intraoperative and postoperative outcomes of total vaginal natural orifice transendoscopic hysterectomy (TVNH) and single-incision laparoscopic hysterectomy (SILH) in patients with a narrow pubic arch.

Methods

This observational retrospective study was conducted at the Department of Obstetrics and Gynaecology between January 2023 and September 2025.

Results

Among patients scheduled for hysterectomy with a narrow pubic arch, 30 patients (65.2%) underwent the SILH procedure, while 16 patients (34.8%) underwent the TVNH procedure. Hysterectomy combined with oophorectomy was performed in 25 patients (83.3%) in the SILH group and in 13 patients (81.3%) in the TVNH group. The operative duration was significantly longer in the TVNH group compared to the SILH group (83.1 ± 13.7 vs. 74.5 ± 12.3 minutes; $P = 0.036$). No major intraoperative complications were observed in either group. During the postoperative period, patients in the TVNH group demonstrated significantly lower mean scores on both the Visual Analog Scale and the Faces Pain Scale-Revised. In addition, at the 48th postoperative hour, the Quality of Recovery-15 score was significantly higher in the TVNH group.

Conclusions

Despite a relatively longer operative time in patients with a narrow pubic arch, TVNH provides several advantages, including reduced postoperative pain, improved cosmetic outcomes, enhanced quality of recovery, and no increase in complication rates.

ESGE35-0071 - P221
ePoster Presentations

The Role of Vaginal Natural Orifice Transendoscopic Surgery in Gynecological Emergencies

Emre Biton[1], Serkan Ustuntas[1], Kemal Gungorduk[2]
[1]Mugla Sitki Kocman University, Department of Obstetrics and Gynaecology, Mugla, Türkiye
[2]Mugla Sitki Kocman University,
Department of Obstetrics and Gynaecology Division of Gynecologic Oncology, Mugla, Türkiye

Background

Transvaginal natural orifice transluminal endoscopic surgery (vNOTES) represents an innovative and minimally invasive surgical technique that is increasingly recognized across various gynecological applications. While the body of evidence regarding vNOTES is currently more limited compared to traditional laparoscopy, this technique presents distinct benefits, such as reduced blood loss, shorter operative times, lower postoperative pain, faster recovery and hospital discharge, improved aesthetic outcomes, and fewer postoperative complications. Despite the growing support for vNOTES in the management of elective adnexal conditions, its application, safety, and efficacy in emergency settings remain insufficiently studied. This report aims to detail our clinical experience and provide insights into employing vNOTES for managing gynecological emergencies.

Methods

A retrospective analysis was conducted by evaluating data from patients who underwent vNOTES for gynecological emergencies in two Gynaecology centres between January 2023 and December 2025. Relevant demographic information and perioperative outcomes were collected and analysed.

Results

A total of 40 patients were enrolled in this study. The procedures were performed to manage gynaecological emergencies, including suspected ectopic pregnancies in 19 patients (47.5%), suspected adnexal torsion in 6 patients (15.0%), hemoperitoneum post-hysterectomy in 5 patients (12.5%), pelvic abscess in 4 patients (10.0%), and ruptured ovarian cysts in 6 patients (15.0%). Surgical interventions included unilateral salpingectomy (47.5%), ovarian cystectomy (12.5%), adnexal detorsion (10.0%), oophorectomy (7.5%), hemoperitoneum evacuation (15.0%), and combined abscess drainage with appendectomy (7.5%). The median operative time was 39 minutes, ranging from 24 to 72 minutes. Median estimated blood loss was 150 mL, with a range of 30 to 350 mL, and no intraoperative complications were reported. All surgeries were successfully completed using vNOTES, with no need for conversion to standard laparoscopy or open surgery. The median hospital stay post-surgery was 2 days, varying between 1 and 5 days. Postoperative pain, evaluated using the visual analog scale, indicated a median score of 2 (range: 1-5) at the 24-hour mark. No procedure-related complications were identified.

Conclusions

This study showcases the clinical applicability of vNOTES procedures for addressing emergency gynaecological conditions, such as tubal ectopic pregnancy, adnexal torsion, painful ovarian disorders, post-hysterectomy hemoperitoneum, and severe uterine bleeding. Supported by existing literature, our findings suggest vNOTES may offer certain benefits when compared to conventional laparoscopy in managing these conditions.

ESGE35-0073 - P222
ePoster Presentations

vNOTES Parasitic Myomectomy and Abdominal Wall Repair Following Total Laparoscopic Hysterectomy: A Case Report

Tomonori Hada[1]
[1]*Yotsuya Medical Cube, Gynaecology, Tokyo, Japan*

Background

Parasitic leiomyomas can occur at various intra-abdominal sites following laparoscopic myomectomy (LM) without in-bag morcellation. Large leiomyomas in the anterior abdominal wall are often difficult to manage laparoscopically due to restricted instrument range of motion. We report a case of a 12 cm abdominal wall parasitic leiomyoma successfully treated using a hybrid approach involving total laparoscopic hysterectomy (TLH) and vaginal natural orifice transluminal endoscopic surgery (vNOTES).

Methods

A woman in her 40s (G0) with a history of LM 12 years prior presented with urinary frequency and abdominal bloating due to multiple uterine fibroids. Surgery was initiated laparoscopically. A 12 cm mass, preoperatively suspected to be a subserosal fibroid, was identified as a parasitic leiomyoma located subperitoneally in the left lower anterior abdominal wall. Due to instrument interference, the port configuration was changed to a right ipsilateral approach. Following TLH, a vaginal access platform was used to transition to vNOTES for the management of the parasitic mass, as it was outside the reach of transabdominal instruments.

Results

Under vNOTES visualization, the parasitic leiomyoma was successfully enucleated through gradual dissection. The resulting defects in the posterior rectus sheath and parietal peritoneum were repaired using barbed sutures under vNOTES guidance. Subsequently, a smaller parasitic leiomyoma on the rectal serosa was resected laparoscopically, and the vaginal vault was closed. The specimen weights were 222 g for the uterus and 482 g for the parasitic leiomyoma. The patient recovered without complications.

Conclusions

The vNOTES approach provides excellent visualisation and manoeuvrability for anterior abdominal wall lesions that are difficult to reach via conventional transabdominal ports. This hybrid technique allows for safe enucleation and reliable suturing of fascial defects, serving as a valuable minimally invasive alternative to laparotomy for large parasitic leiomyomas.

ESGE35-0081 - P223
ePoster Presentations

Randomized Controlled Pilot Study of an Inhaled Analgesic for Pain Reduction during Outpatient Intrauterine Procedures

Sarah Smith[1], *Nina Wingate*[2]
[1]*University of Saskatchewan, Department of Obstetrics and Gynaecology, Regina, Canada*
[2]*University of Saskatchewan, Obstetrics and Gynaecology, Regina, Canada*

Background

The objective of the study is to evaluate the feasibility, safety, and preliminary efficacy of an inhaled analgesic as an adjunct for pain control during outpatient endometrial biopsy and intrauterine device insertion.

Methods

A randomized, double-blind, placebo-controlled pilot study was conducted in outpatient Gynaecology clinics. Eligible participants undergoing intrauterine device insertion or endometrial biopsy were randomized 1:1 to receive either inhaled analgesic or placebo. Pain was assessed using a Numeric Rating Scale during the procedure and at 30 minutes post-procedure. Secondary outcomes included patient satisfaction, willingness to recommend the intervention, and adverse events.

Results

Ten participants were enrolled (n=10). The inhaled analgesic group demonstrated lower mean pain scores during the procedure compared to placebo (4.0 vs 5.2) and at 30 minutes post-procedure (4.0 vs 5.0). post-procedural pain was low in both groups (1.2 vs 1.8 at 30 minutes). Patient satisfaction scores were higher in the intervention group (mean 3.4 vs 2.8), and a greater proportion of participants reported willingness to recommend the intervention (100% vs 80%). Adverse effects were mild and well tolerated. Dizziness was reported in 40% of the intervention group. No serious adverse events were observed.

Conclusions

This pilot study demonstrates that a randomized trial of an inhaled analgesic for outpatient intrauterine procedures is feasible and well tolerated. Preliminary findings suggest a potential reduction in procedural pain and improved patient satisfaction. A fully powered randomized controlled trial is warranted to determine clinical efficacy and inform integration into outpatient gynecologic practice.

ESGE35-0085 - P224
ePoster Presentations

Text-Based Risk Stratification of Adnexal Masses From Pelvic Imaging Reports Using a Large Language Model: A Histopathology-Correlated Exploratory Study

Burak Cakmak[1], *Harika Yumru Celiksoy*[2], *Caglasu Keles Sancaktar*[3]
[1]*Mus State Hospital, Obstetrics and Gynaecology, Mus, Türkiye*
[2]*Sisli Etfal Research and Training Hospital, Department of Gynecological Oncology, Istanbul, Türkiye*
[3]*Tepecik Research and Training Hospital, Department of Obstetrics and Gynaecology, Izmir, Türkiye*

Background

Accurate preoperative risk stratification of adnexal masses guides the decision between conservative laparoscopic management and referral to gynaecologic oncology. Pelvic magnetic resonance imaging (MRI) reports in routine practice are typically narrative rather than structured, and large language models (LLMs) have been proposed as decision-support tools for unstructured clinical text. The reliability of LLMs for higher-order diagnostic reasoning on real-world reports, however, remains poorly characterised. We evaluated how a contemporary general-purpose LLM interprets narrative pelvic MRI reports for adnexal mass risk stratification, using final histopathology as the reference standard.

Methods

In this retrospective, single-centre exploratory diagnostic study, we identified 60 consecutive patients who underwent pelvic MRI for an adnexal mass and subsequent surgery with definitive histopathology between January 2022 and June 2025. All MRI reports were generated by a single gynaecologic radiologist under real-world reporting conditions, without structured templates. Anonymised report texts were submitted in a zero-shot configuration to a commercially available LLM (ChatGPT 5.2®, OpenAI), with web browsing disabled and a uniform prompt across all cases. The model was blinded to images and clinical data and classified each lesion as benign, intermediate, or malignant. The reference standard was final surgical histopathology. For binary analysis, intermediate lesions were grouped with malignant. Sensitivity, specificity, and overall accuracy were computed; confidence intervals were not estimated given the exploratory design. Reporting followed STARD-AI and TRIPOD-AI where applicable.

Results

Final histopathology yielded 50 benign (83.3%), 4 borderline (6.7%), and 6 malignant (10.0%) lesions; median age was 53 years (range 18–85). For malignant versus non-malignant classification, the LLM showed sensitivity 90.0% (9/10), specificity 42.0% (21/50), and overall accuracy 50.0% (30/60)—below the 83.3% no-information benign-prevalence baseline. All 4 borderline lesions were classified as malignant. Among truly benign lesions, 23/50 (46%) were misclassified as malignant; false positives clustered systematically in lesions with descriptive complexity (wall irregularity, septations, heterogeneous signal, septal enhancement)—commonly torsion/infarction, degenerative leiomyomas, stromal tumours, and large benign cystic lesions. The single false negative was an early-stage tubal high-grade serous carcinoma with sparse imaging descriptors.

Conclusions

A general-purpose LLM applied to narrative pelvic MRI reports yields high sensitivity but unacceptably low specificity for adnexal mass risk stratification, with overall accuracy below the trivial benign-baseline. Errors are non-random and driven by descriptive complexity rather than malignant biology, with a substantial false-positive burden that would translate into unnecessary oncologic referral and overtreatment. LLMs in this setting should be framed as supervised, human-in-the-loop adjuncts—not autonomous triage tools—pending prospective validation with structured prompting (e.g., O-RADS MRI lexicon) and multimodal input.

ESGE35-0086 - P225
ePoster Presentations

Comparison of two-layer interrupted and continuous suturing in laparoscopic repair of caesarean scar defect: a retrospective cohort study

Nobuta Yuri[1], *Yuji Tanaka*[1], *Shunichiro Tsuji*[1]
[1]*Shiga University of Medical Science, Obstetrics and Gynaecology, Otsu, Japan*

Background

While laparoscopic repair is increasingly performed to restore residual myometrial thickness in caesarean scar defect (CSD), the optimal suturing technique remains controversial. This study aimed to compare the surgical and clinical outcomes of two-layer interrupted suturing versus two-layer continuous suturing in the laparoscopic repair of CSD.

Methods

A retrospective cohort study was conducted on patients who underwent laparoscopic CSD repair at Shiga University of Medical Science Hospital between March 2021 and August 2025. Surgery was performed for symptomatic CSD, including abnormal uterine bleeding, dysmenorrhea, and secondary infertility. Exclusion criteria included cases with concomitant laparoscopic myomectomy or cystectomy, and cases with incomplete data. Patients were divided into two groups: the interrupted group (two-layer interrupted sutures) and the continuous group (two-layer continuous sutures using barbed sutures). Residual myometrial thickness (RMT) was measured via magnetic resonance imaging before and three months postoperatively. Clinical outcomes, including dysmenorrhea improvement (evaluated by a numerical rating scale), bleeding duration, and postoperative pregnancy rates over 18 months, were compared. This study was approved by the ethics committee of Shiga University of Medical Science.

Results

The study included 63 cases (27 interrupted; 36 continuous). Patient baseline characteristics were comparable between groups. The operative time was significantly longer in the interrupted group (median 201 minutes) than in the continuous group (median 133 minutes; $p < 0.0001$). However, the postoperative RMT was significantly thicker in the interrupted group (median 9.0 mm) than in the continuous group (median 6.0 mm; $p < 0.0001$). The mean RMT increase was also significantly greater in the interrupted group (7.3 mm) than in the continuous group (2.8 mm; $p < 0.0001$). Furthermore, the improvement in dysmenorrhea was significantly better in the interrupted group (change in NRS: -3 vs. -2; $p = 0.017$). No significant differences were found in the reduction of bleeding duration (-7 days in the interrupted group vs. -5 days in the continuous group) or postoperative pregnancy rates (65% in the interrupted group vs. 73% in the continuous group).

Conclusions

While two-layer interrupted suturing involves longer operative times compared to continuous suturing, it results in significantly superior anatomical restoration of the myometrium and better

improvement of dysmenorrhea. From the perspective of the quality of anatomical repair and clinical symptom relief, interrupted suturing is considered the recommended technique.

ESGE35-0092 - P226
ePoster Presentations

Huge Cervical Tumor: Lymphoma

Tomasz Łatkiewicz[1], *Rafał Tarkowski*[1]
[1]*University Clinical Hospital No. 1,*
I Chair and Department of Oncological Gynaecology and Gynaecology, Lublin, Poland

Background

Patient, 51 years old. Last menstrual bleeding was more than 1 year ago. She was after 2 caesarean section. 14 months after last menstruation she noticed abnormal uterine bleeding and moderate pelvic pain. She regularly visited a gynaecologist. During examination, there was large cervical tumour. Cervical biopsy was performed. Initial diagnosis was Aggressive Angiomyxoma. MRI scan described: cervical tumour, with the largest dimension: 10cm. Parametrium were involved. No distant metastasis were described.

Methods

Patient had laparoscopy. There were massive adhesions which were removed. Hysterectomy with bilateral salpingo-oophorectomy and vaginal cuff, ureterolysis was performed

Results

Final histopathological result was aggressive B-cell lymphoma. Patient was referred to a haematologist. In positron emission tomography (PET-CT) there were not any suspicion of cancer metastasis. She had 6 cycles of chemotherapy. After treatment there is no evidence of cancer relapse.

Conclusions

Primary lymphoma of the uterine cervix is a very rare tumor. Symptoms are not specific. Most common are abnormal uterine bleeding, dyspareunia and pelvic pain. Average age of diagnosis is 55 years old. Cervical screening is not proper for diagnosis, because lymphoma grows from cervical stroma. There is no clear treatment for cervical lymphoma. Usually, it is combination of radiotherapy, chemotherapy and surgery. Lymphomas respond well to chemotherapy so it should be used as a primary treatment. Treatment should be decided during oncological consilium. Because of the rarity of cervical lymphoma, it should be treated in experienced department.

ESGE35-0093 - P227
ePoster Presentations

A Novel Minimally Invasive Test for Endometrial Cancer Detection: Clinical Validation of Molecular-Augmented Cytology (Akt/mTOR/Pax-2)

Xi Yang[1], Ke Ma[1], Yiting Meng[2], Jia Wen[1], Rui Chen[1], Ginping Liao[1]
[1]Beijing Tsinghua Changgung Hospital- School of Clinical Medicine- Tsinghua University, Department of Obstetrics and Gynaecology, Beijing, China
[2]Beijing Tsinghua Changgung Hospital- School of Clinical Medicine- Tsinghua, Department of Pathology, Beijing, China

Background

Endometrial carcinoma (EC) is now the leading gynecologic cancer in many high-income cities and regions worldwide. Against this background, and with the recent launch of screening for high-risk women in Beijing, there is an urgent need for well-tolerated diagnostic tools. This study aims to verify a minimally invasive detection strategy, which combines the collection of endometrial cells for smear examination with the detection of Akt, mTOR and Pax-2 by immunocytochemistry (ICC), in order to improve the accuracy of screening.

Methods

This prospective study evaluated a pre-specified sample of 92 patients undergoing hysteroscopy (32 EC, 30 benign lesions, 30 normal endometrium). Endometrial cells were collected using the endometrial sampler and prepared as liquid-based cytology (LBC) thin-layer smears procedure. All cytological samples were diagnostically interpreted by experienced cytopathologists. ICC for Akt, mTOR, and Pax-2 was subsequently performed on the sample slides. Diagnostic performance was assessed using receiver operating characteristic (ROC) analysis. Biomarker expression levels (H-scores) from ICC were compared with tissue immunohistochemistry (IHC) results from corresponding histological specimens.

Results

Initial cytological assessment of the endometrial cell samples demonstrated a sensitivity of 76.0% for detecting EC, and 87.5% for identifying atypical hyperplasia and EC cases. ICC analysis revealed significant upregulation of Akt and mTOR in EC, alongside marked downregulation of Pax-2 compared to benign and normal cohorts ($p < 0.01$). The combined biomarker-cytology approach demonstrated superior diagnostic performance over tissue IHC. Specifically, this result indicates that the ICC detection targeting Akt and mTOR has higher specificity while still maintaining high sensitivity. The areas under the ROC curves for all ICC markers exceeded 0.85, confirming the enhanced diagnostic value of the cytology-based approach.

Conclusions

This study establishes that immunocytochemical (ICC) biomarkers (Akt, mTOR, and Pax-2)-augmented liquid-based endometrial cytology is a highly accurate and minimally invasive diagnostic tool for EC. It demonstrates superior accuracy compared to conventional methods such as transvaginal ultrasound

(TVS) and standard cytology alone. The robust performance observed in this study supports the implementation of this approach in future multi-center screening trials.

ESGE35-0095 - P228
ePoster Presentations

Prospective Evaluation of Vaginoplasty With a Novel Porcine-Derived Acellular Double-Sided Bio membrane for Mayer–Rokitansky–Küster–Hauser Syndrome

Na Chen[1], *Lan Zhu*[1]
[1]*Peking Union Medical College Hospital, Obstetrics & Gynaecology, Beijing, China*

Background

To prospectively evaluate the safety and efficacy of vaginoplasty using a novel porcine-derived acellular double-sided bio membrane in patients with Mayer–Rokitansky–Küster–Hauser syndrome, with safety assessed by vital signs, laboratory parameters, and the incidence of adverse events, and efficacy evaluated in terms of anatomical (vaginal length and width), histological (epithelialization), and functional (sexual function) outcomes.

Methods

We conducted a prospective observational study involving five patients with MRKH syndrome undergoing primary vaginoplasty using a novel porcine-derived acellular double-sided bio membrane graft as a scaffold. Patients were followed up at 1, 3, 6, and 12 months postoperatively. Safety was assessed via clinical evaluations and the incidence of adverse events. Efficacy was evaluated based on anatomical (neovaginal length and width), histological (epithelialization via colposcopy and cytology), and functional (Female Sexual Function Index, FSFI) outcomes. The study was approved by the institutional ethics committee, and informed consent was obtained from all participants.

Results

All five patients underwent successful vaginoplasty without intraoperative complications. Anatomical outcomes were satisfactory in all patients, with neovaginal length maintained at 8 cm (range 8–8 cm) at 1 month, 8 cm (range 6–10 cm) at 3 months, 8 cm (range 8–10 cm) at 6 months, and 9 cm (range 8–9 cm) at 12 months; vaginal width consistently allowed accommodation of 2–3 fingerbreadths throughout follow-up. Histologically, colposcopy and TCT demonstrated complete squamous epithelialization of the neovagina by 3 months, with sustained epithelialization at 6 months. Functionally, only one patient resumed regular sexual activity at 4 months postoperatively, reporting satisfactory sexual function with an FSFI score of 31.5. Regarding safety, one patient developed a postoperative urinary tract infection that resolved with conservative treatment, and no other severe, late, or graft-related complications, including vaginal stenosis or abnormal discharge, were observed during follow-up.

Conclusions

This biomaterial-based vaginoplasty is safe, feasible, and effective for MRKH syndrome, with favourable anatomical and functional outcomes; further multicentre validation is needed.

ESGE35-0107 - P229
ePoster Presentations

Improving Early Postoperative Follow-up after Benign Gynecologic Surgery

Asha Bhalwal[1], *Domnique Jhonson*[2], *Aya Mohr Sasson*[3]
[1]*McGovern Medical School at The University of Texas Health Science Center, Department of Obstetrics- Gynaecology & Reproductive Sciences- Division of Advanced Minimally Invasive Gynaecology Surgery, Houston, USA*
[2]*McGovern Medical School UT Health Obstetrics and Gynaecology Houston TX USA, Obstetrics and Gynaecology - Division of Minimally Invasive Gynaecology Surgery, Houston, USA*
[3]*McGovern Medical School at The University of Texas Health Science Center, Obstetrics and Gynaecology - Division of Advanced Minimally Invasive Gynaecology Surgery, Houston, USA*

Background

Study Objective:

To evaluate the impact of postoperative day 1 follow-up calls performed by residents compared with designated personnel (physician assistants) on follow-up rates, patient satisfaction, and postoperative communication after benign gynecologic surgery within an enhanced recovery after surgery (ERAS) protocol.

Methods

Design:

Retrospective cohort study.

Setting:

Tertiary academic medical center.

Patients or Participants:

Women undergoing elective benign gynecologic surgery within an ERAS pathway.

Interventions:

Postoperative day 1 follow-up phone calls were conducted by residents during one 3-month period and by designated personnel (physician assistants) during a separate 3-month period. Outcomes were compared between groups.

Results

A total of 225 patients were included, of whom 77 (34%) received postoperative follow-up by residents and 148 (66%) by physician assistants. The proportion of patients successfully contacted increased significantly in the physician assistant group (100 [67%] vs 33 [42%]; p=0.002), representing a 25% absolute increase.

Patient-initiated calls to the clinic decreased from 25% in the resident group to 20% in the physician assistant group; however, this difference did not reach statistical significance (p=0.120).

Patients in the physician assistant group more frequently reported postoperative concerns, including urinary symptoms (19 [12.8%] vs 1 [1.3%]; p=0.004) and vaginal bleeding (26 [17.6%] vs 4 [5.2%]; p=0.011). Additionally, patients reported greater comfort in sharing concerns when contacted by physician assistants (48 [33%] vs 8 [10.5%]; p=0.001). Overall satisfaction was similar between groups (p=0.38).

There were no significant differences in emergency department visits or hospital readmissions between groups.

Conclusions

Postoperative day 1 follow-up conducted by physician assistants within an ERAS pathway was associated with higher successful contact rates and improved patient-reported communication without increasing healthcare utilization. These findings support the use of designated personnel to enhance early postoperative care after benign gynecologic surgery.

ESGE35-0108 - P230
ePoster Presentations

Beyond the Incision: Enhancing Recovery In Vnotes Hysterectomy with Vaginal Cuff Liposomal Bupivacaine Block

Asha Bhalwal[1], Claire Lewis[2], Aya Mohr sason[2], Alvaro Montealgre[2]
[1]McGovern Medical School at The University of Texas Health Science Center, Department of Obstetrics- Gynaecology & Reproductive Sciences, Houston, USA
[2]McGovern Medical School at The University of Texas Health Science Center, Department of Obstetrics- Gynaecology & Reproductive Sciences- Division of Advanced Minimally Invasive Gynaecology Surgery, Houston, USA

Background

Study Objective: To evaluate whether local vaginal cuff infiltration with liposomal bupivacaine improves perioperative pain control in patients undergoing vaginal natural orifice transluminal endoscopic surgery (vNOTES) hysterectomy for benign indications.

Methods

Design: Retrospective cohort study.

Setting: Tertiary academic medical center.

Patients or Participants: Women undergoing vNOTES hysterectomy for benign indications between October 2024 and March 2026. Patients undergoing concomitant procedures or conversion to an alternative surgical approach were excluded.

Interventions: Beginning November 2025, routine vaginal cuff infiltration with liposomal bupivacaine (Exparel®) was introduced. The protocol consisted of 20 mL bupivacaine mixed with 20 mL liposomal bupivacaine and 20 mL normal saline (total 60 mL), administered circumferentially prior to colpotomy (40 mL) and at cuff closure (20 mL). Prior to implementation, patients received 40 mL ropivacaine with epinephrine alone.

Results

Seventy-seven patients met inclusion criteria, including 13 (17%) in the liposomal bupivacaine group and 64 (83%) in the standard local anaesthetic group. Baseline demographic and clinical characteristics were comparable between groups. Approximately half of cases in both groups were performed for abnormal uterine bleeding due to fibroids, and robotic assistance was used in 92% versus 72%, respectively. Mean Foley catheter duration was similar (86 vs. 97 minutes; p=0.23), and no conversions occurred. Composite complication rates were comparable between groups. Immediate postoperative pain scores were low (VAS 2 [1–3] vs. 2 [1–2]; p=0.26), as were postoperative day 1 pain scores (VAS 4 [1–5] vs. 4 [3–6]; p=0.97).

Conclusions

Vaginal cuff infiltration with liposomal bupivacaine during vNOTES hysterectomy is feasible and may offer a trend toward improved immediate postoperative analgesia; however, no significant difference

in pain outcomes was demonstrated in this small cohort. Given the limited sample size and potential for type II error, further prospective, adequately powered studies are needed to better define its role in multimodal pain control strategies in minimally invasive gynecologic surgery.

ESGE35-0109 - P231
ePoster Presentations

Precision Meets Access: Robotic Vs Laparoscopic Vnotes Hysterectomy Outcomes

Asha Bhalwal[1], Claire Lewis[2], Alvaro Montealgre[2], Aya Mohr Sasson[2]
[1]McGovern Medical School at The University of Texas Health Science Center, Department of Obstetrics- Gynaecology & Reproductive Sciences, Houston, USA
[2]McGovern Medical School at The University of Texas Health Science Center, Department of Obstetrics- Gynaecology & Reproductive Sciences- Division of Advanced Minimally Invasive Gynaecology Surgery, Houston, USA

Background

To compare perioperative outcomes of robotic-assisted vaginal natural orifice transluminal endoscopic surgery (RA-vNOTES) versus laparoscopic-assisted vNOTES (LA-vNOTES) hysterectomy, with a focus on composite surgical outcomes.

Methods

Design: Retrospective cohort study.

Setting: Tertiary academic medical center.

Patients or Participants: Women undergoing vNOTES hysterectomy for benign indications between October 2024-March 2026 were included. Patients undergoing concomitant major procedures were excluded. Cases were grouped based on surgical approach: robotic-assisted (RA-vNOTES) versus laparoscopic-assisted (LA-vNOTES).

Interventions: RA-vNOTES procedures were performed using a robotic platform for visualization and instrumentation through a transvaginal access port. LA-vNOTES cases utilized conventional laparoscopic instrumentation through a similar transvaginal approach. Standardized perioperative protocols were applied across both groups.

Results

A total of 77 women underwent vNOTES hysterectomy, including 58 (76%) robotic-assisted and 19 (24%) conventional procedures. Baseline demographic characteristics were comparable between groups. Mean uterine volume, assessed by transvaginal ultrasound, was significantly larger in the robotic group (312 mm^3 vs. 177 mm^3; p=0.02). Surgical indications differed, with fibroids more common in the robotic cohort (60%), whereas abnormal uterine bleeding predominated in the conventional group (30%) (p=0.008).

Mean operative time was shorter in the robotic group (145 vs. 156 minutes), although this difference was not statistically significant (p=0.63). No cases required conversion to an alternative surgical approach. The composite complication rate did not differ significantly between groups. Postoperative pain, assessed using the visual analog scale (VAS), was low and comparable between groups both immediately postoperatively and on follow-up.

Conclusions

RA-vNOTES is a feasible and safe approach compared to LA-vNOTES, with comparable composite outcomes. Robotic integration may offer advantages in ergonomics, visualization, and surgical precision. Further prospective studies are needed to define its role in optimizing vNOTES outcomes.

ESGE35-0110 - P232
ePoster Presentations

Prenatal Detection of Uterine Scar Defect at Routine Anatomy Ultrasound

Asha Bhalwal[1], Aya Mohr Sasson[2], Mallory Vial[2], Edgar Hernandez[3], Eleazor Soto[3]
[1]McGovern Medical School at The University of Texas Health Science Center, Department of Obstetrics- Gynaecology & Reproductive Sciences, Houston, USA
[2]McGovern Medical School at The University of Texas Health Science Center, Department of Obstetrics- Gynaecology & Reproductive Sciences- Division of Advanced Minimally Invasive Gynaecology Surgery, Houston, USA
[3]McGovern Medical School at The University of Texas Health Science Center, Department of Obstetrics- Gynaecology & Reproductive Sciences- Division of Maternal Fetal Medicine, Houston, USA

Background

Rising caesarean delivery rates have increased the prevalence of uterine scar defects, which are associated with serious pregnancy complications including uterine rupture, abnormal placentation, and preterm birth. Despite these risks, there is no standardized approach to evaluating caesarean scar integrity during pregnancy. Early detection during routine imaging presents an opportunity for innovation in prenatal diagnosis and management. We aimed to assess current practice patterns and clinical decision-making when uterine scar defects are identified in the second trimester.

Methods

Design: Cross-sectional quality improvement study using a structured questionnaire; no longitudinal follow-up.

Setting: Tertiary academic medical center with integrated Maternal-Fetal Medicine (MFM) and minimally invasive gynecologic surgery collaboration.

Patients or Participants: Thirty-four MFM-trained sonographers and providers participated; 59% had ≥5 years of experience. Participants were surveyed regarding real-world clinical encounters; no direct patient enrolment was required.

Interventions: Administration of a multiple-choice questionnaire assessing timing of scar evaluation, diagnostic criteria, use of adjunct imaging, multidisciplinary consultation, and management strategies.

Results

Ninety-seven percent of respondents reported encountering uterine scar defects prenatally. Evaluation was performed in 23% of first trimester scans and increased to 62% during anatomy ultrasound. Common diagnostic criteria included bulging membranes (82%) and fetal parts within the defect (62%). MRI was utilized by 24%. Management strategies varied: 47% recommended serial ultrasound, 53% early inpatient monitoring, and 70% planned delivery at 36–37 weeks. While 73% acknowledged feasibility of prenatal repair, only 65% would recommend intervention.

Conclusions

Significant variability exists in prenatal detection and management of uterine scar defects. Standardized diagnostic criteria and multidisciplinary, minimally invasive strategies represent critical opportunities to improve maternal outcomes. Further prospective studies are needed to guide evidence-based clinical protocols.

ESGE35-0116 - P233
ePoster Presentations

Nature of hematocolpos in obstructive uterovaginal malformations: cohort study of 68 patients

Liang Ze[1], Liu Yuanhao[2], Xijuan Lin[3], Yu Qianlan[1], Wang Wenze[2], Zhu Lan[1]
[1]Peking Union Medical College Hospital,
Department of Obstetrics and Gynaecology- National Clinical Research Center for Obstetric and Gynecologic Diseases, Beijing, China
[2]Peking Union Medical College Hospital, Department of Pathology, Beijing, China
[3]Peking Union Medical College Hospital- Peking Union Medical College- Chinese Academy of Medical Sciences,
Department of Obstetrics and Gynaecology- National Clinical Research Center for Obstetric and Gynecologic Diseases, Beijing, China

Background

Obstructive uterovaginal malformations are rare but consequential congenital anomalies requiring timely surgical intervention. Although hematocolpos is a hallmark of these malformations, its histopathological nature–whether it is a true vaginal structure or an acquired cavity formed by menstrual accumulation–remains unclear, limiting accurate classification, pathogenesis interpretation, and surgical decision-making.

Methods

This cohort study included 68 treatment-naïve patients with mid vaginal septum, distal vaginal atresia, or oblique vaginal septum syndrome, diagnosed by both MRI and surgical findings. Hematocolpos specimens were obtained from the vaginal fornix during vaginal reconstruction or hysterosalpingectomy, or from the vaginal septum in oblique vaginal septum syndrome. Detailed histopathological and immunohistochemical analyses were performed, with epithelial characteristics across malformation subtypes compared.

Results

Absence of an epithelial lining was identified in 18 /22 mid vaginal septum, 19 /28 distal vaginal atresia, 5 /12 oblique vaginal septum syndrome with intact septum, and 3/6 oblique vaginal septum syndrome with separate hemiuterus cases. When present, the lining consisted of cervical columnar epithelium or, uniquely in oblique vaginal septum syndrome with intact septum, GATA3-positive columnar cells consistent with Gartner's duct-derived epithelium.

Conclusions

These findings demonstrate that hematocolpos in mid vaginal septum, distal vaginal atresia, and oblique vaginal septum syndrome with separate hemiuterus represents an acquired cavity formed by menstrual accumulation rather than a congenital vaginal segment, challenging current classification systems and supporting reconstruction procedures. Conversely, oblique vaginal septum syndrome with intact septum preserves a Gartner's duct-derived epithelialized structure across infancy to adolescence, highlighting the need for early recognition and longitudinal management.

ESGE35-0123 - P235
ePoster Presentations

Reducing Fitz-Hugh-Curtis syndrome symptoms by laparoscopic perihepatic adhesiolysis

Dr Sayed Elakhras[1], Vasilios Tanos[2], Mohamed Salama[3], Damianos Michaelides[4], Maya Sophie de Wilde[5]
[1]Omam Hospital, Minimally Invasive Gynecological Surgery, Giza, Egypt
[2]Medical School- University of Nicosia- Cyprus , Obstetrics and Gynaecology, Nicosia, Cyprus
[3]Ain Shams University, Obstetrics and Gynaecology, Cairo, Egypt
[4]Cyprus Institute of Neurology and Genetics, Department of Biostatistics, Nicosia, Cyprus
[5]Faculty of Medicine- Carl von Ossietzky University, Obstetrics and Gynaecology, Oldenburg, Germany

Background

Perihepatic adhesions are an under-recognized consequence of intra-abdominal inflammation, especially associated with pelvic inflammatory disease and Fitz–Hugh–Curtis syndrome.
Although often asymptomatic, patients may present with right upper quadrant pain and atypical cardiopulmonary or gastrointestinal symptoms, leading to diagnostic challenges.
This study evaluates the clinical presentation, intraoperative findings, and outcomes of laparoscopic adhesiolysis in affected patients.

Methods

A retrospective cohort study was conducted including 118 women aged 18–47 years (mean 33 years) who underwent laparoscopic adhesiolysis for perihepatic adhesions.
Patient demographics, infertility characteristics, imaging findings, intraoperative adhesion patterns, and postoperative outcomes were analysed

Results

Most patients were in their early thirties with a mean BMI of 27.7. Infertility was nearly equally distributed between primary (49%) and secondary (51%). Preoperative imaging was frequently inconclusive, with 53% of MRI scans showing no significant findings.

Intraoperatively, adhesions were heterogeneous: dense (45%) and vascular (43%) adhesions predominated over filmy adhesions (24%), with partial liver surface involvement being most common. Bowel adhesions were present in approximately 20% of cases, while omental involvement was less frequent. Concomitant pelvic pathology, including adhesions, endometriosis, and fibroids, was common.

Laparoscopic adhesiolysis was safe, with no recorded intraoperative or postoperative complications. The mean operative time was 39 minutes, and 76% of patients were discharged within 12 hours.

Significant symptomatic improvement was observed postoperatively. Pleuritic-like pain decreased from 50% to 1%, pain in the right upper quadrant from 55% to 1.7%, and shortness of breath from 47% to 2%. Upper gastrointestinal symptoms, including dyspepsia, regurgitation, and hyperacidity, resolved completely.

Conclusions

Perihepatic adhesions represent a clinically significant but often overlooked source of abdominal, cardiopulmonary, and gastrointestinal symptoms.
Laparoscopic adhesiolysis is a safe and effective intervention, providing substantial symptom relief and diagnostic clarity. The frequent association with pelvic pathology highlights the importance of comprehensive laparoscopic evaluation.
Increased awareness of this condition may improve diagnosis and optimise patient management in gynaecological and endoscopic surgical practice.

ESGE35-0125 - P236
ePoster Presentations

Measurement of uterine contractility in patients with recurrent implantation failure

Dr Sayed Elakhras[1], Mohamed Elsemary[2], Ahmed Faheem[2], Dr. Mohamed Salama[3], Vasilios Tanos[4]
[1]Omam Hospital, Minimally Invasive Gynecological Surgery, Giza, Egypt
[2]Omam Hospital, Assisted Reproductive Technology, Cairo, Egypt
[3]Ain Shams University, Obstetrics and Gynaecology, Cairo, Egypt
[4]Nicosia Medical School, Obstetrics and Gynaecology, Nicosia, Cyprus

Background

Recurrent implantation failure (RIF) is a very disappointing outcome for patients undergoing Assistive Reproductive Technology (ART) procedures. However, the causes of this condition is often undiagnosed in most patients.
Uterine hyper-contractility (UHC) around the time of Embryo Transfer (ET) has been proposed as possible cause of RIF.
If uterine contractility could be assessed ahead of time, ET would rather be postponed if UHC is found to avoid failure

Methods

A special device designed to measure the myometrial contractility within the uterine cavity is used in patients undergoing ART. The measuring electrodes are carefully introduced via the cervical canal using a catheter introducer similar to the ET catheter.
The probe is kept still in place within the uterine cavity for 20 minutes, while the measurements are fed to the reading device, and are uploaded to central cloud storage.
The readings of the myometrial contractility are visible in real time, while being recorded.

Results

This is a pilot stage for this innovative device and technique. The readings obtained varied from patient to patient, with most of those showing UHC have already gave history of previous failed implantation in a previous ART cycle.
Data are still being processed, and provisional results will be used to build upon for a more controlled phase of the study

Conclusions

Assessment of uterine hyper-contractility was proved to be feasible using this innovative technique. Additionally, the procedure itself is well tolerated by the patients, and the obtained data are easy to analyze, to be correlated at a later stage with failure of implantation.

ESGE35-0127 - P237
ePoster Presentations

Tubo-ovarian Contraceptive Device

Dr Sayed Elakhras[1], Vasilios Tanos[2], Mohamed Salama[3]
[1]Omam Hospital, Minimally Invasive Gynecological Surgery, Giza, Egypt
[2]Nicosia Medical School, Obstetrics and Gynaecology, Nicosia, Cyprus
[3]Ain Shams University, Obstetrics and Gynaecology, Cairo, Egypt

Background

Intra-uterine Contraceptive Devices (IUCD) are a very popular method of contraception. Although it is very effective, and widely acceptable, there is a margin pf complications during its application. The main significant complication is uterine peroration and false passage

Methods

We report a case of chronic pelvic pain in a multiparous lady, in whom are investigations were normal, apart from mild diffuse adenomyosis of an RVF uterus, and negative sliding sign, denoting pelvic adhesions. She has previously had 3 uncomplicated caesarean deliveries.
The patient was counselled for diagnostic laparoscopy for investigating the cause of the chronic pelvic pain, in view that the probable cause is pelvic adhesions.

Results

Laparoscopy revealed utero-vesical adhesions, at the site of the previous caesarean sections, in addition of diffuse uterine enlargement.
Additionally, there were omental and colonic adhesions at the left adnexal region, extending to the uterus. Following careful dissection of these adhesions, a copper IUCD was seen penetrating the ovary, and embedded in tubo-ovarian adhesions, overlied by the omental and bowel adhesions.
This amalgamated mass was adherent to the uterus, at the possible site of IUCD perforation during insertion.
After adhesiolysis, the IUCD was safely extracted, ensuring integrity of the involved bowel loops
As far as we investigated, there are very rare reports of such cases where the IUCD reached up to the ovary and tube, without causing acute symptoms, that make it remain undiscovered for so long

Conclusions

IUCD is a very effective and popular contraceptive means. Meticulous technique of application, and careful follow up are necessary to ensure patient safety, especially those with previous caesarean deliveries and RVF uteri.

ESGE35-0129 - P238
ePoster Presentations

Microwave Ablation Prior to Laparoscopic Myomectomy for Large Fibroids: A Feasibility Case Report

Nicolas Galazis[1], Thekla Achmet[2], Marianna Kakoulli[2], Polys Mitsingas[3], Stylianos Kakoullis[2], Kyriakos Kakoullis[4]
[1]Nicosia Polyclinic Private Hospital, Maternity and Gynaecology, Nicosia, Cyprus
[2]European University of Nicosia, Medical School, Nicosia, Cyprus
[3]Aretaeio Hospital, Maternity and Gynaecology, Nicosia, Cyprus
[4]Nicosia Polyclinic Private Hospital, Maternity and Gynaecology, Nicosia, Cyprus

Background

Real Time Transvaginal Ultrasound guided Microwave Fibroid Ablation (RT-TVUS-MWFA) using the Low Energy Multiple Overlapping Ablation (LEMOA) protocol is an emerging minimally invasive uterus-preserving treatment for symptomatic uterine fibroids, aiming to reduce symptom severity and improve quality of life. Limited evidence exists regarding its role as a preoperative strategy before laparoscopic myomectomy. We present a case evaluating the feasibility and surgical implications of RT-TVUS-MWFA prior to laparoscopic myomectomy in a patient with a large symptomatic fibroid.

Methods

A 38-year-old woman presented with heavy menstrual bleeding caused by a single large symptomatic intramural uterine fibroid measuring 10.58 × 8.57 × 9.15 cm, with a calculated volume of 434.4 cm^3. Both hysterectomy and myomectomy were discussed, and the patient opted for a uterus-preserving approach. Given the large uterine size (22 weeks size clinically) fibroid shrinkage strategies were discussed in order to achieve the myomectomy laparoscopically. GnRH analogue injection was declined because of the potential menopausal side effects and the patient opted for RT-TVUS-MWFA for pre-myomectomy shrinkage.

The procedure consisted of 15 ablations, with a total ablation time of 896 seconds and delivered energy of 14.9 kJ. Clinical outcomes were assessed using serial imaging and the Uterine Fibroid Symptom and Quality of Life (UFS-QoL) questionnaire. Laparoscopic myomectomy was performed 7 months after ablation.

Results

No peri- or post-procedural complications occurred following microwave ablation, and the patient was discharged on the same day. Fibroid volume decreased from 434.4 cm^3 at baseline to 379 cm^3 immediately post-ablation, 362 cm^3 at 40 days, and 303 cm^3 at 3 months, corresponding to an overall volume reduction ratio of 30.2%. Symptom Severity Score (SSS) improved from 31.25 at baseline to 18.75 at 3 months, while Quality of Life (QoL) score improved from 6.03 to 5.17. Seven months after ablation, laparoscopic myomectomy was completed without conversion to laparotomy or perioperative complications. Intraoperatively, reduction in fibroid size was confirmed; however, post-ablation tissue changes resulted in difficult tissue plane identification, dissection and excision of the fibroid. The patient was discharged 2 days postoperatively.

Conclusions

RT-TVUS-MWFA using the LEMOA protocol achieved significant fibroid shrinkage and symptom improvement and may represent a feasible non-hormonal alternative to GnRH analogue pretreatment. However, post-ablation tissue alterations may increase operative difficulty during laparoscopic myomectomy. While this approach may be beneficial in selected uterus-preserving cases, microwave ablation may potentially be better suited as a definitive treatment or prior to hysterectomy rather than before laparoscopic myomectomy.

ESGE35-0136 - P240
ePoster Presentations

Evaluation of endometriosis compartments across different age groups using the #Enzian classification through transvaginal ultrasound (TVS)

Federica Iacobini[1], Consuelo Russo[1], Giuseppe Gabriele Iorio[2], Sara Valeriani[1], Alfredo Ercoli[3], Caterina Exacoustos[1]
[1]University of Rome Tor Vergata, Department of Surgical Sciences- Gynaecological Unit, Rome, Italy
[2]University of Naples Federico II, Department of Public Health, Naples, Italy
[3]University of Rome Tor Vergata, Department of Biomedicine and Prevention- Gynaecological Unit, Rome, Italy

Background

This study aimed to evaluate in patients with ultrasound signs of endometriosis/adenomyosis, without any prior surgery and not on hormonal therapy, age-related differences in #Enzian compartments and symptoms

Methods

To analyse disease progression across the lifespan, patients were divided into four cohorts of age:12–20, 21–30, 31–40, and 41–55 years. For each age group 100 consecutive patients were included in the statistical analysis for a total of 400 women. A second dataset was generated to focus on the critical age range identified in the initial analysis (21–40 years) and it was stratified into 5 year intervals to better identify inflection points in disease severity. Statistical analyses evaluated differences in endometriosis distribution across compartments and in symptom prevalence

Results

Cumulative Link Model (CLM) analysis demonstrated a clear age-dependent increase in endometriosis severity across compartments. Linear contrasts showed the most pronounced increase in compartments A(OR 3.75;95% CI 2.16–6.98) and C(OR 4.40;95% CI 2.47–8.47),indicating a rise in severity with advancing age. Quadratic contrasts below 1 for compartments A, C, and B suggested an acceleration of disease progression in the central age ranges (21–30 and 31–40 years),whereas compartment O showed a more gradual increase. The second dataset confirmed and refined the age-related patterns observed in dataset 1.Quadratic contrasts suggested the point of acceleration lies between 26–30 and 31–35 years and identified the optimal trigger at 25.5 years. At this threshold, the strategy aims to maximize early diagnosis, achieving a sensitivity of 79.4%. Most endometriosis symptoms decreased significantly with age whereas heavy menstrual bleeding was reported more frequently by older patients.

Conclusions

The #Enzian classification proves to be a valuable tool for identifying age-related differences in pelvic endometriosis assessed by transvaginal ultrasound. The identification of a critical window between 26 and 35 years suggests a key period for closer monitoring and timely clinical intervention.

ESGE35-0144 - P241
ePoster Presentations

Laparoscopic lateral suspension for apical pelvic organ prolapse: clinical and surgical outcomes from a single-centre retrospective series

Inés Abad[1], Belén Ortiz Cruz[1], Isabel Martínez Walters[1], Marina Martí Sopeña[1], Juan Antonio Solano Calvo[1], Álvaro Zapico Goñi[1]
[1]Hospital Universitario Príncipe de Asturias, Ginecología y Obstetricia, Alcalá de Henares- Madrid, Spain

Background

Pelvic organ prolapse (POP) is a highly prevalent condition that markedly impairs women's quality of life. Because adequate apical support is a key determinant of durable reconstructive outcomes, surgical approaches that provide effective correction with low morbidity are of particular interest. Although laparoscopic sacropexy remains a reference procedure for apical prolapse, it requires promontory dissection and may be associated with vascular, neurologic and visceral complications. Laparoscopic lateral suspension (LLS), as described by Dubuisson, has emerged as a minimally invasive alternative that avoids promontory dissection and can be performed both in uterine-preserving procedures and after hysterectomy.

Methods

We conducted a retrospective observational study including 85 patients who underwent LLS for apical POP at our institution over a 5-year period. Median follow-up was 21.4 months (range 3–54), and median operative time was 120 minutes. Seven patients underwent a concomitant procedure, most commonly adnexectomy. Recurrence was defined as stage III or IV POP at follow-up.

Results

Recurrence occurred in 5 patients (5.9%). Two bladder injuries were identified intraoperatively and repaired during the same procedure. No intraoperative bowel injuries were recorded. One patient required laparotomy 2 months after surgery because of intestinal obstruction related to an ileosigmoid band. Dyspareunia was reported by 4 patients at the end of follow-up. At final evaluation, 26 patients had stage I POP and 37 had no residual prolapse.

Conclusions

In our experience, LLS is a feasible and safe minimally invasive option for apical POP repair, associated with a low recurrence rate and acceptable morbidity in real-world practice. It may represent a valuable alternative to sacropexy in selected patients, particularly when avoidance of promontory dissection is desirable. Larger comparative studies with longer follow-up are warranted to better define its role in the surgical management of apical prolapse.

ESGE35-0152 - P243
ePoster Presentations

Vesico-Cervico-Vaginal Vestibule!

Mohamed Salama[1], *Elakhras Sayed*[2], *Vasilios Tanos*[3]
[1]*Ain Shams University, Obstetrics and Gynaecology, Cairo, Egypt*
[2]*Omam Hospital, Minimally Invasive Gynaecology, Cairo, Egypt*
[3]*Nicosia Medical School, Obstetrics and Gynaecology, Nicosia, Cyprus*

Background

The female urinary and genital tracts are closely related, not just in anatomical location, but in embryological origin as well.
Abnormal communications between both tracts are either due to congenital malformations, or trauma, either from accidents or surgical trauma.
The complexity of congenital malformations may further be rendered more confusing by surgical interference, especially if poorly performed, and ambiguously documented.

Methods

We hereby present a case of complex anatomical derangement, where congenital malformations were further compromised by non-anatomical surgical intervention.
Complete loss of organ orientation was the result of the newly formed abnormal communications between diverse uro-genital landmarks, ending up in the formation of anomalous spaces and faulty communication between the vagina, cervix and the urinary bladder.

Results

Careful dissection, with meticulous tracing of any residual anatomical landmarks, complemented with imaginative thinking and surgical roadmaps, resulted in gradual de-coding of the ambiguous structures and communications, resulting in gradually restoring tissue orientation, with adequate anatomical normality and acceptable functionality.

Conclusions

Some urogenital congenital anomalies are complex and confusing on their own merit. This complexity can be further complicated by non-anatomical surgical interventions, not attempting to restore the normal anatomical relationships. Poor operative documentation can further contribute to confusion, disorientation and compromization of the patient outcomes following consecutive surgical procedures.
Sticking to meticulous surgical principles, and respect of the anatomical landmarks, together with imaginative reasoning can help navigate these challenges.

ESGE35-0153 - P244
ePoster Presentations

Expanding the Limits of Hysteroscopy: Resection of a Large Prolapsed Hybrid Myoma with Cervical Involvement.

Artur Ludwin[1], Małgorzata Satora[1], Lucja Zaborowska[1]
[1]Medical University of Warsaw, 1st Department of Obstetrics and Gynaecology, Warsaw, Poland

Background

Large prolapsed hybrid myomas with cervical involvement are technically challenging and are frequently managed by hysterectomy. Advanced hysteroscopic techniques may offer a minimally invasive uterus-sparing alternative in selected patients. We present a case report describing the surgical management of a large, prolapsed hybrid myoma with cervical involvement and protrusion into abdominal cavity in a university hospital setting.

Methods

A 35-year-old multiparous woman was referred with persistent abnormal uterine bleeding after having been advised to undergo hysterectomy in an outside institution. The transvaginal ultrasound revealed a hybrid uterine fibroid protruding both into the abdominal cavity with compression of the urinary bladder and into the uterine cavity, involving the uterine isthmus and the cervix, and at the same time prolapsing through the cervical canal into the vagina. Despite the prior recommendation for hysterectomy, the patient was qualified for a uterus-sparing hysteroscopy in our institution.

Results

The patient underwent hysteroscopy performed with a bipolar resectoscope loop. Direct visualization revealed a prolapsing myoma with a broad base, arising from the uterine isthmus and extending into the uterine cavity, measuring approximately 7 × 10 cm in total. The base of uterine fibroid was progressively incised and transected allowing complete removal of the lesion. The obtained material was submitted for histopathological examination. Due to cervical bleeding, a Foley catheter (20 mL) was placed for tamponade, effectively achieving hemostasis. The patient reported a definitive improvement in reported complaints. The procedure was uneventful. The Foley catheter was removed on the second day after the hysteroscopy. Histopathological analysis confirmed the diagnosis of a uterine fibroid, with no evidence of necrosis or increased mitotic activity.

Conclusions

Our case challenges the assumption that large, prolapsed hybrid myomas with cervical involvement and protruding into the abdominal cavity require hysterectomy. We demonstrate that even a 10 cm lesion can be effectively managed hysteroscopically. Minimally invasive and uterine-sparing surgical techniques can be employed in expert hands. This is important not only to preserve fertility but also to avoid life-threatening complications.

ESGE35-0166 - P246
ePoster Presentations

Postoperative readhesion in patients with Obstructed Hemivagina and Ipsilateral Renal Anomaly (OHVIRA) syndrome: a retrospective study

Shuang Song[1], Lan Zhu[2]
[1]Peking Union Medical College Hospital- Chinese Academy of Medical Sciences & Peking Union Medica l College, Department of Obstetrics and Gynaecology, Beijing, China
[2]Peking Union Medical College Hospital, Department of Obstetrics and Gynaecology, Beijing, China

Background

Obstructed Hemivagina and Ipsilateral Renal Anomaly (OHVIRA) syndrome is a rare congenital urogenital malformation characterized by the triad of uterine didelphys, obstructed hemivagina and ipsilateral renal anomaly. Timely surgical resection of the vaginal septum can effectively relieve the obstruction and help preserve fertility. Nevertheless, we noticed that certain patients suffered from repeating postoperative readhesion, therefore underwent additional surgical procedures, even hyseterectomy. The aim of this study was to analyze the incidence and related risk factors of postoperative readhesion in patients with OHVIRA syndrome.

Methods

This is a single center, retrospective study enrolling patients diagnosed with OHVIRA syndrome in our center between January 2000 and December 2023. We collected the demographics, clinical features and managements of enrolled patients by chart review and confirmed the postoperative readhesion status by chart review and telephone interview. We analyzed the potential risk factors of postoperative readhesion in OHVIRA patients by Kaplan-Meier survival analysis and Cox proportional hazard regression.

Results

A total of 164 cases was enrolled and 16 (9.8%) cases experienced postoperative readhesion and additional surgincal management. Among them, 6 patients were classified as subtype I, 3 patients as subtype II, 2 patients as subtype III and 5 patients as subtype IV. To relieve the obstruction caused by readhesion, 9 patients underwent hemihysterectomy ultimately, and the other 7 patients underwent resection of adhesion scar. By Cox regression, we identified that subtype IV classification (HR 11.502, 95% CI 2.769-47.776) was the potential risk factor of postoperative readhesion, and septum resection as primary management (HR 0.117, 95%CI 0.038-0.367) was the potential protective factor.

Conclusions

Nearly 10% OHVIRA patients suffered from postoperative readhesion. Careful preoperative evaluation of definite subtype and anatomical features can effectively decrease the risk of readhesion. Moreover, resecting the septum as much as possible during the surgery, rather than simple drainage or incision, can also prevent patients from postoperative readhesion.

ESGE35-0180 - P248
ePoster Presentations

Bowel Endometriosis Surgery in the Robotic Era: Gastrointestinal Morbidity in a Structured MDT Programme Compared with a Laparoscopic Benchmark

Oscar BARNICK[1], *Ahmed Karim*[1], *Shaheen Khazali*[1]
[1]*HCA, The Lister Hospital, London, United Kingdom*

Background

Bowel surgery for deep endometriosis carries recognised risks of gastrointestinal morbidity, including bowel leak, rectovaginal fistula, pelvic sepsis and stoma formation. This study aimed to compare gastrointestinal surgical workload and morbidity between robotic-assisted endometriosis excision performed within a structured multidisciplinary model and our single-surgeon laparoscopic benchmark.

Methods

This retrospective study included consecutive patients undergoing endometriosis surgery performed by S.K. in the UK between 1 January 2015 and 20 March 2026. The laparoscopic comparator was derived from our previously published single-surgeon series of 1116 procedures performed between 2015 and 2023, after excluding 59 early robotic-assisted cases. The robotic cohort comprised 307 consecutive robotic-assisted procedures extracted from the current analysis database. In the robotic cohort, bowel surgery was performed within a structured MDT model with a dedicated single colorectal surgeon. Gastrointestinal outcomes included bowel procedure type, intra-operative bowel injury, ileostomy formation, bowel leak, rectovaginal fistula, pelvic abscess, bleeding requiring surgical intervention and gastrointestinal-related return to theatre. Disease complexity was compared using #Enzian and VNESS staging systems.

Results

In the laparoscopic benchmark, 571/1057 procedures involved bowel surgery (54.0%), including 436/1057 rectovaginal shaves (41.2%), 66/1057 partial-thickness discoid excisions (6.2%), 9/1057 full-thickness discoid excisions (0.9%) and 60/1057 segmental bowel resections (5.7%). Primary ileostomy was performed in 7/571 bowel procedures (1.2%) and emergency ileostomy in 4/571 (0.7%). Intra-operative bowel adverse events occurred in 8/1057 procedures (0.8%). Major post-operative morbidity following bowel surgery was 12/571 (2.1%), with 4/1057 bowel leaks (0.4%) and 2/1057 rectovaginal fistulas (0.2%).

In the robotic cohort, 223/307 procedures involved bowel surgery (72.6%). Robotic bowel procedures included 87/307 rectovaginal shaves (28.3%), 22/307 partial-thickness discoid excisions (7.2%), 80/307 full-thickness discoid excisions (26.1%), 32/307 segmental resections (10.4%) and 6/307 ileocecal, ileocolic or partial caecal resections (2.0%). Primary ileostomy was performed in 4/223 robotic bowel procedures (1.8%), with no emergency ileostomies (0/223; 0.0%). Intra-operative bowel injury occurred in 4/307 robotic procedures (1.3%). No post-operative bowel leaks (0/223; 0.0%) or rectovaginal fistulas (0/223; 0.0%) were recorded. Pelvic abscess occurred in 2/223 bowel

surgery cases (0.9%) and return to theatre, excluding thoracic complications, in 3/223 (1.3%). Major complications in robotic bowel surgery occurred in 5/223 cases (2.2%).

Overall complexity markers in the robotic cohort included #Enzian A1–3 in 224/307 (73.0%), B3 in 94/307 (30.6%) and C1–3 in 206/307 (67.1%). VNESS 4 in at least one compartment was more frequent in the robotic cohort than the laparoscopic benchmark: 118/307 (38.4%) versus 144/1057 (13.6%).

Conclusions

Robotic-assisted bowel endometriosis surgery was performed in a high-complexity cohort with a greater bowel surgery workload than the laparoscopic benchmark. Within a structured MDT model involving a dedicated colorectal surgeon, robotic surgery demonstrated low gastrointestinal morbidity, with no bowel leaks, rectovaginal fistulas or emergency ileostomies recorded despite a significant increase in overall disease complexity.

ESGE35-0184 - P249
ePoster Presentations

Mapping Fertility Potential: AI-based Follicle Detection and Classification in Cryopreserved Human Ovarian Tissue

Theresa Hudelist[1], Carol Geppert[2], Kurticyn Petr[3], Lothar Häberle[4], Anna Dietl[4], Ralf Dittrich[4]
[1]Friedrich-Alexander University of Erlangen-Nürnberg, Department of Gynaecology and Obstetrics, Erlangen, Germany
[2]University Hospital Erlangen, Department of Pathology, Erlangen, Germany
[3]Fraunhofer Institute for Integrated Circuits IIS, Digital Health Systems Department, Erlangen, Germany
[4]University Hospital Erlangen, Department of Gynaecology and Obstetrics, Erlangen, Germany

Background

To evaluate whether an artificial intelligence (AI)-based workflow can reliably detect and classify ovarian follicles in digitized histological slides of cryopreserved human ovarian tissue, enabling standardized quantitative assessment of follicle reserve.

Methods

This retrospective single-center observational study included ovarian tissue specimens from 102 women aged 18–36 years undergoing ovarian tissue cryopreservation for fertility preservation. Digitized whole-slide images of hematoxylin and eosin-stained ovarian tissue were manually annotated and used as the reference standard. A total of 11,137 follicles from 119 slides of 60 patients were used for model training, while an independent test cohort comprised 5,035 follicles from 63 slides of 42 patients. The AI workflow combined automated follicle detection and follicle-stage classification using deep learning models. Follicles were classified as primordial, primary, or secondary according to established histomorphological criteria. Model performance was assessed using precision, recall, and F1-score at follicle- and patient-level.

Results

For follicle detection alone, the final AI model achieved a follicle-level precision, recall, and F1-score of 0.88 each. At patient-level, the corresponding F1-score was 0.78. Classification performance varied according to follicle stage. Primordial follicles showed the highest performance, with a follicle-level F1-score of 0.84, followed by primary follicles (0.64) and secondary follicles (0.58). When detection and classification were combined into a single evaluation pipeline, the model achieved a follicle-level precision of 0.80, recall of 0.88, and F1-score of 0.80. The corresponding patient-level F1-score was 0.68. Overall classification accuracy on detected follicles reached 0.91.

Conclusions

AI-based follicle detection and classification in digitised ovarian tissue is feasible, accurate, and enables reproducible and standardised assessment of follicle distribution in fertility preservation.

ESGE35-0186 - P250
ePoster Presentations

Association between the neutrophil percentage-to-albumin ratio and sarcopenia in patients with endometrial carcinoma: evidence from two observational studies

Yu Zhao[1], *Qiong Zhang*[1]
[1]*The Second Affiliated Hospital and Yuying Children's Hospital of Wenzhou Medical University, Department of Obstetrics and Gynaecology, Wenzhou, China*

Background

To investigate the association between the neutrophil percentage-to-albumin ratio (NPAR) and sarcopenia in patients with endometrial carcinoma (EC), providing new insights for risk assessment and clinical management.

Methods

Data were derived from two independent cohorts: (1) the national health and nutrition examination survey (NHANES) database (1999-2006, 2011-2018), including 88 ec patients and 10,834 non-ec individuals after screening; (2) a clinical cohort from xx hospital (january 2021 to december 2024), including 186 EC patients. weighted multivariate logistic regression models were used to explore the association between NPAR and sarcopenia, with stepwise adjustment for covariates. Restricted cubic spline (RCS), receiver operating characteristic (ROC) curves, subgroup analyses, and mediation analyses were performed.

Results

The weighted prevalence of sarcopenia was significantly higher in EC patients (19.32%, 95% ci: 8.91-29.73%) than in non-EC individuals (7.75%, 95% ci: 7.03-8.47%, p=0.002). In the clinical cohort, the prevalence was 28.49%. NPAR levels were significantly elevated in sarcopenic EC patients (NHANES: 16.01±3.03 vs. 14.04±2.50, p=0.012; clinical cohort: 14.43±2.57 vs. 13.52±1.90, p=0.021). each 1-unit increase in NPAR was associated with a 35% increased risk of sarcopenia in NHANES (or=1.35, 95% ci: 1.03-1.77, p=0.034) and a 19% increase in the clinical cohort (or=1.19, 95% ci: 1.01-1.41, p=0.047). The highest NPAR tertile showed 2.49-fold risk versus the lowest (p for trend <0.05). RCS revealed a linear positive correlation. ROC analysis showed an AUC of 0.622 for NPAR alone and 0.748 for a multivariate model. Subgroup analyses indicated stronger associations in patients aged <55 years (p for interaction=0.040) and potentially in stage iii-iv disease (p for interaction=0.073).Total cholesterol partially mediated the association (mediated proportion 16.50%, p=0.053).

Conclusions

Sarcopenia prevalence is significantly higher in EC patients than in the general population. NPAR is positively and independently associated with sarcopenia risk, particularly in younger and possibly advanced-stage EC patients.NPAR may serve as a potential predictive marker, and combining multiple indicators improves predictive efficacy. Total cholesterol plays a partial mediating role in this association.

ESGE35-0189 - P251
ePoster Presentations

Fertility-sparing myomectomy in smooth muscle tumors of uncertain malignant potential, STUMP: safe reproduction without compromising oncologic outcomes.

Elisa Micheluz[1], Federica Perelli[2], Alberto Mattei[3], Giuseppe Vizzielli[4], Stefano Restaino[5], Martina Arcieri[6]
[1]Women's and Children Hospital, Obstetrics and Gynaecology Unit- University of Insubria, Varese, Italy
[2]Meyer Children's Hospital IRCCS, Paediatric Gynaecology Unit, Florence, Italy
[3]Azienda USL Toscana Centro- Santa Maria Annunziata Hospital, Gynaecology and Obstetrics Department, Florence, Italy
[4]"Santa Maria Della Misericordia" University Hospital- Azienda Sanitaria Universitaria Friuli Centrale, Clinic of Obstetrics and Gynaecology- University of Udine, Udine, Italy
[5]University of Sassari, PhD School in Biomedical Sciences- Gender Medicine- Child and Women Health, Sassari, Italy
[6]"Santa Maria Della Misericordia" University Hospital- Azienda Sanitaria Universitaria Friuli Centrale, Clinic of Obstetrics and Gynaecology, Udine, Italy

Background

To evaluate fertility and oncologic outcomes of fertility-sparing surgery in patients with smooth muscle tumors of uncertain malignant potential (STUMP), and to define selection criteria supporting safe conservative management.

Methods

We performed a retrospective review of 35 patients diagnosed with STUMP and treated at a referral gynecologic centre between 2020 and 2024. Preoperative assessment included targeted imaging and comprehensive gynecologic evaluation. Treatment was individualized: definitive hysterectomy or fertility-sparing myomectomy when feasible. Surgical approach, use of tissue extraction techniques, subsequent reproductive treatments and oncologic outcomes were recorded. Follow-up data were analysed with focus on pregnancy achievement, need for assisted reproduction, recurrence and survival. Descriptive statistics are reported.

Results

Of 35 patients, 8 (22.9%) underwent fertility-sparing surgery: hysteroscopic myomectomy n=2, laparoscopic myomectomy n=3, and open myomectomy n=3. Hysterectomy was performed in 27 patients: vaginal n=1, laparoscopic n=6, open n=20. Power morcellation was selectively employed in two thoroughly counselled cases. Among the 8 conservatively managed patients, 3 (37.5%) achieved pregnancy resulting in caesarean delivery, 1 (12.5%) is undergoing assisted reproductive treatment, and 4 (50%) remain nulliparous. After a median follow-up of three years, all patients were alive and no recurrences were observed. While definitive surgery has been associated in the literature with longer recurrence-free intervals, in our series both reproductive success and excellent oncologic outcomes were observed following carefully selected conservative management.

Conclusions

In this single-centre cohort of 35 STUMP patients, fertility-sparing myomectomy was feasible and resulted in meaningful reproductive outcomes without compromising short-term oncological safety. Careful preoperative assessment individualized surgical planning and multidisciplinary discussion are essential to identify candidates for conservative management. These findings support consideration of fertility-preserving approaches for selected patients with STUMP and underscore the need for prospective studies and standardized guidelines to optimize patient selection and long-term surveillance.

ESGE35-0210 - P252
ePoster Presentations

Back to the OR: A 10-Year Analysis of Reoperations After Open and Laparoscopic Gynecologic Surgery

Rafal Moszynski[1,2], *Aleksander Kobierski*[2], *Adam Osinski*[2]
[1]*Poznan University of Medical Sciences, Division of Gynaecology, Poznan, Poland*
[2]*Tadeusz Malinski District Hospital in Srem, Department of Obstetrics and Gynaecology, Srem, Poland*

Background

The aim of this study was to evaluate the incidence and causes of reoperations in patients undergoing open and laparoscopic gynecological surgery.

Methods

A retrospective analysis of medical records was conducted over a 10-year period (2014–2023) at a tertiary teaching hospital. The study assessed the frequency of reoperations, surgical approach, indications for reoperation, and the level of surgeon experience.

Results

Between 2014 and 2023, a total of 72,663 gynecological procedures were performed (range: 6,590–8,042 annually). During this period, 378 reoperations were recorded, corresponding to an overall reoperation rate of 0.52% (range: 0.38–0.64% annually).

The leading cause of reoperation was postoperative bleeding, accounting for 76% of cases (range: 67–100% annually). Other indications included wound dehiscence, bowel perforation, peritonitis, and postoperative ileus.

In 84% of reoperation cases, the primary surgery had been performed by specialists, while in 16% it had been performed by residents under supervision.

A total of 36,645 open procedures were performed, with 358 reoperations recorded in this group, resulting in a reoperation rate of 0.98%. During the same period, 36,018 laparoscopic procedures were performed, with 20 reoperations, corresponding to a reoperation rate of 0.06%.

Conclusions

The risk of reoperation after open gynecological surgery was more than 16 times higher compared with laparoscopic surgery.

Laparoscopic surgery was associated with a significantly lower reoperation rate, suggesting a substantial advantage of minimally invasive techniques in reducing postoperative complications.

These findings support wider implementation of minimally invasive gynecologic surgery whenever feasible.

Prevention and early detection of postoperative intraperitoneal bleeding remain crucial factors in reducing the need for reoperation.

ESGE35-0215 - P253
ePoster Presentations

Development and performance evaluation of an AI detection-and-tracking model for the detection of deep infiltrating endometriosis on transvaginal ultrasound

Charles Jayyosi[1], Mathilde Borrot[2], Florian Cartier[2], Marilyn Rolfe[2], Charles-André Philip[3], Gil Dubernard[1]
[1]Hospices Civils de Lyon- Hôpital de la Croix Rousse, Gynecologie et Obstétrique, Lyon, France
[2]Femnov, Research and Development, Paris, France
[3]Hospices Civils de Lyon- Hôpital Femme Mère Enfant, Gynecologie et Obstétrique, Lyon, France

Background

In recent years, considerable efforts have been directed toward improving diagnostic approaches for deep infiltrating endometriosis (DE). Transvaginal ultrasound (TVUS) and recto sonography (TVUS with rectal water contrast) has been proposed as a first-line imaging procedure in cases of suspected endometriosis by several clinical guidelines issued by learned societies.
Given the numerous diagnostic challenges associated with endometriosis and the high level of expertise required to perform and interpret transvaginal recto sonography, artificial intelligence (AI) has emerged as a promising assistance to support endometriosis diagnosis in the near future.

Methods

TVUS and recto sonography video clips were retrospectively collected from patients who underwent TVUS with DE or suspicion of DE. Frames were extracted and pre-processed. Endometriotic nodules were spatially annotated by experts using a dedicated annotation platform. Splitting between training, validation and test sets was performed at the patient level to avoid data leakage. Training used data augmentation (shear, rotation, flip, contrast jitter). A YOLOv11-S segmentation architecture, pre-trained on natural images, was fine-tuned for the task. At inference, frame-level detections were post-processed with a ByteTrack algorithm to ensure temporal consistency across the video.

The independent test set comprised 50 video clips (28 recto sonographies, 22 TVUS) from 32 patients (18 with confirmed DE, 12 controls), acquired on three different ultrasound device platforms. Expert reading served as the ground truth. Performance was reported at three nested levels of analysis — lesion, clip (strict localization rule) and patient — using sensitivity (Se), specificity (Sp), positive and negative predictive values (PPV, NPV), F1 score, accuracy, and intersection-over-union (IoU) for spatial precision. The study used anonymized clinical imaging and was conducted in accordance with the institutional ethics framework for retrospective imaging research.

Results

At the lesion level, the model reached Se 79.4%, PPV 62.8%, F1 70.1% (27 true positives, 16 false positives, 7 false negatives). At the clip level (strict): Se 81.8%, Sp 76.5%, PPV 92.3%, F1 84.4%, accuracy 80.0%. At the patient level (strict): Se 78.9%, Sp 66.7%, F1 81.1%. Mean IoU between predicted and reference masks was 0.75, indicating accurate spatial localization. Performance remained consistent across the three ultrasound device manufacturers represented in the test set.

Conclusions

A deep-learning detection-and-tracking model trained on TVUS and recto sonography data reaches a clinically meaningful sensitivity (~80%) at the lesion, clip and patient levels for deep infiltrating endometriosis rectosigmoid nodule detection, with good spatial precision. The main limitation is moderate specificity at the patient level, supporting positioning as a sensitive first-line detection aid rather than a stand-alone diagnostic reader. Prospective multicentric validation on larger and more diverse cohorts is the next step.

ESGE35-0220 - P254
ePoster Presentations

Artificial intelligence assistance on diagnostic accuracy, reader confidence and reading time across experience levels in transvaginal ultrasound for the diagnostic of deep infiltrating endometriosis

Charles Jayyosi[1], *Mathilde Borrot*[2], *Florian Cartier*[2], *Marilyn Rolfe*[2], *Alexia Mazard*[1], *Gil Dubernard*[1]
[1]*Hospices Civils de Lyon- Hôpital de la Croix Rousse, Gynecologie et Obstétrique, Lyon, France*
[2]*Femnov, Research and Development, Paris, France*

Background

In recent years, considerable efforts have been directed toward improving diagnostic approaches for deep infiltrating endometriosis (DE). Transvaginal ultrasound (TVUS) and recto sonography (TVUS with rectal water contrast) has been proposed as a first-line imaging procedure in cases of suspected endometriosis by several clinical guidelines issued by learned societies. Given the numerous diagnostic challenges associated with endometriosis and the high level of expertise required to perform and interpret transvaginal recto sonography, artificial intelligence (AI) has emerged as a promising assistance to support endometriosis diagnosis in the near future.

Methods

Three readers — junior, intermediate (gynaecology resident), and expert (senior gynaecologist who also defined the ground truth) — analyzed the same set of 50 video clips twice: first unaided, then with an AI overlay displaying tracked detections of rectosigmoid endometriotic nodules. The clip order differed between sessions to limit memorization, with a mandatory washout between sessions. For each clip, readers localized suspected nodules with bounding boxes, answered a structured questionnaire, and rated their confidence on a 1–5 Likert scale. Decision time per clip was logged automatically.
The set of 50 video clips included 32 patients (18 with confirmed DE lesions, 12 without DE lesion as controls). Diagnostic metrics (sensitivity, specificity, F1) were computed at lesion, clip and patient level against the expert reference. AI vs. no-AI comparisons used a repeated-measures analysis of variance (ANOVA) and the Wilcoxon signed-rank test. The study used anonymized clinical imaging and was conducted in accordance with the institutional ethics framework for retrospective imaging research.

Results

AI assistance produced large, consistent gains for the junior reader: lesion-level sensitivity increased from 22.9% to 77.8% (+54.9 percentage points, pp); patient-level F1 from 28.6% to 85.0% (+56.4 pp); confidence from 2.56 to 3.60 (+1.04 pt, $p<10^{-6}$); decision time decreased from 79.0s to 47.6s per clip (−31.3s, $p<10^{-5}$). The intermediate reader was already near-ceiling unaided (lesion-level F1 90.1% vs. 89.6% with AI) but read significantly faster (64.5s → 52.2s, p=0.001). The expert reader showed no change in accuracy, confidence or decision time. At every analysis level, the human + AI pair reached a higher F1 than the AI alone. Pooled across readers, confidence increased (+0.41 pt, $p<10^{-6}$) and decision time fell (−11.7s, p≈0.001).

Conclusions

AI assistance behaved as a leveller: large diagnostic, confidence and time gains were concentrated in the non-expert reader, intermediate performance was preserved with faster reading, and expert performance was unaffected. This profile supports deployment of AI as decision-support both in initial training of sonographers and in routine practice, while reaffirming the need and crucial role of human readers.

ESGE35-0223 - P255
ePoster Presentations

Treatment of Cervical Agenesis by Abdominal Trachelectomy Like Approach

Emine Özhan Özturan[1], Recai Pabuccu[2], Emre Göksan Pabuccu[2], Polat Dursun[3]
[1]Ufuk University Hospital, Obstetrics and Gynaecology, Ankara/ Cankaya, Türkiye
[2]Ufuk University Hospital, Reproductive Medicine, Ankara, Türkiye
[3]Ufuk University Hospital, Gynecologic Oncology, Ankara, Türkiye

Background

Cervical agenesis is a rare Müllerian anomaly characterized by primary amenorrhea, cyclic pelvic pain, and infertility. Diagnosis is usually based on clinical examination and imaging modalities such as ultrasound and magnetic resonance imaging. Surgical management aims to restore menstrual outflow and preserve reproductive potential, but it is technically challenging and associated with variable anatomical and reproductive outcomes. Fertility-preserving procedures, including uterovaginal anastomosis, have been described, although reported pregnancy rates remain limited and long-term outcomes are not well established.
The purpose of this study is to present a case supporting fertility-preserving surgical reconstruction as a potential management option for selected patients with cervical agenesis. This case emphasizes the importance of individualized surgical planning and meticulous follow-up, and may contribute to future management strategies and patient counselling.

Methods

A 25-year-old woman with primary amenorrhea and infertility was evaluated at a tertiary university hospital. Preoperative assessment included clinical examination and pelvic MRI demonstrating cervical agenesis with a functional uterus. Surgical management was performed via laparotomy, creating uterovaginal continuity using an abdominal trachelectomy-like anastomosis. A Pipelle cannula was temporarily placed to prevent postoperative stenosis. Postoperative follow-up assessed complications, menstrual function, and reproductive outcome.

Results

The surgical procedure was completed successfully without intraoperative or postoperative complications. Uterovaginal continuity was achieved, and patency of the newly created cervical canal was maintained using a temporary Pipelle cannula. The patient was discharged on postoperative day two and showed no signs of infection, stenosis, or hematometra during early follow-up. One month after surgery, the patient experienced spontaneous and regular menstruation for the first time. During subsequent follow-up, spontaneous conception occurred without the need for assisted reproductive techniques, indicating restoration of reproductive potential.

Conclusions

As this study represents a single-patient case report, no statistical analysis was performed. The observed outcomes reflect an individual clinical experience, and the role of chance cannot be excluded. Nevertheless, the temporal association between surgical reconstruction and restoration of menstruation and fertility suggests a potential causal relationship. These findings should be interpreted cautiously and cannot be generalized without further studies involving larger patient populations.

ESGE35-0231 - P256
ePoster Presentations

Impact of Endometrioma Surgery on Ovarian Response and IVF Outcomes in Fertility Preservation Cycles

Maria MASLENKO[1], Shmuel Herzberg[1], Orian Davidov[1], Amit Klein[1], Avigayil Spinner[1], Uri. P Dior[1]
[1]Hadassah Hebrew University Hospital, Endometriosis Center, Jerusalem, Israel

Background

Ovarian endometrioma is a common manifestation of endometriosis, occurring in approximately 40% of women diagnosed with the disease. It is generally recognized that endometrioma surgery is associated with a decline in ovarian reserve, and current guidelines recommend considering fertility preservation before surgery. However, fertility preservation in women with endometriomas may be technically challenging and may delay surgical treatment and symptom relief. The impact of endometrioma cystectomy on fertility preservation outcomes therefore remains controversial. We aimed to evaluate the effect of endometrioma cystectomy on fertility preservation outcomes.

Methods

We conducted a retrospective cohort study at a tertiary medical center between January 1, 2019 and January 31, 2025. The study included all patients who underwent endometrioma cystectomy and at least one cycle of fertility preservation at our institution, either before and/or after surgery. Overall, 54 patients undergoing 107 fertility preservation cycles were included. Multivariable generalized estimating equation (GEE) models were used to account for repeated measurements across cycles.

Results

The median age of participants was 30 years (IQR 27–33). Bilateral endometriomas were present in 31.5% of patients, and deep infiltrating endometriosis (DIE) findings were identified intraoperatively in 94.4%. Median endometrioma size was 56 mm (IQR 45–78). In multivariable analysis, postoperative status was not significantly associated with the number of mature (MII) oocytes (B=1.657, 95% CI −0.573 to 3.886, p=0.145) or total retrieved oocytes (B=0.582, 95% CI −2.055 to 3.218, p=0.665). Increasing age was independently associated with lower MII oocyte yield (B=−0.221, 95% CI −0.420 to −0.023, p=0.029) and lower total oocyte count (B=−0.263, 95% CI −0.502 to −0.024, p=0.031). Higher total gonadotropin dosage was also negatively associated with both MII oocyte number (B=−1.015, 95% CI −1.732 to −0.298, p=0.006) and total retrieved oocytes (B=−1.163, 95% CI −2.010 to −0.316, p=0.007), while previous delivery history was not significantly associated with outcomes.

Conclusions

Endometrioma cystectomy was not independently associated with reduced fertility preservation outcomes after adjustment for repeated cycles and clinical confounders. Age and ovarian stimulation requirements were the main factors associated with lower oocyte yield. These findings suggest that fertility preservation after surgery remains a feasible option for patients with endometrioma and

support an individualized approach to the timing of fertility preservation relative to surgery. Further prospective studies are needed to better define the optimal management strategy in this population.

ESGE35-0234 - P257
ePoster Presentations

C-reactive protein for early detection of postoperative digestive complications after bowel resection for deep infiltrating endometriosis: a systematic review

Carolina Dolci[1], Anne Gandon[2], Alice Cathelain[2], Anne Devooght[2], Alessandro Ferdinando Ruffolo[2], Yohan Kerbage[2], Chrystèle Rubod[2]
[1]CHU de Lille, Gynaecologic surgery, Lille, France
[2]CHU de Lille, Gynecologic surgery, Lille, France

Background

Deep infiltrating endometriosis (DIE) involving the bowel often requires bowel resection, associated with significant postoperative morbidity. Early diagnosis remains challenging because clinical signs are frequently delayed and nonspecific. This systematic review aimed to evaluate the predictive value of postoperative C-reactive protein (CRP) for early detection of digestive complications after bowel resection for endometriosis.

Methods

A systematic review of PubMed and Medline was performed according to predefined inclusion criteria. Studies evaluating patients undergoing bowel resection for endometriosis and assessing the association between postoperative CRP levels and digestive or septic complications were included. Data extraction included study characteristics, surgical procedures, CRP kinetics and cut-off values, postoperative complications, and diagnostic performance indicators including sensitivity, specificity, positive predictive value (PPV), negative predictive value (NPV), and area under the curve (AUC).

Results

Five observational studies published between 2016 and 2022 were included, representing approximately 934 patients undergoing laparoscopic bowel resection for endometriosis. Across all studies, CRP levels were significantly higher in patients developing postoperative complications, with differences detectable from postoperative day (POD) 2 onward. Riiskjær et al. demonstrated that increasing CRP levels between POD1 and POD3 were associated with a 38.9% probability of major complications (AUC 0.75; NPV 92.1%). Scattarelli et al. reported significantly higher CRP levels on POD4 in patients with anastomotic leakage compared with uncomplicated cases (182 mg/L vs 43 mg/L, $p<0.0001$), with a CRP threshold of 100 mg/L showing 76% sensitivity, 83% specificity, and AUC 0.85. Pécheux et al. identified a lower POD4 cut-off of 56 mg/L associated with postoperative complications, with 98% specificity and 92% PPV. Montanari et al. confirmed good diagnostic performance for a POD4 threshold of 100 mg/L, with sensitivity of 87.5%, specificity of 89.9%, and NPV of 99.3%. Bertocchi et al. reported high specificity and negative predictive value for CRP in detecting anastomotic leakage and major complications, although sensitivity remained low: receiver operating characteristics (ROC) analysis for the diagnosis of major complications (Clavien Dindo III–IV) shows, for an optimal cut-off of CRP on POD 2 of 117.4, a sensibility of 0%, a specificity of 100%, a NPV of 88.8%. Overall, CRP consistently demonstrated high negative predictive values across studies, supporting its utility as a rule-out marker for postoperative complications.

Conclusions

CRP appears to be a valuable biomarker for early detection of postoperative digestive complications following bowel resection for DIE, particularly because of its high negative predictive value. In particular, CRP assessment on postoperative day 4 may help identify patients requiring further investigation with abdominopelvic computed tomography (CT) scan in case of persistent elevation suggestive of septic complications. However, heterogeneity in study design and cut-off thresholds currently limit standardization of its clinical use. Further prospective studies are required to define optimal CRP thresholds and postoperative management algorithms.

ESGE35-0236 - P259
ePoster Presentations

The impact of different hormonal treatment protocols on the decrease in endometrioma size.

Alexander Volodarsky-Perel[1], Muna El Saleh[1], Yehiel Burke[1], Shlomo Cohen[1], Shai Elitzur[1], Elad Berkowitz[1]
[1]Sheba Medical Center, Endometriosis Center, Ramat Gan, Israel

Background

Endometrioma is an ovarian cystic lesion originating from ectopic endometrial glands and stroma and is identified in 17-44% of patients with endometriosis. The size of endometrioma is associated with decreased ovarian reserve and infertility treatment outcome, pelvic pain, and surgical complexity and risks. Conservative medical management can reduce the size of an endometrioma. However, the optimal hormonal treatment protocol was not previously evaluated. Our study aimed to compare the effect of combined estrogen-progesterone and progesterone-only treatment on the endometrioma size.

Methods

We conducted a retrospective cohort study evaluating patients with endometriomas who were managed in the tertiary endometriosis center and received hormonal treatment for at least 5 months. All the patients were evaluated using an endometriosis-targeted transvaginal ultrasound (US) before and during the hormonal treatment for an endometriosis follow-up. The patients who changed the hormonal treatment or underwent surgery within a period of less than 5 months since the hormonal treatment was initiated were excluded from the analysis. The baseline and follow-up largest diameters of the endometriomas, as well as the delta between the follow-up and the baseline diameters, were compared between the groups. The study protocol was approved by the Institutional Review Board.

Results

A total of 86 patients with ovarian endometriomas were included in the final analysis. The demography and clinical characteristics, including the baseline AMH and CA125 serum levels, of women managed with combined estrogen-progesterone treatment (n=43) were similar to those treated with progesterone only (n=43). The median treatment duration was 7 months (interquartile range of 5 to 9 months). The baseline largest diameter of endometriomas was also similar between the groups [39 (23 – 52) vs 37 (24 – 51), P=0.89] . The follow-up endometriosis targeted US demonstrated significantly lower largest diameter of endometrioma in the combined treatment group comparing to the progesterone-only treatment. We conducted a subgroup analysis comparing the patients treated with combined oral contraceptives (n=39) and Dienogest only (n=33). The baseline endometrioma diameter was similar between the groups. Significantly lower largest diameter of endometrioma was demonstrated by the follow-up targeted US in the combined oral contraceptives group comparing to the Dienogest [23 (10 – 44) vs 37 (19 – 54), P=0.03]. The comparison of the delta between the follow-up and baseline largest diameters confirmed those results [-14 (-27 – -2) vs -7 (-12 – -0.5), P=0.02].

Conclusions

In the absence of contraindications, the combined estrogen-progesterone treatment should be considered in patients with ovarian endometrioma. By a more significant size reduction of endometrioma, this clinical tactic can result in higher ovarian accessibility, higher oocyte yield during the infertility treatment, as well as in the reduction of the risks and complexity of the surgery.

ESGE35-0257 - P261
ePoster Presentations

Endoscopic evaluation as the decisive diagnostic modality in female genital tuberculosis among infertile women: a cross-sectional study

Shivansh Jaiswal[1,2,3], *Leena Wadhwa*[1], *Sanjana Wadhwa*[1], *Shivangi Jaiswal*[4]
[1]*ESIH-PGIMSR, Department of Obstetrics and Gynaecology, New Delhi, India*
[2]*Jaiswal Advanced Gynaecology and Maternity Hospital, Department of Reproductive Medicine, Gwalior, India*
[3]*Gurukripa Hospital and Research Centre, Department of Reproductive Medicine, Sikar, India*
[4]*Jaiswal Advanced Gynaecology and Maternity Hospital, Department of Obstetrics and Gynaecology, Gwalior, India*

Background

Female genital tuberculosis (FGTB) is an important cause of infertility in tuberculosis-endemic regions. Diagnosis remains challenging because of the paucibacillary nature of the disease and the limited sensitivity of conventional microbiological investigations. This study evaluated the diagnostic accuracy of cartridge-based nucleic acid amplification testing (CB-NAAT) and the contribution of combined hysteroscopy and laparoscopy in infertile women with suspected FGTB.

Methods

This prospective cross-sectional study consecutively enrolled 141 infertile women with clinical suspicion of FGTB at a tertiary centre in New Delhi, India (November 2018 – February 2020; IEC approval: ESIPGIMSR-IEC/2018011). Endometrial samples were subjected to CB-NAAT blinded to endoscopic findings. Combined hysteroscopy and laparoscopy were performed in 139 of 141 participants. FGTB diagnosis was established using a composite reference standard incorporating clinical, radiological, and endoscopic criteria. Sensitivity, specificity, predictive values, and likelihood ratios with 95% confidence intervals were calculated.

Results

FGTB was diagnosed in 26 of 141 women (18.44%). CB-NAAT was positive in four cases (2.84%), demonstrating sensitivity of 11.54% (95% CI 2.45–30.15%) and specificity of 99.13% (95% CI 95.25–99.98%). One false-positive CB-NAAT result was identified. Conventional microbiological investigations including acid-fast bacilli smear, culture, and histopathology were negative in all cases. Laparoscopy identified tuberculosis-suggestive findings in 23 cases (16.31%), while hysteroscopy identified abnormalities in 14 cases (9.93%). Combined radiological and endoscopic findings established 61.54% of diagnoses. Among 26 FGTB cases, both hysteroscopy and laparoscopy were abnormal in 11 (42.31%), laparoscopy alone in nine (34.62%), and hysteroscopy alone in three (11.54%).

A representative index case illustrates the diagnostic importance of combined endoscopic evaluation (patient consent obtained). A 34-year-old woman with 11 years of primary infertility, previous pulmonary tuberculosis, hypomenorrhea, and bilateral tubal block on hysterosalpingography underwent combined hystero-laparoscopy. Hysteroscopy demonstrated severe intrauterine

adhesions with complete anterior-posterior wall apposition, cervical stenosis, right ostial stenosis, and non-visualisation of the left ostium, consistent with severe Asherman syndrome. Laparoscopy revealed dense pelvi-peritoneal and peri-hepatic adhesions with bilateral tubo-ovarian complexes buried within adhesions and absent chromopertubation spill bilaterally, consistent with frozen pelvis secondary to probable FGTB. Endometrial histopathology and CB-NAAT were negative. The diagnosis of probable FGTB was established using composite clinical and endoscopic criteria, and anti-tubercular therapy was initiated. Subsequent fertility management required a freeze-all IVF strategy because of persistently suboptimal endometrial development despite adhesiolysis and hormonal therapy.

Conclusions

CB-NAAT demonstrates very high specificity but poor sensitivity in FGTB and cannot serve as a standalone screening tool. Combined hysteroscopy and laparoscopy contributed substantially to diagnosis when molecular and conventional microbiological investigations were negative. In tuberculosis-endemic settings, integration of clinical suspicion with early endoscopic evaluation may facilitate timely diagnosis and management. Combined hysteroscopy and laparoscopy may identify advanced disease despite negative molecular, microbiological, and histopathological testing, with direct implications for fertility management and reproductive planning.

ESGE35-0258 - P262
ePoster Presentations

Robotic-Assisted Transabdominal Cerclage After Repeated Cervical Excisional Procedures: A Precision Rescue Approach to Cervical Insufficiency

Haticegül Tuncer[1], Utku Akgor[2], Murat Gultekin[2], Z. Selcuk Tuncer[2], Derman Basaran[2]
[1]Hacettepe University, Department of Obstetrics and Gynaecology, Ankara, Türkiye
[2]Hacettepe University, Department of Obstetrics and Gynaecology- Division of Gynecologic Oncology, Ankara, Türkiye

Background

Transabdominal cervical cerclage (TAC) is an effective surgical procedure to prevent preterm birth in selected patients with cervical insufficiency, especially those with previous failed vaginal cerclage or extensive cervical surgery. This abstract describes a successful case of robotic-assisted transabdominal cervical cerclage performed in a patient with significant cervical shortening following multiple cervical surgeries.

Methods

A 37-year-old patient, gravida 1 para 1, previously underwent a McDonald cerclage and delivered at 32 weeks. She had a history of two conizations and one Loop Electrosurgical Excision Procedure(LEEP)procedure due to High-grade Squamous Intraepithelial Lesions(HSIL). Pelvic examination revealed no visible exocervix. Additional cervical re-excision was performed due to vaginal lesion presence, achieving surgical remission. Before planned embryo transfer, transvaginal ultrasonography measured a cervical length of 22.4millimeters. Consequently, robotic-assisted transabdominal cervical cerclage was indicated.

The robotic-assisted procedure began with bladder flap dissection. Avascular spaces were developed bilaterally between the ascending and descending branches of the uterine artery at the cervicoisthmic level. Windows were created in both broad ligaments. A 1.0 Mersilene tape was passed anterior-to-posterior on the left and posterior-to-anterior on the right, and laid flat along the posterior uterine wall. The tape was then tied securely on the anterior aspect of the uterus, and its ends were approximated with 2-0 Prolene sutures to prevent knot slippage. Bladder peritonization was completed using 2-0 Vicryl. Correct cerclage placement was confirmed via transvaginal ultrasound.

Results

The procedure was completed successfully without complications. The patient subsequently underwent embryo transfer, resulting in a term pregnancy and delivery. The robotic-assisted TAC effectively maintained cervical integrity throughout gestation, ensuring favorable perinatal outcomes.

Conclusions

In selected patients, robotic-assisted transabdominal cervical cerclage provides superior perinatal outcomes compared to vaginal cerclage. Given appropriate clinical settings and available expertise,

robotic-assisted TAC should be considered and recommended as a viable option for managing cervical insufficiency in patients with complex cervical histories.

ESGE35-0264 - P263
ePoster Presentations

A Challenging Single-Port Robotic Myomectomy for Symptomatic Fibroids Causing Ureteric Compression

Saima Farooq[1], *Amer Raza*[1]
[1]*Cromwell Hospital, Gynaecology, LONDON, United Kingdom*

Background

Objectives
To demonstrate the role of robotic minimally invasive surgery in the management of complex symptomatic fibroids associated with adenomyosis, ureteric compression, and coexisting peritoneal endometriosis while preserving uterine integrity through a precision-based surgical approach.

Methods

A 48-year-old woman presented with progressively worsening pelvic pain, pressure symptoms, and fatigue affecting her quality of life. MRI demonstrated multiple intramural fibroids, including a dominant posterior fibroid measuring 6.7 × 6.6 cm and an additional 4 × 3 cm fibroid, causing right ureteric compression with early renal pelvic dilatation. Imaging also suggested coexisting peritoneal endometriosis involving the left uterosacral ligament. Robotic surgery was performed through a single concealed infraumbilical access platform. Following docking, diluted vasopressin was injected circumferentially around the fibroids under direct vision. Bilateral temporary uterine artery occlusion was achieved using bulldog clamps after careful ureterolysis and retroperitoneal dissection. Robotic enucleation of fibroids was completed with meticulous haemostasis and layered uterine reconstruction. Indocyanine green was utilised to confirm preservation of the endometrial cavity. Simultaneous excision of visible peritoneal endometriosis was performed. Contained manual knife morcellation within an endoscopic retrieval bag allowed safe specimen extraction without intraperitoneal tissue dissemination.

Results

Complete excision of all fibroids and visible endometriosis was achieved without intraoperative complications, conversion, or breach of the uterine cavity. Excellent haemostasis was maintained throughout the procedure with minimal blood loss. The patient experienced an uncomplicated postoperative recovery with early mobilisation and discharge after overnight observation.

Robotic minimally invasive surgery provides a safe and effective approach for complex fibroid disease associated with ureteric compression and endometriosis. Advanced vascular control, enhanced dexterity, and contained extraction techniques facilitate precise dissection and uterine reconstruction while preserving minimally invasive benefits.

Conclusions

Single-port robotic surgery expands the boundaries of minimally invasive gynaecology, enabling safe management of difficult myomectomy cases with complex pelvic anatomy while maintaining excellent haemostasis, cosmetic outcomes, and precise fertility-preserving uterine reconstruction.

ESGE35-0265 - P264
ePoster Presentations

Pyomyoma, a rare but potentially life-threatening complication: case report of sepsis.

Yasmine Chiba[1], Ben Amor Mizouni[1], Ben Jaballah Soukeina[1], Trimech Imen[1], Hfaiedh Ines[1], Mourali Mechaal[1]
[1]Habib Bougatfa University Hospital in Bizerte, Department of Obstetrics and Gynaecology, Bizerte, Tunisia

Background

Infection of uterine fibroids is a rare but potentially serious complication of these common benign tumors in women of reproductive age. It occurs when a degenerating fibroid becomes secondarily infected by bacteria, potentially leading to the formation of a pyomyoma. This condition may present with severe clinical features, including fever, pelvic pain, and signs of sepsis, and requires prompt and appropriate management to prevent systemic complications.
Objective: To report a rare case of septic degeneration of a uterine fibroid complicated by septic shock in a young woman, requiring urgent medical and surgical management with myomectomy, while highlighting the diagnostic challenges, therapeutic approach, prognostic issues, and fertility preservation concerns.

Methods

We report the case of a 38-year-old woman with no significant medical history who presented with acute abdominal pain after minor trauma.

Results

The patient was nulliparous and nulligravid unmarried woman, presented to the emergency department with abdominal pain and fatigue in a febrile setting.

She was febrile at 39°C, tachycardic at 110 beats/min, and hypotensive with a blood pressure of 90/50 mmHg. Abdominal examination revealed marked abdominal distension extending above the umbilicus (30-week gravid uterus).

Suprapubic pelvic ultrasonography demonstrated a large heterogeneous slightly hyperechoic mass containing multiple vacuolated areas suggestive of air bubbles. The lesion exceeded the ultrasound field, preventing complete visualization, and the uterus and adnexa could not be individualized.

Laboratory investigations revealed a marked inflammatory syndrome with leukocytosis exceeding 20,000/mm³ and a C-reactive protein level greater than 200 mg/L.

An abdominopelvic computed tomography scan showed a giant posterior intramural uterine mass measuring 220 × 165 × 210 mm, containing hemorrhagic changes and multiple air bubbles, with radiological features highly suggestive of a pyomyoma.

In view of the hemodynamic instability, persistent fever, and severe biological inflammatory syndrome, sepsis was strongly suspected. Broad-spectrum intravenous antibiotic therapy was initiated, and the patient was urgently transferred to the operating room for exploratory laparotomy.

Intraoperatively, the uterus was enlarged. The diagnosis of a giant intramural fibroid was retained, and conservative surgical management by myomectomy was decided. Prior to myomectomy, bilateral hypogastric artery ligation was performed to minimize the risk of hemorrhage. A vertical incision was made over the fibroid prominence, followed by careful dissection and enucleation.

Intraoperative findings were notable for extensive degenerative changes of the fibroid associated with a foul-smelling fetid odour. Enucleation was completed without complications despite entry into the uterine cavity, which was subsequently repaired with meticulous haemostatic control.

Conclusions

Infection of uterine fibroids is a rare but potentially serious complication. It occurs when a degenerating fibroid becomes secondarily infected by bacteria, potentially leading to the formation of a pyomyoma. This condition may present with severe clinical features, including fever, pelvic pain, and signs of sepsis, and requires prompt and appropriate management to prevent systemic complications.

ESGE35-0273 - P265
ePoster Presentations

Anatomical Roadmapping in Robotic Bladder Endometriosis Surgery: A Reproducible Stepwise Approach

Saima Farooq[1], *Amer Raza*[1]
[1]*Cromwell Hospital, Gynaecology, LONDON, United Kingdom*

Background

Bladder endometriosis represents a technically challenging form of deep infiltrating endometriosis and is frequently associated with chronic pelvic pain, urinary symptoms, and substantial impairment in quality of life. Surgical management of large vesical nodules remains demanding because of the close relationship to the ureters, bladder mucosa, and surrounding pelvic structures. Complete excision while preserving urinary tract integrity requires meticulous anatomical dissection and a carefully planned operative strategy.

Methods

This video presentation demonstrates an anatomy-based robotic technique for the management of a symptomatic 4 cm bladder endometriotic nodule identified on preoperative MRI. A combined gynaecological and urological approach was adopted, including preoperative cystoscopy and bilateral ureteric stent placement to optimise identification of the lower urinary tract and define disease extent. Robotic excision was performed using a reproducible stepwise framework focused on systematic bladder mobilisation, retroperitoneal dissection, identification of anatomical landmarks, layered excision of the lesion, protection of the ureteric orifices, assessment of bladder integrity, and structured reconstruction. The approach prioritised precise anatomical orientation and controlled dissection to facilitate safe resection while minimising unnecessary bladder trauma.

Results

The bladder nodule was excised incrementally in layers, preserving surrounding pelvic structures and avoiding unnecessary full-thickness cystotomy. Clear surgical margins were achieved with preservation of urinary tract integrity. Where required, bladder repair was performed with intraoperative testing confirming a watertight closure. The patient experienced an uncomplicated postoperative recovery with significant improvement in symptoms following surgery.

Conclusions

A structured robotic approach to bladder endometriosis enables safe and reproducible excision of complex vesical disease while preserving urinary function and minimising morbidity. Standardised anatomy-driven surgical strategies may improve operative reproducibility, support advanced endometriosis training, and enhance outcomes in complex robotic pelvic surgery.

ESGE35-0277 - P266
ePoster Presentations

SABRE Technique Single-Port Advanced Bowel Robotic Extraction. Innovative Contained Single-Port Extraction Following Robotic Rectosigmoid Resection for Endometriosis, A Novel Extraction Strategy Without Transanal Retrieval.

Saima Farooq[1], *Amer Raza*[1]
[1]*Cromwell Hospital, Gynaecology, LONDON, United Kingdom*

Background

Natural orifice specimen extraction techniques have increasingly contributed to the evolution of minimally invasive colorectal surgery by reducing abdominal wall trauma and improving postoperative recovery. However, applications in deep infiltrating rectosigmoid endometriosis remain limited, particularly using robotic single-port platforms. We present a modified minimally invasive approach involving robotic single-port segmental bowel resection with contained specimen extraction through the single-port access platform rather than transanal extraction.

Methods

This video presentation demonstrates a novel single-port robotic approach for the management of deep rectosigmoid endometriosis requiring segmental bowel resection. Ten patients with advanced bowel endometriosis underwent robotic single-port excision with retroperitoneal dissection, rectosigmoid mobilisation, segmental colorectal resection, intracorporeal anastomosis, and contained specimen extraction through the single-port access platform. The technique emphasised coordinated robotic instrumentation, safe pelvic dissection, preservation of surrounding structures, and maintenance of minimally invasive surgical principles without additional abdominal extraction incisions.

Results

All procedures were completed successfully without conversion to laparotomy or requirement for additional abdominal ports. The robotic single-port platform provided enhanced articulation, stable visualisation, and precise dissection within confined pelvic anatomy. Segmental bowel specimens were safely retrieved through the single-port access site using a contained extraction technique. Preliminary postoperative outcomes demonstrated favourable recovery, minimal access-related morbidity, and excellent cosmetic outcomes. No immediate intraoperative complications were observed.

Conclusions

This series demonstrates the technical feasibility and safety of robotic single-port segmental bowel resection with contained specimen extraction through the single-port access platform for rectosigmoid endometriosis. The technique further expands the boundaries of minimally invasive pelvic surgery by combining advanced robotic precision with innovative specimen retrieval strategies while avoiding additional abdominal extraction incisions. To our knowledge, this represents one of

the earliest reported series demonstrating contained single-port extraction following robotic segmental bowel resection for deep infiltrating endometriosis and may contribute to future evolution of advanced colorectal endometriosis surgery.

ESGE35-0278 - P267
ePoster Presentations

Predictive factors for symptom improvement after medical and surgical treatment of endometriosis

Waldir Modotti[1], Isabela Velho[2], Flávia Bueloni-Dias[2], Nilton Leite[2], Bernardo Lasmar[2], Daniel Dias[2]
[1]INSTITUTO MODOTTI, Gynaecology, Assis, Brazil
[2]Sao Paulo State University – FMB/Unesp, Department of Gynaecology and Obstetrics, Botucatu, Brazil

Background

To analyze epidemiological and clinical predictive factors influencing the response to clinical and surgical treatment in patients with endometriosis.

Methods

Retrospective cross-sectional study conducted at a single university public reference center, using a research protocol for data collection from medical records. Epidemiological, clinical, and physical characteristics, including imaging findings, disease classification at the time of surgery, and treatment types were evaluated. The variables of interest were compared with the proportion of satisfactory and unsatisfactory responses to clinical and surgical treatment.

Results

Eighty-five patients with a mean age of 36 years and BMI of 27.14 Kg/m2 were included. It was observed that 74.1% of patients did not experience satisfactory improvement in pain with clinical treatment. Following surgical procedures, 45.9% of patients reported complete pain relief. Significant associations were identified between symptoms such as dysmenorrhea and cyclic diarrhoea with the proportion of responses to clinical treatment ($P<0.05$). Early use of hormone therapy was positively associated with the proportion of satisfactory responses to clinical treatment ($P<0.05$). The location of lesions in imaging studies and the classification of lesions according to the Enzian, AAGL, and MAPA for endometriosis systems showed significant correlations with the frequency of responses to both clinical and surgical treatment ($P<0.05$).

Conclusions

In this study, clinical factors, imaging findings, and surgical staging were identified as influencing the proportions of response to treatments. Women with ovarian endometriomas seem to have the highest rates of satisfactory response to both clinical and surgical treatments.

ESGE35-0284 - P268
ePoster Presentations

Beyond Feasibility: Defining the Real Indications for Robotic Surgery in Deep Infiltrating Endometriosis

Andrei Manu[1], Bogdan-Cătălin Coroleucă[2], Ciprian-Andrei Coroleucă[1], Mihaela Arina Banu[1], Cristina-Maria Iacob[1], Elvira Brătilă[1]
[1]Clinical Hospital of Obstetrics and Gynaecology "Prof. Dr. Panait Sîrbu" and Faculty of Medicine- "Car ol Davila" University of Medicine and Pharmacy, Obstetrics and Gynaecology, Bucharest, Romania
[2]Clinical Hospital of Obstetrics and Gynaecology "Prof. Dr. Panait Sârbu", Obstetrics and Gynaecology, Bucharest, Romania

Background

To define the clinical and anatomical scenarios in which robotic surgery offers added value over conventional laparoscopy in the surgical management of deep infiltrating endometriosis, and to propose a practical framework for patient selection based on disease complexity and anatomical distribution.

Methods

We performed a retrospective analysis of patients operated for deep infiltrating endometriosis using the robotic platform at our institution. Cases were selected based on anatomical complexity, focusing on disease involving the ureter, bowel, diaphragm, parametrium, lateral pelvic compartment and pelvic autonomic nerves. Operative findings and case selection patterns were analysed to identify the scenarios in which robotic surgery demonstrated clear added value over conventional laparoscopic approaches

Results

A total of 229 robotic gynecological procedures were included in the institutional database, of which 102 were performed for endometriosis. The majority of these cases involved deep infiltrating or anatomically complex disease, requiring advanced dissection in areas where exposure, precision and tissue handling are critical.

From our experience, the robotic platform appears particularly useful in selected patients with ureteral endometriosis, bowel involvement, diaphragmatic lesions, lateral pelvic compartment disease, parametrial infiltration, pelvic nerve proximity, severe adhesions. In these selected scenarios, the robotic platform was particularly relevant for anatomically demanding steps such as ureterolysis, bowel nodule dissection, diaphragmatic excision, lateral pelvic compartment exposure and nerve-sparing dissection around pelvic autonomic structures.

Conclusions

Robotic surgery should not be considered a universal approach for all patients with endometriosis, but rather a selective strategy for complex deep infiltrating disease. In our experience, the value of robotics in endometriosis lies not in routine disease, but in anatomical complexity. Ureteral, bowel,

diaphragmatic and lateral pelvic compartment involvement represent the scenarios in which the robotic platform may transform surgical exposure, precision and decision-making.

ESGE35-0286 - P269
ePoster Presentations

Robotic Adenomyomectomy: From Excision to Myometrial Repair

Andrei Manu[1], Bogdan-Cătălin Coroleucă[2], Anca Mihaela Hashemi[2], Maria Bianca Nițescu[2], Ciprian-Andrei Coroleucă[1], Elvira Brătilă[1]
[1]Clinical Hospital of Obstetrics and Gynaecology "Prof. Dr. Panait Sîrbu" and Faculty of Medicine- "Car ol Davila" University of Medicine and Pharmacy, Obstetrics and Gynaecology, Bucharest, Romania
[2]Clinical Hospital of Obstetrics and Gynaecology "Prof. Dr. Panait Sârbu", Obstetrics and Gynaecology, Bucharest, Romania

Background

Adenomyomectomy is technically demanding due to the absence of a true cleavage plane, creating a surgical dilemma between complete excision and preservation of myometrial integrity. The aim of this study is to evaluate the contribution of the robotic platform across all operative phases — dissection plane identification, controlled excision and anatomical multilayer reconstruction — in patients undergoing fertility-sparing surgery for symptomatic adenomyosis.

Methods

We reviewed our institutional experience with conservative surgical treatment of adenomyosis, focusing on patients managed by robotic adenomyomectomy. Rather than evaluating the robotic platform only as a minimally invasive approach, the analysis focused on the reconstructive phase of the procedure. Particular attention was given to preoperative imaging, intraoperative identification of the adenomyotic area, controlled excision, hemostasis, preservation of residual myometrial thickness and multilayer closure of the uterine defect.

Results

Our series included 19 adenomyomectomies, of which 10 were performed robotically. Symptom improvement was reported in 90% of patients, and successful pregnancies were achieved in 40%. Adenomyomectomy is technically demanding due to the absence of a true cleavage plane, unlike myomas with a recognisable pseudocapsule. In this context, the robotic platform demonstrated added value across all phases of the procedure. During excision, high-definition three-dimensional visualisation facilitated identification of the dissection plane within poorly defined adenomyotic tissue, enabling controlled removal without excessive myometrial sacrifice. Intraoperative indocyanine green fluorescence imaging allowed real-time visualisation of the uterine cavity, reducing the risk of inadvertent entry and guiding the extent of resection. The combination of magnified visualisation and wristed instrumentation enabled the surgeon to excise precisely what was necessary — no more, no less — preserving the maximum amount of healthy myometrium. During reconstruction, tremor-free suturing and stable instrument control facilitated meticulous haemostasis, elimination of dead space and progressive layer-by-layer closure to restore uterine architecture and maintain adequate wall thickness.

Conclusions

The critical step in fertility-sparing adenomyomectomy is not simply removal of adenomyotic tissue, but safe reconstruction of the uterus after excision. Robotic surgery should therefore be considered not only as a platform for minimally invasive access, but as a reconstructive tool that may facilitate precise multilayer closure, preservation of myometrial thickness and restoration of uterine integrity. In selected patients, this approach may support symptom improvement while maintaining future reproductive potential.

ESGE35-0288 - P270
ePoster Presentations

Extra pelvic Endometriosis Treated by Minimally Invasive Surgery: Mapping, Excision and Multidisciplinary Strategy

Andrei Manu[1], Bogdan-Cătălin Coroleucă[2], Ciprian-Andrei Coroleucă[1], Cristina-Maria Iacob[1], Arina Banu[1], Elvira Brătilă[1]
[1]Clinical Hospital of Obstetrics and Gynaecology "Prof. Dr. Panait Sîrbu" and Faculty of Medicine- "Carol Davila" University of Medicine and Pharmacy, Obstetrics and Gynaecology, Bucharest, Romania
[2]Clinical Hospital of Obstetrics and Gynaecology "Prof. Dr. Panait Sârbu", Obstetrics and Gynaecology, Bucharest, Romania

Background

Extra pelvic endometriosis represents a diagnostic and surgical challenge, frequently presenting with atypical symptoms, limited preoperative imaging sensitivity and the need for coordinated multidisciplinary management across anatomical boundaries. The aim of this study is to describe the role of minimally invasive surgery in the diagnosis and treatment of extra pelvic endometriosis, with emphasis on systematic lesion mapping, tailored excision and multidisciplinary surgical planning.

Methods

We reviewed our institutional experience and educational surgical material on extra pelvic endometriosis, focusing on cases involving abdominal wall, inguinal, ileocecal, appendiceal, diaphragmatic and thoracic-related disease. The analysis emphasized diagnostic challenges, preoperative imaging, intraoperative exploration and surgical strategy. Minimally invasive approaches were considered according to lesion site, extension, associated pelvic disease and the need for collaboration with colorectal, general, thoracic or abdominal wall surgeons.

Results

Extra pelvic endometriosis presented with heterogeneous anatomical locations and frequently atypical symptoms, contributing to delayed or missed diagnosis. Abdominal wall endometriosis was associated with painful masses and previous surgical scars, while inguinal endometriosis required careful differentiation from hernia or soft-tissue tumors. Digestive extra pelvic localizations, particularly ileal, caecal and appendiceal lesions, were often difficult to diagnose preoperatively and required systematic intraoperative inspection of the terminal ileum, caecum and appendix. In our experience, ileal lesions were almost never diagnosed preoperatively, even when MRI was performed, supporting the importance of deliberate surgical exploration. Minimally invasive surgery allowed complete excision in selected cases while adapting the approach to lesion distribution. For ileocecal disease, the surgical objective was complete excision while avoiding unnecessary right colectomy or stoma whenever feasible. Preferred reconstructive options included ileocecal, ileo-ascending or ileo-ileal anastomosis, respecting standard principles of vascularization and tension-free repair. For diaphragmatic disease, minimally invasive and robotic-assisted approaches enabled inspection of the diaphragmatic surface, liver mobilization, excision of superficial or full-thickness lesions and diaphragmatic repair when required.

Conclusions

Extra pelvic endometriosis requires a high index of suspicion, structured preoperative assessment and systematic intraoperative exploration. Minimally invasive surgery offers an effective platform for tailored excision across abdominal wall, digestive, ileocecal, appendiceal and diaphragmatic sites. The key principle is multidisciplinary management: endometriosis remains a gynecological disease even when it extends beyond the pelvis, but optimal treatment often requires collaboration across surgical specialties.

ESGE35-0297 - P271
ePoster Presentations

Can Micro laparoscopy be used for rectal shave? The Basingstoke way

Janani Karpagavalli Sankar[1], *George Goumalatsos*[2], *Arcot Venkatasubramaniam*[2]
[1]*Basingstoke and North Hampshire Hospital, Obstetrics and Gynaecology, Basingstoke, United Kingdom*
[2]*Basingstoke and North Hampshire hospital, Obstetrics and Gynaecology, Basingstoke and Deane, United Kingdom*

Background

Background: Laparoscopic excision is an established treatment for severe endometriosis; however, evidence regarding the use of micro-laparoscopy for complex endometriosis surgery remains limited. We report a case of widespread pelvic endometriosis excision, ureterolysis, and rectal shave performed using 3 mm laparoscopic instruments.

Methods

Case: A 24-year-old nulliparous woman presented with persistent pelvic pain following previous laparoscopic excision of a right ovarian endometrioma. Initial laparoscopy had demonstrated extensive superficial endometriosis with thickened pelvic peritoneum, an endometriotic nodule over the right ureter, and disease in the rectovaginal space. Postoperative MRI showed a normal uterus and ovaries, with no measurable plaque or deep infiltrating endometriosis. The patient declined hormonal treatment because of concerns regarding weight gain.

Surgical management: Following bowel preparation, repeat laparoscopy was performed using a 5 mm umbilical port and 3 mm accessory ports. Widespread superficial endometriosis was identified on both pelvic sidewalls and in the pouch of Douglas. The right ovary was adherent to the right pelvic sidewall, and an endometriotic nodule was present at the level of the right uterosacral ligament overlying the right ureter. Both ovaries were mobilised and suspended to the anterior abdominal wall. Bilateral pelvic sidewall dissection, ureterolysis, opening of the pararectal space, rectovaginal dissection, and rectal shave were performed using 3 mm instruments. During dissection of thickened endometriotic peritoneum, a small serosal ureteric defect occurred and was repaired laparoscopically with 4/0 Vicryl. Diseased peritoneum was shaved from the rectum without bowel injury and removed in an Endo bag through the umbilical incision.

Results

Outcome: At 6-month follow-up, the patient remained pain-free and reported excellent quality of life.

Conclusions

Conclusion: This case demonstrates that micro-laparoscopy using 3 mm instruments can be feasible and effective for complex pelvic endometriosis surgery, including ureterolysis and rectal shave. The Basingstoke approach combines 4K imaging, 3 mm instruments, careful traction-countertraction, precise peritoneal excision, and multidisciplinary support to achieve safe dissection with minimal

tissue trauma. Micro-laparoscopy may therefore represent an effective approach for selected cases of advanced endometriosis requiring rectal shave, without conversion to larger accessory ports.

ESGE35-0309 - P273
ePoster Presentations

robotic single-port hysterectomy: initial outcomes from a consecutive case series

Leonardo Nelva Stelio[1], Giulia Sidoti[2], Carmela Quatrale[1], Luca Calzolari[1], Federica Ottolini[1], Federico Spelzini[1]
[1]ASST Grande Ospedale Metropolitano Niguarda, OB/GYN, Milan, Italy
[2]Università di Messina, ob/gyn, Messina, Italy

Background

Hysterectomy represents a cornerstone procedure in gynecologic surgery and constitutes the standard treatment for a wide range of conditions, both benign and malignant. In this context, the evolution of minimally invasive techniques has led to the development of robot-assisted single-port surgery. The present study aims to analyze perioperative and short-term outcomes of robot-assisted laparoscopic hysterectomy performed using the Da Vinci® SP system, in order to assess its feasibility and effectiveness in clinical practice

Methods

A monocentric observational study was conducted, including all patients who underwent robot-assisted laparoscopic hysterectomy with the da Vinci® SP system between May 2025 and February 2026 in Grande Ospedale Metropolitano Niguarda. For each patient, demographic and clinical data, as well as key intraoperative and postoperative parameters, were collected. Continuous variables are expressed as the median of individual values. Postoperative complications were assessed based on emergency department visits and reports from post-discharge follow-up evaluations

Results

A total of 36 patients were included. The median age was 46 years and the median BMI was 23.6 kg/m². Surgical indications included 26 cases of benign disease and 10 cases of premalignant or malignant pathology. During surgery, the use of an accessory trocar was required in 11 cases, whereas in 25 procedures hysterectomy was completed using a single-port approach exclusively. The median operative time was 180 minutes and median estimated blood loss was 100 cc. Only one procedure required conversion to laparotomy. One intraoperative complication occurred, consisting of a right ureteral injury. The mean postoperative length of stay was 3 days. Postoperative follow-up data are currently available for 31 patients: among these, 5 minor complications were reported, including transient bladder atony, 1 episode of postoperative anaemia requiring blood transfusion, and umbilical cutaneous dehiscence.

Conclusions

In our experience, single-port robot-assisted laparoscopic hysterectomy proved to be a feasible and generally safe technique, with a low conversion rate and a reduced incidence of major complications. Preliminary results suggest that this approach may represent a valid minimally invasive alternative to conventional multiport laparoscopy in selected patients. Larger studies with longer follow-up are needed to confirm the potential advantages of this technique.

ESGE35-0319 - P274
ePoster Presentations

All is well that ends well!

Mohamed Salama[1], Elakhras Sayed[2], Mohamed Kandil[2], Vasilios Tanos[3]
[1]Ain Shams University, Obstetrics and Gynaecology, Cairo, Egypt
[2]Omam Hospital, Minimally Invasive Gynaecology, Cairo, Egypt
[3]Nicosia Medical School, Obstetrics and Gynaecology, Nicosia, Cyprus

Background

Reproductive surgery has helped many patients achieve pregnancy over the last few decades. Although there has been some "paradigm shift" in the reproductive medicine and surgery mindset with the widespread availability of Assisted Reproductive Techniques (ART), reproductive surgery still has a significant role.

Adhesion prevention barriers, in the form of mechanical barriers, gel solutions or powder, offer hopeful means of preventing post-surgical adhesions. However, these are not always effective, and additionally, may have some adverse effects especially in harboring infection if applied to potentially contaminated field.

Methods

In this presentation, we trace the story of a 25 years old lady, who has had her fair share of surgical interventions, complications, and resolutions for her infertility problem.

She has suffered primary infertility for 2 years, for which she has had laparoscopic surgery for cystectomy of a 6x5 cm right endometriotic cyst.

Two years later, she still did not achieve pregnancy, and was additionally suffering from chronic pelvic pain. Ultrasound scanning (USS) revealed recurrence of the cyst on the right ovary, now 5 cm in size, together with a left sided one of 4 cm, and encysted turbid fluid collection in the Cul-de-sac. This was correlating with the finding of pain and tenderness on pelvic exam, and fullness in the Cul-de-sac.

Laparoscopic re-intervention was consented for.

Results

On laparoscopic second intervention, severe abdominal and pelvic adhesions, involving the omentum, bowel, and both adnexa were encountered. After lysis of these adhesions, bilateral tubo-ovarian abscesses were discovered. On drainage of these abscesses, the remnants of Interceed® adhesion prevention barrier were recovered.

It appears that this adhesion prevention barrier acted as a niche for microorganism that infested that potentially contaminated field after the first laparoscopy.

Abscesses were drained, adhesions cut, and anatomy restored as much as possible, and the patient was decided to have another procedure following resolution of infection.

She has had her third-look laparoscopy 6 months later, during which, infection has resolved, and some pelvic and adnexal adhesions were cut, and tubal patency was surprisingly confirmed.

Six months following that last intervention, the patient conceived spontaneously. Her pregnancy progressed smoothly until term delivery of healthy baby.

Conclusions

Reproductive surgery still has a role in helping patients with infertility due to surgically-resolvable causes. Even though the surgical intervention itself may carry a potential for adverse effects, good patient selection, timely procedures, and surgical expertise still can carry hope for these patients, in whom even ART may not help them realise their reproductive goals.

ESGE35-0325 - P275
ePoster Presentations

Laparoscopic management of uterine dehiscence in an ongoing IVF pregnancy following prior myomectomy: a case report

Arti Dave[1], Rachel Mason[1], Mohamed Darwish[1], Maria Constantinides[1], Yasmin Alsoud[1]
[1]Barts Health NHS Trust, Gynaecology, London, United Kingdom

Background

Uterine dehiscence in an ongoing pregnancy is an exceptionally rare and high-risk complication, particularly following prior myomectomy. Laparoscopic management in this context has rarely been described. We present a case of uterine dehiscence managed laparoscopically at 14 weeks in an in-vitro fertilisation (IVF) singleton pregnancy, with subsequent antenatal surveillance and outcomes.

Methods

A 40-year-old woman, with a body mass index (BMI) of 36.4, with a history of right salpingectomy for a ruptured ectopic, open myomectomy and right oophorectomy, presented at 14 weeks gestation with haemodynamic instability and haemoperitoneum. Bedside ultrasound (USS) confirmed a viable foetus and significant haemoperitoneum. Emergency diagnostic laparoscopy identified a 2cm defect at the previous myomectomy site on the right lateral uterine wall, with 1.5 litres of haemoperitoneum. Laparoscopic suturing of the defect was performed successfully. Post-operatively, cyclogest and prophylactic antibiotics were commenced, and she was counselled extensively regarding the high risk of subsequent rupture, with termination of pregnancy offered and declined. A structured multi-disciplinary (MDT) surveillance programme was initiated, including serial USS and magnetic resonance imaging (MRI).

Results

Myometrial thickness around the gestational sac measured 11.4–14.9 mm on USS at 14 weeks. MRI at 14 weeks showed no evidence of dehiscence or collection. She was admitted to hospital at 19 weeks with abdominal pain. Despite ongoing surveillance in hospital, she deteriorated acutely at 21+2 weeks with confirmed uterine rupture, requiring emergency laparotomy, hysterotomy, and excision of the myometrial defect, with an estimated blood loss of 6 litres. The foetus was non-viable at this gestation.

Conclusions

This case demonstrates that laparoscopic repair of uterine dehiscence in an ongoing pregnancy is technically feasible but does not eliminate the risk of subsequent rupture. Serial imaging surveillance may underestimate the true degree of myometrial compromise. Clinicians should counsel patients rigorously regarding the ongoing risk of life-threatening haemorrhage and maintain a very low threshold for intervention when symptoms recur. MDT involvement and structured antenatal surveillance are essential in this rare but potentially fatal clinical scenario.

ESGE35-0331 - P276
ePoster Presentations

Tubal Granuloma

Dr Sayed Elakhras[1], Vasilios Tanos[2], Nouran Osama[3], Dr. Mohamed Salama[4]
[1]Omam Hospital, Minimally Invasive Gynecological Surgery, Giza, Egypt
[2]Nicosia Medical School, Obstetrics and Gynaecology, Nicosia, Cyprus
[3]Omam Hospital, Medical Research, Cairo, Egypt
[4]Ain Shams University, Obstetrics and Gynaecology, Cairo, Egypt

Background

Granuloma is a chronic inflammatory condition, where some balance exists between the causative trigger (organism, or injury) and the host immune system. It can resolve spontaneously or after treatment, progress to acute inflammation, proceed to fibrosis or get complicated.
The Fallopian tubes are commonly affected by infectious process due to its thin lining and exposure to both peritoneal cavity and the vaginal microbiome through the uterine cavity.

Methods

This is a presentation of the case of 21 years old Virgo intacta, who presented with a history of primary amenorrhea and chronic pelvic pain. Her hormonal profile (FSH, LH and E2 levels) are normal. Ultrasound scan revealed normal sized uterus and ovaries, but with thin endometrial line (3 mm). Karyotyping was also normal. She was submitted for combined laparoscopy and hysteroscopy for further investigation.

Results

Hysteroscopy revealed a normal uterine cavity, but lined by thin, atrophic poorly vascularised endometrium. Laparoscopy revealed extensive colonic adhesions with the uterus and adnexa. Additionally, there were bilateral tubo-ovarian adhesions, upon the lysis of which, bilateral Fallopian tube nodules were found. Each was about 20x10 mm. These nodules were excised from the tubes, trying to preserve the tubal lumen. Histopathological examination of these nodules revealed heavy mucosal infiltration of lymphocytes and plasma cells, focally interspersed with giant cells, associated with loss of mucosal plicae. The diagnosis was consistent with tubal granulomatous disease, the differential diagnosis of which could be (TB, schistosomiasis, actinomycosis, spirochetes, enterobius, or chlamydial infection). Further investigation of the specific nature of the causative agent is pending.

Conclusions

The Fallopian tubes can be a target for infection by micro-organisms causing chronic granulomatous diseases. These infections can also affect the endometrium leading to endometrial atrophy and fibrosis. If these infections are acquired in childhood or early in adolescence, can lead to primary amenorrhea and be very detrimental to women's reproductive potential. Screening and early treatment programs, especially in endemic areas should be vigorously implemented.

ESGE35-0338 - P277
ePoster Presentations

Concordance of preoperative ultrasound #Enzian scores with intraoperative findings in women without bowel and/or bladder endometriosis

Ini Zwart[1], Dries Twijnstra[2], Frank Willem Jansen[2], Mathijs Blikkendaal[3]
[1]Leiden University Medical Centre and Reinier de Graaf Hospital,
Gynaecology & Obstetrics and Dutch Endometriosis Clinics, Leiden and Delft, The Netherlands
[2]Leiden University Medical Center, Gynaecology and obstetrics, Leiden, The Netherlands
[3]Reinier de Graaf Hospital, Dutch Endometriosis Clinics, Delft, The Netherlands

Background

The aim of this study is to assess the concordance of transvaginal ultrasound (TVUS) and intraoperative #Enzian scores in women without bowel and/or bladder endometriosis in an endometriosis expertise center. Diagnostic imaging for endometriosis is performed by an experienced specialist, who is familiar with current classification systems for endometriosis, in order to properly diagnose endometriosis. Gynaecologists with expertise in endometriosis perform ultrasounds routinely, to assess bladder, uterus, ovaries, rectovaginal space, pouch of Douglas and bowel, and describe their findings using the #Enzian classification. Ultrasound is a preferred imaging modality, as it is widely available, affordable and mobility of internal organs can be assessed. Only in a subpopulation, an additional magnetic resonance imaging (MRI) is performed to examine extent of the disease in the bowel, bladder and/or pelvic sidewall to allow precise surgical mapping, in case TVUS was inconclusive, or if extra pelvic endometriosis is suspected. In case of organ involvement (other than uterus and ovaries), a surgeon and/or urologist is needed during surgery, and thus preoperative diagnosis is of importance in surgical planning. However, diagnostic accuracy of TVUS, compared to intraoperative scores, has not been evaluated when these lesions are thought to be absent. If high diagnostic accuracy is found, the current use of MRI is justified. This will allow simplified surgical planning across other centres, and more cost-efficient use of additional resources. Therefore, we aim to evaluate the concordance of TVUS and intraoperative #Enzian scores in women with no preoperative suspicion of bowel and/or bladder endometriosis.

Methods

A retrospective study is currently being performed, including patients who underwent a surgical procedure for endometriosis between 2023 and May 2026 in an endometriosis expertise center. The primary outcome measure was the concordance of #Enzian scores between TVUS and surgery. Variables collected are age, length and weight, gravidity and parity, time between imaging and surgery, description of ultrasound findings according to the IDEA-consensus, #Enzian scores for TVUS, indication for additional MRI, and surgical characteristics. Data is subtracted from medical files and matched to surgical characteristics from the EQUSUM database. Concordance between TVUS and intraoperative #Enzian scores are assessed for compartments C (rectum) and FB (bladder). Also, the indication for additional MRI and the retrospective need for MRI, if not pre-operatively performed, is evaluated. Furthermore, the sensitivity, specificity, positive predictive value (PPV), negative predictive

value (NPV), accuracy and 95%-confidence intervals were assessed for #Enzian compartments C and FB.

Results

700 procedures have been performed between 2023 and May 2026. Results will follow this summer.

Conclusions

The results of this study will provide more precise indications for MRI and lead to improved surgical planning and cost-efficient use of MRI in patients with no pre-operative suspicion of bowel and/or bladder endometriosis on TVUS.

ESGE35-0343 - P279
ePoster Presentations

Robotic Surgery in Cervical Cancer: From Fertility-Sparing Trachelectomy to Pelvic Exenterative Procedures

Catalin Bogdan Coroleuca[1], Andrei Manu[2], Ciprian-Andrei Coroleuca[2], Maria Bianca Nitescu[3], Anca-Mihaela Hashemi[3], Elvira Brătilă[2]
[1]Clinical Hospital of Obstetrics and Gynaecology "Prof. Dr. Panait Sârbu", Obstetrics & Gynaecology, Bucharest, Romania
[2]Clinical Hospital of Obstetrics and Gynaecology "Prof. Dr. Panait Sîrbu" and Faculty of Medicine- "Car ol Davila" University of Medicine and Pharmacy, Obstetrics and Gynaecology, Bucharest, Romania
[3]Clinical Hospital of Obstetrics and Gynaecology "Prof. Dr. Panait Sârbu", Obstetrics and Gynaecology, Bucharest, Romania

Background

Cervical cancer management spans a broad surgical spectrum — from fertility-sparing procedures in young patients to radical resections and exenterative surgery in advanced or recurrent disease. Optimal surgical outcomes in this heterogeneous population require precise pelvic dissection, individualised oncological planning and, in selected cases, the ability to perform complex reconstructive or extended procedures within a minimally invasive framework. The aim of this study is to describe the role of robotic surgery across this full spectrum, from fertility-sparing radical trachelectomy to radical hysterectomy and anterior pelvic exenteration, and to define the selected scenarios in which robotic assistance may offer added value.

Methods

We reviewed our institutional robotic surgery database and identified patients operated for cervical cancer or high-grade cervical pathology. Cases were categorized according to surgical procedure: radical trachelectomy, radical hysterectomy or anterior pelvectomy. Data regarding age, diagnosis, use of sentinel lymph node mapping, lymphadenectomy and recorded perioperative events were analysed.

Results

Robotic surgery was used in a selected group of patients with cervical cancer or advanced cervical pathology, covering a broad surgical spectrum. Procedures included radical trachelectomy in young patients requiring fertility preservation, radical hysterectomy for surgically eligible cervical cancer, and pelvic exenterative surgery in complex cases requiring extended pelvic resection. Six robotic cervical cancer procedures were reviewed, covering the full surgical spectrum from fertility-sparing to radical and exenterative surgery. The median patient age was 43 years, reflecting a cohort where fertility considerations were central to surgical planning. Perioperative outcomes were favourable across all complexity levels: median operative time 93 minutes, median console time 77 minutes and median estimated blood loss 155 mL. The robotic platform facilitated precise pelvic dissection across all procedural categories, with particular value in ureteral identification, parametrial dissection, paravesical and pararectal space development and, in exenterative cases, organ separation in fibrotic

or previously treated planes. In fertility-sparing cases, robotic assistance enabled radical oncological dissection while preserving uterine and pelvic anatomy.

Conclusions

Robotic surgery can support the full spectrum of cervical cancer management — from fertility-sparing to radical and exenterative procedures — with acceptable perioperative outcomes across all complexity levels. Its value lies not in routine application, but in selected scenarios where anatomical precision, individualised oncological planning and pelvic access are central to surgical strategy.

ESGE35-0348 - P281
ePoster Presentations

Single-Suture Laparoscopic Burch Modification After TLH for Concomitant Stress Urinary Incontinence: A Simplified Approach

Ömer Faruk Öz[1], Yavuz Yılmaz[1], Can Dinç[1], Selen Doğan[2], Murat Özekinci[1], İnanç Mendilcioğlu[3]
[1]Akdeniz University, Obstetrics and Gynaecology- TR-MIGS, Antalya, Türkiye
[2]Akdeniz University, Gynecologic Oncology- Obstetrics and Gynaecology- TR-MIGS, Antalya, Türkiye
[3]Akdeniz University, Maternal-Foetal Medicine- Obstetrics and Gynaecology- TR-MIGS, Antalya, Türkiye

Background

Stress urinary incontinence (SUI) may coexist with benign gynecologic conditions requiring hysterectomy, creating an opportunity for concomitant surgical management. Burch colposuspension remains an established option for SUI associated with urethral hypermobility and is based on restoring bladder neck support by suspending the paravaginal tissues to the Cooper ligament. Although the classical laparoscopic technique usually uses two sutures on each side, a simplified single-suture approach may preserve the same anatomical principle while reducing operative steps. This video report aims to clearly demonstrate the operative sequence, explain the rationale for reducing the number of sutures, and emphasize safety checks during the combined procedure.

Methods

We present a video case of a 49-year-old woman, gravida 2 para 2, with one previous caesarean section and one vaginal delivery, who presented with an eighteen-month history of abnormal uterine bleeding refractory to hormonal and progestogenic treatment. Endometrial biopsy showed simple hyperplasia without atypia. She also reported a two-year history of SUI. Urodynamic evaluation confirmed pure stress-predominant urinary incontinence with urethral hypermobility and no detrusor overactivity. Pelvic examination demonstrated grade 1 cystocele. A combined total laparoscopic hysterectomy with bilateral salpingo-oophorectomy (TLH+BSO) and laparoscopic Burch colposuspension was planned. After completion of TLH+BSO using standard laparoscopic steps, the patient was not repositioned. The space of Retzius was entered laparoscopically, and the bladder neck region, paravaginal fascia, and bilateral Cooper ligaments were exposed. Because of intraoperative suture material limitation, a modified technique was used. One permanent braided suture was placed on each side between the paravaginal fascia at the level of the bladder neck and the ipsilateral Cooper ligament. Sutures were tied under direct vision with careful tension adjustment to elevate and support the bladder neck without excessive traction or obstruction.

Results

The combined procedure was completed successfully without intraoperative complications. Intraoperative cystoscopy demonstrated intact bladder mucosa and bilateral ureteric jet patency. The postoperative course was uneventful. At three-month follow-up, the patient reported complete resolution of SUI. No voiding dysfunction, urinary retention, or de novo urgency was observed.

Clinical examination demonstrated satisfactory bladder neck support and no progression of anterior vaginal wall prolapse.

Conclusions

This case demonstrates that laparoscopic Burch colposuspension can be performed immediately after TLH+BSO in the same operative session without patient repositioning. A single-suture modification, using one permanent suture per side from the paravaginal fascia to the Cooper ligament, appears technically feasible and may offer a pragmatic simplification of the conventional two-suture technique. The approach maintains the essential anatomical concept of bladder neck elevation while potentially reducing suture placement, operative manipulation, and complexity. Early postoperative functional and anatomical outcomes were satisfactory in this selected patient. However, this is a single-case experience, and longer follow-up and comparative studies are required before equivalence with the standard two-suture Burch technique can be assumed.

ESGE35-0349 - P282
ePoster Presentations

A retrospective review of vNOTES Hysterectomy (VANH) and peri-operative recovery in a high risk population

Maria Constantinides[1], Ping Tan[1], Esther Skene[1], Fabian Roberts[1], Deepali Sinha[1], Shaimaa Ibrahim[1]
[1]Newham University Hospital- Barts Health NHS Trust, Obstetrics and Gynaecology, London, United Kingdom

Background

Vaginal Natural Orifice Transluminal Endoscopic Surgery hysterectomy (VANH) has emerged as a minimally invasive alternative to conventional laparoscopic and vaginal approaches. The objective of this study is to evaluate postoperative recovery outcomes and aims to assess the feasibility of vNOTES technique, particularly in prolapse patients who are commonly at higher anaesthetic risk due to their comorbidities.

Methods

We conducted a retrospective review of patients who underwent VANH at one secondary care centre in London, UK between November 2024 and March 2025. Data on patient demographics, indication, blood loss, complications, postoperative pain scores, length of stay and satisfaction were collected.

Results

A total of 32 patients underwent VANH, with an average age of 59 (range: 42-81 years), a BMI of 29 (range: 21-49), parity of 3 and majority of Asian origin (46.9%). The most common indication for VANH was pelvic organ prolapse 24/32 (75%), followed by fibroids 6/32 (19%) and hyperplasia/CIN 2/32 (6%). Of the 24 cases with prolapse,20 underwent concurrent high uterosacral suspension (83.3%). Mean blood loss was 223 mls (range: 10-1200 mls) with mean pain score 2.76 / 10 on the evening of the surgery and 2.32 twenty four hours after the surgery. Mean length of hospital stay was 2.03 days (range: 0-13 days). On the evening of surgery, the majority (94%) of patients were able to eat and drink, while a minority experienced nausea (22%), vomiting (9%), and vaginal bleeding (28%). Intra-operative complications were rare; one patient had conversion to laparoscopy and one patient had excessive bleeding of >1L requiring transfusion.

Conclusions

Our results indicate that VANH is associated with reduced postoperative pain and symptoms, short hospital stays, and minimal complications. This method is a viable option for patients that would be high risk or ineligible for laparoscopic procedures.

ESGE35-0353 - P283
ePoster Presentations

Relugolix Combination Therapy in the Management of Uterine Fibroids: A One-Year Retrospective Study at Whittington Hospital

Asmaa Badr[1], Preethi Jacob[1], Shahd Dafa-Alla[1], Zara Ahmad[2], Diana Nneka Kanife[2], Guldzhan Vorona[3]
[1]Whittington Health NHS Trust, Obstetrics and Gynaecology, London, United Kingdom
[2]University College London, Obstetrics and Gynaecology, London, United Kingdom
[3]Whittington Health, Obstetrics and Gynaecology, London, United Kingdom

Background

Relugolix combination therapy is an oral gonadotropin-releasing hormone antagonist used for uterine fibroids and endometriosis. The aim of this study was to evaluate the effectiveness of Relugolix combination therapy (relugolix–estradiol–norethisterone acetate) in the management of uterine fibroids, focusing on symptom control, radiological response, tolerability, and surgical outcomes. A secondary aim was to assess its role in surgical planning, either as bridging therapy before surgery or following unsuccessful conventional medical treatment.

Methods

This retrospective study was conducted at Whittington hospital between January 2024 and January 2025. Patients prescribed Relugolix combination therapy were identified from pharmacy records, and clinical data were extracted from electronic health records. Variables included demographics, indications, symptoms, haemoglobin, fibroid characteristics, imaging findings, treatment duration, and outcomes. For surgical cases, intraoperative findings, estimated blood loss, length of stay, and readmission rates were also reviewed.

Results

Relugolix combination therapy was prescribed to 37 patients with fibroids; 12 were excluded because of loss to follow-up or inability to start treatment due to drug unavailability. The final cohort included 25 patients: 16 remained on medical treatment and 9 proceeded to surgery. Treatment duration ranged from 1 to 21 months, most commonly 5–6 months. At baseline, 88% reported heavy or very heavy menstrual bleeding and 60% moderate-to-severe pain. Pain improved in 40%, while heavy menstrual bleeding improved in 16%; 24% achieved amenorrhoea. Radiologically, fibroid size decreased in 7 patients, remained stable in 11, and increased in 4. Relugolix combination therapy was generally well tolerated, with 76% continuing therapy. Among surgical patients, most received Relugolix combination therapy as bridging therapy.

Conclusions

Relugolix combination therapy appears to provide symptomatic benefit and is generally well tolerated in women with uterine fibroids. It may also support preoperative optimisation and surgical planning, although prospective studies are needed to define predictors of response and longer-term outcomes.

ESGE35-0357 - P284
ePoster Presentations

Occult Endometrial Carcinoma in Patients with Atypical Endometrial Hyperplasia: Experience from a Tertiary Gynecologic Oncology Center

Mariana Salgado Simões[1], *Ana Otília Costa*[1], *João Casanova*[1]
[1]*Hospital da Luz Lisboa,*
Gynecologic Oncology Unit- Gynecologic and Obstetrics Service- Department of Surgery, Lisboa, Portugal

Background

Atypical endometrial hyperplasia (AEH) is a premalignant lesion associated with a substantial risk of concurrent endometrial carcinoma (EC). Reported rates of occult EC in patients undergoing hysterectomy following a preoperative diagnosis of AEH range from 30–50%, raising important concerns regarding optimal surgical staging and the potential role of sentinel lymph node (SLN) mapping. This study aimed to evaluate the incidence of occult EC in patients diagnosed preoperatively with AEH and to assess the clinical relevance of SLN mapping in this setting.

Methods

A retrospective analysis was conducted at the Gynecologic Oncology Unit of Hospital da Luz Lisboa, including patients who underwent robotic surgery for AEH between January 2023 and January 2026. Demographic, diagnostic, surgical, and histopathological data were reviewed. Surgical treatment consisted of robotic total hysterectomy with or without bilateral salpingo-oophorectomy, combined with SLN mapping.

Results

A total of 20 patients with a preoperative diagnosis of AEH underwent surgery during the study period. All patients underwent total hysterectomy with bilateral salpingo-oophorectomy, except for one patient in whom ovarian preservation was performed. Mean age was 59.9 years (range 39-87), and mean body mass index was 28.9 kg/m² (range 21-42).

The initial diagnosis was established by office endometrial biopsy in 25% of cases (n=5) and surgical hysteroscopy in 75% (n=15). Final histopathology confirmed persistent AEH in 35% (7/20), while occult EC was identified in 65% (13/20).

Final staging among patients diagnosed with endometrial cancer on the hysterectomy specimen was the following: FIGO stage IA1 (n=9), stage IA2 (n=2), stage IIC (n=1), and stage IIIA2 (n=1), highlighting the presence of clinically significant disease beyond low-risk early-stage carcinoma.

SLN mapping achieved a bilateral detection rate exceeding 90% with no increase in surgical morbidity. Nodal assessment provided essential staging information and influenced adjuvant treatment planning in selected cases.

Conclusions

Our series demonstrates a notably higher incidence of occult EC among patients with a preoperative AEH than previously reported in the literature, including cases with advanced pathological stage. Robotic surgery with systematic SLN mapping appears to be a safe and effective staging strategy, enabling accurate risk stratification and supporting individualized adjuvant treatment decisions. These findings suggest that SLN mapping may be considered in the surgical management of AEH, particularly when performed in specialized minimally invasive gynecologic oncology centres.

ESGE35-0362 - P286
ePoster Presentations

Caesarean Myomectomy – to Do or Not to Do?

Joseph Iskaros[1], Maria Constantinides[2], Charlotte Depoers[2], Jaice Mary Devasia[1], Lily Wheeler[3], Guldzhan Vorona[2]
[1]University College Hospital London, Obstetrics and Gynaecology, London, United Kingdom
[2]Whittington Health NHS Trust, Obstetrics and Gynaecology, London, United Kingdom
[3]University College London Hospital, Obstetrics and Gynaecology, London, United Kingdom

Background

The management of uterine fibroids encountered at caesarean section remains a clinical challenge. Caesarean myomectomy is traditionally avoided due to concerns regarding severe intraoperative haemorrhage and the potential need for peripartum hysterectomy. However, emerging evidence suggests that, in selected cases and with advanced surgical expertise, it may be performed safely.

This study presents a case series of 31 women with symptomatic uterine fibroids who underwent myomectomy at the time of caesarean section. The aim was to evaluate the safety of the procedure, including intraoperative and postoperative outcomes, and to assess its potential in reducing the need for subsequent surgical intervention.

Methods

This case series includes 31 patients who underwent caesarean myomectomy between 2023 and 2026 across two London hospitals. All women had large symptomatic fibroids identified antenatally on ultrasound and MRI. Cases were reviewed in a fetal medicine multidisciplinary team (MDT) and selected for planned caesarean delivery with the option of concurrent myomectomy.

All procedures were preoperatively planned. Intraoperative haemostatic measures included intramyometrial/subserosal vasopressin injection at the fibroid base to achieve visible uterine blanching, uterine tourniquet application, tranexamic acid administration, cell salvage, use of advanced ultrasonic bipolar energy devices, and application of a Veriset™ haemostatic patch.

Results

Indications for caesarean myomectomy included degenerated symptomatic fibroids and technical difficulty in accessing or closing the uterine incision. Access was via a Pfannenstiel skin incision with lower segment caesarean in 26/31 cases; 5/31 required a midline or classical uterine incision.

Mean maternal age was 38.9 years (range 27–49), and parity ranged from 0 to 3, with three women having had a previous caesarean delivery. Antenatal symptoms commonly included abdominal, back and pelvic pain, pelvic pressure, and urinary and/or bowel dysfunction. Gestational age at delivery ranged from 36+4 to 39+3 weeks; 23/31 (74.2%) fetuses were cephalic and 8/31 (25.8%) were breech.

Mean estimated blood loss was 1.43 L (range 0.3–5.5 L), and 6/31 (19.6%) patients required allogenic blood transfusion. Mean operative time was 96.9 minutes (range 42–240 minutes). All patients were

managed within an Enhanced Recovery After Surgery (ERAS) pathway, with a mean postoperative hospital stay of 2.89 days.

Conclusions

Concurrent caesarean myomectomy appears safe in carefully selected patients when performed by experienced surgeons within a well-prepared multidisciplinary setting. Intraoperative strategies including tranexamic acid, cell salvage, advanced energy devices, uterine tourniquet use, and topical haemostatic agents can substantially limit blood loss and reduce the likelihood of peripartum hysterectomy.

By addressing significant fibroids at the time of caesarean delivery, this approach has the potential to avoid future major surgery, with its associated anaesthetic exposure and morbidity, and to reduce the long-term impact of fibroid-related symptoms. Careful case selection, detailed preoperative planning, and robust perioperative protocols remain essential to optimise safety and outcomes.

ESGE35-0367 - P287
ePoster Presentations

A New Specialist Endometriosis Clinic in Secondary Care – Are We Improving Pre-operative Diagnostic Pathways?

Suzie Gordon[1], *Mihai Gherghe*[1], *Allam Mohammed*[1], *Inna Sokolova*[2]
[1]*University Hospital Wishaw, Gynaecology Department, NHS Lanarkshire, United Kingdom*
[2]*University Hospital Crosshouse, Gynaecology Department, NHS Aryshire and Arran, United Kingdom*

Background

A Specialist Endometriosis Clinic was established within secondary care to support patients with complex endometriosis. These patients do not require tertiary care at a regional Endometriosis centre but need more intensive management than can be provided in general gynaecology.

The aim of this audit is to determine if the clinic improves patient care and service delivery, assess compliance with NICE and ESHRE guidance, and evaluate the pre-operative diagnostic accuracy of the investigation pathway.

Methods

A comprehensive retrospective cohort audit was conducted of the first 100 patients referred between May 2022 and May 2025. Data collected included referral documentation, medical management, imaging findings, MDT involvement, operative findings, and surgical outcomes.

Results

Most referrals originated from general gynaecology (43%) or primary care (39%), with 60% of patients having a prior diagnosis of endometriosis. Previous surgery within five years had been undertaken in 54% of patients, and 31% were referred due to recurrent symptoms following previous ablation. Symptoms and/or signs suggestive of deep infiltrating endometriosis (DIE) were present in 54% of patients.

Specialist transvaginal ultrasound scan (TVUSS) was performed in 86% of patients. DIE was positively identified in 20.9% (18/86). Among patients undergoing subsequent laparoscopy (n=27), specialist clinic TVUSS (n=19) demonstrated sensitivity 0.92, specificity 0.83, positive predictive value (PPV) 1.0, and negative predictive value (NPV) 0.83. In comparison, departmental TVUSS (n=8) demonstrated sensitivity 0, specificity 1.0, and NPV 0.375.

MRI diagnostic yield was higher when requested through the specialist clinic: 72% (11/18) of scans demonstrated positive findings compared with 41% (7/17) requested prior to referral by general gynaecologists.

Only 48% of referring clinicians had initiated medical management before referral. Hormonal therapy was optimised at the first clinic appointment in 82% of patients, while 60% commenced second-line medical therapies for the first time.

Among patients undergoing laparoscopy (n=32), 16% had negative findings, 47% had endometriosis, and 37% had DIE, compared with reported UK DIE rates of approximately 4% in undifferentiated

diagnostic laparoscopy referrals. Combined operating lists with general surgery involvement were planned in 21% of surgical cases. Eight patients were directly referred to tertiary services following pre-operative diagnosis of stage IV disease, avoiding unnecessary diagnostic laparoscopy.

Conclusions

This specialist clinic provides an effective escalation pathway for patients with suspected complex endometriosis within secondary care. Access to specialist ultrasound improves detection of DIE and supports more accurate pre-operative planning. The pathway also reduces unnecessary MRI requests and facilitates appropriate referral to tertiary centres when required. The clinic is managing a higher-complexity caseload and fulfilling its intended role in the care of advanced endometriosis.

ESGE35-0369 - P288
ePoster Presentations

Laparoscopic management of deep infiltrating vaginal endometriosis with suspected rectal invasion

Nataliia Dorofeeva[1], *Koba Kamashidze*[2]
[1]*BAU International University Batumi, Obstetrics and Gynaecology, Batumi, Georgia*
[2]*The University of Georgia, Obstetrics and Gynaecology, Tbilisi, Georgia*

Background

To highlight the diagnostic and surgical challenges of managing a patient with massive vaginal bleeding caused by deep infiltrating endometriosis of the posterior pelvic compartment, with preoperative suspicion of rectal invasion. Endometriosis is a common chronic condition in women of reproductive age, associated with pelvic pain, dysmenorrhea, infertility and impaired health-related quality of life. Deep infiltrating vaginal endometriosis is a rare condition that may involve the rectovaginal space, rectum and may present with massive bleeding, especially with concomitant coagulopathy, creating diagnostic and surgical challenges.

Methods

A 31-year-old nulliparous woman with von Willebrand disease presented with massive vaginal bleeding from the upper third of the vagina. Her medical history included severe dysmenorrhea since menarche, no previous surgeries, no other major comorbidities. Initial vaginal examination revealed multiple hemorrhagic nodules in the upper third of the posterior vaginal wall.

Pelvic ultrasound and magnetic resonance imaging (MRI) demonstrated infiltrative lesions between the vagina and rectum, 7 cm proximal to the anus, measuring 11 and 8 mm in diameter, with significant fibrous changes, mesorectal fascia infiltration, rectal serosal deformation and suspected subserosal intestinal invasion. Colonoscopy and routine coagulation tests were within normal limits.

After haemostatic stabilization, dienogest was administered for 3 months, achieving bleeding control but with persistent clinically significant disease. A multidisciplinary surgical plan was developed for further management. Laparoscopic excision of deep infiltrating endometriosis involving the vagina and rectovaginal tissues was performed.

Results

Intraoperatively, dense fibrous adhesions were identified between the endometriotic lesions and the anterior rectal wall, without signs of full-thickness intestinal invasion. Bowel resection and stoma formation were avoided. Histology confirmed endometriosis.

Postoperatively, the patient received monthly subcutaneous injections of goserelin at a dose of 3.6 mg for four months, followed by dienogest therapy. The postoperative period was uneventful. At 1 month, normal vaginal scar epithelialization was noted, without visible endometriotic lesions. At 3 months, pelvic MRI revealed only postoperative fibrotic changes without pathological vascularization or rectal deformity. The patient remained asymptomatic during follow-up, resumed sexual activity, and plans pregnancy.

Conclusions

This case demonstrates the complexity of differential diagnosis of deep infiltrating endometriosis of the posterior pelvic compartment with suspected bowel involvement. Despite significant MRI signs of possible rectal invasion, a thorough laparoscopic assessment allowed for organ-preserving surgery without bowel resection. Comprehensive preoperative examination, multidisciplinary approach, and minimally invasive surgical strategy may allow effective treatment of complex forms of endometriosis, avoiding radical interventions. Organ-preserving laparoscopic treatment of deep infiltrating endometriosis can reduce surgical trauma, preserve reproductive potential, and improve health-related quality of life in reproductive-age patients.

ESGE35-0370 - P289
ePoster Presentations

Demographic, psychosocial and care-pathway characteristics of new referrals to a secondary-care endometriosis service: a six-month retrospective audit

Sophie Bracke[1], *Wai Phyo Maung*[1], *Saskia Delray*[1], *Guldzhan Vorona*[1]
[1]*Whittington Health NHS Trust, Obstetrics & Gynaecology, London, United Kingdom*

Background

Patients referred to secondary-care endometriosis services often present with complex clinical, psychosocial and demographic factors that may influence healthcare access, engagement with treatment and progression through referral pathways.

This audit aimed to characterise the demographic, psychosocial and clinical profile of new patients referred to a secondary-care endometriosis pathway, to evaluate pathway timeliness against the 18-week referral-to-treatment (RTT) standard, and to explore associations between patient factors including deprivation, mental health, neurodiversity and parity, and pathway outcomes such as waiting times, did-not-attend rates and treatment acceptance.

Methods

Retrospective single-centre case-note audit of consecutive new patients seen in a London district general hospital endometriosis clinic between 01 January and 30 June 2025. Variables extracted included age, parity, ethnicity, postcode Index of Multiple Deprivation (IMD) decile, mental-health and neurodevelopmental conditions, referral source, pre-clinic and first-clinic imaging, presenting features, prior endometriosis diagnosis, treatment offered (grouped into hormonal, surgical, imaging/investigation, analgesia/medical, onward referral and conservative/follow-up), and treatment acceptance. Mental-health and neurodevelopmental conditions were classified separately using a structured keyword schema. Non-endometriosis cases, follow-ups and duplicates were excluded. Categorical associations were tested with chi-square or Fisher's exact tests; continuous variables with the Mann–Whitney U test.

Results

138 patients formed the analysable cohort. Median age was 33 years (interquartile range 27–38); 71% were nulliparous and 55% lived in IMD "more-deprived" areas. Mental-health conditions were documented in 46% (depression 36%, anxiety 32%, self-harm or suicidality 6%, eating disorder 3%, psychotic or personality disorder 4%); neurodevelopmental conditions in 3% (likely under-ascertained). Chronic pelvic pain was the dominant presenting feature (77%); 34% had a prior endometriosis diagnosis. Median referral-to-first-appointment interval was 147 days (interquartile range 127–196); only 24% met the 18-week RTT standard. The did-not-attend rate was 20%, and 79% had pelvic imaging at first attendance. Treatment offers were non-mutually-exclusive (mean 1.15 offers per patient; 18% of patients received no offer, including did-not-attends). Hormonal therapy was the dominant intervention, offered to 76 patients (55% of cohort) and consisting mainly of progestogen-only oral preparations, levonorgestrel intrauterine systems and gonadotrophin-releasing-hormone antagonist combinations. Other offers were further imaging/investigation (n=29),

conservative management (n=11), surgery (n=8), non-hormonal medical (n=6) and onward referral (n=4). Where a treatment offer was made, acceptance was 71%. Treatment acceptance was numerically higher in patients with documented mental-health conditions (75% versus 69%).

Conclusions

This audit characterises a young, predominantly nulliparous and ethnically diverse referral cohort. The principal compliance gap is the 18-week RTT, breached in three-quarters of patients and not differentiated by deprivation, prior-diagnosis status or mental-health burden. Imaging at first clinic was achieved in 75%; hormonal therapy is the dominant first-line offer with 71% acceptance where made. Priorities for re-audit are capacity and clinic-cancellation review, one-stop imaging, structured documentation of decision rationale, and onward referral to specialist endometriosis centres as per national standards.

ESGE35-0371 - P290
ePoster Presentations

Enhancing Junior Doctors Confidence in Maternity Triage Through Survey-Informed Educational Resources

Savera Muslim[1]
[1]*George Eliot Hospital, Obstetrics and maternity, Sutton Coldfield, United Kingdom*

Background

The triage system for acute maternity presentations improves patient safety and standardises care. Junior doctors (foundation and GP trainees) often have limited obstetric experience, and a gap was identified in formal teaching before being rostered to triage.

This quality improvement project aimed to assess resident doctors' confidence in maternity triage and develop targeted educational resources to improve clinical knowledge and confidence when assessing patients.

Methods

11. Setting: maternity triage in a District General Hospital.
12. A paper-based Likert scale survey assessed junior doctor confidence across eight common presentations: antenatal bleeding, abdominal pain, hypertension, preterm premature rupture of membranes (PPROM), reduced fetal movements, suspected labour, sepsis/unwell, and postnatal concerns.
13. Junior doctors, triage midwives, and supervising doctors were surveyed over an 8-month period.
14. A structured triage guide based on local and national guidelines was developed and shared during departmental teaching.

A repeat survey was completed after the intervention to assess impact

Results

- Initial survey: 10 junior doctors and 15 MDT professionals (triage midwives, consultants, and registrars).
- Post-intervention survey: 8 junior doctors.
- Before the intervention, junior doctors reported low confidence in maternity triage overall.
- Highest baseline confidence: sepsis assessment (40%).
- Lowest baseline confidence: suspected labour and PPROM (20%).
- 83% of junior doctors felt they had not received adequate training.
- 87% of MDT staff identified a need for further junior doctor training.

- After introduction of the educational resources, confidence improved significantly.
- 87.5% reported confidence in assessing antenatal bleeding, suspected labour, and postnatal concerns.
- 100% reported confidence in assessing abdominal pain and sepsis.
- 75% reported confidence in assessing hypertension, PPROM, and reduced fetal movements.
- No respondents reported being “not confident” or “slightly confident”.
- 87.5% of junior doctors found the standardised educational resources useful.

Conclusions

This project demonstrates that practical, standardised educational tools can improve trainee confidence and support clinical workflow in busy maternity triage settings. Future work could expand the guide to include additional presentations and embed this learning within obstetrics and gynaecology placements for regional medical students.

ESGE35-0376 - P291
ePoster Presentations

A Challenging Case Demonstrating Effective Combined Hysteroscopic and Laparoscopic Surgery for Type 2 Caesarean Scar Pregnancy

Farwa Shah[1], *Grisham Smotra*[1]
[1]*Walsall Manor Hospital, Obstetrics & Gynaecology, Birmingham, United Kingdom*

Background

Caesarean scar pregnancy (CSP) is a rare but potentially life-threatening form of ectopic pregnancy with increasing incidence secondary to rising Caesarean section rates. Type II CSP is characterised by deep implantation of trophoblastic tissue within a Caesarean scar niche with outward growth towards the serosa, resulting in significant risks of haemorrhage, uterine rupture, and fertility loss. Persistent retained products of conception (RPOCs) following surgical evacuation should raise suspicion for underlying CSP, particularly in women with previous Caesarean deliveries. Management remains challenging and requires careful pre-operative planning to minimise morbidity while preserving fertility.

Methods

We present the case of a G3P2+0 - 9/40- with two previous Caesarean sections, prior midline laparotomy, and previous surgical evacuation for missed miscarriage. Persistent RPOCs were identified on follow-up ultrasound, demonstrating vascular tissue adherent to a Caesarean scar niche. MRI confirmed a Type II CSP with residual myometrial thickness measuring 3 mm.

Following informed consent, four units of blood were cross-matched in anticipation of potential haemorrhage. Based on imaging findings suggesting dense adherence of tissue within the niche, advanced hysteroscopic tissue resection was planned using the OmniScope platform with MyoSure XL capability to facilitate efficient transition between diagnostic hysteroscopy, suction, and mechanical tissue resection.

The procedure was performed under concurrent laparoscopic guidance to facilitate safe completion of resection. Laparoscopy was technically challenging, as the bladder was densely adherent and concealing the Caesarean scar niche. Careful bladder dissection was required to adequately expose the lower uterine segment and Caesarean scar prior to completion of hysteroscopic resection under direct serosal visualisation. Scan pictures that assisted in diagnosis and helped in precise diagnose and pre surgical planning.

Results

A large volume of adherent RPOCs was successfully resected using the combined minimally invasive approach. The procedure was completed without major haemorrhage, uterine perforation, conversion to laparotomy, or hysterectomy. Success of treatment was confirmed biochemically with a greater than 70% decline in serum β-hCG levels measured 48 hours apart. Fertility preservation was achieved, and the patient had an uncomplicated post-operative recovery.

Conclusions

This case highlights the importance of considering CSP in women with persistent RPOCs following miscarriage surgery, particularly in the presence of previous Caesarean delivery. MRI assessment of residual myometrial thickness was essential in operative planning. Combined hysteroscopic and laparoscopic management provided a safe, fertility-preserving, minimally invasive approach in a high-risk Type II CSP with ultra-thin residual myometrium. This technique may represent an effective surgical strategy for carefully selected patients with complex Caesarean scar pathology.

ESGE35-0384 - P293
ePoster Presentations

Feasibility of an one-stop office visit for diagnosis and treatment in women with postmenopausal bleeding

Ellen Boersema[1], Joey Court[2], Jorien Woolderink[2], David van der Ham[2]
[1]Martini hospital- Groningen- the Netherlands, Obstetrics and Gynaecology, Roden, The Netherlands
[2]Martini hospital, Obstetrics and Gynaecology, Groningen, The Netherlands

Background

Postmenopausal bleeding (PMB) requires a quick evaluation to rule out endometrial pathology. Increasing diagnostic-to-treatment intervals and resource scarcity in operating rooms as well as staff require a new approach. We devised a one-stop office hysteroscopy setting in which history taking, diagnostics and if indicated treatment are performed in one single visit, improving both workflow efficiency and patient satisfaction. A previous study demonstrated that it is feasible to remove endometrial polyps and submucosal myomas in an office setting, showing complete resection in 67% and 44%, respectively (Gulumser et al, 2010)**.**The objective of this study is to investigate whether a single visit for diagnosis and treatment of PMB is feasible and to identify factors for needing a subsequent procedure.

Methods

This retrospective single-center cohort study included all consecutive patients who were planned for a one-stop visit with PMB in a pilot phase over a 12-month period. Clinical records were reviewed for diagnostic work-up, percentage of patients requiring a hysteroscopy, procedural outcomes, success rate and factors for subsequent visits and procedures.

Results

A total of 36 patients were assessed. In 29 of the 36 patients (81%), the complete procedure was performed in a single office visit. In 22 patients (61,7%) there was an indication for hysteroscopy with an endometrial layer >4mm or inconclusive at transvaginal ultrasound. In 19/22 patients (86,3%) an office hysteroscopy was performed directly. In total, 11 hysteroscopic polypectomies (57,8%), 1 myomectomy (5,2%) and 5 diagnostic hysteroscopies (26,2%) were performed.

Successful completion of the initial hysteroscopy (either by completion of the diagnostic work-up without pathological findings or complete resection of the lesion) was achieved in 13 out of 19 cases (68,4%); in 6 patients a second procedure was planned. Reasons for failure to complete the initial hysteroscopy included early cessation due to pain in 4 patients, excessive anxiety regarding the procedure in 1 patient and logistical factors in 1 patient. Two patients were in retrospect not suitable for the one-stop concept due to a hysterectomy in the past.

Conclusions

The one-stop office setting for analysis of postmenopausal bleeding demonstrates a high feasibility, with completion of both diagnostic and therapeutic work-up within a single visit in 81% of patients. Although a successful office hysteroscopy of 68,4% is in line with to previous results,

counselling and pre-visit pain medication may increase the success rate even more. This should be evaluated in a larger group of patients.

ESGE35-0385 - P294
ePoster Presentations

Do Newer Technologies Perform as Well? A Five-Year Comparison of MinTouch® and NovaSure® Endometrial Ablation

Farwa Shah[1]
[1]*Walsall Manor Hospital, Obstetrics & Gynaecology, Birmingham, United Kingdom*

Background

Endometrial ablation is a well-established minimally invasive alternative to hysterectomy for the management of heavy menstrual bleeding (HMB) in women who have completed their families. NovaSure® radiofrequency ablation is one of the most widely used second-generation global endometrial ablation systems with extensive long-term outcome data demonstrating high patient satisfaction and durable symptom control. MinTouch® microwave endometrial ablation is a newer modality designed to deliver rapid, uniform thermal energy with potentially reduced procedure time and improved tolerability. However, comparative real-world data between these two systems remain limited. This study compares clinical outcomes over a five-year experience in a single centre.

Methods

A retrospective comparative analysis was performed on 50 women treated with endometrial ablation for HMB over a five-year period. Patients underwent either MinTouch® or NovaSure® ablation depending on clinical suitability, uterine cavity assessment, and device availability.

Data collected included baseline demographics, uterine cavity characteristics, operative time, intra- and post-operative complications, symptom improvement, amenorrhoea rates, need for additional intervention, and progression to hysterectomy. Follow-up was obtained from electronic health records and outpatient clinic reviews.

Primary outcome measures were treatment success and need for additional intervention, defined as repeat ablation or hysterectomy. Secondary outcomes included procedural complications and patient-reported symptom improvement.

Results

Both MinTouch® and NovaSure® groups demonstrated significant improvement in menstrual symptoms and high levels of patient satisfaction.

Within our departmental cohort, NovaSure® showed more durable symptom control, with a lower proportion of patients requiring further intervention over follow-up. In contrast, the MinTouch® group demonstrated a higher rate of secondary procedures, including repeat ablation and progression to hysterectomy in a subset of patients with persistent or recurrent heavy menstrual bleeding.

Overall, complication rates were low in both groups, with no major intra-operative complications recorded. Minor peri-operative events were comparable between the two cohorts and did not significantly impact recovery.

NovaSure® demonstrated a lower overall failure rate within our dataset, whereas MinTouch® showed promising early outcomes but a relatively higher proportion of long-term reintervention.

Conclusions

Both MinTouch® and NovaSure® endometrial ablation are safe and effective options for the management of heavy menstrual bleeding in appropriately selected patients. Within our departmental experience, MinTouch® demonstrated favourable early outcomes with good short-term symptom control and high initial success rates. However, over longer follow-up, NovaSure® showed more durable clinical effectiveness, with better sustained symptom relief and lower rates of reintervention, including repeat ablation and progression to hysterectomy. Overall, NovaSure® appeared to provide superior long-term treatment durability, whereas MinTouch® performed well in the early postoperative period but showed comparatively higher late failure rates. These findings highlight the importance of patient selection and counselling regarding expected short- and long-term outcomes when choosing between endometrial ablation technologies.

ESGE35-0398 - P296
ePoster Presentations

Obstetric complications of deep infiltrating endometriosis: a case series from a tertiary OB/GYN centre

Katarina Ivankova[1], *Zuzana Marvanova*[1]
[1]*Institute for Mother and Child Care- Prague- Czech Republic, Gynaecology, Prague, Czech Republic*

Background

Deep infiltrating endometriosis (DIE) is associated with increased obstetric risks, including spontaneous miscarriage, foetal growth restriction, placenta praevia, preeclampsia, antepartum haemorrhage, and a higher rate of caesarean delivery. During pregnancy, endometriotic lesions may undergo decidualisation, which can result in haemoperitoneum, weakening of the intestinal wall with risk of spontaneous rupture, or sonographic features mimicking ovarian malignancy. The objective of this case series was to describe maternal and perinatal outcomes in pregnancies complicated by DIE managed at a tertiary obstetric centre.

Methods

We conducted a retrospective analysis of 10 cases managed between 2020 and April 2026 at the Institute for Mother and Child Care, Prague. Data collected included method of conception (spontaneous vs. in vitro fertilisation [IVF]), pregnancy complications, perinatal outcomes, mode of delivery, intraoperative and postoperative blood loss, length of hospital and intensive care unit (ICU) stay, and history of prior surgical treatment for DIE.

Results

The mean maternal age at delivery was 33.7 years and the mean body mass index at conception was 23.4 kg/m². Conception was achieved via IVF in six cases; four pregnancies were spontaneous. Nine patients delivered by caesarean section and one by vaginal delivery. The mean blood loss associated with delivery or subsequent surgical revision was 1530 mL. A history of prior surgery for DIE was present in nine patients; one patient had no prior surgical treatment and was diagnosed on the basis of ultrasound findings alone.

The most frequent and severe complication was spontaneous haemoperitoneum, observed in four cases as the primary indication for emergency caesarean section. In one additional case, haemoperitoneum developed nine hours after an otherwise uncomplicated vaginal delivery. Further complications included preeclampsia, significant intraoperative bleeding, and extensive intra-abdominal adhesions.

Conclusions

Pregnancy in women with DIE carries a risk of rare but potentially life-threatening complications, most notably spontaneous haemoperitoneum, which may occur antepartum or in the immediate postpartum period. Multidisciplinary prenatal counselling and vigilant intrapartum monitoring are essential in this population. Clinicians should maintain a high index of suspicion for haemoperitoneum regardless of the mode of delivery. Further large-scale prospective studies are

needed to better define the incidence and management of obstetric complications associated with DIE.

ESGE35-0402 - P298
ePoster Presentations

Postoperative C-reactive protein after argon plasma coagulation ablation of ovarian endometriomas in patients undergoing bowel surgery for deep endometriosis

Francesca de Simone[1,2], Linda Bertoldo[1,2], Alberto Aguzzi[1,2], Elio Fabbri[3], Renato Seracchioli[1,2], Diego Raimondo[1]
[1]IRCCS Azienda Ospedaliero - Universitaria di Bologna,
Division of Gynaecology and Human Reproduction Physiopathology, Bologna, Italy
[2]University of Bologna, Department of Medical and Surgical Sciences DIMEC, Bologna, Italy
[3]University of Bologna, Department of Biomedical and Neuromotor Sciences, Bologna, Italy

Background

Since C-reactive protein (CRP) is routinely used after bowel surgery for Deep Endometriosis (DE) to detect postoperative inflammatory complications, tissue damage caused by Argon Plasma Coagulation (APC) ablation of ovarian endometriomas may represent a confounding factor in postoperative CRP interpretation. Hence, the aim of this study was to compare CRP levels between patients undergoing elective bowel surgery for DE with or without the ablation of ovarian endometriomas using APC.

Methods

A single-center observational retrospective cohort study was conducted, including all reproductive-age patients who underwent bowel surgery for DE (shaving, discoid resection, segmental resection) and excluding patients who developed postoperative complications during hospital stay that could have independently affected CRP levels. Data about patient history, pre-operative ultrasound, operative reports and CRP values on the third postoperative day were collected. The primary outcome was the comparison of POD 3 CRP values between patients who underwent APC ablation and those who did not. The secondary outcome was the correlation between endometrioma volume (estimated on preoperative ultrasound) and POD 3 CRP values in patients undergoing APC ablation. Continuous variables were compared using Student's t-test or Mann–Whitney U test, as appropriate. Correlations were assessed using Pearson's correlation coefficient. A p-value <0.05 was considered statistically significant.

Results

A total of 94 women were included. Mean age at surgery was 38 years (range: 24-52). 45 (47.9%) patients underwent intraoperative ovarian endometriomas ablation with APC, while 49 did not. Bowel surgery was performed by shaving in 31 (33.0%) patients, discoid resection in 28 (29.8%), and segmental bowel resection in 35 (37.2%). On POD 3, the mean CRP value was 6.8 mg/dL (range: 0.7–33.7 mg/dL) in patients who underwent APC ablation and 7.0 mg/dL (range: 0.2–17.6 mg/dL) in those who did not. No significant difference in POD 3 CRP values was found between the two groups (p=0.973), even after stratifying by bowel surgical technique (p=0.572, p=0.479, and p=0.389, respectively). No significant correlation (r=-0.114; p=0.453) was found between endometrioma volume and CRP values on POD 3 in the APC ablation group.

Conclusions

Ablation of ovarian endometriomas using APC does not appear to significantly influence postoperative CRP values in patients undergoing bowel surgery for DE. Endometrioma volume was not associated with postoperative CRP values. These findings suggest that the use of APC is unlikely to interfere with postoperative CRP levels and, consequently, to mimic early postoperative inflammatory complications.

ESGE35-0406 - P299
ePoster Presentations

When the Vessel Won't Stop Bleeding: A Strategic Pivot in Laparoscopic Hysterectomy

Yavuz Yilmaz[1], Omer Faruk Oz[1], Can Dinc[1], Selen Dogan[2], Murat Ozekinci[3], Inanc Ibrahim Mendilcioglu[4]
[1]Akdeniz University, Obstetrics and Gynaecology- TR-MIGS, Antalya, Türkiye
[2]Akdeniz University, Gynecologic Oncology- Obstetrics and Gynaecology- TR-MIGS, Antalya, Türkiye
[3]Akdeniz University, Reproductive Endocrinology and Infertility- Obstetrics and Gynaecology- TR-MIGS, Antalya, Türkiye
[4]Akdeniz University, Maternal-Fetal Medicine- Obstetrics and Gynaecology- TR-MIGS, Antalya, Türkiye

Background

To demonstrate strategic intraoperative decision-making during total laparoscopic hysterectomy (TLH) complicated by recurrent uterine artery bleeding unresponsive to repeated haemostatic attempts, and to illustrate the technique of safe laparoscopic bladder dissection in the setting of dense post-caesarean adhesions at the level of the lower uterine segment.

Methods

A 46-year-old woman (gravida 2, para 2, both deliveries by caesarean section) presented with a two-month history of abnormal uterine bleeding and anaemia (haemoglobin 8.2 g/dL). Endometrial biopsy had previously revealed endometrial polyps. Transvaginal ultrasound demonstrated an irregular endometrium of 8 mm with bilateral ovaries appearing normal. Total laparoscopic hysterectomy was planned. During the procedure, recurrent bleeding from the left uterine artery was encountered following repeated haemostatic sealing attempts, each of which failed to achieve durable haemostasis.

A deliberate surgical decision was made to temporarily leave the bleeding vessel and proceed to complete the contralateral uterine artery ligation and rapid vaginal cuff development, thereby expediting completion of the hysterectomy and achieving haemostatic control through uterine devascularisation rather than direct vessel control.

This strategy required negotiating dense bladder adhesions at the level of the previous caesarean scar. The bladder was mobilised using a combination of sharp laparoscopic scissor dissection, hydrodissection with continuous suction-irrigation, and judicious energy-based tissue division, allowing safe entry into the vesicovaginal space. The vaginal cuff was then rapidly completed and closed.

Results

Haemostasis was achieved upon completion of the hysterectomy without the need for conversion to laparotomy or additional vascular control measures.

Bilateral ureteric integrity was confirmed intraoperatively by direct visualisation of ureteric peristalsis on both sides. No ureteric, bladder, or bowel injury was identified. The patient was discharged uneventfully on postoperative day two.

Conclusions

When repeated direct haemostatic attempts at a uterine artery fail during TLH, completing the hysterectomy through rapid contralateral devascularisation and vaginal cuff closure is a safe and effective alternative strategy. Dense post-caesarean bladder adhesions can be safely managed laparoscopically through a multimodal dissection approach combining sharp dissection, hydrodissection, and energy-based techniques. Bilateral ureteric visualisation at the conclusion of the procedure remains mandatory in all complex laparoscopic hysterectomies.

ESGE35-0410 - P300
ePoster Presentations

Impact of a Nurse-Led Outpatient Hysteroscopy Service on Access, Efficiency, and Early Cancer Detection.

Shawn Marie Robinson[1], Monica Del Peral[2], Rhonda Flemming[1], Guldzhan Vorona[1]
[1]Whittington Hospital Trust, Gynaecology, London, United Kingdom
[2]Whittington Hopsital Trust, Gynaecology, London, United Kingdom

Background

Rising demand for gynaecology services within the NHS has led to persistent delays in diagnostic and operative care, with only 56–61% of patients treated within the 18-week target and average waits of 14–18 weeks (NHS England, 2024). Outpatient hysteroscopy, endorsed by the Royal College of Obstetricians and Gynaecologists and the British Society for Gynaecological Endoscopy, offers a safe and effective ambulatory alternative to inpatient procedures, reducing reliance on general anaesthesia and theatre capacity (RCOG, 2022; BSGE, 2023). In response to NHS elective recovery priorities, a Nurse-Led Outpatient Hysteroscopy Service was established to improve patient access, streamline care, and facilitate early detection of endometrial pathology (NMC, 2018; BSGE, 2023).

Objectives

To evaluate the impact of a Nurse-Led Outpatient Hysteroscopy Service on waiting list reduction, patient access, procedural outcomes, and delivery of ambulatory gynaecology care over a one-year period.

Methods

A retrospective service evaluation was conducted using electronic patient records, procedural databases, and patient-reported outcome measures from 2025. Key outcomes included procedural volume, operative interventions, levonorgestrel intrauterine system (Mirena) insertions, cancer detection rates, and pain scores. Performance was benchmarked against national standards from the NHS, British Society for Gynaecological Endoscopy, Nursing and Midwifery Council, and Royal College of Obstetricians and Gynaecologists

Results

A total of 1,021 outpatient hysteroscopies were independently performed by a Nurse Hysteroscopist, including 571 diagnostic and 450 operative procedures, alongside 107 Mirena insertions or replacements. Twelve cases of endometrial cancer were identified and appropriately referred via urgent cancer pathways, enabling timely diagnosis and management. The mean patient-reported pain score was 5/10, consistent with accepted outpatient tolerability standards and comparable to doctor-led services. Procedural volume exceeded that typically reported for individual clinician-led practice, demonstrating high service capacity. The implementation of a “see-and-treat” model reduced dependence on theatre-based care and contributed to improved patient flow within a system facing prolonged waiting times.

Conclusions

The Nurse-Led Outpatient Hysteroscopy Service significantly enhanced service efficiency, reduced waiting list burden, and supported early cancer detection. High procedural throughput, effective operative capability, and acceptable patient experience highlight the role of advanced Nurse Hysteroscopists as safe and autonomous practitioners. Expansion of nurse-led hysteroscopy services represents a scalable and sustainable strategy to support NHS elective recovery while maintaining high clinical standards.

ESGE35-0418 - P301
ePoster Presentations

Modified Docking Configuration for the Hugo™ RAS System in Gynecologic Oncology: A Single-Setup Strategy for Pelvic and Lumboaortic Procedures

Sara Mastrovito[1], Andrea Rosati[1], Emanuele Perrone[1], Riccardo Oliva[1], Davide Arrigo[1], Francesco Fanfani[1]
[1]Fondazione Policlinico Universitario A. Gemelli IRCCS,
Department of Women's and Children's Health- Gynecologic Oncology Complex Unit, Rome, Italy

Background

The Hugo™ robotic-assisted surgery (RAS) system is a modular robotic platform with independent arm carts that enable multiple docking configurations. In gynecologic surgery, a standardized docking strategy using the published “Bridge” port placement and “Compact” configuration has been described and validated for pelvic procedures.
However, the extensive experience gained with the system since its release, together with the introduction of advanced energy devices (LigaSure™ RAS) and indocyanine green vision, has expanded robotic gynecologic oncology to complex multi-quadrant procedures such as lumboaortic lymphadenectomy and upper abdominal staging.
In these procedures, the conventional configuration may limit instrument reach and increase robotic arm collisions, potentially requiring redocking.
We aimed to develop and clinically validate a modified docking configuration to improve access to both pelvic and upper abdominal targets without need for redocking and to minimize collisions.

Methods

We designed a modified docking strategy based on progressive adjustments of arm tilt and trocar positioning. The tilt angles of robotic arms 2 and 3 were increased from −45° to −15°, expanding their cranial range of motion and facilitating access to the para-aortic region.
Trocar placement was adapted accordingly, with the trocars for arms 1 to 3 placed on the transumbilical line and the trocar for arm 4 positioned more cranially to allow effective bowel retraction during upper abdominal dissection. A second variation of the configuration was also developed, placing the trocar for arm 3 slightly below the umbilical line.
This adjustment improves perpendicular access to pelvic structures and may be advantageous in procedures focused on pelvic surgery, including sentinel lymph node mapping or pelvic lymphadenectomy, where the third arm is commonly used for LigaSure or monopolar shears.
This docking strategy was applied in a consecutive cohort of 80 robotic gynecologic oncology procedures performed at our institution, including 20 cases requiring upper abdominal surgery with lumboaortic lymphadenectomy. Feasibility, need for redocking, and intraoperative workflow were assessed.

Results

The modified docking configuration was successfully implemented in all cases. Adequate instrument reach to the upper abdomen was consistently achieved, allowing completion of the procedures without the need for robotic redocking. Across the cohort, the modified setup reduced external arm interference and maintained a smooth operative workflow. No docking-related conversions or major technical limitations were observed.

Conclusions

A modified Hugo RAS docking configuration with increased arm tilt and adjusted trocar placement enables safe and efficient performance of multi-quadrant gynecologic oncology procedures, including lumboaortic lymphadenectomy, without redocking. The proposed setup preserves optimal pelvic access while extending reach to the upper abdomen and may represent a practical standardized configuration for complex robotic gynecologic surgery.

ESGE35-0422 - P302
ePoster Presentations

Obstetrics complications after hysteroscopic metroplasty for dysmorphic uterus

Laura Pérez Martín[1], Duna Trobo Marina[1], Cecilia Garcia Diaz[1], Ainoa Saez Prat[1], Laura Perez Burrel[1], Federico Mariano Perez Milan[1]
[1]Hospital General Universitario Gregorio Marañón, Obstetrics and Gynaecology, Madrid, Spain

Background

Congenital uterine anomalies, particularly T-shaped uterus, have been associated with infertility, recurrent implantation failure, miscarriage, and adverse obstetric outcomes, including preterm birth. Hysteroscopic metroplasty has emerged as a minimally invasive surgical approach aimed at restoring normal uterine cavity anatomy and improving reproductive outcomes. Although several studies have reported favourable fertility and pregnancy results following the procedure, concerns remain regarding its potential impact on uterine integrity and the subsequent risk of preterm delivery. The evidence available is still limited and heterogeneous. This study aims to evaluate obstetric outcomes, with a specific focus on preterm birth, in patients undergoing hysteroscopic metroplasty for T-shaped uterus.

Methods

Descriptive retrospective study reporting obstetric complications occurred in pregnancies achieved after hysteroscopic metroplasty for dysmorphic uterus, either spontaneously or after ART (Assisted Reproduction Techniques), in a tertiary University Hospital in Madrid (Spain) between January 2023 and December 2025. Result variables in the eare expressed in absolute numbers and percentages.

Results

A total of 42 hysteroscopic metroplasties were performed during the study period in patients diagnosed with dysmorphic uterus. Among them, 22 patients were diagnosed with T-shaped uterus, 12 with Y-shaped uterus, 6 with I-shaped uterus, and 2 with incomplete uterine septum. Mean patient age was 37,8 years, with a mean infertility duration of 2,21 years. Mean Anti-Müllerian Hormone levels were 2,33 ng/ml. Twenty out of 42 patients had a history of previous uterine surgery: 3 myomectomies, 16 uterine curettages, and 1 caesarean section. Concomitant endometriosis or adenomyosis was present in 6 patients. Eight patients required two procedures in order to achieve a satisfactory metroplasty (19%). Bipolar energy was used in 22 procedures, whereas scissors were employed in 20 cases. Anti-adhesion treatment with intrauterine hyaluronic acid gel was administered in 28 patients. Postoperative intrauterine adhesions were diagnosed in 5 patients. Among the 42 patients who underwent metroplasty, 19 achieved pregnancy. Five pregnancies occurred spontaneously, whereas 14 were achieved through assisted reproductive techniques. A total of 6 obstetric complications were recorded during pregnancy, including 4 patients hospitalized for risk of preterm labour, 1 case of placenta accreta, 1 case of type I fetal growth restriction, 1 postpartum hemorrhage due to uterine atony, and 1 patient with hypertensive disorder during pregnancy.

Conclusions

Hysteroscopic metroplasty in patients with dysmorphic uterus appears to be a feasible and overall safe procedure, with encouraging reproductive outcomes following both spontaneous conception and assisted reproductive techniques. Obstetric complications during pregnancy remained relatively uncommon and were mainly manageable within standard obstetric care. Further prospective studies with larger cohorts are warranted to better define the reproductive and obstetric outcomes associated with hysteroscopic correction of dysmorphic uterine cavities.

ESGE35-0427 - P304
ePoster Presentations

The Difficult Laparoscopic Hysterectomy: Managing a Triple Intraoperative Challenge — Enlarged Uterus, Manipulator Dislodgement with Posterior Bleeding, and Difficult Vaginal Extraction

Can Dinç[1], Ömer Faruk Öz[1], Selen Doğan[2], Nasuh Utku Doğan[1], Murat Özekinci[3], İbrahim İnanç Mendilcioğlu[4]
[1]Akdeniz University, Obstetrics and Gynaecology- TR-MIGS, Antalya, Türkiye
[2]Akdeniz University, Gynecologic Oncology- Obstetrics and Gynaecology- TR-MIGS, Antalya, Türkiye
[3]Akdeniz University, Reproductive Endocrinology and Infertility- Obstetrics and Gynaecology- TR-MIGS, Antalya, Türkiye
[4]Akdeniz University, Maternal-Foetal Medicine- Obstetrics and Gynaecology- TR-MIGS, Antalya, Türkiye

Background

To demonstrate structured intraoperative decision-making during total laparoscopic hysterectomy with bilateral salpingo-oophorectomy (TLH+BSO) complicated by three simultaneous challenges: a markedly enlarged fibroid uterus, intraoperative uterine manipulator dislodgement with posterior colpotomy bleeding, and difficult vaginal specimen extraction requiring retractor assistance.

Methods

A 48-year-old woman (gravida 1, para 1, caesarean section) presented with a three-month history of heavy abnormal uterine bleeding, changing up to one pad per hour. She had a known history of uterine fibroids and a prior laparoscopic myomectomy performed on two occasions ten years prior. She was on anticoagulant therapy for deep vein thrombosis diagnosed two years earlier. Transvaginal ultrasound demonstrated a 73×72 mm degenerated fibroid arising from the uterine fundus and a 30 mm isthmic fibroid. Pipelle endometrial biopsy was performed. TLH+BSO was planned.

During the procedure, three sequential intraoperative challenges were encountered and managed: **Enlarged uterus:** Markedly enlarged fibroid uterus significantly restricted laparoscopic working space and instrument triangulation, requiring stepwise adaptation of the operative approach.

Manipulator dislodgement + posterior bleeding: During posterior colpotomy, the uterine manipulator dislodged from the cervix, obscuring the posterior vaginal fornix and causing local bleeding. The posterior colpotomy was completed under direct laparoscopic vision without manipulator guidance, with haemostasis achieved laparoscopically.

Difficult vaginal extraction: Due to uterine size, transvaginal specimen extraction was not achievable by conventional means. A vaginal retractor was employed to expand the introitus and facilitate controlled specimen delivery.

Results

All three challenges were successfully managed without conversion to laparotomy. TLH+BSO was completed laparoscopically.

Bilateral ureteric integrity was confirmed by direct visualisation of ureteric peristalsis. No visceral injury was identified. The patient was discharged on postoperative day two without complications.

Conclusions

Laparoscopic hysterectomy for an enlarged fibroid uterus demands anticipation of multiple simultaneous intraoperative challenges. Manipulator dislodgement during colpotomy does not necessitate conversion — posterior colpotomy can be safely completed under direct laparoscopic vision. When transvaginal extraction is impeded by specimen size, a vaginal retractor is a simple and effective adjunct. Structured sequential problem-solving and composure are the key determinants of success in the difficult laparoscopic hysterectomy.

ESGE35-0450 - P306
ePoster Presentations

Exploring laparoscopic sterilisation requests referred to a Gynaecological Multi-Disciplinary Meeting at a tertiary centre in the United Kingdom

Hailey Sathyavan[1], Anna-Lucia Koerling[2], Diab Yasser[2], Archana Vasireddy[2]
[1]King's College London, Women's Services, London, United Kingdom
[2]Guy's and St Thomas' NHS Foundation Trust, Women's Services, London, United Kingdom

Background

In 2024-25, 10,793 female sterilisations were carried out in the United Kingdom. Current Faculty of Sexual and Reproductive Healthcare (FSRH) guidance states that patients requesting sterilisation should have decision-making capacity, understand the irreversible nature of the procedure, be informed of alternative contraception options including long-acting contraceptives (LARC), and understand the risk of procedure failure. This study aims to highlight the key themes of sterilisation requests referred to the Benign Gynaecology Multi-Disciplinary Meeting (MDM), and how these may impact future practice.

Methods

Outcomes of all patients discussed at the benign gynaecology MDM between February 2024 and February 2026 at Guy's and St. Thomas' Hospital Trust were retrospectively reviewed. Data collected included: indication for referral, age, parity, past medical history, past surgical history, and MDM outcome. Key themes were then extracted from this data.

Results

Between February 2024 and February 2026, 15 requests for sterilisation were discussed at the Benign Gynaecology MDM. Patients ranged from 21-39 years; 11 of 15 patients were nulliparous. Following initial MDM discussion, 6 patients were listed for surgery – either laparoscopic tubal ligation with clips or bilateral salpingectomy.

Four key themes emerged from the referrals: which included medical and genetic concerns, contraceptive failure or intolerance, psychosocial trauma history, and reproductive autonomy. Medical and genetic concerns included fears surrounding transmission of inherited or chronic medical conditions to any future children. Some patients expressed concerns around contraceptive failure and previously experiencing adverse effects from other forms of contraception.

Of the requests that the MDM team advised were outside of standard practice, recurring themes were identified. These included significant high surgical risk (in the presence of alternative forms of contraception like LARCs which would be equally as effective); pre-existing psychiatric concerns requiring further input; and concerns regarding future fertility wishes. An argument is to be made in regard to the role of autonomy in these decisions.

Conclusions

This study highlights the conflict between reproductive autonomy and best interest decisions recommended by clinicians. MDM recommendations aimed to reduce surgical risk while considering co-morbidities, future fertility wishes and the potential for future regret when sterilisation is requested early in adult life. MDT discussion in benign gynaecology is essential when patient choice falls outside standard practice. In such situations, MDT provides collective expert review to balance patient autonomy with clinical safety, supports transparent decision making, ensures realistic counselling and promotes defensible evidence-based care. It provides opportunities for new ideas from the diverse expertise of the team. The authors are also interested in the outcomes of the SALSTER study, which can hopefully help with ensuring the best sterilisation methods are used during surgery – laparoscopic tubal ligation with clips versus bilateral salpingectomy.

ESGE35-0462 - P308
ePoster Presentations

Beyond Rupture: Clinical Severity and Surgical Timing in Tubal Ectopic Pregnancy

Nissim Arbib[1], Chen Manor Bar[1], yair dykan[1], Zvi Klein[1], Doron Ben Ari Adiv[2], Shanny Kolp-Asis[3]
[1]Gray Faculty of Medical and Health Sciences- Tel Aviv University- Tel Aviv- Israel., Department of Obstetrics and Gynaecology- Meir Medical Center- Kfar Saba- Israel, Kfar Saba, Israel
[2]gray faculty of medical and health Sciences- tel aviv university- tel aviv- israel., Department of Obstetrics and Gynaecology- Meir Medical Center- Kfar Saba- Israe, kfar saba, Israel
[3]Gray Faculty of Medical and Health Sciences- Tel Aviv University- Tel Aviv- Israel., Department of Obstetrics and Gynaecology- Mayanei Hayeshua Medical Center- Bnei Brak- Israel, Bnei Brak, Israel

Background

To evaluate which preoperative clinical, laboratory, and sonographic findings are associated with tubal ectopic pregnancy rupture and whether these factors are reflected in real-world surgical timing.

Methods

This retrospective cohort study included all women who underwent surgical management for first-trimester tubal ectopic pregnancy at a single tertiary medical center between 2016 and 2024. Patients were classified according to intraoperative findings as ruptured or non-ruptured ectopic pregnancy. Demographic, clinical, laboratory, sonographic, and surgical data were collected, including time from diagnosis to surgery. Multivariable logistic regression was performed to identify independent factors associated with rupture, and multivariable linear regression was used to evaluate factors associated with surgical timing.

The study has been approved by the IRB.

Results

A total of 282 women with surgically confirmed tubal ectopic pregnancy were included, of whom 100 (35.5%) had intraoperatively confirmed rupture. Hemoperitoneum (70% vs. 33.1%, p<0.001), peri-adnexal blood clots (53% vs. 26.4%, p<0.001), abdominal pain (93% vs. 71.4%, p<0.001), and lower haemoglobin levels at diagnosis (11.7 ± 1.4 vs. 12.4 ± 1.2 g/dL, p=0.001) were more common among women with rupture. In multivariable logistic regression analysis, peri-adnexal blood clots (aOR 2.04, 95% CI 1.10–3.77), abdominal pain (aOR 3.06, 95% CI 1.22–7.68), lower haemoglobin levels (aOR 0.75, 95% CI 0.60–0.94), and moderate to severe hemoperitoneum were independently associated with rupture. Although ruptured cases undergoing surgery for hemodynamic instability or hemoperitoneum had shorter diagnosis-to-surgery intervals, no individual clinical, laboratory, or sonographic variable, including rupture status itself, was independently associated with shorter time to surgery in multivariable analysis. ROC analysis demonstrated only modest discriminatory performance of individual variables for predicting rupture.

Conclusions

Objective markers of intra-abdominal bleeding were associated with tubal rupture in surgically managed ectopic pregnancies. However, rupture status itself was not independently associated with shorter time to surgery. These findings suggest that surgical timing in clinical practice is based on an overall assessment of clinical severity rather than on rupture status alone

ESGE35-0475 - P309
ePoster Presentations

Ovarian Ectopic Pregnancy- a clinical paradox

Nissim Arbib[1], Chen Manor Bar[1], Doron Ben Ari Adiv[1], Hadar Gluska[1], Zvi Klein[1], Yael Yagur[1]
[1]Gray Faculty of Medical and Health Sciences- Tel Aviv University- Tel Aviv- Israel.,
Department of Obstetrics and Gynaecology- Meir Medical Center- Kfar Saba- Israel, Kfar Saba, Israel

Background

Ectopic pregnancy is a leading cause of first-trimester morbidity and mortality. While 95–97% occur in the fallopian tubes, ovarian ectopic pregnancy is rare, accounting for only 0.5–3% of cases. Despite its rarity, ovarian ectopic pregnancy poses distinct diagnostic and surgical challenges compared with tubal ectopic pregnancy.
Study Objective was to compare the clinical, sonographic, and surgical characteristics of ovarian versus tubal ectopic pregnancy and to identify factors contributing to its frequent preoperative misdiagnosis

Methods

Retrospective cohort study.

Setting: Tertiary referral center.
Patients or Participants: A total of 293 women surgically treated for ectopic pregnancy between 2016 and 2024, including 182 unruptured tubal, 100 ruptured tubal, and 11 ovarian ectopic pregnancies.
Interventions: Surgical management including salpingectomy, salpingostomy, or ovarian wedge resection, with intraoperative and histopathological confirmation.
Clinical characteristics, laboratory parameters, and ultrasound findings were compared between groups.
The study has been approved by IRB

Results

Measurements and Primary Results: Baseline characteristics were similar across groups, except for higher intrauterine device use among women with ovarian ectopic pregnancy (p=0.004). Ovarian ectopic pregnancy was associated with significantly greater intraoperative blood loss compared with ruptured and unruptured tubal ectopic pregnancy (928.6 ± 521.9 mL vs. 695.7± 609.3 mL and 225.9 ± 382.1 mL; p<0.001). Despite this, patients with ovarian ectopic pregnancy reported lower pain scores (VAS 3.2 ± 3.4 vs. 5.3 ±3.5 and 4.6 ± 4.2; p<0.001), less frequent abdominal pain (71.4% vs. 93% and85.7%; p<0.001), and lower rates of hemodynamic instability (7.1% vs. 25.0%and 14.3%; p<0.001). None of the ovarian ectopic pregnancies were diagnosed preoperatively, with most misclassified as ruptured tubal ectopic pregnancy.

Conclusions

Conclusion: Ovarian ectopic pregnancy represents a clinical paradox, with mild symptoms despite significant hemoperitoneum, leading to frequent preoperative misdiagnosis. Clinicians should maintain a high index of suspicion to improve recognition and optimize surgical preparedness and intraoperative decision-making. Given its greater surgical complexity compared with tubal ectopic pregnancy, accurate preoperative diagnosis is essential.

ESGE35-0518 - P312
ePoster Presentations

Hysteroscopy for caesarean scar pregnancy

Irem Usta Korkut[1], *Ece Aksakal*[1], *Aylin Pelin Cil*[1]
[1]*American Hospital, Women's Health Center, İstanbul, Türkiye*

Background

Caesarean scar pregnancy occurs when a new pregnancy implants in a previous caesarean incision. It causes bleeding in early pregnancy, and as the pregnancy progresses, it continues as placenta accreta. Its incidence is 1 in 2000 births. Caesarean scar pregnancy can be treated with D&C, intracavitary or systemic methotrexate therapy, hysteroscopy, or laparoscopy.

Methods

A 35-year-old female patient, G6P5, with a history of 5 caesarean sections. The patient, diagnosed with caesarean scar pregnancy at another center, presented to our clinic with vaginal bleeding. On examination, the pregnancy was 6+1 weeks according to the last menstrual period (LMP). Transvaginal ultrasonography showed a 13 mm gestational sac (GS) at the caesarean scar line. CRL was consistent with 5+5 weeks, Foetal cardiac activity was negative. Vaginal bleeding was observed. The patient was scheduled for hysteroscopy

Results

The cavity was accessed via office hysteroscopy. A bleeding area was observed in front of the gestational sac located on the anterior wall. The gestational sac was separated from the uterine cavity by hydrodissection. Vacuum aspiration was then performed using a size 6 Karman cannula. Hysteroscopy after aspiration showed no intra-cavity bleeding. The procedure was completed without complications.

Conclusions

Bleeding is a complication that complicates the management of pregnancies with caesarean scars. D&C is a blind procedure. In cases of methotrexate administration, patient follow-up and treatment should continue. In suitable patients, a hysteroscopic approach may be preferred because it allows visualization of the cavity, provides both diagnostic and therapeutic opportunities, and shortens the patient's follow-up period.

ESGE35-0521 - P313
ePoster Presentations

Feasibility of Robotic LigaSure™ in Hugo™ RAS Robotic-Assisted Hysterectomy: Effects on Operative Time and Blood Loss

Nadin Alghanaim[1], Dean Conrad[2], Amani Harris[2], Andrew Zuschmann[2], Rawan Alghamdi[3], Danny Chou[3]
[1]King Abdulaziz University, Obstetrics and Gynaecology, Jeddah, Saudi Arabia
[2]Sydney Minimally Invasive Gynaecological Surgery Centre, Obstetrics and Gynaecology, Sydney, Australia
[3]Sydney Women's Endosurgery Centre, Obstetrics and Gynaecology, Sydney, Australia

Background

The Hugo™ RAS system (Medtronic, United States), launched in 2022, is recognized for its innovative design, which includes an open console and independent robotic arms, allowing for greater flexibility in configuration. Research has demonstrated the feasibility of using the Hugo RAS system in benign gynaecological surgeries, along with insights into the learning curve related to docking and operation times. The goal of our study is to evaluate the effects of robotic LigaSure™ compared to standard fenestrated bipolar and monopolar scissors on operative time and blood loss during Hugo™ RAS robotic-assisted hysterectomy.

Methods

A retrospective observational pilot study was conducted by reviewing operative records from January 2023 to October 2025. Descriptive statistics, independent t-tests, Fisher's exact tests, and multiple linear regression were used, adjusting for patient age, BMI, and uterine size. We compared robotic LigaSure™ with standard fenestrated bipolar graspers and monopolar scissors for vessel sealing and tissue dissection. All procedures were performed at Hurstville Private Hospital using the Hugo™ RAS robotic platform. Patient positioning and docking protocols were standardized and optimized.

Thirty-four patients undergoing robotic-assisted hysterectomy for benign gynecological conditions were included. Seventeen procedures employed robotic LigaSure™, while seventeen utilized standard instrumentation. Eligibility criteria included age of 18 years or older and uterine weight of less than 250 g. All surgeries were performed by Drs. Dean Conrad and Danny Chou. Institutional Review Board approval was obtained, and informed consent was not required because the study was observational.

Results

Primary outcomes included operative time and estimated blood loss (EBL). The LigaSure™ group demonstrated a significantly shorter mean operative time (50.4 ± 13.7 minutes) compared to the standard instrument group (58.9 ± 16.9 minutes; $P < 0.05$). No significant difference was found in EBL ($P = 0.951$). Multiple regression analysis confirmed a reduction in operative time of 4.6 minutes (95% confidence interval: –9.3 to 0.2; $P < 0.05$) associated with LigaSure™, independent of age, BMI, and uterine weight. A trend suggesting a learning curve was noted for docking and operative times.

Conclusions

The use of robotic LigaSure™ in Hugo™ RAS robotic-assisted hysterectomy is feasible and is associated with reduced operative time without increased blood loss. These findings indicate potential workflow efficiencies and underscore the need for further large-scale, prospective studies to evaluate clinical and economic benefits.

ESGE35-0524 - P314
ePoster Presentations

Relugolix Combination Therapy: ultrasound morphological response of endometriosis and adenomyosis

Valentina Colantonio[1], Elvira Nocita[2], Giulia Monaco[2], Meriem Jamhour[2], Alfredo Ercoli[3], Caterina Exacoustos[2]
[1]University of Naples "Federico II", Department of Public Helth, Naples, Italy
[2]University of Rome "Tor Vergata", Department of Surgical Sciences- Gynecological Unit, Rome, Italy
[3]University of Rome "Tor Vergata", Department of Biomedicine and Prevention- Gynecological Unit, Rome, Italy

Background

The aim of the study is to evaluate by transvaginal ultrasound morphological changes of pelvic endometriosis and adenomyosis before and during treatment with Relugolix Combination Therapy (CT) (relugolix/estradiol/norethisterone acetate). Furthermore symptom variations and quality of life were evaluated during follow-up period.

Methods

A retrospective observational study was conducted including premenopausal patients with an ultrasound diagnosis of adenomyosis and/or pelvic endometriosis, with or without concomitant uterine fibroids, who were treated with RelugolixCT (once daily oral) for at least 6 months. Clinical and sonographic data were routinely collected before treatment (T0), during first follow-up scan (at 3–6 months, T1), and at the second follow-up evaluation (at 7–12 months, T2). Transvaginal sonography examinations were performed according to standardized protocols (Idea and Musa). The pelvic disease was classified according to Enzian score. Symptom severity was assessed using a visual analogue scale (VAS).

Results

50 patients (mean age 44.0 ± 6.7 years) met inclusion criteria having a follow up period ranging between 3 and 12 months. During follow up period 17% of patients reported a persistent pelvic pain. Persistent dysmenorrhea was reported during treatment in 4% of cases and 34% of patients who reported dyspareunia at the baseline still had the symptom during follow-up with improvement of VAS score (6.3±2.1 vs 3.4±3.5 p = 0.002). Diffuse adenomyosis was observed in 42 (86,2%) patients at starting follow-up associated to fibroids in 53.3% of cases. A significant uterine volume reduction was observed at T1 (176.4±143.3 Vs 128.8± 72.8 cm3 p = 0,00008) confirmed at T2. Uterine fibroid decreased in volume, passing by 21.6±27.4 cm3 (T0) to 19.4±30.2 cm3 (T1), no further reduction in volume, vascularizations or number of fibroids was observed at T2. Adenomyosis, despite the uterine volume reduction, showed at T1 and T2 still ultrasound direct signs. Endometrioma prevalence was 30% at T0 and remains the same during the follow up period, showing online a slight decrease in size. No statistically significant sonographic changes in deep infiltrating endometriosis nodules were detected throughout the follow-up period. Enzian score remains still unchanged for all compartments expect for O.

Conclusions

In this retrospective cohort, treatment with RelugolixCT led to a significant reduction in uterine and fibroid volume, and improvement in painful symptoms. While endometriosis and adenomyosis showed no major morphological changes, endometriomas underwent a slight decrease in size. These results suggest a selective clinical and structural effect on fibroid compartments, with limited impact on infiltrative endometriotic lesions and adenomyosis.

ESGE35-0548 - P316
ePoster Presentations

Robotic radical hysterectomy in an apparent IB1 cervical cancer patient without uterine manipulator: step-by-step technique

Stamatios Petousis[1], *Chrysoula Margioula-Siarkou*[1]
[1]*Aristotle University of Thessaloniki, 2nd Department of Obstetrics and Gynaecology, Thessaloniki, Greece*

Background

A robotic approach might be feasible and safe for selected cervical cancer patients. The main objective of the present study is to report the case of a patient with apparent IB1 cervical cancer who was treated with robotic radical hysterectomy, as well as to describe the corresponding surgical technique performed without the use of a uterine manipulator.

Methods

Epidemiological and histopathological characteristics were reviewed, and a video recording of the robotic procedure was used to create a short surgical video.

Results

This is the case of a 52-year-old patient who presented following a cone biopsy, in which a squamous cell carcinoma of the cervix measuring 1.2 cm with a depth of invasion of 7 mm was identified, without lymphovascular invasion and with clear margins. After negative lymph node staging (robotic sentinel lymph node biopsy with negative frozen section and complete pelvic lymphadenectomy, which initially demonstrated no infiltrated lymph nodes), and following informed consent, a robotic radical hysterectomy type B according to Querleu classification was performed. The operation lasted 150 minutes, with a drop in hemoglobin from 12.3 to 11.3 g/dL.

Basic anatomical steps of type-B radical hysterectomy should include, among others, the preparation of paravesical and pararectal spaces, the identification, preparation and mobilization of ureter, the identification and ligitation of uterine vessels, the preparation of lateral parametrium by continuous mobilization of ureter and decollation from pelvic peritoneum and attaching parametrium, the preparation of ventral parametrium through opening of the paravesical space and identification of vesicouterine ligaments, the preparation of dorsal parametrium through preparation of rectouterine space and ligitation of uterosacral ligaments.

The intraoperative course was uneventful. The patient was discharged on the first postoperative day, while her postoperative course during the first two months was uncomplicated. As preventive measures to avoid disease dissemination, a vaginal cuff was created, and instead of a uterine manipulator, the broad surface of a trocar guide was used. The parametrial extension in the histopathological specimen was 3.5 cm on the left and 4.5 cm on the right, while the length of the resected vaginal segment was 2.5 cm. The specimen margins were free of disease.

Avoidance of manipulator usage may decrease the possibility of cancerous spread while permitting adequate exposure of safe vaginal anatomical margins for radical resection.

Conclusions

The management of selected cases of cervical cancer is still feasible and safe with robotic surgery under specific clinical and technical conditions. Avoiding the use of a uterine manipulator significantly reduces the risk of disease dissemination and recurrence at the vaginal cuff.

ESGE35-0594 - P319
ePoster Presentations

National Endometriosis Frameworks in High-Income Countries: How Does Ireland Compare?

Sarah Murphy[1]
[1]*CUMH, Obstetrics and Gynaecology, Roscommon, Ireland*

Background

Endometriosis is a chronic inflammatory condition requiring complex multidisciplinary management. Over recent years, several high-income countries have introduced national strategies and accredited specialist networks to improve diagnosis, access to care and surgical outcomes. Ireland recently introduced both a National Clinical Guideline and a National Framework for Endometriosis Care. Comparative evaluation of international models may identify strengths, limitations and opportunities for future service development. To compare the newly implemented Irish endometriosis framework with established national models of endometriosis care in other high-income countries.

Methods

A comparative narrative review of national endometriosis frameworks and specialist service models was performed. Publicly available national guidelines, governmental policy documents and specialist accreditation systems from Ireland, the United Kingdom, France, Australia, Germany and the Netherlands were reviewed. Key domains analysed included national policy, accredited specialist centres, multidisciplinary care provision, referral pathways and surgical governance

Results

Several countries demonstrated established national strategies for endometriosis care with varying degrees of service centralisation and accreditation. The United Kingdom utilises a British Society for Gynaecological Endoscopy (BSGE) accredited centre model for severe endometriosis surgery, while Germany and France have developed certified specialist centre networks with multidisciplinary governance structures. Australia introduced a National Action Plan for Endometriosis focused on awareness, early diagnosis and evidence-based management. Ireland's recently introduced framework shares several features with these systems, including centralisation of complex surgery and development of multidisciplinary supraregional centres. However, compared with more mature international models, Ireland currently has fewer accredited specialist centres, limited nationally standardised referral pathways and evolving surgical training structures. Despite these limitations, the Irish framework represents a substantial advancement toward coordinated national endometriosis care.

Conclusions

International models demonstrate the importance of accredited specialist centres, multidisciplinary care and national governance structures in endometriosis management. Ireland's emerging framework aligns with many international best-practice principles but remains in an early phase of implementation. Ongoing development of specialist networks, surgical accreditation and equitable national access will be critical for future progression.

ESGE35-0601 - P321
ePoster Presentations

The use of relugolix/estradiol/norethisterone acetate combination therapy for endometriosis-associated symptoms: an observational study at a UK endometriosis centre

Hui Lim[1], *John Shanks*[1]
[1]*East Lancashire Hospitals NHS Trust, Obstetrics and Gynaecology, Burnley, United Kingdom*

Background

There is a huge unmet need for long-term, non-invasive treatments to manage the symptoms of endometriosis. In April 2025, the National Institute for Health and Care Excellence (NICE) recommended the use of relugolix/estradiol/norethisterone acetate combination therapy for treatment of endometriosis-associated symptoms in patients who have had medical or surgical treatment for endometriosis. Our objective was to assess the effectiveness and tolerability of relugolix/estradiol/norethisterone acetate in our patients.

Methods

We conducted a retrospective, observational study on all patients who had been prescribed relugolix/estradiol/norethisterone acetate combination therapy for endometriosis-associated symptoms from January 2024 to June 2025 at East Lancashire Hospitals NHS Trust, an accredited endometriosis centre in the United Kingdom. Data on patient demographics, symptoms, investigations and follow-up appointments were collected from electronic records.

Results

64 patients were prescribed relugolix/estradiol/norethisterone acetate for the management of endometriosis during the time period investigated. 97% had previous medical or surgical treatment for endometriosis. Two patients did not start the treatment after reading the product leaflet, as they had a history of migraines with aura.

Follow-up data was available for 71% of those that had treatment. Of these, 50% reported an improvement in their pelvic pain. 11% were amenorrhoeic but had ongoing pain. 30% reported no improvement in their symptoms. 48% experienced side effects, with headaches and mood disturbances being the most common. 23% discontinued treatment due to intolerable side effects, including headaches, migraines, tiredness, joint pain, constant bleeding and mood disturbances.

Among those that had relugolix/estradiol/norethisterone acetate treatment for 12 months, only 23% (n=5) had undergone DEXA scans. Of these five patients, two had normal bone density, and the remaining three had osteopenia. One of the osteopenia cases was already known to have osteopenia, with similar T scores before and after treatment.

Conclusions

Relugolix/estradiol/norethisterone acetate combination therapy is effective in managing pelvic pain in endometriosis patients. It is a useful alternative to the hormonal treatments that are currently available and can help alleviate symptoms whilst patients are awaiting surgery. However, side effects

can be rather common, and patients should be appropriately counselled regarding these prior to initiation of treatment. Our unit can improve on ensuring that follow up takes place in a more timely fashion, collecting more detailed information on symptoms at the time of follow up, and ensuring that all patients who have been on treatment for 12 months are having DEXA scans.

ESGE35-0612 - P322
ePoster Presentations

#ENZIAN a feasibility study comparing Ultrasound Scan & Surgical concordance.

Alvaro Bedoya-Ronga[1], *Tereza Indrielle-Kelly*[2], *Miski Scerif*[2]
[1]*Midlands Metropolitan Hospital, Gynaecology, Sandwell, United Kingdom*
[2]*Midlands Metropolitan University Hospital, Gynaecology, Sandwell, United Kingdom*

Background

Objective
To assess the concordance between retrospective #ENZIAN ultrasound scan (u) and surgery (s) at Midlands Metropolitan Endometriosis Centre (MMEC)

Background

NICE and ESHRE guidelines recommends ultrasound scan as the first diagnostic tool for endometriosis.

New BSGE accreditation criteria for Endometriosis Centre incorporates "index Case" which are based on #ENZIANs findings.

There are many studies demonstrating the accuracy and reproducibility of #ENZIANu for preoperative assessment.

The MMEC registered as endometriosis centre with BSGE in 2022. We have a "No Diagnostic Laparoscopy" philosophy, this is to reduce morbidity, follow GIRFT principles and optimise theatre utilisation. Our patients undergo Endometriosis US (EndoUS), following IDEA and Musa criteria for pre-op stratification and surgical planning.

Methods

A retrospective review of 40 scan and surgical findings was performed. They were reclassified using #ENZIAN and concordance for "index case" were analysed.

We acknowledge our small sample makes statistical analysis inconclusive, but sufficient to detect our weakness.

Results

We found seven-months average delay between scan and surgery; this potentially affected the concordance.

Regarding surgical Index cases we found 15 of Compartment A, 7 of B, and 10 of C. The US accurately detected 2, 0 and 7 respectively, giving a Sensitivity (true positives) of 13%, 0% and 60% and a Specificity (true negative) of 100%, 90% and 96% for compartments A, B, and C respectively.

Conclusions

We have identified areas where scanning requires improvement for concordance and accuracy of #ENZIAN surgical findings. We are currently focusing on better assessing Compartment A and B.

ESGE35-0613 - P323
ePoster Presentations

Clinical Implementation of Mechanical Hysteroscopic Tissue Removal: Evaluating Efficiency and Safety in an Ambulatory Setting

Inês Monteiro Brás[1], *Beatriz Ferreira*[1], *Cristina Alves*[1], *Cátia Moreira*[1], *Patrícia Correia*[1]
[1]*Unidade Local de Saúde de Trás-os-Montes e Alto Douro, Obstetrics and Gynaecology, Vila Real, Portugal*

Background

Mechanical hysteroscopic tissue removal systems have emerged as one of the best options for managing intra-uterine pathology. Compared to traditional electrosurgical resectoscopy, they provide faster operative times and lower risk of complications, while ensuring high resection rates and adequate tissue for histological diagnosis. Integrated Bigatti Shaver (IBS ®) is one of the currently approved devices, with a smaller diameter and reusable removal system.

This study aimed to evaluate operative efficiency and intra-operative complications associated with the implementation of an Integrated Bigatti Shaver (IBS ®) in our ambulatory surgical center.

Methods

This was a retrospective cohort study including patients submitted to operative hysteroscopy with 19 Fr. Integrated Bigatti Shaver (IBS ®) since implementation in our center, from January to December of 2025. We collected data regarding patients' demographics, procedure details, including hysteroscopic approach, total procedure time and completeness of resection, intraoperative complications and histological diagnosis. Statistical analysis was done with SPSS software.

Results

A total of 68 patients were included. The mean age was 53.6 ± 12.0 years, with 32 (48.5%) of the cohort being post-menopausal. Abnormal uterine bleeding was present in 26 (39.4%) cases; an endometrial polyp was suspected via transvaginal ultrasound or diagnostic hysteroscopy in 57 (83.8%) patients.

A vaginoscopic approach was used in 43 (63.2%) cases. Complete resection was achieved in 64 (94.1%) women. The median total procedure time, including device setup and breakdown, was 18 minutes (IQR 14.0-21.0). Procedure duration did not correlate significantly with the number of lesions, the size of the largest lesion or the aggregate size of all lesions. In cases involving a single intrauterine lesion (41 (60.3%)), the mean time was 18.5 ± 8.4 minutes, with a median lesion size of 1.5 cm (IQR 1.0-2.0). Procedure times remained consistent and did not correlate with the surgeons' increasing experience.

Hemorrhagic complications occurred in 6 (8.8%) patients, including the 4 cases where complete resection was not achieved. 4 (5.9%) procedures required conversion to bipolar resectoscopy. No major complication was reported, such as uterine perforation, false passage or fluid overload.

Histological analysis confirmed the diagnosis of endometrial polyp in 51 (75.0%), with only one case of endometrial carcinoma.

Conclusions

The Integrated Bigatti Shaver (IBS ®) is a safe and efficient surgical procedure for intra-uterine pathology, with reduced operative times, regardless of the type, number and size of lesions, and with a low incidence of complications. The inclusion of setup and breakdown in our operative times emphasizes the efficiency of the procedure. The system is easily adoptable, characterized by a shallow learning curve, and provides adequate tissue samples for histological analysis. The feasibility of vaginoscopic approach enables office hysteroscopy and decreases the risk of iatrogenic injuries, such as false passage and uterine perforation.

ESGE35-0624 - P324
ePoster Presentations

Oral GnRH Antagonists in Real-World Clinical Practice: Have They Arrived to Stay?

Andrea Sánchez Iglesias[1], Diana Alejandra Guerrero Lojano[1], Zaida Lizarraga Castañeda[1], María Bosca García[1], Patricia Marrero Álvarez[2], Elena Suarez Salvador[1]
[1]Vall d'Hebron University Hospital, Obstetrics and Gynaecology, Barcelona, Spain
[2]Vall d'Hebron University Hospital, Pharmacy department, Barcelona, Spain

Background

To analyze the impact and use of GnRH antagonists in routine clinical practice at a tertiary referral hospital, including their acceptance, efficacy, and safety profile.

Methods

A retrospective study was conducted at a tertiary hospital, including all patients prescribed an oral GnRH antagonist since public reimbursement approval in Spain, either relugolix combined with estradiol/norethisterone acetate 40 mg/1 mg/0.5 mg or linzagolix 100 mg and 200 mg.

Results

Out of 238 patients, oral GnRH antagonists were prescribed for uterine fibroids in 64.7% of cases (n=154), while 35.3% (n=84) for endometriosis. Following medical consultation, 90.5% of patients initiated the prescribed treatment.

Among patients with uterine fibroids, the mean age was 45.0 years (±6.5), with heavy menstrual bleeding being the most common symptom (67.9%). Patients with endometriosis had a mean age of 41.7 years (±5.8), and the most frequent symptoms were non-cyclic pelvic pain (77.4%), followed by dysmenorrhea and dyspareunia. Coexistence of different endometriosis types, mainly ovarian and deep endometriosis, was identified in 52.4% of patients (n=44). One third (28.6%) had undergone a previous surgery for endometriosis.

Previous hormonal treatment had been used in both groups, in 63.5% of patients with uterine fibroids and 84.5% of those with endometriosis. Among these last group, almost half (42.9%) had received more than one prior hormonal treatment.

Regarding the type of oral GnRH antagonist prescribed, uterine fibroid cases showed the following distribution: 58.5% received relugolix (E+P), 30.8% linzagolix 200 mg (including 11 patients receiving add-back therapy), and 10.7% linzagolix 100 mg. In endometriosis cases, relugolix (E+P) was prescribed in 83.3% of patients, followed by linzagolix 200 mg in 15.5% (including 7 patients receiving add-back therapy), and linzagolix 100 mg in 1.2%.

Treatment was considered tolerable in 90.8% of patients with uterine fibroids and 86.4% of patients with endometriosis. Adverse effects were reported in 27.7% and 50.0% of patients, respectively, with hot flashes and headaches being the most frequent. Treatment discontinuation occurred in 70.9% of patients with uterine fibroids, predominantly because it had been prescribed as a preoperative strategy for anaemia recovery and symptom control until scheduled surgery date. Among

patients who continued treatment, heavy menstrual bleeding and haemoglobin levels showed significant improvement at 3 months ($p<0.001$).

In endometriosis cases, treatment discontinuation was observed in 44.9% of patients, mainly related to adverse effects or insufficient clinical response. Among those who continued treatment, statistically significant improvement in pelvic pain, dysmenorrhea, and dyspareunia was observed ($p<0.001$).

Conclusions

GnRH antagonists demonstrated high acceptance, good tolerability, and significant clinical effectiveness in management of both uterine fibroids and endometriosis in routine clinical practice. These findings support their role as a valuable therapeutic option; however, treatment discontinuation remained frequent, likely reflecting patient profile differences. Further studies are needed to better evaluate their long-term use in endometriosis.

ESGE35-0625 - P325
ePoster Presentations

Persistent Pelvic Pain After Hysterectomy for Uterine Fibroids

Maria Duaso Pueyo[1], Sonia Monreal Clua[1], Laura Mañalich Barrachina[1], Diana Alejandra Guerrero Lojano[1], Marta Miguez Medina[1], Elena Suarez Salvador[1]
[1]Hospital Universitari Vall d'Hebron, Gynaecology, Barcelona, Spain

Background

The aim of this study was to evaluate pain resolution after hysterectomy in patients with symptomatic uterine fibroids whose surgical indication included pain, and to identify factors associated with persistent postoperative pelvic pain.

Methods

A retrospective descriptive study including 133 patients who underwent hysterectomy for symptomatic uterine fibroids was conducted. Demographic, clinical, surgical, and pathological variables were collected. Patients whose surgical indication included pain (isolated pain or pain associated with bleeding or fibroid growth) were identified. Chronic postoperative pelvic pain was defined as pain persisting more than 3 months after surgery. Fibroid characteristics were analyzed in patients operated on for pain, while pathological findings, surgical complications, previous medical treatments, and medical comorbidities were correlated with persistent postoperative pain.

Results

The mean age was 44.9 years. Pain was part of the surgical indication in 37/133 patients (27.8%). After hysterectomy, pain resolved in 30/37 patients (81.1%), whereas 7/37 patients (18.9%) experienced chronic postoperative pelvic pain. Chronic postoperative pelvic pain was identified in 13/133 patients (9.8%) in the overall cohort.

Patients operated on for pain most frequently presented with more than four fibroids (37.8%), fibroids larger than 4 cm (56.8%), multiple fibroid locations (45.9%), and intramural fibroids (43.2%).

Incidental adenomyosis on final pathology, not previously diagnosed preoperatively, was identified in 16/37 patients (43.2%) whose surgical indication included pain. Among the 7 patients with persistent postoperative pelvic pain, 5 patients (71.4%) had adenomyosis on final pathology.

Postoperative complications occurred in 15/133 patients (11.3%). Among the 13 patients with chronic postoperative pelvic pain in the overall cohort, only one patient (7.7%) experienced a complication requiring medical treatment, suggesting no clear association between surgical complications and persistent postoperative pain.

Patients whose surgical indication included pain had more frequently received multiple previous medical treatments before surgery (32.4%). Similarly, among patients with persistent postoperative pelvic pain, multiple previous medical treatments were also the most frequent therapeutic history (38.5%).

Previous medical comorbidities associated with chronic pain or psychological disorders were identified in 21 patients (15.8%). Among patients operated on for pain with associated comorbidities, anxiety-depressive syndrome was the most frequent diagnosis (57.1%), followed by endometriosis (28.6%) and fibromyalgia (14.3%). However, among the 13 patients with persistent postoperative pelvic pain, 12 patients (92.3%) had no previous medical comorbidities and only 1 patient (7.7%) had a previous anxiety-depressive syndrome, suggesting no clear association between previous comorbidities and persistent postoperative pain.

Conclusions

Hysterectomy achieved pain improvement in most patients with symptomatic uterine fibroids. Persistent postoperative pelvic pain appeared to be more strongly associated with coexisting adenomyosis than with uterine fibroids themselves. No clear association was observed between postoperative complications or previous medical comorbidities and persistent pelvic pain. Careful preoperative assessment of associated gynecological conditions may improve patient counselling and expectations regarding postoperative pain resolution.

ESGE35-0631 - P326
ePoster Presentations

Current Compensation Trends Among Minimally Invasive Gynaecology Surgeons in North America

Aya Mohr-Sasson[1], Raanan Meyer[2], Liron Bar-El[2]
[1]McGovern Medical School at The University of Texas Health Science Center, Department of Obstetrics- Gynaecology & Reproductive Sciences, Houston, USA
[2]Cedars-Sinai Health Sciences University, Department of Obstetrics and Gynaecology, Los Angeles, USA

Background

Minimally invasive gynecologic surgery (MIGS) has significantly advanced surgical care in women's health, yet compensation structures for MIGS surgeons remain highly variable and insufficiently standardized across practice settings and healthcare systems. This variability may contribute to perceived inequities and influence career satisfaction and workforce sustainability within the specialty. The aim of this study was to evaluate current compensation trends, satisfaction, and practice variability among minimally invasive gynecologic surgeons in North America.

Methods

This cross-sectional study included MIGS surgeons who completed training and entered independent practice since January 2019. Participants completed an anonymous, web-based questionnaire assessing demographics, compensation structure, and satisfaction with remuneration. The survey was distributed electronically, with voluntary participation and implied consent. Surgeons in training and incomplete responses were excluded. The primary outcome was the average total compensation of MIGS surgeons. Secondary outcomes included compensation components, surgeon-reported satisfaction, and variability by practice setting (academic vs. private), geographic region, and gender.

Results

A total of 100 responses were collected, primarily from the United States (62%) and Canada (37%). Most respondents were female (72%) and fellowship-trained in MIGS (82%). The majority practiced in academic (56%) or community (33%) settings, with laparoscopic surgery as the dominant approach (71%). Compensation structures varied, most commonly consisting of base salary with productivity incentives (40%) or fee-for-service models (33%). Total annual compensation demonstrated wide variability, generally ranging between approximately $300,000 and $600,000. Most surgeons worked 40–60 hours per week, with a substantial proportion performing ≥20 cases per month. Satisfaction with compensation was moderate, with 63% reporting being very or somewhat satisfied; however, only 45% felt their income adequately reflected their workload and expertise. Common concerns included disparities in pay across subspecialties (64%), low base salary (37%), lack of transparency (32%), and gender or geographic disparities (33%). Notably, 44% of respondents were considering changing positions for improved compensation, and 86% believed that increased transparency could improve compensation equity.

Conclusions

MIGS compensation in North America demonstrated marked variability and was frequently perceived as misaligned with workload and expertise. These findings underscore the need for transparent, standardized compensation frameworks to improve equity, satisfaction, and long-term sustainability within the specialty.

ESGE35-0632 - P327
ePoster Presentations

A New Era in Surgical Communication: From Talking to Seeing Through Women's Perspectives

Aya Mohr-Sasson[1], Asha Bhalwal[1], Randa Jalloul[1], Alvaro Montealegre[1], Alisha Watson[1], Olivia Dziadek[1]
[1]McGovern Medical School at The University of Texas Health Science Center, Department of Obstetrics- Gynaecology & Reproductive Sciences, Houston, USA

Background

In the modern era of digital and social media, patients are increasingly exposed to visual medical information, reshaping expectations for communication and understanding. Intraoperative image sharing represents a potential shift from traditional verbal explanation to visual engagement in surgical care. This study aimed to evaluate women's perspectives on viewing intraoperative images following benign gynecologic surgery and their perceived impact on understanding, satisfaction, and the physician–patient relationship.

Methods

This cross-sectional survey study was conducted at a tertiary academic medical center including all women undergoing elective benign gynecologic surgery between July 2024 and October 2025. Intraoperative images were routinely captured during surgery. Patients who received images at discharge were compared with those who did not. On postoperative day 1, participants completed a 12-item questionnaire assessing perceptions of image viewing, understanding of pathology, satisfaction, and impact on the physician–patient relationship.

Results

A total of 220 patients completed the survey; 125 (57%) viewed intraoperative images and 97 (44%) did not. Patients who viewed images more frequently reported improved understanding of their pathology. Overall, 83% of participants indicated they would be happy or very happy to view images, and 37% reported that viewing images improved or would improve their understanding. A majority of patients (60.1%, n=131) sought additional information from external sources, primarily internet-based. Regarding timing, 12.3% (n=27) preferred immediate image review, while most favoured delayed or combined review (34.1%, n=75 both immediate and follow-up; 33.6%, n=74 follow-up only). Few patients reported negative emotional responses. Image viewing was also associated with a more positive perceived impact on the physician–patient relationship. Overall satisfaction was high, with 91% indicating they would choose surgery again.

Conclusions

Viewing intraoperative images is associated with improved patient-reported understanding and may enhance the physician–patient relationship without increasing distress. In a healthcare environment increasingly driven by visual information, incorporating structured postoperative image review represents a simple, patient-centered strategy to enhance communication, engagement, and surgical experience.

ESGE35-0642 - P329
ePoster Presentations

Management of complications following laparoscopic lateral suspension: consequences of vaginal axis alteration in the treatment of pelvic organ prolapse.

Ewa Barcz[1], Edyta Horosz[2], Wojciech Majkusiak[2], Paweł Tomasik[3], Andrzej Pomian[4], Aneta Zwierzchowska[5]
[1]Cardinal Stefan Wyszynski University in Warsaw, Gynaecology and Obsterics Dept- Medical Faculty- Collegium Medicum, Warszawa, Poland
[2]Cardinal Stefan Wyszynski University in Warsaw, Department of Gynaecology and Obstetrics- Medical Faculty- Collegium Medicum, Warszawa, Poland
[3]Cardinal Stefan Wyszynski University in Warsaw, Departement of Gynaecology and Obstetrics- Medical Faculty- Collegium Medicum, Warszawa, Poland
[4]Cardinal Stefan Wyszynski University in Warsaw, Department of Gynaecology and Obstetrics, Warszawa, Poland
[5]Cardinal Stefan Wyszynski University in Warsaw, Department of Gynaecology and Obstetrics-, Warszawa, Poland

Background

Apical prolapse, either isolated or associated with anterior compartment prolapse, is the most common clinical challenge in the surgical treatment of pelvic organ prolapse. Laparoscopic sacrocolpopexy remains the gold standard for treating apical compartment prolapse. However, due to the potential technical challenges associated with this procedure, alternative, less technically demanding surgical approaches have recently been increasingly adopted in clinical practice, including various modifications of laparoscopic lateral suspension techniques. In these procedures, fixation to the lateral pelvic structures, including the iliopectineal ligament or the lateral pelvic sidewall toward the anterior superior iliac spines, may alter the physiological vaginal axis by ventralizing the vaginal apex and opening the posterior compartment. Clinically, this may lead to complications, including iatrogenic enterocele, bladder pain syndrome (BPS), and overactive bladder (OAB) symptoms with increased frequency, nocturia, and persistent urgency.

Methods

A retrospective analysis was conducted of patients admitted to a tertiary Urogynaecological referral center for surgical complications after lateral suspension procedures performed outside the clinic, between 2021 and 2026. All patients underwent a comprehensive Urogynaecological examination, including POP-Q assessment, ultrasonographic evaluation, and quality-of-life assessment using validated questionnaires. Subsequently, surgical procedures were performed to reverse symptoms associated with lateral suspension. At 6–8 months postoperatively, a follow-up evaluation was conducted, mirroring the preoperative assessment.

Results

The analysis included 32 patients admitted for complications after lateral suspension. In 25 patients, an enterocele was identified, associated with ventral displacement of the cervix. 21 patients had recurrent apical prolapse,(point C from 0 to +4 cm). Fourteen patients reported bladder pain syndrome (4 with constant pain, 10 with pain during bladder filling). Overactive bladder syndrome(OABs) was present in 29 patients.

In all patients (n = 29) presenting with lower urinary tract symptoms (LUTS), laparoscopic removal of the implants was performed. Postoperative follow-up showed complete resolution of symptoms in 20, improvement in 5, while 4 patients continued to report OABs. In all cases of enterocele, transvaginal repair was performed with an A.M.I.® InGynious Posterior system. During follow-up of up to 8 months, no recurrence defects was observed. Quality-of-life assessment using the PFIQ and POPDI-20 questionnaires demonstrated a significant improvement in symptoms; however, it was not uniform across all domains, with LUTs persisting in some patients.

Conclusions

Lateral suspension is an alternative to sacrocolpopexy for apical prolapse. Owing to its relatively straightforward technique, it has been gaining increasing popularity. However, attention should be paid to potential complications as well as to the anatomical alterations. Above complications requires re-operation, whose extent and risk constitute a significant burden for patients. Therefore, we propose that this technique should be preceded by an appropriate preoperative patients' counselling. We are unable to report the real incidence of above complications (patients admitted outside the clinic) which is the main limitation of this study.

ESGE35-0647 - P330
ePoster Presentations

from operating room to office: anesthesia-free hysteroscopy in 14,914 cases - a 9-year real-world cohort

Hila Goldstein[1], Gadi Ben Shitrit[2], Zvi Vaknin[3], Rina Tamir Yaniv[1,4], Gabi Haran[5]
[1]Assuta medical center, Invasive Gynaecology, Tel Aviv, Israel
[2]ASSUTA, Invasive Gynaecology, Tel Aviv, Israel
[3]The Yitzhak Shamir Medical Center - Assaf Harofeh, Gynecological Oncology, Rishon Lezion, Israel
[4]Mayanaai Hayeshua Medical Center, Gyn, Bene Brak, Israel
[5]Assuta hospitals, Gynaecology &Gynecological Oncology, Tel Aviv, Israel

Background

office hysteroscopy without anesthesia is increasingly advocated, yet large real-world datasets documenting its scope and determinants are lacking. we aim to characterize the clinical and institutional determinants of anesthesia-free hysteroscopy across a 9-year multi-center cohort.

Methods

retrospective analysis of 52,896 hysteroscopic procedures performed at 5 assuta sites (2017–2026). multivariable logistic regression and mixed-effects models identified predictors of anesthesia-free practice.

Results

14,914 procedures (28.2%) were performed without any anesthesia. the rate increased from 12.2% in 2017 to a peak of 36.7% in 2022–2023, with significant inter-surgeon variability (0%–94.1%) and inter-site variability (4.3%–46.7%). diagnostic hysteroscopy (71.5%) and operative hysteroscopy (20.9%) comprised the majority. surgeon identity was a stronger predictor than patient age or indication.

Conclusions

in a large private network, nearly one-third of all hysteroscopies were performed without anesthesia. surgeon-level practice patterns, rather than patient characteristics, were the dominant driver of this choice. these data support the call for standardized outpatient hysteroscopy protocols.

ESGE35-0657 - P332
ePoster Presentations

Laparoscopic Myomectomy in a female with congenitally absent uterus.

Ammar Rafiq[1], Syeda Tahseen[1], Adewunmi Toluwase[1], Ahmed Hassan[1], Manjula Annappa[1], Gourab Misra[1]
[1]University Hospitals of North Midlands NHS Trust, Obstetrics & Gynaecology, Stoke-on-Trent, United Kingdom

Background

We are presenting a case of laparoscopic myomectomy in a 43 years old woman with known MMayer-Rokitansky-Küster-Hauser (MRKH) syndrome.

Methods

Patient initially presented with stress incontinence symptoms to urogynae clinic. MRI showed 8.5 x 7.5cm soft tissue mass attached to left pelvic wall, with rudimentary vagina. After discussion in MDT, we planned, “Cystoscopy with intra-ureteric ICG, EUA, Laparoscopic Myomectomy with Colposuspension OR Bulkamid Injections.”

Results

Intra-operatively a large, bulky soft tissue mass was seen adherent to the left pelvic side wall. Both tubes and ovaries appeared healthy. A small rudimentary uterine horn was seen attached to the right side of pelvic wall as well. We created a plane between the fibroid mass and left side wall, while securing feeding vessels, traversing medially. Gradually mobilizing this fibroid, we managed to completely separate it from the pelvic wall. It was still attached to a small stump with right sided rudimentary horn, from where it was also released. We also did bilateral salpingectomy. Fibroid was removed with power morcellation. As length of vagina was too small for colposuspension, we performed Bulkamid Injections to help with symptoms of stress incontinence.

Conclusions

This case demonstrate a rare finding of a large fibroid growing in the rudimentary uterine horn in a patient with MRKH syndrome. Surgical video shows how difficult and unusual anatomy can be navigated by adhering to simple surgical principles and understanding the tissue planes.

ESGE35-0662 - P333
ePoster Presentations

Changes in lower urinary tract symptoms after laparoscopic supracervical hysterectomy with cervicosacropexy for pelvic organ prolapse with apical compartment involvement

Aneta Zwierzchowska[1], *Andrzej Pomian*[1], *Paweł Tomasik*[1], *Ewa Barcz*[1]
[1]*Medical Faculty Collegium Medicum- University of Cardinal Stefan Wyszynski, Department of Gynaecology and Obstetrics, Warsaw, Poland*

Background

Pelvic organ prolapse (POP), particularly with apical defects, may coexist with lower urinary tract symptoms (LUTS), but the effect of reconstructive surgery on specific urinary symptoms remains clinically relevant. The objective of this study was to evaluate changes in LUTS and urinary-related quality of life after laparoscopic supracervical hysterectomy with cervicosacropexy (CSP) for advanced POP with apical compartment involvement.

Methods

This retrospective study included women undergoing laparoscopic supracervical hysterectomy with CSP for advanced POP with apical compartment involvement. Median age was 59.00 years [49.75–66.00] and median parity was 2.00 [2.00–3.00]. Anatomical correction was assessed using the Pelvic Organ Prolapse Quantification system (POP-Q). Urinary symptoms and urinary-related quality of life were assessed preoperatively and 6 months postoperatively using the Urogenital Distress Inventory short form (UDI-6) and Incontinence Impact Questionnaire short form (IIQ-7). Preoperative/postoperative data were available for 162/107 UDI-6 and 151/106 IIQ-7 assessments. Additional pelvic floor symptoms were assessed using an original symptom questionnaire based on International Urogynaecological Association/International Continence Society (IUGA/ICS) terminology, with 20–24 preoperative and 18–21 postoperative item-level assessments. Since complete paired data were unavailable, preoperative and postoperative responses were analysed as independent samples. Welch t-test, Mann-Whitney U test, chi-square or Fisher exact test were used, with Benjamini-Hochberg correction for multiple testing.

Results

POP-Q point C improved from 2.00 [1.00–4.00] to -6.00 [-7.00–-5.00], Ba from 3.00 [1.00–4.00] to -2.00 [-2.50–0.00], and Bp from -1.00 [-2.00–2.00] to -2.00 [-2.00–-1.00] (all adjusted $p<0.001$). UDI-6 total score decreased from 11.00 [6.00–16.00] to 6.00 [2.00–11.00] ($p<0.001$, adjusted $p<0.001$), and IIQ-7 total score from 7.00 [1.50–14.50] to 1.00 [0.00–7.75] ($p<0.001$, adjusted $p<0.001$). All individual IIQ-7 items improved significantly. Among UDI-6 items, significant improvements were observed in frequent urination, difficulty emptying the bladder, and pain or discomfort in the lower abdominal or genital area. Symptoms corresponding to stress urinary incontinence (SUI) and overactive bladder (OAB) did not show statistically significant improvement after correction for multiple testing. In the IUGA/ICS-based questionnaire subgroup, obstructive voiding symptoms improved significantly: difficult initiation of micturition, weak stream and need for manual assistance decreased from approximately 50% preoperatively to 0% postoperatively ($p<0.001$).

Conclusions

Laparoscopic supracervical hysterectomy with CSP for advanced POP with apical compartment involvement was associated with anatomical correction, improved urinary-related quality of life and improvement in selected lower urinary tract symptoms, particularly frequent urination, bladder emptying difficulty, pelvic discomfort and obstructive voiding symptoms. SUI and OAB symptoms did not improve significantly, suggesting the need for specific preoperative counselling and, in selected patients, additional diagnostic or therapeutic strategies.

ESGE35-0665 - P334
ePoster Presentations

Trocar insertion site hematoma mimicking disseminated intravascular coagulation after laparoscopic hysterectomy: a case of systemic consumptive coagulopathy

Merih Oğur[1], *Hakan Nazik*[1]
[1]*Medicalpark Seyhan hospital, Gynaecology and Obstetrics, Adana, Türkiye*

Background

To report a rare case in which a localized umbilical trocar insertion site hematoma triggered a systemic inflammatory response and consumptive coagulopathy mimicking disseminated intravascular coagulation (dic) after laparoscopic hysterectomy. The case also highlights how active absorption of a large, organized hematoma may lead to markedly elevated d-dimer levels and acute clinical deterioration that can be mistaken for thromboembolic events.

Methods

A 51-year-old woman underwent laparoscopic total hysterectomy and bilateral salpingectomy for treatment-resistant menometrorrhagia. A 10 mm umbilical trocar and two 5 mm lateral trocars were used, and hemostasis was achieved with a vessel sealing device. Postoperatively, haemoglobin decreased from 12.4 g/dl to 9.7 g/dl, and a 5 cm anterior abdominal wall hematoma was detected on ultrasonography and managed conservatively before discharge on postoperative day one. She was later readmitted because of persistent high fever, chills, and severe laboratory abnormalities. The diagnostic work-up included repeat laparoscopy, superficial tissue and abdominal ultrasonography, chest x-ray, thoracic and abdominal computed tomography angiography, lower extremity venous doppler ultrasonography, and multidisciplinary consultations.

Results

At readmission, haemoglobin had dropped to 7.9 g/dl, and fever recurred every 6 hours despite intravenous antibiotic therapy. Emergency diagnostic laparoscopy on postoperative day four showed a completely normal pelvic surgical field and bowel, localizing the bleeding source to the umbilical trocar site. An 8 cm organized umbilical hematoma extending to the rectus sheath was identified; 200 cc of bloody fluid was drained, while the organized component was left in situ for conservative management to avoid potential uncontrollable bleeding. Laboratory tests showed thrombocytopenia (96 k/µl), elevated c-reactive protein (154.8 mg/l), prolonged prothrombin time (16.7 s), and a d-dimer level of 2,796.01 ng/ml. Computed tomography angiography and venous doppler ultrasonography excluded pulmonary embolism and deep venous thrombosis. Intensive care management included blood product replacement (erythrocyte suspension and fresh frozen plasma), broad-spectrum antibiotics, low molecular weight heparin, and corticosteroids. After clinical stabilization and a 48-hour afebrile period, the patient was transferred to the ward. A subacute d-dimer peak of 5,928.59 ng/ml was observed without oxygen desaturation, supporting ongoing hematoma absorption rather than thromboembolism. Follow-up ultrasonography showed regression of the hematoma to 5.5 cm, and the patient was discharged with complete clinical recovery.

Conclusions

Trocar insertion site hematomas should be recognized as potential sources of significant postoperative blood loss and latent systemic inflammatory triggers rather than minor wound complications. Absorption of a large, organized hematoma can induce a consumptive coagulopathy that mimics dic and causes extreme d-dimer elevation, creating diagnostic confusion with thromboembolic disease. In patients with unexplained postoperative fever, thrombocytopenia, or coagulation abnormalities, careful evaluation of trocar insertion sites is essential even when the primary pelvic surgical field appears stable.

ESGE35-0673 - P335
ePoster Presentations

Lighting the way: Intraureteral indocyanine green as the new standard for ureteral protection in gynaecological surgery

Muhterem Melis Canturk[1], *Burak Giray*[1], *Oytun Turkkan*[1], *Dogan Vatansever*[1], *Cagatay Taskiran*[1]
[1]*Koc University Hospital,*
Department of Obstetrics and Gynaecology / Division of Gynecologic Oncology, Istanbul, Türkiye

Background

Ureteral injury affects 0.03–21% of gynecological procedures, depending on complexity, with over 50% detected only postoperatively. Prophylactic ureteral stenting; the traditional preventive strategy, has failed to demonstrate significant injury reduction across multiple meta-analyses and randomized trials, while adding costs of US$1,500–$7,500 per patient and increasing urinary tract complication rates. Indocyanine green (ICG), an FDA-approved near-infrared fluorophore, has emerged as a real-time alternative for intraoperative ureteral visualization.

Methods

A PubMed search was conducted covering January 2016 to December 2026 using combinations of "indocyanine green," "ICG," "near-infrared fluorescence," "ureteral identification," "ureterolysis," "intraureteral," "gynaecological surgery," "endometriosis," and "robotic surgery." Seventeen publications were included: case reports, prospective and retrospective cohort studies, a systematic review and meta-analysis, and narrative review chapters across gynaecologic, colorectal, urologic, and paediatric populations.

Results

The standard technique involves cystoscopy-guided instillation of 25 mg ICG in 10 mL sterile water (5 mL per ureter) via a 5–6-French catheter, providing 4–12 hours of continuous fluorescence. Bilateral fluorescence was achieved in 94–100% of cases across all included studies. In an indirect comparison, one meta-analysis (ICG: n=569; stents: n=25,784) demonstrated 6-fold lower ureteral injury rates (0.18% vs. 1.12%, p=0.022) and 5-fold lower urinary tract complication rates (2.16% vs. 11.58%, p<0.001) with ICG compared with prophylactic stenting. In the largest direct outcomes study (n=555), ICG-guided selective stenting reduced ureteral complications from 22.7% to 1.7% (p=0.001) and fistula rates from 13.6% to 0.6% (p=0.005). ICG reduced identification time by 17-fold compared with ureteral dissection (1s vs. 17s, p<0.0001), with fluorescence maintained for more than 8 hours. Junior and senior surgeons achieved equivalent outcomes under ICG guidance with zero ureteral injuries despite ureterolysis rates exceeding 80%. Key technical differences exist: catheter advancement depth varies from 1–2 cm to 15 cm, with deeper advancement associated with higher complication rates; mucosal ICG absorption occurs when no catheter is left in situ, preserving ureteral flexibility. Intravesical ICG proved unreliable in fibrotic tissue. No randomized trial has directly compared intraureteral ICG against stenting. Dosing remains unstandardized, concentrations varying more than 20-fold across series, and one case of dialysis-requiring acute kidney injury following intraureteral administration confirms that intravenous safety data cannot be extrapolated to this route.

Conclusions

Intraureteral ICG fluorescence is a feasible, reproducible, and operationally superior alternative to prophylactic stenting for ureteral identification across the full spectrum of complex gynecological surgery, with evidence of benefit across experience levels, surgical platforms, and anatomically challenging fields. Standardisation of technique, prospective safety monitoring, and RCT-level evidence remain necessary before universal adoption.

References:
Due to word count limitations, the full reference list cannot be included in this abstract. All references will be provided in the main presentation.

ESGE35-0729 - P338
ePoster Presentations

Sclerotherapy vs laser treatment vs cystectomy for endometriomas. Preliminary results of a polycentric study in Greece.

Fani Gkrozou[1], Dimitrios Lentzaris[1], Vasilieios Bais[1], Nikoleta Koutalia[1], Artemis Alexopoulou[2]
[1]University of Ioannina, Obstetrics and Gynaecology, Ioannina, Greece
[2]401 General Military Hospital, Gynaecology Clinic, Athens, Greece

Background

This study is aiming to compare the three methods of treating ovarian endometriomas (laparoscopic cystectomy, laparoscopic sclerotherapy and laparoscopic laser treatment) looking at patient's ovarian reserve and possible recurrence rate of endometriomas.

Methods

Patients randomly are selected to have laparoscopic cystectomy (group A), laparoscopic sclerotherapy (group B) and laparoscopic laser treatment (group C) in two different hospitals in Greece. Ovarian reserves are assessed by measuring AMH, before and 3 months after the operation. We also assessed patients with transvaginal ultrasound 6 and 12 months after their operation.

Results

In our study, laparoscopic sclerotherapy shows a recurrence rate of 11.2%, laparoscopic cystectomy 10.7% and laser treatment at 10.2%. All three methods seem to have a similar effect on the ovarian reserve.

Conclusions

Laparoscopic sclerotherapy and laser treatment are promising methods for the treatment of endometriomas, when they are compared with the traditional laparoscopic cystectomy. More studies are necessary to validate the results and prove or not their superiority

ESGE35-0732 - P339
ePoster Presentations

Clinical Outcomes of Fractional CO_2 Laser Therapy in Postpartum Vaginal Rehabilitation

Yaryna Veretelnyk[1], Olha Proshchenko[2], Dmytro Govsieiev[2]
[1]Bogomolets National Medical University, Department of Hospital Obstetrics and Gynaecology, Kyiv, Ukraine
[2]Bogomolets National Medical University,
Department of Hospital Obstetrics and Gynaecology and Postgraduate Education, Kyiv, Ukraine

Background

The postpartum period is commonly associated with structural and functional involution of the vaginal mucosa resulting from birth-related trauma and lactational hypoestrogenism. These changes may contribute to vaginal dryness, myofascial laxity, pelvic floor dysfunction, and deterioration in sexual quality of life. The present study aimed to evaluate the efficacy and safety of micro ablative fractional carbon dioxide (CO_2) laser therapy for postpartum vaginal rehabilitation and restoration of pelvic floor function.

Methods

This prospective controlled cohort study included 30 multiparous women evaluated 8–10 weeks after repeated vaginal deliveries. Participants were allocated into a treatment group (n = 15; mean age 34.1 ± 3.8 years), which received two sessions of fractional CO_2 laser therapy at a 4-week interval, and a control group (n = 15; mean age 33.8 ± 4.1 years), managed with standard postpartum follow-up alone. Clinical assessment was performed at baseline, 4 weeks, 8 weeks, 3 months, and 6 months. The primary outcome measure was the Vaginal Health Index Score (VHIS). Secondary outcomes included Female Sexual Function Index-6 (FSFI-6), Pelvic Floor Distress Inventory (PFDI-20), International Consultation on Incontinence Questionnaire–Urinary Incontinence Short Form (ICIQ-UI SF), and Pelvic Organ Prolapse Quantification (POP-Q) parameters.

Results

Baseline demographic, clinical, and functional characteristics were comparable between groups. At 6-month follow-up, the fractional CO_2 laser group demonstrated a significant improvement in VHIS from 11.4 ± 1.6 to 21.8 ± 1.2, compared with 14.3 ± 1.8 in the control group ($p < 0.001$). FSFI-6 scores increased from 12.4 ± 2.1 to 24.6 ± 1.9 in the treatment group, compared with 15.1 ± 2.3 in controls ($p < 0.01$). The prevalence of stress urinary incontinence symptoms decreased from 53.3% to 13.3% in the laser group, whereas symptoms persisted in 33.3% of controls at 6 months. This was accompanied by a reduction in genital hiatus measurements according to the POP-Q system. No treatment-related adverse events were reported.

Conclusions

Fractional CO_2 laser therapy appears to be a safe, minimally invasive, and effective modality for postpartum pelvic floor rehabilitation. The intervention significantly enhances vaginal mucosal recovery, improves sexual function, and reduces symptoms of stress urinary incontinence compared with standard postpartum care.

ESGE35-0750 - P341
ePoster Presentations

Fertility-Sparing Surgical Management and Long-Term Outcome of Ovarian Dysgerminoma Presenting as Acute Adnexal Torsion: A Case Report

Ana Kashia[1], *Tamar Tchitanava*[2]
[1]*OB/GYN, OB/GYN, Tbilisi, Georgia*
[2]*MediclubGeorgia, ob/gyn, Tbilisi, Georgia*

Background

Dysgerminoma is a rare malignant ovarian germ cell tumor affecting predominantly women of reproductive age. Despite its malignant potential, it is highly chemosensitive and associated with excellent prognosis when appropriately managed. Fertility-sparing surgery is considered the standard of care whenever feasible.

Methods

Case Presentation

A 34-year-old non–sexually active woman presented to the emergency department with acute severe right lower abdominal pain. Transvaginal ultrasound demonstrated a right ovarian mass measuring 111 × 63 × 90 mm with solid components and absent Doppler flow, suggestive of adnexal torsion. Tumor markers revealed mildly elevated β-hCG (8.57 mIU/mL) and normal CA-125 (12.2 U/mL).

The patient underwent emergency laparotomy, which revealed right adnexal torsion (360° × 2) involving the ovary and fallopian tube with ischemic changes. A right salpingo-oophorectomy was performed.

Histopathology with immunohistochemistry confirmed ovarian dysgerminoma (PLAP positive, TTF-1 negative, inhibin negative).

Further Management

Following diagnosis, a second-stage fertility-sparing laparoscopic staging procedure was performed. No macroscopic disease was observed. Peritoneal cytology, bilateral pelvic and para-aortic lymphadenectomy, omentectomy, multiple peritoneal biopsies, and left ovarian biopsy were performed. All specimens and cytology were negative for malignancy.

Results

Follow-up and Outcome

Postoperative tumor markers remained within normal limits (β-hCG <0.5 mIU/mL, AFP 2.42 ng/mL, CA-125 9.1 U/mL, LDH 147.7 U/L). Surveillance followed standard protocols with serial clinical, radiological, and biochemical assessment. At 7-year follow-up, the patient remains disease-free with no evidence of recurrence.

Conclusions

This case highlights that ovarian dysgerminoma may present as acute adnexal torsion requiring emergency surgery. Despite initial non–fertility-sparing management due to adnexal non-viability, comprehensive surgical staging confirmed absence of residual disease. Long-term follow-up demonstrates excellent oncologic outcome, supporting individualized and staged fertility-preserving management strategies.

ESGE35-0755 - P342
ePoster Presentations

Laparoscopic management of a dermoid ovarian cyst complicated by chemical peritonitis: Case Report

Andreas Kalampalikis[1], Omowumi Oworu[1], Kar Yan Chong[1], Mansi Tiwari[1]
[1]University Hospital Lewisham, Women's Health, London, United Kingdom

Background

Mature cystic teratomas (dermoid cysts) represent the most common benign ovarian neoplasm, accounting for 10-20% of all ovarian tumours and up to 60% of benign ovarian masses in women of reproductive age. While laparoscopic cystectomy is the gold standard for management due to its minimally invasive nature and fertility-preserving potential, inadvertent cyst rupture occurs in 15-100% of cases. Chemical peritonitis, though rare (0.2-2% incidence), represents a serious complication resulting from intense foreign-body inflammatory response to spillage of sebaceous cyst contents, particularly keratin and cholesterol crystals.

Methods

A 31-year-old woman presented with acute abdominal pain due to ovarian torsion secondary to a large 12cm left ovarian dermoid cyst. She underwent emergency laparoscopic detorsion, cyst drainage, and cystectomy. Specimen was retrieved with endocatch bag, followed by copious peritoneal lavage. Histopathology confirmed a mature cystic teratoma. Twenty-eight days later, she presented with right iliac fossa pain, nausea, and raised inflammatory markers. Imaging demonstrated residual dermoid material and features of peritonitis. Initial management with broad-spectrum antibiotics failed, and she re-presented nine days later with worsening symptoms and radiological evidence of diffuse peritoneal inflammation with ascites.

Results

Repeat laparoscopy revealed extensive adhesions, preventing access to the left ovary, and purulent abdominal fluid. Following adhesiolysis, washout, and drain insertion, prolonged intravenous antibiotics were administered. Cultures were negative. Definitive surgery was performed seven weeks later with Palmer's point laparoscopy, which was converted to midline laparotomy due to dense bowel adhesions. Left salpingo-oophorectomy, right ovarian cystectomy for a 5cm simple ovarian cyst, extensive adhesiolysis, and peritoneal washout were performed. Histopathology confirmed benign left ovarian dermoid cyst and right ovarian corpus luteal cyst. Patient made a full recovery with preserved right ovarian function.

Conclusions

Chemical peritonitis following dermoid cyst spillage results from the inflammatory cascade triggered by keratin, hair follicles, and sebaceous material. Risk factors include large cyst size (>10cm), thick cyst walls, and extensive sebaceous content. While most cases are managed successfully with thorough lavage and prophylactic antibiotics, severe chemical peritonitis may require multiple surgical interventions. Current literature suggests that meticulous surgical technique, including gentle

handling, use of endobags for specimen retrieval, and extensive peritoneal irrigation with warmed saline (minimum 3-5 litres), significantly reduces complication rates. Some authors advocate adjunctive corticosteroid therapy to modulate the inflammatory response, though evidence remains limited.

This case highlights that chemical peritonitis, while rare, can lead to significant morbidity requiring extensive surgical management. The delayed presentation with persistent inflammation necessitated conversion to open surgery and oophorectomy, emphasising the importance of thorough initial lavage and early recognition. Surgeons should counsel patients about this rare but serious complication, particularly when managing large dermoid cysts with increased spillage risk. Preventive strategies and early intervention can minimise fertility risks for this predominantly young population.

ESGE35-0772 - P343
ePoster Presentations

Real-world outcomes of office operative hysteroscopy using a miniaturized mechanical tissue removal system: a retrospective study.

Jesús Manuel Barreiro García[1], *Rosana Elena González Suárez*[1], *María del Carmen Sánchez Sánchez*[1], *Luis Miguel González Seijas*[1], *María del Carmen Parada Millán*[1]
[1]*Barbanza Hospital- SERGAS, Obstetrics and Gynaecology, Ribeira, Spain*

Background

Miniaturized office hysteroscopic operative systems have expanded the possibilities for ambulatory management of intrauterine pathology, potentially reducing the need for conventional resectoscopic surgery. This study aimed to evaluate procedural outcomes, complications and referral rates to resectoscopic hysteroscopy associated with the use of the Aveta system in routine clinical practice.

Methods

A retrospective observational study was conducted including 353 office hysteroscopies performed between January 2025 and March 2026 at our secondary care hospital. Demographic and procedural data were obtained from electronic medical records. Procedure type, complications and referral to conventional resectoscopic hysteroscopy were analysed.

Results

The Aveta hysteroscopic system was introduced at our center in January 2025. A total of 353 office hysteroscopies were performed using the system between January 2025 and March 2026.

Mean patient age was 50.8 ± 11.9 years. Forty-nine patients (13.9%) were nulliparous and 304 (86.1%) were multiparous. All procedures were performed using a vaginoscopic approach with oral administration of 400 mg ibuprofen one hour before the procedure. No anesthesia or routine cervical dilatation was required.

Hysteroscopic findings included endometrial polyps in 196 patients (55.5%), proliferative endometrium in 96 (27.2%), retained intrauterine devices in 24 (6.8%), submucosal fibroids in 20 (5.7%), uterine septum in 10 (2.8%), suspicious malignant findings in 4 (1.1%), retained products of conception in 1 (0.3%) and endometritis-compatible findings in 1 patient (0.3%).

Successful completion of the intended office procedure was achieved in 329 patients (93.2%). Therapeutic procedures successfully performed using the Aveta system included 183 polypectomies, 14 hysteroscopic myomectomies and 24 intrauterine device removals.

Overall, 24 patients (6.8%) required referral to operative resectoscopic hysteroscopy in the operating room. Reasons for referral included severe cervical stenosis preventing access (54.2%), technical complexity of the procedure (29.1%) and pain intolerance (16.7%).

Complications were limited to 10 vasovagal reactions (2.8%). No uterine perforations were reported, and no patient required hospital admission or emergency surgery.

Conclusions

The Aveta system appears to be a feasible and safe option for office hysteroscopy, allowing successful treatment of a broad spectrum of intrauterine pathology with low complication and referral rates. Most procedures were successfully completed in an outpatient setting, supporting the feasibility of minimally invasive office management. Its implementation may reduce the need for operative resectoscopic hysteroscopy, anesthesia and operating room utilization.

ESGE35-0773 - P344
ePoster Presentations

Office hysteroscopic treatment of angular pregnancy: A report of two cases and review of the literature

Ece Aksakal[1], *Irem Usta Korkut*[2], *Bulent Urman*[2]
[1]*American Hospital, Obstetrics and Gynaecology, Istanbul, Türkiye*
[2]*VKV American Hospital, Obstetrics and Gynaecology, Istanbul, Türkiye*

Background

Angular pregnancy, implantation in a lateral uterine angle medial to the uterotubal junction, is rare and frequently confused with interstitial pregnancy. Management of nonviable cases ranges from expectant follow-up to methotrexate and surgery, the latter traditionally by cornual wedge resection. Hysteroscopic treatment has been reported but usually with resectoscopic instruments in an operating-room setting, often combined with laparoscopy or preceded by methotrexate. We describe primary office hysteroscopic management of nonviable angular pregnancy in two women and review the literature.

Methods

Two nulligravid women with asymptomatic left-sided angular pregnancies were managed by office operative hysteroscopy under conscious sedation using a 5 French small-bore hysteroscope. The borders of the gestational sac were delineated with a needle bipolar cutting electrode, after which products of conception were extracted with grasping forceps; anti-adhesion gel was instilled. A structured PubMed and Embase search identified prior reports of hysteroscopic management of angular pregnancy for comparison.

Results

Case 1 was a 43-year-old who conceived after in vitro fertilisation with preimplantation genetic testing; serum beta-human chorionic gonadotropin followed an atypical triphasic course peaking at 1550 mIU/mL despite a small empty sac of approximately six to eight millimetres without yolk sac or fetal pole. Case 2 was a 26-year-old who conceived spontaneously, diagnosed sonographically. Both procedures were completed in a single office session with minimal bleeding and no complications; histopathology confirmed chorionic villi and trophoblast in both. In case 1, beta-human chorionic gonadotropin fell to 51 then 2 mIU/mL, confirming resolution. Case 2 subsequently achieved spontaneous conception and currently has an ongoing, normally sited intrauterine pregnancy, demonstrating preserved fertility. Across the literature, hysteroscopic management has typically been performed in symptomatic patients, in an inpatient or operating-room setting, with resectoscopic instruments, or after methotrexate or embolisation; office, sedation-only management of asymptomatic angular pregnancy with documented subsequent natural fertility has not previously been reported.

Conclusions

Office hysteroscopy with a small-bore hysteroscope under conscious sedation may offer precise, uterus-sparing resolution of selected nonviable angular pregnancies, avoiding methotrexate, laparoscopy and general anaesthesia, while preserving fertility. Accurate differentiation of angular from interstitial implantation is essential for safe case selection.

ESGE35-0778 - P345
ePoster Presentations

Impact of hysteroscopic polypectomy on obstetric outcomes in women with idiopathic infertility: a retrospective cohort study.

Iwona Gawron[1], Andrzej Zmaczynski[1], Robert Jach[1]
[1]Jagiellonian University Medical College, Chair of Gynaecology and Obstetrics, Krakow, Poland

Background

The objective of this study was to compare obstetric outcomes in women with idiopathic infertility who underwent office hysteroscopy (OH), during which uterine polyps were diagnosed and excised, with those of women who did not present with any focal uterine lesions.

Methods

The retrospective study included women aged 18 to 45 who underwent OH as part of the diagnostic and therapeutic evaluation for idiopathic infertility. The procedure was performed with Karl Storz 5.0 mm Bettocchi® operative sheath with 2.9 mm 30° telescope with 5Fr working channel, without general anesthesia. Sodium Chloride 0.9% solution was used as the medium. Grasping forceps, blunt scissors, or a bipolar needle electrode were used to obtain tissue specimens. The extracted tissue was subjected to standard histopathological examination. Immunohistochemical staining with Monoclonal Mouse Anti-Human CD138 antibodies was used to detect plasmocytes. Standard statistical methods and IBM SPSS Statistics were used to analyze the specified clinical variables.

Results

The study included 196 women, of whom 122 were diagnosed with uterine polyps and underwent removal during OH, while 74 had no focal lesions. Women diagnosed with polyps more frequently experienced primary infertility (78/122, 64%), while those without polyps predominantly had secondary infertility (51/74, 69%) ($p < 0.001$). Furthermore, women with polyps had more previous pregnancies than those without (1 vs. 0; $p<0.001$). No significant differences were found between women with and without polyps in terms of age (36 vs. 35 years; $p = 0.24$), frequency of abnormal uterine bleeding (70.5% vs. 79.7%; $p=0.18$), duration of attempts to conceive (24 vs. 24 months; $p=0.90$), plasma cell density per mm^2 (2 vs. 2.5; $p=0.645$), frequency of in vitro fertilization use (34.4% vs. 41.9%; $p=0.36$), rate of miscarriages before 22 weeks (7.4% vs. 8.1%; $p=1$), or rate of live births (54.9% vs. 50%; $p=0.56$).

Conclusions

The removal of uterine polyps through OH in women with idiopathic infertility did not result in improved obstetric outcomes compared to women with idiopathic infertility who did not have focal uterine lesions. These findings suggest that the presence of uterine polyps may not significantly influence obstetric outcomes in this population. Further studies are warranted to investigate additional factors affecting infertility and to assess the potential benefits of polypectomy in women with idiopathic infertility.

ESGE35-0779 - P346
ePoster Presentations

Developing a Robotic Gynaecology Service: A Model of Successful Implementation, Challenges and Early Outcomes

Andras KOSTIC[1]
[1]*Saint Mary's Hospital- Manchester University NHS Foundation Trust- Manchester- United Kingdom, Department of Gynaecology-, Manchester, United Kingdom*

Background

Objectives: To share experience regarding service transformation, governance, workforce challenges, and integration into elective recovery pathways during the introduction of a robotic gynaecology service within a large tertiary National Health Service (NHS) teaching hospital in the UK.

Methods

A prospective service evaluation was undertaken following the introduction of a robotic gynaecology programme in April 2025 within a multi-site tertiary gynaecology division. The programme was designed to support complex gynaecological surgery, including complex benign gynaecology, complex endometriosis, urogynaecology, and gynaecological oncology within the largest NHS Trust in the UK. A structured implementation strategy was developed, including governance oversight, robotic training pathways, multidisciplinary theatre team preparation, patient selection criteria, and ongoing clinical outcome monitoring. Data were collected prospectively for robotic procedures performed during the implementation period.

Results

The service necessitated daily access to the robotic platform; however, a significant operational challenge during implementation was the restructuring of consultant job plans and theatre allocation to facilitate protected robotic training access while maintaining elective service provision. A total of 2,196 robotic gynaecological procedures were performed during the study period. The average time required to complete the basic robotic training module, achieve competency, and reach surgical efficiency was 3 months, with regular fortnightly access to the robotic system. During phase 1, 7 consultants underwent robotic training, including 2 gynaecological oncologists, 2 benign gynaecologists, 2 endometriosis surgeons, and 1 urogynaecologist, enabling implementation across multiple gynaecological subspecialties. For benign hysterectomy surgery, the average gynaecologist consistently achieved the European benchmark console time after approximately 40 cases. The introduction of the robotic programme supported expansion of minimally invasive surgical capacity and, following the early success of implementation, the Division gained additional limited access to a second robotic platform at another site.

Conclusions

The introduction of a robotic gynaecology programme within a high-volume tertiary NHS centre is feasible and can be achieved safely; however, it is associated with significant organisational and operational challenges, including theatre capacity pressures, workforce limitations, competing emergency gynaecology demands, and the complexities of introducing advanced surgical technology across a large multi-site division. The programme achieved successful integration into routine clinical practice, with progressive expansion of robotic activity and surgeon engagement across all gynaecological subspecialties. Early outcomes demonstrated safe implementation with low conversion rates, acceptable perioperative complication profiles, and reduced inpatient length of stay compared with historical open or complex laparoscopically surgical pathways. Successful implementation requires strong clinical leadership, structured governance, multidisciplinary engagement, and continuous outcome monitoring.

ESGE35-0785 - P347
ePoster Presentations

From hysterectomy to reconstruction: first robotic uterovaginal anastomosis for congenital cervical malformations

Angelica Naldini[1], Cecilia Angelucci[1,2], Ursula Catena[1], Francesco Fanfani[1]
[1]Catholic University of the Sacred Heart, Department of Obstetrics and Gynaecology, Rome, Italy
[2]Gynecologic and Obstetric Clinic, Department of Medicine- Surgery and Pharmacy, Sassari, Italy

Background

Congenital cervical malformations are among the rarest and most challenging Müllerian anomalies, typically presenting with obstructed menstrual flow, severe pelvic pain, and compromised reproductive potential. For decades, these patients were often relegated to hysterectomy or unsuccessful attempts at cervical canalization, with definitive loss of fertility. More recently, uterovaginal anastomosis has emerged as a conservative alternative in highly selected cases; however, experience remains extremely limited and restricted to non-robotic approaches. In the era of advanced robotic surgery, reconstructive options may be redefined. To date, no robotic-assisted uterovaginal anastomosis has been reported. We present the first robotic experience, demonstrating the feasibility of a minimally invasive, fertility-sparing approach in this complex setting.

Methods

Two consecutive patients with congenital cervical malformations were treated at a tertiary referral center over a two-year period. Both underwent robotic uterovaginal anastomosis: one with the Da Vinci platform and one with the Toumai system. The procedure consisted of precise identification of the uterine cavity, meticulous dissection of the vaginal apex, and construction of a tension-free, well-vascularized anastomosis between the uterine corpus and the vagina under enhanced 3D visualization. Perioperative outcomes and short-term functional results were prospectively evaluated. Follow-up included clinical assessment and office hysteroscopy at 1 and 3 months.

Results

Robotic reconstruction was successfully achieved in both cases without conversion or intraoperative complications. No major postoperative complications occurred. Hospital stay was limited to 3 and 4 days. Both patients experienced immediate restoration of menstrual outflow with complete resolution of obstructive symptoms. Importantly, both resumed satisfactory sexual activity. Hysteroscopic evaluation at 1 and 3 months confirmed a patent uterine cavity and a stable, well-functioning uterovaginal anastomosis.

Conclusions

This initial experience suggests that robotic-assisted uterovaginal anastomosis is not only feasible but may represent a paradigm shift in the management of congenital cervical malformations. Procedures once considered incompatible with fertility preservation can now be approached with precision, minimal invasiveness, and functional success. In expert tertiary centres, robotic technology enables complex reconstructive surgery that challenges the historical indication for hysterectomy in these

young patients. To our knowledge, this is the first report of robotic uterovaginal anastomosis. Larger studies and longer follow-up are required to confirm durability and reproductive outcomes

ESGE35-0792 - P349
ePoster Presentations

Opportunistic salpingectomy performed during the laparoscopic supracervical hysterectomy procedure (LASH) - pathology reports of 921 cases.

Marta MONIST[1], Aleksandra Kamińska[1], Marek Gogacz[1], Michał Bogusiewicz[1]
[1]Medical University of Lublin, Second Department of Gynaecology, Lublin, Poland

Background

More than 90% of all hysterectomies worldwide are performed for benign conditions (primarily fibroids, endometriosis, and abnormal bleeding). In the United States alone, over 600,000 hysterectomies are performed annually, of which over 65% are now minimally invasive procedures. In premenopausal patients who have completed their family planning, an opportunistic salpingectomy is performed. The fallopian tube epithelium pathology is associated with developing of tubo-ovarian cancers. Serous tubal intraepithelial carcinoma (STICs) is a precursor lesion in many as 60% of all high grade serous ovarian cancers (HGSCs).

The aim of the study was to evaluate the histopathological findings and clinical significance of opportunistic salpingectomy performed during laparoscopic supracervical hysterectomy (LASH), with emphasis on the detection of occult premalignant and malignant tubal lesions.

Methods

A retrospective analysis was conducted of 921 consecutive opportunistic salpingectomy specimens obtained from women undergoing laparoscopic supracervical hysterectomy for benign indications between 2013 and 2023 at a university hospital in the Department of Surgical Gynaecology and Gynecologic Oncology. All fallopian tubes were examined histopathologically using standardized sectioning protocols. Patient demographics, surgical indications, and incidental pathologic findings were analysed.

Results

The average age of the patients was 47,07 (SD=5,05) years and the mean body mass index was 26,13 (SD=4,77). Average parity was 1,90 (SD=1,03). Among 921 salpingectomy specimens, the majority demonstrated normal histological findings (793 cases) or benign lesions (125 cases). Common benign abnormalities included chronic salpingitis, endometriosis, cystadenomas. Two precancerous lesions of the fallopian tube (Serous Tubal Intraepithelial Carcinoma - STIC) and one fallopian tube cancer (well-differentiated papillary adenocarcinoma) were identified in the study group.

Benign lesions - 125	Precancerous lesions - 2	Cancerous lesions - 1
Chronic salpingitis – 112 Endometriosis – 8 Serous Cystadenoma - 2 Adenomatoid tumor – 1 Pseudomucinous	Serous Tubal Intraepithelial Carcinoma (STIC) - 2	Well-differentiated papillary adenocarcinoma - 1

cystadenoma – 1
Hydrosalpinx - 1

Normal oviducts - 793

Table 1. Pathology report on the removed fallopian tubes.

Conclusions

Opportunistic salpingectomy during benign gynecologic surgery is a safe preventive strategy with minimal added surgical risk. Although occult precancerous and cancerous changes in the fallopian tubes are extremely rare—as evidenced by the three cases in our study (0,32%) — routine histopathological examination of both excised fallopian tubes facilitates the early detection of abnormalities in the fallopian tube epithelium and contributes significantly to ovarian cancer prevention efforts.

ESGE35-0800 - P350
ePoster Presentations

Da Vinci Xi single trocar setup for management of multicompartment DE

Matteo Tamagnini[1], Angelo Finelli[1], Jasmine Di Biasi[2], Federica Campolo[3], Sofia Bigardi[1], Manuel Maria Ianieri[4]
[1]Policlinico di Abano,
Department of Women's Health and Maternal Care- Obstetrics and Gynaecology- Policlinico di Abano, Abano Terme, Italy
[2]Policlinico Universitario Agostino Gemelli,
Department of Women's and Children's Health and Maternal Care- Obstetrics and Gynaecology- Fond azione Policlinico Universitario Agostino Gemelli IRCCS, Rome, Italy
[3]Catholic University of the Sacred Heart- Rome,
Department of Women's Health and Maternal Care- Obstetrics and Gynaecology- Policlinico di Abano, Abano Terme, Italy
[4]Saint Camillus International University of Health Sciences,
Department of Women's Health and Maternal Care- Obstetrics and Gynaecology- Policlinico di Abano, Abano Terme, Italy

Background

Deep infiltrating endometriosis (DIE) involving pelvic and upper abdominal compartments represents one of the most complex scenarios. Combined treatment of parametrial, rectosigmoid, and diaphragmatic disease usually requires different surgical skills and often necessitates trocar repositioning or additional port placement. These adjustments may increase operative complexity and reduce procedural efficiency. The da Vinci Xi system, with its enhanced multi-quadrant accessibility, may allow simultaneous pelvic and upper abdominal surgery using a single trocar configuration.

Methods

The video presents a stepwise robotic procedure performed using the da Vinci Xi platform in a patient affected by extensive pelvic and upper abdominal endometriosis. Surgical planning focused on a single trocar setup allowing pelvic and upper abdominal surgery. Key surgical steps included anatomical pelvic assessment, nerve-sparing dorsolateral parametrectomy, vascular-sparing rectosigmoid segmental resection with a side-to-end anastomosis. After the pelvic surgery, maintaining the same trocar configuration, we set up the docking for the diaphragmatic surgery. Upper abdominal dissection included right hepatic mobilization through division of the right triangular and coronary ligaments until exposure of the bare area, used as a safe anatomical landmark to avoid right hepatic vein injury. Peritonectomy and full-thickness diaphragmatic resection with direct inspection of the thoracic cavity were performed. Diaphragmatic closure was achieved using double-layer barbed sutures combined with controlled pleural aspiration and Valsalva manoeuvre to minimize postoperative pneumothorax risk.

Results

The described technique enabled complete excision of pelvic and diaphragmatic endometriosis through a single trocar setup. Nerve-sparing dorsolateral parametrectomy, vascular and nerve sparing sigmoid resection and full thickness diaphragmatic nodule resection were feasible with the same trocar setup.

Conclusions

Robotic surgery may facilitate the management of complex multicompartment endometriosis involving both pelvis and upper abdomen. Strategic trocar placement, vascular-sparing bowel preparation, and standardized hepatic and diaphragmatic landmarks may improve surgical safety and operative efficiency in advanced disease.

ESGE35-0805 - P351
ePoster Presentations

When blind endometrial sampling fails: the role of hysteroscopy in postmenopausal bleeding

Hikmet Tunc Timur[1], Elif Şeyma Çetinkaya[1], Zeynep Bayramoglu[2], Sefa Kurt[1]
[1]Dokuz Eylul University School of Medicine, Obstetrics and Gynaecology, Izmir, Türkiye
[2]Dokuz Eylul University School of Medicine, Pathology, Izmir, Türkiye

Background

Postmenopausal bleeding (PMB) requires reliable endometrial sampling to exclude endometrial carcinoma and its precursors. Endometrial aspiration biopsy (EAB) using a flexible suction curette is widely used as a first-line outpatient test, while fractional curettage (FC) and hysteroscopy with directed biopsy are used selectively. We aimed to compare the diagnostic yield, non-diagnostic sample rate and clinical pathway efficiency of these three techniques in women with PMB, particularly when initial sampling is inadequate.

Methods

We retrospectively reviewed 227 endometrial sampling procedures performed in 213 postmenopausal women with PMB (2021–2025) at a single tertiary centre. Procedures comprised EAB (n=130), FC with separate endocervical and endometrial sampling (n=74) and hysteroscopy with directed biopsy under anaesthesia (n=23). Age, parity, endometrial thickness and sampling pathology were recorded; a hierarchical reference standard was applied: hysterectomy histopathology where available, otherwise hysteroscopic biopsy. In the specific case of polyp removal at hysteroscopy, absence of polyp at subsequent hysterectomy was treated as concordant. Outcomes included the non-diagnostic sample rate (disaggregated tissue fragments, surface epithelium or insufficient material), concordance with the surgical reference standard, and diagnostic yield of repeat procedures. Categorical comparisons used the chi-square and Fisher exact tests.

Results

Mean age was 60.7 ± 9.4 years and mean endometrial thickness 8.5 ± 5.4 mm. Non-diagnostic samples were obtained in 56.2% of EAB, 45.9% of FC and 43.5% of hysteroscopy procedures. Among 124 women undergoing EAB, 39 (31.5%) required further sampling or hysterectomy. When sampling was repeated after a previous non-diagnostic procedure (n=32), a definitive diagnosis was reached in 33.3% with repeat EAB, 55.6% with FC and 80.0% with hysteroscopy. In the surgically-confirmed subgroup (48 women undergoing hysterectomy; carcinoma prevalence 35.4%, reflecting selection for persistent symptoms or suspicious findings), the index sampling procedure was concordant with premalignant or malignant disease in 6 of 11 EAB procedures, 6 of 6 FC procedures and 3 of 3 hysteroscopy procedures (EAB vs FC, Fisher p=0.10); specificity was 100% for all three methods. Two women with previously non-diagnostic blind sampling were found to have endometrial intraepithelial neoplasia at hysteroscopy and endometrial carcinoma at hysterectomy.

Conclusions

EAB retained value as a first-line outpatient test owing to its high specificity when positive, consistent with previous reports. However, its high non-diagnostic rate and the proportion of women requiring further sampling are important practical limitations. Repeating a blind procedure after a non-diagnostic sample had low yield, whereas hysteroscopy with directed biopsy provided the highest diagnostic yield as a second-line investigation and identified lesions previously missed by blind techniques. These data support hysteroscopy as the preferred next step after non-diagnostic sampling rather than a repeat blind procedure. Findings should be interpreted in light of the retrospective design and the potential for verification bias inherent in using a surgical reference standard.

ESGE35-0812 - P353
ePoster Presentations

Conservative management of atypical endometrial hyperplasia and early-stage endometrial cancer in high-surgical-risk patients unfit for definitive surgery

Mariangela Ravo[1], Emma Bonetti Palermo[2], Fabio Forzan[3], Eleonora La Fera[4], Francesco Fanfani[5], Ursula Catena[5]
[1]University of Campania "Luigi Vanvitelli",
Department of Women- Child and General and Specialized Surgery, Naples, Italy
[2]ASST Spedali Civili of Brescia, Department of Obstetrics and Gynaecology, Brescia, Italy
[3]University of Padua, Department of Women and Children's Health, Padua, Italy
[4]Fondazione Policlinico Universitario A. Gemelli- IRCCS.,
Department of Woman and Child Health and Public Health- Gynecologic Oncology Unit, Rome, Italy
[5]Fondazione Policlinico Universitario A. Gemelli- IRCCS,
Department of Woman and Child Health and Public Health- Gynecologic Oncology Unit, Rome, Italy

Background

Conservative management has emerged as a potential therapeutic option for patients with atypical endometrial hyperplasia (AEH) and early-stage endometrial cancer (EC) who are unfit for definitive surgery because of severe medical comorbidities. However, evidence regarding oncological outcomes in this fragile population remains limited.

Methods

This retrospective cohort study included 30 patients diagnosed with AEH or early-stage EC between 2021 and 2025 at the CLASS Hysteroscopy Digital Hysteroscopic Clinic of Fondazione Policlinico Gemelli IRCCS. Diagnosis was established by hysteroscopy-guided endometrial biopsy. Surgical risk was standardized using the Charlson Comorbidity Index (CCI). All patients underwent office hysteroscopic removal of pathological tissue using a tissue removal device (TRD), followed by placement of a levonorgestrel-releasing intrauterine system (LNG-IUS), with or without megestrol acetate. Follow-up included scheduled office hysteroscopies with endometrial biopsies at 3 and 6 months.

Results

The cohort included 19 patients with AEH and 11 patients with EC. Median age was 69 years (range 44–89), and median CCI score was 7 (range 0–11). All patients with EC had FIGO stage IA disease, including 5 grade 1 and 6 grade 2 carcinomas. At 3 months, among 14 evaluated patients, the complete response rate was 78.6% (11/14), while 21.4% (3/14) achieved a partial response. At 6 months, among 17 evaluated patients, the complete response rate increased to 94.1% (16/17), with one patient (5.9%) showing a partial response. Median follow-up was 24 months (mean 26.6; range 0–96). During follow-up, 6 patients (20.0%) developed a subsequent positive endometrial biopsy, suggestive of persistence or recurrence, at a median of 25.5 months from diagnosis (range 5–38); 4 cases occurred in patients initially diagnosed with EC and 2 in patients with AEH. Three patients subsequently underwent definitive surgery for non-oncological reasons, with final histopathology

confirming stable disease. One patient died of unrelated medical causes. No disease-related deaths were observed.

Conclusions

Combined hysteroscopic treatment using TRD and LNG-IUS placement, with or without megestrol acetate, appears to represent an effective and safe alternative for high-surgical-risk patients with AEH and early-stage EC. The high complete response rate and the absence of disease-related mortality support the role of individualized conservative management with strict hysteroscopic surveillance in carefully selected fragile patients.

ESGE35-0822 - P354
ePoster Presentations

Structured Preoperative Triage for Office Operative Hysteroscopy: Real-World Outcomes From a High-Volume Tertiary Referral Pathway

Alessandra Lucia Giuliano[1], Federica Campolo[2], Angelo Finelli[3], Francesca Davià[3], Fatilba Skoku[4], Manuel Maria Ianieri[1]
[1]Saint Camillus International University of Health Sciences,
Department of Women's Health and Maternal Care- Obstetrics and Gynaecology- Policlinico di Abano, Abano Terme, Italy
[2]Catholic University of the Sacred Heart- Rome,
Department of Women's Health and Maternal Care- Obstetrics and Gynaecology- Policlinico di Abano, Abano Terme, Italy
[3]Policlinico di Abano Terme,
Department of Women's Health and Maternal Care- Obstetrics and Gynaecology- Policlinico di Abano, Abano Terme, Italy
[4]Università Cattolica Nostra Signora del Buon Consiglio- Tirana,
Department of Women's Health and Maternal Care- Obstetrics and Gynaecology- Nostra Signora del Buon Consiglio, Tirana, Albania

Background

To evaluate whether structured preoperative clinical triage supports safe expansion of office operative hysteroscopy within a high-volume tertiary referral pathway.

Methods

We performed a retrospective observational cohort study including consecutive women undergoing operative hysteroscopy at the I.D.E.A. Digital Hysteroscopy and Advanced 3D Ultrasound Unit, Policlinico di Abano Terme, Italy. Patients were preoperatively allocated to office local anesthesia or planned sedation according to institutional clinical assessment of anticipated procedural complexity, based on indication and planned intervention. The primary endpoint was successful completion of planned office operative hysteroscopy without escalation to deeper anesthesia. Secondary endpoints included postoperative tolerability measured by VAS, major intraoperative complications, and anesthesia allocation by procedural indication. Group comparisons were performed using chi-square analysis, and exploratory multivariable logistic regression assessed factors associated with planned sedation.
The study was approved by the institutional ethics committee.

Results

A preliminary analysis included 617 operative hysteroscopic procedures, with a median patient age of 49 years. Among the 610 procedures with available anesthesia data, 391, 64.1%, were managed under office local anesthesia, while 219, 35.9%, were preoperatively allocated to planned sedation. All procedures planned under local anesthesia were successfully completed, with zero conversions to deeper anesthesia. Postoperative tolerability was favorable, with a median VAS score of 2. No major

intraoperative complications were recorded. Anesthesia allocation differed significantly according to procedural indication, p<0.001. Planned sedation was most frequent for uterine anomalies/metroplasty, 100%, myoma-related procedures, 84.2%, and retained products of conception, 46.2%, while endometrial and cervical polyps were predominantly managed in the office setting, with sedation rates of 26.8% and 22.8%, respectively. In exploratory multivariable logistic regression, complex operative procedures remained independently associated with planned sedation allocation, adjusted OR 8.5, 95% CI 4.9 to 14.9, p<0.001, whereas postmenopausal status was not significantly associated with sedation allocation, p=0.16

Conclusions

Structured preoperative triage was associated with safe expansion of office operative hysteroscopy in a high-volume tertiary setting. Careful case selection may optimize patient tolerability, preserve high procedural completion rates, and minimize unplanned anesthesia escalation while maintaining broad access to office-based minimally invasive treatment.

ESGE35-0825 - P356
ePoster Presentations

Prediction of Bowel Resection for Endometriosis with Evidence of Luminal Stenosis on Pre-operative Transvaginal Ultrasound Examination

Jonathan Hedges[1], Frances Bailey[1], Laila Akhtar[2], Janice Rymer[1], Kumar Kunde[1], Tom Holland[1]
[1]Guy's and St. Thomas' NHS Foundation Trust, Gynaecology, London, United Kingdom
[2]King's College London, Faculty of Life Sciences and Medicine, London, United Kingdom

Background

Bowel infiltration affects 8–12% of women with endometriosis, with 90% of cases localised to the rectosigmoid colon. Surgical treatments include rectal shave, disc and segmental bowel resections, each carrying distinct risks. Surgical management is typically reserved for patients with significant bowel symptoms, including dyschezia or obstructed defecation. Accurate preoperative assessment is essential to guide surgical planning and informed consent. Trans-vaginal ultrasound (TVUS) is a validated imaging modality for identifying deep infiltrating endometriosis (DIE), offering dynamic pelvic assessment with high sensitivity for rectosigmoid disease when performed by an experienced operator. Few studies have examined the relationship between preoperative TVUS findings and the type of bowel surgery performed, and none have evaluated luminal occlusion as a predictor of surgical complexity. This study examined preoperative TVUS features associated with bowel resection in rectosigmoid DIE.

Methods

This single-centre retrospective cohort study utilised data from the BSGE Endometriosis database and the TVUS imaging database at Guy's and St. Thomas' NHS Foundation Trust. Between 1/2/2014 and 30/11/2025, 200 patients underwent bowel surgery for DIE. Patients without preoperative specialist TVUS were excluded, yielding an analytical cohort of 75 patients (66 shave, 1 disc, 8 segmental). Fisher's exact test and Mann-Whitney U test were used for categorical and continuous variables respectively. Odds ratios, likelihood ratios and 95% confidence intervals are reported. Analyses were performed in R (version 4.3.3).

Results

Rectal involvement on TVUS, defined as a discrete nodule or rectal tethering, was identified in 9 of 9 (100%) segmental/disc patients and 58 of 66 (87.9%) shave patients, with sensitivity 100%, specificity 12.1%, PPV 13.4%, NPV 100%, and negative likelihood ratio of 0, effectively ruling out the need for segmental or disc resection when absent. Greater than 50% luminal occlusion was the strongest predictor of segmental or disc resection, present in 6 of 9 (66.7%) segmental/disc patients compared with 2 of 66 (3.0%) shave patients (OR 54.5, 95% CI 6.68–771.95; $p<0.001$), with sensitivity 66.7%, specificity 97.0%, PPV 75.0%, NPV 95.5%, and positive likelihood ratio 22.0. Multiple bowel lesions were associated with segmental or disc resection (OR 17.1, 95% CI 0.80–1101.3; $p=0.036$). Caudo-cranial nodule length reached significance (median 26.0mm vs 17.5mm; $p=0.050$).

Conclusions

Greater than 50% luminal occlusion on preoperative TVUS is a highly specific predictor of segmental or disc resection. This feature has not previously been described in the literature. This has clinical utility in preoperative surgical planning, patient counselling, and multidisciplinary team discussion. Caudo-cranial nodule length and the presence of multiple bowel lesions were also independently associated with segmental or disc resection, consistent with previously published data examining TVUS predictors of surgical complexity in rectovaginal endometriosis.

ESGE35-0826 - P357
ePoster Presentations

One-Stop Office Hysteroscopy With Hysteroscopy-Guided Endoscopic Paracervical Anesthesia: Feasibility, Safety, and Patient Tolerability in a High-Volume Tertiary Center

Federica Battaglia[1], Federica Campolo[2], Mariaquirina Melchionda[1], Sofia Bigardi[3], Kristi Cako[4], Manuel Maria Ianieri[1]
[1]Saint Camillus International University of Health Sciences,
Department of Women's Health and Maternal Care- Obstetrics and Gynaecology- Policlinico di Abano, Abano Terme, Italy
[2]Catholic University of the Sacred Heart- Roma,
Department of Women's Health and Maternal Care- Obstetrics and Gynaecology- Policlinico di Abano, Abano Terme, Italy
[3]Policlinico di Abano,
Department of Women's Health and Maternal Care- Obstetrics and Gynaecology- Policlinico di Abano, Abano Terme, Italy
[4]Univeristà Cattolica Nostra Signora del Buon Consiglio,
Department of Women's Health and Maternal Care- Obstetrics and Gynaecology- Tirana, Tirana, Albania

Background

To assess the feasibility, safety, and patient tolerability of a high-volume one-stop office hysteroscopy pathway incorporating hysteroscopy-guided endoscopic paracervical anesthesia.

Methods

We conducted a retrospective observational cohort study of consecutive women undergoing diagnostic or operative hysteroscopy at the I.D.E.A. Digital Hysteroscopy and Advanced 3D Ultrasound Unit, Policlinico di Abano Terme, Italy, between January 2025 and April 2026. Data were extracted from prospectively maintained institutional databases. The primary endpoint was feasibility, defined as successful completion of planned office operative hysteroscopy without conversion to deeper anesthesia. Secondary endpoints included postoperative pain assessed by VAS, procedural case mix, and major perioperative complications. The study was approved by the institutional ethics committee.

Results

A total of 870 hysteroscopic procedures were analysed, including 332 diagnostic and 538 operative procedures. Median patient age was 49 years. Among operative procedures, 331 of 536 patients, 61.8%, were preoperatively selected for office management under local anesthesia, while 202 of 536, 37.7%, were scheduled under sedation according to anticipated procedural complexity. All planned office operative procedures were successfully completed, with zero conversions to deeper anesthesia. Polypectomy was the most frequent intervention, 74.8%, followed by tissue removal procedures, targeted endometrial biopsy, myomectomy, metroplasty, adhesiolysis, and IUD-related interventions.

No major perioperative complications were recorded. Postoperative tolerability was favourable, with a median VAS score of 2.

Conclusions

A structured high-volume one-stop office hysteroscopy pathway appears feasible, safe, and well tolerated in a tertiary referral setting. Appropriate case selection combined with minimally invasive anesthesia strategies, including hysteroscopy-guided endoscopic paracervical anesthesia, may support broader use of office operative hysteroscopy for a wide range of intrauterine pathology.

ESGE35-0853 - P359
ePoster Presentations

Pregnancy outcomes following laparoscopic surgeries during pregnancy: a Retrospective Case-Control study.

Hadel Watad[1], Yonatan Patt[2], Aviran Ohayon[2], Yossi Bart[2], Raanan Meyer[2], Shlomo B. Cohen[2]
[1]Sheba Medical Center- Tel Aviv University Faculty of Medicine, Obstetrics and Gynaecology, Ramat Gan, Israel
[2]Sheba Medical Center- Tel Aviv University Faculty of Medicine, Obstetric and Gynaecology, Ramat Gan, Israel

Background

We aimed to compare obstetric and neonatal outcomes between pregnancies with and without laparoscopic surgery, including analysis by trimester.

Methods

This was a retrospective case control study at a single tertiary medical center. The study included all individuals who underwent laparoscopic abdominal surgery during pregnancy and delivered at our hospital between April 2011 and March 2020. We included singleton pregnancies only. Each laparoscopic case was matched in a 1:5 ratio with singleton pregnancies without surgical intervention, delivered at the same medical shift. This was a retrospective study, and informed consent was waived by the Institutional Helsinki Committee.

Results

A total of 152 pregnant individuals with singleton pregnancies underwent laparoscopic surgery during pregnancy and delivered at our institution: 48.7% in the first, 42.1% in the second, and 9.2% in the third trimester. The most common procedures were adnexal surgery (49.3%) and appendectomy (32.9%). Median gestational age (GA) at surgery was 14.2 weeks (IQR 9.5-20.3).

Overall, GA delivery was slightly lower in the laparoscopic group compared to controls (39.0 vs. 39.6 weeks, $p = 0.008$), although rates of preterm birth <37 and <34 weeks were not significantly different. Birth weight percentile and SGA rates were comparable between groups.

NICU admission (12.6% vs. 4.5%, $p < 0.001$) and composite adverse neonatal outcomes (19.7% vs. 9.1%, $p < 0.001$) were higher in the laparoscopic surgery group. However rates of low Apgar score, stillbirth, neonatal sepsis and respiratory distress were comparable.

Surgical and obstetric complications increased with advancing GA. Third trimester surgeries were associated with higher rates of postoperative ileus and overall surgical complications. Use of obstetric interventions (tocolytics, Antenatal Corticosteroids) also increased with GA ($p<0.001$). Preterm birth < 34 weeks was more frequent in second and third trimester surgeries ($P=0.047$).

On multivariate analysis, laparoscopic surgery during pregnancy was an independent predictor of NICU admission (aOR 2.703, 95% CI 1.38-5.294, $p=0.004$) and composite adverse neonatal outcomes

(aOR 2.338, 95% CI 1.36-4.018, p=0.002). caesarean delivery was also independently associated with composite adverse neonatal outcomes (3.367, CI 95% 1.840-6.161, p<0.001).

Conclusions

Laparoscopic surgery during pregnancy appears to be safe across all trimesters when clinically indicated, with no significant adverse impact on overall obstetric outcomes; however, individuals who underwent laparoscopic surgery had approximately 2.7-fold higher odds of having a newborn admitted to NICU compared with those without surgery.

ESGE35-0856 - P360
ePoster Presentations

Mullerian-type adenocarcinoma following endometriosis excision: A case presentation

Sarah Bennet[1,2], Kimberley Nyamakope[1], Alba Bajarami[1], Diana Marcus[1], Olivia Raglan[1], Jeffery Ahmed[1]
[1]Chelsea and Westminster Hospital, Obstetrics and Gynaecology, London, United Kingdom
[2]Imperial College London, Department of Metabolism- Digestion and Reproduction, London, United Kingdom

Background

While endometriosis is considered non-malignant, it does share some features with cancer including local and distant invasion of tissue, damage to effected organs and both local and systemic inflammation[1]. In addition, it has been associated with a higher risk of ovarian, thyroid and breast cancer[1]. This increased risk of ovarian cancer on the background rate of 1.3 % was previously considered to be insignificant, however a large cohort study has since reported a 4.2-fold increased risk of ovarian cancer in those with endometriosis, increasing to a 9.7-fold increase in with deep and/or ovarian disease[3].

Methods

We present a case of a 35-year-old woman who underwent pelvic clearance at our endometriosis centre. She was initially investigated for pelvic pain with an MRI identifying a 10cm atypical endometrioma. She was discussed at the gynae-oncology multidisciplinary meeting and a plan for robotic assisted pelvic clearance under the endometriosis team was made.

Results

On laparoscopy, there was minimal peritoneal endometriosis, a large right sided endometrioma and evidence of Fitz-Hugh-Curtis syndrome. The rest of the pelvis was unremarkable. A total laparoscopic hysterectomy and bilateral salpingo-oophorectomy was performed, with the right fallopian tube and ovary removed in an endoscopic bag without spillage. The patient was discharged on oestrogen only hormone replacement therapy in view of complete excision of minimal peritoneal endometriosis. Histology showed no evidence of atypical hyperplasia or malignancy, with the right ovary containing an endometriotic cyst and cystic follicles.

Six months later, the patient presented febrile, with severe pelvic pain and elevated CRP. An MRI was performed showing moderate ascites and diffuse nodular thickening throughout the posterior parietal surface. Ascitic tap was performed with the aim of tissue diagnosis and confirmed mullerian type adenocarcinoma, possibly clear cell. Initial histology is being re-examined and the patient is now undergoing chemotherapy treatment.

Conclusions

Mullerian type adenocarcinoma should be considered in the differential diagnosis of women presenting with pain following complete excision of endometriosis, in particular in the presence of pyrexia despite no localising infective symptoms.

Women with endometriosis should be treated with continuous combined hormone replacement therapy, as the risks of oestogen only regimes any outweigh any benefit.

1. Kvaskoff M et al. Endometriosis and cancer: a systematic review and meta-analysis. Hum Reprod Update. 2021 Feb 19;27(2):393-420.
2. Kvaskoff M et al. Informing women with endometriosis about ovarian cancer risk. Lancet. 2017 Dec 2;390(10111):2433-2434.
3. Barnard ME et al. Endometriosis Typology and Ovarian Cancer Risk. JAMA. 2024 Aug 13;332(6):482-489.

ESGE35-0879 - P362
ePoster Presentations

Complete Uterine Septum Mimicking Uterus Didelphys Before Embryo Transfer: A Clinical Dilemma Between Surgical Adhesion Risk and Obstetric Outcome

Caglar Yazicioglu[1], *Sule Esatagaoglu*[2]
[1]*Acıbadem International Hospital, IVF center, Istanbul, Türkiye*
[2]*Sule Esatagaoglu clinic, Obstetrics & Gynaecology, Istanbul, Türkiye*

Background

The management of a complete uterine septum before embryo transfer remains controversial, especially in patients without previous pregnancy loss. Although septate uterus is associated with adverse reproductive and obstetric outcomes, hysteroscopic septum resection may also carry a risk of intrauterine adhesions, particularly in broad-based complete septa. Therefore, the decision to proceed with pre-transfer surgical correction may be difficult and should be individualized.

Methods

Case: A 25 year-old infertile patient underwent IVF treatment. During the initial evaluation, a single cervix with two apparent cervical ostia was observed, leading to the impression of a didelphys-type uterine configuration. Since the septal area appeared broad and extensive, pre-transfer hysteroscopic resection was not performed due to concern about postoperative intrauterine adhesions. A single good-quality blastocyst was transferred into the relatively wider cavity.

The pregnancy progressed into the second trimester. First-trimester screening, detailed ultrasonography and NIPT did not reveal any foetal anomaly and showed low risk for common aneuploidies. However, the pregnancy was complicated by preterm pregnancy loss at 19 weeks. During the subsequent management of retained placental tissue, the uterine anatomy became clearer. After evacuation, the two apparent ostia within the single cervix were seen to communicate, supporting the diagnosis of a complete uterine septum rather than uterus didelphys. Hysteroscopic septum incision was then performed to unify the cavities and facilitate complete removal of the retained tissue.

Results

Due to the extent of the septum and residual fundal septal tissue, further hysteroscopic assessment and correction were performed. Final postoperative cavity evaluation demonstrated a unified uterine cavity suitable for embryo transfer. A subsequent single frozen blastocyst transfer resulted in a successful pregnancy and live birth at 34 w 5 d. The neonate weighed 2890 g, with no major neonatal complications.

Conclusions

A single cervix with two apparent ostia may be misleading and should prompt careful differentiation between complete septate uterus and uterus didelphys before embryo transfer. The management of broad complete uterine septum remains a clinical dilemma. The decision for pre-transfer hysteroscopic correction should be individualized after counselling the patient on the competing risks

of postoperative intrauterine adhesions versus adverse obstetric outcomes such as miscarriage, preterm birth, foetal loss and placental complications. This case suggests that, after an adverse reproductive outcome, hysteroscopic correction followed by cavity reassessment may allow successful live birth.

ESGE35-0883 - P363
ePoster Presentations

Laparoscopic Management of Interstitial ectopic Pregnancy Following Previous Tubal Surgery: optimizing Diagnosis and Surgical Strategy

Syeda Tahseen[1], Harpreet Kaur[2], Dolly Saxena[3], Ammar Rafiq[3], Mallikarjun Kodampur[3], Ayesha Mahmud[3]
[1]University Hospitals of North Midlands NHS Trust, Obstetrics & Gynaecology, Stoke-on-Trent, United Kingdom
[2]University of North Midlands NHS Trust, Obstetrics & Gynaecology, Stoke on Trent, United Kingdom
[3]University Hospitals of North Midlands NHS Trust, Obstetrics & Gynaecology, Stoke on Trent, United Kingdom

Background

Interstitial ectopic pregnancies account for 2% to 4% of all ectopic gestation and carry a significant risk of catastrophic hemorrhage. A primary objective of this case report is to demonstrate the successful, minimally invasive surgical management of an interstitial pregnancy in a patient with altered pelvic anatomy. This case highlights how previous tubal surgery can alter pelvic anatomy and predispose to unusual implantation sites. Recognizing subtle symptoms of peritoneal irritation, even in the context of haemodynamic stability, remains crucial for timely intervention.

Methods

This case reviews a 33-year-old female, Para 1, initially followed on the Pregnancy of Unknown Location pathway via the Early Pregnancy Unit due to sub optimally rising serial bhCG levels. She had a background of endometriosis and laparoscopic treatment of right hydrosalpinx and right tubal occlusion in India in 2019. Trans vaginal ultrasound demonstrated a sac-like structure with a double-decidual reaction measuring 8 × 8 mm located within the myometrium, with no increased vascularity—features suspicious for an interstitial pregnancy**.** MRI subsequently confirmed a right interstitial ectopic pregnancy. Although haemodynamically stable, the patient reported persistent right iliac fossa pain, vaginal spotting, and intermittent right shoulder-tip pain. Given the high failure and rupture rates associated with medical management in symptomatic interstitial ectopics, urgent laparoscopic excision was undertaken.

Results

Inoperative exploration revealed a bulky gravid uterus and an intact right interstitial ectopic pregnancy measuring 2 cm in size. Localized evidence of endometriosis was noted on the right tube; the right ovary, left adnexa, bowel, and upper abdomen were normal, with no haemoperitoneum. To secure a bloodless field, 20 ml of a vasopressin solution (20 Units in 60 ml) was injected around the cornual site. The ectopic pregnancy was excised using an advanced bipolar energy device, and diathermy was applied to the myometrial base. The myometrial defect was sutured in two layers using barbed suture. The patient recovered uneventfully and was followed up with serial bhCG levels until they returned to a non-pregnant baseline, confirming complete resolution

Conclusions

Laparoscopic excision is a highly effective treatment for interstitial ectopic pregnancies. Using vasopressin and barbed sutures allows for controlled excision and secure myometrial reconstruction. Given the depth of the cornual repair, the patient was advised to have a caesarean section in her next pregnancy to mitigate the risk of uterine rupture. This case reinforces the importance of early recognition, appropriate imaging, and tailored surgical planning in managing rare ectopic pregnancies.

ESGE35-0891 - P364
ePoster Presentations

Chronic pelvic pain three years after hysterectomy: a challenging retroperitoneal laparoscopic dissection

Tural Ismayilov[1], Burak Akagunduz[1], Begüm Sinem Kezer[2]
[1]Bingöl State Hospital, Obstetrics and Gynaecology, Bingöl, Türkiye
[2]Goztepe Prof. Dr. Suleyman Yalcin City Hospital, Obstetrics and Gynaecology, Istanbul, Türkiye

Background

To present the laparoscopic management of a chronic symptomatic multiloculated pelvic cystic collection detected three years after abdominal hysterectomy for benign disease.

Methods

A 49-year-old multiparous woman (G5P5) presented with chronic pelvic pain. She had undergone total abdominal hysterectomy with bilateral salpingectomy through a Pfannenstiel incision for uterine leiomyoma three years earlier. Her postoperative course had been uneventful, and she was discharged on postoperative day one. Pelvic magnetic resonance imaging revealed a multiloculated cystic collection over the vaginal vault without contrast enhancement. Tumor markers and acute phase reactants were within normal limits. Interventional radiology assessment concluded that percutaneous drainage was not feasible. Therefore, diagnostic and therapeutic laparoscopy was planned.

A 10-mm umbilical trocar was inserted for the laparoscope, and three additional 5-mm trocars were placed in the right hypogastric, left hypogastric, and suprapubic regions. Dense adhesions involving the bladder and rectosigmoid colon over the vaginal vault were identified intraoperatively. Sharp and blunt dissection techniques were used to restore the anatomical planes. Retroperitoneal spaces were opened to minimize the risk of ureteral, bladder, and bowel injury during dissection. The cystic collections were exposed, aspirated, and the associated peritoneal folds were excised. Bilateral oophorectomy was performed, and the specimens were removed within an endobag.

Results

The procedure was completed laparoscopically without intraoperative or postoperative complications. Macroscopic findings were not suggestive of malignancy. The patient was discharged on postoperative day one. Histopathological evaluation is ongoing.

Conclusions

Late postoperative pelvic cystic collections may rarely present years after benign gynecologic surgery and can be associated with chronic pelvic pain. In selected symptomatic patients, laparoscopic management may be feasible and effective when percutaneous drainage is not suitable. Careful retroperitoneal dissection is essential to reduce the risk of ureteral, bladder, and bowel injury in complex pelvic dissections.

ESGE35-0895 - P365
ePoster Presentations

Utero-ovarian ligament plication as an oophoropexy technique for prevention of recurrent ovarian torsion

Hazal Kutlucan[1], Gökhan Tulunay[1]
[1]TOBB Economy and Technology University Faculty of Medicine Hospital, Obstetrics and Gynaecology, Ankara, Türkiye

Background

Ovarian torsion is a gynaecological emergency and occurs completely or partially when there is a rotation of ovary on the axis of supporting ligaments which can cause obstruction of vascular structures. It is mostly seen at the right side which the reason can be the presence of sigmoid colon at the left side and provides prevention of twisting. Acute unilateral onset of abdominal pain, nausea and vomiting, tenderness in lower abdomen, enlarged ovary palpation with pelvic examination, high CRP (C-reactive protein) and sedimentation caused by ischemia and necrosis can be seen. Asymmetrical ovarian enlargement, free fluid in the peritoneum, lost of Doppler flow of ovary and twisted vascular pedicle (whirlpool sign) are the ultrasonographic signs of ovarian torsion. In case of suspicion of torsion, even there is not any ultrasonographic finding, emergent laparoscopically surgical diagnose should be considered especially in fertile ages.

Methods

The reproductive aged patient applied to emergency for sudden onset right pelvic pain. In ultrasonography, 4 cm ovarian mass with partial vascularization was observed. She had a previous ovarian torsion and laparoscopic detorsion history 6 months ago. Diagnostic laparoscopy was scheduled with suspicion of recurrent ovarian torsion. In the operation; right sided, purple colour, three times twisting ovary was initially seen. Detorsion was made and oophoropexy procedure was considered due to long, high elasticity right utero-ovarian ligament. Utero-ovarian ligament plication was conducted with continuous suturing to shorten the ligament and bring closer to the uterus. It is a technique of oophoropexy which connects the ovary to the uterus as folding and stitching the ligament to reduce excessive ovarian mobility and gain stabilization to prevent further possible twistings. Other oophoropexy techniques include fixation of the ovary to the abdominal or pelvic wall and plication of the uterosacral ligament or round ligament. Combined approaches may also be preferred.

Results

The postoperative ultrasound of the target right ovary showed precise vascularization and the intention to preserve fertility was achieved with this technique. During one year of follow-ups she did not apply again for any recurrence.

Conclusions

Clinicians should be aware of ovarian torsion in case of acute abdominal pain in reproductive age women even if imaging is not conclusive. Utero-ovarian ligament plication is a reasonable fertility-

sparing option to prevent recurrent ovarian torsions and maintain the fertility. In case of high risk of recurrence, the combined oophoropexy approaches can also be considered.

ESGE35-0910 - P366
ePoster Presentations

Mastering HyCoSy: A Visual Guide with Practical Tips and Tricks

Maria Constantinides[1], *Shital Sawant*[1]
[1]*Newham University Hospital- Barts Health NHS Trust, Obstetrics and Gynaecology, London, United Kingdom*

Background

Hysterosalpingo-contrast sonography (HyCoSy) is an important first-line investigation in fertility assessment, providing a minimally invasive method for assessing tubal patency and pelvic anatomy. Variability in technique and limited practical training opportunities may affect procedural confidence and consistency. This educational project aims to provide a practical visual guide to HyCoSy, highlighting key procedural steps, tips, and troubleshooting strategies relevant to routine secondary care practice.

Methods

A step-by-step guide was developed based on standard NHS HyCoSy protocols used within a secondary care fertility service. The poster outlines the eight core stages of the procedure:

1. Optimising governance procedures including Standard Operating procedures (SOP) and consent.
2. Equipment setup
3. Baseline transvaginal ultrasound
4. Speculum insertion and cervical cleaning
5. Catheter placement
6. Contrast administration under ultrasound guidance
7. Image interpretation and documentation
8. Post-procedure care including analgesia and antibiotics

Practical tips and troubleshooting advice are incorporated throughout to support image optimisation, procedural efficiency, and patient comfort

Results

We present a concise and practical overview of the HyCoSy procedure, emphasising key technical steps, common challenges, and troubleshooting strategies encountered in routine clinical practice. It highlights practical measures to optimise image quality, improve procedural flow, and enhance patient comfort. The resource provides a structured approach that may support greater consistency and confidence among clinicians performing HyCoSy in secondary care settings.

Conclusions

A structured and standardised approach to HyCoSy, combined with practical troubleshooting strategies and technical guidance, may improve procedural confidence, optimise image acquisition, and support consistent, high-quality fertility assessment in secondary care practice.

ESGE35-0931 - P368
ePoster Presentations

Impact of the ESGE 34th Annual Congress on a Young Surgeon's Minimally Invasive Gynecologic Practice

M. Furkan Ercişli[1]
[1]*University of Health Sciences ümraniye Training and Research Hospital, ob&gyn, Istanbul, Türkiye*

Background

International surgical congresses may influence operative decision-making, adoption of minimally invasive techniques, and professional development among early-career surgeons. Educational exposure during the early stages of independent surgical practice may substantially influence future surgical orientation and implementation of minimally invasive approaches. However, objective data demonstrating the direct impact of congress participation on real-world surgical practice remain limited. This study aimed to evaluate changes in minimally invasive gynecologic surgical practice patterns following participation in the ESGE 34th Annual Congress.

Methods

A retrospective longitudinal single-surgeon analysis was conducted using a prospectively maintained surgical logbook. The pre-congress period, corresponding to the initial phase of independent surgical practice following completion of residency training, included the 15 months preceding participation in the ESGE 34th Annual Congress. Surgical procedures performed during this period were compared with those performed during the subsequent 7-month post-congress period. Surgical approach, case distribution, minimally invasive surgery volume, and adoption of newly implemented surgical techniques were evaluated between the two periods. Monthly surgical case rates and proportional distributions of surgical approaches were analyzed to minimize the effect of unequal observation periods. Newly adopted techniques during the post-congress period, including advanced vNOTES-based approaches and anatomy-oriented minimally invasive strategies, were additionally assessed.

Results

A total of 638 surgical procedures were analysed, including 330 procedures performed during the 15-month pre-congress period and 308 procedures performed during the 7-month post-congress period. Despite the substantially shorter observation period, monthly surgical case volume approximately doubled following participation in the ESGE 34th Annual Congress (approximately 44 vs 22 procedures/month). The post-congress period demonstrated broader implementation of minimally invasive and vaginal access-based gynecologic procedures, together with increased utilization of operative hysteroscopy, Burch colposuspension, advanced laparoscopic procedures, and reconstructive pelvic surgery. In addition, several advanced and higher-complexity procedures, including endometriosis surgery, ovarian detorsion, metroplasty, uterine rupture repair, and debulking surgery, were incorporated during the post-congress period. Overall, the findings suggested increased procedural diversity, greater surgical complexity, and expanded adoption of anatomy-oriented minimally invasive surgical techniques following congress participation.

Conclusions

Participation in the ESGE 34th Annual Congress was associated with substantial changes in minimally invasive gynecologic surgical practice in an early-career surgeon. Increased surgical volume, broader procedural diversity, and adoption of advanced minimally invasive techniques were observed during the post-congress period. These findings suggest that international surgical congresses may play a significant role in shaping surgical orientation, technical development, and implementation of contemporary minimally invasive gynecologic approaches during the early stages of independent surgical practice.

ESGE35-0933 - P370
ePoster Presentations

Placenta Accreta Spectrum in Nulliparous Women – A Retrospective Single-Center Cohort Study

Adam Grzeczka[1,2], *Dariusz Wydra*[1,2]
[1]*Medical University of Gdansk, Department of Gynaecology- Obstetrics and Neonatology, Gdansk, Poland*
[2]*University Clinical Centre in Gdansk,*
Clinic of Obstetrics and Gynaecology- Gynecological Oncology and Endocrine Gynaecology, Gdansk, Poland

Background

Placenta accreta spectrum (PAS) is one of the most serious complications in obstetrics and is associated with significant risk of massive hemorrhage and hysterectomy. Although the vast majority of cases occur in women with previous caesarean sections, PAS in nulliparous women remains uncommon and relatively poorly documented. Better understanding of risk factors in this group may improve antenatal detection and clinical outcomes.

Methods

We aimed to describe the clinical presentation, risk factors, management, and outcomes of placenta accreta spectrum in five nulliparous women treated in a single tertiary referral center over a 10-year period. This retrospective study included all nulliparous patients with confirmed PAS managed at our department between 2015 and 2025. We analysed maternal age, gynecological history, placental location, prenatal imaging, mode of delivery, surgical treatment, blood loss, transfusion requirements, histopathological results, and short-term maternal outcomes.

Results

Five nulliparous women aged 33 to 45 years (mean 38.6 years) were identified. Four deliveries occurred at 36 weeks and one at 40 weeks. Placenta previa was present in the majority of cases. Although none of the patients had a prior caesarean section, three had a history of uterine intervention: two underwent hysteroscopy with polypectomy and one had a myomectomy. All five patients ultimately required hysterectomy. In four cases, caesarean section was followed immediately by hysterectomy. The fifth patient delivered vaginally but developed severe postpartum hemorrhage due to retained placenta and required emergency hysterectomy in the postpartum period. Histopathology confirmed abnormal placental adherence or myometrial invasion in every case. Blood loss was substantial in most patients; one woman required transfusion of 5 units of packed red blood cells and 2 units of fresh frozen plasma. All cases were managed by a multidisciplinary team. There were no maternal deaths.

Conclusions

Our findings show that placenta accreta spectrum can occur in nulliparous women even without a previous caesarean scar. In this small cohort, advanced maternal age, placenta previa, and prior intrauterine procedures (particularly hysteroscopy and myomectomy) were the most common associated factors. The fact that hysterectomy was necessary in all cases — including after vaginal delivery — emphasizes the potential severity of this condition in first pregnancies especially when we do not expect abnormal placental implantation. These observations highlight the importance of careful antenatal ultrasound evaluation in nulliparous women with placenta previa or suspicious history of uterine surgery. Management in a tertiary center with immediate access to a multidisciplinary team appears essential. Larger studies are required to better define the risk profile and optimal management strategy for PAS in nulliparous patients.

ESGE35-0941 - P371
ePoster Presentations

When rare meets rarer: caesarean scar pregnancy following a cervical pregnancy in a patient with a history of Strassman surgery for bicornuate uterus

Artur Ludwin[1], Lucja Zaborowska[1]
[1]Medical University of Warsaw, 1st Department of Obstetrics and Gynaecology, Warsaw, Poland

Background

Caesarean scar pregnancy (CSP) affects 1 in 9000 women with a history of caesarean section, while cervical pregnancy (CP) is estimated to occur in 1 out of 2000 gestations. Both forms of ectopic pregnancies carry a significant risk of severe, potentially life-threatening complications. Although several management algorithms have been proposed, a universally accepted treatment strategy for CP and CSP has yet to be established.

Methods

A sequential case report

Results

A 39-year-old woman, gravida 4 para 3, at 6 weeks and 5 days of gestation, was admitted to the university hospital in Warsaw, Poland, with an initial diagnosis of CP. Her history included three caesarean sections and Strassmann surgery performed for a bicornuate uterus via laparotomy. Transvaginal ultrasound revealed a viable pregnancy with cardiac activity, substantially dilating the cervical canal, with rich vascularization visible on Doppler imaging. Given the patient's wish to preserve fertility, she was qualified for systemic methotrexate and transrectal ultrasound (TRUS) guided enucleation of cervical pregnancy. The procedure was performed using Ludwin's cold-loop technique, allowing for the removal of an intact gestational sac. The postoperative course was uneventful; the patient was discharged in good condition. Complete pregnancy removal was confirmed by negative b-HCG levels and a control ultrasound examination.

One year later, the patient presented with vaginal bleeding and a positive pregnancy test. Ultrasound examination revealed a pregnancy located within the caesarean scar niche. Foetal cardiac activity was not visible; the gestational age was estimated as 5 weeks 3 days. Due to rising b-HCG level, the patient was scheduled for TRUS-guided enucleation of cervical pregnancy without prior pharmacological treatment. The perioperative course was uneventful.

Conclusions

This case highlights the importance of careful surveillance in patients with a history of multiple uterine surgeries and prior ectopic pregnancies. The TRUS-guided enucleation represents a promising, minimally invasive technique for patients with CSP and CP seeking fertility preservation.

ESGE35-0950 - P372
ePoster Presentations

Optimising Patient Experience in Ambulatory Hysteroscopy: A Two-Year Quality Improvement Review

Seuvandhi Gunasekera[1], *Nibedan Biswas*[2]
[1]*Shrewsbury and Telford NHS Trust, Gynaecology Department, Telford, United Kingdom*
[2]*Shrewsbury and Telford NHS Trust, Gynaecology, Telford, United Kingdom*

Background

Ambulatory hysteroscopy is a well-recognised and preferred approach for the diagnosis and management of intrauterine pathology due to its minimally invasive nature, reduced hospital stay, and cost-effectiveness. The success of the service and the quality of the care provided is heavily reflected by the patient's experience. Therefore, it is important to identify factors which affect the patient experience. Our aim was to evaluate the patient experience at our local ambulatory hysteroscopy unit over a two year period and determine measures to enhance patient centered care.

Methods

We designed a patient feedback questionnaire looking at various factors including, procedural outcomes, and key quality indicators such as pain scores, procedure completion rates, patient satisfaction measure. Our unit manages over a 1000 patients per year with approximately 5-6 clinics per week. The audit is ongoing as a continuous patient feedback pathway. Here we present findings over a two-year period. Regular analysis is being undertaken to ensure our service is being updated based on the results.

Results

The review demonstrated improvements across several patient experience indicators over the study period. Patient satisfaction scores are improving, while reported procedural discomfort and anxiety showed a downward trend. Patients are finding they are better prepared for the procedure as well. PEnhanced communication, better expectation-setting, and targeted pain management approaches emerged as key contributors to improved patient perceptions and procedural tolerance.

Conclusions

Patient centered care with a positive patient experience is vital in ensuring the success of an ambulatory service such as this. As evidenced by our findings, regular patient feedback gives us vital information on how to improve patient centered care and improve overall patient experience.

ESGE35-0955 - P374
ePoster Presentations

A snapshot of uptake of Laparoscopic Hysterectomy in a tertiary unit over two years.

Shruti Saralaya[1], Sayaka Okano[1]
[1]University Hospitals Plymouth, Gynaecology, Plymouth, United Kingdom

Background

In recent years there is widespread demand has prompted a move towards Laparoscopic route of hysterectomy in hospitals of all sizes , be it district general or tertiary centres. There is robust data to suggest that there are distinct benefits in performing surgery by the laparoscopic route and there is uptake of training in Laparoscopic surgery. The primary outcome was the year-over-year proportional change in laparoscopic uptake. Secondary outcomes included operative time, conversion rates, and length of hospital stay

Methods

This was a retrospective, comparative analysis of the number of cases of Total Laparoscopic Hysterectomy done in two years i.e. 2022 and 2025 to look at the trends of uptake of Total Laparoscopic Hysterectomy compared to other routes of Hysterectomy. This time period was selected as 2022 was the year after COVID pandemic when the elective operative lists were almost back to running at full capacity and the year 2025 there was increase in number of Gynaecologist's offering Laparoscopic route of Hysterectomy due to upskilling and recruitment. We looked at the electronic records of theatre dashboard to obtain the total number of hysterectomy done by all routes and indications, we then tabulated the information of the cases in columns of Laparoscopic Route of Hysterectomy, the time duration of surgery, successful day case discharge and length of hospital stay and level of surgeon performing the procedure.

Results

Our data analysis showed that while in the two-year comparative period, total hysterectomy number remained constant, the uptake of laparoscopic hysterectomies increased from 90 cases in the year 2022 to 118 cases in the year 2025. There were 2 surgeons who performed Laparoscopic Hysterectomy in the year 2022 and in the year 2025 there were 5 Gynaecologists who were performing Laparoscopic Hysterectomy. The volume of cases of the lead surgeon who mentored the other surgeons remained stable. additional 28 cases were performed by the 3 Gynaecologists who had trained up in Laparoscopic surgery. Majority of cases were for benign indication and in patients in age range between 40 to 55 years. Daycase surgery was achieved in 75% of cases and 23hr discharge in another 12%. Conversion rate was low. Pain was main reason for failed discharge.

Conclusions

Over two years a steady shift towards route of laparoscopic hysterectomy as the primary surgical route for benign gynecological conditions correlates with increasing push for day case hysterectomy by training surgeons willing to make the shift towards laparoscopic surgery with mentorship and protected operative sessions to help upskill the laparoscopic skills. The added benefit of enhanced

recovery after surgery has accelerated the acceptance of this pathway. Operative times for Laparoscopic Hysterectomy was initially proved longer, increasing surgical proficiency will improve the efficiency in the long run.

ESGE35-0966 - P375
ePoster Presentations

Understanding Patient Experience in gonadotropin-releasing hormone (GnRH) analogue Treatment: Audit the Patients Feedback

Shawn Marie Robinson[1], *Nancy Ofosu*[1], *Monica Del Peral*[2], *Rhonda Flemming*[1], *Guldzhan Vorona*[1]
[1]*Whittington Hospital Trust, Gynaecology, London, United Kingdom*
[2]*Whittington Hopsital Trust, Gynaecology, London, United Kingdom*

Background

Endometriosis and uterine fibroids are prevalent gynaecological conditions frequently managed with gonadotropin-releasing hormone (GnRH) analogue therapy to suppress ovarian steroidogenesis, alleviate symptoms, and improve health-related quality of life (Taylor et al., 2018; NICE, 2024). Evidence demonstrates that GnRH analogues are effective in reducing pelvic pain, controlling menstrual bleeding, and decreasing fibroid volume, particularly when employed as a preoperative adjunct or for longer-term symptom management (Surrey et al., 2017).

Despite these benefits, GnRH therapy is associated with hypoestrogenic adverse effects, including vasomotor symptoms, mood disturbances, sleep disruption, and musculoskeletal complaints, which may adversely impact treatment adherence and patient satisfaction (ESHRE, 2022). In this context, systematic evaluation of patient-reported outcomes and experiences is essential to assess treatment tolerability, perceived effectiveness, and the quality of multidisciplinary care delivery.

Methods

A structured telephone audit was conducted involving 90 patients undergoing GnRH analogue therapy. Data were collected using a standardised patient feedback proforma. The cohort comprised 42 patients treated for endometriosis and 38 for uterine fibroids. Following informed consent, participants were contacted and asked a series of predefined questions assessing their understanding of treatment, experienced adverse effects, perceived symptom improvement, access to medication, and overall satisfaction with clinical support.

Results

Most patients reported that the indication for GnRH analogue therapy and its potential adverse effects were clearly explained prior to treatment initiation. The multidisciplinary team, particularly specialist nursing staff, was consistently described as supportive, respectful, and responsive, with overall care rated highly.

A substantial proportion of patients reported meaningful symptom improvement, particularly in terms of pelvic pain and reduction in menstrual bleeding. Commonly reported adverse effects included vasomotor symptoms, mood disturbance, sleep disruption, headaches, and musculoskeletal discomfort; the majority of patients indicated that these had been appropriately counselled beforehand.

Access to medication was generally reported as satisfactory; however, a subset of patients experienced difficulties obtaining ongoing prescriptions through primary care services. Overall patient

satisfaction was high, with many respondents rating their experience between 8 and 10 on a 10-point scale. A number of patients required onward referral or follow-up for definitive surgical management, including progression to hysterectomy pathways.

Conclusions

This audit demonstrates high levels of patient satisfaction with GnRH analogue therapy and specialist gynaecological care. Patients reported significant symptom improvement and highlighted the importance of clear communication and supportive, patient-centred nursing input.

Key challenges identified include variability in prescription continuity within primary care and the need for enhanced support for patients awaiting definitive surgical management. These findings underscore the value of systematically incorporating patient-reported experience measures to inform service development, optimise treatment pathways, and strengthen multidisciplinary collaboration in the management of endometriosis and uterine fibroids.

ESGE35-0979 - P376
ePoster Presentations

Is Single-Port the Final Destination of Robotic Surgery? A Video Demonstration Across Surgical Complexity

Saima Farooq[1], *Amer Raza*[1]
[1]*Cromwell Hospital, Gynaecology, LONDON, United Kingdom*

Aim

Is Single-Port the Final Destination of Robotic Surgery? A Video Demonstration Across Surgical Complexity.

Background

Single-port robotic surgery represents the latest evolution in minimally invasive surgery and continues to challenge traditional perceptions regarding surgical complexity. Initially adopted for selected procedures, advances in instrumentation, imaging technology and surgeon experience have expanded its application to increasingly complex benign gynaecological and endometriosis surgery. This video aims to demonstrate the versatility of a single-port robotic platform across a wide spectrum of advanced pelvic procedures and to explore whether single-port surgery may represent the next major step in the evolution of robotic-assisted surgery.

Materials / Patients

A narrated video compilation was developed using representative clips from consecutive single-port robotic procedures performed at a tertiary referral centre specialising in advanced benign gynaecology, endometriosis and robotic surgery. The video demonstrates:• Large fertility-preserving myomectomy with multilayer uterine reconstruction• Adenomyomectomy for symptomatic adenomyosis• Large uterus hysterectomy requiring advanced dissection and specimen management• Ureterolysis for deep infiltrating ureteric endometriosis• Excision of bladder endometriosis with reconstruction• Vaginal endometriotic nodule excision• Bowel shaving for superficial rectal disease• Disc excision for full-thickness bowel endometriosis• Segmental rectosigmoid resection for advanced bowel involvement• Indocyanine green fluorescence imaging to enhance anatomical identification and tissue perfusion assessment Selected clips highlight key surgical principles including retro peritoneal dissection, organ preservation, intracorporeal suturing, reconstruction, management of large pathology and multisystem disease surgery.

Methods / Results

The video demonstrates that a single-port robotic platform can be successfully applied across abroad range of increasingly complex surgical scenarios. Key technical advantages demonstrated include:• Precise tissue handling within confined pelvic spaces• Enhanced visualisation of critical anatomical structures• Advanced intracorporeal suturing and reconstruction• Safe retroperitoneal dissection around the ureter and pelvic sidewall• Fertility-preserving surgery in selected patients• Organ-preserving approaches for bowel endometriosis• Fluorescence-guided surgery to improve intraoperative decision-making• Management of large uterine pathology while maintaining minimally

invasive principles Collectively, these examples illustrate the ability of a single-port platform to facilitate procedures involving multiple organ systems while preserving surgical precision and ergonomic efficiency

Discussion

As above

Conclusion

Single-port robotic surgery has evolved beyond a cosmetic innovation and is increasingly being utilised for some of the most technically demanding procedures in contemporary pelvic surgery. The ability to perform myomectomy, adenomyomectomy, large hysterectomy, ureteric dissection, bladder surgery, vaginal nodule excision, bowel shaving, disc excision, segmental bowel resection and fluorescence-guided surgery through a single incision demonstrates the expanding capabilities of this platform. As technology continues to advance and surgical expertise grows, single-port robotics may redefine the boundaries of minimally invasive surgery. Whether it represents the next step in robotic evolution or the final destination of robotic-assisted surgery remains an intriguing question for the future.

Impact on Patients' Health

As above

ESGE35-0981 - P377
ePoster Presentations

Urinary Tract Endometriosis: A 7- Year Cohort Study from a UK District General Hospital – Clinical Spectrum and Surgical Outcomes

Prashanthi Swami Selvaraj[1], *Maureen Rey*[2], *Elisabeth Bean*[3], *Yemi Coker*[4]
[1]*Queens Hospital. Barking - Havering and Redbridge University Hospital & NHS Trust, Obstetrics and Gynaecology ., London, United Kingdom*
[2]*Queen Hospital. Barking- Havering and Redbridge University Hospital and NHS Trust ., Endometriosis Specialist Nurse, London, United Kingdom*
[3]*Queens Hospital. Barking- Havering and Redbridge University Hospital and NHS trust ., Obstetrics & Gynaecology, London, United Kingdom*
[4]*Queens Hospital. Barking- Havering and Redbridge University Hospital and NHS Trust, Obstetrics and Gynaecology, London, United Kingdom*

Background

Urinary tract endometriosis (UTE) is a form of deep infiltrating endometriosis (DIE) that may remain asymptomatic until significant organ damage has occurred. Owing to its low prevalence, published data on UTE worldwide remain limited. This study aimed to determine the incidence, clinical presentation, surgical management, and outcomes of UTE in a tertiary endometriosis unit within a UK district general hospital.

Methods

A retrospective cohort study was conducted of all women diagnosed with UTE between January 2019 and December 2025 at a tertiary endometriosis centre within a UK district general hospital. The unit provides advanced laparoscopic and robotic-assisted surgery with multidisciplinary team involvement. Primary outcomes were the incidence and clinical spectrum of UTE. Secondary outcomes included renal impact, length of hospital stay, readmission rates, and perioperative complications.

Results

During the study period, 1,116 women attended the endometriosis clinic, of whom 23 were diagnosed with UTE, giving an incidence of 2.1%. Twelve women had isolated ureteric disease, eight had isolated bladder disease, and three had combined bladder and ureteric involvement. Sixty-five percent (15/23) were nulliparous and 48% (11/23) were from Black, Asian and Minority Ethnic (BAME) backgrounds.

Chronic pelvic pain was present in all women (23/23). Notably, 7/23 patients (30%) had no urinary symptoms despite active urinary tract disease. Among symptomatic women, urinary frequency was the most common presentation (8/23), followed by loin pain (6/23), urgency (5/23), dysuria (4/23), and haematuria (2/23). Dysmenorrhoea and dyspareunia were reported in 22/23 and 16/23 women, respectively. Subfertility affected 8/23 women (35%), while mental health comorbidities were identified in 7/23 (30%), highlighting the substantial psychosocial burden associated with endometriosis.

The posterior bladder wall was the most frequent site of bladder involvement, while the distal ureter was the predominant site of ureteric disease. Reduced split renal function was observed in 7/23 women. Preoperative ureteric stenting was required in 8/23 women while awaiting definitive surgery to prevent obstructive uropathy. Despite intervention, three women progressed to ureteric strictures with subsequent renal atrophy.

Seventeen women underwent robotic-assisted surgery and six underwent conventional laparoscopy. Procedures included ureterolysis (16/23), bladder endometriosis excision and repair (9/23), cystoscopic ablation (2/23), ureteric reimplantation with Boari flap and psoas hitch (4/23), ureteric resection and anastomosis (1/23), and nephrectomy (1/23). Additional procedures included ovarian cystectomy (10/23), hysterectomy (4/23), and bowel resection (1/23). Median postoperative length of stay was ≤7 days, with no returns to theatre.

Conclusions

UTE is rare but significant form of DIE associated with a substantial risk of irreversible renal damage. Early diagnosis, multidisciplinary input, and timely surgical intervention are essential to preserve renal function. Robotic-assisted surgery facilitates precise dissection and complex reconstruction in advanced disease. Management should extend beyond disease clearance to address subfertility, psychological wellbeing, and overall quality of life.

ESGE35-0984 - P378
ePoster Presentations

Spontaneous Twin Pregnancy After Laparoscopic Ethanol Sclerotherapy and Dienogest Treatment for Bilateral "Kissing" Endometriomas in a Young Woman with Severely Reduced Ovarian Reserve:

Elnara Mammadova[1]
[1]*Central Oil Workers' Hospital, Obstetrics and Gynaecology, Baku, Azerbaijan*

Background

To demonstrate successful spontaneous twin pregnancy following laparoscopic ethanol sclerotherapy and postoperative dienogest treatment for bilateral kissing endometriomas in a young woman with severely diminished ovarian reserve.

Methods

A 23-year-old nulligravid woman with infertility, bilateral ovarian endometriomas, and severely diminished ovarian reserve (AMH 0.57 ng/mL).

Pelvic MRI demonstrated a 52 × 44 mm right ovarian endometrioma and a 59 × 51 mm left ovarian endometrioma with an additional 44 × 38 mm cystic component. Laparoscopy revealed bilateral posteriorly adherent ("kissing") endometriomas without extensive pelvic adhesions. Both fallopian tubes were patent. To preserve ovarian tissue, cystectomy was avoided. The endometriomas were aspirated, treated with ethanol sclerotherapy, and subsequently re-aspirated. Postoperatively, dienogest 2 mg daily was administered for six months.

Spontaneous conception, pregnancy outcome, and live birth following conservative fertility-preserving management.

Results

Following completion of six months of dienogest therapy, the patient conceived spontaneously without assisted reproductive technology. Early pregnancy was confirmed by serum β-hCG measurement, and subsequent ultrasound demonstrated a spontaneous dichorionic diamniotic twin intrauterine pregnancy. The pregnancy progressed until 34 weeks of gestation, when preterm delivery resulted in the birth of two healthy live neonates.

Conclusions

This case illustrates that laparoscopic ethanol sclerotherapy combined with postoperative dienogest may represent a fertility-preserving alternative for selected young women with bilateral kissing endometriomas and severely diminished ovarian reserve. Despite a preoperative AMH level of 0.57 ng/mL, spontaneous dichorionic twin pregnancy was achieved. Further studies are required to evaluate long-term reproductive outcomes and recurrence rates following this conservative approach.

ESGE35-0985 - P379
ePoster Presentations

Clinical Characteristics of Ovarian Endometriosis and Changes in Sexual Function Following Laparoscopic Treatment

Nargiz Shamsadinskaya[1]
[1]*Azerbaijan Medical University, obstetrics- Gynaecology, Baku, Azerbaijan*

Background

Ovarian endometriosis is a chronic gynecological disorder associated with pelvic pain, infertility, hormonal and metabolic abnormalities, and impaired sexual function. The impact of laparoscopic treatment on sexual function remains an important clinical issue.
To evaluate the clinical characteristics and sexual function of patients with ovarian endometriosis before and after laparoscopic treatment.

Methods

A prospective observational study was conducted in 28 patients with ovarian endometriosis aged 24–41 years. Primary infertility was present in 11 patients and secondary infertility in 7 patients. Excess body weight (approximately 30% above normal) was observed in 12 patients. Hormonal assessment revealed hypothyroidism in 15% of patients, while insulin resistance was also identified. Serum CA-125 levels ranged from 70 to 150 U/mL. Pelvic pain was assessed using the Visual Analogue Scale (VAS), and sexual function was evaluated using the Female Sexual Function Index (FSFI). All patients underwent laparoscopic surgical treatment.

Results

Prior to surgery, patients reported severe pelvic pain with VAS scores of 7–8. Reduced libido, dyspareunia, and impaired sexual satisfaction were common findings. Elevated CA-125 levels and ultrasonographic evidence of endometriotic ovarian cysts were observed. Following laparoscopic treatment, pelvic pain decreased, dyspareunia improved, and a positive trend in sexual function was noted. Overall quality of life and sexual well-being improved after surgery.

Conclusions

Ovarian endometriosis is associated with significant pain, sexual dysfunction, infertility, and metabolic disturbances. Laparoscopic treatment contributes to pain reduction and improvement in sexual function, supporting its role as an effective therapeutic approach in women with ovarian endometriosis.

ESGE35-0986 - P380
ePoster Presentations

Mayer-Rokitansky-Kuster-Hauser Syndrome

Natiq Maharramov[1]
[1]*Leyla Medical Center, Gynaecology&Obstetrics, Baku, Azerbaijan*

Background

Mayer-Rokitansky-Kuster-Hauser (MRKH) syndrome consists of vaginal aplasia with other mullerian (ie, paramesonephric) duct abnormalities. People with MRKH syndrome have a female chromosome pattern (46,XX) and normally functioning ovaries. They also have normal breast and pubic hair development. One of the early signs of MRKH syndrome is primary amenorrhea. MRKH syndrome has two types. Type 1 affects only the reproductive organs. People with MRKH syndrome type 2 also have abnormalities in other parts of the body.

Methods

A 24-year-old Azerbaijani married female patient presented with primary amenorrhea and coital difficulties in 2021. She has normal female phenotype, normal 46, XX karyotype. She was married for three months. At 16 years old, she underwent ultrasonography and learned she had no uterus and vagina. She had an appendectomy surgery in 2018. She had normal secondary sexual characteristics. General physical examination findings were normal. Hormonal level of luteinizing hormone, follicle stimulating hormone, prolactin, progesterone, and testosterone levels were all normal. Magnetic resonance imaging of pelvis revealed agenesis of uterus, cervix and proximal two third of vagina. We had done diagnostic laparoscopic surgery and confirmed MRKH syndrome in 2021. We selected amnion as graft for vaginoplasty over other grafts because it is easily available and its supply is nearly unlimited. Amniotic membranes do not express HLA-A, B and consequently immunological rejection does not occur. Also amnion graft may have antimicrobial properties and epithelialisation effects

Results

We checked the pregnant women to have any infection who we retrieved amnion graft. The amnion was kept in normal saline after properly cleaning of the blood, clots. We prepared 10.5 cm mould wrapped with amnion graft and then we put gently into the newly created vagina. A soft mould was used to dilate the vagina intermittently by the patient herself under our observation. We cut the sutures between labia minora after 6 days of operation. After a week patient is allowed to leave the hospital. We examined with speculums after 3 weeks of operation. We reassessed her vaginal integrity after one month of the surgery. She had normal sexual intercourse after 1 months of the surgery. She has used Premarin (conjugated estrogens) vaginal cream as a lubricant for 6 months. From 2021 until 2024 she has been coming for checking with her husband three times a year. They have normal sexual intercourse after the surgery. She has not experienced any complications after surgery until 2024.

Conclusions

In patients with MRKH syndrome, the use of an amnion graft during neovagina surgical creation can prevent complications, and shortens the rehabilitation period.

ESGE35-0989 - P381
ePoster Presentations

The Impact of Adenomyosis on Female Reproductive Potential

Zeynab Huseynova[1]
[1]*Binagadi Medical Center named after A.D.Malikov, Gynaecology and Obstetrics, Baku, Azerbaijan*

Background

Adenomyosis is one of the benign uterine pathologies that may negatively affect female reproductive potential. It is associated with structural and functional changes in the uterus, impaired endometrial receptivity, altered uterine contractility and an increased risk of infertility and pregnancy loss.
To evaluate the impact of adenomyosis on fertility and reproductive outcomes in women with reproductive dysfunction.

Methods

Clinical and reproductive data of women diagnosed with adenomyosis were analysed. The study assessed infertility type, menstrual disorders, pregnancy losses, and related clinical characteristics. A prospective observational study was conducted among reproductive-age women diagnosed with adenomyosis and fertility complaints. The study group included 35 patients aged 18-45 years with adenomyosis and reproductive dysfunction.

A comprehensive examination included clinical and anamnestic assessment, as well as special instrumental investigations. All women included in the study underwent transvaginal ultrasound examination, and Doppler ultrasound was performed during the first phase of the menstrual cycle to evaluate uterine artery hemodynamics parameters. Each patient's medical history was obtained through an interview using a structured questionnaire.

Quantitative and qualitative data were statistically processed using the analysis of variance (Student-Bonferroni t-test and Mann-Whitney U-test) and discriminant analysis (Pearson Chi-Square test) in the SPSS-26 statistical package. The null hypothesis was rejected at a P-value of <0.05.

Results

In patients with adenomyosis and high body mass index, the frequency of reproductive function disorders increased with age. The clinical presentation was variable and included dysmenorrhea (73,7%), abnormal uterine bleeding (57,9%), chronic pelvic pain (31,3%) and infertility (primary - 21,1%; secondary- 36,8%); however, some patients remained asymptomatic.

The findings indicate that adenomyosis is associated with reduced implantation potential and unfavourable pregnancy outcomes. Estradiol and prolactin levels, as well as coagulation activity, were higher in patients with adenomyosis than in other groups. Changes in uterine artery hemodynamic parameters were observed depending on the location of the pathological focus in the endometrium. In adenomyosis group, S/D ratio, RI, and PI were higher than in healthy women and women with other benign uterine pathologies. Secondary infertility was more frequent in patients with adenomyosis.

Current management of adenomyosis in patients with reproductive dysfunction should be individualized. Treatment decisions depend on the women's age, symptoms, ovarian reserve, reproductive plans, type and extent of adenomyosis, and presence of other gynecological diseases. Current approaches include medical therapy, assisted reproductive technologies, and, in selected cases, fertility – preserving surgery.

Conclusions

Adenomyosis has a significant negative impact on female reproductive potential. Early diagnosis, individualized treatment, and careful reproductive management are important for improving fertility outcomes in women with adenomyosis.

ESGE35-0991 - P382
ePoster Presentations

Uterine AVM After Miscarriage

Tanzila Aliyeva[1], *Jamila Gurbanova*[1], *Flora Huseynova*[1]
[1]*Research Institute of Obstetrics and Gynaecology, Obstetrics and Gynaecology, Baku, Azerbaijan*

Background

Uterine arteriovenous malformation (AVM) is a rare but potentially life-threatening vascular abnormality characterized by a direct connection between uterine arteries and veins without an intervening capillary network. Acquired AVMs are commonly associated with uterine trauma, including curettage, caesarean section, and other surgical procedures. Clinical presentation usually involves recurrent or sudden heavy vaginal bleeding that may result in severe anaemia and hemodynamic instability. Doppler ultrasonography is the primary diagnostic tool, while MRI or contrast-enhanced CT may be used for confirmation. Management depends on the severity of bleeding, hemodynamic status, and fertility preservation goals.

Methods

A 30-year-old woman, gravida 5 para 3+1, with a history of three previous caesarean sections, presented with a missed miscarriage at 21 weeks of gestation with foetal demise of approximately two weeks' duration. Uterine evacuation and curettage were performed for retained placental tissue, and the patient was discharged in stable condition. On postoperative day 10, she was readmitted with heavy vaginal bleeding. Physical examination revealed pallor, while pelvic examination demonstrated a bulky uterus, normal adnexa, and a closed cervical os without active bleeding. Ultrasonography showed a 69 × 67 mm complex vascular lesion in the lower anterior uterine wall containing multiple blood-filled spaces and dilated vascular channels with active flow. A provisional diagnosis of uterine AVM was made and subsequently confirmed by MRI. Haemoglobin level was 6 g/dL. During evaluation, the patient developed sudden massive vaginal bleeding. Two units of packed red blood cells were transfused. Due to significant blood loss and hemodynamic deterioration, emergency surgery was performed.

Results

Laparotomy was carried out through a Joel-Cohen incision. Dense adhesions involving the uterus, anterior abdominal wall, and urinary bladder were carefully dissected released using both sharp and blunt dissection. The ascending branches of both uterine arteries and veins were identified and ligated bilaterally. A 6 × 6 cm dark violet vascular lesion was found within the previous uterine scar and excised with healthy margins. The uterine defect was repaired using a double-layer suturing technique (metroplasty)

Conclusions

Postoperatively, bleeding ceased and the patient was discharged in stable condition. The patient was advised to undergo follow-up hysteroscopy in 6 months. She subsequently resumed normal menstrual cycles and was followed for 3 months, during which she conceived spontaneously. Uterine

AVM should be considered in women presenting with severe bleeding following uterine evacuation. Early diagnosis and timely intervention are essential. In selected patients, fertility-preserving surgery may be a life-saving alternative to hysterectomy while maintaining reproductive potential.

ESGE35-1005 - P387
ePoster Presentations

Laparoscopic vaginoplasty for vaginal agenesis in Mayer-Rokitansky-Küster-Hauser Syndrome type 1: restoring anatomical and functional outcome

Elena Iuliana Anamaria Berbecaru[1,2], Dominic Gabriel Iliescu[1,2], Anca Maria Istrate Ofiteru[2,3], Roxana Dragusin[1,2], George Lucian Zorila[1,2]
[1]University of Medicine and Pharmacy of Craiova, Obstetrics and Gynaecology, Craiova, Romania
[2]Clinical County Hospital of Craiova, Obstetrics and Gynaecology, Craiova, Romania
[3]University of Medicine and Pharmacy of Craiova, Histology, Craiova, Romania

Background

Mayer-Rokitansky-Küster-Hauser (MRKH) Syndrome is a congenital disorder characterized by Müllerian aplasia, resulting in absence of the uterus and the upper two-thirds of the vagina in phenotypically normal, 46,XX females with normal ovarian function. Management of vaginal agenesis aims to create a functional neovagina that allows painless, satisfactory sexual intercourse, with success depending on both surgical precision and postoperative compliance. We report the anatomical and functional outcome of laparoscopic Davydov vaginoplasty in a young woman with MRKH type 1.

Methods

A 23-year-old nulliparous woman, diagnosed with MRKH Syndrome type 1 in adolescence, presented with a 2.5 cm blind-ending vaginal pouch and bilateral rudimentary, non-communicating uterine horns, confirmed on pelvic MRI. Ovarian function and external genitalia were normal. She reported an inability to achieve penetrative intercourse due to severe dyspareunia on attempted contact. A laparoscopic Davydov vaginoplasty was performed under general anesthesia: the vesico-rectal space was dissected to the pelvic peritoneum, the peritoneal flaps were mobilized and advanced to line the newly created vaginal canal, and the neovaginal vault was closed laparoscopically by purse-string suturing of the peritoneal edges. Operative time was approximately 120 minutes, with minimal blood loss and no intraoperative complications. Postoperative rehabilitation included daily vaginal dilation, beginning right after surgery, using a graduated set of dilators with topical estrogenic cream, with progressive increase in dilator size over a 12-week period.

Results

The procedure and early postoperative course were uneventful, with no bladder, bowel, or vascular injury. At the 3-month follow-up, examination confirmed a fully epithelialized, compliant neovagina measuring approximately 9 cm in length with adequate calibre and distensibility. The patient reported resumption of regular, pain-free penetrative intercourse without need for further dilation, and a marked subjective improvement in sexual function and quality of life.

Conclusions

Laparoscopic Davydov vaginoplasty offers excellent anatomical reconstruction in patients with MRKH Syndrome and vaginal agenesis, with a low complication profile. Long-term functional success depends on the synergy between meticulous laparoscopic peritoneal mobilization and a disciplined, progressive postoperative dilation protocol supported by topical estrogenic therapy.

ESGE35-0323 - P388
ePoster Presentations

Application of spaghetti knotting technology in Laparoendoscopic single-site (LESS) suturing instruction

Qiong Zhang[1], *Yu Zhao*[1]
[1]*The Second Affiliated Hospital and Yuying Children's Hospital of Wenzhou Medical University, Department of Obstetrics and Gynaecology, Wenzhou, China*

Background

Spaghetti knotting technology is an emerging technique that alleviates visual field restriction for operators in laparoendoscopic single-site (LESS) surgery. This study therefore compared it with conventional knotting technology to assess teaching efficacy and operational workload in LESS suturing instruction.

Methods

Forty junior residents were recruited to learn knot tying skills using LESS simulators. They were randomly and equally divided into a control group (trained with conventional knotting) and an experimental group (trained with spaghetti knotting technology). Assessments were conducted before and after training, including suturing time, thread length, needle insertion accuracy, knotting stability, tissue integrity, tissue tightness, cognitive workload (mental, physical, and temporal demands, performance, effort, and frustration), the number of instrument collisions, learning curve slope (based on the first 10 repetitions), subjective satisfaction with the training method, and number of intra-procedure errors.

Results

No significant differences in baseline knotting skills or workload were observed between the two groups prior to training. Following training, both groups demonstrated significant improvements in knotting skills and workload. Compared with the control group, the experimental group achieved significantly better outcomes in knotting time ($p = 0.001$), thread length ($p = 0.01$), and tissue integrity ($p = 0.003$), characterized by shorter suturing duration, longer residual thread, and higher tissue integrity. In addition, the spaghetti knotting technique was associated with a significantly lower workload. Further analysis revealed that the experimental group exhibited fewer instrument collisions ($p = 0.028$) and a steeper learning curve slope during the first 10 repetitions ($p = 0.012$), indicating faster skill acquisition, as well as significantly higher subjective satisfaction with the training method ($p = 0.009$). Conversely, no significant differences were found between the two groups in needle insertion accuracy ($p = 0.560$), knotting stability ($p = 0.059$), tissue tightness ($p = 0.731$), or number of intra-procedure errors ($p = 0.210$), suggesting that both techniques are equally safe for basic skill training.

Conclusions

In LESS suturing instruction, training with spaghetti knotting techniques significantly improves students' learning efficacy and reduces their workload compared with conventional knotting

techniques. Furthermore, spaghetti knotting may represent a practical approach for laparoscopic skills teaching and holds feasible clinical application value in LESS surgery.

ESGE35-0549 - P389
ePoster Presentations

Racial and Ethnic Representation in Surgical Endometriosis Randomized Controlled Trials: A Systematic Review

Olga Bougie[1], *Grace Zhou*[2], *Christopher Vizena*[2], *Fariya Zaheer*[3]
[1]*Mount Sinai Health Systems, Obstetrics and Gynaecology, Toronto, Canada*
[2]*University of Toronto, Obstetrics and Gynaecology, Toronto, Canada*
[3]*Queen's University, Medicine, Kingston, Canada*

Background

Emerging evidence suggests that the prevalence and clinical presentation of endometriosis may differ across racial and ethnic groups. Despite growing recognition of these disparities, the extent to which participants with diverse demographic backgrounds are represented in endometriosis randomized controlled trials (RCTs) remains unclear. This study systematically reviewed the racial and ethnic demographics of participants enrolled in surgical endometriosis RCTs.

Methods

We searched Medline, Cochrane Library, PubMed, Embase, Web of Science, and ClinicalTrials.gov databases from January 1, 2000, to October 1, 2025, for randomized controlled trials evaluating the efficacy of surgical interventions for endometriosis. Studies were included if they: (1) included participants aged >18 years and (2) enrolled >25 patients and (3) and English full text article was available. We used descriptive statistics to report the observed trends.

Results

Of 1,521 records identified, 77 studies published between 2000 and 2026 met inclusion criteria. Studies originated primarily from the United States, Sweden, Italy, and Australia. Only 7 of 77 studies (9.1%) reported participant race and/or ethnicity data. Among these studies, racial/ethnic information was available for 490 participants, of whom 363 (74.1%) were identified as White/Caucasian and 31 (6.3%) as Black/African American. Reporting of other racial and ethnic groups was inconsistent, with most categories appearing in only one or two studies. Additionally, one study described the use of an exclusively Italian cohort of 224 participants to “prevent race bias,” but did not provide explicit racial or ethnic demographic data.

Conclusions

The distribution of racial and ethnic groups varied substantially across randomized controlled trials evaluating surgical management of endometriosis, although the majority of studies did not report participant racial or ethnic demographics. These findings highlight significant gaps in demographic reporting and limited representation of diverse populations in surgical endometriosis RCTs, underscoring the need for more inclusive recruitment strategies and standardized reporting practices in future research.

ESGE35-0165 - P390
ePoster Presentations

Clinical characteristics and etiology study of patients with unicornuate uterus and rudimentary horn uterus

Xinmiao Bao[1], Lan Zhu[2]
[1]Peking Union Medical College Hospital- Chinese Academy of Medical Sciences and Peking Union Medical College, Department of Obstetrics and Gynaecology-, Beijing, China
[2]Peking Union Medical College Hospital- Chinese Academy of Medical Science and Peking Union Medical College, Department of Obstetrics and Gynaecology, Beijing, China

Background

Unicornuate uterus is a rare type of congenital uterine malformation. Large cohort studies on unicornuate uterus are still lacking. Previous studies mostly focused on targeted sequencing of candidate genes without a comprehensive evaluation of the genetic background. This study retrospectively analysed the clinical phenotypes and whole genome sequencing of patients with unicornuate uterus and rudimentary horn uterus.

Methods

We retrospectively analysed the inpatient medical records of patients with unicornuate uterus and rudimentary horn uterus at Peking Union Medical College Hospital from January 2010 to January 2025. Whole genome sequencing of a total of 6 trio families (proband and her biological parents) of patients was performed followed by bioinformatic data analysis. Potential pathogenic genes were screened based on candidate genes found in publication and pathogenicity of variants.

Results

A total of 79 surgically confirmed unicornuate uterus patients diagnosed upon surgery were included in this study. A functional rudimentary horn was observed in 63/79 (79.7%) patients with a unicornuate uterus, of which 56/63 (88.9%) patients presented with periodic lower abdominal pain. Endometriosis developed in 45.6% (36/79) patients, and 17.7% (14/79) patients accompanied with fallopian tube malformation on the side ipsilateral to rudimentary horn uterus. The frequency of urinary tract anomalies (33.3%, 19/57) and scoliosis (19.3% , 11/57) were significantly higher than that of the general population. Laparoscopic rudimentary horn uterus resection and ipsilateral salpingo-oophorectomy were the most common surgical treatment, and the mean age of the patients at the time of surgery was 28.1 ± 10.2 years. Six variants were found in five genes including 2 novel missense mutations: (MAP3K1) c.1892T>G(p.Val631Gly), (ITGA8) c.1766T>G(p.Leu589Trp), 2 splicing mutations: (PARL2) c.-194-1G>T, (THRB) c.-115+3G>A and 2 intron variants: (TEK) c.364+3894C>T, (THRB) c.23-12968G>A. Among which, PATL2 and TEK were identified as likely pathogenic, and the significance of THRB、MAP3K1、 ITGA8 variants were uncertain.

Conclusions

After surgically confirmed, a rudimentary horn uterus was observed in all patients with a unicornuate uterus. A functional rudimentary horn uterus was observed in 80% of patients with a unicornuate uterus, and fallopian tube malformation can be commonly found in 6 these patients. Nearly half of the unicornuate uterus patients with functional rudimentary horn uterus developed endometriosis. Patients with a unicornuate uterus are at increased risk for urinary malformations and scoliosis, and therefore urinary ultrasound and spinal X-ray should be routinely screened upon diagnosis. Pelvic magnetic resonance imaging (MRI) has a higher diagnostic rate than pelvic ultrasound and is useful in the classification of uterine malformation. PATL2 and TEK were considered as candidate causative genes, and THRB, MAP3K1, ITGA8 might be related to the disease but have uncertain significance. Unicornuate uterus with rudimentary horn uterus may be a polygenic and multifactorial disease.

ESGE35-0542 - P391
ePoster Presentations

Coexisting Adenomyosis Correlates With Higher #ENZIAN Disease Burden and Surgical Complexity in Endometriosis

Laurin Burla[1], Bernhard Kraemer[1], Cecilia Negri[1], Johanna Schlatter[1], Juergen Andress[1], Lukas Schimunek[1]
[1]University Hospital Tuebingen, Department of Women's Health, Tuebingen, Germany

Background

Adenomyosis has increasingly been linked to more severe phenotypes of endometriosis. This study aimed to evaluate the association between coexisting adenomyosis, endometriosis disease burden, and surgical complexity.

Methods

This retrospective study included 599 women with surgically confirmed endometriosis treated at a tertiary referral center. Disease extent was classified using the #ENZIAN classification and revised American Society for Reproductive Medicine (rASRM) staging system. Adenomyosis was identified through preoperative assessment and intraoperative documentation. Multivariable regression analyses were adjusted for age, body mass index (BMI), and deep endometriosis (DE).

Results

Adenomyosis was identified in 315/599 women (52.6%). Age and BMI did not differ significantly between groups. Women with adenomyosis demonstrated significantly greater disease burden and surgical complexity. Operative times were longer (median 85.0 vs 66.0 minutes) and remained independently associated after adjustment (adjusted increase of 15.64 minutes, 95% CI 3.63–27.66; p=0.011). Deep endometriosis was more frequent in women with adenomyosis (75.8% vs 59.0%) and remained independently associated in multivariable analysis (OR 2.21, 95% CI 1.53–3.21). Advanced rASRM stage III–IV disease was strongly associated with adenomyosis (OR 3.31, 95% CI 1.99–5.58). Greater peritoneal disease burden was observed, including higher rates of #ENZIAN P3 disease (40.3% vs 16.9%; OR 2.88, 95% CI 1.80–4.73). Independent associations were observed across #ENZIAN compartments A, B, and C, with the strongest association for compartment C (OR 3.11, 95% CI 2.00–4.96). Adnexal and tubal involvement were also significantly more frequent in women with adenomyosis.

Conclusions

Adenomyosis is independently associated with greater endometriosis disease burden across all examined endpoints, including deep endometriosis, advanced rASRM staging, more extensive peritoneal and compartment-specific involvement, and longer operative time. The strongest associations were observed for rASRM III–IV and #ENZIAN C compartment involvement. These findings support the use of preoperative adenomyosis assessment to identify patients at higher risk for surgically complex endometriosis, with implications for surgical planning, patient counselling, and specialist referral.

ESGE35-0960 - P396
ePoster Presentations

From Frozen Pelvis to Functional Recovery: Robotic Management of Ureterovaginal Fistula Following Single Port Deep Endometriosis Surgery

Saima Farooq[1], *Amer Raza*[1]
[1]*Cromwell Hospital, Gynaecology, LONDON, United Kingdom*

Background

Deep infiltrating endometriosis (DIE) involving the rectovaginal septum and pararectal spaces represents one of the most technically demanding forms of benign pelvic surgery. Delayed ureteric complications following radical excision are uncommon but may require complex multidisciplinary reconstruction.

Methods

Case Presentation and Surgical TechniqueA 46-year-old woman with severe stage IV endometriosis presented with chronic pelvic pain, dysmenorrhoea, dyspareunia, and bowel symptoms refractory to previous medical management. MRI demonstrated diffuse adenomyosis, rectovaginal disease, bilateral adnexal adhesions, and complete obliteration of the pouch of Douglas consistent with a frozen pelvis. The patient underwent robotic hysterectomy with extensive excision of endometriosis, bilateral ureterolysis, opening of pararectal spaces, rectovaginal dissection, bowel shaving, and excision of deep posterior compartment disease. Postoperatively, she developed persistent urinary leakage. Imaging confirmed a distal ureteric injury with ureterovaginal fistula and associated hydronephrosis requiring nephrostomy insertion. A multidisciplinary robotic reconstructive procedure was subsequently undertaken. Dense postoperative fibrosis was encountered. The diseased distal ureteric segment communicating with the vagina was identified and excised. Robotic ureteroneocystostomy was performed with tension-free ureteric reimplantation and omental interposition flap placement. Intraoperative indocyanine green assessment confirmed satisfactory vascularity and anastomotic integrity.

Results

The reconstruction was completed successfully without intraoperative complications. Postoperative recovery was uneventful with complete resolution of urinary leakage and preservation of urinary drainage. Follow-up imaging and cystoscopic stent removal confirmed satisfactory recovery.

Conclusions

This video demonstrates the feasibility of robotic ureteric reconstruction following complex endometriosis surgery and highlights the importance of multidisciplinary collaboration, early recognition, and advanced robotic reconstructive skills in managing delayed ureteric complications.

ESGE35-0268 - P397
ePoster Presentations

Advanced Robotic Excision of Abdominal Wall and Umbilical Endometriosis with Concurrent Pelvic Endometriosis: A 28-Case Series from a Specialist Endometriosis Unit

Saima Farooq[1], *Amer Raza*[1]
[1]*Cromwell Hospital, Gynaecology, LONDON, United Kingdom*

Background

Abdominal wall and umbilical endometriosis remain underdiagnosed manifestations of extra-pelvic endometriosis, frequently presenting with cyclical pain, palpable nodules, diagnostic delay, and significant impact on quality of life. Surgical excision may be technically challenging due to infiltration across multiple abdominal wall layers and coexistence of pelvic endometriosis. This video presentation demonstrates advanced robotic surgical strategies from a tertiary endometriosis unit managing 28 cases of abdominal wall and umbilical endometriosis over four years.

Methods

A retrospective video series of 28 consecutive patients undergoing surgical management for abdominal wall or umbilical endometriosis was reviewed. Patients commonly presented with cyclical pain at previous caesarean section, appendectomy, or umbilical scars associated with palpable nodules. Preoperative imaging included ultrasound and MRI with endometriosis protocol. The featured case demonstrates bilateral abdominal wall endometriotic nodules associated with pelvic peritoneal endometriosis managed using a combined multidisciplinary approach involving robotic excision and abdominal wall reconstruction planning. Surgical techniques included single-port robotic access, ureteric identification, nerve-sparing peritoneal excision, complete excision of abdominal wall nodules, layered closure, adhesion-reduction strategies, and selective consideration of mesh repair where required.

Results

Complete macroscopic excision was achieved in all cases. Several patients had concurrent pelvic endometriosis requiring simultaneous minimally invasive treatment. The video highlights key operative principles including safe abdominal wall dissection, identification of disease planes, cosmetic scar utilisation, haemostatic dissection, and multidisciplinary collaboration with colorectal and abdominal wall surgeons. No major intraoperative or postoperative complications were observed. Patients demonstrated good postoperative recovery with symptomatic improvement on follow-up and no early recurrence identified during the follow-up period.

Conclusions

Robotic management of abdominal wall and umbilical endometriosis enables precise excision, enhanced visualisation, excellent cosmetic outcomes, and simultaneous treatment of associated pelvic disease. A structured multidisciplinary minimally invasive approach allows safe management of this complex and often overlooked form of endometriosis.

ESGE35-0978 - P398
ePoster Presentations

Single-Port Robotic Discoid Excision for Rectosigmoid Endometriosis: First 10 Cases Demonstrating Feasibility, Safety and Outcomes Comparable to Multiport Robotics

Saima Farooq[1], Amer Raza[1]
[1]Cromwell Hospital, Gynaecology, LONDON, United Kingdom

Aim

Single-Port Robotic Discoid Excision for Rectosigmoid Endometriosis: First 10 Cases Demonstrating Feasibility, Safety and Outcomes Comparable to Multiport Robotics

Background

Deep infiltrating rectosigmoid endometriosis represents one of the most challenging manifestations of advanced endometriosis and frequently requires complex bowel surgery to achieve complete disease clearance while preserving bowel function. Robotic-assisted surgery has transformed the management of advanced endometriosis by providing enhanced dexterity, three-dimensional visualisation and improved precision during pelvic dissection. However, published data regarding single-port robotic discoid excision remain limited. We present our initial ten-case experience of single-port robotic discoid excision for rectosigmoid endometriosis and evaluate its feasibility, safety and perioperative outcomes. A surgical video demonstrating the operative technique and key technical steps accompanies this report.

Materials / Patients

A retrospective review was performed of the first ten consecutive patients who underwent single-port robotic discoid excision for symptomatic rectosigmoid endometriosis at a tertiary referral centre for advanced endometriosis and robotic surgery. Procedures were performed by an experienced multidisciplinary team with expertise in complex endometriosis management. Demographic characteristics, operative findings, associated procedures, perioperative outcomes, complications, need for re-intervention and postoperative recovery were analysed. Surgical feasibility was assessed through completion rates, conversion rates and short-term clinical outcomes.

Methods / Results

Ten patients with symptomatic deep infiltrating rectosigmoid endometriosis successfully underwent single-port robotic discoid excision. All procedures were completed robotically without conversion to multiport robotic surgery, conventional laparoscopy or laparotomy. In several cases, associated endometriosis involving additional pelvic compartments, including the uterosacral ligaments, pelvic sidewall, ureter and adnexa, was identified and treated during the same operation, highlighting the versatility of the single-port platform in managing complex multi-compartment disease. The single-port approach provided excellent visualisation, precise dissection and effective bowel preservation within confined pelvic spaces. Operative access and instrument articulation allowed meticulous identification of critical anatomical structures while maintaining the principles of minimally invasive surgery. Postoperative recovery was favourable, with short hospital stay, early mobilisation and return

to normal activities in most patients. One patient developed a postoperative ureteric leak with fistula formation requiring return to theatre. The complication was recognised promptly and managed successfully with re-operation. The patient subsequently made a good recovery and was discharged home with a favourable clinical outcome. No mortality, permanent bowel dysfunction or stoma formation occurred. Overall perioperative outcomes and complication rates were comparable to those reported in published multiport robotic and conventional laparoscopic discoid excision series.

Discussion

As above

Conclusion

Our initial ten-case experience demonstrates that single-port robotic discoid excision for rectosigmoid endometriosis is a feasible, efficient and safe minimally invasive technique inappropriately selected patients. Although one significant postoperative complication occurred, it was recognised early and managed successfully, resulting in a favourable outcome. The overall safety profile appears comparable to established multiport robotic approaches while potentially offering the advantages of reduced abdominal access trauma, improved cosmesis and enhanced postoperative recovery. Further prospective studies with larger cohorts are required to evaluate long-term outcomes and confirm the role of single-port robotics in complex bowel endometriosis surgery.

Impact On Patients' Health

As above

ESGE35-1009 - P400
ePoster Presentations

Cytological Regression and hrHPV Status in ASC-US and LSIL: Towards a Less Invasive Follow-Up Strategy

Olha Proshchenko[1], Oleksandra Zahorodnia[1], Yeva Ihnatenko[1]
[1]Bogomolets National Medical University, Department of Obstetrics and Gynaecology №1, Kyiv, Ukraine

Background

To evaluate cytological regression, changes in high-risk human papillomavirus (hrHPV) status, and histological findings in women with atypical squamous cells of undetermined significance (ASC-US) and low-grade squamous intraepithelial lesions (LSIL) during a 6-month follow-up period, and to assess differences in these outcomes according to baseline cytological category and hrHPV status.

Methods

Data from 50 women with cervical cytological abnormalities examined at Universum Clinic Medical Center, Kyiv, between September 2025 and September 2026 were analysed. According to baseline liquid-based cytology, women were divided into two equal groups: ASC-US (n=25) and LSIL (n=25). Cytological examination and hrHPV testing were performed at baseline and after 6 months. Cytological regression was defined as a change from ASC-US or LSIL to negative for intraepithelial lesion or malignancy (NILM). Colposcopy was performed to assess the cervical epithelium and determine indications for targeted biopsy. Histological findings were classified as negative/reactive changes, cervical intraepithelial neoplasia grade 1 (CIN1), grade 2 (CIN2), or grade 3 (CIN3). CIN2 and CIN3 were additionally analysed as CIN2+. Fisher's exact test was used for comparisons between groups, with $p<0.05$ considered statistically significant.

Results

The study revealed differences in the dynamics of cytological abnormalities and hrHPV test results between women with ASC-US and LSIL. After 6 months, regression to NILM was observed in 18 of 25 (72.0%) women with ASC-US and only 1 of 25 (4.0%) women with LSIL ($p<0.001$). Cytological abnormalities persisted in 7 of 25 (28.0%) and 24 of 25 (96.0%) women, respectively. At the initial examination, hrHPV was detected in 16 of 25 (64.0%) women with ASC-US and 20 of 25 (80.0%) women with LSIL. Cytological regression was significantly more frequent in hrHPV-negative than in hrHPV-positive women at 6 months (64.3% vs. 4.5%, $p<0.001$) (Table 1). Based on colposcopic findings, cervical biopsy was performed in 23 of 50 (46.0%) women. Histological examination showed no pathology or reactive changes in 6 of 23 (26.1%) cases, CIN1 in 13 of 23 (56.5%), CIN2 in 3 of 23 (13.0%), and CIN3 in 1 of 23 (4.3%). All CIN2+ cases occurred among women with LSIL. Among 14 hrHPV-positive women who underwent biopsy, CIN2+ was detected in 4 (28.6%) cases, whereas no CIN2+ lesions were identified among 9 hrHPV-negative women.

Conclusions

The study results showed that the dynamics of cytological abnormalities over 6 months differed significantly between women with ASC-US and LSIL. Cytological regression of ASC-US and LSIL was associated with negative hrHPV status, while higher-grade lesions were observed in women with persistent hrHPV infection. These findings support consideration of hrHPV status together with cytological findings during follow-up of women with ASC-US and LSIL. And help avoid repeated colposcopy and unnecessary cervical biopsies in women at low risk, while persistent hrHPV infection may indicate the need for further investigation.

VIDEO POSTER PRESENTATIONS

ESGE35-0141 - VP001
Video in ePoster

VNOTES for Uterine Low-Grade Endometrial Stromal Sarcoma

Cihan Comba[1], Sema Karakas[2], Nazlıcan Baytekin[3], Faraneh Azari[3], Burak Güler[4], Ömer Demir[5]
[1]Istanbul Aydın University Faculty of Medicine, Gynecologic Oncology, Istanbul, Türkiye
[2]Hisar Hospital Intercontinental, Gynecologic Oncology, Istanbul, Türkiye
[3]Istanbul Aydın University Faculty of Medicine, Obstetrics and Gynaecology, Istanbul, Türkiye
[4]Acıbadem Altınizade Hospital, Obstetrics and Gynaecology, Istanbul, Türkiye
[5]Karadeniz Technical University Faculty of Medicine, Obstetrics and Gynaecology, Trabzon, Türkiye

Background

Vaginal natural orifice transluminal endoscopic surgery (VNOTES) is increasingly used in gynecologic surgery; however, its role in oncologic cases remains controversial. In this video, we present the application of VNOTES in a patient ultimately diagnosed with low-grade endometrial stromal sarcoma (LG-ESS), highlighting its feasibility in selected cases.

Methods

A 40-year-old woman presented with lower abdominal pain and a long-standing diagnosis of uterine fibroid. Imaging findings raised suspicion of malignancy. A VNOTES hysterectomy with bilateral salpingectomy and intraoperative frozen section analysis was performed. Following final pathology revealing LG-ESS, a secondary VNOTES bilateral oophorectomy was carried out based on multidisciplinary tumor board recommendation.

Results

The procedures were successfully completed using the VNOTES approach, with intact specimen removal and no intraoperative complications. Postoperative recovery was uneventful. Our center has increasing experience in applying VNOTES in selected gynecologic oncologic cases, adhering strictly to oncologic surgical principles.

Conclusions

VNOTES may represent a feasible minimally invasive approach in carefully selected patients with suspected uterine malignancy. This case supports its potential applicability in uterine sarcoma when appropriate surgical precautions are taken. To the best of our knowledge, this represents one of the first reported applications of VNOTES in uterine sarcoma. Further data are required to establish its oncologic safety.

https://player.vimeo.com/video/1190973613?autoplay=1

ESGE35-0055 - VP003
Video in ePoster

A Rare Cause of Overactive Bladder–Like Symptoms: Late Intravesical Suture Extrusion and Bladder Stone Formation

Bulut Varli[1], *Batuhan Aslan*[1], *Batuhan Turgay*[1]
[1]*Ankara University- Faculty of Medicine, Department of Obstetrics and Gynaecology, Ankara, Türkiye*

Background

To present a rare case of delayed intravesical non-absorbable suture extrusion with secondary bladder stone formation, manifesting as long-standing overactive bladder–like symptoms after previous pelvic surgery.

Methods

A 67-year-old woman with a history of total abdominal hysterectomy and bilateral salpingo-oophorectomy for uterine myoma 14 years earlier was evaluated for persistent lower urinary tract symptoms. She had experienced dysuria, urinary frequency, urgency, and nocturia for 10 years, without hematuria. Overactive bladder was initially considered; however, due to her age, history of pelvic surgery, and refractory symptoms, diagnostic cystoscopy was performed.

Results

Cystoscopy revealed an approximately 5 cm bladder stone, suspected to have developed secondary to intravesical extrusion of a non-absorbable suture. Detrusor trabeculation was also observed. The suture was divided using endoscopic scissors, and the stone with the associated suture material was removed transurethrally. At the 3-month follow-up, dysuria, urinary frequency, and urgency had markedly improved. Persistent nocturia was managed with vaginal estrogen and beta-3 agonist therapy.

Conclusions

Delayed intravesical suture extrusion with secondary bladder stone formation is a rare but important differential diagnosis in patients presenting with persistent or severe overactive bladder–like symptoms after pelvic surgery. Absence of hematuria does not exclude an intravesical foreign body. Cystoscopic evaluation should be considered in selected patients with refractory lower urinary tract symptoms, particularly those with a history of pelvic surgery, as it may provide both diagnosis and definitive treatment.

https://player.vimeo.com/video/1188479400?autoplay=1

ESGE35-0181 - VP004
Video in ePoster

Indocyanine green-guided laparoscopic myomectomy for enhanced endometrial cavity visualization

Benoit Peyresblanques[1], *Jean Dubuisson*[2]
[1]*Geneva University Hospitals, Department of Paediatrics- Gynaecology and Obstetrics, Geneva, Switzerland*
[2]*Geneva University Hospitals, Department of Paediatrics- Gynaecology and Obstetrics, Geneva, Switzerland*

Background

Deep intramural myomas represent a surgical challenge due to the risk of inadvertent endometrial breach, which may lead to postoperative complications and impaired uterine healing. Accurate intraoperative identification of the endometrial cavity is therefore essential.

Methods

ICG was injected into the uterine cavity via a transcervical catheter, allowing real-time visualization using near-infrared imaging during dissection.

Results

This technique facilitated identification of the dissection plane and preservation of endometrial integrity.

Conclusions

ICG-guided laparoscopic myomectomy appears to be a simple and effective technique to enhance visualization and reduce the risk of uterine cavity breach.

https://player.vimeo.com/video/1191196539?autoplay=1

ESGE35-0326 - VP005
Video in ePoster

The Double Loop!

Mohamed Salama[1], *Elakhras Sayed*[2], *Vasilios Tanos*[3]
[1]*Ain Shams University, Obstetrics and Gynaecology, Cairo, Egypt*
[2]*Omam Hospital, Minimally Invasive Gynaecology, Cairo, Egypt*
[3]*Nicosia Medical School, Obstetrics and Gynaecology, Nicosia, Cyprus*

Background

Intra-uterine Contraceptive Devices (IUCD) are very popular, widely used and very effective means of contraception. The copper IUCD is usually quite visible on ultrasound scanning (USS), while the hormonal IUCD is not always clearly visible.

Methods

We report a curious case, who was submitted for diagnostic hysteroscopy for a history of abnormal uterine bleeding (AUB). She gave a history of hormonal IUCD insertion for this AUB, but after a few months' patience, she was still bothered by the bleeding, and wanted it removed.
Hysteroscopy was planned for IUCD removal, inspection of the uterine cavity for organic pathology and decision for further management steps.

Results

On entering the uterine cavity, there was a surprise of fi ding 2 IUCD's inside! One was the Hormonal IUCD the patient wanted removed, and another cupper IUCD that was slightly embedded higher up the cavity! Both were removed the hysteroscopic grasping forceps, and then the cavity was inspected, that revealed hyperaemic endometrial lining, but otherwise no other abnormalities.
It is to be noted that the pre-operative USS report findings were only "IUCD in place", without mentioning of any double shadows, for example. On re-obtaining medical history from the patient, with special inquiry about the IUCD insertion and removal, the patient revealed that she reportedly has had the copper IUCD removed before the hormonal one was applied!

Conclusions

Rare incidents in O&G are not that rare indeed! Meticulous history taking from the patients, and detailed ultrasonographic assessment are important preventive tools to avoid such operative surprises.
Patient counseling, precise notification, and accurate documentation are no less important in that regard.

https://player.vimeo.com/video/1191488620?autoplay=1

ESGE35-0324 - VP006
Video in ePoster

Pelvic Splenectomy!

Dr Sayed Elakhras[1], Vasilios Tanos[2], Dr. Mohamed Salama[3]
[1]Omam Hospital, Minimally Invasive Gynecological Surgery, Giza, Egypt
[2]Nicosia Medical School, Obstetrics and Gynaecology, Nicosia, Cyprus
[3]Ain Shms University, Obstetrics and Gynaecology, Cairo, Egypt

Background

The peritoneal surfaces are highly vascular and can provide alternative blood supply for different organs and structures. A notorious example of this is the occurrence of parasitic myomata, which are independent of the uterus for vascularization.

Methods

This video presents a rare case of a patient who was submitted for laparoscopy for infertility, but on inspection of the pelvis, strange, lobulated vascular fleshy nodules were encountered on the pelvic peritoneum.
These were suspected to be neoplastic lesions, and were carefully excised, and removed out of the peritoneal cavity inside a tissue extraction bag

Results

Histopathological examination of the extracted tissue revealed implanted splenic tissue, consistent with peritoneal splenosis. No malignancy detected

This correlates to the medical history of the patient that she has had exploratory laparotomy for a motor car accident, that caused splenic rupture. During that surgery, splenectomy was performed, but obviously some residual tissues found settlement in the pelvic peritoneum.

Conclusions

Careful tissue removal following any spillage into the peritoneal cavity is very important.
Left-over tissues can easily implant on the peritoneal surfaces, continue to grow, and can cause problems later in life.

https://player.vimeo.com/video/1191485862?autoplay=1

ESGE35-0472 - VP007
Video in ePoster

Robot-assisted sacrocolpopexy with uterine preservation for recurrent anterior vaginal wall prolapse following laparoscopic rectopexy

Chaima Mbarki[1], Marie Carbonnel[1], Hind Abbou[1], Jean-Marc Ayoubi[1]
[1]Foch university hospital,
Department of Obstetrics and Gynaecology and Reproductive medicine- Professor Jean-Marc Ayoubi, Suresnes, France

Background

Robot-assisted surgery is an important advancement in Urogynaecology, offering improved precision and visualization during complex pelvic floor reconstruction procedures. It plays a particularly important role in cases of recurrent pelvic organ prolapse after previous prosthetic repair, as altered anatomy and fibrosis can make reoperative surgery challenging. In such cases, robotic assistance can enable safer and more precise correction of compartmental imbalance, particularly in instances of anterior prolapse recurrence following prior posterior compartment repair, such as rectopexy.

Methods

This is the case of a 75-year-old postmenopausal woman (gravida 6 and para 2) with two prior vaginal deliveries. In 2023, she underwent robot-assisted laparoscopic rectopexy for stage III symptomatic rectocele. She experienced symptomatic relief for six months. In 2025, she presented with recurrent vaginal heaviness. A pelvic examination revealed a stage II anterior wall prolapse, according to the POP-Q classification system. The patient reported discomfort and pain with the use of a pessary, which led to an indication for surgical management. After obtaining informed consent, we performed a robot-assisted laparoscopic sacrocolpopexy. The procedure included dissecting the pelvic spaces and identifying anatomical landmarks. The previous posterior mesh was preserved. Broad ligament tunnelling was performed to allow passage of the anterior mesh, which was then fixed in place to restore support to the anterior compartment and overall pelvic balance.

Results

The surgery estimated blood loss was 150 mL and operative time was 140 minutes. The postoperative course was uneventful, and the patient was discharged on postoperative day 3. At 6 months, no recurrence was observed.

Conclusions

Promontofixation with a three-compartment repair remains the gold standard for the surgical management of pelvic organ prolapse. Treating all three compartments reduces the risk of recurrence and eliminates the need for complex secondary surgeries that require advanced expertise and detailed knowledge of the pelvic anatomy.

https://player.vimeo.com/video/1191282722?autoplay=1

ESGE35-0217 - VP009
Video in ePoster

Extrinsic adenomyosis as a surgical continuum of posterior deep infiltrating endometriosis: stepwise laparoscopic compartment-based excision leading to fertility restoration after recurrent IVF failure

Ece Ermin[1], *Do Gyun Kim*[2], *Myung Sook Lee*[2]
[1]*Bozok University, Obstetrics and Gynaecology, Yozgat, Türkiye*
[2]*Dongguk University, Obstetrics and Gynaecology, Gyeongju, Korea- Republic Of*

Background

Extrinsic adenomyosis (EA) is increasingly recognized as part of the deep infiltrating endometriosis (DIE) spectrum and may contribute to severe pelvic compartmental distortion and recurrent assisted reproduction failure.

Methods

Adenomyomectomy should be reserved for selected patients with fertility preservation intent. Although hormonal therapy may be effective in early disease, advanced cases require surgery. According to Kishi Yohei's classification, adenomyosis is divided into intrinsic, focal, mixed, and extrinsic types. We report a 28-year-old woman with chronic pelvic pain, low back pain, and three failed in vitro fertilization (IVF) cycles. Imaging demonstrated extrinsic adenomyosis associated with posterior deep infiltrating endometriosis (DIE) and severe pelvic distortion. A stepwise laparoscopic retroperitoneal compartment-based approach was performed, including pararectal space dissection, ureterolysis, parametrial excision, and complete posterior DIE resection. Rectal involvement was treated with discoid resection. Dissection was performed along embryological planes to preserve the junctional zone.

Results

Complete laparoscopic excision was achieved without intraoperative complications. Postoperative recovery was uneventful. The patient conceived spontaneously and delivered at 37 weeks of gestation via caesarean section.

Conclusions

Extrinsic adenomyosis should be considered part of the deep infiltrating endometriosis (DIE) continuum rather than an isolated uterine pathology. Preservation of the junctional zone allows safe compartment-based surgery. This approach may improve fertility outcomes in advanced endometriosis–adenomyosis spectrum disease refractory to assisted reproductive techniques.

https://player.vimeo.com/video/1191287410?autoplay=1

ESGE35-0483 - VP010
Video in ePoster

Challenging Robotic Surgery in a Massive Multi-Fibroid Uterus: Strategic Dissection in Distorted Pelvic Anatomy

Anıl Erturk[1], Gizem Senol Yilmaz[1], Nergis Kender Erturk[2]
[1]Cerrahpasa Faculty of Medicine, Department of Obstetrics and Gynaecology, Istanbul, Türkiye
[2]Bursa Yuksek Ihtısas Traning and Research Hospital, Department of Obstetrics and Gynaecology, Bursa, Türkiye

Background

Uterine Leiomyoma can cause significant pelvic symptoms and marked uterine enlargement, often creating substantial technical challenges for minimally invasive surgery. In cases of giant multi-myomatous uteri with severe anatomical distortion, the feasibility of robotic surgery remains a subject of ongoing clinical interest. This video abstract presents the robotic surgical management of a complex giant myomatous uterus.

Methods

A 51-year-old woman presented with abnormal uterine bleeding, chronic pelvic pain, dyspareunia, and pelvic fullness. Pelvic examination and ultrasonographic evaluation demonstrated a markedly enlarged multi-myomatous uterus extending beyond the pelvic cavity and reaching the infraumbilical region. Preoperative laboratory evaluation, including tumor markers, revealed no evidence of malignancy. Following comprehensive preoperative assessment, robot-assisted hysterectomy was planned. The surgical video demonstrates trocar placement, retroperitoneal dissection, ureterolysis, vascular pedicle control, management of distorted pelvic anatomy, and specimen extraction strategies.

Results

Robot-assisted surgery was completed successfully without conversion to laparotomy. Despite severe distortion of pelvic anatomy caused by the massive uterine size and multiple fibroids, critical anatomical landmarks were identified safely, adequate exposure was achieved, and vascular control was secured throughout the procedure. The postoperative course was uneventful, and the patient was discharged in stable condition.

Conclusions

Robot-assisted surgery represents a safe and effective minimally invasive option in selected patients with giant multi-myomatous uteri. Careful preoperative planning, advanced anatomical dissection, and structured surgical strategy may facilitate successful management of even highly complex uterine pathology while preserving the benefits of minimally invasive surgery.

https://player.vimeo.com/video/1191663156?autoplay=1

ESGE35-0395 - VP011
Video in ePoster

Laparoscopic Enterocele Repair as an alternative to vaginal mesh implantation - surgery technique step by step

Hanna Szweda[1], *Katarzyna Sachadel*[1], *Tadeusz Issat*[1]
[1]*Institute of Mother and Child, Obstetrics and Gynaecology, Warsaw, Poland*

Background

When the pelvic fascia is damaged, weakened, or absent in the posterior compartment, an enterocele develops.
This is a type of hernia where loops of intestine protrude into the hernial sac. Clinically, it can be difficult to distinguish from a rectocele and requires ultrasound diagnosis.
Thus, enterocele is underdiagnosed and often inappropriately treated defect.

Given the nature of this defect—the absence or damage of the pelvic fascia in the posterior pouch—the use of an alloplastic implant is necessary. Vaginal surgery is typically performed. Though the alloplastic material use is recommended, still posterior colporrhaphy is the most performed procedure for posterior prolapse regardless the type.

One of the risk factors for enterocele is prior surgery changing the vaginal axis and opening the posterior compartment (i.e. anterior or lateral uterine suspensions, Burch urethrosuspension). In such patients, the cervix may be high, with a coexisting massive enterocele.
The high position of the cervix complicates vaginal mesh implantation.
Laparoscopic access is an alternative surgical approach, particularly for such patients.

The purpose of this video abstract is to demonstrate and popularize laparoscopic posterior compartment repair with alloplastic material implantation for enterocele as an alternative to vaginal surgery.

Methods

We present the laparoscopic mesh implantation for the repair of enterocele and coexisting apical defect as the alternative surgical technique , step by step, mentioning possible modifications depending on volume and type of coexisting defects.

Results

Laparoscopic mesh implantation is an effective way of enterocele treatment

Conclusions

Urogynaecological surgery should be individualized.
Laparoscopic mesh implantation can be an alternative to vaginal surgery, worth to consider especially in patients with coexisting apical defect and enterocele, young women that avoiding vaginal scaring is preferred, or women with enterocele and highly positioned cervix or vaginal apex after previous surgery. https://player.vimeo.com/video/1191417464?autoplay=1

ESGE35-0317 - VP012
Video in ePoster

Laparoscopic bilateral hypogastric artery ligation for hypervascular retained trophoblastic tissue after medical abortion

Yasmine Chiba[1], *Mili Youssef*[1], *Hfaiedh Ines*[1], *Mhiri Karima*[1], *Ferdaws Mellouli*[1], *Mourali Mechaal*[1]
[1]*Habib Bougatfa University Hospital in Bizerte, Department of Obstetrics and Gynaecology, Bizerte, Tunisia*

Background

Retained trophoblastic tissue (RTT) after medical abortion may be associated with marked hypervascularization, increasing the risk of severe hemorrhage during surgical evacuation.
This video aims to demonstrate the feasibility and safety of laparoscopic bilateral hypogastric artery ligation as a strategy to reduce pelvic blood flow before surgical management.

Methods

We report the case of a 33-year-old woman with a history of one previous caesarean section who was referred one month after medical termination of pregnancy. Transvaginal ultrasound revealed retained trophoblastic tissue measuring 15 mm. Color Doppler examination demonstrated marked hypervascularization with an aliasing phenomenon and a peak systolic velocity ranging from 20 to 39 cm/s, suggesting a high risk of bleeding.

In the absence of an embolization unit, laparoscopic bilateral hypogastric artery ligation was performed.

Results

The procedure included retroperitoneal dissection with identification of the ureter and internal iliac arteries, followed by bilateral arterial ligation. Diagnostic hysteroscopy and ultrasound-guided aspiration were subsequently performed.

the procedure was completed successfully without intraoperative complications or significant hemorrhage. Post operative ultrasound confirmed complete evacuation with an empty uterine cavity. The patient had an uneventful postoperative recovery.

Conclusions

Laparoscopic bilateral hypogastric artery ligation may represent a safe and effective alternative for the management of hypervascular retained trophoblastic tissue when embolization is unavailable, reducing the risk of severe intraoperative bleeding.

https://player.vimeo.com/video/1191481400?autoplay=1

ESGE35-0358 - VP013
Video in ePoster

Laparoendoscopic single-site modified radical hysterectomy(Type B,Querleu-Morrow classification) bilateral salpingectomy bilateral sentinel pelvic lymph node mapping with indocyanine green (ICG) and fluorescence-guided excision

Qiong Zhang[1], Yu Zhao[1]
[1]The Second Affiliated Hospital and Yuying Children's Hospital of Wenzhou Medical University, Department of Obstetrics and Gynaecology, Wenzhou, China

Background

To describe the feasibility of laparoendoscopic single-site (LESS) modified radical hysterectomy (type B) combined with indocyanine green (ICG) fluorescence-guided sentinel lymph node mapping in a patient with FIGO stage Ia2 cervical squamous cell carcinoma, focusing on surgical technique, intraoperative findings, and postoperative plan.

Methods

A 44-year-old female with FIGO stage Ia2 cervical squamous cell carcinoma underwent a less procedure. after general anesthesia, a 2.5 cm intraumbilical incision was made, and a single-port device was inserted. pneumoperitoneum was established. ICG (1 ml) was injected into the cervical stroma at 3 and 9 o'clock. near-infrared fluorescence identified sentinel nodes, which were excised for frozen section. bilateral salpingectomy was performed, followed by type b modified radical hysterectomy: round ligaments transected, vesicouterine space developed, uterine arteries divided medial to the ureters, and cardinal/uterosacral ligaments transected medial to the ureters with preservation of the ureteral tunnel. the vaginal cuff was incised 1.5 cm below the tumor, and the uterus, parametria, and upper vagina were removed en bloc. the vaginal cuff was closed with barbed suture, and a blake drain was placed.

Results

Three sentinel nodes (right external iliac, right obturator, left common iliac bifurcation) were identified and excised; frozen section was negative for carcinoma. the uterus was normal in size, with a cervical invasion depth of 3.1 mm. no gross parametrial extension was noted. ovaries were preserved. estimated blood loss was 120 ml, and no intraoperative complications occurred. the postoperative plan included foley catheter for 4-5 days, drain removal when output <50 ml/day, and pathology review.

Conclusions

The LESS approach with ICG sentinel mapping avoided the need for full lymphadenectomy, and the type b hysterectomy reduced potential ureteral and bladder morbidity. no conversion to laparotomy was required. this technique appears feasible and safe for selected patients with early-stage cervical cancer.

https://player.vimeo.com/video/1191526338?autoplay=1

ESGE35-0334 - VP014
Video in ePoster

Accidental finding of Sub-phrenic abscess. A case report

Dr Sayed Elakhras[1], Mohamed Salama[2], Haneen Abdel-Wahab[3], Vasilios Tanos[4]
[1]Omam Hospital, Minimally Invasive Gynecological Surgery, Giza, Egypt
[2]Ain Shams University, Obstetrics and Gynaecology, Cairo, Egypt
[3]Omam Hospital, Obstetrics and Gynaecology, Cairo, Egypt
[4]Nicosia Medical School, Obstetrics and Gynaecology, Nicosia, Cyprus

Background

Sub-phrenic abscess is suppurative inflammation that usually occupies the spaces between the hepatic surface and the diaphragm.
It could be the result of many surgical causes, such as perforated peptic ulcer, severe cholecystitis or suppurative cholangitis.
Such cases usually present with severe toxic manifestations, up to septicemia, and significant upper abdominal pain.
It is very uncommon for patients to have this kind of infection, passing unnoticed.

Methods

in this presentation, we discuss the case of a 43 years old lady, who was complaining of secondary infertility, following a previous vaginal delivery 3 years before. She was hypothyroid, but controlled, and has previously had 2 operation. One was a laparoscopy during which she had bilateral tubal ligation for hydrosalpinges, and the other was an open myomectomy procedure.
Her infertility workup revealed bilateral tubal block, and low ovarian reserve.
She consented for diagnostic laparoscopy for the chronic pelvic pain, associating infertility

Results

Laparoscopy revealed severe adhesions, involving the omentum, colonic adhesions with the lateral pelvic wall, bilateral tubo-ovarian adhesions, and ovarian fossa adhesions.
After adhesiolysis of all these adhesions, the tube were found distended and disconnected from the uterine insertion.
Looking up in the abdomen, significant adhesions were found between the liver and diaphragmatic surfaces, also involving the omentum and bowel. During dissection of these adhesions, a pocket of pus was encountered between the liver and the undersurface of the diaphragm, denoting sup-phrenic abscess.
It is notable that the patient was not presented with any manifestations of toxemia, nor did she complain about significant hypochondrial pain.

Conclusions

Sub-phrenic abscess is mainly a surgical condition, usually presented by severe systemic and local manifestations. However, it sems that in a rarity of cases can progress silently from low-grade, well-contained infectious process.

Meticulous examination of the whole abdominal cavity, and investigating the source of abnormal adhesions help reveal this insidious presentation.

https://player.vimeo.com/video/1191500292?autoplay=1

ESGE35-1002 - VP018
Video in ePoster

Navigating the Pelvis: SOSURE Technique in Bladder DIE, Adenomyosis, and Butterfly Excision of Posterior DE Lesion

Kartika Indah Lestari[1], *Mohammad Haekal Mohammad Haekal*[2]
[1]*Nunukan General Hospital obstetric and Gynaecology, Obstetrics and Gynaecology, Nunukan - North Borneo, Indonesia*
[2]*1Obstetric and Gynaecology Department- Harapan Kita National Women and Children Health Centre- Indonesia,*
1Obstetric and Gynaecology Department- Harapan Kita National Women and Children Health Centre- Indonesia, Jakarta, Indonesia

Background

Deep infiltrating endometriosis (DIE) is a severe manifestation of endometriosis, affecting approximately 1% of women of reproductive age. [1-3] Among patients with DIE, urinary tract endometriosis (UTE) is found in 19-53% of cases.[3] Bladder endometriosis (BE) is the most frequent form of UTE, accounting for 70-85% of involvements.[3] It is defined by the presence of endometrial glands and stroma within the detrusor muscle.[4] Deep Infiltrating Endometriosis (DIE) involving the bladder and posterior compartment presents significant surgical challenges due to distorted pelvic anatomy and the proximity of vital structures. The SOSURE (Surgical Opening of Spaces in Uterine RE-positioning) technique aims to provide a systematic approach to restoring anatomy.[5]

Methods

Case Presentation: We present the case of a 36-year-old female with an 8-year history of primary infertility, severe dysmenorrhea (VAS 7-8), and dysuria. The patient has a history of left-sided endometrioma cystectomy via laparotomy three years ago. She has an AMH level of 0.97 ng/mL (diminished ovarian reserve). Ovarian stimulation using an agonist protocol has been performed, resulting in six frozen blastocysts. Diagnostic imaging revealed bladder endometriosis involving muscularis layer of the bladder wall, anterior corpus adenomyosis (2 cm), bilateral hydrosalphings and a right endometrioma. From cystoscopy, we saw there was no mucosal involvement of deep endometriosis lesion in the bladder. The patient underwent laparoscopic surgery using the SOSURE technique, mnemonic for the steps that are required in most endometriosis excision surgery. This involved systematic Survey & Sigmoid mobilisation- Ovarian mobilisations- Suspension of uterus and ovaries- Ureterolysis -Rectovaginal and/or paracetal space entry- Excision of all visible or palpabale disease, allowing for a "butterfly excision" of posterior DIE lesions and meticulous resection of bladder DIE while preserving organ function. The procedure was done uneventfully, patient was discharged one day after surgery, and given GnRH analog post operative for endometriosis disease suppression.

Results

Postoperative recovery was uneventful. Patient was given GnRH analog after surgery in order to do preparation of frozen embrio transfer.

Conclusions

The SOSURE technique provides a safe and reproducible surgical framework for complex DIE cases. By optimizing the pelvic environment surgically, reproductive outcomes in ART can be improved even in patients with significant adenomyosis and endometriosis.

ESGE35-0458 - VP020
Video in ePoster

Laparoscopic Laser Vaporization for Endometrioma with Preservation of Ovarian Reserve – TR-MIGS

Necati Berk Kaplan[1], Bulut Varlı[1], Batuhan Aslan[1], Batuhan Turgay[1], Yavuz Emre Şükür[1]
[1]Ankara University, Obstetrics and Gynaecology, Ankara, Türkiye

Background

To demonstrate a fertility-preserving laparoscopic laser ablation technique for ovarian endometrioma and to evaluate its short-term clinical and ovarian reserve outcomes. Laser ablation aims to minimize damage to healthy ovarian tissue while effectively treating endometriotic lesions.

Methods

A 41-year-old patient with chronic pelvic pain and ovarian endometrioma underwent laparoscopic laser ablation after failure of multiple medical treatment modalities. The procedure was planned as a fertility-preserving intervention. Following cyst drainage and inspection of the cyst cavity, selective laser vaporization of endometriotic tissue was performed while minimizing thermal spread to the surrounding ovarian cortex. Preoperative and postoperative ovarian reserve was assessed using serum Anti-Müllerian Hormone (AMH) levels.

Results

The procedure was completed laparoscopically without intraoperative or postoperative complications. Significant symptomatic improvement was achieved, with dysmenorrhea visual analog scale (VAS) score decreasing from 9 preoperatively to 3 at 3-month follow-up. Ovarian reserve was largely preserved, with AMH levels showing a limited decline from 2.97 ng/mL preoperatively to 2.52 ng/mL postoperatively.

Conclusions

Laparoscopic laser ablation may represent a fertility-preserving alternative to cystectomy in selected patients with ovarian endometrioma, particularly in cases with diminished ovarian reserve or bilateral disease. The precise and superficial tissue effect of laser energy may help reduce ovarian damage while maintaining satisfactory clinical outcomes.

https://player.vimeo.com/video/1191642888?autoplay=1

ESGE35-0459 - VP021
Video in ePoster

Beyond Blind Curettage: Complications Following Unsupervised Medical Abortion In Scarred Uterus

Priyanka Das[1], Neeta Singh[2], Neha Varun[2], Deepali Garg[2], Jyoti Meena[2], Garima k[2]
[1]Senior Resident, Obstetrics and Gynaecology, Guwahati- Assam, India
[2]All India Institute of Medical Sciences- New Delhi, Obstetrics and Gynaecology, New Delhi, India

Background

The increasing availability of over-the-counter (OTC) medical abortion pills constitutes nearly 70–73% in India. Unsupervised use in women with previous caesarean scars may lead to catastrophic complications, particularly when diagnosis is delayed and repeated blind curettage is attempted. Vascular post-abortal scar-site pathology may mimic scar ectopic pregnancy or uterine arteriovenous malformation (AVM), posing major diagnostic and therapeutic challenges. We demonstrate the role of vascular imaging and minimally invasive multidisciplinary management in complex post-abortion complications in scarred uterus.

Methods

Two challenging cases referred to our tertiary care centre with persistent post-abortal bleeding following unsupervised medical abortion and prior failed interventions.

Case 1: A 24-year-old woman with two previous caesarean sections presented after self-administration of medical abortion pills followed by two blind dilatation and curettage (D&C) elsewhere and multiple blood transfusions. Colour Doppler imaging revealed markedly hypervascular scar-site retained products of conception (RPOC), with suspicion of scar ectopic pregnancy/AVM. **Case 2:** A 28-year-old woman with one previous caesarean section and missed abortion underwent failed medical management followed by D&C, subsequently presenting with persistent bleeding and imaging findings suggestive of scar ectopic pregnancy with minimal vascular RPOC. A multidisciplinary minimally invasive approach was adopted in both cases. Case 1 underwent bilateral uterine artery embolization followed by combined hysteroscopy and laparoscopy with laparoscopic excision of adherent products of conception, repair of scar-site defect, and bilateral tubal ligation. Case 2 underwent diagnostic hysteroscopy followed by hysteroscopic removal of RPOC under laparoscopic guidance with bilateral tubal ligation.

Results

Both patients had successful surgical outcomes with complete removal of pathology, effective haemostasis, and avoidance of major intraoperative complications or hysterectomy.

Conclusions

Repeated blind curettage without prior vascular evaluation in scarred uterus may convert a manageable condition into life-threatening haemorrhage. Early vascular assessment and imaging-guided minimally invasive management are crucial.

https://player.vimeo.com/video/1191644241?autoplay=1

ESGE35-0550 - VP022
Video in ePoster

Laparoscopic Cystectomy: Nine centimetres Mature Teratoma

Yasmine Chiba[1], Abdelhedi Cyrine[1], Hfaiedh Ines[1], Ben Amor Mizouni[1], Mourali Mechaal[1], Mellouli Ferdaous[1]
[1]Habib Bougatfa University Hospital in Bizerte, Department of Obstetrics and Gynaecology, Bizerte, Tunisia

Background

Mature Teratomas, or Dermoid cysts, are germ cell tumors formed by pluripotent cells. They often contain well-differentiated cells that produce mature tissues in inappropriate locations like the ovaries. The surgical treatment is generally based on ultrasound or *Magnetic Resonance Imaging (*MRI) findings, tumor size, and the existence of gynecologic pathology. The debate between laparoscopic and laparotomic approach is still ongoing, the main issue being the risk of intra peritoneal cyst rupture and chemical peritonitis.

The aims of this presentation were to describe our surgical approach and the techniques that enable cystectomy to be carried out safely, in order to defend the laparoscopic approach.

Methods

Our patient was 29 years old, followed-up for pelvic pain related to a nine centimetres left adnexal mass suggestive of a dermoid cyst. A first exploration was allowed by introducing the 5 millimetres camera of an hysteroscope through the same site of the pneumoperitoneum insufflation**.** This allowed us to introduce successfully the 10 millimetres central camera under visual control. Then, we protected the cyst with an endobag we started the first cyst incision on the anti-mesial edge, using a monopolar hook. We used cold curved scissors to dissect the ovarian tissue from the cyst wall and very slight controlled divergent pulls. Hemostasis was controlled carefully using bipolar energy, particularly near the Fallopian tube and nourishing vessels. The cystectomy was completed successfully without rupture, and the cyst, protected by an endobag, was extracted through a pelvic incision.

Results

The cystectomy was completed successfully, and the extraction of the surgical specimen was carried out without rupture. Post-operative care was simple. The final pathology examination concluded in a Mature Teratoma without malignancy signs.

Conclusions

The laparoscopic cystectomy in case of Mature Teratomas larger than 5 centimetres can be carried out safely and should be recommended as a first-line treatment, if the patient's condition so allows.

https://player.vimeo.com/video/1191643719?autoplay=1

ESGE35-0554 - VP023
Video in ePoster

Laparoscopic repair of isthmocele

Yasmine Chiba[1], Ben Amor Mizouni[1], Hfaiedh Ines[1], Nouiji Sabrine[1], Jaafar Wissal[1], Mourali Mechaal[1]
[1]Habib Bougatfa University Hospital in Bizerte, Department of Obstetrics and Gynaecology, Bizerte, Tunisia

Background

Isthmocele, or caesarean scar defect, is a common late complication of caesarean delivery that may cause abnormal uterine bleeding, pelvic pain, and infertility. With the increasing rate of caesarean sections worldwide, laparoscopic repair has emerged as an effective minimally invasive treatment for symptomatic patients, offering both symptom relief and restoration of uterine integrity.

Methods

We report the case of a 35-year-old woman, gravida 3 para 3, with a history of three previous caesarean sections, who presented with intermenstrual spotting evolving for one year. Pelvic ultrasound revealed a 13 × 8 mm hypoechoic defect located at the site of the caesarean scar, consistent with an isthmocele.

Given the patient's persistent symptoms, surgical management was indicated, and the decision was made to perform laparoscopic repair of the isthmocele.

The surgical procedure consisted of excision of the defective tissue, identified by transillumination using the light of a hysteroscope inserted vaginally after bladder dissection. The defect was then closed laparoscopically with interrupted sutures using absorbable material.

Results

The laparoscopic surgical procedure went without complications.

Conclusions

Laparoscopic repair of isthmocele appears to be a safe and effective minimally invasive approach for symptomatic patients. It allows correction of the caesarean scar defect, improvement of gynecological symptoms, and restoration of uterine integrity, with favourable postoperative outcomes.

https://player.vimeo.com/video/1191652874?autoplay=1

ESGE35-0503 - VP024
Video in ePoster

Beyond Tubal: Laparoscopic Management of a Misdiagnosed Live Interstitial Ectopic Pregnancy Using a Stepwise Technique

Jennifer Shallop[1], *Vasileios Logdanidis*[1], *Monisha Dhar*[1], *Prashant Purohit*[1]
[1]*Kings College Hospital UK, Obstetrics and Gynaecology, London, United Kingdom*

Background

To demonstrate a reproducible stepwise laparoscopic technique for management of a live interstitial ectopic pregnancy initially misdiagnosed as tubal, emphasising advanced haemostatic strategies, anatomical localisation, and fertility-preserving uterine reconstruction.

Methods

A 39-year-old G6P2 presented at 6+5 weeks' gestation with persistent spotting and right iliac fossa pain following referral from a termination of pregnancy clinic.
Initial ultrasound suggested a live right tubal ectopic pregnancy.
Repeat expert transvaginal ultrasound demonstrated an empty uterine cavity with a 3 cm live right interstitial ectopic pregnancy separate from the tubal ampulla.
The patient was haemodynamically stable and underwent urgent laparoscopic management with an uneventful recovery and short hospital stay.

Results

Laparoscopy confirmed a right interstitial ectopic pregnancy within a normal anteverted uterus without hemoperitoneum. Pelvic adhesions consistent with previous pelvic inflammatory disease were identified. A standardised stepwise surgical approach was performed:

15. Circumferential dilute vasopressin injection for vascular control
16. Bipolar coagulation applied to the implantation base prior to incision to minimise bleeding
17. Right salpingectomy performed followed by an incision to serosa, there was evidence of dense trophoblastic invasion preventing safe conservative dissection hence a wedge resection was undertaken.
18. Myometrial integrity and haemostasis was secured by laparoscopic suturing

Intraoperative "bubbling" confirmed true interstitial implantation, reinforcing accurate anatomical diagnosis.
There was minimal blood loss and no conversion to laparotomy.

Conclusions

True interstitial ectopic pregnancy remains a high-risk condition requiring definitive management due to significant haemorrhagic potential.
There is no consensus on the optimal surgical technique, though minimally invasive laparoscopic

approaches are increasingly favoured over laparotomy.
Haemostatic techniques include vasopressin infiltration, purse-string sutures, uterine artery occlusion, endoloop application, and hydrodissection-assisted resection. Conservative surgery may better preserve myometrial integrity, while wedge resection may improve haemostasis and reduce persistent trophoblastic tissue.
This video demonstrates a safe, reproducible laparoscopic technique combining targeted vascular control, precise anatomical dissection, and fertility-preserving uterine reconstruction.
The educational value lies in the structured operative sequence and practical haemostatic strategies that can be translated into advanced minimally invasive gynaecological practice.

https://player.vimeo.com/video/1196745364?autoplay=1

ESGE35-0563 - VP026
Video in ePoster

Invisible Access, Visible Precision: vNOTES Hysterectomy and BSO

Öykü Ege Atkıcı[1], Oğuz Arslan[2], Rümeysa Belen Gümüş[2], Mustafa Kemal Köksal[2], İbrahim Yalçın[2]
[1]Dokuz Eylul University, Department of Obstetrics and Gynaecology, Izmır, Türkiye
[2]Dokuz Eylul University, Department of Obstetrics and Gynaecology, Izmır, Türkiye

Background

Vaginal natural orifice transluminal endoscopic surgery (vNOTES) has emerged as an innovative minimally invasive approach combining enhanced pelvic visualization with reduced surgical trauma and improved cosmetic outcomes. We present a vNOTES hysterectomy with bilateral salpingo-oophorectomy in a patient with postmenopausal bleeding, previous breast cancer history, and BRCA variant of uncertain significance (VUS) positivity.

Methods

A 53-year-old patient presented with postmenopausal bleeding and thickened endometrium. Following circumferential vaginal incision and posterior colpotomy, the cul-de-sac and uterosacral ligaments were identified. An Alexis retractor was inserted, and pneumoperitoneum was established through the vNOTES platform. Bilateral uterine arteries, parametrial tissues, round ligaments, and infundibulopelvic ligaments were sequentially sealed and transected using LigaSure. Continuous visualization of both ureters was maintained throughout the procedure to ensure safe retroperitoneal dissection and ureteral preservation.

Results

The procedure was completed successfully without intraoperative complications or significant bleeding. Excellent visualization of pelvic anatomical landmarks enabled precise vascular control and safe adnexal dissection. Bilateral ureteral integrity and peristalsis were confirmed intraoperatively. The uterus and bilateral adnexal structures were removed vaginally without abdominal incision, and the vaginal cuff was closed with continuous double-layer suturing.

Conclusions

vNOTES hysterectomy with bilateral salpingo-oophorectomy provided safe retroperitoneal dissection, effective vascular control, and excellent anatomical visualization in this patient. By combining scarless specimen extraction with minimally invasive access, vNOTES represents a safe and cosmetically favourable alternative in contemporary gynecologic surgery.

https://player.vimeo.com/video/1191687827?autoplay=1

ESGE35-0585 - VP027
Video in ePoster

Minimally Invasive Management of a Complex Ovarian Cyst in a Patient with Long-Term Mitrofanoff Follow-up for Neurogenic Bladder: Importance of Advanced Laparoscopic Gynecologic Surgery

Dilek Tektaş[1], Nura Fitnat Topbas Selcuki[1], Bircan Kasap[1]
[1]Sisli Hamidiye Etfal Training and Research Hospital, Gynaecology and Obstetrics, Istanbul, Türkiye

Background

Patients with a history of reconstructive urinary surgery for neurogenic bladder often undergo multiple abdominal operations, leading to severe intraabdominal adhesions. These adhesions make subsequent pelvic surgeries technically challenging and increase the risk of perioperative complications. In such patients, minimally invasive approaches may reduce morbidity; however, surgical difficulty is significantly increased due to altered anatomy and fibrotic tissue planes

Methods

We report the laparoscopic management of a complex ovarian cyst in a patient with neurogenic bladder and a long-term Mitrofanoff conduit. A strategic laparoscopic entry was achieved via a 10-mm trocar placed at Palmer's point to avoid midline adhesions. Extensive adhesiolysis was performed, followed by identification and management of the adnexal mass using standard advanced laparoscopic gynecologic techniques, including cyst aspiration, careful dissection, and endobag-assisted specimen retrieval.

Results

A 36-year-old woman with neurogenic bladder managed with a Mitrofanoff conduit since 2003 presented with a complex right adnexal cystic mass. Her surgical history included left salpingo-oophorectomy and right ovarian cystectomy in 2020. Preoperative imaging confirmed a multiloculated right ovarian cyst measuring approximately 10 cm. During laparoscopy, dense omental and abdominal wall adhesions were encountered. After meticulous adhesiolysis, the cystic mass was identified in the right ovary. Controlled dissection was performed due to distorted pelvic anatomy. The cyst was aspirated, mobilized, and excised laparoscopically with minimal spillage, which was managed by copious irrigation. The specimen was retrieved in an endobag, and hemostasis was achieved. The procedure was completed without complications.

Conclusions

Pelvic surgery in patients with prior complex reconstructive urologic procedures such as Mitrofanoff diversion requires advanced laparoscopic expertise due to severe adhesions and altered anatomy. Careful preoperative planning, appropriate trocar placement, and skilled adhesiolysis enable safe minimally invasive management even in highly complex cases. Laparoscopic surgery should be preferred when feasible, as it reduces postoperative morbidity, shortens recovery time, and limits further adhesion formation.

https://player.vimeo.com/video/1191697643?autoplay=1

ESGE35-0574 - VP028
Video in ePoster

Breaking the ice: a systematic approach to the frozen pelvis.

Lorena Bellan Domiciano Da Silva[1], Roberta Ferraz Salles Kesselring[1], Gabriela Asenjo Seoanes Wright[1], Adrielle Rodas Fernandes[1], Mariano Tamura Vieira Gomes[1], Mariana Corinti[1]
[1]Einstein Hospital Israelita, Minimally Invasive Gynecologic Surgery, São Paulo, Brazil

Background

Frozen pelvis secondary to deep infiltrating endometriosis represents one of the most complex scenarios in minimally invasive gynecologic surgery due to severe fibrosis, distorted anatomy, and close involvement of critical pelvic structures. We present a standardized robotic surgical roadmap for the management of advanced posterior compartment endometriosis using a systematic lateral-to-medial approach.

Methods

A 38-year-old nulligravid patient presented with progressive dysmenorrhea, dyspareunia, constipation, and infertility. Preoperative transvaginal ultrasound with bowel preparation demonstrated a 3.5 cm right ovarian endometrioma, bilateral reduced ovarian mobility, and deep infiltrating endometriosis involving the retrocervical region, right ovarian fossa, posterior vaginal fornix, and anterior rectosigmoid wall. A 4.7 cm rectosigmoid lesion infiltrating the muscularis propria and involving approximately 40% of the bowel circumference was identified. Robot-assisted laparoscopic excision was performed by a multidisciplinary gynecologic and colorectal surgical team. The procedure followed a reproducible stepwise strategy including retroperitoneal access, rectal mobilization, vesicovaginal space development, lateral pelvic dissection using the infundibulopelvic ligament as a landmark, fertility-sparing adnexal surgery, Okabayashi space dissection, and rectovaginal space development using the reverse technique. Indocyanine green fluorescence imaging with the Firefly® system was used throughout the procedure to improve ureteral identification and retroperitoneal navigation.

Results

The systematic lateral-to-medial approach enabled progressive restoration of pelvic anatomy and safe compartmental excision of extensive endometriotic disease in a frozen pelvis setting. Critical structures including the ureters, hypogastric nerves, and pelvic vessels were successfully identified and preserved. Ovarian cystectomy was completed with minimal energy use to optimize ovarian reserve, and tubal preservation was achieved after careful adhesiolysis. Final inspection demonstrated complete restoration of pelvic anatomy without intraoperative complications.

Conclusions

A standardized lateral-to-medial robotic approach provides a safe and reproducible strategy for the surgical management of frozen pelvis caused by deep infiltrating endometriosis. Early retroperitoneal access, anatomical landmark-guided dissection, compartmental surgery, and fluorescence-guided

ureteral identification are key elements to minimize complications while maximizing radical excision and fertility preservation.

https://player.vimeo.com/video/1191694862?autoplay=1

ESGE35-0710 - VP029
Video in ePoster

Uterine artery ligation during laparoscopic hysterectomy for enlarged benign uterus

Yasmine Chiba[1], Rjiba Chayma[1], Medemagh Malek[1], Mhiri Karima[1], Hfaiedh Ines[1], Mourali Mechaal[1]
[1]Habib Bougatfa University Hospital in Bizerte, Department of Obstetrics and Gynaecology, Bizerte, Tunisia

Background

To present a stepwise laparoscopic technique for uterine artery ligation at its origin during hysterectomy for an enlarged benign uterus, with emphasis on ureteral identification and early vascular control.

Methods

We present the case of a 55-year-old postmenopausal patient, gravida 6 para 4, with three vaginal deliveries and one previous caesarean section. She had no relevant medical or surgical history and presented with postmenopausal bleeding evolving over one year. Hysteroscopy with endometrial biopsy showed no malignancy, with atrophic endometrial tissue and leiomyomatous tissue. Clinical examination found a uterus enlarged to approximately 12 weeks of gestation with minimal bleeding of endouterine origin. Ultrasound showed a globular enlarged uterus suggestive of adenomyosis, and thin regular homogeneous endometrium. A laparoscopic hysterectomy was indicated. Surgical exploration found an enlarged globular uterus, an omento-uterine adhesion, adhesions related to the right adnexa, and an elevated bladder. The procedure included adhesiolysis, bilateral salpingectomy, identification of the ureters, opening of the broad ligament and uterine artery ligation at its origin.

Results

Right uterine artery ligation at its origin was performed after clear identification of the pelvic anatomical landmarks and the right ureter. The broad ligament was opened to access the retroperitoneal space. Careful dissection was continued along the anterior division of the internal iliac artery until the uterine artery.The right ureter was clearly identified and kept under direct vision throughout the dissection. The uterine artery was then sealed and divided at its origin, allowing early devascularisation of the uterus before completion of the laparoscopic hysterectomy.The procedure was completed without intraoperative complications.

Conclusions

Uterine artery ligation at its origin can be safely integrated into laparoscopic hysterectomy for an enlarged benign uterus when performed with systematic ureteral identification. This approach provides early vascular control, may improve exposure and haemostasis, and is particularly useful in technically demanding hysterectomy with adhesions or distorted pelvic anatomy.

https://player.vimeo.com/video/1195289710?autoplay=1

ESGE35-0614 - VP030
Video in ePoster

Laparoscopic Resection of Abdominal Wall Endometriosis

Evgeni Baev[1]
[1]*Municipal Hospital, Department of Obstetrics and Gynaecology, Sofia, Bulgaria*

Background

The aim of this video is to demonstrate that laparoscopic excision of abdominal wall endometriosis is feasible and can be done safely following the principles of an interdisciplinary team work.

Methods

A case of a 32-year-old woman, 0 gravida with a history of chronic noncyclic pain in the right lower abdomen and failed spontaneous conception for an year. Furthermore, severe dysmenorrhea, dyspareunia and dysuria with pain progression despite of hormonal treatment with dienogest. The clinical and sonographic examination showed a suspicion of bladder endometriosis and deep infiltrating endometriosis of the left pelvic sidewall as well as endometriotic cyst. A diagnostic laparoscopy proved the presence of large abdominal wall endometriosis with involvement of the ileocecal pol and peritoneal lesions of the diaphragm. An ICG-guided fluorescence ensures a safe retroperitoneal preparation.

Results

No complications were observed. No mesh reinforcement on the internal abdominal wall was needed. Discharge on the fourth postoperative day. The pathological findings revealed skeletal muscle endometriosis. The follow-up visits at third and sixth postoperative month revealed a complete pain relief. A spontaneous pregnancy without artificial reproductive therapy within the first year was achieved and a vaginal birth at terms was recorded.

Conclusions

Abdominal wall endometriosis is a rare condition with not a fully understood pathogenetic character. Despite its rarity, alongside with diaphragmatic it is the most common form of extrapelvic endometriosis. However, no standardized approach has been suggested so far due to lack of consensus.

In our opinion, surgical management of abdominal wall endometriosis is a feasible and safe option for both women failing to achieve a sufficient pain control under hormonal treatment and desiring to conceive. In our case report, we showed that the laparoscopic approach in cases of disseminated deep infiltrating endometriosis of the abdominal wall has improved the patient`s outcome due to complete pain relief, improved quality of life and improved fertility rate and should be considered as an option when counselling patients in such a severe condition.

https://player.vimeo.com/video/1191706646?autoplay=1

ESGE35-0777 - VP032
Video in ePoster

Hysteroscopic Cold-Cut Excision of a Deep FIGO Type 2 Myoma: A Tissue-Sparing Alternative to Electrosurgery

Anıl Erturk[1]
[1]*Cerrahpasa Faculty of Medicine, Department of Obstetrics and Gynaecology, Istanbul, Türkiye*

Background

FIGO type 2 submucosal myomas are frequently associated with abnormal uterine bleeding and may negatively affect quality of life and reproductive outcomes. Conventional hysteroscopic myomectomy is commonly performed using electrosurgical energy under general anesthesia; however, concerns regarding thermal tissue injury, patient discomfort, and the need for operative theater settings have increased interest in office-based mechanical techniques. Cold-scissor hysteroscopic myomectomy performed under local anesthesia may represent a minimally invasive and tissue-preserving alternative in selected patients with small submucosal myomas.

Methods

A 33-year-old woman (G1P1) with a history of one prior vaginal delivery presented with abnormal uterine bleeding, predominantly occurring after menstruation. Transvaginal ultrasonography demonstrated a 12×10 mm FIGO type 2 submucosal myoma. Considering the small size of the lesion and the patient's preference for minimally invasive treatment, office hysteroscopy was planned under local anesthesia. Hysteroscopic myomectomy was performed using mechanical scissors without the use of electrocautery energy. Complete excision of the myoma was achieved through a cold-cut technique.

Results

The procedure was completed successfully in an office setting without the need for conversion to operative hysteroscopy or general anesthesia. No intraoperative or postoperative complications occurred. Electrosurgical energy was not required at any stage of the procedure, allowing preservation of the surrounding endometrial and myometrial tissue. The patient tolerated the procedure well and was discharged on the same day. At the 3-month follow-up, the patient reported complete resolution of abnormal uterine bleeding, and follow-up ultrasonography demonstrated a normal uterine cavity without residual pathology or recurrence.

Conclusions

Office hysteroscopic cold-scissor myomectomy under local anesthesia appears to be a safe, feasible, and minimally invasive treatment option for selected small FIGO type 2 submucosal myomas. Avoidance of electrocautery may minimize thermal tissue injury while providing effective symptom control and rapid recovery.

https://player.vimeo.com/video/1195565695?autoplay=1

ESGE35-0693 - VP033
Video in ePoster

Sentinel Lymph Node Dissection in Endometrial Cancer

Tuğba Tekelioğlu Kutlu[1], Huseyin Akilli[2], Rahma Eno hassano[3], Esra U. Kuscu[2], Nejat Ozgul[2], Ali Haberal[2]
[1]Samsun City Hospital, Gynaecologic Oncology, Samsun, Türkiye
[2]Baskent University Hospital, Gynaecologic Oncology, Ankara, Türkiye
[3]Baskent University Hospital, Obstetrics and Gynaecology, Ankara, Türkiye

Background

Minimally invasive surgery is the standard treatment approach for endometrial cancer. The aim of this video is to demonstrate the technique of laparoscopic sentinel lymph node dissection.

Methods

A 40-year-old woman diagnosed with grade 1, stage 1 endometrial cancer was included. The patient showed progression despite Megace therapy administered for fertility preservation. The surgery was performed laparoscopically. A total of 2 cc of indocyanine green was injected, including 1 cc deep and 1 cc superficial injection.

Results

The peritoneum close to the round ligament was opened using an energy device to enter the retroperitoneal space. Careful dissections were performed through the bubble area toward the obturator fossa. A green-stained sentinel lymph node and the lymphatic pathway were identified. The lymph node was dissected away from the external iliac vein and separated from the surrounding tissues while preserving the obturator nerve. The procedure was completed successfully.

Conclusions

Laparoscopic sentinel lymph node dissection is a safe and feasible minimally invasive technique in patients with endometrial cancer.

https://player.vimeo.com/video/1195157918?autoplay=1

ESGE35-0738 - VP034
Video in ePoster

Robotic Management of External Iliac Artery Injury During Pelvic Lymphadenectomy for Advanced Vulvar Cancer

Giuseppe Mercurio[1], Stefano Uccella[2], Pier Carlo Zorzato[2], Luca Mezzetto[3], Francesca Saletti[4], Sofia Thiella[4]
[1]AOUI Verona- Ospedale Donna e del Bambino, Ginecologia ed Ostetricia, verona, Italy
[2]AOUI Verona, UOC Ginecologia ed Ostetricia BT, Verona, Italy
[3]AOUI Verona, Chirurgia Vascolare, verona, Italy
[4]AOUI Verona, UOC Ginecologia e Ostetricia BT, verona, Italy

Background

Vascular injuries during pelvic lymphadenectomy are uncommon but potentially life-threatening complications in gynecologic oncology surgery. Immediate bleeding control and accurate vascular repair are essential to prevent massive hemorrhage, conversion to laparotomy, and postoperative ischemic complications. Robotic-assisted surgery may offer important technical advantages in the management of vascular emergencies because of enhanced three-dimensional visualization, tremor filtration, articulated instruments with multiple degrees of freedom, and improved intracorporeal suturing capabilities. We report the robotic management of an external iliac artery injury occurring during ultra-radical pelvic surgery for advanced vulvar cancer, emphasizing the technical benefits provided by the Da Vinci Xi system.

Methods

A 70-year-old multiparous woman with two previous vaginal deliveries was referred for treatment of infiltrating squamous vulvar carcinoma G2–G3, FIGO stage IVB. Her medical history included type II diabetes mellitus and medically controlled hypertension. No significant previous surgical history was reported.

The patient was scheduled for robotic total pelvic exenteration type III according to Magrina classification with bilateral inguinofemoral lymphadenectomy using the Da Vinci Xi robotic platform.

During right pelvic lymphadenectomy, an accidental lesion of the external iliac artery occurred. Immediate proximal vascular control was achieved using the fourth robotic arm, allowing stable compression of the vessel and optimal visualization of the surgical field. The vascular defect was repaired robotically with interrupted 5-0 Prolene sutures. Hemostatic reinforcement was completed using a fibrin sealant patch (TachoSil®). Postoperative thromboembolic prophylaxis with daily weight-adjusted enoxaparin was administered according to institutional protocol.

Results

The robotic platform enabled precise intracorporeal vascular repair without conversion to open surgery. The articulated robotic instruments facilitated optimal needle angulation and controlled needle impact on the vascular wall, allowing accurate placement of interrupted sutures while

minimizing additional endothelial trauma. The stability provided by the fourth robotic arm was particularly useful in maintaining proximal vascular control throughout the repair.

Complete hemostasis was achieved intraoperatively. Computed tomography angiography performed on postoperative day one demonstrated no contrast medium extravasation or vascular leakage. No postoperative vascular, hemorrhagic, or thromboembolic complications occurred. At 30-day follow-up, the patient remained clinically stable without evidence of vascular complications.

Conclusions

Robotic-assisted management of major vascular injuries during gynecologic oncology surgery is feasible and safe in selected cases. The Da Vinci Xi platform provides important technical advantages for vascular suturing, including enhanced instrument articulation, stable exposure, and precise intracorporeal needle control. These characteristics may improve intraoperative safety and reduce the need for conversion during complex pelvic procedures.

ESGE35-0780 - VP035
Video in ePoster

A Challenging Case of Laparoscopic Bilateral Salpingectomy : The Impact of Adhesions on Fertility, an Underestimated Problem ?

Ece Sen[1], Ali Akdemir[1], Sabahattin Anıl Arı[2], Fatih Sendag[1]
[1]Ege University- Faculty of Medicine, Obstetrics & Gynaecology, Izmir, Türkiye
[2]Bakırcay University Cigli Regional Education Hospital, Obstetrics & Gynaecology, Izmir, Türkiye

Background

Adhesions are fibrin bands that develops in 67-97% of cases after abdominal surgical interventions. Risk factors for adhesions include the type of surgical procedure and technique, genetic predisposition, age, malignancy, pelvic inflammatory disease, endometriosis, infections, comorbidities (1,2). Adhesions can distort anatomy, reduce blood supply, impair organ function and mobility (3), leading to mechanical ileus, infertility, chronic pelvic pain, and surgical difficulties.

Adhesions of inner or outer side of Fallopian tube can cause partial or total tubal occlusion and restrict to grasping of the ovum by the fimbria. Consequently the rate of conception decreases whereas the risk of ectopic pregnancy increases (1).

This video demonstrated to bilateral salpingectomy and anatomic restoration of the pelvis in a patient with severe adhesions.

Methods

A 26-year-old woman with a desire for fertility (G1P1) presented for evaluation. Her past surgical history included a caesarean section and relaparotomy for postoperative ileus five years prior. On ultrasound examination, bilateral hydrosalpinges were observed, while the uterus, bilateral ovaries appeared normal. Anti-Müllerian hormone (AMH) level and semen parameters were normal. No additional comorbidities were presented.

The peritoneal cavity was accessed via Palmer's point due to periumbilical adhesions. Extensive adhesiolysis was performed, including release of adhesions between the small bowel, omentum, and anterior abdominal wall, as well as adhesions involving the anterior and posterior uterine surfaces. Bilateral salpingectomy was performed and normal anatomy was restored.

Results

The patient was discharged on postoperative day two without any complications.

Conclusions

Laparoscopy is the gold standard for the diagnosis and management of abdominal and pelvic adhesions (4).

Although no standardized guideline exists for the management of postoperative adhesions, the use of minimally invasive techniques, adherence to microsurgical principles, meticulous hemostasis,

appropriate use of adhesion barriers, reduction of the inflammatory response are recommended to minimize adhesion formation.

https://player.vimeo.com/video/1195574631?autoplay=1

ESGE35-0815 - VP036
Video in ePoster

Accessory and cavitated uterine mass (ACUM): video demonstration of typical intramyometrial and atypical broad-ligament presentations

Rok Sumak[1], *Branka Žegura Andrić*[1]
[1]*University Medical Centre Maribor, Department of General Gynaecology and Gynaecologic Urology, Maribor, Slovenia*

Background

Accessory and cavitated uterine mass (ACUM) is a rare müllerian anomaly usually located within the anterolateral myometrium near the insertion of the round ligament. This video aims to demonstrate the surgical anatomy, laparoscopic identification, excision, and uterine reconstruction in a typical intramyometrial acum and an atypical pedunculated broad-ligament presentation.

Methods

We reviewed eight surgically managed patients with typical or suspected acum at our institution. Seven patients had typical intramyometrial lesions, while one patient had an atypical right-sided pedunculated broad-ligament lesion. The video presents two representative cases: one typical left intramyometrial acum and one atypical right-sided lesion. Preoperative ultrasound and magnetic resonance imaging findings were correlated with laparoscopic anatomy and histopathology. Patient consent to present and publish the video material was obtained.

Results

The typical case showed a left lateral intramyometrial cavitated lesion with hemorrhagic content, located below the tubal angle and round ligament insertion. Laparoscopic excision confirmed a non-communicating cavitated mass surrounded by smooth muscle and lined by endometrial-type tissue. The atypical case showed a right lateral cavitated lesion adjacent to the uterine corpus and partially separated from the myometrium by peduncle. Laparoscopic excision was feasible, with preservation of the uterine miometrial tissue. Histopathology confirmed an accessory uterine cavity. Associated pelvic endometriosis was identified in several patients within the series.

Conclusions

ACUM is usually intramyometrial, but pedunculated broad-ligament presentations may occur and can mimic focal adenomyosis, myoma, endometriotic lesions, or rudimentary uterine structures. Video demonstration may improve recognition of anatomical landmarks and support complete laparoscopic excision with uterine preservation.

https://player.vimeo.com/video/1195642531?autoplay=1

ESGE35-0871 - VP038
Video in ePoster

Laparoscopic Vaginectomy for Primary Vaginal Adenocarcinoma: A Case Report

Sultan Jinda Doğan[1], Mehmet Ali Vardar[2], Ghanim Khatip[3]
[1]Çukurova University, Obstetrics and Gynaecology, Adana, Türkiye
[2]Çukurova University, Gynecologic Oncology department, Adana, Türkiye
[3]Çukurova University, Gynaecologic Oncology department, Adana, Türkiye

Background

Primary vaginal adenocarcinoma is an uncommon gynecologic malignancy accounting for a small proportion of female genital tract cancers. Because of its rarity, optimal diagnostic and therapeutic approaches remain controversial. We aimed to present the clinical, surgical, and pathological findings of a patient diagnosed with primary vaginal adenocarcinoma.

Methods

A G2P2A0 woman with a history of one vaginal delivery and one caesarean section presented with postcoital bleeding. Her medical history was significant for diabetes mellitus and coronary artery disease with previous coronary stent placement. Gynecologic examination revealed a 2–3 cm mass lesion on the left lateral vaginal wall. Vaginal biopsy demonstrated adenocarcinoma. PET-CT imaging showed no evidence of distant metastatic disease. The patient underwent bilateral sentinel lymph node dissection, laparoscopic hysterectomy, bilateral salpingo-oophorectomy, total vaginectomy, and bilateral inguinal sentinel lymph node dissection. Histopathological findings and lymph node status were evaluated postoperatively.t metastasis was detected. Following multidisciplinary evaluation at the gynecologic oncology tumor board, close surveillance without adjuvant treatment was recommended.

Results

Final pathological examination demonstrated no lymph node involvement. The tumor was identified as a focal lesion measuring less than 1 mm in width within the specimen, with an overall tumor size of 11 mm and a stromal invasion depth of 7 mm. Surgical margins were negative, and no distant

Conclusions

Primary vaginal adenocarcinoma is a rare malignancy that requires individualized multidisciplinary management. Comprehensive surgical staging may provide favourable oncologic outcomes in selected patients without metastatic disease. Careful postoperative surveillance can be considered in patients with negative lymph nodes and no residual disease.

https://player.vimeo.com/video/1195717639?autoplay=1

ESGE35-0007 - VP039
Video in ePoster

Transvaginal natural orifice single-port laparoscopic sacrohysteropexy: a hybrid uterus-sparing technique for apical prolapse

Zhensheng Mai[1], *Yubin Han*[1]
[1]*The first people's hospital of Foshan, Department of Obstetrics and Gynaecology, Foshan, China*

Background

To demonstrate the surgical technique of a hybrid transvaginal natural orifice transluminal endoscopic surgery (vNOTES) single-port laparoscopic sacrohysteropexy using an intraoperatively tailored y-shaped polypropylene mesh for uterus-sparing apical prolapse repair.

Methods

A 48-year-old multiparous woman (g2p2) with symptomatic stage III pelvic organ prolapse (pop-q: point C +4 cm, point D +2.5 cm) underwent the procedure. A circumferential colpotomy was performed. Vesicovaginal and rectovaginal spaces were developed transvaginally. Unilateral pararectal space blunt dissection facilitated vaginal single-port insertion with purse-string suture for airtight seal. A retroperitoneal tunnel was created to the sacral promontory. A 15×10 cm lightweight polypropylene mesh was tailored into y-shape. Short arms were fixed transvaginally to anterior and posterior vaginal walls (extending to point Aa); the long arm was secured tension-free to the anterior longitudinal ligament via extracorporeal knot tying. Peritoneum was closed over the mesh. Patient consent to present and publish has been obtained.

Results

The procedure was completed successfully with minimal blood loss and no complications. Postoperative recovery was uneventful with rapid symptom resolution. At one-year follow-up, pop-q showed sustained correction with point C at -6 cm, confirming durable apical support and preserved vaginal axis.

Conclusions

This hybrid vNOTES sacrohysteropexy combines vaginal surgery advantages for superior avascular plane dissection and efficient mesh suturing; the transvaginal route is effective for sacral fixation. Major points for viewers include precise plane development, purse-string secured port insertion for airtight seal, and meticulous retroperitoneal tunneling with protection of adjacent structures for safe tension-free mesh placement.It represents a promising minimally invasive evolution for selected prolapse cases.

https://player.vimeo.com/video/1170684923?autoplay=1

ESGE35-0054 - VP040
Video in ePoster

vNOTES Myomectomy for Primary Ovarian Leiomyoma Combined with Uterine Fibroid

Emre Biton[1], Berke Nur Ergu[2], Kemal Gungorduk[3]
[1]Mugla Sitki Kocman University, Gynaecology and Obstetrics, Mugla, Türkiye
[2]Mugla Sıtkı Koçman University, Department of Obstetrics and Gynaecology, Muğla, Türkiye
[3]Mugla Sıtkı Koçman University,
Department of Obstetrics and Gynaecology Division of Gynaecologyc Oncologoy, Muğla, Türkiye

Background

Primary ovarian leiomyoma is an exceptionally rare tumor, comprising only 0.5% 1% of all benign ovarian neoplasms, with limited cases documented in the literature [1,2]. Its origin remains a subject of debate, with theories proposing it may arise from ovarian hilar blood vessels, cells of the ovarian ligament, smooth muscle cells, or multipotent cells within the ovarian stroma [1,2]. Preoperative diagnosis is often difficult due to the nonspecific nature of imaging and laboratory findings. Moreover, its similarity to fibromas frequently leads to diagnostic challenges [2,3]. Vaginal natural orifice transluminal endoscopic surgery (vNOTES) presents numerous benefits, such as superior cosmetic outcomes, quicker return of flatus, and reduced hospital stays. This minimally invasive technique has gained significant and growing acceptance across various gynecologic procedures. vNOTES appears to be a feasible option based on the limited evidence currently available for gynecological indications that preserve the uterus and ovaries [4]. This video demonstrates the surgical removal of a left ovarian tumor, identified alongside an intramural leiomyoma, performed using vNOTES.

Methods

A comprehensive case report complemented by a video presentation showcasing the step-by-step process of a surgical technique aimed at treating ovarian and uterine myomas. A 42-year-old nulligravida woman presented with complaints of lower abdominal pain and expressed a desire to conceive. She had a BMI of 23 kg/m². Both physical and abdominal examinations were normal, but on vaginal examination, a mobile mass measuring approximately 4 × 5 cm was identified in the left lower abdomen. Laboratory investigations, including complete blood count and biochemical tests, showed normal results, and tumor markers such as CA 125, HE4, inhibin B, and CEA were within normal limits. Transvaginal ultrasonography revealed a homogeneously isoechoic mass in the left adnexa (measuring 41 mm × 36 mm) along with a homogeneous posterior intramural lesion within the uterine wall. Pelvic MRI demonstrated a well-defined 4 × 3 cm solid tumor in the left adnexa and a posterior intramural uterine leiomyoma on T2-weighted sequences. The MRI signal findings suggested that the ovarian tumor was likely consistent with a fibroma or thecoma.

Results

A vNOTES procedure was performed to remove both masses, successfully yielding histological confirmation of a primary ovarian leiomyoma and uterine leiomyoma, devoid of malignancy features. Following the ERAS guidelines, oral intake and patient ambulation were initiated on the day of

surgery.
The patient underwent a smooth recovery and showed no symptoms or signs of recurrence at the 9 month follow-up, as confirmed by MRI findings.

Conclusions

The coexistence of a primary ovarian leiomyoma with a uterine leiomyoma is an exceptionally rare occurrence. While ovarian leiomyomas are typically asymptomatic findings, they should be included in the differential diagnosis when assessing solid ovarian masses.

https://player.vimeo.com/video/1188438478?autoplay=1

ESGE35-0072 - VP042
Video in ePoster

Extraperitoneal Approach for Sacrocolpopexy in Vaginal Natural Orifice Transluminal Endoscopic Surgery

Serkan Ustuntas[1], Kemal Gungorduk[2], Emre Biton[3]
[1]Faculty of Medicine- Muğla Sıtkı Koçman University, Department of Obstetrics and Gynaecology, Mugla, Türkiye
[2]Mugla Sıtkı Kocman University, Gynecologic Oncology, Mugla, Türkiye
[3]Mugla Sıtkı Kocman University, Gynacology and Obstetrics, Mugla, Türkiye

Background

Background: The aim of this video presentation is to demonstrate the surgical steps and feasibility of the extraperitoneal sacrocolpopexy technique performed via transvaginal Natural-Orifice Transluminal Endoscopic Surgery (vNOTES) for the management of advanced apical compartment prolapse.

Methods

Methods: We present the clinical case of a 62-year-old obese woman (BMI: 31 kg/m²) with a history of 4 vaginal deliveries, who presented with pelvic pressure and the sensation of a vaginal bulge. Her medical and family histories were unremarkable. Clinical evaluation confirmed a Stage 4 apical-vaginal prolapse according to the POP-Q system. Pelvic ultrasound showed a normal-sized uterus with no endometrial abnormalities, and surgical intervention was planned.

Results

Results: The video illustrates the comprehensive surgical steps of the vNOTES extraperitoneal sacrocolpopexy. The procedure was successfully completed while utilizing only a modest Trendelenburg tilt (10°-15°), which provided adequate visualization and ergonomic access for mesh placement despite the patient's elevated BMI.

Conclusions

Conclusions: The vNOTES extraperitoneal sacrocolpopexy technique is both a viable and safe short-term surgical option for addressing advanced apical compartment prolapse. Importantly, this technique allows for a modest Trendelenburg tilt (10°-15°), offering a significant intraoperative and anaesthetic advantage, particularly for patients with an elevated BMI.

https://player.vimeo.com/video/1189157207?autoplay=1

ESGE35-0121 - VP044
Video in ePoster

Rudimentary horn pregnancy in a unicornuate uterus: a case report and implications for fertilization mechanisms

Norbert Nosal[1], *Ludwig Sebastian*[2]
[1]*Elisabeth Hospital Essen, Gynaecology and Obstetrics, Essen, Germany*
[2]*University of Cologne, Department of Gynaecology and Obstetrics, Cologne, Germany*

Background

Pregnancy in a rudimentary horn (RH) represents a rare and potentially life-threatening condition. While fertilization is generally assumed to occur in the ipsilateral fallopian tube, alternative mechanisms such as transperitoneal migration of the ovum or sperm have been proposed.

Methods

The case report is about a 35-year-old woman (gravida 2, para 1) presenting at 8 weeks of gestation with a viable pregnancy located in the right rudimentary horn. Previous laparoscopy with chromopertubation, performed 2.5 years prior, demonstrated no communication between the right rudimentary horn and the cervix, with a left-sided unicornuate uterus.

Results

Early diagnosis was achieved in the first trimester based on ultrasound findings and the patient's known medical history. Surgical management was performed via laparoscopy, including resection of the pregnant rudimentary horn and the ipsilateral fallopian tube. A review of the literature confirms that pregnancies in a rudimentary horn, although rare, have been described in several hundred cases.

Conclusions

This case supports the possibility of alternative fertilization mechanisms, such as transperitoneal migration of gametes, in the development of rudimentary horn pregnancies. Awareness of this condition is essential for early diagnosis and appropriate management.

https://player.vimeo.com/video/1190880715?autoplay=1

ESGE35-0145 - VP046
Video in ePoster

Laparoscopic Sacrocolpopexy in the Post-Radical-Hysterectomy Pelvis: A Step-by-Step Approach to Vault Prolapse After Cervical Cancer Surgery

Burak Cakmak[1], *Harika Yumru Celiksoy*[2], *Ecem Pasaoglu*[3]
[1]*Mus State Hospital, Obstetrics and Gynaecology, Mus, Türkiye*
[2]*Sisli Hamidiye Etfal Research and Training Hospital, Gynecological Oncology, Istanbul, Türkiye*
[3]*Sisli Hamidiye Etfal Research and Training Hospital, Obstetrics and Gynaecology, Istanbul, Türkiye*

Background

Vaginal vault prolapse following radical hysterectomy is an under-reported but clinically challenging entity, in which extensive prior pelvic dissection, lymphadenectomy, and altered ureteral course substantially increase the technical difficulty of any subsequent reconstructive procedure. Laparoscopic sacrocolpopexy is regarded as the gold-standard treatment for apical prolapse, yet evidence and technical descriptions in the post-oncologic pelvis remain scarce. The aim of this video is to demonstrate a standardised, reproducible laparoscopic sacrocolpopexy technique in a patient with symptomatic vault prolapse two years after a Type II radical hysterectomy with pelvic lymphadenectomy.

Methods

We present the case of a 66-year-old patient who, two years previously, had undergone Type II radical hysterectomy, pelvic lymphadenectomy, and anterior colporrhaphy for cervical cancer with a stage III cystocele. After two years of oncologic follow-up without recurrence, she presented with symptomatic vaginal vault prolapse, and laparoscopic sacrocolpopexy was planned. The video illustrates a stepwise approach: (1) right pelvic sidewall adhesiolysis; (2) LigaSure-assisted dissection of the peritoneum overlying the vaginal cuff; (3) right lateral peritoneal opening with identification of the ureter and avoidance of the major sidewall vessels; (4) exposure of the sacral promontory while protecting the right ureter, common iliac vessels, and middle sacral artery; (5) fixation of a T-shaped polypropylene mesh to the vaginal cuff with five helical tackers, reinforced with three interrupted polypropylene and three braided polyester (Ethibond) sutures; (6) tension-free sacral fixation with five tackers plus an Ethibond suture; and (7) complete retroperitonealisation of the mesh with a continuous Vicryl suture.

Results

The procedure was completed laparoscopically without conversion. No intraoperative complications, ureteral or vascular injury, or visceral injury occurred. Anatomical apical support was achieved with full mesh retroperitonealisation. The postoperative course was uneventful.

Conclusions

Laparoscopic sacrocolpopexy is feasible and safe in the post-radical-hysterectomy pelvis when a standardised, anatomy-respecting technique is applied. Careful adhesiolysis, a right lateral approach

for ureteral identification, and dual-suture mesh reinforcement with complete retroperitonealisation are key technical principles for reproducible apical support in this complex post-oncologic setting.

https://player.vimeo.com/video/1190979836?autoplay=1

ESGE35-0232 - VP047
Video in ePoster

Laparoscopic Myomectomy

Inês Batista[1], Andreia Martins[1], Luis Castro[1], Helder Ferreira[1], Rosa Zulmira Macedo[1]
[1]ULS Santo António- Centro Materno-Infantil do Norte, Ginecologia, Porto, Portugal

Background

Case Description: A female patient, aged 26, with continuous bleeding due to multiple submucosal fibroids.

Methods

Surgery Description: It was decided to do a laparoscopic myomectomy. To optimize surgical exposure, T-lifts were applied to the ovaries. Temporary occlusion of the uterine arteries, infundibulopelvic and round ligaments was performed for haemostatic control during the uterine incision. The cluster of submucosal fibroids was excised using Ligasure, and the uterine wall was closed in a double-layer suture. Fibroids were removed via morcellation. Subsequently, the transient clips were removed to restore normal vascularization, confirming the absence of active bleeding. Finally, the Interceed was applied over the uterine scar for adhesion prevention.

Results

The surgical procedure was concluded with no complications and minimal blood loss. The fibroids were removed and the symptoms of bleeding stopped.

Conclusions

The surgery was successfully executed and the patient regained her quality of life.

https://player.vimeo.com/video/1191307609?autoplay=1

ESGE35-0233 - VP048
Video in ePoster

Outpatient Hysteroscopic polypectomy using a loop device in a fertility population

Mahua Bhaduri[1], Kuga Vigneswaran[2], Venkatesh Subramanian[1]
[1]King's College Hospital, Obstetrics and Gynaecology, London, United Kingdom
[2]King's Fertility, King's Fertility, London, United Kingdom

Background

Endometrial polyps are localized hyperplastic overgrowths of endometrial glands and stroma surrounding a vascular core and are commonly encountered in patients undergoing fertility treatment. They have been associated with reduced implantation and pregnancy rates, likely due to mechanical distortion of the uterine cavity and alterations in endometrial receptivity. In this population, preservation of the endometrium is critical to optimize implantation potential. Blind dilation and curettage or empirical medical management are associated with higher recurrence rates and an increased risk of endometrial injury and are therefore not recommended. Outpatient hysteroscopy offers a minimally invasive “see and treat” approach with direct visualization and targeted treatment. The objective of this video abstract is to demonstrate outpatient hysteroscopic polypectomy using the LiNA Lasso device in a fertility patient, highlighting techniques to avoid endometrial injury.

Methods

This video presents an anonymized case of a 35-year-old patient undergoing fertility treatment with frozen embryos, diagnosed with endometrial polyps on saline sonogram following an IVF cycle. An outpatient hysteroscopic polypectomy was performed using the LiNA Lasso, a single-use mechanical device compatible with a 1.87 mm working channel hysteroscope, allowing polyp removal without cervical dilation or energy application. The procedural steps, including cervical entry, cavity inspection, identification of pedunculated and broad-based polyps, and targeted mechanical resection, are demonstrated.

Results

Complete polyp removal was achieved in the outpatient setting without complications, with preservation of the surrounding endometrium. The mechanical, non-energy technique minimized the risk of thermal injury and reduced patient discomfort and complications associated with blind cervical dilation.

Conclusions

Outpatient hysteroscopic polypectomy using the LiNA Lasso is a feasible and endometrium-sparing approach for managing endometrial polyps in fertility patients. Careful patient selection, meticulous hysteroscopic technique, and appropriate instrument choice are essential to optimize reproductive outcomes. Blind dilatation and thermal energy should be avoided where possible.

https://player.vimeo.com/video/1191310790?autoplay=1

ESGE35-0237 - VP049
Video in ePoster

Ultimate Pain Relief: Radical Management of Recurrent DIE Incorporating Dorsal Parametrectomy

Emre Biton[1], Kemal Gungorduk[2]
[1]Mugla Sitki Kocman University, Department of Obstetrics and Gynaecology, Mugla, Türkiye
[2]Mugla Sitki Kocman University,
Department of Obstetrics and Gynaecology Division of Gynecologic Oncology, Mugla, Türkiye

Background

The surgical management of complex adnexal masses combined with severe adenomyosis requires meticulous planning, particularly in patients with a history of prior open pelvic surgery. Operating on a solitary ovary with a high-risk malignancy index demands both oncological safety and principles of minimally invasive surgery. This video demonstrates the challenging total laparoscopic hysterectomy (TLH) and left unilateral salpingo-oophorectomy (USO) in a patient suffering from chronic pelvic pain that severely impaired her social life, complicated by previous laparotomy and altered pelvic anatomy

Methods

A 50-year-old nulliparous female (G0P0) presented with chronic pelvic pain significantly affecting her daily life. Her surgical history was notable for a laparotomy in 2007 for a right salpingo-oophorectomy and cyst excision. Preoperative laboratory tests revealed elevated tumor markers: CA-125 was 52.3 U/mL, HE4 was 129 pmol/L, and the ROMA index was calculated as 44.9. Pelvic MRI demonstrated an enlarged uterus with adenomyosis and multiple nodular lesions, including a 5 cm heterogeneous fundal mass with restricted diffusion. In the left adnexal lodge, a 64x45 mm complex mass—hyperintense on T1-weighted images and hypointense on T2, consistent with an endometrioma—was observed, accompanied by an adjacent 21 mm irregular, thick-walled cystic component. Transvaginal ultrasound confirmed the adenomyotic uterus and a 53x53 mm left adnexal mass. Preoperative endometrial sampling reported endometrial polyp fragments. Given her severe symptoms and imaging findings, a TLH and left USO were planned.

Results

The laparoscopic procedure was completed in 128 minutes, with an estimated blood loss of 220mL. Despite the presence of pelvic adhesions from the prior laparotomy, optimal exposure and complete excision were achieved without any intraoperative complications. The patient had an uneventful recovery and was discharged on postoperative day 2. Final histopathological analysis confirmed Adenomyosis, and left ovarian endometrioma.

Conclusions

Total laparoscopic hysterectomy and adnexectomy can be safely and effectively performed in patients with complex adnexal masses, severe adenomyosis, and a history of previous open surgery. Thorough preoperative evaluation and meticulous laparoscopic technique are crucial for restoring the patient's quality of life while adhering to surgical safety principles.

https://player.vimeo.com/video/1191316681?autoplay=1

ESGE35-0239 - VP050
Video in ePoster

Unexpected High-Grade Serous Ovarian Carcinoma in a Presumed Benign Gynecologic Emergency

Mukadder Gök[1], Ömer Faruk Öz[1], Can Dinç[1], Selen Doğan[2], Nasuh Utku Doğan[2], İnanç Mendilcioğlu[3]
[1]Akdeniz University, Obstetrics and Gynaecology- TR-MIGS, Antalya, Türkiye
[2]Akdeniz University, Gynecologic Oncology- Obstetrics and Gynaecology- TR-MIGS, Antalya, Türkiye
[3]Akdeniz University, Maternal-Foetal Medicine- Obstetrics and Gynaecology- TR-MIGS, Antalya, Türkiye

Background

To present an incidental diagnosis of high-grade serous ovarian carcinoma identified during emergency laparoscopic surgery for bilateral adnexal torsion and hemorrhagic cyst rupture.

Methods

A 42-year-old G1P1 woman with a history of previous caesarean section and systemic lupus erythematosus presented with acute pelvic pain. Physical examination revealed abdominal tenderness and guarding. Transvaginal ultrasonography demonstrated a 6 cm hemorrhagic cyst in the right ovary, a 4 cm simple cyst in the left ovary, absent Doppler flow in both ovaries, and free fluid in the Douglas pouch. Emergency diagnostic laparoscopy was performed for suspected bilateral adnexal torsion and hemorrhagic cyst rupture. Intraoperatively, bilateral adnexal torsion and hemorrhagic cyst rupture were confirmed. Right oophorectomy and bilateral salpingectomy were performed. Suspicious peritoneal lesions identified on the pelvic peritoneum were excised for histopathological evaluation.

Results

No intraoperative complications occurred. The patient was discharged on postoperative day 2. Final histopathological examination revealed high-grade serous ovarian carcinoma involving both ovaries and the left tube, with carcinoma infiltration in the peritoneal lesion. The patient was subsequently referred to the gynecologic oncology department for further oncologic management.

Conclusions

High-grade serous ovarian carcinoma may be incidentally identified during emergency surgery performed for bilateral adnexal torsion and hemorrhagic cyst rupture. Careful intraoperative evaluation of suspicious peritoneal lesions and minimal tumor manipulation are essential for appropriate oncologic management.

https://player.vimeo.com/video/1191309417?autoplay=1

ESGE35-0254 - VP053
Video in ePoster

Robotic-assisted sentinel lymph node mapping in endometrial cancer: surgical landmarks and technical tips for identifying the true sentinel lymph node

Merve Didem Eşkin Tanriverdi[1,2], *Günsu Kimyon Cömert*[3], *Zelıha Fırat Cüylan*[2,3]
[1]*Ankara Bilkent City Hospital, Gynaecology and Obstetrics, Ankara, Türkiye*
[2]*The Turkish Platform for Minimally Invasive Gynecologic Surgery, Tp-MIGS, Ankara, Türkiye*
[3]*Ankara Bilkent City Hospital, Department of Gynecologic Oncology, Ankara, Türkiye*

Background

Sentinel lymph node (SLN) mapping has become an important component of surgical staging in endometrial cancer. However, identification of the true SLN may be challenging because the first fluorescent lymph node visualized under near-infrared imaging is not always the actual sentinel node. Knowledge of pelvic retroperitoneal anatomy, common lymphatic mapping pathways, and meticulous dissection techniques are essential to achieve accurate SLN detection and avoid false mapping.

Methods

A 49-year-old patient with grade 1 endometrioid endometrial carcinoma underwent robotic-assisted SLN biopsy, total hysterectomy, and bilateral salpingo-oophorectomy. Preoperative positron emission tomography-computed tomography demonstrated focal fluorodeoxyglucose uptake confined to the uterine cavity without distant metastasis. Cervical injection of 2 cc of 1.25 mg/mL ICG was performed at the 3 and 9 o'clock positions using superficial and deep injections. Bilateral retroperitoneal spaces were developed after transection of the round ligaments. The paravesical and pararectal spaces, ureters, external iliac vessels, obliterated umbilical arteries, obturator nerves, and lymphatic channels were identified under near-infrared fluorescence imaging. Lymphatic pathways were followed systematically to distinguish the true SLN from secondary fluorescent lymph nodes.

Results

Successful bilateral SLN mapping was achieved. On the left side, fluorescent lymphatic channels crossing the obliterated umbilical artery initially led to a fluorescent interiliac lymph node; however, continued dissection demonstrated the true SLN within the proximal obturator region along the upper paracervical pathway. On the right side, the first fluorescent lymph node identified in the interiliac region was similarly differentiated from the true SLN after further obturator dissection. Both SLNs were safely dissected with preservation of the obturator nerves and surrounding vascular structures. Key technical principles included proper cervical injection technique, early SLN mapping before extensive dissection, development of avascular retroperitoneal planes, identification of the obliterated umbilical artery, and meticulous tracking of fluorescent lymphatic trunks. Factors complicating mapping included visceral adiposity, increased vascularization, limited tissue penetration of near-infrared fluorescence, and bleeding obscuring lymphatic visualization.

Conclusions

Accurate SLN identification in endometrial cancer requires detailed knowledge of retroperitoneal anatomy and careful tracking of lymphatic pathways rather than removal of the first fluorescent lymph node encountered. Recognition of common mapping patterns and adherence to meticulous surgical technique may improve detection of the true SLN and reduce the risk of false mapping during robotic-assisted SLN biopsy.

https://player.vimeo.com/video/1191335729?autoplay=1

ESGE35-0260 - VP054
Video in ePoster

Laparoscopic management of isthmocele following caesarean scar ectopic pregnancy using transillumination technique

Chaima Mbarki[1], Ines Hfaiedh[1], Yasmine Chiba[1], Mizounmizoun Ben Amor[1], Wissal Jaafar[1], Mechaal Mourali[1]
[1]Bougatfa Teaching Hospital- Faculty of Medecine of Tunis- University Tunis El Manar, Gynaecology and Obstetrics departement- Professor Mechaal Mourali, Bizerta, Tunisia

Background

A caesarean scar defect, (isthmocele), is a complication of C-section delivery that is becoming more widely recognized. It is associated with abnormal uterine bleeding, pelvic pain, infertility, and an impaired quality of life. Minimally invasive approaches have become the standard of care for managing this condition. Identifying the defect intraoperatively is essential to ensure precise repair. Vaginal transillumination using a diagnostic hysteroscopic cold light is a simple, effective alternative technique that enhances visualization of the scar defect and guides surgical dissection.

Methods

We present the case of a 34-year-old woman (gravida 3 and a para 2) who has had two previous caesarean deliveries. She presented to the emergency department with abnormal uterine bleeding and a positive β-hCG test. A pelvic ultrasound revealed an ectopic pregnancy within the caesarean scar niche (empty gestational sac) at six weeks of amenorrhea. The patient was hemodynamically stable and was initially managed with uterine aspiration and methotrexate. There was a declining β-hCG trend, and the peak systolic velocity was 7 cm/s without bladder involvement. After β-hCG negativization and a seven-week interval, she developed a symptomatic isthmocele. Ultrasound showed residual myometrial thickness of 3 mm. After providing informed consent, she underwent laparoscopic repair of the defect. During the procedure, vaginal transillumination with a diagnostic hysteroscopic cold light was used to delineate the margins of the isthmocele and guide precise dissection and repair.

Results

The surgery was uneventful, requiring only a three-day hospital stay, and the symptoms resolved completely. There were no short- or mid-term complications reported at the 6 month follow-up.

Conclusions

Laparoscopic repair of an isthmocele using vaginal transillumination with a hysteroscopic cold light source is a simple, effective, and reproducible technique. It improves the identification of the defect during surgery, enabling precise dissection and customized repair without the need for fluorescent agents. This approach may improve surgical safety and outcomes for caesarean scar defects.

https://player.vimeo.com/video/1191346345?autoplay=1

ESGE35-0267 - VP055
Video in ePoster

From Pelvic Pathology to Precision: Laparoscopic Glimpses of Hydrosalpinx & Appendiceal Adhesions

Preethi Ann Jacob[1], *Justina Igwe*[1], *Dhanuson Dharmasena*[1], *Guldzhan Vorona*[1]
[1]*Whittington Hospital, Obstetrics and Gynaecology, London, United Kingdom*

Background

Hydrosalpinx is a recognised complication of pelvic inflammatory disease (PID). It is associated with chronic pelvic pain, infertility and adverse reproductive outcomes. Surgical treatment revolves around the removal of diseased tubo-ovarian structures while preserving ovarian function.

This case highlights the complexity of laparoscopic management of hydrosalpinx complicated by dense adhesions and appendiceal involvement, which required a multidisciplinary (MDT) approach.

Methods

A 32-year-old nulliparous woman presented with chronic right iliac fossa and pelvic pain. She had a history of PID complicated by bilateral tubo-ovarian abscess in 2023.

Initial imaging in 2023 demonstrated a large pelvic collection with unclear aetiology. Follow-up transvaginal ultrasound revealed bilateral tubo-ovarian abscess. She completed antibiotics; however, she did not attend follow-up imaging.

In 2025, fertility investigations revealed a right hydrosalpinx with a patent left tube. Diagnostic laparoscopy and right salpingectomy were performed, which revealed extensive adhesions involving the right ovaries, fallopian tube and appendix. Due to dense adhesions involving the appendix, a joint intraoperative decision with general surgeons was made to do an appendectomy in conjunction with the right salpingectomy.

Results

The procedure was completed as a day case with minimal blood loss and no bowel spillage. Recovery was uneventful. Appendix histology revealed chronic inflammation, fibrosis and a foreign body giant cell reaction, suggestive of previous intestinal perforation. No evidence of endometriosis present. Fallopian tube histology revealed calcification and a foreign body giant cell reaction. Ovarian tissue was preserved, and the left fallopian tube appeared normal.

Conclusions

This case illustrates the complex overlap of gynaecological and gastrointestinal pathology in chronic pelvic disease.

Laparoscopic salpingectomy can be performed while preserving ovarian reserve, even in the presence of dense adhesions.

Timely recognition of the atypical appearance of appendiceal involvement, multidisciplinary collaboration and follow-up imaging after PID are essential to optimise outcomes.

Consent was obtained from the patient for the publication.

https://player.vimeo.com/video/1191370233?autoplay=1

ESGE35-0270 - VP056
Video in ePoster

Laparoscopic Identification and Excision of Retroperitoneal Cystic Endometriosis: A Video Demonstration

Vasileios Sevas[1], Dimitrios Rafail Kalaitzopoulos[2], Emmanouil Andreou[3], Georgios Grigoriadis[4]
[1]Geneva University Hospitals and University of Geneva HUG, Obstetrics and Gynaecology, Genéve, Switzerland
[2]Department of Gynaecology and Obstetrics- Cantonal Hospital of Schaffhausen- Schaffhausen- Switzerland., Obstetrics and Gynaecology, Schaffhausen, Switzerland
[3]Laiko General hospital- Athens, Obstetrics and Gynaecology, Athens, Greece
[4]Papageorgiou General Hospital, Obstetrics and Gynaecology, Thessaloniki, Greece

Background

Objective: To raise awareness of retroperitoneal cystic endometriosis and demonstrate its laparoscopic identification and management.

Methods

Video demonstration of a laparoscopic surgical procedure:
A 31-year-old nulliparous woman presented with severe dysmenorrhea (VAS score: 9/10)., dyspareunia (VAS score: 9/10), and chronic pelvic pain (VAS score: 8/10). Pelvic MRI demonstrated bilateral ovarian endometriomas, the largest measuring approximately 5 cm on the right and 4 cm on the left, **#Enzian score**: O3L/O3R (bilateral ovarian endometriomas >3 cm), no evidence of deep infiltrating or retroperitoneal disease.

Results

Interventions: Laparoscopic excision of endometriosis with retroperitoneal dissection. During excision of a thickened left uterosacral ligament, a soft cystic structure was identified beneath the left ureter and hypogastric nerve fibers. Opening the lesion revealed serosanguineous fluid and drainage of this fluid revealed a deeper cyst containing characteristic chocolate-colored fluid. The retroperitoneal cyst was completely identified and excised, followed by bilateral ovarian cystectomy. The postoperative course was uneventful, and the patient was discharged on postoperative day 1. Histopathology confirmed the endometriotic origin of the specimens. At 3-month follow-up, imaging showed no recurrence, and the patient reported significant improvement in pain-related symptoms. Retroperitoneal cystic endometriosis is rarely visualized laparoscopically, and this video demonstrates identification and excision in real-time.

Conclusions

Retroperitoneal cystic endometriosis is a rare manifestation of endometriosis.[1,2,5] Lack of awareness may lead to misdiagnosis pre-operatively, as well as intra-operatively. Based on this case, one could argue for routinely opening retroperitoneal spaces in all cases of endometriosis. Although the impact of this location on symptoms remains unclear, thorough excision of all endometriotic lesions is indicated to optimize surgical outcomes. https://player.vimeo.com/video/1191381402?autoplay=1

ESGE35-0272 - VP057
Video in ePoster

Near-Infrared Navigation in Single-Port Robotics: Expanding the Role of ICG in Complex Gynaecological Surgery

Saima Farooq[1], *Amer Raza*[1]
[1]*Cromwell Hospital, Gynaecology, LONDON, United Kingdom*

Background

Indocyanine green (ICG) fluorescence imaging has emerged as a valuable adjunct in advanced minimally invasive gynaecological surgery, enabling enhanced visualisation of tissue perfusion and critical anatomical structures in real time. In complex robotic procedures, where distorted anatomy and advanced disease increase operative difficulty, fluorescence-guided surgery may improve intraoperative precision, anatomical orientation, and surgical safety.

Methods

This video presentation demonstrates the diverse applications of ICG fluorescence imaging within advanced single-port robotic gynaecological surgery through a curated operative series. The video highlights four principal applications. Firstly, fluorescence-assisted ureteric identification is demonstrated during complex retroperitoneal dissection for severe endometriosis, facilitating safer ureterolysis and preservation of surrounding structures. Secondly, intracavitary ICG instillation during robotic myomectomy is utilised to delineate the endometrial cavity and support precise fibroid dissection while maintaining uterine integrity. Thirdly, fluorescence angiography is employed following bowel surgery for deep infiltrating endometriosis to assess tissue vascularity and anastomotic perfusion in real time. Finally, selective dye testing is demonstrated to evaluate tissue integrity and confirm adequate perfusion where clinically indicated.

Results

Across all demonstrated procedures, ICG fluorescence provided dynamic visual enhancement that improved anatomical definition and facilitated tissue-preserving dissection. The technology supported safer retroperitoneal surgery, improved confidence during complex robotic suturing and bowel surgery, and enabled real-time assessment of tissue viability. Integration of fluorescence guidance enhanced operative precision while maintaining the advantages of a single-port robotic approach.

Conclusions

Multimodal integration of ICG fluorescence within single-port robotic gynaecological surgery represents an important advancement in precision-guided minimally invasive surgery. Real-time fluorescence imaging enhances surgical orientation, supports safer dissection in advanced pathology, and refines intraoperative decision-making. This approach demonstrates the expanding role of image-

guided robotic surgery in achieving safer, more tailored, and technologically advanced management of complex gynaecological disease. https://player.vimeo.com/video/1199572452?autoplay=1

ESGE35-0305 - VP060
Video in ePoster

Unusual morphology of caesarean scar niche

Wojciech Zajdel[1], *Michał Pomorski*[2]
[1]*University Hospital in Wrocław, Obstetrics and Gynaecology, Wroclaw, Poland*
[2]*Wrocław Medical University, Obstetrics and Gynaecology, Wrocław, Poland*

Background

Prolonged postmenstrual spotting is a recognized long-term effect of caesarean section in a subset of women. This symptom is frequently associated with the presence of a caesarean scar defect (CSD). Each CSD may vary in size, volume, RMT and location on uterine wall.
In this case CSD has unusual morphology, in its caudal part fragments of the anterior uterine wall can be seen separated from each other. All the way to the lower part of the anterior labia of the cervix, posing an operative challenge.

Methods

To carry out a procedure we used 26Fr Storz Resectoscope. First the great volume of retaining menstrual blood is flushed, than the uterine cavity is inspected for any other anomalies. Then the resection process starts, first the vast caudal part of the niche is resected. Then the lesser cephalad part is resected allowing better communication between cavity and the CSD. Final part is coagulation of the vessels in the niche.

Results

3 months after the procedure patient reported complete disappearance of menstrual spotting.

Conclusions

Evidence indicates that hysteroscopic resection of the niche is effective in reducing the duration of postmenstrual spotting, endoscopist needs to be well aware of sometimes unusual morphology of CSD in order to perform its hysteroscopic resection correctly.

https://player.vimeo.com/video/1191451902?autoplay=1

ESGE35-0320 - VP062
Video in ePoster

Radical multidisciplinary laparoscopic excision of deep infiltrating endometriosis involving the bladder and rectosigmoid colon

Juan Carlos Ramirez Mejia[1], *Carlos Gustavo Trujillo*[2], *Karen Daniela Cepeda*[1]
[1]*Hospital Universitario Fundacion Santa Fe de Bogota,*
Gynaecology- Obstetrics and Human Reproduction, Bogota, Colombia
[2]*Hospital Universitario Fundacion Santa Fe de Bogota, Urology, Bogota, Colombia*

Background

Deep infiltrating endometriosis involving the bladder and rectosigmoid colon is a severe manifestation of endometriosis associated with chronic pelvic pain, urinary symptoms, and significant impairment in quality of life. Surgical management is technically challenging because complete excision often requires a multidisciplinary minimally invasive approach. We present the laparoscopic management of advanced multiorgan deep infiltrating endometriosis with transmural bladder involvement.

Methods

A 43-year-old nulliparous woman presented with severe dysmenorrhea, dyschezia, menstrual hematuria, and chronic pelvic pain. Contrast-enhanced magnetic resonance imaging demonstrated severe adenomyosis, posterior compartment endometriosis involving the rectosigmoid colon with infiltration of more than 40% of the serosa and muscularis propria, and a transmural bladder lesion measuring approximately 20 × 18 mm. Preoperative cystoscopy confirmed a violaceous raised lesion consistent with bladder endometriosis. The patient underwent laparoscopic surgery after complete bowel preparation. Repeat cystoscopy with bilateral ureteral catheterization was performed to delineate the extent of bladder resection. Intraoperatively, severe pelvic adhesions and fibrosis between the uterus and bladder were identified. Bladder transillumination with saline filling facilitated lesion identification. Complete laparoscopic excision of the bladder lesion was achieved through full-thickness bladder resection using ultrasonic energy, followed by single-layer bladder closure with continuous barbed suture and additional reinforcement with polydioxanone suture. Hysterectomy, bilateral salpingectomy, ovarian cystectomy, and rectosigmoid segmental resection were also performed.

Results

Complete excision of all visible endometriotic lesions with disease-free margins was successfully achieved. Bladder integrity was preserved after reconstruction, with no intraoperative complications identified. Ureteral catheters were removed 24 hours postoperatively, and bladder catheterization was maintained for 10 days.

Conclusions

A multidisciplinary laparoscopic approach for severe deep infiltrating endometriosis with bladder and bowel involvement is feasible and allows safe complete excision with satisfactory urinary tract

preservation. Careful surgical planning and meticulous reconstruction are essential to optimize outcomes.

https://player.vimeo.com/video/1191479982?autoplay=1

ESGE35-0322 - VP063
Video in ePoster

A New View of Apical Support: Paravaginal V-NOTES Sacrospinous Fixation

Merve Menteşe[1], Emin Erhan Dönmez[2], Yağmur Solak[2], Betül Öztürk[2]
[1]Istanbul Training and Research Hospital, Obstetrics and Gynaecology, İstanbul, Türkiye
[2]Istanbul Training and Research Hospital, Obstetrics and Gynaecology, Istanbul, Türkiye

Background

Pelvic organ prolapse (POP) is a common gynecological condition that significantly affects quality of life in women. Sacrospinous fixation (SSF) is a well-established vaginal procedure for the surgical management of apical prolapse. Recently, vaginal natural orifice transluminal endoscopic surgery (V-NOTES) has gained increasing attention because of its minimally invasive advantages and enhanced visualization. We present a case of Grade 4 uterine prolapse treated with V-NOTES sacrospinous fixation using a paravaginal approach.

Methods

A 68-year-old postmenopausal woman presented with pelvic pressure and urinary incontinence. Her history included previous cystocele surgery, hypertension, and prediabetes. Gynecological examination demonstrated Grade 4 uterine prolapse with occult stress urinary incontinence. Vaginal hysterectomy, bilateral salpingo-oophorectomy, sacrospinous fixation, anterior-posterior colporrhaphy, perineoplasty, tension-free vaginal tape (TVT), and cystoscopy were planned.

Following vaginal hysterectomy, hydrodissection of the posterior vaginal wall was performed, and paravaginal dissection was initiated. The V-NOTES port was inserted into the paravaginal space, and CO_2 insufflation was established at 12–15 mmHg. Under endoscopic visualization, the rectal space was developed and the sacrospinous ligament was identified. To avoid pudendal neurovascular injury, sutures were placed at least 2 cm medial to the ischial spine. Using an endoscopic needle holder, 1:0 Prolene sutures were passed full thickness through the sacrospinous ligament. After removal of the V-NOTES port, the vaginal apex was attached to the sacrospinous sutures using pulley sutures, allowing gradual and controlled tension adjustment during apical fixation.

Results

The procedure was completed successfully without intraoperative complications. Direct endoscopic visualization enabled safe identification of the sacrospinous ligament and preservation of adjacent anatomical structures. Adequate apical support and anatomical alignment were achieved. Concomitant anterior-posterior colporrhaphy, TVT, and perineoplasty were performed uneventfully. Cystoscopic evaluation confirmed intact bladder and urethral integrity.

Conclusions

Paravaginal V-NOTES sacrospinous fixation appears to be a safe and effective minimally invasive option for the treatment of advanced apical prolapse. Enhanced visualization of the sacrospinous ligament may improve surgical precision and reduce the risk of rectal and pudendal neurovascular

injury. Further prospective studies with larger patient populations are required to evaluate long-term outcomes and broader applicability of this technique.

https://player.vimeo.com/video/1191486635?autoplay=1

ESGE35-0327 - VP064
Video in ePoster

Stepwise hysteroscopic myomectomy for a submucosal fibroid

Yasmine Chiba[1], Mili Youssef[1], Hfaiedh Ines[1], Rjiba Chayma[1], Bouassida Mehdi[1], Mourali Mechaal[1]
[1]Habib Bougatfa University Hospital in Bizerte, Department of Obstetrics and Gynaecology, Bizerte, Tunisia

Background

Objectives

To demonstrate a standardized hysteroscopic myomectomy technique for the management of a submucosal fibroid while preserving uterine integrity and maintaining optimal visualization throughout the procedure.

Methods

A patient presenting with abnormal uterine bleeding was diagnosed with a submucosal FIGO type 2 fibroid. Operative hysteroscopy was performed using a resectoscopic approach under continuous glycine irrigation fluid. The myoma was progressively resected in a stepwise fashion until complete removal, with resection consistently performed from posterior to anterior. Sequential removal of fibroid fragments allowed gradual exposure of the implantation base while preserving the surrounding myometrium and minimizing thermal injury. Final hysteroscopic inspection was performed to evaluate the uterine cavity.

Results

Complete hysteroscopic excision of the fibroid was achieved without intraoperative complications. Final inspection confirmed a regular uterine cavity with intact bilateral tubal ostia and no residual lesion. No uterine perforation, excessive bleeding, or fluid overload occurred during the procedure. The postoperative course was uneventful, and the patient was discharged without complications.

Conclusions

Stepwise hysteroscopic myomectomy is a safe and reproducible technique for the treatment of large submucosal fibroids. Progressive resection with a posterior-to-anterior approach improves visualization, facilitates controlled excision, and helps preserve uterine integrity while achieving complete removal.

https://player.vimeo.com/video/1191490430?autoplay=1

ESGE35-0352 - VP066
Video in ePoster

Laparoscopic retrieval of a displaced copper intrauterine device in a patient with three prior caesarean sections: a minimally invasive approach

Can Dinç[1], Yavuz Yılmaz[1], Ömer Faruk Öz[1], Selen Doğan[2], Nasuh Utku Doğan[1], İbrahim İnanç Mendilcioğlu[3]
[1]Akdeniz University, Obstetrics and Gynaecology- TR-MIGS, Antalya, Türkiye
[2]Akdeniz University, Gynecologic Oncology- Obstetrics and Gynaecology- TR-MIGS, Antalya, Türkiye
[3]Akdeniz University, Maternal-Foetal Medicine- Obstetrics and Gynaecology- TR-MIGS, Antalya, Türkiye

Background

To demonstrate the safe and effective laparoscopic retrieval of a displaced copper intrauterine device (IUD) in a high-risk patient with three prior caesarean sections, and to highlight the critical importance of post-insertion follow-up imaging in the timely detection of device migration.

Methods

A 26-year-old woman (gravida 3, para 3, all deliveries by caesarean section) was referred to our centre after presenting with absent IUD strings on speculum examination. A copper IUD had been inserted for contraceptive purposes three months prior at an external facility; no post-insertion follow-up imaging had been performed. Transvaginal ultrasound confirmed the device was absent from the uterine cavity. Plain abdominal X-ray demonstrated the IUD projected in the midline at the level of the aortic bifurcation, indicating intra-abdominal migration. Diagnostic laparoscopy was performed under general anaesthesia via a standard three-port technique. The abdominal cavity was systematically explored to localise and retrieve the device.

Results

Intraoperatively, the IUD was identified within the mesocolon of the ascending colon, embedded in the mesenteric fat without evidence of visceral perforation or significant adhesion formation. Complete laparoscopic retrieval was achieved without conversion to laparotomy or bowel injury.

Intraoperative general surgery consultation was obtained following device retrieval. The consulting surgical team concurred that no colonic injury or bowel compromise was present, and a conservative postoperative management plan was jointly agreed upon. The patient was monitored accordingly throughout the postoperative period.

The patient was discharged on postoperative day one in good clinical condition. No early or late postoperative complications were recorded.

Conclusions

Laparoscopy is a safe, efficient, and definitive approach for the retrieval of a displaced intra-abdominal IUD, even in patients with a history of multiple caesarean sections. The discordance between the radiological projection (aortic bifurcation level on plain X-ray) and the true

intraoperative location (ascending colon mesocolon) underscores the limitations of plain imaging and the indispensable role of laparoscopic exploration. Intraoperative multidisciplinary consultation with general surgery is recommended when the device is found in proximity to bowel structures, ensuring comprehensive assessment and safe postoperative follow-up. This case reinforces the necessity of routine post-insertion surveillance to enable early identification of device displacement and prevent delayed complications.

https://player.vimeo.com/video/1191525163?autoplay=1

ESGE35-0354 - VP067
Video in ePoster

Laparoscopic bilateral salpingo-oophorectomy for a 16cm ovarian cyst in the post-hysterectomy pelvis

Mickey Buckingham[1], Mansi Tiwari[1]
[1]University Hospital Lewisham, Women's Health, London, United Kingdom

Background

To demonstrate a systematic laparoscopic approach for the bilateral removal of the adnexa in a patient with a 16cm ovarian cyst and a distorted, post-hysterectomy pelvis. The video focuses on the restoration of anatomy and the identification of safe surgical planes where traditional uterine landmarks are absent and extensive adhesions are present.

Methods

A 46-year-old female, status-post vaginal hysterectomy, presented with acute pelvic pain and a 16cm adnexal mass. The bilateral salpingo-oophorectomy (BSO) focused on three critical surgical interfaces:

15. The Pelvic Sidewall: A 'lateral-to-medial' approach was adopted. The retroperitoneum was opened at the pelvic brim to allow for early identification of the ureters. The infundibulo-pelvic ligaments were skeletonised and ligated, and the cysts were mobilised medially from the sidewalls.
16. The Bladder: The vesicovaginal space was developed via sharp dissection to mobilise the bladder off the vaginal vault and the anterior cyst capsule. This ensured bladder integrity despite the absence of a uterine manipulator.
17. The Bowel: The cyst was densely adherent to the rectum and sigmoid. Traction-countertraction was employed to identify the avascular plane, permitting dissection to avoid injury to the bowel serosa.

Results

Successful laparoscopic BSO was achieved with complete adhesiolysis. Despite extensive adhesions and distorted surgical planes, there were no visceral or vascular injuries. The 16cm cyst was drained in a controlled manner and both adnexa were removed via an endobag through a 10mm umbilical port. Histopathology confirmed a benign mucinous cystadenofibroma. The patient was discharged on postoperative day one.

Conclusions

Surgical management of large adnexal masses in a post-hysterectomy setting requires meticulous dissection. The absence of a uterus necessitates early retroperitoneal access and reliance on the pelvic brim and vaginal vault as primary landmarks. Systematic isolation of these planes is mandatory to mitigate iatrogenic risks in complex benign gynaecology.
https://player.vimeo.com/video/1191526478?autoplay=1

ESGE35-0399 - VP069
Video in ePoster

Laparoscopic pectopexy for vaginal vault prolapse in a previously hysterectomised patient: management of incidental incisional hernia and dense adhesions

Yavuz Yilmaz[1], Ömer Faruk Öz[1], Can Dinç[1], Selen Doğan[2], Nasuh Utku Doğan[1], Murat Özekinci[3]
[1]Akdeniz University, Obstetrics and Gynaecology- TR-MIGS, Antalya, Türkiye
[2]Akdeniz University, Gynecologic Oncology- Obstetrics and Gynaecology- TR-MIGS, Antalya, Türkiye
[3]Akdeniz University, Reproductive Endocrinology and Infertility- Obstetrics and Gynaecology- TR-MIGS, Antalya, Türkiye

Background

To demonstrate laparoscopic pectopexy for vaginal vault prolapse in a patient with a complex abdominal history, and to describe the intraoperative management of incidental incisional hernia with bowel content — including a simple external compression manoeuvre to facilitate safe bowel reduction — and systematic adhesiolysis in a heavily scarred abdominal field.

Methods

A 66-year-old woman (gravida 3, para 3, all vaginal deliveries) presented with vaginal vault prolapse and urinary voiding dysfunction. She had undergone total abdominal hysterectomy nine years prior and total abdominal rectoplasty four years prior. Known comorbidity: type 2 diabetes mellitus.

Laparoscopy was initiated with a supraumbilical 10 mm camera port and bilateral 5 mm operating ports. An infraumbilical incisional hernia containing herniated bowel loops was identified on entry. Dense post-hysterectomy adhesions further limited visualisation and instrument access; an additional 10 mm suprapubic port was placed to optimise triangulation and improve visualisation of the operative field.

To facilitate safe reduction of the herniated bowel, gentle external manual compression was applied over the hernia defect from outside the abdominal wall, allowing the bowel loops to reduce spontaneously under direct laparoscopic vision. This simple manoeuvre enabled adhesiolysis to proceed safely with optimal exposure, and the hernia defect was clearly delineated thereafter.

The vesicovaginal space was then developed, bilateral paravesical spaces entered along the round ligaments, and the Cooper (iliopectineal) ligaments exposed. The anterior vaginal vault was reinforced with a braided polyester suture and fixed bilaterally to the Cooper ligaments using titanium helical tackers. The peritoneum was reperitonealised.

Results

The procedure was completed without conversion or intraoperative complications. Bowel reduction was achieved atraumatically using the external compression technique without requiring additional instrumentation.

Intraoperative general surgery consultation was obtained; elective hernia repair was recommended and planned. The patient was monitored postoperatively with this finding taken into account.

The patient was discharged on postoperative day one. Vaginal vault support was restored and voiding dysfunction resolved at follow-up.

Conclusions

Laparoscopic pectopexy is feasible and safe in patients with dense adhesions and prior multiple abdominal surgeries. External manual compression of a hernial defect is a simple, effective, and atraumatic adjunct to facilitate bowel reduction under direct laparoscopic vision, avoiding the need for additional instrumentation. Placement of a supplementary suprapubic port provides critical triangulation when standard port configuration is insufficient due to adhesions or anatomical distortion. Multidisciplinary intraoperative consultation ensures comprehensive management of incidental findings without adding operative risk.

Written informed consent was obtained from the patient for publication of clinical images included in this abstract and the accompanying video presentation.

https://player.vimeo.com/video/1191597636?autoplay=1

ESGE35-0414 - VP070
Video in ePoster

Laparoscopic management of a severely adhesive caesarean scar pregnancy

Can Dinç[1], Ömer Faruk Öz[1], Selen Doğan[2], Nasuh Utku Doğan[1], Murat Özekinci[3], İbrahim İnanç Mendilcioğlu[4]
[1]Akdeniz University, Obstetrics and Gynaecology- TR-MIGS, Antalya, Türkiye
[2]Akdeniz University, Gynecologic Oncology- Obstetrics and Gynaecology- TR-MIGS, Antalya, Türkiye
[3]Akdeniz University, Reproductive Endocrinology and Infertility- Obstetrics and Gynaecology- TR-MIGS, Antalya, Türkiye
[4]Akdeniz University, Maternal-Foetal Medicine- Obstetrics and Gynaecology- TR-MIGS, Antalya, Türkiye

Background

To demonstrate laparoscopic excision of a type 2 caesarean scar pregnancy (CSP) with critically reduced residual myometrial thickness (RMT) and double-layer uterine repair as a fertility-preserving minimally invasive approach, and to describe safe surgical management in the context of severe lower uterine segment adhesions.

Methods

A 36-year-old woman (gravida 4, para 3, three prior caesarean sections) presented at seven weeks and five days of gestation. Transvaginal ultrasound confirmed fetal cardiac activity and an implantation site within the caesarean scar niche, with a residual myometrial thickness of 2.1 mm, consistent with type 2 CSP. Serum beta-human chorionic gonadotropin was 49,350 IU/L, with an inadequate rise over 48 hours to 47,170 IU/L. Given the critically reduced RMT and niche-type implantation, laparoscopic excision and uterine repair were planned. At laparoscopy, severe adhesions were identified between the lower uterine segment and the bladder, necessitating systematic adhesiolysis and careful stepwise dissection to access the scar line.

Following adhesiolysis, the gestational tissue within the scar niche was excised under direct laparoscopic vision. The lower uterine segment defect was then repaired in two layers using barbed absorbable sutures, restoring myometrial continuity and structural integrity of the uterine wall.

Haemostasis was confirmed and the procedure was completed without conversion to laparotomy.

Results

Complete excision of gestational tissue was achieved with secure double-layer myometrial closure.

The postoperative course was uneventful. Serial serum beta-human chorionic gonadotropin levels declined appropriately. No haemorrhagic or infectious complications were observed. Uterine integrity was preserved, maintaining the patient's future fertility potential.

Conclusions

Laparoscopic excision with double-layer uterine repair is a feasible and effective fertility-preserving approach for type 2 caesarean scar pregnancy, even in the presence of severe adhesions and critically

reduced residual myometrial thickness. Systematic adhesiolysis is essential to achieve adequate exposure of the scar line. Double-layer closure restores myometrial integrity and may reduce the risk of uterine rupture in subsequent pregnancies. This case supports the role of minimally invasive surgery as the preferred approach in selected CSP cases when expertise is available.

https://player.vimeo.com/video/1191613257?autoplay=1

ESGE35-0421 - VP071
Video in ePoster

Laparoscopic bilateral lateral suspension for total vaginal cuff prolapse in a hysterectomised patient with prior pelvic reconstructive surgery

Can Dinç[1], Yavuz Yılmaz[1], Ömer Faruk Öz[1], Selen Doğan[2], Nasuh Utku Doğan[1], İbrahim İnanç Mendilcioğlu[3]
[1]Akdeniz University, Obstetrics and Gynaecology- TR-MIGS, Antalya, Türkiye
[2]Akdeniz University, Gynecologic Oncology- Obstetrics and Gynaecology- TR-MIGS, Antalya, Türkiye
[3]Akdeniz University, Maternal-Foetal Medicine- Obstetrics and Gynaecology- TR-MIGS, Antalya, Türkiye

Background

To demonstrate laparoscopic bilateral lateral suspension as an effective surgical option for total vaginal cuff prolapse in a previously hysterectomised elderly patient with a history of prior pelvic reconstructive surgery, and to report the operative technique, intraoperative findings, and short-term functional outcomes.

Methods

A 69-year-old postmenopausal woman (gravida 3, para 3, all vaginal deliveries) presented with a mass protruding into the vagina and progressive pelvic pressure. Her surgical history included total abdominal hysterectomy followed by pelvic reconstructive surgery for cystocele and rectocele. Clinical examination confirmed total vaginal cuff prolapse (POP-Q stage III–IV) with recurrent grade 2 cystocele and mild stress urinary incontinence. Conservative management had been previously attempted without sustained benefit. Laparoscopic bilateral lateral suspension was performed under general anaesthesia. A standard three-port approach was employed.

Bilateral lateral suspension was achieved by passing permanent sutures through the full thickness of the anterior vaginal wall at the level of the vault bilaterally, and anchoring them to the lateral abdominal wall at the level of the anterior superior iliac spine, creating a lateral tension vector to restore vaginal vault support. Post-hysterectomy adhesions were encountered and systematically divided to allow adequate vault mobilisation prior to suture placement.

No mesh was employed. The procedure was completed without repositioning.

Results

The procedure was completed without intraoperative or postoperative complications.

At three-month follow-up, complete anatomical restoration of the vaginal vault was confirmed. The patient reported resolution of prolapse symptoms and significant improvement in quality of life. No de novo voiding dysfunction or mesh-related complications were observed.

Conclusions

Laparoscopic bilateral lateral suspension is a feasible, mesh-free surgical option for vaginal vault prolapse in previously hysterectomised patients, including those with prior pelvic reconstructive

surgery. The technique provides effective apical support through a lateral tension vector without the need for presacral dissection or mesh implantation. It may represent a particularly suitable approach in elderly patients or those in whom mesh use is contraindicated or undesirable. Further prospective data are needed to establish long-term efficacy.

https://player.vimeo.com/video/1191618390?autoplay=1

ESGE35-0424 - VP072
Video in ePoster

Feasibility of single port adnexectomy during second trimester of pregnancy

Carmela Quatrale[1], Federica Ottolini[1], Leonardo Nelva Stellio[1], Luca Calzolari[1], Federico Spelzini[1]
[1]ASST Grande Ospedale Metropolitano Niguarda, Gynaecology and Obstetrics, Milan, Italy

Background

Minimally invasive approaches are considered safe when surgery is needed in pregnant women. This case shows the feasibility of single port (SP) robotic surgery during the second semester of pregnancy

Methods

A 36 years old first-time pregnant woman was diagnosed with a 10 cm left ovarian cyst during routine second trimester ultrasound examination. Adnexa were normal during previous scans. The cyst was multilocular solid with three papillary projections. Ultrasound features argued for borderline ovarian tumor. Hence, the patient was candidate for surgery. Betamethasone for fetal lung maturation was administered at 23 weeks of pregnancy. The patient underwent SP left adnexectomy at 23 weeks and 3 days of pregnancy. A single 2.7 cm incision was made in the epigastrium. The patient could not tolerate >20 degrees Trendelenburg position due to hypotension, so it was reduced to 15 degrees. In order to gain correct vision of the left ovary, patient was rotated towards the right. Low pressure pneumoperitoneum of 8 mmHg was used. Due to difficult vision and dimension of the uterus, a retrograde adnexectomy was performed, starting from the uterine ovarian ligament towards the infundibulopelvic ligament as opposed to standard technique. The adnexa was safely extracted inside an endobag.

Results

Surgery was performed with low pressure pneumoperitoneum through a single port access with 15 degrees of Trendelenburg. Operative time was 80 minutes and blood loss was negligible. There were no complications. Patient was discharged four days after surgery. First medical check two weeks after surgery was normal. Final histology was mature ovarian teratoma.

Conclusions

This case shows feasibility and safety of SP robotic surgery during the second semester of pregnancy. Adjustments were needed in patient position to avoid hypotension and venous compression due to uterus size. SP robotic surgery appears to be a versatile tool, simplifying the use of minimally invasive approach during second trimester.

https://player.vimeo.com/video/1191621281?autoplay=1

ESGE35-0429 - VP073
Video in ePoster

Complete uterovaginal septum: Hysteroscopic surgical approach

Ece Aksakal[1], Irem Usta Korkut[1], Bulent Urman[1]
[1]American Hospital, Obstetrics and Gynaecology, Istanbul, Türkiye

Background

Complete vaginal septum is a rare Müllerian anomaly resulting from incomplete fusion or canalization of the müllerian ducts. It is commonly associated with complex uterine malformations, particularly septate uterus, uterus didelphys, or duplicated cervix. The exact incidence is unknown due to its rarity, but Müllerian anomalies overall are estimated to occur in approximately 4–7% of women, while complete longitudinal vaginal septum represents only a small subset of these anomalies.

Methods

A 34-year-old woman with otherwise unexplained infertility was referred for evaluation and management of a complete uterine septum. Preoperative gynecologic assessment demonstrated a uterine septum associated with a double cervix and a longitudinal vaginal septum.

After careful counselling, hysteroscopic metroplasty and incision of the vaginal septum was planned. Initially, the longitudinal vaginal septum was incised using bipolar energy (POWERSEAL, Olympus, Germany). Subsequently, the two cervical canals were unified. Uterine sounds were inserted into the uterine cavities to facilitate anatomical orientation and guidance during the procedure.

A bipolar hysteroscope was then introduced into the right uterine cavity. The complete uterine septum extending throughout the cavity was identified and progressively incised from right to left using bipolar energy. Septal resection was continued carefully up to the level of both tubal ostia in order to achieve complete unification of the uterine cavity. Hemostasis was achieved with selective bipolar coagulation of bleeding sites. At the conclusion of the procedure, hyaluronic acid gel (Hyalobarrier®) was applied into to the cavity to reduce postoperative adhesion formation.

The operation was completed without complications. Postoperatively, the patient was prescribed estrogen therapy to support endometrial healing.

Results

Treatment is primarily surgical and depends on symptoms, reproductive goals, and associated anomalies. Symptomatic patients may present with dyspareunia, dysmenorrhea, infertility, or obstructed menstrual flow. Surgical management typically consists of complete excision of the vaginal septum under direct visualization, with careful preservation of surrounding structures.

Conclusions

When associated uterine anomalies are present, hysteroscopic correction may be performed simultaneously. Surgical treatment generally provides good anatomical, reproductive, and symptomatic outcomes.

https://player.vimeo.com/video/1191624256?autoplay=1

ESGE35-0435 - VP075
Video in ePoster

A Diagnostic Dilemma of a Uterine Mass with Suspicious Imaging Features: Laparoscopic Myomectomy of a Degenerated Leiomyom

Yeter Gizem Çevik[1], Can Dinç[1], Ömer Faruk Öz[1], Selen Doğan[2], Nasuh Utku Doğan[1], İbrahim İnanç Mendilcioğlu[3]
[1]Akdeniz University, Obstetrics and Gynaecology- TR-MIGS, Antalya, Türkiye
[2]Akdeniz University, Gynecologic Oncology- Obstetrics and Gynaecology- TR-MIGS, Antalya, Türkiye
[3]Akdeniz University, Maternal-Foetal Medicine- Obstetrics and Gynaecology- TR-MIGS, Antalya, Türkiye

Background

To report a case of a symptomatic uterine mass with radiological features suspicious for atypical or malignant transformation, and to highlight the role of minimally invasive surgery in the diagnosis and treatment of complex myomas.

Methods

A 35-year-old gravida 0 woman presented with abdominal distension, pelvic pain, and urinary frequency. Transvaginal ultrasonography revealed an anteverted uterus with a 10 mm trilaminar endometrium and a 71 × 46 mm heterogeneous cystic-solid lesion in the right adnexal region, initially suggestive of a FIGO type 6–7 leiomyoma versus a complex adnexal mass. The right ovary was not clearly visualized, while the left ovary appeared normal.

Pelvic magnetic resonance imaging demonstrated a left-deviated uterus and a 6.5 × 4.5 × 5 cm well-circumscribed uterine-adjacent mass with heterogeneous T2 hyperintensity, diffusion restriction, and non-enhancing components, raising suspicion for an malign or miksoid degenerated leiomyoma.

Tumor markers and LDH were within normal limits.

Results

The patient underwent laparoscopic myomectomy after informed consent. The total operative time was 1.5 hours. Intraoperatively, a 6 cm type 7 myoma originating from the posterior right uterine corpus and extending toward the right adnexa was identified. Additionally, two smaller (approximately 1 cm) subserosal myomas were noted on the posterior uterine wall and fundus.

All myomas were excised using advanced bipolar energy . The largest specimen was retrieved via extracorporeal morcellation within a specimen retrieval bag. while the smal myomas were removed through trocar sites. Bilateral ureteric peristalsis was confirmed, and hemostasis was achieved. The procedure was completed without complications. The postoperative course was uneventful, and the patient was discharged on postoperative day 2. Final histopathological examination confirmed a degenerative leiomyoma.

Conclusions

Degenerated uterine leiomyomas may present with atypical imaging features mimicking malignant transformation, even in the presence of normal tumor markers. This case emphasizes the importance of correlating radiological findings with intraoperative assessment and histopathology. Laparoscopic myomectomy offers a safe and effective minimally invasive strategy, providing both diagnostic and therapeutic management, with the added benefit of fertility preservation.

https://player.vimeo.com/video/1191628324?autoplay=1

ESGE35-0447 - VP076
Video in ePoster

Hysteroscopically Guided Total Laparoscopic Isthmocele Repair: A Step by Step Surgical Technique

Anıl Erturk[1], *Gizem Yilmaz Senol*[2]
[1]*Cerrahpasa Faculty of Medicine, Department of Obstetrics and Gynaecology, Istanbul, Türkiye*
[2]*Cerrahpasa Faculty of Medicine, Department of Obstetrics and Gynaecology, Istanbul, Türkiye*

Background

Isthmocele, also referred to as caesarean scar defect, is a recognized late complication of caesarean delivery and may present with postmenstrual spotting, pelvic pain, and impaired quality of life. Surgical management is indicated in symptomatic patients, particularly when the defect is clearly identified on imaging. We aimed to demonstrate the surgical steps and clinical outcome of hysteroscopy-assisted laparoscopic isthmocele repair.

Methods

A symptomatic patient with a history of two previous caesarean deliveries presented with persistent postmenstrual spotting and intermenstrual bleeding. Transvaginal ultrasonography revealed an isthmocele pouch measuring 7 mm in depth at the anterior lower uterine segment. During surgery, the vesicouterine peritoneum was initially dissected, and the bladder was mobilized to expose the anterior uterine wall. The margins of the defect were then precisely identified using hysteroscopic transillumination. Under laparoscopic guidance, the fibrotic isthmocele tissue was completely excised. Following complete removal of the defect, the myometrial edges were reconstructed with primary suturing, achieving anatomical restoration of the uterine wall.

Results

The procedure was completed successfully without intraoperative or postoperative complications. Follow-up evaluations at 3 and 6 months demonstrated complete resolution of the patient's symptoms, with no recurrent postmenstrual spotting or additional complaints.

Conclusions

Hysteroscopy-assisted laparoscopic repair represents a safe and effective minimally invasive approach for the treatment of symptomatic Isthmocele. Combined hysteroscopic visualization facilitates accurate localization of the defect, enables complete excision of fibrotic tissue, and supports optimal uterine reconstruction with favourable short-term clinical outcomes.

https://player.vimeo.com/video/1191636518?autoplay=1

ESGE35-0457 - VP077
Video in ePoster

Laparoscopic Adhesiolysis and Salpingectomy for Deep Pelvic Endometriosis

Elif Cetinkaya[1], *Ibrahim Yalcin*[1], *Oguz Arslan*[1]
[1]*Dokuz Eylul University, Department of Obstetrics and Gynaecology, Izmir, Türkiye*

Background

Surgical management of deep pelvic endometriosis in patients with a history of total hysterectomy requires advanced laparoscopic techniques due to extensive post-operative adhesions. This case aims to demonstrate the systematic laparoscopic approach for managing dense omental and bowel adhesions involving the colonic mesentery and pelvic sidewalls in a post-hysterectomy setting.

Methods

A female patient with a history of hysterectomy presented with chronic pelvic pain. Laparoscopic surgery was performed using a four-trocar technique. Following a 10 mm umbilical incision, pneumoperitoneum was established with a Veress needle. Intraoperative findings showed dense omental adhesions to the anterior abdominal wall. A systematic adhesiolysis was performed using a bipolar vessel sealer (LigaSure™). The sigmoid colon was found to be densely adherent to the left pelvic sidewall and the ovary. Sharp and blunt dissection were utilized to mobilize the adnexa and restore pelvic anatomy. Bilateral salpingectomy was performed. During sigmoid colon mobilization, a superficial serosal injury was identified and primarily repaired laparoscopically with 3.0 Vicryl sutures. Excision of the endometriotic lesion on the colonic mesentery and an omental biopsy were completed.

Results

The procedure was successfully completed laparoscopically in 120 minutes. Minimal blood loss was recorded, and both ureters were identified and preserved throughout the dissection. The patient had an uneventful postoperative course and reported significant relief of symptoms. Histopathology confirmed endometriosis in the colonic mesentery and omental specimens.

Conclusions

Laparoscopic management of deep endometriosis in patients with a history of hysterectomy is safe and effective when performed with meticulous dissection and a clear understanding of pelvic anatomy. Immediate laparoscopic repair of serosal injuries is a critical skill for managing complex bowel adhesions. This case highlights the importance of a systematic laparoscopic approach in treating rare endometriotic localizations and extensive adhesions in previously operated patients.

https://player.vimeo.com/video/1191638517?autoplay=1

ESGE35-0461 - VP078
Video in ePoster

From Image to Diagnosis: The Predictive Value of Hysteroscopy

Hajer Bettaieb[1], Marouene Zouari[2], Hadhemi Rouis[2], Amal Chermiti[2]
[1]Faculty of Medicine- Tunis El Manar University, Department of Obstetrics and Gynaecology- Tunisia, Tunis, Tunisia
[2]faculty of medicine of Tunis,
Department of Obstetrics and Gynaecology- El Yasminet Hospital- Ben Arous- Tunisia, Tunis, Tunisia

Background

The aim of this video is to describe the hysteroscopic patterns associated with various benign and malignant gynecologic conditions and to emphasize the contribution of hysteroscopy to diagnostic assessment. Secondary objectives include highlighting the correlation between hysteroscopic appearance and histopathological findings and improving the identification of suspicious intrauterine lesions.

Methods

A retrospective collection of hysteroscopic procedures performed in our Department of Obstetrics and Gynaecology was assembled. Videos were classified according to benign and malignant pathologies, and each recording was analysed to highlight the characteristic hysteroscopic features of the corresponding lesion.

Results

Chronic endometritis is characterized by multiple micro polyps giving the mucosa a “strawberry-like” appearance.

In adenomyosis, the cavity appears irregular with hypervascularization and small endometrial pits.

Hysteroscopic examination of endometrial atrophy typically reveals a thin, pale, smooth, and fragile endometrium.

Intracavitary fibroids appear as firm, well-circumscribed whitish masses protruding into the uterine cavity, whereas endometrial polyps are typically soft, smooth, and pedunculated lesions with a pinkish or pale appearance.

In atypical endometrial hyperplasia, the endometrium appears thickened with irregular polypoid projections and atypical superficial vascularization, while endometrial cancer is associated with whitish necrotic areas, friable exophytic or cerebriform masses, and tortuous chaotic vessels.

Conclusions

Hysteroscopy is a valuable tool for the evaluation of intrauterine pathology, allowing identification of characteristic patterns associated with both benign and malignant conditions.

https://player.vimeo.com/video/1191642416?autoplay=1

ESGE35-0464 - VP079
Video in ePoster

The role of Indocyanine Green in minimizing ureteral injuries in complex Total Laparoscopic Hysterectomy.

Margherita Renso[1], *Stefano Scarperi*[1], *Valentino Bergamini*[1]
[1]*Obstetrics and Gynaecology Division B- Azienda Ospedaliera Integrata- University of Verona- Verona-Italy, Obstetrics and Gynaecology, Verona, Italy*

Background

Total Laparoscopic Hysterectomy (TLH) carries a significant risk (1.2%, range 0.6%–4%) of ureteral complications, higher than open abdominal or vaginal approach. The presence of large fibroids leads to poor pelvic visibility, decreased uterine mobility, deformity and displacement of the ureters from their anatomical positions.

Methods

This is a case of a 49 years old women with no previous major abdominal surgeries suffering from menometrorrhagia. The uterus measured 14 cm of length and showed a diffuse fibromatosis, where the largest were a posterior 8 cm FIGO 7 fibroid and a right 6 cm intraligamentous FIGO 6 fibroid. TLH with bilateral salpingoophorectomy was recommended.

Results

Immediately before surgery we performed a cystoscopy and injected 25 ml of ICG diluted in 10 ml sterile water in both ureters via a ureter catheter. Then we performed the hysterectomy with salpingoophorectomy with the ureter and the vision control during the surgery.

Conclusions

The use of indocyanine green could help the surgeon to minimize the risk of ureteral injuries during laparoscopic complex surgery.

https://player.vimeo.com/video/1191647423?autoplay=1

ESGE35-0496 - VP081
Video in ePoster

An alternative vNOTES technique for prophylactic prolapse surgery

Ahkam Göksel Kanmaz[1], Ece Cagirici[1], Emrah Töz[1], Yaşam Kemal Akpak[1], Özgün Akbaş[1]
[1]Izmir State Hospital, Gynaecology and Obstetrics, Izmir- TR-MIGS, Türkiye

Background

Pelvic organ prolapse following hysterectomy remains an important concern, particularly in postmenopausal women undergoing surgery for benign gynecologic conditions. High uterosacral ligament suspension is an established technique for apical support; however, alternative minimally invasive approaches aiming to improve vaginal depth and long-term support continue to evolve. In this work, we demonstrate a novel prophylactic apical support technique performed via vNOTES hysterectomy combined with high uterosacral ligament suspension and sacrouterine ligament reconstruction.

Methods

A 66-year-old postmenopausal woman presenting with postmenopausal bleeding and chronic pelvic pain underwent vNOTES total hysterectomy with bilateral salpingo-oophorectomy. Preoperative examination showed no uterine prolapse. Following hysterectomy, bilateral proximal uterosacral ligaments were identified under direct vNOTES visualization, with continuous attention to ureteral anatomy and peristalsis. Bilateral 2-0 Ethibond sutures were placed through the proximal uterosacral ligaments for apical support. Additional bilateral sacrouterine sutures were passed through the premucosal–postperitoneal plane. The left sacrouterine ligament suture was then advanced in a locked continuous fashion through the vaginal mucosa and peritoneum to create a supportive tunnel and tied to the contralateral side. Following vaginal cuff closure, both the sacrouterine and high uterosacral ligament suspension sutures were tied together to elevate the vaginal apex.

Results

The procedure was completed successfully without intraoperative complications. Intraoperative CO_2 cystoscopy confirmed normal bladder integrity and bilateral ureteral patency. Vaginal depth increased by approximately 3 cm following suspension. At 8-month postoperative follow-up, the patient reported complete resolution of pain with preserved apical support, and point D was measured at 5.1 cm.

Conclusions

This combined vNOTES high uterosacral ligament suspension and sacrouterine reconstruction technique appears to be a feasible and effective prophylactic approach for apical support following hysterectomy. The technique may provide enhanced vaginal depth and durable pelvic support while maintaining a minimally invasive transvaginal approach.

https://player.vimeo.com/video/1191670562?autoplay=1

ESGE35-0508 - VP082
Video in ePoster

v-notes extraperitoneal sacrocolpopexy

Ghanim Khatib[1], Oguzhan Kayim[1], Nimetullah Sarıyıldız[2], Duygu Güzel[1], Mehmet Ali Vardar[1]
[1]Cukurova University Balcali Hospital, Gynaecologic Oncology, Adana, Türkiye
[2]Cukurova University Balcali Hospital, Obstetrics and Gynaecology, Adana, Türkiye

Background

To demonstrate the surgical steps and feasibility of sacrocolpopexy performed via vaginal natural orifice transluminal endoscopic surgery (vNOTES) in the management of apical pelvic organ prolapse.

Methods

This video presents a step-by-step vNOTES sacrocolpopexy procedure performed in a patient with symptomatic apical pelvic organ prolapse. Following vaginal access and creation of the vNOTES platform, pelvic dissection was carried out to expose the sacral promontory. A synthetic mesh was fixed to the vaginal apex and anchored to the anterior longitudinal ligament using endoscopic suturing. Peritoneal closure was completed to fully cover the mesh.

Results

The procedure was successfully completed without intraoperative complications. Adequate exposure of the sacral promontory and secure mesh fixation were achieved. The vNOTES approach allowed excellent visualization, minimal blood loss, and avoided abdominal incisions.

Conclusions

vNOTES sacrocolpopexy is a feasible and minimally invasive alternative for the treatment of apical pelvic organ prolapse, combining the benefits of vaginal access with endoscopic visualization. This technique may offer reduced postoperative morbidity and improved cosmetic outcomes in selected patients.

https://player.vimeo.com/video/1191675071?autoplay=1

ESGE35-0511 - VP083
Video in ePoster

unilateral laparoscopic cervicopectopexy: a uterus-sparing approach for early apical prolapse

Preslava Petrova[1], Ester Ilieva[2], Dobromir Andreev[3], Atanas Aleksandrov[2], Aleksandar Lyubenov[4]
[1]MHAT "Heart and Brain", Obstetrics and Gynaecology, Pleven, Bulgaria
[2]MHAT ''Heart and Brain", Obstetrics and Gynaecology, Pleven, Bulgaria
[3]MHAT "Heart and Brain'', Obstetrics and Gynaecology, Pleven, Bulgaria
[4]MHAT ''Heart and Brain'', Obstetrics and Gynaecology, Pleven, Bulgaria

Background

Early apical prolapse is increasingly encountered in women who wish to preserve their uterus. This has led to a growing need for effective uterus-sparing surgical techniques that are adapted to individual patient characteristics. Minimally invasive approaches aiming to restore apical support while limiting surgical dissection are of particular interest.

Methods

We present a surgical video of a 45-year-old patient with symptoms of pelvic heaviness and vaginal fullness, who expressed a clear preference for uterine preservation. No significant uterine pathology was identified. POP-Q assessment demonstrated stage II apical prolapse (C 0 to +1, D –4 to –5), consistent with a true apical defect without cervical elongation, with only a mild anterior compartment involvement.

A unilateral right-sided laparoscopic cervicopectopexy was performed using a suture-only technique. The procedure included identification of the pectineal (Cooper's) ligament, careful dissection of the right pelvic sidewall, creation of a peritoneal tunnel, and preparation of the cervix and uterine isthmus. Sutures were placed on the cervix and secured to the pectineal ligament, followed by tension adjustment to restore the physiological uterine axis. The procedure was completed with peritonization and final inspection.

Results

The procedure was completed laparoscopically without intraoperative complications. Adequate apical support and restoration of the uterine axis were achieved. No significant bleeding or intraoperative difficulties were encountered. The postoperative course was uneventful.

At three-month follow-up, the patient reported resolution of symptoms, including pelvic heaviness and vaginal fullness. Clinical examination confirmed improved apical support without evidence of recurrence or new compartment defects.

Conclusions

Unilateral laparoscopic cervicopectopexy represents a feasible, safe, and reproducible uterus-sparing technique for the management of early apical prolapse. This tailored, suture-only approach provides effective apical support while minimizing surgical dissection and avoiding the use of mesh. It may be particularly suitable for selected patients with confirmed true apical defects who desire uterine

preservation.
https://player.vimeo.com/video/1191676015?autoplay=1

ESGE35-0519 - VP084
Video in ePoster

Reviving a Classic: Robotic Burch Colposuspension for the Surgical Management of Stress Urinary Incontinence

Anıl Erturk[1], Fatma Nur Aycicek[1], Nergis Kender Erturk[2]
[1]Cerrahpasa Faculty of Medicine, Department of Obstetrics and Gynaecology, Istanbul, Türkiye
[2]Bursa Yuksek Ihtisas Training and Research Hospital, Department of Obstetrics and Gynaecology, Bursa, Türkiye

Background

Stress Urinary Incontinence is a common pelvic floor disorder that significantly affects quality of life in elderly women. Concomitant gynecologic pathology requiring surgical intervention may provide an opportunity for simultaneous correction of urinary symptoms. The Burch colposuspension remains an effective surgical option for selected patients with stress urinary incontinence undergoing pelvic surgery. We present the surgical management of a patient with an adnexal mass and concomitant stress urinary incontinence treated in a single operative session.

Methods

A 68-year-old woman with a history of two previous caesarean deliveries presented with symptoms of stress urinary incontinence. Pelvic ultrasonography demonstrated a 55 mm solid ovarian mass. Further evaluation with magnetic resonance imaging suggested a benign ovarian fibroma. Preoperative tumor markers were within normal limits. Cervical cytology and endometrial sampling showed no evidence of malignancy. Following comprehensive preoperative assessment, the patient underwent robotic hysterectomy with adnexal surgery, followed by concomitant Burch colposuspension in the same session.

Results

The procedure was completed successfully without intraoperative or postoperative complications. Final postoperative recovery was uneventful. At the 10-day postoperative follow-up, the patient reported significant improvement in urinary incontinence symptoms, with no additional postoperative complaints.

Conclusions

Simultaneous management of benign gynecologic pathology and Stress Urinary Incontinence is feasible and safe in appropriately selected patients. Concomitant Burch colposuspension during gynecologic surgery may provide effective early symptom relief without increasing perioperative morbidity. This combined approach may optimize surgical outcomes and improve postoperative quality of life.

https://player.vimeo.com/video/1191678838?autoplay=1

ESGE35-0527 - VP085
Video in ePoster

Preserve First, Excise Second: A Reserve-Sparing Laparoscopic Technique for Large Ovarian Endometrioma Prioritising Cleavage Plane Development, Suture Haemostasis, and Avoidance of Energy Devices

Yavuz Yilmaz[1], *Hasan Aykut Tuncer*[2]
[1]*Akdeniz University, Obstetrics and Gynaecology, Antalya, Türkiye*
[2]*Akdeniz University, Gynecologic Oncology- Obstetrics and Gynaecology, Antalya, Türkiye*

Background

To demonstrate a structured, ovarian reserve-sparing laparoscopic technique for large endometrioma excision, emphasising delayed intentional perforation, systematic cleavage plane development, cortical suture haemostasis without energy device application, and ovarian reconstruction — with the aim of minimising follicular loss and preserving reproductive potential.

Methods

A 40-year-old woman (gravida 1, para 1) with a desire for future fertility presented with a three-year history of dysmenorrhoea, dyspareunia, and chronic pelvic pain. Transvaginal ultrasound demonstrated a 98×94 mm right ovarian endometrioma. Pre-operative anti-Müllerian hormone (AMH) was 1.2 ng/mL with a reduced antral follicle count on the affected side (AFC right: 2, left: 8), indicating already compromised ovarian reserve. Laparoscopic endometrioma excision was planned using a strictly energy-sparing, suture-based technique.

The operative strategy followed four sequential principles:

Delayed perforation: The cyst wall was not immediately perforated on entry. Adhesiolysis and identification of the correct cleavage plane between the cyst wall and ovarian cortex were prioritised first, reducing inadvertent spillage and allowing controlled dissection.

Cleavage plane development: The natural tissue plane was progressively opened using blunt and sharp dissection. Traction-countertraction technique allowed the cyst wall to be stripped along the correct anatomical layer, preserving the overlying cortex.

Suture haemostasis — no energy devices: All bleeding points on the ovarian bed were controlled exclusively with absorbable sutures. No bipolar or monopolar energy was applied to the ovarian cortex, avoiding thermal damage to adjacent follicles.

Cortical closure: The ovarian cortex was approximated with interrupted absorbable sutures, restoring ovarian architecture and preventing follicular atresia from exposure.

Results

Complete excision of the endometrioma was achieved without capsule rupture until the controlled perforation step.

Postoperative AMH at three months was 1.1 ng/mL — no clinically significant decline from baseline, consistent with preserved ovarian reserve. The patient reported resolution of dysmenorrhoea and dyspareunia. No intraoperative or postoperative complications were recorded.

Conclusions

In patients with borderline ovarian reserve, laparoscopic endometrioma excision can be performed with minimal impact on AMH when a structured reserve-sparing technique is applied. Delayed perforation, systematic cleavage plane development, exclusive suture haemostasis, and cortical closure collectively reduce follicular loss. Avoidance of energy devices on the ovarian cortex is critical — thermal damage accelerates follicular atresia and should not be accepted as routine haemostasis. This technique demonstrates that surgical completeness and fertility preservation are not mutually exclusive.

https://player.vimeo.com/video/1191680918?autoplay=1

ESGE35-0538 - VP086
Video in ePoster

Fertility-sparing laparoscopic surgery for deep infiltrating endometriosis with bilateral endometriomas

Dilek Tektaş[1], Hüseyin Kıyak[2], Nura Fitnat Topbas Selcuki[1], Burak Cakmak[3]
[1]Şişli Hamidiye Etfal Training and Research Hospital, Gynaecology and Obstetrics, Istanbul, Türkiye
[2]Kanuni Sultan Suleyman Training and Research Hospital, Gynaecology and Obstetrics, Istanbul, Türkiye
[3]Mus State Hospital, Gynaecology and Obstetrics, Mus, Türkiye

Background

Endometriosis is a chronic inflammatory disease affecting approximately 6–10% of reproductive-aged women, often leading to severe quality-of-life impairment. In young patients, such as this 32-year-old female, the management of deep infiltrating endometriosis (DIE) and bilateral endometriomas is particularly challenging due to the need to balance pain relief with fertility preservation. The patient presented with symptomatic bilateral endometriomas and an obliterated Douglas pouch, experiencing severe dysmenorrhea and dyschezia. Despite the anatomical distortion, no bowel nodules or additional peritoneal lesions were identified, making a fertility-sparing surgical approach the primary objective.

Methods

A systematic laparoscopic approach was employed. The procedure began on the right side with an incision and aspiration of the endometrioma's chocolate-colored fluid. To ensure safety, ureterolysis was performed by dissecting the peritoneum over the ureter's course, using the ureteric line as a guide to mobilize the pelvic wall and release right-sided adhesions in the Douglas pouch. A similar identification was performed on the left side. Blunt dissection—the gentle separation of tissues along natural planes—was used to push the bowels back and clear the surgical field. The primary instrument used for dissection and hemostasis was the Harmonic Scalpel (ultrasonic shears), which operates at temperatures below 80°C, thereby minimizing lateral thermal spread and protecting adjacent vital structures like the ureter and bowel. Finally, the cyst capsules were removed using the stripping technique.

Results

The surgical intervention successfully achieved complete excision of all visible endometriotic lesions and restoration of the normal pelvic anatomy by opening the obliterated Douglas pouch. By utilizing the Harmonic Scalpel's low thermal profile, the risk of heat-related injury to the ovaries and tubes was minimized. All reproductive structures, including the fallopian tubes and healthy ovarian parenchyma, were meticulously preserved to maximize future fertility potential. In young patients under 35, such complete excision of DIE has been associated with high spontaneous pregnancy rates.

Conclusions

A structured and systematic surgical approach is essential for treating deep endometriosis in patients desiring children. This case highlights that ureterolysis serves as a critical landmark for safe pelvic mobilization and that the use of ultrasonic energy devices can protect the ovarian reserve by limiting thermal damage. For a 32-year-old patient, this conservative yet thorough surgical strategy provides an effective solution for alleviating chronic pain while maintaining the biological capacity for natural conception.

https://player.vimeo.com/video/1191682126?autoplay=1

ESGE35-0543 - VP087
Video in ePoster

Pelvic sentinel node in endometrial cancer: A laparoscopic blue dye technique

Yasmine Chiba[1], Bouassida Mehdi[1], Hfaiedh Ines[1], Medemagh Malek[1], Mellouli Ferdaous[1], Mourali Mechaal[1]
[1]Habib Bougatfa University Hospital in Bizerte, Department of Obstetrics and Gynaecology, Bizerte, Tunisia

Background

Sentinel lymph node (SLN) mapping has become an increasingly adopted technique in the surgical staging of early-stage endometrial cancer, offering a less morbid alternative to systematic pelvic lymphadenectomy while maintaining adequate oncologic staging accuracy. Its role is particularly relevant in low- and intermediate-risk disease, where the likelihood of nodal metastasis is reduced.

Methods

We report the case of a 62-year-old postmenopausal woman presenting with abnormal uterine bleeding. Endometrial biopsy confirmed a grade 1 endometrioid adenocarcinoma. Pelvic magnetic resonance imaging demonstrated a uterine-confined lesion with less than 50% myometrial invasion and no evidence of suspicious pelvic or para-aortic lymph nodes, consistent with presumed FIGO stage I disease.

She underwent minimally invasive surgical management consisting of total laparoscopic hysterectomy with bilateral salpingo-oophorectomy and pelvic SLN mapping. Patent Blue dye was injected into the cervix at the 3 and 9 o'clock positions, both superficially and deeply within the cervical stroma. Following peritoneal access, retroperitoneal dissection was performed through the paravesical and pararectal spaces to expose the pelvic sidewall anatomy and lymphatic basins. Careful dissection allowed identification of key anatomical landmarks including the external iliac vessels, obturator fossa, and internal iliac region.

Results

Bilateral sentinel lymph nodes were successfully identified through blue dye uptake and lymphatic staining. The nodes were carefully dissected and retrieved laparoscopically without intraoperative complications. Systematic exploration confirmed accurate mapping of the pelvic lymphatic drainage pathways.

Final histopathological examination confirmed a FIGO stage IA endometrioid adenocarcinoma with less than 50% myometrial invasion and no lymph node metastasis in the sentinel nodes. Surgical margins were negative.

Conclusions

Laparoscopic SLN mapping using Patent Blue dye in early-stage endometrial cancer is a safe, feasible, and effective technique for lymphatic staging. It enables accurate identification of pelvic nodal status while avoiding the morbidity associated with systematic lymphadenectomy.

https://player.vimeo.com/video/1191673096?autoplay=1

ESGE35-0551 - VP088
Video in ePoster

Double Caesarean Scar Defect as a Cause of Persistent Postmenstrual Spotting: Hysteroscopic Management of a Rare Case – TR-MIGS

Necati Berk Kaplan[1], *Batuhan Aslan*[1], *Yavuz Emre Şükür*[1]
[1]*Ankara University, Obstetrics and Gynaecology, Ankara, Türkiye*

Background

To present a rare case of double isthmocele in a symptomatic patient with a history of two previous caesarean sections and to describe the hysteroscopic management of this uncommon condition. Isthmocele, also known as caesarean scar defect or uterine niche, is a recognized late complication of caesarean delivery and is commonly associated with postmenstrual spotting. Multiple caesarean sections and retroflexed uterus are known risk factors; however, the presence of two distinct isthmocele is exceptionally rare in the literature.

Methods

A 33-year-old woman with a history of two prior caesarean sections presented with postmenstrual spotting occurring approximately 7–8 days after the end of menstruation. Transvaginal ultrasonography revealed two separate caesarean scar defects located at the lower uterine segment. Diagnostic hysteroscopy confirmed the presence of two distinct pouch-like defects on the anterior uterine wall. Operative hysteroscopy was subsequently performed using a resectoscopic approach. Fibrotic tissue surrounding both niches was resected, and the inferior edges of the defects were flattened to facilitate drainage of menstrual blood accumulated within the pouches. Care was taken to preserve the residual myometrium during resection. Hysteroscopic correction is considered a minimally invasive technique with low morbidity and high rates of symptom improvement in appropriately selected patients.

Results

The procedure was completed successfully without intraoperative or postoperative complications. The patient experienced complete resolution of postmenstrual spotting during follow-up. Histopathologic examination revealed fibrotic scar tissue consistent with caesarean scar defects. The identification of two discrete isthmocele in a patient with only two previous caesarean deliveries represents an unusual clinical finding.

Conclusions

Double isthmocele represents an exceptionally uncommon form of caesarean scar defect and should be considered in patients presenting with persistent postmenstrual spotting after caesarean delivery. Thorough evaluation of the lower uterine segment is crucial, as multiple defects may remain undetected during routine assessment. Hysteroscopic management offers a minimally invasive and effective approach, allowing simultaneous diagnosis and treatment with favorable symptomatic outcomes.

https://player.vimeo.com/video/1191687573?autoplay=1

ESGE35-0557 - VP089
Video in ePoster

Laparoscopic Management of Ruptured Endometrioma: Prioritizing Pain Control, Ovarian Preservation and Bilateral Targeted Sclerotherapy (TR-MIGS Study)

Filiz Gökçe Ikibudak[1], Oğuz Arslan[2], Rümeysa Belen Gümüş[2], Mustafa Kemal Köksal[2], İbrahim Yalçın[2]
[1]Dokuz Eylül University, Obstetrics and Gynaecology, İzmir, Türkiye
[2]Dokuz Eylul University, Obstetrics and Gynaecology, İzmir, Türkiye

Background

To demonstrate the operative strategy and key intraoperative findings of bilateral laparoscopic ethanol sclerotherapy following spontaneous rupture of ovarian endometrioma

Methods

A 26-year-old nulligravid woman presented with severe left-sided pelvic pain (VAS 9/10), associated with acute worsening of lower abdominal discomfort and pelvic pressure. Ultrasonography revealed complex solid-cystic adnexal masses measuring approximately 9 cm on the left and 3.5 cm on the right, without Doppler vascularity. Magnetic resonance imaging confirmed a 9 cm left ovarian lesion consistent with endometrioma. Surgical management was initially planned; however, the patient was readmitted with acute-onset severe abdominal pain. A decline in CA-125 levels from 365 U/mL to 71 U/mL, combined with clinical findings, raised strong suspicion for recurrent endometrioma rupture. Given the inflammatory milieu, surgery was deferred for four weeks to allow acute inflammation to resolve and facilitate safer operative intervention. This video illustrates the subsequent laparoscopic management.

Results

Laparoscopic evaluation demonstrated dense pelvic adhesions and diffuse peritoneal inflammation consistent with prior cyst rupture, along with characteristic powder-burn lesions. We perforated the left ovarian endometrioma via trocar entry, completely aspirated the cyst contents, and irrigated until clear return was achieved. A Foley catheter was introduced into the cyst cavity, and the balloon was inflated with 5 mL saline to prevent ethanol spillage. The cavity was then instilled with 95% ethanol for 10 minutes. Following complete aspiration of ethanol, visual inspection confirmed effective destruction of the cyst lining. A biopsy was obtained from a non-exposed region for histopathologic confirmation. The same sclerotherapy protocol was applied to the contralateral ovarian cyst.

Conclusions

Laparoscopic ethanol sclerotherapy represents a technically feasible approach that spares ovarian reserve in the management of endometriomas in women of reproductive age. While preserving ovarian reserve remains a primary advantage, this technique may also offer significant pain control in selected patients.

https://player.vimeo.com/video/1193537970?autoplay=1

ESGE35-0558 - VP090
Video in ePoster

Minimally invasive surgical staging with atypical sentinel lymph node localization in endometrial cancer

Şerife Akbay Türker[1], *Rümeysa Belen Gümüş*[2], *İbrahim Yalçın*[3]
[1]*Taşova State Hospital, Obstetrics and Gynaecology, SAMSUN, Türkiye*
[2]*Dokuz Eylül University- Faculty of Medicine, Gynecologic Oncology, İzmir, Türkiye*
[3]*Dokuz Eylül University- Faculty of Medicine-, Gynecologic Oncology, İzmir, Türkiye*

Background

Sentinel lymph node (SLN) mapping has become an important component of minimally invasive surgical staging in endometrial cancer. Although SLNs are most commonly identified in the obturator and external iliac regions, atypical lymphatic drainage pathways may occasionally occur and may affect staging accuracy. We aimed to present a case of endometrial cancer with atypical SLN localization detected during minimally invasive surgical staging.

Methods

A patient diagnosed with early-stage endometrial cancer underwent minimally invasive surgical staging including total laparoscopic hysterectomy, bilateral salpingo-oophorectomy, and SLN dissection. Preoperative and intraoperative evaluation of lymph node localization was performed according to anatomical lymphatic pathways. Surgical exploration identified an atypically localized SLN during the procedure.

Results

Minimally invasive surgical staging was completed successfully. In addition to the expected pelvic lymphatic regions, an atypical SLN localization was detected intraoperatively outside the commonly observed anatomical areas. The atypically localized SLN was carefully dissected and removed laparoscopically. Complete staging was achieved without conversion to laparotomy. Final histopathological examination confirmed endometrial carcinoma, and no metastatic involvement was identified in the excised lymph nodes. The postoperative period was uneventful, and the patient was discharged in good clinical condition.

Conclusions

Atypical SLN localization may occur during surgical staging of endometrial cancer and should be recognized to avoid understaging. Careful anatomical evaluation during minimally invasive surgery may facilitate identification of uncommon lymphatic drainage pathways and contribute to accurate oncologic staging. Awareness of atypical SLN locations is important for gynecologic oncologists performing minimally invasive staging procedures.

https://player.vimeo.com/video/1191682002?autoplay=1

ESGE35-0567 - VP091
Video in ePoster

Single-port adaptation in two major gynecologic emergencies: a video presentation from a resource-limited secondary hospital

Tural İsmayilov[1], Begüm Sinem Kezer[2], Meryem Hocaoglu[3]
[1]Bingöl State Hospital, Obstetrics and Gynaecology, Bingöl, Türkiye
[2]Goztepe Prof. Dr. Suleyman Yalcin City Hospital, Obstetrics and Gynaecology, Istanbul, Türkiye
[3]Göztepe Prof. Dr. Suleyman Yalcin City Hospital, Obstetrics and Gynaecology, İstanbul, Türkiye

Background

To demonstrate the feasibility of intraoperative adaptation to single-port laparoscopy in two different major gynecologic emergencies managed in a resource-limited secondary public hospital

Methods

The first case was a 35-year-old G1P1 woman with a previous caesarean section who presented to the emergency department with a cute abdominal pain that started 6 hours earlier during the 23rd day of her menstrual cycle. Initial laboratory evaluation revealed hemoglobin of 10.3 g/dL and negative beta-human chorionic gonadotropin. Abdominal computed tomography excluded appendicitis and demon strated an adnexal mass measuringapproximately 9 cm. Gynecologic ultrasonography revealed an 80×90 mm right ovarian cyst suspicious for ovarian torsion. Following conventional laparoscopic entry and c onfirmation of torsion, surgery was continued using a single-port platform with detorsion and ovarian cystectomy.

The second case was a 25-year-old nulliparous woman with Genito-Pelvic Pain/Penetration Disorder who refused transvaginal examination during follow-up for pregnancy of unknown location. She presented with abdominalpain and progressive hemoglob in decline from 10.3 g/dL to 7.7 g/dL within 2 hours. Following clinical and ultrasonographic evaluation, ruptured ectopic pregnancy w as suspected. Emergency surgery was initiated withconventional laparoscopy and intraoperatively ad apted to a single-port approach. Left salpingectomy was performed.

Results

Both procedures were completed successfully without conversion to laparotomy or additional trocar placement. In the first case, postoperative pathology revealed serous cystadenoma and the patient w as discharged 12 hoursafter surgery. In the second case, 2 units of erythrocyte suspension were transfused postoperatively, and the patient was discharged 18 hours after surgery with stable hemoglobin levels.

Conclusions

In selected patients, intraoperative adaptation to single-port laparoscopy may be feasible in different gynecologic emergencies, even in resource-limited secondary hospital settings. This video presentation highlights a pragmatic, minimally invasive approach without compromising surgical safety.

https://player.vimeo.com/video/1191690979?autoplay=1

ESGE35-0573 - VP092
Video in ePoster

Robot-assisted management of deep infiltrating rectal endometriosis requiring low anterior rectal resection

Valentina Auletta[1], *Davit Bokhua*[2]
[1]*University of Jena, Gynaecology Oncology and Endometriosis, Jena, Germany*
[2]*University of Jena, Gynaecology, Jena, Germany*

Background

A 36-year-old premenopausal patient presented with persistent symptoms despite previous hysterectomy for adenomyosis and prior laparoscopic endometriosis surgery. Preoperative transvaginal ultrasound showed a suspicious bowel lesion measuring approximately 23 mm. Rectal endoscopic ultrasound identified a hypoechoic lesion at 8 cm from the anal verge, with suspected infiltration from the serosa to the muscularis. The preoperative classification was #ENZIAN(u) C2. After counselling, including discussion of bowel resection and protective stoma formation, robot-assisted complete endometriosis excision was planned.

Methods

Robotic Endometriosis Resektion on Bowel Endometriosis

Results

The video demonstrates systematic adhesiolysis in a pelvis with dense adhesions between the rectum, left pelvic sidewall and left ovary. A nodular rectal endometriotic lesion of approximately 2 cm was identified. Key surgical steps included opening of the left lateral pelvic peritoneum, identification and ureterolysis of the left ureter, mobilisation of the rectum in the rectovaginal and presacral spaces, and release of the sigmoid colon from lateral adhesions. The lesion was completely mobilised and left attached to the anterior rectal wall. Due to deep rectal involvement, a colorectal surgeon performed low anterior rectal resection with end-to-end anastomosis and protective ileostomy. Estimated blood loss was 50 ml. The postoperative classification was #ENZIAN P1 C3.

Conclusions

Robot-assisted surgery may facilitate precise dissection in severe posterior compartment endometriosis with distorted pelvic anatomy. This case highlights the importance of preoperative bowel assessment, ureteral identification, stepwise rectovaginal dissection and multidisciplinary collaboration when bowel resection is required.

https://player.vimeo.com/video/1191691373?autoplay=1

ESGE35-0575 - VP093
Video in ePoster

Posterior stage of laparoscopic sacrocolpopexy

Yasmine Chiba[1], Barouni Rihab[1], Hfaiedh Ines[1], Zoghlami Achref[1], Jaafar Wissal[1], Mourali Mechaal[1]
[1]Habib Bougatfa University Hospital in Bizerte, Department of Obstetrics and Gynaecology, Bizerte, Tunisia

Background

To demonstrate the posterior stage of laparoscopic sacrocolpopexy for advanced pelvic organ prolapse, highlighting a structured technique for secure mesh fixation and posterior compartment restoration.

Methods

We report the case of a 56-year-old woman presenting with a vaginal bulge sensation. Clinical examination revealed stage III urogenital prolapse, predominantly posterior. After obtaining informed consent from the patient, laparoscopic sacrocolpopexy (promontofixation) was performed. Following exposure of the posterior compartment, bilateral identification of the levator ani muscles was achieved. Anchoring sutures were placed using non-absorbable material to create stable fixation points. A Y-shaped polypropylene mesh was introduced and positioned accordingly. The mesh arms were secured to the levator ani muscles, with reinforcement when necessary. The central portion of the mesh was fixed to the posterior cervical surface. The mesh was then passed through the created posterior tunnel and anchored to the sacral promontory using a pre-placed suture. Bilateral dissection was maintained with meticulous hemostasis throughout the procedure.

Results

The procedure was completed successfully without intraoperative complications. Adequate anatomical restoration of the posterior compartment was achieved with appropriate mesh tension and stable fixation.

Conclusions

The described posterior stage of laparoscopic sacrocolpopexy is a reproducible and structured technique for the management of advanced posterior-predominant prolapse. Secure bilateral fixation combined with promontory anchoring may contribute to durable anatomical correction.

https://player.vimeo.com/video/1191692556?autoplay=1

ESGE35-0584 - VP095
Video in ePoster

In-organ Core Needle Biopsy: Step-by-Step Technique

Veronika Vaisová[1]
[1]*First Faculty of Medicine- Charles University and General University Hospital in Prague, Department of Gynaecology- Obstetrics and Neonatology, Prague, Czech Republic*

Background

Atypical myometrial lesions may require targeted histopathological verification prior to surgical management. Ultrasound-guided in-organ core needle biopsy (CNB) may provide precise tissue acquisition while minimizing transperitoneal passage and potential dissemination risk.

Methods

This educational surgical video demonstrates a standardized ultrasound-guided in-organ core needle biopsy technique using a transcervical intracavitary approach. Following vulvovaginal disinfection, a paracervical block with 20 ml of 1% Mesocain is administered into all four cervical quadrants. A guiding sheath is introduced through the cervical canal into the uterine cavity. After sonographic identification of the target lesion and planning of a safe biopsy trajectory, an 18G automated core biopsy needle is inserted through the sheath into the myometrial lesion. Three representative biopsy cores with a sample length of 22 mm are obtained and fixed in formaldehyde solution. Final ultrasound assessment excludes immediate complications, including bleeding or hematoma formation.

Results

The in-organ approach enables precise tissue acquisition while minimizing transperitoneal passage and potential dissemination risk. The technique provides sufficient tissue yield for histopathology, immunohistochemistry (IHC), and molecular profiling (NGS), particularly in poorly transvaginally accessible or fundally located lesions.

Conclusions

In-organ CNB represents a feasible and reproducible minimally invasive technique for targeted sampling of atypical myometrial lesions. The presented approach is currently implemented within the prospective multicentre MYSTR cohort study: The Role of Pre-Surgical Tru-cut Biopsy in the Management of Atypical Myometrial Lesions.

https://player.vimeo.com/video/1191699230?autoplay=1

ESGE35-0611 - VP099
Video in ePoster

Stepwise Caesarean Scar Niche Repair: Surgical Planning, Intraoperative Mapping and Operative Pitfalls Across Complex Presentations

Jennifer Shallop[1], Sharon Davidesko[1], Philippa Hallchurch[1], Prashant Purohit[1], Nitish Narvekar[1]
[1]Kings College Hospital UK, Obstetrics and Gynaecology, London, United Kingdom

Background

To demonstrate complex caesarean scar niche presentations and adapted minimally invasive surgical techniques, focusing on preoperative assessment, intraoperative anatomical localisation, excision, and uterine reconstruction.

Methods

An educational surgical video from a tertiary centre for advanced minimally invasive gynaecological surgery.

Preoperative assessment included detailed transvaginal ultrasound following ISUOG guidance to define niche location, dimensions and residual/adjacent myometrial thickness (RMT).
By ensuring comprehensive preoperative evaluation, appropriate patient selection, and thorough counselling including fertility implications support informed consent and optimise operative planning. MRI was judiciously used for complex niches with distorted anatomy, broad defects, or suspected lateral or posterior extension.

Intraoperatively, hysteroscopy was central to correlating imaging with real anatomy and accurately localising the niche, allowing direct visualisation and precise mapping of the defect in relation to the internal and external os to guide subsequent dissection. Indocyanine green (ICG) mapping was utilised in selected complex cases to improve delineation of poorly defined defects.

Results

This video highlights common intraoperative challenges, where surgical exposure frequently reveals dense vesicouterine adhesions, obliterated tissue planes, and lateral extension of the niche, all of which can significantly obscure defect identification and complicate safe dissection and reconstruction.

Intraoperative adaptation including extensive uterovesical dissection and stepwise identification of healthy myometrium before excision are essential to avoid bladder injury and maintain orientation in distorted anatomy.

Full-thickness wedge excision was performed in all cases, followed by meticulous two-layer uterine closure. Integrity of repair is confirmed using saline or methylene blue testing, with additional reinforcement sutures placed where required. Robotic assistance is used in selected cases to facilitate dissection and improve suturing precision in complex anatomy.

Conclusions

Complex caesarean scar niche repair requires thorough preoperative planning, counselling, and consent to enable definitive surgery.

However, intraoperative findings often exceed imaging expectations, safe outcomes depend on accurate anatomical identification, and precise reconstruction, via meticulous surgical technique.

https://player.vimeo.com/video/1196735784?autoplay=1

ESGE35-0622 - VP100
Video in ePoster

A stepwise approach for robotic excision of bladder nodules in endometriosis

Nicolas Samartzis[1], *Dimitrios Rafail Kalaitzopoulos*[2], *Laurin Burla*[2], *Horace Roman*[3]
[1]*Cantonal Hospital Schaffhausen, Gynaecology and Obstetrics, Schaffhausen, Switzerland*
[2]*Cantonal Hospital of Schaffhausen, Gynaecology and Obstetrics, Schaffhausen, Switzerland*
[3]*IFEMEndo- Clinique Tivoli-Ducos, Gynaecology, Bordeaux, France*

Background

Excision of deep infiltrating endometriosis involving the bladder can be challenging and requires good anatomical knowledge and surgical strategy. In cases with large nodules involving the full thickness of the bladder, a combined cystoscopic and robotic approach can be helpful.

Methods

This video aims to demonstrate a standardized, reproducible method. The procedure have been performed at the IFEM-Endo Center in Bordeaux. The patient gave consent to publish the video.

Results

The first step is the opening of the peritoneum and the paravesical space, identifying the umbilical and uterine arteries, as well as the lateral wall of the bladder on both sides. The ureter is visualized as it crosses under the uterine artery. The nodule is released from the pubocervical fascia. Further dissection is performed in the vesicovaginal space until healthy tissue is reached caudally to the nodule.

The urologist performs a cystoscopy to identify the limits of mucosal involvement and to assess whether the meatus of the ureter is involved. A circular incision of the muscular layer around the nodule is made using the bipolar hook. Complete resection is then achieved from the abdominal cavity. The bladder wall is closed using a running barbed suture. To relieve tension on the bladder in cases of large openings, dissection is performed in the space of Retzius. Filling the bladder with saline helps to assess its permeability.

Conclusions

According to our experience, a systematic approach helps to achieve a complete excision of bladder nodules while reducing the inadvertent resection of healthy bladder tissue. This method also minimizes the risk of injury to the critical adjacent structures.

https://player.vimeo.com/video/1191725327?autoplay=1

ESGE35-0628 - VP101
Video in ePoster

Uses of ICG in Complex Gynecologic Surgeries

Danielle Wilson[1], *Asha Bhalwal*[1]
[1]*University of Texas Health Science Center at Houston, Obstetrics and Gynaecology, Houston, USA*

Background

9. Background :As the complexity in benign gynecological surgery increase, Innovations in surgery must be investigated to continue to care for and treat our patients. This video will demonstrate the uses of ICG in complex gynecologic surgery to overcome challenges that may arise.

Methods

10. A retrospective review of the uses of ICG commonly performed in our practice.

Results

Indocyanine green or pICG is an FDA-approved dye used to enhance real-time visualization of tissues. Its uses include ureteral identification, chromoperturbation, endometrial cavity identification in both myomectomy and adenomyomectomy, bladder dissection in hysterectomy, including both the notes and robotic and lastly, in ovarian torsion.

Conclusions

Conclusions: Use of ICG advances complex gynecologic minimally invasive surgery, allowing for realtime identification of tissues and helping to decrease the risk of injury.

https://player.vimeo.com/video/1191754364?autoplay=1

ESGE35-0629 - VP102
Video in ePoster

Robotic assisted laparoscopic trachelectomy and excision of endometriosis

Danielle Wilson[1], *Asha Bhalwal*[1]
[1]*University of Texas Health Science Center at Houston, Obstetrics and Gynaecology, Houston, USA*

Background

The following video will discuss the indications, steps and complications of trachelectomy and demonstrate two cases of robotic assisted laparoscopic trachelectomy with endometriosis excision.

Methods

Retrospective review of two patients undergoing robotic assisted laparoscopic trachelectomy with excision of endometriosis

Results

Robotic assisted laparoscopic trachelectomy is a safe and effective option for excision of endometriosis and remnant cervix in patients who have had a history of supracervical hysterectomies. We had no complications during our review.

Conclusions

Patients who are undergoing trachelectomy and require further investigation for concurrent disease such as chronic pelvic pain, endometriosis, pelvic mass, or known adhesive disease, can safely undergo the procedure via a robotic assisted laparoscopic approach.

https://player.vimeo.com/video/1191757127?autoplay=1

ESGE35-0635 - VP103
Video in ePoster

ICG in Chromopertubation: A New Era in Tubal Patency Assessment

Aya Mohr-Sasson[1], *Asha Bhalwal*[1]
[1]*McGovern Medical School at The University of Texas Health Science Center, Department of Obstetrics- Gynaecology & Reproductive Sciences, Houston, USA*

Background

While methylene blue remains the standard for Chromopertubation, its diagnostic accuracy can be hindered by factors such as improper positioning of the uterine manipulator, variations in intrauterine pressure, and potential fallopian tube constriction, which can result in false-negative findings. In contrast, the use of indocyanine green (ICG), a fluorescent contrast agent, offers a groundbreaking alternative with enhanced visualization, enabling more reliable and consistent assessment of tubal patency. This video aims to demonstrate the technique of ICG-based Chromopertubation, showcasing its application in minimally invasive surgery for real-time tubal assessment, and highlighting its advantages over conventional methylene blue.

Methods

This video-based surgical demonstration features a step-by-step guide to ICG-based chromopertubation and its clinical application. ICG, a fluorescent contrast agent with a well-established safety profile, was prepared by diluting 0.5 mL (2.5 mg/mL) in 500 mL of normal saline. From this solution, 20 mL was instilled into the uterine cavity via a diagnostic uterine manipulator. This technique outlines the adequate concentration needed for achieving appropriate dilution to optimize visualization of tubal patency while minimizing dye overload. Intraoperative imaging was performed using near-infrared fluorescence (NIRF) technology integrated into the robotic surgical platform. The patient, a 36-year-old woman with abnormal uterine bleeding and a history of endometriosis, underwent robotic-assisted myomectomy, right ovarian cystectomy, and chromopertubation using ICG.

Results

ICG fluorescence imaging enabled clear, real-time visualization of the fallopian tubes and confirmed right-sided tubal patency with distal spill. The left tube was surgically absent. Compared to methylene blue, ICG provided superior visualization and reduced the risk of false-negative results caused by factors such as tubal spasm, intrauterine pressure, or uterine manipulator positioning. The procedure was completed without complications, and the patient's reproductive anatomy was preserved.

Conclusions

ICG-guided chromopertubation is a safe, effective, and technically feasible method for assessing tubal patency during minimally invasive gynecologic surgery. Its enhanced visualization and reliability make it a promising alternative to traditional dye-based methods, particularly in reproductive surgery where accurate tubal assessment is critical for fertility planning.

https://player.vimeo.com/video/1191783030?autoplay=1

ESGE35-0652 - VP104
Video in ePoster

Laparoscopic repair of iatrogenic bowel injury: a case-based review of safety and technique

Büşra Asena Torun[1], Sevtap Seyfettinoglu[1], Sevda Bas[1], Mehmet Ali Narin[1]
[1]Adana City Training and Research Hospital, Gynaecological Oncology, Adana, Türkiye

Background

This presentation aims to report an iatrogenic bowel injury during vaginal specimen extraction in laparoscopic surgery and to evaluate its successful laparoscopic management.

Methods

A 52-year-old patient underwent laparoscopic surgery for endometrial cancer and sentinel lymph node mapping. During vaginal extraction of the uterus with a single-tooth tenaculum, an accidental bowel injury occurred. The defect was immediately repaired laparoscopically. An intraoperative air-leak (bubble) test was performed to confirm the integrity of the repair.

Results

The laparoscopic repair was successful, with a negative air-leak test confirming a secure seal. The patient's postoperative recovery was uneventful, and she was discharged without any gastrointestinal or surgical complications.

Conclusions

High surgical vigilance is essential during the vaginal extraction phase of laparoscopy. This case demonstrates that iatrogenic bowel injuries can be safely and effectively managed through a minimally invasive approach.

https://player.vimeo.com/video/1193627706?autoplay=1

ESGE35-0666 - VP106
Video in ePoster

Isolated Omental Leiomyoma Mimicking a Large Subserosal Uterine Myoma: A Diagnostic and Laparoscopic Challenge

Miroslav Nikolic[1], Slađana Mihajlović[1], Nikola Potparević[1], Diana Lerinc[1]
[1]KBC "dr Dragiša Mišović Dedinje", Gynaecology and obstetrics, Belgrade, Serbia

Background

A presumed subserosal uterine myoma may occasionally conceal a rare extrauterine origin. Isolated omental leiomyoma is an exceptional finding and represents a diagnostic pitfall, particularly in young women without previous surgery. Because preoperative imaging may not reliably define the site of origin, systematic laparoscopic assessment of the lesion's attachment, vascular pedicle and relationship to the uterus and adnexa is essential.

Methods

A 23-year-old nulliparous patient with mild abdominal pain was referred after transvaginal ultrasound suggested a large subserosal myoma measuring approximately 12 x 10 cm. Laparoscopy was performed for definitive diagnosis and minimally invasive treatment. Intraoperatively, the presumed uterine fibroid was identified as a well-circumscribed myomatous mass arising exclusively from the greater omentum, supplied by a distinct omental vascular pedicle. Gentle mobilisation allowed complete visualisation of a normal uterus, both ovaries and both fallopian tubes, without evidence of current or previous uterine attachment. After careful inspection, the omental pedicle was sealed and divided, and the mass was completely excised. The specimen was placed in a retrieval bag and removed by contained morcellation.

Results

The operative view demonstrated a diagnostic shift from a presumed subserosal uterine myoma to an isolated omental tumour. Complete laparoscopic excision was achieved without conversion. The uterus and adnexa were normal, clearly separate from the lesion, and required no intervention. Histopathology confirmed leiomyoma. The decisive intraoperative findings were exclusive omental localisation, a dedicated omental blood supply and complete separation from the uterus and adnexa. Final histopathology confirmed leiomyoma of size 16x15 cm.

Conclusions

Isolated omental leiomyoma is a rare diagnostic pitfall that may mimic a subserosal uterine myoma on preoperative imaging. Systematic laparoscopic assessment of the lesion's origin, vascular supply and relationship to the uterus and adnexa is crucial for correct diagnosis and safe treatment. In this case, laparoscopy enabled definitive anatomical diagnosis, complete excision of the omental mass and contained specimen extraction.

https://player.vimeo.com/video/1194536491?autoplay=1

ESGE35-0672 - VP108
Video in ePoster

Three probes, one goal: Safe dissection in deep infiltrating endometriosis

Muhterem Melis Canturk[1], Burak Giray[1], Oytun Turkkan[1], Dogan Vatansever[1], Cagatay Taskiran[1]
[1]Koc University Hospital,
Department of Obstetrics and Gynaecology / Division of Gynecologic Oncology, Istanbul, Türkiye

Background

Deep infiltrating endometriosis (DIE) involving the rectovaginal septum and adnexal structures represents one of the most surgically challenging manifestations of endometriotic disease. The complex anatomical distortion imposed by fibrotic implants demands a systematic operative strategy that ensures safe visceral mobilisation and complete lesion excision while preserving adjacent neurovascular and visceral structures.

Methods

This video article describes a structured, probe-assisted laparoscopic approach to advanced DIE, centered on the simultaneous deployment of three intracavitary probes — rectal, vaginal, and uterine. Following identification of the superior hypogastric nerve plexus and bilateral ureters at the pelvic brim, the right retroperitoneal space was developed to achieve safe ureteral lateralization prior to salpingectomy. Progressive bowel mobilization was performed using blunt and sharp dissection along the plane between the fibrotic nodule and the rectal muscularis propria.

Results

The tri-probe configuration enabled simultaneous triangulation of operative boundaries at the critical phase of rectovaginal dissection: the rectal probe defined the posterior rectal wall, the vaginal probe delineated the posterior vaginal fornix, and the uterine probe anteflexed the uterine corpus to open the rectovaginal space. Bilateral mesorectal dissection was completed with safe ureteral exclusion laterally. Final sharp excision achieved complete clearance of the endometriotic nodule, including associated intramural fibroids, with preservation of uterine integrity and without visceral injury.

Conclusions

The tri-probe technique offers a reproducible framework for navigating the anatomical complexity of advanced DIE. By providing simultaneous real-time tactile and visual feedback across all three compartments, this approach has the potential to reduce visceral injury, improve resection completeness, and enhance surgical reproducibility across varying levels of laparoscopic experience.

https://player.vimeo.com/video/1194961034?autoplay=1

ESGE35-0700 - VP112
Video in ePoster

Stepwise Total Laparoscopic Hysterectomy for Fibroid Uterus and Left Dermoid Cyst in a case with frozen Pelvis

Mohammed Mamdouh Saleh[1], *Hossam Abdou Elmansy*[2]
[1]*Suez canal university, Obstetrics and Gynaecology, ISMAILLIA, Egypt*
[2]*Helwan University Hospitals, OBS/GYN Department, Cairo, Egypt*

Background

Severe pelvic adhesions represent a major surgical challenge during minimally invasive gynecologic procedures due to distorted anatomy and increased risk of visceral injury. The presence of adnexal pathology associated with a bulky fibroid uterus further increases operative complexity. This video demonstrates a stepwise laparoscopic approach for safe adhesiolysis and successful completion of total laparoscopic hysterectomy in a highly adhesive pelvis.

Methods

A 56-year-old multiparous postmenopausal woman, para three vaginally presented with chronic pelvic pain. Preoperative evaluation revealed a bulky fibroid uterus associated with a large left adnexal lesion mostly dermoid cyst. Tumor markers were within the normal levels. Laparoscopic exploration demonstrated extensive pelvic and abdominal adhesions with severe distortion of pelvic anatomy. Complete adhesiolysis was first performed. Left salpingoophorectomy was done and the left adnexa was put high in the abdomen. The rest of hysterectomy was classic with delivery of the uterus & right adnexa through the vagina followed by the left adnexa.

Results

The procedure was successfully completed laparoscopically. No injuries occurred. The postoperative course was uneventful. Histopathological examination confirmed mature cystic teratoma associated with fibroid uterus

Conclusions

Complex pelvic pathology associated with severe adhesions can be safely managed laparoscopically in experienced hands. A standardized stepwise approach with meticulous adhesiolysis and careful anatomical dissection improves surgical safety and facilitates successful minimally invasive management even in highly challenging cases.

https://player.vimeo.com/video/1195195819?autoplay=1

ESGE35-0702 - VP113
Video in ePoster

Laparoscopic Hysterectomy and Paraaortic Bulky Lymphadenectomy in a Patient with Locally Advanced Cervical Cancer and Persistent Pyometra After Chemoradiotherapy

Nasuh Utku Doğan[1], Can Dinc[2], Selen Dogan[3]
[1]Dogan Gynaecology Clinic, Gynecologic Oncology, Antalya, Türkiye
[2]Akdeniz University, Gynaecology, Antalya, Türkiye
[3]Akdeniz University, Gynecologic Oncology, Antalya, Türkiye

Background

To present the feasibility and surgical outcomes of a minimally invasive approach in a complex patient with locally advanced cervical cancer, persistent pyometra after chemoradiotherapy, and suspicious bulky paraaortic lymphadenopathy.

Methods

A 62-year-old woman diagnosed with FIGO stage IIB cervical cancer underwent concomitant chemoradiotherapy. At the time of diagnosis, she had pyometra associated with foul-smelling vaginal discharge. Two months after completion of treatment, the pyometra and symptoms persisted. Positron emission tomography-computed tomography (PET-CT) demonstrated a bulky suspicious paraaortic lymph node. Following multidisciplinary tumor board evaluation, laparoscopic hysterectomy and paraaortic lymph node excision were planned. Prophylactic double-J ureteral stents were inserted preoperatively, and a total laparoscopic approach was performed.

Results

Total operative time was 180 minutes, with an estimated blood loss of 30 cc. The postoperative course was uneventful, and the patient was discharged on postoperative day 3. Final histopathological examination revealed a reactive paraaortic lymph node and chronic radiation-related inflammatory changes in the uterus without residual malignancy.

Conclusions

Minimally invasive surgery may be safely and effectively performed even in highly challenging situations such as post-radiotherapy pelvis, persistent pyometra, inflammatory status, and extensive intraabdominal adhesions. Careful patient selection and advanced laparoscopic expertise are essential for successful outcomes in these complex oncologic cases.

https://player.vimeo.com/video/1195208007?autoplay=1

ESGE35-0711 - VP115
Video in ePoster

Suspicious looking Endometrium in a Young patient -Hysteroscopic management using mechanical tissue removal system

Nosheen Rafaqat[1], Guldzhan Vorona[2], Wai Phyo Maung[2]
[1]none, Whittington Hospital, London, United Kingdom
[2]Whittington Hospital, Gynaecology, London, United Kingdom

Background

Diagnostic Hysteroscopy and tissue sampling is mandatory to confirm if Endometrial pathology is suspected. Mechanical hysteroscopic tissue removal system should be preferred over miniature bipolar electrodes to remove endometrial polyp.

Methods

Case summary:

A 33-year-old nulliparous woman (BMI 23) presented with heavy menstrual bleeding and intermenstrual bleeding for one year. Relevant history of polycystic ovarian syndrome and acne was on doxycycline treatment and planning to be commenced on oral retinoid therapy. She was sexually active, using barrier contraception only, Family history was significant for breast cancer. She requested copper intrauterine contraception and declined hormonal treatment.

Results

Transvaginal ultrasound

Demonstrated an anteverted uterus with an endometria thickness of 11 mm and a suspected endometrial polyp. Both ovaries appeared normal.

She was counselled regarding Hysteroscopy with levonorgestrel intrauterine system insertion; however, she opted for hysteroscopy with copper coil insertion under general anaesthesia.

Hysteroscopy Procedure & findings

After ensuring WHO safety checklist and sterile preparation, a 30° hysteroscope was introduced into the uterine cavity. Hysteroscopic examination revealed multiple small polyps creating an irregular and suspicious appearance of the endometrium.

A TruClear soft tissue shaver system was used for mechanical resection of the polyps and endometrial tissue. This technique allowed continuous tissue removal with excellent visualisation, minimal trauma, and negligible bleeding while restoring the uterine cavity effectively. A copper intrauterine device was inserted at the end of the procedure.

Histopathology result:

Histopathological examination demonstrated proliferative endometrium with benign endometrial polyps and no evidence of hyperplasia or malignancy.

Conclusions

This case highlights that suspicious hysteroscopic appearances in young women are commonly associated with benign pathology. Multiple small endometrial polyps can be highly symptomatic despite benign histology. Histopathological assessment remains essential for definitive diagnosis. The TruClear soft tissue shaver proved to be a safe, efficient, and minimally traumatic option for management of diffuse endometrial polyps.

https://player.vimeo.com/video/1195292336?autoplay=1

ESGE35-0712 - VP116
Video in ePoster

Anterior

Yasmine Chiba[1], Barouni Rihab[1], Mellouli Ferdaous[1], Hfaiedh Ines[1], Jaafar Wissal[1], Mourali Mechaal[1]
[1]Habib Bougatfa University Hospital in Bizerte, Department of Obstetrics and Gynaecology, Bizerte, Tunisia

Background

To describe a standardized surgical technique for the anterior step of laparoscopic sacrocolpopexy (promontofixation), focusing on safe vesicovaginal dissection and optimal mesh placement in a patient with stage III anterior compartment prolapse.

Methods

We report the case of a 58-year-old postmenopausal multiparous woman (G3P3), with a history of foetal macrosomia, overweight, and chronic heavy lifting, who presented with a symptomatic vaginal bulge. Clinical examination including POP-Q assessment revealed a stage III anterior compartment prolapse (cystocele), without urinary leakage on cough stress testing.

The anterior compartment dissection was performed laparoscopically. After cranial retraction of the bladder, the vesicouterine peritoneum was incised to access the vesicovaginal space. A systematic dissection was carried out in a caudal and lateral direction with stepwise coagulation of the lateral vesicovaginal pillars to maintain a bloodless field.

Results

The correct avascular plane was identified by the characteristic “cobweb-like” appearance of the loose areolar tissue, allowing safe separation of the bladder from the anterior vaginal wall. The vaginal uterine manipulator facilitated optimal anatomical orientation and confirmation of the correct dissection plane. The anterior vaginal wall was progressively exposed, presenting a whitish fibrous aspect. A pre-cut polypropylene mesh strip was then positioned and secured to the anterior vaginal wall using four to five non-transfixing Ethibond sutures, ensuring stable fixation.

Conclusions

The anterior step of laparoscopic sacrocolpopexy is a reproducible technique based on meticulous vesicovaginal dissection along the avascular plane, allowing safe bladder mobilization and secure mesh fixation. This standardized approach contributes to effective restoration of anterior pelvic support in stage III cystocele.

https://player.vimeo.com/video/1195292988?autoplay=1

ESGE35-0713 - VP117
Video in ePoster

Lateral window technique for safe bladder dissection in severe vesicouterine adhesions following previous caesarean sections during subtotal laparoscopic hysterectomy of a large symptomatic fibroid uterus

Arsen Karanfilovski[1], *Mohamed Abuzaid*[1]
[1]*St. Vinzenz Hospital, Obstetrics & Gynaecology, Hanau, Germany*

Background

The aim of this report is to demonstrate the importance of individualized preoperative planning, strategic intraoperative flexibility, and the use of alternative surgical approaches to achieve safe and effective subtotal laparoscopic hysterectomy in patients with markedly changed pelvic anatomy due to extensive post-surgical adhesions and a large fibroid uterus.

Methods

A 43-year-old obese G2P2 patient with two previous caesarean sections presented with a large symptomatic fibroid uterus causing abdominal pressure symptoms and therapy-refractory menometrorrhagia despite levonorgestrel-releasing intrauterine device (LNG-IUD) treatment (meanwhile lost IUD). Imaging demonstrated a markedly enlarged uterus with a dominant 14-cm posterior wall myoma and extensive vesicouterine adhesions extending toward the umbilicus, initially interpreted as a possible paraumbilical hernia containing adipose tissue.Considering the patient's completed family planning and significant symptom burden, laparoscopic subtotal hysterectomy with bilateral salpingectomy, extensive adhesiolysis were planned and performed.

Results

In accordance with the preoperative surgical strategy, pneumoperitoneum was established via Palmer's point because of the widespread adhäsions and the large fibroid uterus extending slightly above the level of the umbilicus, allowing safe supraumbilical placement of the optical trocar. Intraoperatively, extensive vesicouterine adhesions significantly obscured the surgical field and distorted normal pelvic anatomy. Therefore, a targeted adhesiolysis using the lateral window technique was performed to safely mobilise the bladder and restore clear anatomical orientation of the pelvic organs and anatomical landmarks. The procedure was completed as planned without intraoperative or postoperative complications. Operative time was slightly above two hours, mainly due to prolonged morcellation of the large uterus. Estimated blood loss was minimal. The postoperative course was uneventful, and the patient was discharged on postoperative day two.

Conclusions

This case demonstrates that individualized operative planning, strategic intraoperative flexibility, and the use of alternative laparoscopic techniques such as the lateral window approach enable safe minimally invasive management of large symptomatic fibroid uteri in the presence of severe vesicouterine adhesions following previous caesarean sections. Tailored adaptation to distorted pelvic

anatomy facilitated successful completion of the procedure with minimal blood loss, no perioperative complications, and rapid postoperative recovery.

https://player.vimeo.com/video/1195320892?autoplay=1

ESGE35-0715 - VP118
Video in ePoster

Artificial Intelligence-Assisted Interpretation of Adnexal Masses: A Case-Based Comparison of ChatGPT and Gemini with Final Histopathology (TR-MIGS Study)

Oğuz Arslan[1], Rümeysa Belen Gümüş[1], Muhammed Eren Aksun[1], Sefa Kurt[1], Çağatayhan Öztürk Salih Taşkın[2], İbrahim Yalçın[1]
[1]Dokuz Eylül University School of Medicine,
Division of Gynaecologic Oncology- Department of Obstetrics and Gynaecology, Izmir, Türkiye
[2]Ankara University School of Medicine,
Division of Gynaecologic Oncology- Department of Obstetrics and Gynaecology, Ankara, Türkiye

Background

To evaluate the performance of artificial intelligence models in the interpretation of adnexal masses by comparing the predictions of ChatGPT and Gemini with final histopathological diagnoses in a case-based series.

Methods

Ten consecutive gynecologic cases involving adnexal masses were retrospectively evaluated. Clinical findings, serum CA-125 levels, ultrasonographic imaging findings were presented to ChatGPT and Gemini for independent interpretation. AI-generated predictions were compared with final histopathological diagnoses. Exact diagnostic concordance, clinically relevant (benign versus malignant/borderline classification) accuracy were assessed. Patient data were anonymized prior to analysis, and written informed consent was obtained from all participants.

Results

Among the 10 evaluated cases, exact histopathological concordance was achieved in 2 cases (20%) by both ChatGPT and Gemini. Benign versus malignant/borderline classification accuracy was 60% (6/10) for ChatGPT and 70% (7/10) for Gemini. Both models demonstrated accurate prediction in cases of endometrioma. However, important diagnostic discrepancies were observed in selected cases, including ectopic pregnancy. Both AI models were also unsuccessful in accurately identifying adnexal mass pathology in cases associated with intrauterine pregnancy. Gemini demonstrated relatively higher performance in distinguishing neoplastic from benign lesions.

Conclusions

Artificial intelligence models demonstrated moderate performance in the evaluation of adnexal masses, with limited exact histopathological concordance but higher clinically relevant classification accuracy. Although both ChatGPT and Gemini showed potential utility in gynecologic imaging interpretation, important diagnostic inaccuracies remain.

https://player.vimeo.com/video/1195331217?autoplay=1

ESGE35-0760 - VP123
Video in ePoster

Vaginal Natural Orifice transluminal endoscopic surgery (vNOTES) for managing gynecologic emergencies

Patrycja Gumuła[1], Katarzyna Bień Dziekońska[1], Tadeusz Issat[1]
[1]Institute of Mother and Child, Gynaecology, Warsaw, Poland

Background

Vaginal natural orifice transluminal endoscopic surgery (vNOTES) is a novel minimally invasive surgical technique that utilizes the vaginal canal as a natural orifice to gain access to the peritoneal cavity for various gynecologic procedures. This innovative approach combines the benefits of natural orifice surgery with the precision of endoscopic visualization and instrumentation, providing an alternative to conventional laparoscopy and laparotomy that avoids abdominal incisions and associated complications

Methods

The procedure performed was a vNOTES salpingectomy for a tubal ectopic pregnancy.

Under general anesthesia, the patient was placed in the lithotomy position. Sterile vaginal preparation was carried out, and a Foley catheter was inserted.

After adequate exposure of the cervix, a posterior colpotomy was created to gain access to the peritoneal cavity through the posterior vaginal fornix. A specialized vaginal access port was then inserted, and pneumoperitoneum was established using carbon dioxide insufflation, providing an optimal working space for endoscopic surgery.

Using a laparoscope and endoscopic instruments introduced through the vaginal port, a systematic exploration of the pelvis was performed. The affected fallopian tube containing the ectopic pregnancy was identified, and the contralateral adnexa together with surrounding pelvic structures were carefully evaluated.

The mesosalpinx and associated vascular pedicles were coagulated and divided using advanced bipolar energy devices, allowing safe dissection with meticulous hemostasis throughout the procedure. Due to the condition of the affected tube, a complete salpingectomy was performed with removal of the fallopian tube containing the ectopic pregnancy.

Once fully mobilized, the resected fallopian tube with the ectopic pregnancy was removed transvaginally through the vaginal access site. The pelvic cavity was irrigated and carefully inspected. Final inspection confirmed satisfactory hemostasis and excluded injury to adjacent pelvic organs, including the bowel, bladder, ovaries, and contralateral fallopian tube.

Results

No visible abdominal scars
Minimally invasive surgical approach

Lower use of analgesics after surgery
Shorter time of hospitalization

Conclusions

Better cosmetic outcome and higher patient satisfaction

https://player.vimeo.com/video/1195438420?autoplay=1

ESGE35-0761 - VP124
Video in ePoster

When Robotics Meets Hysteroscopy: A Synergistic Approach to Isthmoplasty

Giuseppe D'Angelo[1], Mario Ascione[2], Fabiola Nardelli[2], Danilo Borrelli[2],
Gaby Moawad[3], Luigi Della Corte[2]
[1]University of Naples Federico II,
Department of Public Health- University of Naples Federico II- Naples- Italy, Naples, Italy
[2]University of Naples Federico II, Department of Public Health, Naples, Italy
[3]The George Washington University Washington,
Department of Obstetrics and Gynaecology- Center for Endometriosis and Advanced Pelvic Surgery, Washington, USA

Background

To demonstrate a standardized, combined robotic-assisted and hysteroscopic approach for the precise surgical management of a severe caesarean scar defect (CSD).

Methods

We present the surgical case of a 33-year-old patient with secondary infertility, chronic cyclic pelvic pain, and a large CSD. Preoperative three-dimensional transvaginal ultrasound highlighted a severely reduced residual myometrial thickness (RMT) of 1.5 millimeters. This critical measurement contraindicated a purely hysteroscopic approach, dictating the need for a combined surgical repair. Following robotic adhesiolysis and excision of concurrent peritoneal endometriosis, a simultaneous diagnostic hysteroscopy was performed. The hysteroscope acted as a dynamic intrauterine manipulator to distend the defect from within. By activating the robotic near-infrared fluorescence imaging, the transillumination provided by the hysteroscope clearly mapped the anatomical boundaries of the niche. This enabled the precise excision of the fibrotic scar tissue while safely preserving the surrounding healthy myometrium. A tension-free, double-layer myometrial closure was performed using a barbed self-locking suture. The procedure concluded with a final hysteroscopic evaluation and the application of an anti-adhesion barrier.

Results

The synergistic application of hysteroscopic transillumination and robotic near-infrared imaging provided enhanced depth perception and accurate tissue differentiation. This approach strictly avoided unnecessary wide resections. The double-layer reconstruction successfully restored the functional anatomy of the lower uterine segment. Post-operative transvaginal ultrasound confirmed the complete anatomical restoration of the defect and a significantly increased RMT. The patient experienced an uneventful recovery.

Conclusions

Integrating a robotic platform with concurrent hysteroscopy maximizes surgical ergonomics and precision during complex CSD repairs. This dual-visualization strategy optimizes targeted tissue

excision and myometrial reconstruction, offering a safe, tailored approach to improve reproductive outcomes in patients with severe isthmocele.

https://player.vimeo.com/video/1195437953?autoplay=1

ESGE35-0762 - VP125
Video in ePoster

Robotic approach for large abdominal wall Endometrioma: Is it feasible?

Fernanda Dishchekenian[1], Paula Medina[2], Amir Zeide[3], Fernanda Okita[2]
[1]Einstein Hospital Israelita, Gynaecology, Sao Paulo, Brazil
[2]Hospital Moriah, Gynaecology, Sao Paulo, Brazil
[3]Hospital Moriah, Gastrointestinal surgery, Sao Paulo, Brazil

Background

Patient ACGC, 46 years old, presenting chronic abdominal pain and dyspareunia for the past three years, using hormonal intrauterine device. One caesarean section in the past. Pelvic MRI showed an anteverted uterus with an estimated volume of 113 cm³ with adenomyosis. There was a lesion in the midline hypogastric abdominal wall, measuring 6.0 × 3.9 × 2.2 cm, involving the full thickness of the rectus abdominis muscle, with peritoneal in contact with fundal uterine serosa. In addition, it demonstrated a vesical peritoneal thickening.The endometrioma nodule was palpable, poorly mobile, and adherent to the deeper tissue planes in physical examination. Patient was eligible for robot-assisted total hysterectomy and abdominal wall endometrioma resection.

Methods

Patient was placed in a semi gynecological position, under general anesthesia, with arms alongside the body and legs eighty grades abducted in adjustable stirrups. Four robotic portals were positioned: one in the umbilical scar for the optics, two on the right and left iliac fossae and the last one on the right flank. Surgery began with endometriosis lesions resection in the posterior compartment peritoneum followed by hysterectomy, and bilateral salpingectomy. The next step was the endometrioma abdominal wall resection The nodule was deeply infiltrative, extending into the rectus abdominis muscle. Following resection, a continuous two-layer suture was performed to approximate the musculature and a monofilament polyester mesh was placed to reinforce the weakened abdominal wall. The endometrioma specimen was extracted by the vagina before colporrhaphy.

Results

Surgical duration was three hours, with minimal blood loss and no complications. Patient had satisfactory postoperative clinical evolution, discharged on the first postoperative day. Pathology reports confirmed endometriosis lesions and adenomyosis.

Conclusions

This case report demonstrates that the robotic platform may enable the resection of large abdominal wall endometrioma. In addition, we could observe the benefits in improvement of postoperative recovery and the achievement of better aesthetic outcomes.

https://player.vimeo.com/video/1195441254?autoplay=1

ESGE35-0765 - VP126
Video in ePoster

Florid Cystic Endosalpingiosis Mimicking Pelvic Malignancy: A Rare Case Report and Robotic Surgical Management Strategy

Guldzhan Vorona[1], Preethi Jacob[2], Pryia Narayanan[3], Ahmed Karim[4], Osama Naji[5]
[1]UCLH/Whittington Hospital, Minimal Access gynaecological surgery, LONDON, United Kingdom
[2]Whittington Hospital, Minimal Access Gynaecological Surgery, London, United Kingdom
[3]University College London Hospitals, Radiology, London, United Kingdom
[4]St Georges University Hospital, Colorectal Surgical department, London, United Kingdom
[5]St Thomas Hospital, Minimal Access Gynaecological Surgery, London, United Kingdom

Background

Florid cystic endosalpingiosis (FCE) is a rare, tumour-like proliferation of tubal epithelium that can closely mimic advanced pelvic malignancy.
This case illustrates the diagnostic challenges and robotic surgical management of FCE coexisting with endometriosis in a structurally distorted pelvis, with near-infrared indocyanine green (ICG) imaging used to delineate and protect the ureters and bladder.

Methods

A 53-year-old woman, menopausal since age 42, presented with unscheduled bleeding on hormone replacement therapy, pelvic pain and bloating.
Her surgical history included laparoscopic ovarian cystectomy prior to embarking on pregnancy and a complex midline caesarean section at 31 weeks' gestation for bilateral adnexal torsion, resulting in right oophorectomy and cystectomy of the left ovary.
Imaging demonstrated adenomyosis, uterine fibroids, a left adnexal mass and extensive thin-walled multilocular cysts enveloping the posterior uterus and Pouch of Douglas.
In view of her symptoms, anxiety and the complex imaging findings, she underwent robotic-assisted total hysterectomy with extensive adhesiolysis.

Results

Robotic surgery enabled precise adhesiolysis and restoration of pelvic anatomy, revealing a highly vascular uterus with multiple translucent, serous fluid–filled cysts over the posterior wall.
Intraoperative ICG fluorescence enhanced real-time visualisation of the ureters and bladder, minimising the risk of urinary tract injury.
Histology confirmed benign FCE with focal endometriosis extending into the myometrium and psammomatous calcifications, without atypia.

Conclusions

FCE is a rare benign entity that can present as a radiologically and macroscopically malignant appearing multicystic pelvic mass. Robotic-assisted surgery provides superior three-dimensional visualisation and dexterity, supporting safe anatomical restoration and definitive excision in the setting of extensive adhesions and complex multicystic disease.

https://player.vimeo.com/video/1195514330?autoplay=1

ESGE35-0770 - VP127
Video in ePoster

Robot-assisted resection of diaphragmatic endometriosis

Alice Moïse[1]
[1]*CHU Liege, Gynaecology, Liège, Belgium*

Background

Large diaphragmatic nodule of endometriosis resected by robot procedure.

Methods

Surgery performed by Dr. Gaby Moawad, Laurent de Landsheere, and Michelle Nisolle.

This is a 30-year-old female patient presenting with catamenia-related (menstrual) right shoulder pain (scapulalgia).

The MRI shows a 24 mm diaphragmatic nodule, involving the right diaphragm and in contact with hepatic segment VII.

The surgery was performed using a robot-assisted approach, with the robot positioned for thoracic surgery.

Diaphragmatic endometriosis is a rare location for extra-pelvic endometriosis.

Step 1: Verification of pelvic status

• No pelvic endometriosis identified. Step 2: Opening of the round ligament and the falciform ligament of the liver

1. Identification of both layers of the falciform ligament.
2. Identification line of the muscular portion of the diaphragm.

Step 3: Hepatic mobilization

• Hepatic mobilization relative to the lesion and opening of the right triangular ligament. Step 4: Resection of a nodule

1. Resection of a nodule from the muscular portion of the diaphragm.
2. Identification of healthy margins, resection, and opening of the pleural cavity.

Step 5: Exploration of the pleural cavity

1. Identification of lesions with an inflammatory appearance that could correspond to superficial endometriosis.
2. Coagulation of these lesions to avoid resection.
3. Visualization of the lung.

Step 6: Diaphragm closure using V-Loc 3.0

• For the final portion of the diaphragm, a purse-string suture is performed using V-Loc 3.0, allowing suction to be introduced through the remaining incision.

Step 7: Evacuation of the pneumothorax

1. The anaesthesiologist is asked to create positive pressure (hyperpressure) in the patient's thoracic cavity while simultaneously suctioning the contents of the pleural cavity. This allows the lung to re-expand to its normal size and prevents a residual pneumothorax.

2. Closure of the diaphragm is completed simultaneously with the removal of the suction catheter.

Results

Step-by-step surgery for diaphragmatic endometriosis

Conclusions

Even gynaecologists can see a lung.

https://player.vimeo.com/video/1195534000?autoplay=1

ESGE35-0795 - VP129
Video in ePoster

Surgical Management of a Giant Parasitic Leiomyoma in the Canal of Nuck

Anett Larm[1], Jüri Piirsoo[1], Johanna Sell[1], Katrin Kressel[2], Georgi Džaparidze[3]
[1]West Tallinn Central Hospital, Gynaecology, Tallinn, Estonia
[2]West Tallinn Central Hospital, Radiology, Tallinn, Estonia
[3]East Tallinn Central Hospital, Pathology, Tallinn, Estonia

Background

Parasitic leiomyoma is a rare benign smooth-muscle tumor located outside the uterus with an independent blood supply. The canal of Nuck is a rare site of pathology in females and may present as an inguinal or labial mass.

We present the surgical management of a giant parasitic leiomyoma located in the canal of Nuck. Informed consent for presentation and publication was obtained from the patient.

Methods

In this video, we present a 58-year-old woman with a painless left labial mass. The patient had previously undergone total abdominal hysterectomy for uterine fibroids in November 2024. The size of the uterus was approximately 20-21 weeks of gestation.

Pelvic MRI demonstrated a 7.5 × 8 × 22 cm mass extending through the left inguinal canal into the canal of Nuck. Retrospective review of CT imaging from July 2024 demonstrated continuity between the lesion and the uterus, suggesting a pedunculated parasitic leiomyoma.

Results

A 10 cm inguinal incision was made following the Lichtenstein approach. The tumor was carefully dissected from the surrounding tissues. Feeding vessels originating from the inguinal canal were ligated and divided. The 20 × 12 × 6 cm mass was completely excised and removed without complications. The subcutaneous tissue was approximated in multiple layers, the skin was closed with a running mattress suture. The postoperative course was uneventful. Histopathological examination confirmed leiomyoma.

The video demonstrates identification of feeding vessels within the inguinal canal and complete excision of the lesion while preserving surrounding structures.

Conclusions

Parasitic leiomyoma involving the canal of Nuck is extremely rare, with only a few cases described in the literature. This video demonstrates the diagnostic challenges and surgical management of a large extrauterine leiomyoma presenting as an inguinal-labial mass.

https://player.vimeo.com/video/1195611448?autoplay=1

ESGE35-0796 - VP130
Video in ePoster

Two-Step Hysteroscopic Management of a Large Type 2 Leiomyoma with GnRH Analogue Therapy Between Procedures in a Perimenopausal Nulliparous Woman

Salih Yilmaz[1], *Ezgi Sancakli*[2]
[1]*Alle Clinic, Obstetrics & Gynaecology, Istanbul, Türkiye*
[2]*Acibadem Altunizade Hospital, Obstetrics&Gynaecology, Istanbul, Türkiye*

Background

Submucosal leiomyomas are among the leading causes of abnormal uterine bleeding and may significantly impair quality of life. Hysteroscopic myomectomy is considered the gold standard treatment for symptomatic submucosal fibroids. However, large type 2 leiomyomas with deep intramural extension remain surgically challenging. We present a two-step hysteroscopic management of a large type 2 leiomyoma which has Lasmar score 6 in a perimenopausal nulliparous woman desiring uterine preservation despite previous recommendation for hysterectomy.

Methods

A 47-year-old nulliparous woman (G3P0A3) presented with severe abnormal uterine bleeding causing iron deficiency anaemia and significant impairment in quality of life. Her medical history was significant only for hypertension. Transvaginal ultrasonography demonstrated an enlarged uterus containing a 52 × 48 mm FIGO type 2 leiomyoma with deep intramural extension; both ovaries appeared normal. Following detailed counselling regarding management options, including hysterectomy, the patient opted for a uterus-preserving hysteroscopic approach.

An initial hysteroscopic myomectomy was performed by using a tissue removal system. Due to the firm consistency and marked intramural component of the leiomyoma, complete resection could not be achieved during the first procedure; therefore, a planned two-stage hysteroscopic approach was adopted. No intraoperative or postoperative complications occurred.

Subsequent to the first procedure, interval GnRH analogue therapy was used to decrease the size of the residual leiomyoma. The duration of GnRH analogue therapy was limited to 4 months due to hypertensive adverse effects in a patient with known hypertension. A second-stage hysteroscopic resection was subsequently performed, resulting in complete excision of the leiomyoma. No intraoperative or postoperative complications occurred.

Results

Following medical pretreatment with GnRH analogue, complete hysteroscopic excision of the residual leiomyoma was successfully achieved during the second-stage procedure. The patient experienced significant improvement in abnormal uterine bleeding, and hysterectomy was avoided.

Conclusions

Large type 2 leiomyomas with substantial intramural extension may be effectively managed using a staged hysteroscopic approach in selected patients desiring uterine preservation. Adjunctive

gonadotropin-releasing hormone agonist therapy may facilitate complete resection and improve surgical feasibility in technically challenging cases.

https://player.vimeo.com/video/1195615295?autoplay=1

ESGE35-0804 - VP131
Video in ePoster

Robotic Excision of a Cervical Stump Following Subtotal Hysterectomy for Endometriosis: A Stepwise Video Demonstration

Danya Chandrakumar[1], *Yemi Coker*[1]
[1]*Barking- Havering and Redbridge University Hospitals NHS Trust, Gynaecology, London, United Kingdom*

Background

Following subtotal hysterectomy for endometriosis, patients may continue to experience significant pelvic pain due to persistent disease, adhesions or pathology involving the retained cervical stump. Surgical excision of the cervical stump is often complex, as previous pelvic surgery may obscure anatomical planes and increase the risk of bladder or ureteric injury. This video demonstrates a stepwise robotic technique for cervical stump excision.

Methods

A 42-year-old patient with severe ongoing pelvic pain was referred following a laparoscopic subtotal hysterectomy for endometriosis performed at another centre. She had subsequently undergone unilateral laparoscopic salpingo-oophorectomy for ovarian torsion. Despite previous surgery, her symptoms persisted and significantly affected her quality of life. Following specialist assessment and counselling, she underwent robotic excision of the cervical stump with completion salpingo-oophorectomy.

Results

The video outlines key operative steps and safety considerations in managing a cervical stump in the context of previous endometriosis surgery. Emphasis is placed on safe entry, assessment of adhesions and insertion of the uterine/cervical manipulator under direct laparoscopic vision to reduce the risk of visceral injury. Early recognition of anatomical landmarks, careful delineation of the bladder reflection and systematic development of the vesicocervical plane are key. Monopolar scissors are used to mobilise the bladder away from the anterior cervix while maintaining close attention to tissue planes. The cervical stump is then excised with ongoing awareness of the ureteric course. Adjunctive rigid cystoscopy and intraureteric indocyanine green are used to aid ureteric identification in a high-risk re-operative pelvis.

Conclusions

This video highlights a clinically relevant and technically challenging scenario in endometriosis surgery. A stepwise approach, meticulous bladder dissection, ureteric mapping and repeated intraoperative reassessment are essential to achieving safe excision of the cervical stump in patients who may have altered pelvic anatomy following their index surgery.

https://player.vimeo.com/video/1195623470?autoplay=1

ESGE35-0835 - VP133
Video in ePoster

Laparoscopic Excision of Rectovaginal Nodule with Obliterated Cul-de-Sac and Bilateral Endometriomas: A Step-by-Step Approach

Fatih Sendag[1], Kubra Bagci[2], Cihan Yuksel[2]
[1]Ege University, Department of Obstetrics and Gynaecology, Izmir, Türkiye
[2]Private Clinic, Obstetrics and Gynaecology, Izmir, Türkiye

Background

To demonstrate a systematic laparoscopic approach for complete excision of a rectovaginal endometriotic nodule in the presence of bilateral endometriomas with kissing ovary configuration and obliterated pouch of Douglas

Methods

A 31-year-old woman (G1P1, normal spontaneous vaginal delivery) presented with severe dysmenorrhoea, dyspareunia and constipation. Preoperative transvaginal ultrasound and MRI pelvis confirmed bilateral ovarian endometriomas (right 4 cm, left 5 cm; #ENZIAN O3 bilateral) with kissing ovary configuration, complete obliteration of the pouch of Douglas, and a rectovaginal nodule (3.5 cm, #ENZIAN A3) with no rectal wall invasion. Laparoscopic excision was performed following a structured step-by-step approach: sigmoid mobilisation, bilateral ovarian mobilisation and suspension, bilateral ureterolysis with excision of endometriotic implants overlying both ureters, bilateral ovarian cystectomy, pararectal space development with lateral-to-medial dissection, uterosacral ligament excision, rectovaginal nodule excision with posterior colpectomy, and laparoscopic vaginal closure.

Results

Complete excision of all visible disease was achieved. No intraoperative or postoperative complications were observed. Total operative time was 190 minutes with an estimated blood loss of 60 mL. The patient was discharged on postoperative day one. At one-year follow-up, complete resolution of dysmenorrhoea, dyspareunia and constipation was reported with no recurrence of symptoms.

Conclusions

Rectovaginal nodule excision in the setting of kissing ovaries and obliterated cul-de-sac is feasible laparoscopically when a systematic anatomy-first approach is applied. Bilateral ureterolysis and ovarian suspension are critical enabling steps. This video provides a reproducible surgical framework for the management of this challenging presentation of deep infiltrating endometriosis.

https://player.vimeo.com/video/1195676871?autoplay=1

ESGE35-0839 - VP134
Video in ePoster

Office Hysteroscopic Treatment of a Nonviable Angular Pregnancy

Ece Aksakal[1], *Irem Usta Korkut*[1], *Bulent Urman*[1]
[1]*American Hospital, Obstetrics and Gynaecology, Istanbul, Türkiye*

Background

Angular pregnancy is implantation in a lateral uterine angle, medial to the uterotubal junction, and is frequently confused with interstitial pregnancy. This video demonstrates primary office hysteroscopic resolution of a nonviable angular pregnancy under conscious sedation, avoiding methotrexate, laparoscopy and general anaesthesia.

Methods

The patient was a 43-year-old nulligravid woman who conceived after in vitro fertilisation with preimplantation genetic testing. Serum beta-human chorionic gonadotropin followed an atypical triphasic course, peaking at 1550 mIU/mL despite a small empty gestational sac of approximately six to eight millimetres in the left uterine angle, without yolk sac or fetal pole. Office hysteroscopy was performed with a 5 French small-bore hysteroscope. The cavity was entered through the endocervical canal. The left tubal ostium was obstructed by the gestation, with increased vascularisation surrounding it, while the right ostium was clearly visible. The borders of the gestational sac were delineated with a needle bipolar cutting electrode. The products of conception were grasped and gently extracted, and minimal residual tissue was removed on second and third passes. The left cornu and ostium were confirmed normal, bleeding was minimal, and anti-adhesion gel was instilled.

Results

The procedure was completed in a single office session without complications. Histopathology confirmed chorionic villi and trophoblast. Beta-human chorionic gonadotropin fell to 51 then 2 mIU/mL, confirming complete resolution.

Conclusions

Office hysteroscopy with a small-bore hysteroscope under conscious sedation enables precise, uterus-sparing, vision-guided resolution of selected nonviable angular pregnancies. Delineation of the sac borders before extraction allows safe management of modest periostial vascularity in an outpatient setting. Accurate differentiation of angular from interstitial implantation is essential for safe case selection.

https://player.vimeo.com/video/1195684620?autoplay=1

ESGE35-0850 - VP136
Video in ePoster

Intraoperative Ultrasound as a Safety Tool for Fertility-Preserving Hysteroscopic Septoplasty

Thaís Pastana[1], Fernanda Okita[1], Fernanda Dishchekenian[1], Paula Medina[1], Tainá Rocha[1], Mariano Tamura[1]
[1]Hospital Moriah, Department of Gynaecology, São Paulo, Brazil

Background

To demonstrate the safety and feasibility of combining robotic-assisted laparoscopy, hysteroscopic septoplasty, and intraoperative laparoscopic ultrasound guidance for treatment of a partial uterine septum associated with minimal endometriosis in a patient with recurrent implantation failure.

Methods

We present a surgical video of a 42-year-old nulligravid patient with reproductive desire and multiple failed in vitro fertilization attempts. Preoperative imaging revealed a partial uterine septum associated with mild posterior compartment endometriosis. Diagnostic hysteroscopy demonstrated two hemi-cavities separated by a partial septum, with no additional intracavitary abnormalities. Robotic-assisted laparoscopy using the Da Vinci® platform identified superficial endometriotic implants in the retrocervical and posterior compartments. Adhesiolysis and excision of lesions were performed with preservation of both ureters. A laparoscopic ultrasound probe was then introduced through the right iliac fossa trocar and positioned over the anterior uterine wall. Real-time intraoperative ultrasound guided the hysteroscopic septoplasty. Using bipolar energy with a Collins electrode, the septum was progressively incised under continuous ultrasound monitoring. This approach enabled precise identification of septal margins and myometrial thickness, allowing controlled resection while minimizing the risk of uterine perforation.

Results

The procedure was completed without complications or significant bleeding. A unified uterine cavity with clear visualization of both tubal ostia was achieved. Intraoperative ultrasound improved surgical precision and safety during septal resection, while robotic-assisted laparoscopy enabled meticulous dissection and preservation of pelvic anatomy.

Conclusions

Intraoperative laparoscopic ultrasound is a valuable adjunct during hysteroscopic septoplasty, enhancing safety and precision. Combined with robotic-assisted laparoscopy, this minimally invasive approach may optimize uterine reconstruction and improve reproductive outcomes in patients with recurrent implantation failure.

https://player.vimeo.com/video/1195700207?autoplay=1

ESGE35-0851 - VP137
Video in ePoster

Robotic management of bilateral hydrosalpinx and severe pelvic adhesions in an infertile patient

Paula Medina Poeta Fermino[1], *Thais Pastana*[1], *Taina Rocha*[1], *Fernanda Dishchekenian*[1], *Mariano Tamura*[1], *Fernanda Okita*[1]
[1]*Hospital Moriah, Gynaecology and Minimally Invasive Gynecologic Surgery, São Paulo, Brazil*

Background

This video demonstrates the robotic management of severe pelvic adhesive disease associated with bilateral hydrosalpinx and infertility in a 36-year-old nulliparous patient with multiple prior abdominal surgeries during childhood due to congenital intestinal stenosis. The patient presented with primary infertility, previous failed in vitro fertilization (IVF) attempt, cyclic pelvic pain, and recent dyspareunia. Preoperative imaging revealed bilateral hydrosalpinx, extensive pelvic adhesions, retrocervical and uterosacral ligament thickening, as well as presacral fascia and mesorectal fibrosis, suggesting complex pelvic disease with significant anatomical distortion.

Methods

The procedure began with hysteroscopic evaluation, endometrial biopsy for histologic and immunohistochemical assessment, and hysteroscopic excision of an endocervical polyp. Robotic laparoscopy demonstrated severe adhesions involving the bowel, uterus, adnexa, and pelvic sidewalls, resulting in complete distortion of pelvic anatomy.
The video highlights key surgical steps, including careful adhesiolysis, posterior peritoneal and retrocervical dissection, progressive development of anatomical planes, ureter identification, restoration of pelvic anatomy, bilateral salpingectomy, ovarian preservation, and protected specimen retrieval using a specimen retrieval bag.
Special attention is given to surgical strategies adopted in a hostile pelvis scenario, emphasizing meticulous anatomical dissection, traction-countertraction techniques, and the role of pneumoperitoneum in facilitating safer development of surgical planes.

Results

The procedure was completed without intraoperative complications, with estimated blood loss of 20 mL. Total operative time was 4 hours, and the patient was discharged on postoperative day one.

Conclusions

This case demonstrates that robotic surgery represents a safe and effective approach for complex pelvic adhesiolysis and fertility-oriented surgery in infertile patients with severe pelvic adhesive disease and distorted pelvic anatomy.

https://player.vimeo.com/video/1195701994?autoplay=1

ESGE35-0860 - VP138
Video in ePoster

Robot-assisted laparoscopic hysterectomy of a bulky fibroid uterus: A step-by-step demonstration of the benefits of robotic assistance

Sarah Bennet[1,2], Kostantinos Lamprou[1], Olivia Raglan[1]
[1]Chelsea and Westminster Hospital, Obstetrics and Gynaecology, London, United Kingdom
[2]Imperial College London, Department of Metabolism- Digestion and Reproduction, London, United Kingdom

Background

Laparoscopy has significant benefits over the open approach in gynaecological surgery, including fewer complications, a reduced hospital stay and a quicker recovery[1]. However, its use is limited in cases of large fibroid uteri where the bulky uterus can obscure the view and limit access to the pelvis. In addition, the size and weight of the uterus can make uterine manipulation challenging. Robotic assisted laparoscopy can overcome these issues due the improved dexterity provided by hinged instruments as well as providing the benefit of superior ergonomics for the surgeon[2].

Methods

We present a case of a 46-year-old woman, undergoing robotic assisted total laparoscopic assisted hysterectomy and bilateral salpingectomy for a fibroid uterus. The patient presented with symptoms of menorrhagia, abdominal distension, constipation and weight gain. She had no medical history of note. Her surgical history included two previous lower segment caesarean sections. Imaging showed a 12 x 10 x 11 cm submucosal fibroid projecting into the uterine cavity.

Results

A step-by-step approach was performed, with careful identification of anatomical landmarks, adhesiolysis to restore anatomy and careful identification and coagulation of abnormal vasculature. The hinged instruments of the robot allowed safe visualisation of the uterine pedicles and dissection of the bladder, where the bulky uterus would have limited straight-stick laparoscopy. The uterus was removed vaginally using cold knife morcellation in an endoscopic bag to avoid seeding. Blood loss of 100mls was noted with the uterus weighing 845g. The patient was discharged home the same day.

Conclusions

Robot assisted laparoscopy can be safely utilised to perform laparoscopic surgery in cases of bulky uteri which would otherwise require laparotomy. This has benefits to both the patient, in terms of complication rates and recovery, as well as for the surgeon due to the ergonomic benefits of robot assisted surgery over straight stick laparoscopy, in particular with lengthy complex cases.

References

1. *Walker JL, Piedmonte MR, Spirtos NM, Eisenkop SM, Schlaerth JB, Mannel RS, Barakat R, Pearl ML, Sharma SK. Recurrence and survival after random assignment to laparoscopy versus*

laparotomy for comprehensive surgical staging of uterine cancer: Gynecologic Oncology Group LAP2 Study. J Clin Oncol. 2012 Mar 1;30(7):695-700.

2. *Nobbenhuis MAE, Gul N, Barton-Smith P, O'Sullivan O, Moss E, Ind TEJ; Royal College of Obstetricians and Gynaecologists. Robotic surgery in gynaecology: Scientific Impact Paper No. 71 (July 2022). BJOG. 2023 Jan;130(1):e1-e8.*

https://player.vimeo.com/video/1201726642?autoplay=1

ESGE35-0884 - VP140
Video in ePoster

Navigating Extensive Adhesions: A Case Report of Iatrogenic Bladder Injury During Complex Total Laparoscopic Hysterectomy

Nikolay Nedelev[1], *Magdalen Matev*[1]
[1]*USHATOG Selena, Obstetrics and Gynaecology, Plovdiv, Bulgaria*

Background

Urinary tract injuries (UTIs), particularly iatrogenic bladder lesions, are well known complications of total laparoscopic hysterectomy (TLH) with incidence rates rising in patients with a history of multiple abdominal surgeries. This report aims to describe the intraoperative identification and successful laparoscopic repair of a 1.5 cm bladder lesion in a patient with significant adhesive disease, highlighting the importance of alternative entry techniques and precise dissection in high-risk cases.

Methods

The patient, a 50-year-old female, G2P2, presented with a growing submucous myoma causing postmenopausal bleeding. Her surgical history was significant for six prior open procedures: two caesarean sections, one appendectomy, one laparotomy with left salpingo-oophorectomy, and two midline laparotomies for ileus. The patient underwent TLH and right salpingo-oophorectomy with severe adhesiolysis. The surgery was performed with the help of a uterine manipulator in order to optimize exposure and facilitate uterine mobilization. Due to the high probability of periumbilical adhesions, primary access was established at Palmer's point using a 5 mm telescope to safely evaluate the anterior abdominal wall. Following targeted adhesiolysis of the periumbilical area to ensure a safe entry path, a 10 mm umbilical port was established for the primary telescope. Intraoperatively, the pelvic anatomy was significantly distorted by dense vesicouterine adhesions. The bladder was dissected from the lower uterine segment sharply and bluntly using a combination of both central and lateral approaches. During this process, the cleavage plane between the bladder and the anterior vaginal wall was misidentified because of the dense fibrosis and scar tissue from previous surgeries. This led to an iatrogenic 1.5 cm cystotomy.

The bladder injury was immediately identified. Laparoscopic repair was performed using 3-0 barbed sutures in a two-layer continuous technique, followed by peritonization to ensure a tension-free closure. Suture integrity was confirmed through two consecutive methylene blue tests, both of which showed no leakage.

Results

The total operative time was 130 minutes, with an estimated blood loss of 100 ml. The postoperative course was unremarkable with the intra-abdominal drain being removed on the third postoperative day. Discharge occurred on day five with an indwelling Foley catheter, which remained for an additional five days. Follow-up evaluations on days 10 and 20 post-surgery confirmed complete recovery with no urological or surgical complications.

Conclusions

This case highlights that bladder injury remains an inherent risk in complicated gynecological laparoscopy, regardless of the surgeon's experience. In multi-operated patients dense fibrosis often obscures anatomical landmarks, increasing iatrogenic trauma risks. However, immediate intraoperative recognition and primary repair are decisive for ensuring an uncomplicated recovery. Therefore, we believe that maintaining high precision during the intervention is essential to prevent long-term morbidity and secondary interventions.

https://player.vimeo.com/video/1195734756?autoplay=1

ESGE35-0894 - VP141
Video in ePoster

LAPAROSCOPIC EXCISION OF RIGHT HEMI-UTREUS WITH IPSILATERAL CERVICAL AGENESIS IN A YOUNG NULLIPAROUS PATIENT WITH DIDELPHYS UTERUS

Theodoros Theodoridis[1], Eleftherios Klonos[1], Christos Zymperdikas[1], Eirini Iordanidou[1], Antigoni Pana[1], Grigorios Grimbizis[1]
[1]Aristotle University of Thessaloniki, 1st Department of Obstetrics and Gynaecology, Thessaloniki, Greece

Background

Uterus didelphys is a rare congenital Mullerian duct anomaly, with an incidence of approximately 0.1–0.5% in the general population. Based on ESHRE/ESGE classification of congenital anomalies, the present case is categorised as a U4b - C4 - V0 malformation. It is usually asymptomatic; however, it may manifest with dysmenorrhea, infertility, miscarriages, or high-risk pregnancies, requiring an individualized diagnostic and therapeutic approach.
The present case is about an 18-year-old nulliparous patient, with menarche 2 years prior, presented in our department for the investigation of periodic lower abdominal pain. Ultrasonographic evaluation revealed a uterus with two unequal hemi-uteri and a dilated endometrial cavity in the right hemi-uterus. Pelvic MRI further revealed right cervical agenesis.

Methods

Initially, a hysteroscopy was performed, which confirmed the presence of a patent cervical canal and entry into an endometrial cavity. The left tubal ostium w. as identified. Subsequently, the patient underwent a four-port laparoscopy. After initial tissue dissection and demarcation, excision of the right uterine hemi-uterus and ipsilateral salpingectomy were performed. Following the restoration of the wound surface with Vicryl 1-0 sutures, a longitudinal incision was made on the specimen, revealing an outflow of chocolate-coloured fluid, confirming the preoperative imaging findings. Morcellator was used for the removal of the specimen

Results

The patient's recovery period was uneventful. Histological examination of the specimen confirmed the initial diagnosis. Ever since the patient has routine follow upin our outpatient department and remains asymptomatic.

Conclusions

Laparoscopy constitutes a safe and effective alternative for the management of complex congenital anomaly cases, offering significant advantages over laparotomy.

https://player.vimeo.com/video/1195747698?autoplay=1

ESGE35-0898 - VP142
Video in ePoster

Stepwise Laparoscopic Burch Colposuspension After Total Laparoscopic Hysterectomy and Bilateral Salpingo-Oophorectomy

Aylin Tunalı[1], *Yakup Yalçın*[2]
[1]*Bursa Uludag University- Faculty of Medicine-, Obstetrics and Gynaecology, Bursa, Türkiye*
[2]*Bursa Uludag University- Faculty of Medicine, Obstetrics and Gynaecology, Bursa, Türkiye*

Background

Stress urinary incontinence (SUI) may coexist with benign gynaecological conditions requiring surgical treatment. Laparoscopic Burch colposuspension is an established mesh-free option for selected patients with SUI and can be performed during the same laparoscopic session. This educational video demonstrates a stepwise, anatomy-oriented laparoscopic Burch colposuspension performed after total laparoscopic hysterectomy and bilateral salpingo-oophorectomy in a patient with adenomyosis and SUI.

Methods

A 53-year-old multiparous woman with adenomyosis-related abnormal uterine bleeding and SUI underwent total laparoscopic hysterectomy with bilateral salpingo-oophorectomy followed by laparoscopic Burch colposuspension. After vaginal cuff closure, the space of Retzius was entered and developed. Two interrupted 2-0 non-absorbable polyester sutures were placed on each side through the paravaginal tissues adjacent to the bladder neck and proximal urethra and anchored to Cooper's ligament. The sutures were tied in a tension-controlled manner to achieve symmetrical suspension. The video highlights key anatomical landmarks, retropubic dissection planes, and critical technical steps.

Results

Adequate bilateral suspension and haemostasis were achieved without perioperative complications. The patient had spontaneous voiding after Foley catheter removal and was discharged on postoperative day 1. At the 2-year follow-up, she reported complete resolution of SUI symptoms.

Conclusions

A structured laparoscopic Burch colposuspension may facilitate anatomical orientation, surgical reproducibility, and procedural safety in selected patients requiring concomitant laparoscopic surgery for benign gynaecological disease.

https://player.vimeo.com/video/1195748022?autoplay=1

ESGE35-0902 - VP144
Video in ePoster

Laparoscopic Adnexectomy Following Hysterectomy

Yasmine Chiba[1], Fhal Ameni[1], Barouni Rihab[1], Hfaiedh Ines[1], Mellouli Ferdaous[1], Mourali Mechaal[1]
[1]Habib Bougatfa University Hospital in Bizerte, Department of Obstetrics and Gynaecology, Bizerte, Tunisia

Background

Objectives :

To describe the surgical management of complex pelvic adhesions during adnexectomy in a patient with previous haemostatic hysterectomy, highlighting the challenges surgical dissection in distorted pelvic anatomy.

Methods

We report the case of a 62-year-old woman with a history of haemostatic hysterectomy performed for postpartum hemorrhage. She was referred for management of a unilateral adnexal cystic mass incidentally discovered during imaging follow-up.

Pelvic ultrasonography revealed a 3.5 × 4.5 cm cystic adnexal lesion without suspicious vegetations.

Laparoscopic exploration revealed an empty hysterectomy bed and dense adhesions involving the left adnexa, bowel, omentum, and pelvic wall. Careful adhesiolysis was progressively performed to restore pelvic anatomy and mobilize the adnexa.

Adnexectomy was subsequently completed after safe dissection and ligation of the infundibulopelvic ligament.

Results

The adnexal mass was successfully removed without bowel or urinary tract injury. Final inspection showed satisfactory hemostasis. Histopathological examination revealed a simple ovarian cyst. Postoperative recovery was uneventful.

Conclusions

Previous haemostatic hysterectomy may lead to severe pelvic adhesions and distorted pelvic anatomy, making adnexal surgery technically challenging. Careful adhesiolysis is essential to achieve safe adnexal dissection and satisfactory surgical outcomes.

https://player.vimeo.com/video/1195747816?autoplay=1

ESGE35-0905 - VP145
Video in ePoster

LAPAROSCOPIC MANAGEMENT OF INTERSTITIAL PREGNANCY

Theodoros Theodoridis[1], Eleftherios Klonos[1], Christos Zymperdikas[1], Athanasios Tolkos[1], Angelos Daniilidis[1], Grigorios Grimbizis[1]
[1]Aristotle University of Thessaloniki, 1st Department of Obstetrics and Gynaecology, Thessaloniki, Greece

Background

Interstitial pregnancy is a rare form of ectopic pregnancy, characterized by the implantation of the embryo in the interstitial portion of the fallopian tube. It accounts for approximately 2–4% of ectopic pregnancies. The clinical presentation frequently includes abdominal pain, vaginal bleeding, and amenorrhea.
The present case is about a 26-year-old patient who presented to the emergency department reporting lower abdominal pain and a positive pregnancy test. Ultrasonographic evaluation revealed the presence of a gestational sac with positive foetal cardiac activity and aCRL corresponding to a gestational age of 8w+2d, implanted at the distal end of the right uterine horn.

Methods

A four-port laparoscopy was performed. Upon inspection of the peritoneal cavity, the gestational sac was located in the interstitial portion of the right fallopian tube. A right salpingectomy was performed with concomitant excision of the intact ectopic gestational sac. The uterine wound surface was closed using interrupted Vicryl 1-0 sutures. Finally, the specimen was removed from the peritoneal cavity within a laparoscopic specimen retrieval bag. The patient recovered in the operating room, and the specimen was sent for histological examination.

Results

The patient's postoperative recovery was uneventful. She was discharged on the 1stpostoperative day. Histological examination of the specimen confirmed the initial diagnosis of interstitial ectopic pregnancy.

Conclusions

Laparoscopy constitutes a safe option for the management of interstitial pregnancy, combining optimal surgical outcomes with reduced morbidity for the patient.

https://player.vimeo.com/video/1195752733?autoplay=1

ESGE35-0907 - VP146
Video in ePoster

Laparoscopic adnexal myoma

Eleftherios Klonos[1], Christos Zymperdikas[1], Nikolaos Roussos[1], Athanasios Tolkos[1], Theodoros Theodoridis[1], Grigorios Grimbizis[1]
[1]Aristotle University of Thessaloniki, 1st Department of Obstetrics and Gynaecology, Thessaloniki, Greece

Background

To present a case of laparoscopic management of an incidentally detected adnexal mass in a postmenopausal patient with significant oncologic history, and to highlight the role of minimally invasive surgery in definitive diagnosis and treatment.

Methods

A 50-year-old postmenopausal woman (G2P2) with a history of two previous caesarean sections and prior mastectomy for breast cancer, currently on tamoxifen therapy, was found to have an incidental adnexal mass during routine gynecological follow-up. Given her clinical background, a decision was made to proceed with laparoscopic surgical management. Standard laparoscopic entry into the peritoneal cavity was performed, followed by systematic pelvic inspection. A normal-sized uterus and normal ovaries were identified. A left adnexal mass was noted in close relation to the left fallopian tube. A laparoscopic left adnexectomy was performed, followed by meticulous hemostasis and subsequent right adnexectomy. Specimens were retrieved in endoscopic bags, and a pelvic drain was placed under direct visualization.

Results

The procedure was completed laparoscopically without intraoperative complications. Both adnexal specimens were successfully removed without spillage. Postoperative recovery was uneventful. Histopathological examination revealed a fallopian tube fibroma (fibromyoma), confirming a benign etiology.

Conclusions

Laparoscopic management of adnexal masses in postmenopausal patients with oncologic history is safe and effective. It allows definitive diagnosis, minimizes surgical morbidity, and ensures accurate histopathological evaluation. This case supports the role of minimally invasive surgery as the preferred approach in appropriately selected patients.

https://player.vimeo.com/video/1195755349?autoplay=1

ESGE35-0915 - VP148
Video in ePoster

Management of surgical complications: a well-repaired bladder injury laparoscopically

Yasmine Chiba[1], Ben Amor Mizouni[1], Mili Youssef[1], Rjiba Chaima[1], Hfaiedh Ines[1], Mourali Mechaal[1]
[1]Habib Bougatfa University Hospital in Bizerte, Department of Obstetrics and Gynaecology, Bizerte, Tunisia

Background

Laparoscopic hysterectomy is a commonly performed minimally invasive procedure with well-known benefits, including reduced morbidity and faster recovery. However, it is not without risks, and intraoperative complications may occur, particularly involving adjacent organs. Bladder injury is one of the most important complications, especially in patients with prior pelvic surgery such as caesarean section, where adhesions can make dissection more difficult. Early recognition and prompt laparoscopic repair are essential to ensure good outcomes. In this report, we describe the management of a bladder injury occurring during laparoscopic hysterectomy and its laparoscopic repair.

Methods

We report the case of a 55-year-old woman, gravida 6 para 4, with a history of one previous caesarean section, who wa followed for abnormal uterine bleeding consisting of perimenopausal metrorrhagia resistant to medical treatment.

Given the patient's persistent symptoms, surgical management was indicated, and the decision was made to perform laparoscopic hysterectomy.

Results

During the surgery, a bladder injury was made while dissecting the bladder. The complication was identified rapidly and was well repaired by laparoscopic surgical sutures.

Conclusions

Bladder injury during laparoscopic hysterectomy is a rare but significant complication, particularly in patients with previous pelvic surgery. Prompt recognition and immediate laparoscopic repair allow safe and effective management, with good postoperative outcomes when watertight closure is achieved. This case highlights the importance of careful dissection in high-risk patients and confirms that laparoscopic repair remains a reliable and feasible approach in experienced hands.

https://player.vimeo.com/video/1195756460?autoplay=1

ESGE35-0916 - VP149
Video in ePoster

ICG-Guided vNOTES Hysterectomy with High Uterosacral Ligament Suspension

Maria Constantinides[1], *Deepali Sinha*[1], *Shaimaa Ibrahim*[1]
[1]*Newham University Hospital- Barts Health NHS Trust, Obstetrics and Gynaecology, London, United Kingdom*

Background

To demonstrate the feasibility and safety of ICG-guided vaginal Natural Orifice Transluminal Endoscopic Surgery (vNOTES) hysterectomy combined with high uterosacral ligament suspension (HUSLS) . This video highlights fluorescence-guided ureteric identification and key reconstructive surgical steps.

Methods

A patient with symptomatic stage III pelvic organ prolapse, including cystocele and rectocele, underwent vNOTES hysterectomy with bilateral salpingectomy and HUSLS. Following examination under anaesthesia, cystoscopy and ureteric catheterisation were performed with indocyanine green (ICG) dye injection to aid intraoperative ureteric visualisation.

After circumferential vaginal incision and entry into the peritoneal cavity, a GelPOINT® V-Path platform was inserted and pneumoperitoneum established. The video demonstrates pelvic access, identification of pelvic anatomy, fluorescence-guided visualisation of both ureters, hysterectomy and bilateral salpingectomy, followed by native tissue apical suspension.

Results

The procedure was completed successfully without intraoperative complications. ICG fluorescence imaging enabled clear visualisation of both ureters during uterosacral suspension, facilitating safe suture placement. Estimated blood loss was 100 mL. Good apical and vaginal support was achieved at the end of the procedure. The patient had an uncomplicated postoperative recovery.

Conclusions

ICG-guided vNOTES hysterectomy with HUSLS and pelvic floor repair is a safe and feasible minimally invasive approach for advanced pelvic organ prolapse. Fluorescence-guided ureteric identification may enhance surgical safety during reconstructive pelvic surgery while preserving the benefits of a scarless vaginal approach.

https://player.vimeo.com/video/1195757653?autoplay=1

ESGE35-0925 - VP151
Video in ePoster

Caesarean Myomectomy: Surgical Technique and Intraoperative Management

Joseph Iskaros[1], Maria Constantinides[2], Charlotte Depoers[3], Guldzhan Vorona[3]
[1]University College London Hospital, Obstetrics and Gynaecology, London, United Kingdom
[2]Newham University Hospital- Barts Health NHS Trust, Obstetrics and Gynaecology, London, United Kingdom
[3]Whittington Health NHS Trust, Obstetrics and Gynaecology, London, United Kingdom

Background

To demonstrate the operative feasibility and multidisciplinary considerations in performing a Caesarean Myomectomy in a symptomatic patient with fibroids, and to discuss surgical planning and intraoperative strategies to minimizing risk.

Methods

We present the case of a 34-year-old nulligravid woman who first presented at 9+2/40 with heavy bleeding on a background of known fibroids. Following discussion at a tertiary FMU MDT, deemed to proceed with a planned Caesarean Myomectomy locally. Preoperative planning included informed patient consent, availability of cell salvage, advanced bipolar and ultrasonic energy devices, and use of Terlipressin and a uterine tourniquet.

The procedure began with a Pfannenstiel incision. The baby was delivered using forceps. One fibroid was removed prior to delivery of the baby due to obstructing the lower segment. A tourniquet was applied, and Terlipressin 20 IU was into the fibroid capsule. Open myomectomy was then carried out, followed by two-layer uterine closure and reconstitution of the myometrium and serosal layer.

Results

The procedure was completed successfully. Estimated blood loss was 2L. The uterine muscle layers were successfully reconstituted in layers to effectively close the dead space after the removal of the fibroids.

After the procedure, three fibroid specimens were sent for histological analysis. The specimens were reported as benign leiomyomas with infaracted type necrosis. The patient had an uneventful recovery.

Conclusions

Although Caesarean myomectomy is often eschewed due to the risks of life-threatening hemorrhage, it can be safely executed meticulously in selected patients when corroborated by thorough planning, exceptional surgical expertise, and robust intraoperative support. This case emphasizes the critical role of multidisciplinary collaboration and showcases the technical strategies that can significantly improve outcomes in complex obstetric procedures. https://player.vimeo.com/video/1195762447?autoplay=1

ESGE35-0928 - VP152
Video in ePoster

Ovarian transposition in a 6-year-old girl with gluteal rhabdomyosarcoma as oncofertily procedure-case report

Katarzyna Sachadel[1], *Tadeusz Issat*[1], *Anna Raciborska*[2]
[1]*Institute of Mother and Child, Gynaecology Department, Warsaw, Poland*
[2]*Institute of Mother and Child, Paediatric Oncology, Warsaw, Poland*

Background

Ovarian transposition is a fertility-preserving surgical procedure performed in patients requiring pelvic or abdominal radiotherapy. By repositioning the ovaries outside the radiation field, it aims to reduce radiation-induced damage and preserve endocrine and reproductive function. This strategy may be particularly relevant in paediatric patients with rhabdomyosarcoma, whose treatment often includes irradiation close to the gonads. Ovarian transposition is a fertility-preserving surgical procedure performed in patients requiring pelvic or abdominal radiotherapy. By repositioning the ovaries outside the radiation field, it aims to reduce radiation-induced damage and preserve endocrine and reproductive function. This strategy may be particularly relevant in paediatric patients with rhabdomyosarcoma, whose treatment often includes irradiation close to the ovaries.

Methods

We report the case of a 6-year-old girl diagnosed with rhabdomyosarcoma of the left gluteal region in December 2020. Following diagnosis, she started chemotherapy according to the treatment protocol for very high-risk rhabdomyosarcoma. In May 2021, she was referred for radiotherapy. In accordance with paediatric oncology fertility-preservation recommendations, the patient's parents were counselled regarding available oncofertility options and consented to unilateral ovarian transposition.

Results

The procedure was performed laparoscopically. After inspection of the abdominal cavity, a prepubertal uterus and both ovaries without pathological abnormalities were visualized. The mesosalpinx was transected while preserving the fallopian tube. The left ovary was mobilized with preservation of the ovarian vascular pedicle and repositioned cranially and laterally above the pelvic brim, outside the anticipated radiation field. It was fixed to the abdominal wall with absorbable sutures, and two metal clips were placed to facilitate radiotherapy planning. Ovarian perfusion was confirmed intraoperatively. The procedure lasted 45 minutes and was completed without complications. Radiotherapy was initiated eight days later.

Conclusions

In paediatric patients with pelvic or gluteal tumors requiring pelvic irradiation, ovarian transposition remains an important fertility-preserving strategy. Its effectiveness depends on postoperative ovarian position, cumulative and scatter radiation dose, patient age, and prior chemotherapy exposure. The procedure is technically straightforward and associated with low morbidity. Because postoperative

ovarian remigration has been described, surgery should be performed as close as possible to radiotherapy initiation.

https://player.vimeo.com/video/1195761576?autoplay=1

ESGE35-0943 - VP154
Video in ePoster

Robotic Sacrocervicopexy using a Y-Mesh: A Step-by-Step Approach to Tension-Free Anatomical Reconstruction

Evgeni Baev[1]
[1]*Municipal Hospital, Department of Obstetrics and Gynaecology, Sofia, Bulgaria*

Background

Sacrocervicopexy is widely considered the gold standard for the correction of apical pelvic organ prolapse. However, there is currently a lack of international standardization regarding the precise surgical steps and suturing techniques. This video aims to present a standardized, reproducible, step-by-step approach to robotic sacrocervicopexy using a Y-mesh, demonstrating critical maneuvers to ensure anatomical restoration while minimizing mesh-related complications.

Methods

This video article presents the case of a patient with symptomatic total pelvic organ prolapse (POP). The procedure was performed using the daVinci Xi robotic platform. The surgical steps are demonstrated systematically:

1. Dissection of the vesicovaginal space prior to hysterectomy.
2. Robotic supracervical hysterectomy.
3. Dissection of the rectovaginal space.
4. Nerve-sparing dissection of the sacral promontory, with precise identification and preservation of the right hypogastric nerve.
5. Development of Okabayashi's pararectal space.
6. Fixation of the mesh to the anterior vaginal wall using partial-thickness, non-penetrating sutures to avoid vaginal mucosal involvement.
7. Fixation of the mesh to the cervical stump using deep, full-thickness sutures for maximum structural stability.
8. Fixation of the mesh to the posterior vaginal wall ensuring a flat, fold-free placement.
9. Tension-free and defect-oriented fixation of the posterior mesh limb to the anterior longitudinal ligament (ALL) using two non-absorbable sutures.

Results

The robotic sacrocervicopexy was successfully completed without intraoperative complications. Total operative time was 84 minutes, with minimal estimated blood loss ([e.g., <50 mL]). By utilizing partial-thickness, non-penetrating sutures on the anterior and posteror vaginal wall, and deep, full-thickness sutures on the cervical stump as avoiding fold formation, a multicompartiment pelvic

reconstruction was achieved. The patient was discharged on the third postoperative day with excellent anatomical restoration of the all the three compartments, no prolapse complaints and no short-term voiding or defecation dysfunction.

Conclusions

Robotic sacrocervicopexy using a Y-mesh provides an excellent, high-precision approach for a combined prolapse repair. Adhering to a standardized step-by-step dissection, ensuring nerve-sparing promontory exposure, and utilizing fold-free, non-penetrating suturing techniques are critical maneuvers to optimize anatomical outcomes and minimize the long-term risk of mesh erosion or pelvic denervation.

https://player.vimeo.com/video/1195767795?autoplay=1

ESGE35-0948 - VP155
Video in ePoster

Fertility-preserving management of symptomatic uterine fibroids in a nulligravid woman with obesity: a case report

Joseph Iskaros[1], Maria Constantinides[2], Guldzhan Vorona[1]
[1]Whittington Health NHS Trust, Obstetrics and Gynaecology, London, United Kingdom
[2]Newham University Hospital- Barts Health NHS Trust, Obstetrics and Gynaecology, London, United Kingdom

Background

To demonstrate the surgical technique and perioperative management of fertility-preserving open myomectomy in a 41-year-old nulligravid woman with obesity and symptomatic multiple uterine fibroids.

Methods

A 41-year-old nulligravid woman with body mass index 36 kg/m² presented with chronic pelvic pain, dyspareunia, constipation, urinary pressure symptoms, heavy menstrual bleeding, and iron-deficiency anaemia. Transvaginal ultrasonography and MRI demonstrated an enlarged uterus with multiple intramural fibroids. Following preoperative optimization with iron supplementation and hormonal suppression therapy, the patient underwent fertility-preserving open myomectomy. The video demonstrates abdominal entry, uterine exposure, identification and enucleation of fibroids, haemostatic techniques, multilayer uterine reconstruction, and measures used to preserve uterine integrity and future reproductive potential.

Results

Multiple symptomatic fibroids were successfully removed through an open abdominal approach with preservation of the uterus. Careful multilayer closure of the myometrium was performed to optimize uterine healing and reduce future obstetric risk. The procedure resulted in improvement of bulk-related symptoms and abnormal uterine bleeding. The video highlights key operative considerations in obese patients undergoing fertility-preserving surgery, including surgical exposure, blood-loss reduction strategies, and uterine reconstruction techniques.

Conclusions

Open myomectomy remains an important fertility-preserving surgical option for women with large or multiple symptomatic intramural fibroids. Meticulous surgical planning, effective haemostatic control, and careful uterine reconstruction are essential to optimize surgical and reproductive outcomes.

https://player.vimeo.com/video/1195773046?autoplay=1

ESGE35-0963 - VP156
Video in ePoster

Laparoscopic-Assisted Modified Vecchietti Procedure for the Management of Mayer-Rokitansky-Küster-Hauser Syndrome: A Step-by-Step Surgical Approach

Atakan Sen[1], Halime Karakaya Şen[1], Necati Berk Kaplan[1], Batuhan Aslan[1], Yavuz Emre Şükür[1]
[1]Ankara University, Obstetrics and Gynaecology, Ankara, Türkiye

Background

Mayer-Rokitansky-Küster-Hauser (MRKH) syndrome is a congenital disorder characterized by Müllerian agenesis, leading to primary amenorrhea and vaginal aplasia. The condition poses significant challenges to physical and psychosexual well-being. While various surgical and non-surgical interventions exist for vaginal reconstruction, the creation of a functional neovagina that mimics natural anatomy remains the primary goal. The aim of this video is to demonstrate the step-by-step surgical technique of the laparoscopic-assisted modified Vecchietti procedure in a patient with vaginal aplasia.

Methods

We present the case of a 25-year-old woman presenting with primary amenorrhea. Clinical evaluation and pelvic magnetic resonance imaging (MRI) confirmed the diagnosis of MRKH syndrome, revealing the absence of the uterus and the upper two-thirds of the vagina, with a rudimentary vaginal dimple. Following extensive counselling regarding reconstructive options, a laparoscopic-assisted modified Vecchietti procedure was scheduled.

Results

The traction device was maintained for 5 days, resulting in the formation of an adequate neovagina with a depth of 8 cm and sufficient calibre. Postoperative recovery was uneventful. Follow-up examinations at 3 months confirmed excellent functional outcomes and patient satisfaction.

Conclusions

The laparoscopic-assisted modified Vecchietti procedure is a safe, feasible, and highly effective technique for the creation of a neovagina in patients with MRKH syndrome. The laparoscopic approach allows for meticulous dissection and direct visualization, minimizing the risk of visceral injury compared to traditional methods. Adherence to precise surgical steps and an understanding of the pelvic anatomy are essential for optimizing functional outcomes and achieving long-term success.

https://player.vimeo.com/video/1195784723?autoplay=1

ESGE35-0970 - VP158
Video in ePoster

24 weeks fibroid uterus TLH, surgical considerations

Alvaro Bedoya-Ronga[1], *Miski Scerif*[2], *Martin Beard*[2]
[1]*Midlands Metropolitan Endometriosis Centre, Gynaecology, Sandwell, United Kingdom*
[2]*Sandwell and Westmidlands NHS Trust, Gynaecology, Birmingham, United Kingdom*

Background

Objective

To demonstrate the technical viability, safety considerations, and surgical techniques required to perform a Total Laparoscopic Hysterectomy (TLH) on a 24-week size fibroid uterus in a patient with a history of multiple laparotomies.

To discuss safety considerations

Background

Uterine leiomyomas extending above the level of the umbilicus present significant challenges for laparoscopic entry, visualisation, and manipulation. These complexities are compounded in patients with dense pelvic adhesions from previous intra-abdominal surgeries, 3 caesarean sections, where the risk of visceral injury and conversion to open laparotomy is traditionally high.

Methods

A 44-year-old female (BMI 22) presented with a 24-week size uterus secondary to a **10 cm** posterior fundal fibroid, causing heavy menstrual bleeding and urinary retention. Her surgical history was significant for three prior caesarean sections and an abdominoplasty.

Laparoscopic access was safely established at Palmer's point using a Veress needle after nasogastric tube was inserted and splenomegaly ruled out by palpation. The entry pressure was 20 mmHg for trocars, later reduced to 10. We used monopolar scissors, bipolar mirelands and harmonic scalpel. Anatomy was restored from adhesions, and the surgery starts from the anterior compartment; the urinary bladder was filled with saline to define its margins, allowing for a safe dissection. All the vessels were skeletonised prior to coagulation, to minimise bleeding. Ureters were checked prior to coagulation; anterior and posterior leaf of the peritoneum were mobilised before uterine artery coagulation. Colpotomy was undertaken as routine, vault closed, and ovaries suspended to the round ligament. The uterus an tubes were extracted via open morcellation using an Alexis retractor

Results

The procedure was completed successfully via a total laparoscopic approach with no conversion to open surgery. Intraoperative blood loss was minimal, and the anatomy was completely restored without injury to the bladder, ureters, or bowel. The patient made an unremarkable recovery and was safely discharged home on postoperative day one.

Conclusions

For large fibroid uterus, the approach should be opportunistic utilising and gaining access as possible. Commonly this means to access and clear the anterior compartment first to gain mobility and further access but should be tailored to each situation.

Laparoscopic surgery for large uterus is possible and benefits the surgeon with magnification of the visual field and the patient with a faster recovery

https://player.vimeo.com/video/1198117882?autoplay=1

ESGE35-0971 - VP159
Video in ePoster

Open Entry - Taking advantage of the anatomy!

Alvaro Bedoya-Ronga[1], Tereza Indrielle-Kelly[2], Martin Beard[3]
[1]Sandwell and West Birmingham Hospitals NHS Trust, Gynaecology, Sandwell, United Kingdom
[2]Sandwell and West Birmingham Hospitals NHS Trust, Gynaecology, Birmingham, United Kingdom
[3]Sandwell and West Birmingham Hospitals NHS Trust, Gynaecology, Birmingham, United Kingdom

Background

Objective

To demonstrate and document the step-by-step surgical technique for a safe laparoscopic modified Hasson entry at the umbilicus.

Background

Laparoscopic access is a critical phase of minimally invasive surgery, carrying risks of vascular and visceral injury. The umbilicus is formed where the four primary fascial planes of the anterior abdominal wall (the anterior and posterior rectus sheaths, the linea alba, and the transversalis fascia) converge and fuse into a dense fibroaponeurotic ring around the umbilicus, leaving a structural midline defect where the foetal vessels passed, the umbilical ring. We exploit this anatomical landmark for our open entry.

Methods

The video demonstrates an open umbilical entry:

1. **Incision and Exposure:** A vertical skin incision is made within the umbilical stalk, and the skin edges are retracted using towel clips/clamps to optimize visualization.
2. **Dissection:** Subcutaneous tissue is dissected bluntly using haemostatic forceps to isolate the underlying fascia.
3. **Fascial and Peritoneal Entry:** The umbilical ring is identified, and dissected with “roberts” under direct vision, the rectus sheath opening is extended as requires.
4. **Confirmation:** Digital exploration confirmation ensures free space and the absence of immediate visceral adhesions beneath the entry site.
5. **Stay Sutures:** Structural stay sutures are placed through the fascial edges to prevent postoperative hernia.

Results

The open entry technique safely achieves access to the peritoneal cavity without any immediate vascular or visceral complications. The fascial planes are cleanly delineated, and stay sutures are successfully placed, ensuring a controlled, airtight portal for subsequent laparoscopic instrumentation.

Conclusions

This educational video shows how to exploit anatomy for a safer entry

https://player.vimeo.com/video/1198145837?autoplay=1

ESGE35-0973 - VP160
Video in ePoster

Robotic-Assisted Laparoscopic Adhesiolysis and Total Hysterectomy: Operative Techniques for Complication Mitigation

Panagiotis Tsavalos[1], *Angelos Daniilidis*[2], *Ioanna Vagioni*[1], *Nikolaos Roussos*[1]
[1]*Aristotle University of Thessaloniki/ Papageorgiou General Hospital, 1st department of Obstetrics and Gynaecology, Thessaloniki, Greece*
[2]*Aristotle University of Thessaloniki / Papageorgiou General Hospital, 1st Department of Obstetrics and Gynaecology, Thessaloniki, Greece*

Background

This paper demonstrates the critical operative phases of a robotic-assisted total laparoscopic hysterectomy and concomitant adhesiolysis using the da Vinci surgical system, with a primary focus on the application of dual-arm robotic instrumentation to secure optimal exposure, identify key anatomical landmarks, and minimize the risk of accidental thermal or mechanical injuries.

Methods

The surgical procedure is conducted using fenestrated bipolar forceps and monopolar curved scissors, initiating with meticulous adhesiolysis to safely isolate and release fibrous scar tissue from underlying organs. Following tissue mobilization, systematic retroperitoneal dissection is performed, where the robotic arms deliver the necessary traction and counter-traction to develop avascular planes, followed by the isolation and division of the major uterine ligaments, skeletal isolation and sustained bipolar energy desiccation of the uterine artery along the lateral cervix, and a precise 360-degree circumferential colpotomy utilizing a uterine manipulator, concluding with the closure of the pelvic floor via interrupted surgical suturing.

Results

Visual confirmation of the ureter via retroperitoneal dissection proved paramount in preventing inadvertent collateral damage due to its close proximity to the uterine artery and infundibulopelvic ligament, while the integration of robotic articulation provided superior dexterity, enabling meticulous dissection of the bladder flap and safe release of dense adhesions.

Conclusions

In conclusion, a methodical robotic approach combined with precise anatomical demarcation effectively preserves urinary tract integrity, ensures definitive hemostasis, and substantially minimizes serious postoperative complications.

https://player.vimeo.com/video/1198340469?autoplay=1

ESGE35-1000 - VP161
Video in ePoster

A simplified extracorporeal knot-advancement technique for hysteroscopic suture fixation of a hormone-releasing intrauterine system

Boping Yang[1], *Chi Yugang*[1]
[1]*Women and Children's Hospital of Chongqing Medical University. China, Department of General Gynaecology-, Chongqing, China*

Background

Expulsion of a hormone-releasing intrauterine system may occur in patients with adenomyosis, uterine cavity enlargement or distorted uterine anatomy, compromising long-term symptom control for dysmenorrhoea and heavy menstrual bleeding. Hysteroscopic suture fixation is a potential strategy to maintain the intrauterine position of the device. However, conventional intrauterine knot delivery can be technically demanding, particularly when the knot cannot be advanced precisely to the fixation site or becomes loose during manipulation. This study describes a simplified extracorporeal knot-advancement technique designed to facilitate hysteroscopic suture fixation without the use of a conventional knot pusher.

Methods

A patient with adenomyosis, uterine cavity enlargement and repeated expulsion of a hormone-releasing intrauterine system underwent hysteroscopic suture fixation of the device. The operative technique was documented in a step-by-step surgical video for oral presentation. Written patient consent for presentation and publication of the surgical material was obtained.

After trimming the device tail, a non-absorbable suture was tied around one arm of the device, followed by a second knot approximately 0.3 cm from the first knot. One end of a double-armed 4-0 non-absorbable suture was passed through the interval between the two knots and introduced into the uterine cavity. Under hysteroscopic guidance, the needle was grasped with a needle holder, passed through the posterior myometrium and exteriorised through the vagina. The device was then delivered into the uterine cavity. After a simplified extracorporeal knot was created outside the body, traction on a single suture end advanced the knot to the intrauterine fixation site.

Results

The procedure was completed successfully. Hysteroscopic reassessment confirmed appropriate device position and accurate knot placement at the fixation site. This technique enabled controlled knot advancement without a knot pusher, thereby reducing the need for repeated intrauterine manipulation and minimising the risk of incomplete knot delivery or knot loosening. The key technical requirement was to obtain a sufficiently deep and wide myometrial bite to prevent suture detachment during traction. During follow-up, ultrasound confirmed that the device remained correctly positioned. Dysmenorrhoea and menstrual bleeding improved markedly, and no procedure-related adverse events were observed.

Conclusions

This simplified extracorporeal knot-advancement technique may provide a feasible and reproducible approach for hysteroscopic suture fixation of a hormone-releasing intrauterine system in selected patients at high risk of recurrent expulsion. By simplifying intrauterine knot delivery, the technique may reduce procedural complexity, minimise intrauterine manipulation and potentially improve fixation reliability. Adequate myometrial suture depth and width are essential to ensure fixation stability and procedural safety.

ESGE35-0604 - VP163
Video in ePoster

Neuropelvic Endometriosis: Robotic Resection of Obturator Nerve Infiltration Enabling Spontaneous Conception

Adrielle Rodas Fernandes[1], *Mayara Andrade*[1], *Daniel Caraça*[1], *Mariana Vieira*[1], *Patrick Bellellis*[1]
[1]*Einstein Hospital Israelita, Gynaecology, São Paulo, Brazil*

Background

To demonstrate the feasibility and safety of robotic-assisted resection of neuropelvic deep infiltrating endometriosis (DIE) involving the obturator nerve, emphasizing nerve-sparing surgical techniques associated with preservation of pelvic function and restoration of fertility.

Methods

This surgical video case presentation illustrates a step-by-step robotic-assisted approach for the treatment of severe neuropelvic endometriosis in a patient with significant pelvic anatomical distortion secondary to chronic inflammation and fibrotic DIE. The procedure was performed in a standard operating room using a robotic platform to enhance dexterity, tremor filtration, and three-dimensional magnified visualization during retroperitoneal dissection. Intravenous indocyanine green (ICG) administration and bilateral ureteral catheterization were initially performed to improve intraoperative identification of the urinary tract and optimize surgical safety. Temporary bilateral ovariopexy was used to improve retroperitoneal exposure. Surgical treatment included extensive enterolysis, right ovarian fossa peritonectomy, meticulous ureterolysis, and excision of a dense endometriotic nodule located in the right medial pararectal fossa. A strict nerve-sparing approach was adopted, with careful skeletonization of the hypogastric plexus and obturator nerve using minimal and judicious energy application to avoid thermal spread and preserve neural integrity. The procedure concluded with reconstruction of the pararectal peritoneum to obliterate dead space and restore pelvic anatomy.

Results

Complete macroscopic excision of endometriotic disease was achieved with effective hemostasis and no intraoperative complications. Final anatomical inspection confirmed preservation of the autonomic nerves, uterine artery, obturator nerve, and bilateral ureteral integrity, with maintained vascularization and ureteral peristalsis. The robotic platform allowed precise dissection within distorted anatomical planes while minimizing traction and thermal injury to adjacent structures. The patient had satisfactory postoperative recovery with preservation of pelvic function and subsequently achieved spontaneous conception, demonstrating favorable reproductive and functional outcomes following surgery.

Conclusions

Robotic-assisted laparoscopy provides the precision and visualization required for the management of severe neuropelvic DIE involving critical neurovascular structures. Thorough ureterolysis and meticulous nerve-sparing dissection enable complete disease excision while minimizing functional

morbidity. Restoration of pelvic anatomy combined with preservation of neural structures may contribute to improved postoperative function and successful spontaneous conception in patients with advanced endometriosis.

https://player.vimeo.com/video/1191705969?autoplay=1

ESGE35-0651 - VP164
Video in ePoster

Layers Matter: Surgical Decision-Making in Bladder Endometriosis from Diagnosis to Definitive Treatment

Emad Mikhail[1], *Sonia Eskandarion*[1], *Jasmine Eliwa*[1], *Diana Encalada Soto*[1]
[1]*University of South Florida, Obstetrics and Gynaecology, Tampa, USA*

Background

Objective: To demonstrate surgical strategies for complete excision of bladder deep endometriosis while preserving bladder function.

Design: Educational surgical video demonstrating a stepwise robotic surgical approach for the management of four patterns of bladder endometriosis, incorporating intraoperative ultrasound for lesion identification, tailored excision, and real-time surgical decision-making.

Setting: Tertiary academic center

Methods

Four patients with bladder endometriosis were included, representing four distinct disease patterns: peritoneal disease, superficial detrusor disease, mucosal effacing disease, and mucosal infiltrating disease. Patients were 28–42 years old and presented with urinary and pelvic symptoms including chronic pelvic pain, dysuria, urinary frequency and urgency, cyclic hematuria, dyschezia, and incomplete bladder emptying.

Results

All patients underwent a stepwise robotic surgical approach tailored to the depth and pattern of bladder endometriosis. Peritoneal and superficial detrusor disease were managed with lesion excision and preservation of the bladder mucosa, guided by cystoscopy and intraoperative robotic ultrasound for lesion localization and confirmation of complete resection. Mucosal effacing and mucosal infiltrating disease required robotic partial cystectomy to achieve full-thickness excision and ensure complete resection. Bladder reconstruction was performed using continuous suturing to restore integrity, and ureteral stents were placed prophylactically to facilitate ureteral identification and reduce the risk of postoperative injury.

Conclusions

Minimally invasive partial cystectomy remains the definitive treatment for bladder endometriosis. Bladder reconstruction using continuous suturing provides efficient and reliable closure. Postoperative bladder catheterization should be individualized, as duration varies widely from 2 days to 4 weeks depending on surgical complexity and healing.

https://player.vimeo.com/video/1193388004?autoplay=1

ESGE35-0723 - VP165
Video in ePoster

persistent interstitial pregnancy following failed medical treatment: a novel conservative management approach using laparoscopic cornuostomy with temporary uterine artery clamping

Michela Dell'Aquila[1], Tommaso Barbieri Vita[1], Luigi Della Corte[2], Giuseppe Bifulco[1], Pierluigi Giampaolino[1]
[1]University of Naples Federico II, Department of Public Health, Naples, Italy
[2]University of Naples Federico II, Department of Neuroscience- Reproductive Sciences and Dentistry, Naples, Italy

Background

interstitial pregnancy is a rare variant of ectopic pregnancy involving implantation in the intramural portion of the fallopian tube, associated with a high risk of haemorrhage. despite advances in diagnosis, the identification and management of such pregnancies remain complex, and treatment strategies must be tailored to the patient's clinical characteristics. the aim of this video is to provide a step-by-step description of a laparoscopic cornuotomy with temporary vascular control for the conservative management of a persistent interstitial pregnancy following failure of medical treatment.

Methods

a 30-year-old nulliparous woman with no known risk factors was referred to our centre for persistent interstitial ectopic pregnancy six months after unsuccessful methotrexate treatment performed at another facility. previously, the patient had been mistakenly treated with a multi-dose methotrexate regimen despite blood test results showing β-hCG levels of 12,000 IU/mL and ultrasound revealing an interstitial gestational cavity containing a pulsating embryonic pole. at the time of assessment at our centre, six months after, the patient had regular menstrual cycles and negative β-hCG levels. ultrasound examination revealed an empty uterine cavity with persistence of a gestational sac in the right interstitial region, associated with myometrial thickness <5 mm and a positive "interstitial line sign." no embryonic cardiac activity was detected. conservative laparoscopic surgery was therefore planned.

Results

laparoscopy confirmed persistence of the interstitial pregnancy. to minimize intraoperative bleeding, both uterine arteries were temporarily occluded with sutures, followed by local vasopressin infiltration at the site of the ectopic pregnancy. an incision was made on the affected uterine horn, with extraction of the gestational cavity and trophoblastic material. the uterine horn was sutured in layers. no perioperative complications occurred.

Conclusions

this is the first reported case of persistent interstitial pregnancy after failed medical treatment managed conservatively with laparoscopic cornuostomy and temporary uterine artery occlusion. this approach allowed complete removal of the ectopic pregnancy while preserving uterine integrity and

reducing haemorrhagic risk. the case also highlights that methotrexate treatment is likely to fail when used outside established clinical and laboratory criteria.

https://player.vimeo.com/video/1195354267?autoplay=1

ESGE35-0269 - VP166
Video in ePoster

Single-Port Robotic Multidisciplinary Approach to Advanced Rectovaginal and Bowel Endometriosis: Precision Discoid Excision in Frozen Pelvis Anatomy

Saima Farooq[1], *Amer Raza*[1]
[1]*Cromwell Hospital, Gynaecology, LONDON, United Kingdom*

Background

Deep infiltrating endometriosis involving the rectovaginal septum and bowel remains one of the most technically demanding forms of advanced pelvic disease. Surgical complexity increases significantly in the presence of frozen pelvis anatomy, obliterated pouch of Douglas, bilateral parametrial disease, and ureteric involvement. This video demonstrates a multidisciplinary single-port robotic approach for advanced bowel endometriosis requiring discoid bowel excision.

Methods

A 38-year-old woman with longstanding severe pelvic pain, dyschezia, dyspareunia, IBS-type symptoms, and persistent stage IV endometriosis despite previous laparoscopic surgeries was referred for specialist management. Previous surgery elsewhere failed to safely excise the rectovaginal nodule because of concern regarding rectal injury.The procedure included single-port robotic excision of severe pelvic endometriosis, bilateral ureterolysis, rectovaginal dissection, bowel mobilisation, discoid bowel excision, sigmoidoscopy, and leak testing with colorectal collaboration.

Results

Intraoperative findings revealed severe frozen pelvis anatomy with complete obliteration of the pouch of Douglas. Both ovaries were densely adherent to the pelvic sidewalls and ureters. Large bilateral parametrial nodules extended into the uterosacral ligaments, rectovaginal septum, and presacral fascia, with tethering of the rectum posteriorly.A meticulous nerve-sparing robotic dissection was performed with bilateral ureterolysis and development of the pararectal spaces. Following mobilisation of the rectovaginal nodule, successful discoid bowel excision and stapled closure were completed by the colorectal team. Intraoperative sigmoidoscopy and bubble leak testing confirmed bowel integrity without leakage. Complete excision of visible disease was achieved without intraoperative complications.

Conclusions

Single-port robotic surgery provides a precise minimally invasive platform for the management of advanced rectovaginal and bowel endometriosis. A multidisciplinary nerve-sparing approach can facilitate safe discoid bowel excision while preserving pelvic anatomy and bowel integrity in highly complex frozen pelvis disease. This technique also allows enhanced visualisation, meticulous dissection within distorted anatomy, and effective management of extensive parametrial and retroperitoneal disease with excellent postoperative recovery and symptom improvement.

https://player.vimeo.com/video/1199582224?autoplay=1

ESGE35-0143 - VP167
Video in ePoster

Surgical Management of Deep Endometriosis Causing Hemoperitoneum

Jeremy Biro[1], Jade Desilets[2], Olga Bougie[2]
[1]University of Saskatchewan, OBGYN, Regina, Canada
[2]Mount Sinai Hospital- University of Toronto, Gynaecology, Toronto, Canada

Background

The purpose of this case presentation is to demonstrate the surgical management of Stage IV Deep Infiltrating Endometriosis (DIE) complicated by recurrent catamenial hemoperitoneum, a rare and life-threatening manifestation. This video highlights the systematic approach required for complete excision in cases of total pelvic anatomical distortion.

Methods

The patient underwent a multidisciplinary laparoscopic radical excision involving Gynaecology and general surgery. Key procedural steps included the evacuation of a 4-liter hemoperitoneum, extensive ureterolysis to isolate critical structures, and the development of avascular spaces (Space of Retzius and pararectal/paravesical spaces). The surgical team performed a full-thickness bladder resection with a two-layer closure, a laparoscopic appendectomy, and aggressive "skinning" of multifocal bowel lesions to ensure total disease removal while maintaining mucosal integrity.

Results

Successful restoration of pelvic anatomy was achieved through the complete resection of all identifiable endometriotic plaques, including those involving the bladder dome, rectovaginal septum, and large bowel. Post-operative recovery was significant for the resolution of catamenial hemoperitoneum and a marked reduction in dysmenorrhea and hematuria. Although the patient initially experienced transient bladder irritability, normal urinary function was restored, and her hemoglobin levels stabilized.

Conclusions

Advanced Stage IV DIE presenting with massive hemoperitoneum requires a high index of suspicion and meticulous pre-operative planning. Systematic dissection, particularly the use of ureterolysis and a multidisciplinary surgical team, is essential for the safe and radical excision of disease. This case reinforces that complete surgical resection remains the gold standard for managing complex, life-threatening endometriosis phenotypes.

https://player.vimeo.com/video/1190982356?autoplay=1

ESGE35-0202 - VP168
Video in ePoster

Safe neuromonitoring-guided laparoscopic resection of a large presacral schwannoma: a stepwise surgical technique

Pornprom Ittiamornlert[1], *Felix Zeppernick*[2], *Maryam En-Nosse*[2], *Sebastian Harth*[3], *Malgorzata Kolodziej*[4], *Ivo Meinhold-Heerlein*[2]
[1]*Faculty of medicine- Siriraj Hospital- Mahidol University, Department of Obstetrics and Gynaecology, Bangkok, Thailand*
[2]*Justus-Liebig-University Giessen, Department of obstetrics and Gynaecology, Giessen, Germany*
[3]*Justus-Liebig-University Giessen, Department of Radiology, Giessen, Germany*
[4]*Justus-Liebig-University Giessen, Department of Neurosurgery, Giessen, Germany*

Background

To demonstrate safe, stepwise laparoscopic surgical techniques for resection of a large presacral schwannoma, highlighting the role of neuromonitoring in facilitating precise dissection and preservation of the sacral plexus.

Methods

We present a step-by-step surgical video of a 63-year-old woman with a slowly enlarging presacral mass over 15 years, presenting with pelvic pain and bilateral radicular symptoms, more prominent on the right side. MRI revealed a 12.7 × 6.9 × 7.7 cm retroperitoneal mass abutting the S1–S2 nerve roots with displacement of adjacent pelvic organs.

Neuromonitoring was established using spontaneous EMG of the external anal sphincter, bulbocavernosus, and lower extremities. A laparoscopic transabdominal approach was performed. Key surgical steps adequate organ mobilization for optimal exposure, precise identification of the tumor capsular plane, clear identification and preservation of critical structures, meticulous capsular plane dissection, and circumferential dissection from superficial to deep layers. Neuromonitoring-guided identification and preservation of sacral nerve roots facilitated complete tumor excision in a confined, nerve-dense presacral space.

Written informed consent for video recording and publication was obtained.

Results

Complete laparoscopic excision was achieved without conversion or complications. Operative time was 250 minutes with estimated blood loss of 120 mL. Neuromonitoring enabled preservation of sacral nerve roots. The postoperative course was uneventful, with no neurological deficits and preserved bowel and bladder function. The patient was discharged on postoperative day 5. Histopathology confirmed a benign schwannoma. At 1-year follow-up, she remained asymptomatic with no recurrence.

Conclusions

Despite the challenges of large, slow-growing tumors—including anatomical distortion, fibrosis, proximity to critical neural and visceral structures, and risk of presacral bleeding—neuromonitoring-guided laparoscopy enables precise dissection and preservation of the sacral plexus, supporting safe resection with minimal neurological morbidity.

https://player.vimeo.com/video/1191260698?autoplay=1